

Clinical and magnetic resonance analysis of varicella-zoster virus (VZV) transcranial nerve into brain-induced brainstem encephalitis

Jingzhe Han (✉ hanjingzhe2017@sina.com)

Harrison International Peace Hospital

Yanan Xie

The Second Hospital of Hebei Medical University

Zhilei Kang

Harrison International Peace Hospital

Huiqing Zhang

The Second Hospital of Hebei Medical University

Research article

Keywords: Varicella-zoster virus; Brainstem encephalitis; Retrograde; Magnetic resonance; Clinical

Posted Date: December 9th, 2019

DOI: <https://doi.org/10.21203/rs.2.18230/v1>

License:  This work is licensed under a Creative Commons Attribution 4.0 International License. [Read Full License](#)

Abstract

Background: In this study, we summarize the clinical and magnetic resonance characteristics of patients with varicella-zoster virus transcranial brain-induced brainstem encephalitis.

Methods: The patient's baseline data meet the inclusion criteria were collected. All patients were admitted to the hospital for routine blood, urine, and stool, blood glucose, blood pressure, blood lipids, homocysteine, liver function, renal function, electrolytes, eight items before the operation, autoantibodies, 24-hour dynamic EEG. All patients underwent a head MRI scan, and the patients underwent lumbar puncture, perfecting routine cerebrospinal fluid, biochemical and cytological examinations, and high-throughput examination of cerebrospinal fluid pathogens.

Result: Seven patients were enrolled in this study. All patients were associated with skin herpes in the area of cranial nerve distribution. Herpes is complicated with V-cranial nerve in 1 case, facial nerve (6 cases), vestibular nerve (5 cases), tongue pharynx, vagus nerve (1 case). The interval of central nervous system injury after 6 cases of skin herpes were 3-20 days. Laboratory and EEG examinations showed that all patients had no abnormalities in autoantibodies and preoperative eight items; low blood routines showed elevated white blood cells in 4 cases, elevated blood glucose in 4 cases, and abnormal liver function in 2 cases. Magnetic resonance imaging showed the disease involved 2 cases of the dorsolateral medulla, 6 cases with bridge arm, 1 case with multiple lesions, and 1 case without abnormal findings.

Conclusion: CZV-induced cranial nerve palsy and encephalitis can leave serious sequelae, even life-threatening, early diagnosis and early treatment are essential. For VZV infections confined to the cranial nerve, MRI is necessary even without evidence of brain stem injury, especially DWI sequences and 3D-CISS imaging can show extent of affected early cranial nerve.

1. Background

Varicella-zoster virus (VZV) is a member of the family Herpesviridae with the ability to establish latency in dorsal root-, autonomic-, cranial ganglia, and the infection can lead to the damaged of the cranial nerve [1–3]. Such as, the Ramsay Hunt syndrome (RHS), which characterized by peripheral facial nerve involvement, or encephalitis with the central nervous system (CNS) related signs and symptoms [4]. Kleinschmidtmasters B K et al. found that mild neurological sequela when the varicella-zoster virus causes varicella in children. After the varicella is digested, the virus is latent in the cranial and spinal ganglion neurons of almost all individuals. When the infected person getting older and immune function impaired, the virus may reactivate to produce herpes zoster. After herpes zoster has healed, many elderly patients develop postherpetic neuralgia. [5]. Thomas S et al. reviewed 282 patients with VZV reactivation, and they found that the trigeminal rash is the most common clinical manifestation, followed by a segmental rash, central nervous system infection, facial paralysis, post-herpetic neuralgia, and radiculitis. In addition, 1/4 patients with central nervous system infections and facial paralysis have no rash, and the infection can only be demonstrated by cerebrospinal fluid analysis. Although a small number of patients with a simple rash have mild inflammatory cerebrospinal fluid changes, the incidence of central nervous system infection and facial paralysis is significantly higher [6]. The study which coexistence of cranial nerve-damaged and VZV encephalitis is rare. VZV reaches the CNS by either retrograde axonal transport or through the bloodstream. Scattered inflammatory infiltrates along the intrapontine facial nerve from its nuclear origin within the caudal and lateral pons to its nerve root exit zone at the lateral pons have been described histologically. However, there are more patients with cranial nerve injury after VZV infection, but the brain stem is rare, and it is mostly reported in cases. Due to the lack of systematic clinical and imaging features and unclear pathogenesis of the VZV, the rate of missed diagnosis and misdiagnosis is high [7, 8].

Thus, this study trying to analysis the VZV transcranial brain-induced brainstem encephalitis in our department is as follows to understand the clinical features, magnetic resonance characteristics, treatment methods, and prognosis of VZV brainstem encephalitis. Through further research of VZV, we hope to promote cognition of the clinician's about this virus led to brainstem encephalitis and retrograde cranial brain stem encephalitis process and reduce the missed medical treatment process of patients.

2. Methods

2.1 Basic information about the patient's

Seven patients with regional herpes from cranial nerve distribution from January 2015 to May 2019 were selected as VZV brainstem encephalitis according to clinical manifestations, auxiliary examination and high-throughput sequencing of cerebrospinal fluid pathogens. There were six males and one female, aged from 41 to 72 years, mean 57.7 years, three cases (42.85%) over 65 years old. There were three cases (42.85%) of patients with diabetes mellitus, one case (14.29%) with long-term oral administration of hormones due to pemphigus history, two cases (28.57%) with hypertension, and one case of previous physical health. All patients had a history of herpes in the area of cranial nerve distribution before onset, and more details show in Table 1.

Table 1. Basic information of the patient's

Hyp: Hypertension; Type 2: 2 diabetes mellitus; Acy: Acycloguanosine; WBC: White Blood Cell.

2.2 Detection method

All patients were admitted to the hospital for routine examination of routine blood, urine, and stool, blood glucose, blood pressure, blood lipids, homocysteine, liver function, renal function, electrolytes, preoperative eight, autoantibodies, and 24-hour dynamic EEG. All patients underwent a head MRI scan, including T1WI, T2WI, FLAIR, and DWI sequences. One patient also underwent facial nerve 3D-CISS imaging with plain scan + enhancement. All patients underwent a lumbar puncture to improve routine, biochemical, and cytological examination of cerebrospinal fluid. Simultaneous high-throughput measurement of cerebrospinal fluid pathogens (extracting nucleic acids in cerebrospinal fluid and establishing DNA amplification libraries, sequencing of gene libraries, identifying and excluding human sequences, and further using Soap Coverage software to identify viruses, bacteria, fungi, and parasites the genetic sequence) is checked.

3. Result

3.1 Clinical characteristics

All patients were associated with skin herpes in the cranial nerve distribution area, including one case (14.29%) with herpes involvement of the V-cranial nerve, and the left mandibular branch; Six cases (85.71%) involving the facial nerve, including one involving the intercostal nerve; There were five cases of vestibular nerve (71.43%); One case (14.29%) involving tongue pharynx and vagus nerve, which involved VII cranial nerve. Five cases of external ear canal herpes met the diagnostic criteria of RHS (71.43%). One case of herpes perioral, one case of herpetic esophagitis. The interval of central nervous system injury after 6 cases of skin herpes was 3–20 days, which one case was critical, and the interval was unknown. Three patients were treated with cranial nerve injury; two patients were treated with disturbance of consciousness; two patients were treated with unstable walking. There were two cases of meningeal irritation positive (28.57%), one case of the seizure (14.29%), three cases of cerebellar ataxia (42.86%), and one case of pyramidal tract sign (14.29%), more details show in Table 1.

3.2 Laboratory and EEG examination

Blood routine show white blood cells increased in four cases (57.14%), blood glucose increased in four cases (57.14%), liver function abnormalities in two cases (28.57%), all patients had no abnormalities in autoantibodies and preoperative eight items. One case of hyponatremia and hypochloremia. Two cases of abnormal EEG (28.57%), suggesting epilepsy discharge.

3.3 Magnetic resonance examination

No./Patient	1	2	3	4	5	6	7
Age (year)	66	41	72	69	52	48	56
Gender	Male	Male	Male	Male	Male	Male	Female
Risk factor	Hyp	Type 2	Hyp	Type 2	Health	Oral hormone	Type 2
Clinical Features							
Disturbance of Consciousness	No	No	Yes	Yes	No	No	No
Pyramidal Sign	No	No	Yes	No	No	No	No
Cerebellar Ataxia	No	Yes	Unable to Cooperate	No	Yes	Yes	Yes
Meningeal Irritation	No	No	Yes	Yes	No	No	No
Epilepsy	No	No	Yes	Yes	No	No	No
Cranial Nerve Involvement							
V	-	-	-	-	+	-	+
VII	+	+	+	+	-	+	+
VIII	-	+	-	+	-	+	-
IX	+	-	-	-	-	-	-
X	+	-	-	-	-	-	-
Hunt Syndrome	No	Yes	Yes	Yes	No	Yes	Yes
Treatment	Acy	Acy	Acy, γ -globulin, Hormone	Acy, Hormone	Acy	Acy, Hormone	Acy
Initial Symptoms	Viral Esophagitis	Herpes (Left Ear)	Herpes (Right Ear)	Herpes (Left Ear)	Herpes (Left Mouth)	Herpes (Right Ear)	Herpes (Left Ear)
Central Nervous Injury Interval	20d	3d	No	5d	6d	10d	5d
Copy Sequence Number of VZV	14	424	20161	4	18	86	322
Pressure	160	126	>300	100	180	116	176
WBC ($\times 10^6/L$)	32	48	567	24	16	10	86
Protein (g/L)	0.68	0.54	11.36	0.32	0.44	0.36	0.58
Blood sugar	-	-	Reduce	-	-	-	-
Chloride	-	-	Reduce	-	-	-	-

Cytology	Lymphocyte reaction	Lymphocyte reaction	Mixed cell reaction	Lymphocyte reaction	Lymphocyte reaction	Lymphocyte reaction	Lymphocyte reaction
----------	---------------------	---------------------	---------------------	---------------------	---------------------	---------------------	---------------------

All patients underwent MRI. Patient 1 showed left medulla, left bridge with patchy long T1 and long T2 signals, Flair showed high signal, and DWI showed high signal (Fig. 1). Patient 2 showed patchy long T1 and long T2 signals on the left side of the bridge, Flair showed high signal, DWI showed high signal (Fig. 2); 3D-CISS imaging showed facial nerve, vestibular sacral swelling, facial nerve and vestibular nerve walking area DWI visible high Signal shadow (Fig. 3). 3D-CISS imaging enhancement showed visible enhancement of the facial nerve and vestibular nerve in the medial auditory canal. Patient 3 shows abnormal signals in the brainstem and cerebellum (Fig. 4). Patient 4 shows patchy T1 and long T2 signals on the right side of the bridge, the Flair and DWI is high (Fig. 5). Patient 5 shows the left and right T2 signals. The Flair is high, and DWI is slightly higher (Fig. 6 and Fig. 7). Patient 6 showed long T1 and long T2 signals on the left medulla of the left medulla, Flair showed a high signal, and DWI showed a high signal (Fig. 8). Patient 7 MRI plain scan showed no abnormalities, but the patient had symptoms and signs of bridge arm damage, but the family refused to perform 3D-CISS examination (plain scan + enhancement) (Fig. 9). The comprehensive analysis included two cases (28.57%) of the dorsolateral medulla, six cases (85.71%) involving the bridge arm, one case (14.29%) with multiple lesions, and 1 case (14.29%) without abnormal findings.

3.4 Cerebrospinal fluid examination.

All patients were completed with a lumbar puncture (referred to as lumbar puncture) cerebrospinal fluid examination. All patients were examined for a lumbar puncture at 2–5 days after onset. The cerebrospinal fluid pressure is 100–300 mm H₂O (condition limit, up to 300 mmH₂O, only 1 patient). The number of white blood cells in the cerebrospinal fluid of all patients is increased, mainly due to the increase of lymphocytes; cerebrospinal fluid protein is increased to varying degrees. Among them, 6 cases were consistent with viral encephalitis (85.71%). One patient had normal, biochemical and cytological changes in cerebrospinal fluid similar to “tuberculous meningitis” (14.29%). All patients were confirmed to be VZV infection by cerebrospinal fluid pathogen Metagenomic next-generation sequencing (mNGS), and the detection of VZV DNA sequence is 4-20161.

3.5 Treatment and prognosis

The patients in this group were treated with standardized acyclovir antiviral therapy for ten days to 4 weeks after admission, supplemented with mannitol and symptomatic supportive care. Hormone (prednisone acetate 60 mg) was treated in three patients, and intravenous immunoglobulin was administered in one patient (0.4 g/kg, 5 days). Four patients had peripheral facial paralysis, and dizziness left on discharge; one patient had difficulty swallowing; one patient left the left Horner sign; one patient died.

4. Discussion

VZV is highly contagious and can be transmitted through respiratory droplets or direct contact with infected skin lesions [9–11]. VZV is neurotropic and which can be lurking in the neurons of the posterior root ganglia of the spinal cord for a long time after infection. When the infected people have lower resistance, tired, or re-infection, the virus can grow and reproduce and move along the nerve fibers to the skin [7]. When VZV causes to a rash, or alongside the nerve into the central nervous system and led to a retrograde infection which can cause complications such as brainstem encephalitis, meningitis, myelitis, and acute cerebrovascular disease. The elderly (greater than 65 years old) or immune dysfunction persons are common in VZV secondary infections [5, 12]. Among the patients in this group, three were elderly patients, three patients with diabetes, and one patient had long-term oral hormones, which basically met the above-mentioned pathogenesis. Nerve VZV can be invaded into the skull through the nerve and can be invaded by meninges and brain parenchyma [13, 14]. Two patients in this group were treated with disturbance of consciousness, two were positive for meningeal irritation, and six patients with MRI showed central nervous system injury, suggesting that both brain parenchyma and meninges were affected. Most patients often have a typical herpes-like rash several days before the onset of the disease. In this group, seven patients had rashes at different

locations before the disease, mainly in the cranial nerve distribution area, and the time from herpes to central nervous system damage occurred 3-20d range, basically in line with the body's regular elimination of the virus's immune cycle, suggesting that secondary infection caused by the activation of VZV, early to give adequate, full course of antiviral therapy is necessary. The study found that patients with cranial herpes zoster were more likely to have central nervous system damage. The seven patients in this group were basically consistent with the report. VZV invasion of the cranial nerve can lead to different neurological syndromes, such as RHS syndrome. Typical RHS involved unilateral peripheral facial nerve palsy accompanied by erythematous vesicular lesions on the ear. Frequently the VIII cranial nerve can be also involved, and rarely the V, VI, IX, X, XI, and XII cranial nerves can be affected and cause extraocular movement limitations, facial sensorimotor changes, bulbar dysfunction, and neck weakness [15, 16]. The typical clinical manifestations of this group of five patients with post-auricular pain, posterior herpes zoster, and ipsilateral nerve paralysis meet the diagnostic criteria of RHS, suggesting VZV Trigeminal nerves and vestibular nerves are the most likely to cause brainstem encephalitis and are considered to be associated with specific anatomical structures of the geniculate ganglia.

Cranial nerve 3D-CISS imaging or enhancement can clearly show the cranial nerve shape and injury, which can significance clearly show the VZV-induced cranial nerve injury segment and location [16, 17]. Patient 2 has RHS as the first symptom. 3D-CISS imaging shows swelling of the left vestibular nerve and facial nerve, thickening; enhancement of the inferior facial nerve and vestibular nerve enhancement in the internal auditory canal, support for the facial nerve and vestibular nerve and the inner auditory canal VZV violation. Transverse hyperintensities in central pons on T2 and FLAIR substantially showed the signal changes in the left vestibular nucleus and along the vestibulocochlear nerve, so patient 2 can also be diagnosed with VZV brainstem encephalitis according to CSF evidence of VZV and pontobulbar involvement on brain MRI. The possible pathogenesis of the patient brainstem encephalitis is that after VZV, which is latent in geniculate ganglia, is activated, retrograde invasion of geniculate ganglia-into the cranial-involving facial nerve, vestibular cochlear nerve - ascending to the facial nucleus, vestibular nuclei, anterior and posterior Nuclear group. The study found that virus invading nerve cells can cause cell swelling and necrosis, which is characterized by diffusion limitation and high signal in the DWI sequence. The DWI imaging of this patient is characteristic, and DWI shows high signal changes in the left intrapontine facial nerve, facial nerve, vestibular nucleus and along the vestibulocochlear nerve, suggesting acute infection of VZV, and also clearly showing the VAS of the acute phase VAV via the vestibular and facial nerves. At the same time, the complex anatomical relationship in the region is clearly demonstrated. In addition, brainstem injuries in 6 patients showed high or slightly higher DWI signals. Patient 4 had no abnormal findings in the MRI scan, but the patient's facial sacral nose test and the knee sac test were not stable, suggesting the possibility of left bridge arm and cerebellum involvement, head MRI plain scan, possible and imaging examination. The timing is related to the selected layer thickness, and it is regrettable that the patient's family refused further magnetic resonance enhancement and thin scan examination due to economic factors. The MRI of patients with patient 3 showed paroxysmal involvement, and the multiple abnormal signals in the brainstem, bridge arm, and cerebellum. Although the patient did not undergo 3D-CISS imaging examination, the bridge arm was severely affected, and it is considered that VZV is more likely to be invaded by facial nerve or vestibular nerve. The patient did not receive any treatment for RHS, the final lesion spread, the patient died. We considering the possibility of the patient's age and the patient's own attention to the RHS syndrome is not enough. The patient 6 and the patient 7 showed an abnormal signal of the bridge arm, suggesting the possibility of viral invasion through the facial nerve or vestibular nerve. Patient 5 had a history of left-sided herpes simplex before the disease. The head MRI showed a patchy long T1 and long T2 signal on the dorsolateral side of the left medulla, Flair showed a high signal, and DWI showed a slightly high signal. The imaging height was similar to dorsolateral medullary syndrome. However, the patient lacks the key symptoms and signs of a medullary dorsolateral syndrome such as dysarthria, dysphagia, and finally, VZV brainstem encephalitis confirmed by lumbar puncture. The patient's medullary magnetic resonance findings were associated with trigeminal semilunar ganglion latent VZV retrograde cranial-induced trigeminal spinal nucleus damage and axons. Patient 1 was diagnosed with difficulty in swallowing. Gastroscopy showed multiple ulcers of the esophagus (viral possibility). The head MRI showed patchy long T1 and long T2 signals on the left medulla of the left medulla, Flair showed a high signal, and DWI showed a high signal. The patient's magnetic resonance imaging was also similar to the dorsolateral medullary syndrome, but the patient also had typical features such as painless temperature-sensing disorder, ataxia, and Homer's sign. Left peripheral facial paralysis occurred during treatment. The review head MRI showed

that the left side of the bridge arm had a new patchy long T1 and long T2 signal, and the Flair and DWI high signal shadows. Finally, it was confirmed by brainstem encephalitis. The VZV invasion pathway of this patient is not completely clear, and the possible pathogenesis is presumed: (1) VZV is retrograde into the skull through the lingual pharynx and vagus nerve, to the dorsolateral medulla and spread to the dorsal lateral nerve nucleus of the bridge arm. (2) VZV lurks in the trigeminal genic ganglia. After activation, the nerve junction of the facial nerve and the pharyngeal and vagus nerves invades the pharyngeal and vagus nerves. According to Hunt theory, VZV involves both the facial nerve and the vestibular nerve) achieved by the geniculate ganglion. The clinical manifestations and imaging features of the above 2 cases of VZV infection are easily misdiagnosed as a medullary dorsolateral syndrome. Thus, when clinically encountered atypical medullary dorsolateral syndrome lacking key signs such as dysphagia, ataxia, Horner's sign, especially combined when exposure the patient's who facial herpes, be alert to the possibility of VZV brainstem encephalitis. Comprehensive analysis of the bridge arm, the dorsolateral medulla is vulnerable to VZV invasion, retrograde infection of cranial nerves are facial nerve, the vestibular nerve, and trigeminal nerve.

The cerebrospinal fluid examination is crucial for the diagnosis of this type of patients [18–20]. The cerebrospinal fluid leukocytes in 7 patients are elevated to varying degrees. The cerebrospinal fluid cytology suggests lymphocyte reaction, and the protein is increased to varying degrees, suggesting an inflammatory response. The routine, biochemical, and cytological changes of cerebrospinal fluid in this group of patients were consistent with the typical "viral encephalitis" changes. The number of cells in the rat cerebrospinal fluid increased significantly, the protein increased significantly, the sugar and chloride decreased, and the intracranial pressure was greater than 300. It suggests tuberculous meningitis, but pathogen screening suggests VZV infection. The patient has severe symptoms, multiple intracranial lesions, and eventually die. Considering the causes of cerebrospinal fluid changes similar to tuberculous meningitis in this patient are as follows: (1) The body contains a large amount of poison (VZV detection sequence number 20161), brain tissue damage is serious, blood-brain barrier damage is serious, resulting in increased cell number, protein, and intracranial pressure; low chloride in the cerebrospinal fluid may be associated with low blood chlorine; (2) Is there a possibility of tuberculosis infection, but no evidence is found for pathogen screening and a related tuberculosis screening, but the patient is also treated with anti-tuberculosis during treatment. The routine cerebrospinal fluid examination has little significance for the diagnosis of intracranial infection pathogens. NGS is a novel approach to DNA/RNA sequencing, and it can amplify and sequence the entire DNA content of a sample without using any primers or probes. NGS of CSF is a time-saving, accurate, and specific diagnostic tool for CNS viral infection. Compared with traditional clinical diagnosis, NGS can significantly shorten the diagnosis cycle and achieve an early and accurate diagnosis. Using NGS of CSF, all patients confirmed VZV infection.

At present, there is no fixed pattern for the treatment of such diseases, but early administration of a sufficient amount of antiviral therapy, depending on the degree of damage and severity of the disease, the addition of hormones and intravenous injection of human immunoglobulin is necessary [7, 21, 22]. VZV invasion is different from vascular disease, because of the protective effect of the myelin sheath, early viral infection can't invade adjacent structures for a while, so the imaging performance is limited, but once the brain stem and brain parenchyma damage occur, the recovery period will be significantly prolonged [23, 24]. According to a case report, these patients have an excellent long-term prognosis and are qualified for daily work. Although six patients in this group had residual or mild or severe neurological deficits at discharge, except for the intracranial spread of Patient 3VZV, most of the patients had no spread of VZV infection, and the clinical prognosis was relatively good. Unfortunately, the patients were not long-term prognosis evaluated accordingly.

5. Conclusion

The cranial nerve palsies and encephalitis caused by VZV can leave severe sequelae and even Threaten life, early diagnosis, early treatment is essential. VZV activation can be a cranial nerve distribution area herpes, such as RHS, perioral herpes, etc. as the first performance, without any brain stem damage and symptoms and signs of encephalitis. VZV-induced brainstem encephalitis is susceptible to the bridge arm and the dorsolateral medulla, and MRI can be displayed. Therefore, for some VZV infections confined to the cranial nerve, MRI is necessary even without evidence of brain stem injury, especially the DWI sequence. And 3D-CISS imaging can show the extent and extent of the affected cranial nerve at an early stage, provide

evidence of VZV incision, play a warning role for VZV into the skull, and judge the necessity of further lumbar puncture. In addition, when patients with atypical medullary dorsolateral syndrome are clinically encountered, especially in the recent history of herpes in the area of the cranial nerve distribution, it is necessary to be alert to the possibility of VZV brainstem encephalitis. It is essential to take high-throughput sequencing of cerebrospinal fluid pathogens in time.

Abbreviations

VZV

Varicella-zoster virus; RHS:Ramsay Hunt syndrome; CNS:central nervous system.

Declarations

Ethics approval and consent to participate: This study was approved by the institutional review board and ethics committee of Harrison International Peace Hospital.

Consent for publication: Written informed consent was obtained from the patient for publication of this manuscript.

Competing interests: The authors declare that they have no competing interests.

Availability of data and material: The datasets used and/or analyzed during the current study are available from the corresponding author on reasonable request..

Funding: Not applicable.

Authors' contributions: JZH, YNX made substantial contributions to conception and design; ZLK made substantial contributions to acquisition of data; HQZ made substantial contributions to analysis and interpretation of data; JZH, YNX have been involved in drafting the manuscript or revising it critically for important intellectual content; All authors given final approval of the version to be published. Each author should have participated sufficiently in the work to take public responsibility for appropriate portions of the content; All authors agreed to be accountable for all aspects of the work in ensuring that questions related to the accuracy or integrity of any part of the work are appropriately investigated and resolved.

Acknowledgement: Not applicable.

References

1. Ryu J, Park KA, Oh SY, *et al* (2017) Periopic neuritis related with varicella-zoster virus infection preceding sixth cranial nerve palsy and progressive outer retinal necrosis in a immunocompetent patient. *Journal of the Neurological Sciences* 373:155-56.
2. Androudi S (2012) Varicella zoster Virus. *Acta Ophthalmologica* 89(s248):0-0.
3. Sauerbrei A (2016) Diagnosis, antiviral therapy, and prophylaxis of varicella-zoster virus infections. *European Journal of Clinical Microbiology & Infectious Diseases* 35(5):723-34.
4. Haginomori SI, Ichihara T, Mori A, *et al* (2016) Varicella-zoster virus-specific cell-mediated immunity in Ramsay Hunt syndrome. *Laryngoscope* 126(1):E35-E39.
5. Kleinschmidt-Demasters BK, Gilden DH (2001) Varicella-Zoster virus infections of the nervous system: clinical and pathologic correlates. *Archives of Pathology & Laboratory Medicine* 125(6):770.
6. Skripuletz T, Pars K, Schulte A, *et al* (2018) Varicella zoster virus infections in neurological patients: a clinical study. *Bmc Infectious Diseases* 18(1):238.
7. Grahn A, Studahl M (2015) Varicella-zoster virus infections of the central nervous system – Prognosis, diagnostics and treatment. *Journal of Infection* 71(3):281-93.

8. Gershon AA, Breuer J, Cohen JI, *et al* (2015) Varicella zoster virus infection. *Nature Reviews Disease Primers* 1(2):15016.
9. Sawyer MH, Chamberlin CJ, Wu YN, *et al* (1994) Detection of Varicella-Zoster Virus DNA in Air Samples from Hospital Rooms. *Journal of Infectious Diseases* 169(1):91-94.
10. Brody MB, Moyer D (1997) Varicella-zoster virus infection. *Postgraduate Medicine* 102(1):187-94.
11. Jarosinski KW, Carpenter JE, Buckingham EM, *et al.* (2018) Cellular Stress Response to Varicella-Zoster Virus Infection of Human Skin Includes Highly Elevated Interleukin-6 Expression. *Open Forum Infectious Diseases* 5(6): ofy118.
12. Arvin A (2005) Aging, immunity, and the varicella-zoster virus. *New England Journal of Medicine* 352(22):2266.
13. Long SS (2014) Neurologic complications of varicella-zoster virus infection still occur. *Journal of Pediatrics* 165(4):647-49.
14. Flynn T, Ackert J (2017) Herpes Simplex and Herpes Zoster.
15. Kleinschmidt-Demasters BK, Gildeen DH (2001) Varicella-Zoster Virus Infections of the Nervous System. *Archives of Pathology & Laboratory Medicine* 125(6):770.
16. Jo YR, Chung CW, Lee JS, *et al* (2013) Vernet Syndrome by Varicella-Zoster Virus. *Ann Rehabil Med* 37(3):449-52.
17. Carpenter JE, Clayton AC, Halling KC, *et al* (2015) Defensive perimeter in the central nervous system: predominance of infected astrocytes and astrogliosis during recovery from varicella-zoster virus encephalitis. *Journal of Virology* 90(1):379.
18. Cinque P, Bossolasco S, Vago L, *et al* (1997) Varicella-zoster virus (VZV) DNA in cerebrospinal fluid of patients infected with human immunodeficiency virus: VZV disease of the central nervous system or subclinical reactivation of VZV infection? *Clinical Infectious Diseases* 25(3):634-39.
19. Burgoon MP, Hammack BN, Owens GP, *et al* (2010) Oligoclonal Immunoglobulins in Cerebrospinal Fluid during Varicella Zoster Virus (VZV) Vasculopathy Are Directed against VZV. *Annals of Neurology* 54(4):459-63.
20. Depledge DP, Cudini J, Kundu S, *et al* (2018) High Viral Diversity and Mixed Infections in Cerebral Spinal Fluid From Cases of Varicella Zoster Virus Encephalitis. *The Journal of infectious diseases* Oct 5;218(10):1592-601.
21. Straus SE, Ostrove JM, Inchauspé G, *et al* (1988) NIH conference. Varicella-zoster virus infections. Biology, natural history, treatment, and prevention. *Annals of Internal Medicine* 108(6):221-37.
22. Shigeta S, Clercq ED (1988) Treatment (Bromovinyldeoxyuridine) of Varicella-Zoster Virus Infections.
23. Nagel MA, Gildeen D (2016) Developments in Varicella Zoster Virus Vasculopathy. *Current Neurology & Neuroscience Reports* 16(2):12.
24. Nagel MA, Jones D, Wyborny A (2017) Varicella zoster virus vasculopathy: The expanding clinical spectrum and pathogenesis. *Journal of Neuroimmunology* 308:112-17.

Figures

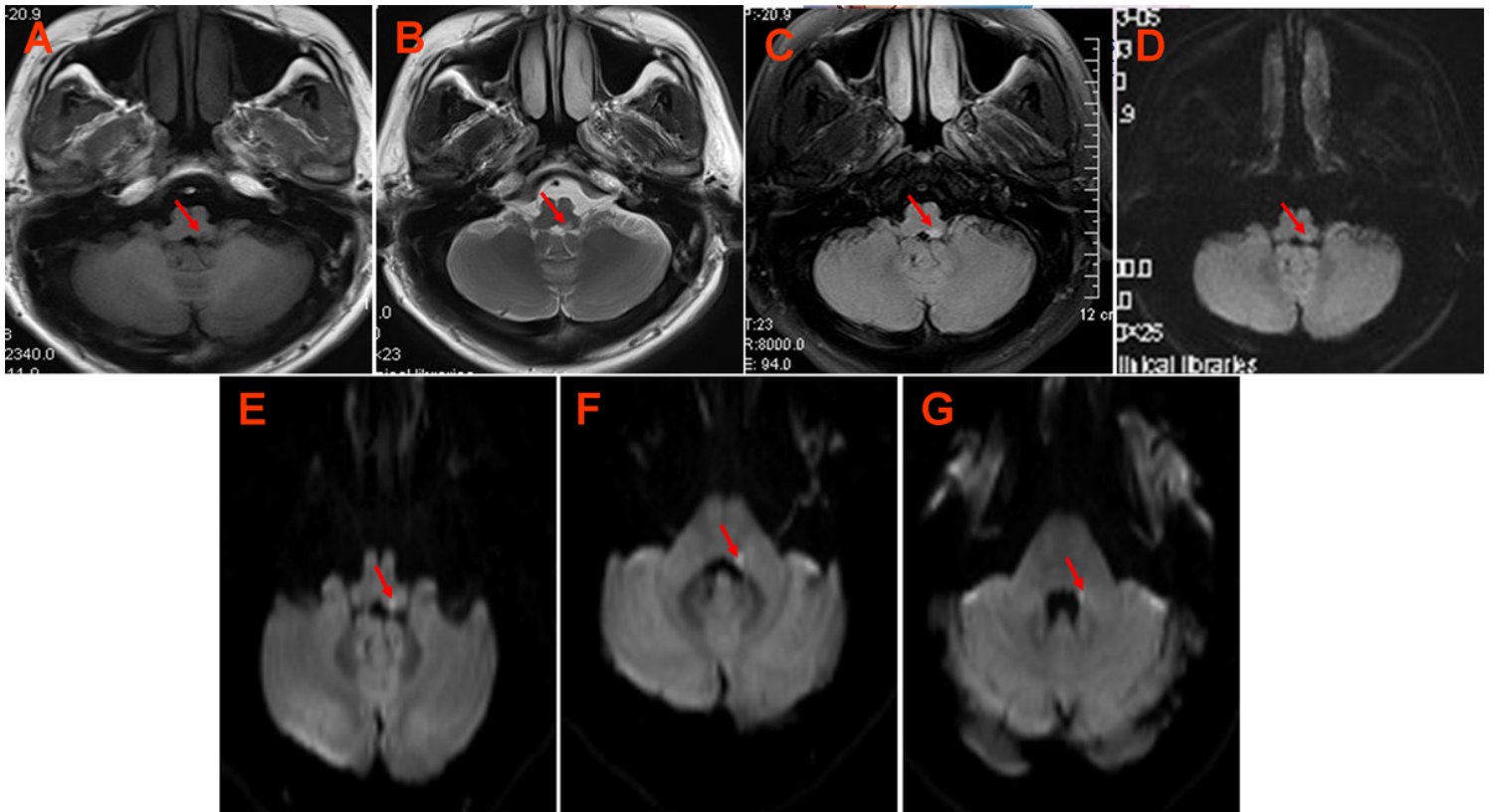


Figure 1

Patient 1: The patient was admitted to the hospital due to unclear speech and difficulty in swallowing. The MRI showed that the left medulla had a patchy long T1 and long T2 signal on the dorsolateral side of the medulla, Flair showed a high sign, and DWI showed a high signal (A-D). On the 7th day after admission, the left peripheral facial paralysis appeared. The MRI showed a patchy DWI with high signal intensity (E-G) on the left medulla and left arm.

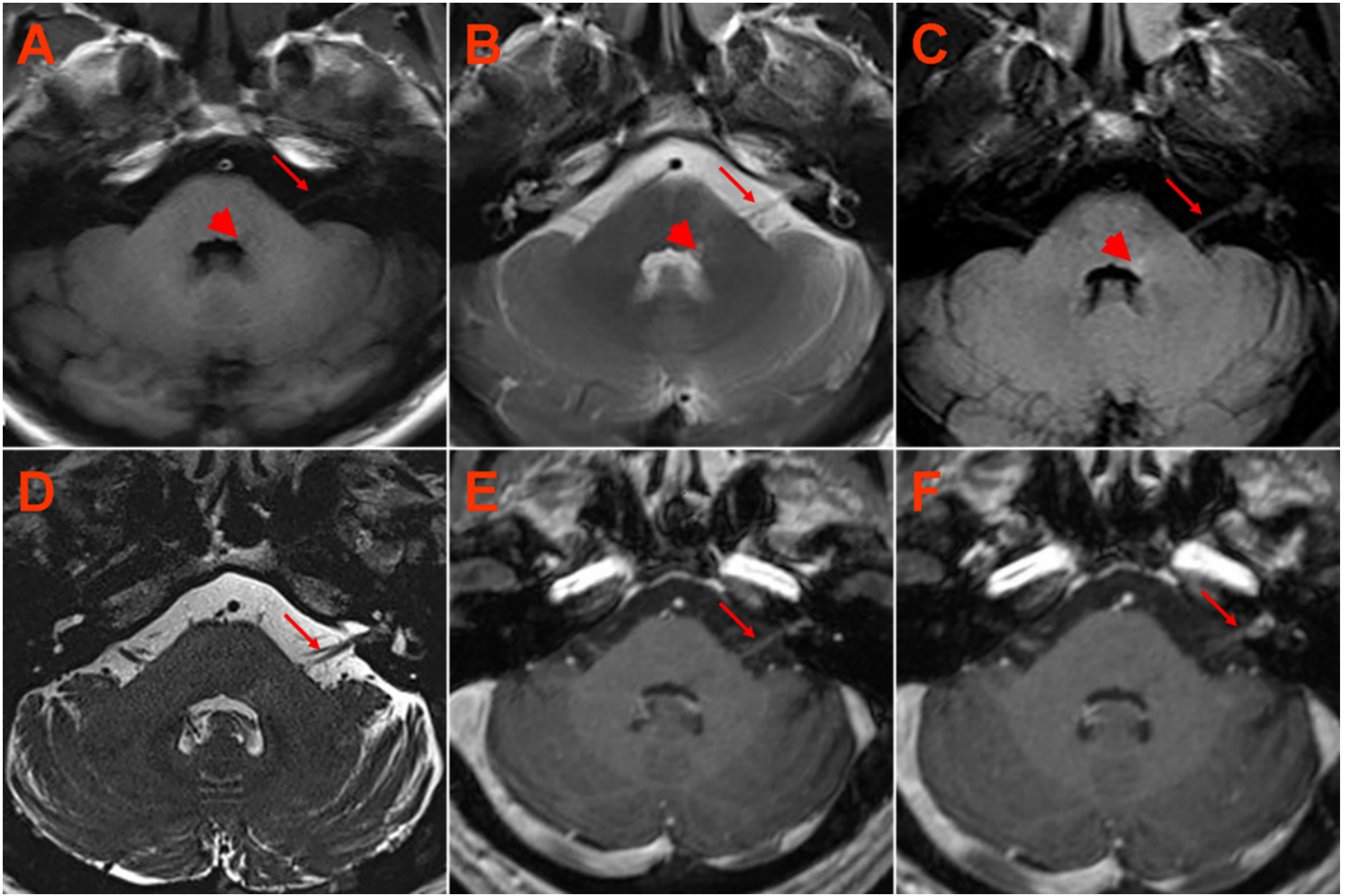


Figure 2

Patient 2: The patient's primary cause was skewed for 7 days, and dizziness accompanied by left ear herpes was admitted to the hospital for 3 days. On the head of the hospital, MR showed the patchy long T1 and long T2 signals on the left arm, Flair showed high signal (A-C); 3D-CISS imaging showed facial nerve and vestibular cochlear swelling (D). Head MRI enhancement showed that the facial nerve and vestibular nerve in the auditory canal showed enhanced enhancement, and the brain stem showed no abnormal improvement signal (E-F).

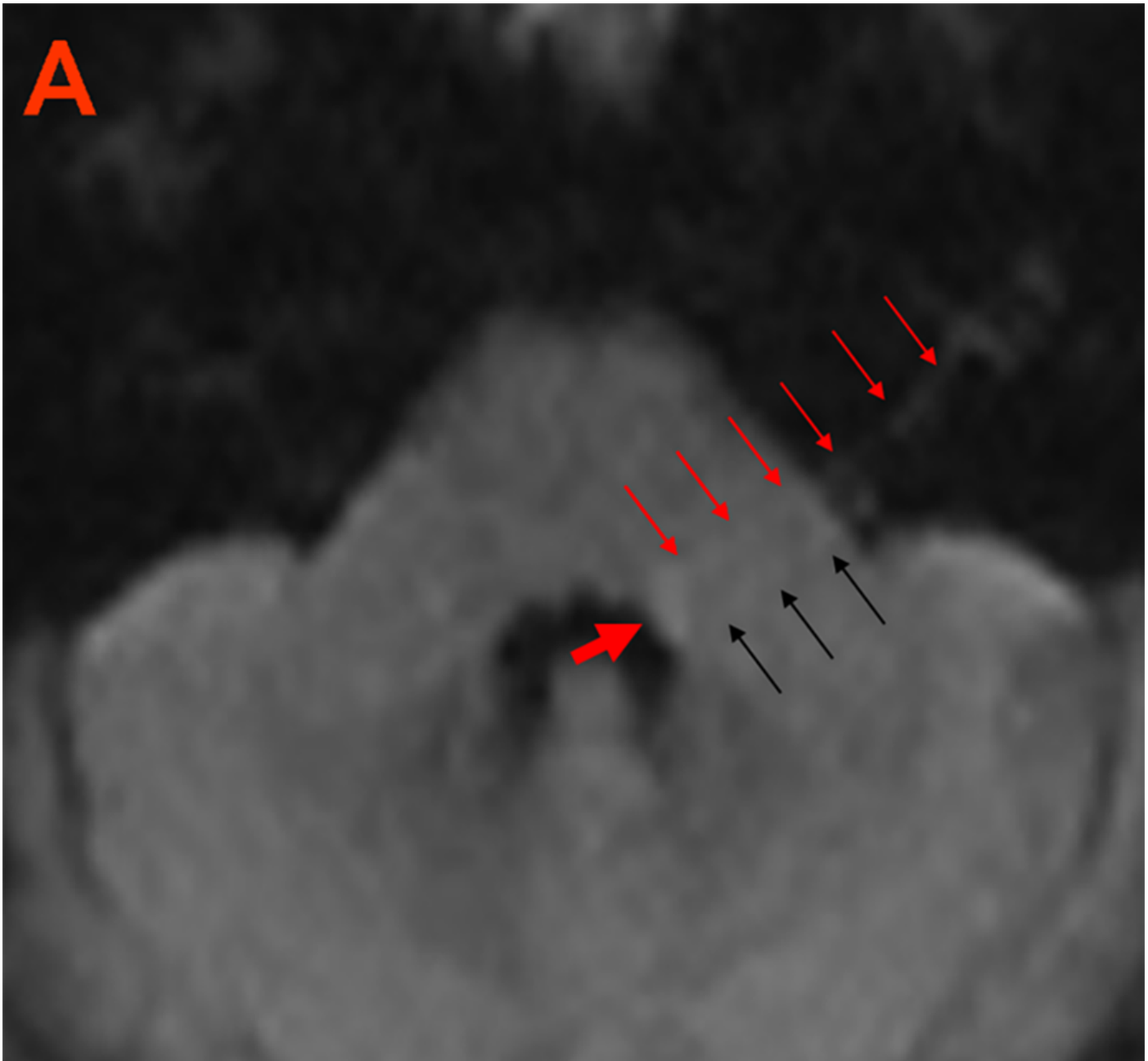


Figure 3

Patient 2: On the facial nerve floor, the DWI sequence shows a high signal on the left side of the bridge arm and the facial nerve, the primary damage to the vestibular nuclei (red thick arrow); the facial nerve pons, the high signal of the cerebral segment (red long arrow); the vestibular pons segment high signal (black long arrow).

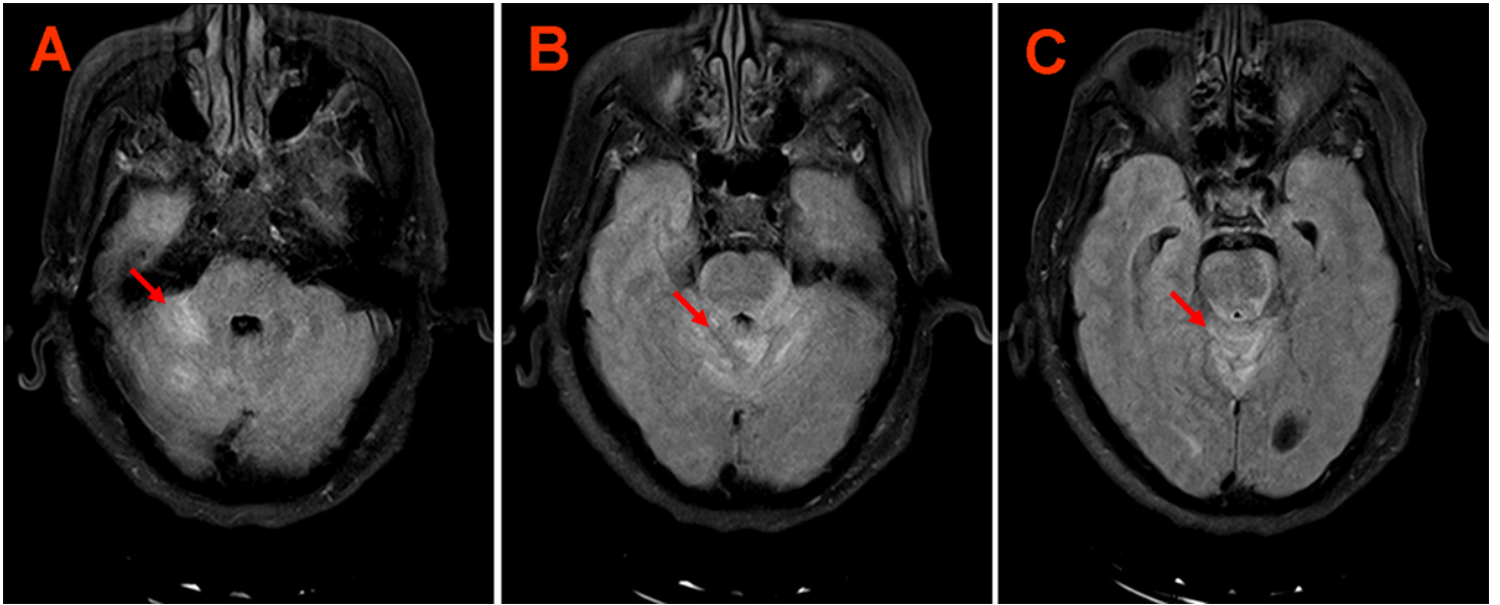


Figure 4

Patient 3: The patient was admitted to the hospital with a headache for five days and was unconscious for one day. The MRI of the head showed multiple abnormal signals (A-C) in the brainstem and cerebellum.

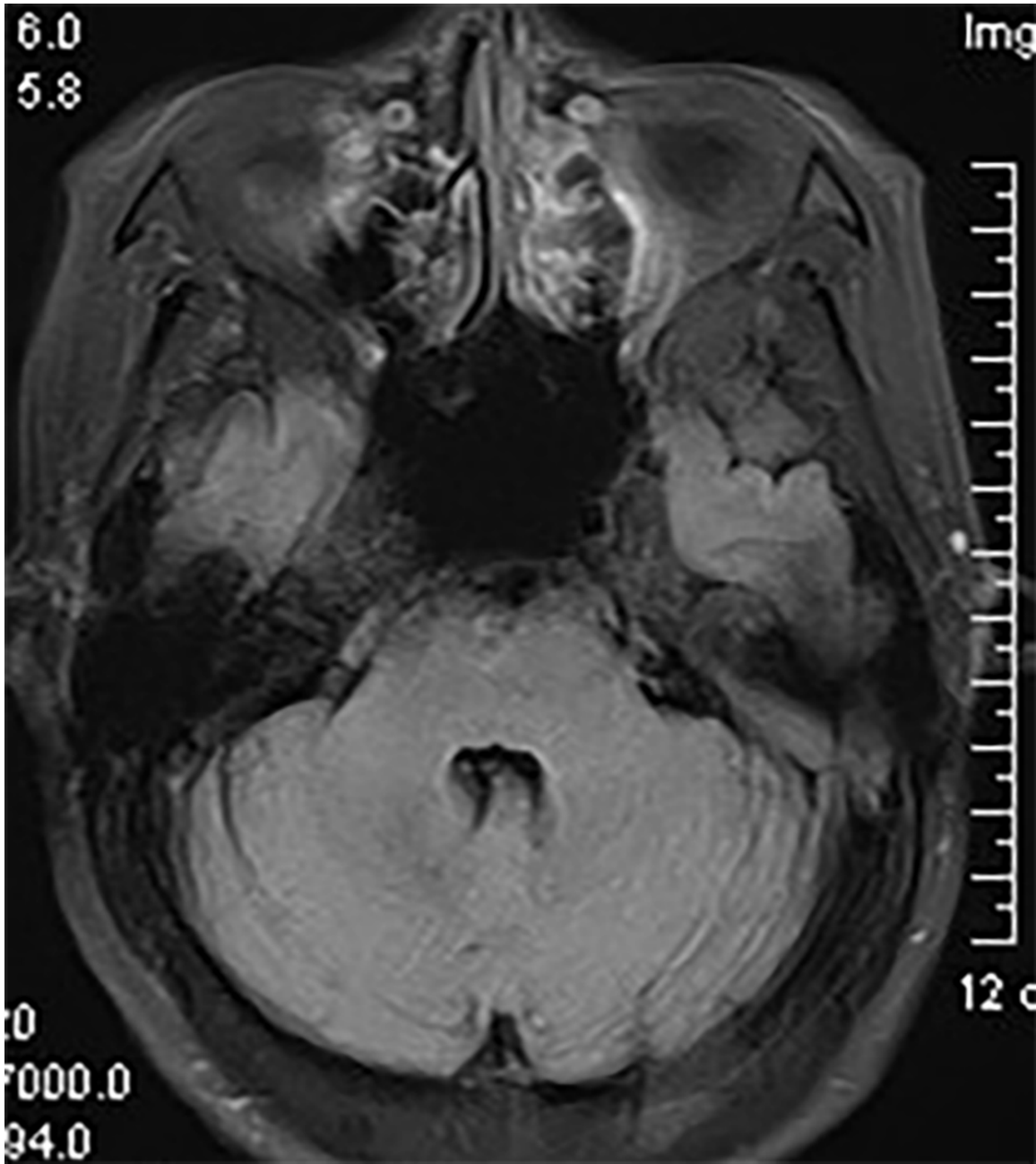


Figure 5

Patient 4: The patient was admitted to the hospital with a speech disorder for three days, and no evident responsibility lesions were found in the head MRI.

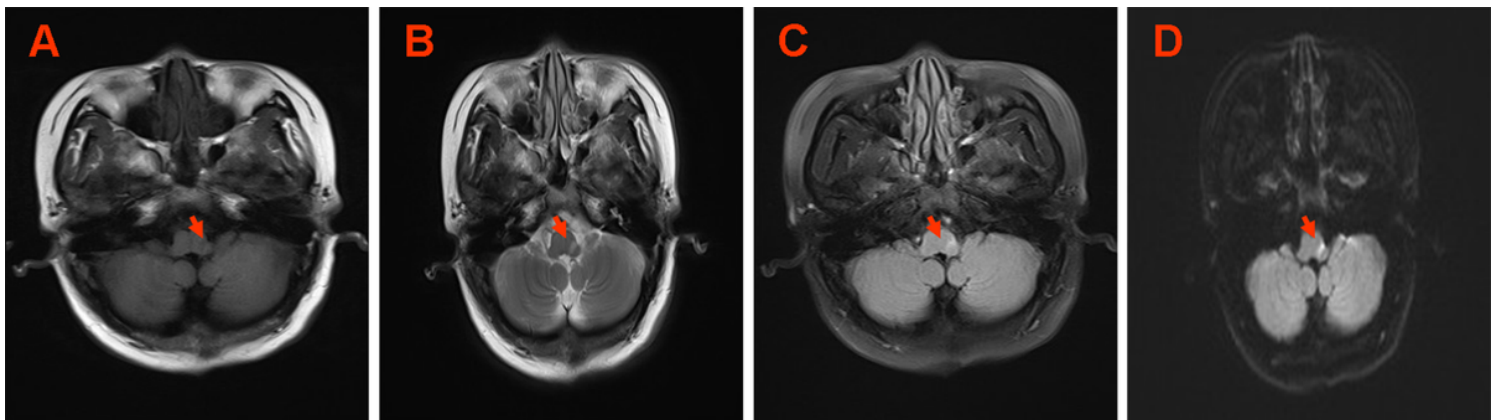


Figure 6

Patient 5: The patient was admitted to the hospital due to walking left, and MRI showed that the left medulla had a patchy long T1 and long T2 signal on the dorsolateral side of the medulla, Flair showed a high signal, and DWI showed a high signal (A-D).

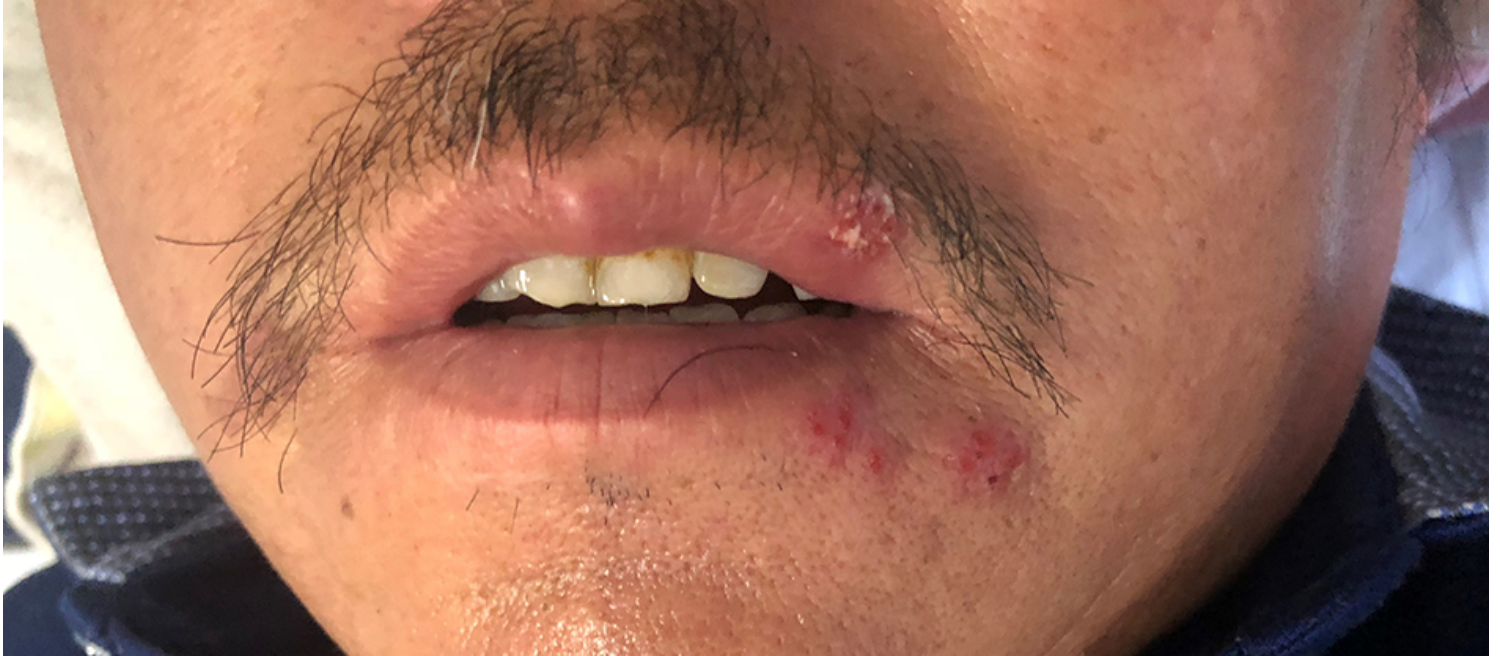

Figure 7

Patient 5: The patient's Left lip of can be seen with herpes.

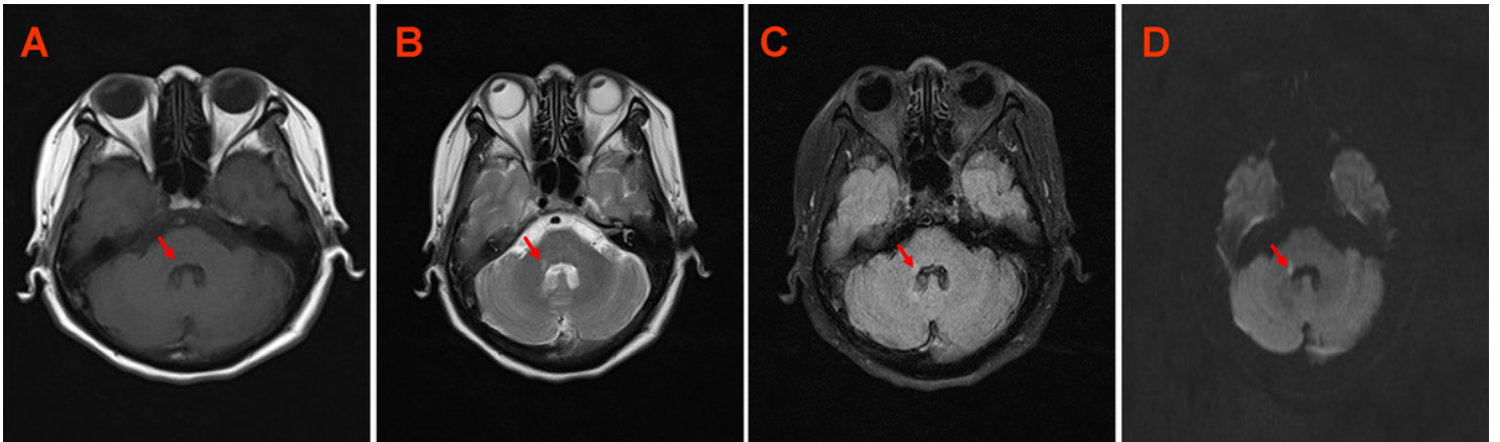


Figure 8

Patient 6: The patient was admitted to the hospital with a three-day slanting angle. The physical examination revealed a peripheral facial paralysis. The MRI showed a long T1 and long T2 signal on the right side of the bridge. The Flair showed a high message, and the DWI showed a high sign.

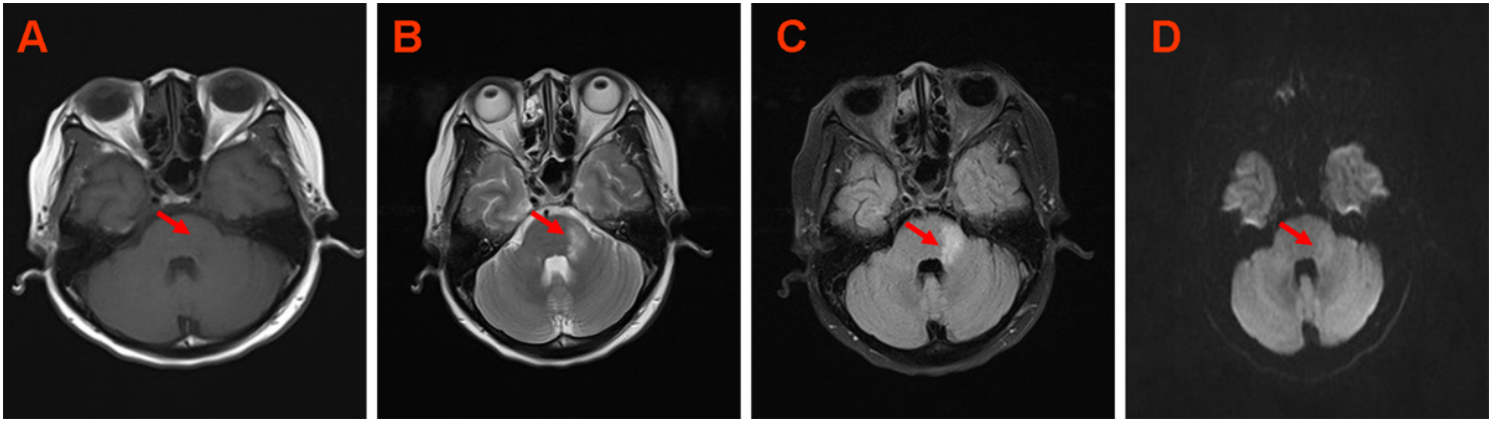


Figure 9

Patient 7: The patient's primary cause was skewed by the angle of the mouth. He was admitted to the hospital on the left side for five days. The left side of the facial nerve was paralyzed, and the left finger nose test and the knee joint test were not stable. The head MRI showed: the left side of the bridge arm was patchy long T1, high T2 signal, Flair showed a high sign, and DWI showed a high message.