

Congenital Hypertrophy of the Retinal Pigment Epithelium (CHRPE)



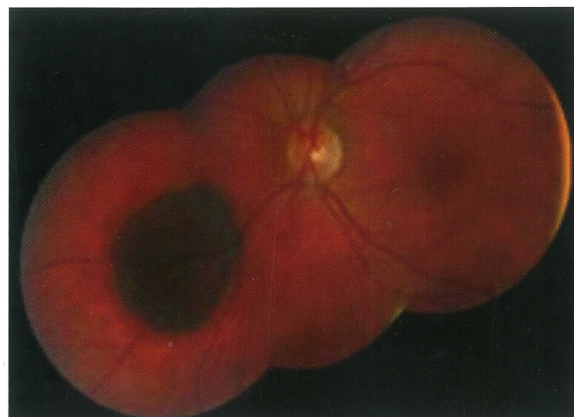Congenital Hypertrophy of the Retinal Pigment Epithelium (CHRPE) is a flat, pigmented spot within the outer layer of the retina at the back of the eye.

Was I born with this?

Yes, the spot is congenital, meaning that patients who have it are typically born this way.

I have had my eyes examined before. Why wasn't I told of this in the past?

Many CHRPE's are in the retinal periphery and are difficult to detect without a full retinal exam by a retina specialist.

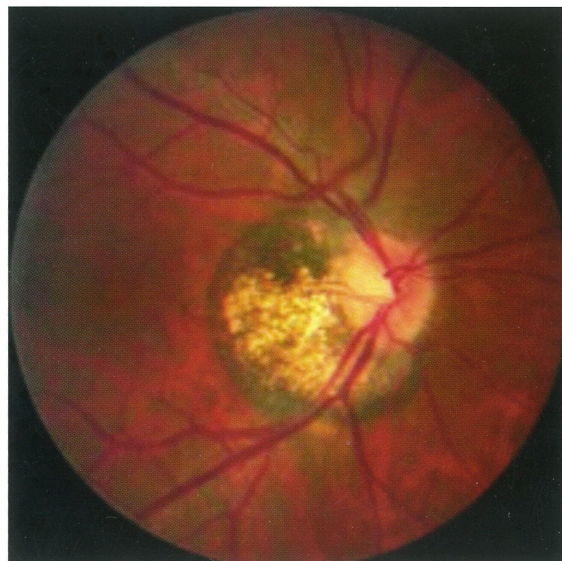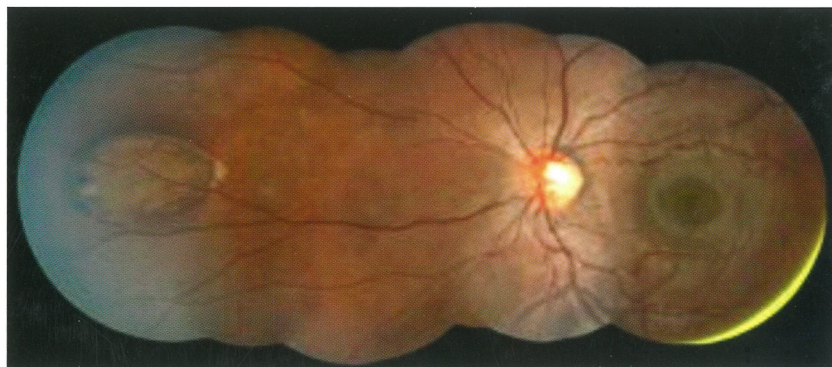


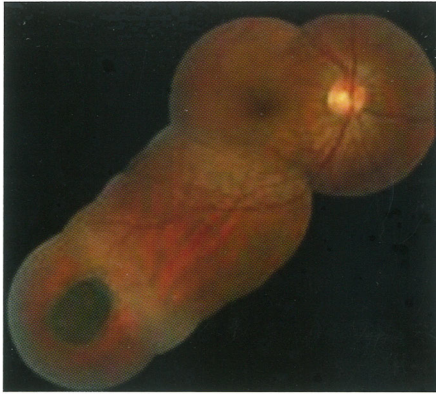What happens to these spots over time?

Many CHRPE's do not change or grow over time. In some patients, the borders of the spot grow very slowly over time but the spot remains flat. In the majority of patients, this is a benign finding that never causes a problem with the patient's vision or life.

Can I lose vision from this?

In a rare instance, if the CHRPE is located in the center of the retina (macula), it can cause patients to have poor vision. But if the spot is in the periphery of the retina as in most patients, it causes no vision loss, just a defect in the visual field in that area only in one eye which has no effect on the patient's functioning.



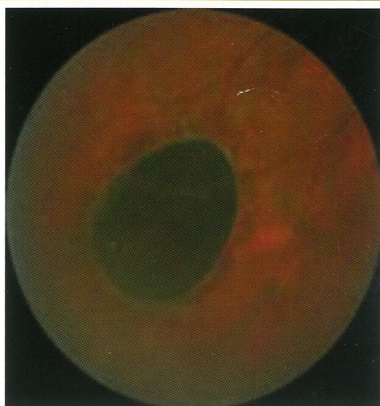
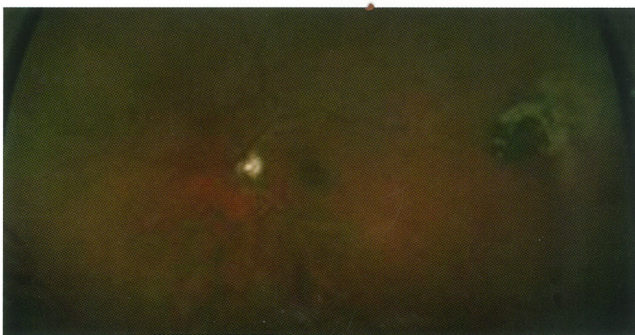
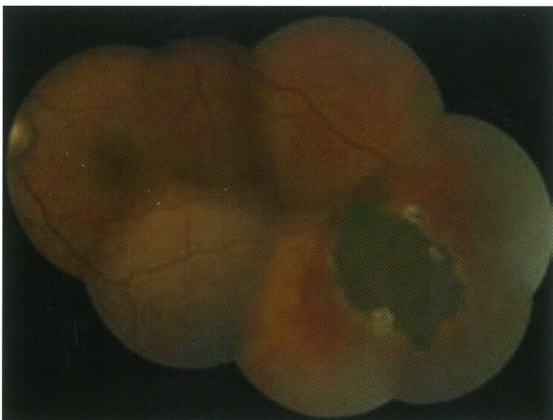
Can this grow into a malignant tumor?

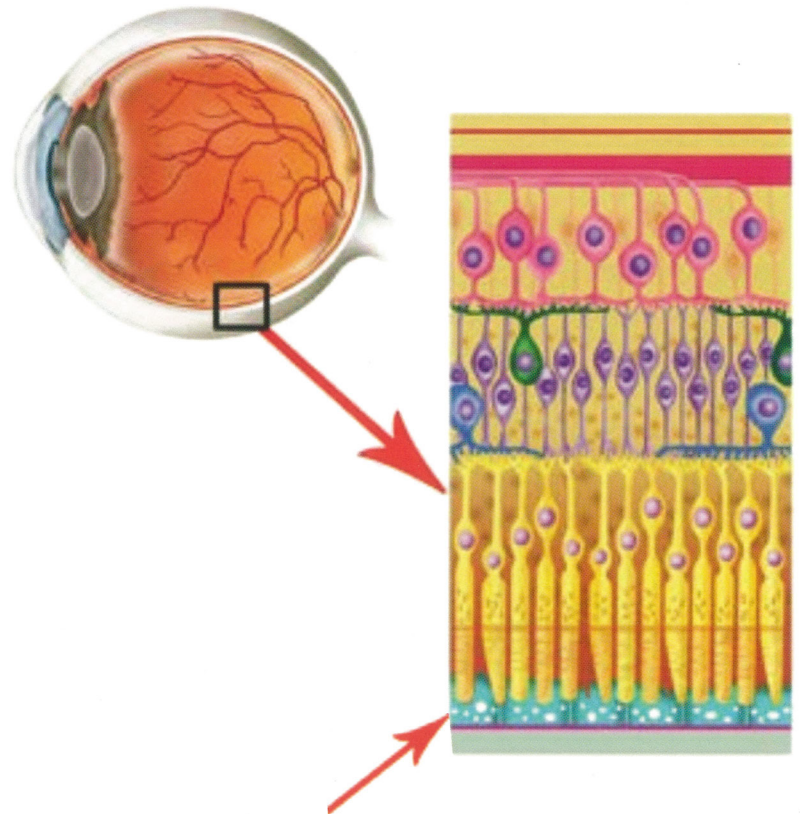
Yes, this is exceedingly rare but not impossible. There have been very few case reports (fewer than 5) of an adenocarcinoma, a malignant tumor, arising from a CHRPE. None of these rare patients ever developed metastases (cancer cells that traveled outside the eye).

Can this be associated with any systemic diseases?

Rarely, patients who have multiple CHRPE's and/or bilateral (both eyes) CHRPE's or CHRPE's with certain characteristic features are found to have Gardner's Syndrome (a genetic condition also called Familial Adenomatous Polyposis, or FAP). Patients with this syndrome can have colon cancer and skin tumors in addition to the retinal findings. If you are found to have these features, Dr. Amy Schefler will refer you to a gastroenterologist and/or geneticist for further testing. If you have a family history of this disorder, it is important to have both a retinal examination as well as routine colonoscopies.



The Retina



Retinal Pigment Epithelium, the outermost layer of the retina, the layer of the retina from which CHRPE's arise.