

EXPERIMENTAL ACCOMMODATIVE IOLs P. 12 • MANAGING POST-PK ASTIGMATISM P. 18  
A FIRST LOOK AT HYPERSONIC VITRECTOMY P. 53 • UPDATE ON EYE RESEARCH P. 56  
HOW PATIENTS CAN AFFORD THEIR GLAUCOMA MEDS P. 60 • INSIDIOUS SILENT SINUS SYNDROME P. 64

# REVIEW<sup>®</sup> of Ophthalmology

June 2019

reviewofophthalmology.com

ISSUE FOCUS: GLAUCOMA

## THE TWO SIDES OF GLAUCOMA SURGERY

*MIGS for the Comprehensive Ophthalmologist* **P. 24**

*Options for When You Need the "Big Guns"* **P. 37**

### ALSO INSIDE:

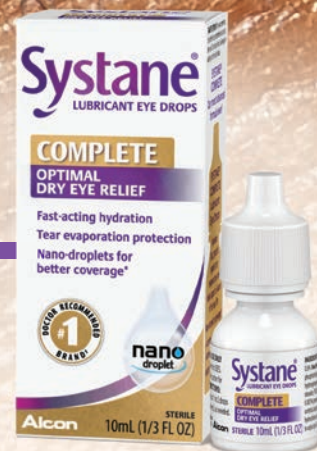- A Look into the Dry-eye Pipeline **P. 42**
- Non Cross-linking Options for Keratoconus **P. 46**



# SYSTANE® COMPLETE: OUR MOST ADVANCED SOLUTION. ONE SIMPLE CHOICE.

Our most innovative drop supports all layers of the tear film and is designed to provide symptom relief for **every major type of dry eye**.<sup>1-9</sup>

- ✓ **Evaporative Dry Eye**
- ✓ **Aqueous-deficient Dry Eye**
- ✓ **Mixed Dry Eye**



**The Relief is Real™**



**Advanced, lipid nano-droplet technology** rapidly delivers the lubricant across the ocular surface — resulting in **better coverage\*** to provide **fast-acting hydration, tear evaporation protection, and long-lasting relief**.<sup>1,5-6,8-10</sup>

**VISIT SYSTANE.COM TO LEARN MORE!**

\*Compared to SYSTANE® BALANCE Lubricant Eye Drops.

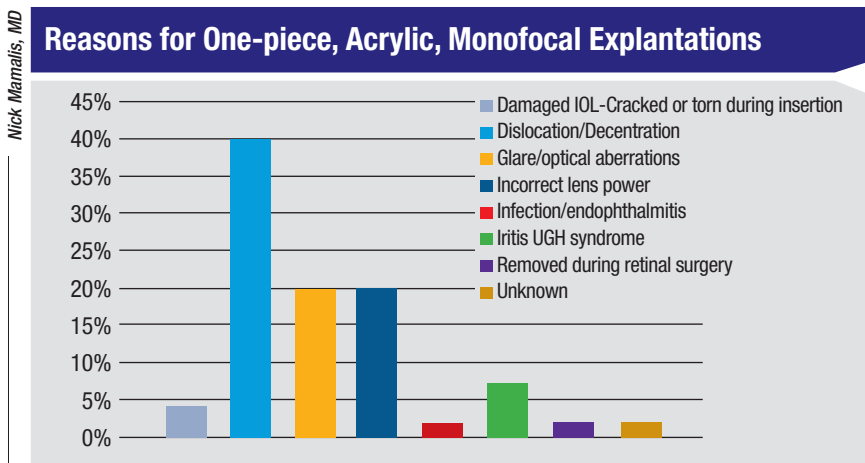
**References:** **1.** Korb D, Blackie C, Meadows D, Christensen M, Tudor M. Evaluation of extended tear stability by two emulsion based artificial tears. Poster presented at: 6th International Conference of the Tear Film and Ocular Surface: Basic Science and Clinical Relevance; September 22-25, 2010; Florence, Italy. **2.** Moon SW, Hwang JH, Chung SH, Nam KH. The impact of artificial tears containing hydroxypropyl guar on mucous layer. *Cornea*. 2010;29(12):1430-1435. **3.** Davitt WF, Bloomenstien M, Christensen M, Martin AE. Efficacy in patients with dry eye after treatment with a new lubricant eye drop formulation. *J Ocul Pharmacol Ther*. 2010;26(4):347-353. **4.** Willcox MDP, Argueso P, Georgiev GA, et al. TFOS DEWS II tear film report. *Ocul Surf*. 2017;15:366-403. **5.** Ketelson H, Rangarajan R. Pre-clinical evaluation of a novel phospholipid nanoemulsion based lubricant eye drop. Invest Ophthalmol Vis Sci. 2017;58:3929. **6.** Ogundele A, Ketelson H, et al. Preclinical evaluation of a novel hydroxypropyl-guar phospholipid nanoemulsion lubricant eye drop for dry eye disease. Poster presented at: The 36th World Ophthalmology Congress (WOC); June 16-19, 2018; Barcelona, Spain. **7.** Craig J, Nichols K, Akpek E, et al. TFOS DEWS II definition and classification report. *Ocul Surf*. 2017;15:276-283. **8.** Lane S, Paugh J, et al. An Evaluation of the in vivo Retention Time of a Novel Artificial Tear as Compared to a Placebo Control. Invest Ophthalmol Vis Sci. 2009;50(13):4679. **9.** Benelli U. Systane® lubricant eye drops in the management of ocular dryness. *Clin Ophthalmol*. 2011;5:783-790. **10.** Torkildsen G. The effects of lubricant eye drops on visual function as measured by the Inter-blink interval Visual Acuity Decay test. *Clin Ophthalmol*. 2009;3:501-506.

# Results of the Annual IOL Explant Survey Released

At the recent ASCRS meeting, Nick Mamalis, MD, professor of ophthalmology, co-director of the Intermountain Ocular Research Center and director of ocular pathology at the Moran Eye Center at the University of Utah, presented findings from his annual survey on foldable IOLs requiring explantation or secondary intervention. He began by noting that the type of lens with the highest rate of explantation is also the one implanted most frequently in the United States. “By far the most commonly explanted lens was a one-piece, hydrophobic acrylic,” says Dr. Mamalis. “But that really reflects the most commonly used lenses. Other materials are less frequently explanted because they’re just not used as much.”

Discussing the reasons for explantation, he says dislocation/decentration ranks as number one. However, he acknowledges that this complication doesn’t mean there’s an inherent problem with the design of the implant. “This implies either a complication during surgery, or some weakness of the zonules or the capsular bag that led to this complication,” he notes.

The second-highest reason for IOL explantation overall was glare/optical aberrations, though this was the most common reason for explantation of multifocals. “[Glare and/or optical aberrations] are usually the problems patients have with multifocals,” he says. “Since there may be difficulty tolerating these, people more commonly report these problems.”



Dr. Mamalis discusses another noteworthy point in the data. “When looking at hydrophilic acrylic (hydrogel) lenses, we’re finding the most common reason for explanting is calcification,” he says. The incidence of explanting these intraocular lenses has gone down over the course of the survey, but Dr. Mamalis says this may be reflective of their less-frequent use in the United States.

Referring to previous surveys, Dr. Mamalis says it’s interesting that dislocation/decentration is still the number one reason for IOL explantations. “It’s always been [number one] and it stays that way,” he says. “Other complications sort of go up and down. Incorrect lens and power is still the third overall reason for IOL removal but it’s gone down over the course of the survey, which means we’re getting better at measuring IOLs and choosing the correct power.”

To avoid complications, Dr. Mamalis says good surgical technique is key.

“An intact capsulorhexis with capsular bag fixation of the IOL will decrease dislocation and decentration markedly,” he says, adding that ensuring accurate IOL measurement is critical. He notes that this is becoming more difficult in patients who’ve previously had refractive surgery. Finally, Dr. Mamalis says that proper patient selection and preop counseling are necessary, especially to reduce complications with multifocal lenses.

## Allergan Wins Small Victory vs. ImprimisRx

The drug-compounding company ImprimisRx was recently ordered to pay \$48,500 to Allergan as a result of a false-advertising lawsuit Allergan  
(Continued on page 35)



# CONTRIBUTORS

**CHIEF MEDICAL EDITOR**

Mark H. Blecher, MD

**CONTACT LENSES**

Penny Asbell, MD

**CORNEA / ANTERIOR SEGMENT**

Thomas John, MD

**GLAUCOMA MANAGEMENT**

Peter Netland, MD, PHD  
Kuldev Singh, MD

**MASTERS OF SURGERY**

Taliva D. Martin, MD  
Sara J. Haug, MD, PhD

**MEDICARE Q & A**

Paul M. Larson, MBA

**PEDIATRIC PATIENT**

Wendy Huang, MD

**PLASTIC POINTERS**

Ann P. Murchison, MD, MPH

**REFRACTIVE SURGERY**

Arturo S. Chayet, MD

**RETINAL INSIDER**

Carl Regillo, MD, FACS  
Emmett T. Cunningham Jr., MD, PHD, MPH

**TECHNOLOGY UPDATE**

Steven T. Charles, MD  
Michael Colvard, MD

**WILLS RESIDENT CASE SERIES**

Jason Flamendorf, MD

# ADVISORY BOARD

PENNY A. ASBELL, MD, MEMPHIS, TENN.

WILLIAM I. BOND, MD, PEKIN, ILL.

ALAN N. CARLSON, MD, DURHAM, N.C.

Y. RALPH CHU, MD, EDINA, MINN.

ADAM J. COHEN, MD, DOWNERS GROVE, ILL.

UDAY DEVGAN, MD, FACS, LOS ANGELES

ERIC DONNENFELD, MD, ROCKVILLE CENTRE, N.Y.

DANIEL S. DURRIE, MD, KANSAS CITY, MO.

ROBERT EPSTEIN, MD, MCHENRY, ILL.

ROBERT D. FECHTNER, MD, NEWARK, N.J.

WILLIAM J. FISHKIND, MD, TUCSON, ARIZ.

JAMES P. GILLS, MD, TARPON SPRINGS, FLA.

HARRY GRABOW, MD, SARASOTA, FLA.

DOUGLAS K. GRAYSON, MD, NEW YORK CITY

THOMAS S. HARBIN, MD, MBA, ATLANTA

DAVID R. HARDTEN, MD, MINNEAPOLIS

KENNETH J. HOFFER, MD, SANTA MONICA, CALIF.

JACK T. HOLLADAY, MD, MSEE, HOUSTON

JOHN D. HUNKELER, MD, KANSAS CITY, MO.

THOMAS JOHN, MD, TINLEY PARK, ILL.

ROBERT M. KERSHNER, MD, MS, PALM BEACH GARDENS, FLA.

GUY M. KEZIRIAN, MD, PARADISE VALLEY, ARIZ.

TERRY KIM, MD, DURHAM, N.C.

TOMMY KORN, MD, SAN DIEGO

DAVID A. LEE, MD, HOUSTON

FRANCIS S. MAH, MD, PITTSBURGH

NICK MAMALIS, MD, SALT LAKE CITY

WILLIAM G. MARTIN, MD, OREGON, OHIO

MIKE S. MCFARLAND, MD, PINE BLUFF, ARK.

JEFFREY B. MORRIS, MD, MPH, ENCINITAS, CALIF.

MARLENE R. MOSTER, MD, PHILADELPHIA

ROBERT J. NOECKER, MD, FAIRFIELD, CONN.

ROBERT OSHER, MD, CINCINNATI

MARK PACKER, MD, WEST PALM BEACH, FLA.

STEPHEN PASCUCCI, MD, BONITA SPRINGS, FLA.

PAUL PENDER, MD, BEDFORD, N.H.

CHRISTOPHER J. RAPUANO, MD, PHILADELPHIA

AUGUST READER III, MD, SAN FRANCISCO

TONY REALINI, MD, MORGANTOWN, W.V.

KENNETH J. ROSENTHAL, MD, GREAT NECK, N.Y.

ERIC ROTHCHILD, MD, DELRAY BEACH, FLA.

SHERI ROWEN, MD, BALTIMORE

JAMES J. SALZ, MD, LOS ANGELES

INGRID U. SCOTT, MD, MPH, HERSHEY, PA.

JOEL SCHUMAN, MD, PITTSBURGH

GAURAV SHAH, MD, ST. LOUIS

DAVID R. STAGER JR., MD, DALLAS

KARL STONECIPHER, MD, GREENSBORO, N.C.

JAMES C. TSAI, MD, NEW YORK CITY

VANCE THOMPSON, MD, SIOUX FALLS, S.D.

FARRELL C. TYSON, MD, CAPE CORAL, FLA.

R. BRUCE WALLACE III, MD, ALEXANDRIA, LA.

ROBERT G. WILEY, MD, CLEVELAND

FRANK WEINSTOCK, MD, CANTON, OHIO

**BUSINESS OFFICES**

11 CAMPUS BOULEVARD, SUITE 100  
NEWTOWN SQUARE, PA 19073  
SUBSCRIPTION INQUIRIES (877) 529-1746  
(USA ONLY); OUTSIDE USA, CALL (847) 763-9630

**BUSINESS STAFF**

PUBLISHER

**JAMES HENNE**

(610) 492-1017 JHENNE@JOBSON.COM

REGIONAL SALES MANAGER

**MICHELE BARRETT**

(610) 492-1014 MBARRETT@JOBSON.COM

REGIONAL SALES MANAGER

**MICHAEL HOSTER**

(610) 492-1028 MHOSTER@JOBSON.COM

**CLASSIFIED ADVERTISING**

(888)-498-1460

VICE PRESIDENT OF OPERATIONS

**CASEY FOSTER**

(610) 492-1007 CFOSTER@JOBSON.COM

PRODUCTION MANAGER

**SCOTT TOBIN**

(610) 492-1011 STOBIN@JOBSON.COM

**SUBSCRIPTIONS**

\$63 A YEAR, \$99 (U.S.) IN CANADA,  
\$158 (U.S.) IN ALL OTHER COUNTRIES.

SUBSCRIPTIONS E-MAIL:

REVOPHTHALMOLOGY@CAMBEYWEST.COM

**CIRCULATION**

PO BOX 71, CONGERS, NY 10920-0071  
(877) 529-1746

OUTSIDE USA: (845) 267-3065

SENIOR CIRCULATION MANAGER

**HAMILTON MAHER**

(212) 219-7870 hmaher@jhihealth.com

CEO, INFORMATION GROUP SERVICES

**MARC FERRARA**

SENIOR VICE PRESIDENT, OPERATIONS

**JEFF LEVITZ**

VICE PRESIDENT, HUMAN RESOURCES

**TAMMY GARCIA**

VICE PRESIDENT, CREATIVE SERVICES & PRODUCTION

**MONICA TETTAMANZI**

CORPORATE PRODUCTION DIRECTOR

**JOHN ANTHONY CAGGIANO**

VICE PRESIDENT, CIRCULATION

**EVELDA BAREA**



395 Hudson Street, 3rd Floor,  
New York, NY 10014

REVIEW OF OPHTHALMOLOGY (ISSN 1081-0226; USPS No. 0012-345) is published monthly, 12 times per year by Jobson Medical Information, 395 Hudson Street, 3rd Floor, New York, NY 10014. Periodicals postage paid at New York, NY and additional mailing offices. Postmaster: Send address changes to Review of Ophthalmology, PO Box 71, Congers, NY 10929-0071. Subscription Prices: US One Year \$63.00, US Two Year \$112.00, Canada One Year \$99.00, Canada Two Year \$181.00, Int'l One Year \$158.00, Int'l Two Year \$274.00. For subscription information call (877) 529-1746 (USA only); outside USA, call (845)-267-3065. Or email us at revophthalmology@cambeywest.com. Canada Post: Publications Mail Agreement #40612608. Canada Returns to be sent to Bleuphip International, P.O. Box 25542, London, ON N6C 6B2.



# Flarex<sup>®</sup>

(fluorometholone  
acetate  
ophthalmic  
suspension) 0.1%

**NOW JOINING THE  
EYEVANCE<sup>™</sup> FAMILY**  
of ophthalmic treatment options



© 2019 EyeVance Pharmaceuticals LLC. All rights reserved.  
FLAREX<sup>®</sup> is a registered trademark of EyeVance Pharmaceuticals LLC.  
FLA-004 01/2019

# Lax Lids Are Red Flags

## To the Editor:

The article "Lid Laxity: Diagnosis and Management" in the Plastics Pointers department of the February issue of *Review of Ophthalmology* (pp. 46-48) was of great interest. The importance of correlating eye diseases with medical conditions (e.g., obstructive sleep apnea, or OSA) has therapeutic implications for patients and genetic implications for families.

In addition to OSA, other medical conditions have been associated with Lax Eyelid Syndrome. In 1984, LES was reported in a patient with non-ketotic hyperglycemia.<sup>1</sup> The case was of particular interest since glycine is a major constituent of collagen. This biochemical defect probably led to weaker collagen fibers and thus greater susceptibility to physical trauma (explaining the association of LES with sleeping on one side). This patient's brother also had non-ketotic hyperglycemia, and the genetic defect was subsequently identified in the brother.<sup>2</sup> In the era of gene therapy it will be possible to correct the genetic defect, thus eliminating many problems!

*Edward W. Gerner, MD*  
*Philadelphia*

1. Gerner EW, Hughes SM. Flopped eyelid with hyperglycemia. *Am J Ophthalmology* 1984;98:614-616.
2. Baker PR II, et al. Variant non-ketotic hyperglycemia is caused by mutations in LIAS, BOLA 3 and the novel gene GLRY5. *Brain* 2014;137:266-379.

## Dr. Armstrong responds:

Thank you for your thoughtful letter.

In addition to obstructive sleep apnea, there are a variety of genetic conditions that have been described in association with lax eyelid syndrome, including Down syndrome, congenital cataracts facial dysmorphism neuropathy (CCFDN), and congenital hyperglycinemia.<sup>1-3</sup> LES also presents in patients with Ehlers-Danlos syndrome with mutations in the COL5A1 and COL5A2 genes coding for type V collagen.<sup>4</sup>

These varied heritable conditions are unified in that the individual genetic mutation compromises the integrity of the tarsal connective tissue and causes eyelid laxity. When lid laxity reaches a critical threshold—or perhaps is exacerbated by mechanical trauma—the inflammatory sequelae of the conjunctiva and ocular surface result. The genetic associations can elucidate the pathogenesis of LES and, as you suggest, in this exciting era of gene therapy may offer a potential for future treatment.

1. Fowler A, Dutton J. Floppy eyelid syndrome as a subset of lax eyelid conditions: Relationships and clinical relevance. *Ophthalmic Plastic Reconstructive Surg* 2010;26:3:195-204.
2. Rao L, Bhandary S, Devi A (2006). Floppy Eyelid Syndrome in an Infant. *Indian Journal of Ophthalmology* 2006;54:3:217-8.
3. Eiferman R, Gossman MD, O'Neill K, Douglas CH. Floppy Eyelid Syndrome in a Child. *Ophthalmic Plastic and Reconstructive Surgery* 1991;109:3:74-75.
4. Segev F, Heon E, Cole W, Wenstrup R, Young F, et al. Structural abnormalities of the cornea and lid resulting from collagen V mutations. *IOVS* 2006;47:2:565-573.

## EDITORIAL STAFF

### Editor in Chief

Walter C. Bethke  
(610) 492-1024  
wbethke@jobson.com

### Senior Editor

Christopher Kent  
(212) 274-7031  
ckent@jobson.com

### Associate Editor

Alexandra Skinner  
(610) 492-1025  
askinner@jobson.com

### Chief Medical Editor

Mark H. Blecher, MD

### Art Director

Jared Araujo  
(610) 492-1032  
jaraujo@jobson.com

### Senior Graphic Designer

Matt Egger  
(610) 492-1029  
megger@jobson.com

### Graphic Designer

Ashley Schmouder  
(610) 492-101048  
aschmouder@jobson.com

### International coordinator, Japan

Mitz Kaminuma  
Reviewophtho@aol.com

### Business Offices

11 Campus Boulevard, Suite 100  
Newtown Square, PA 19073  
(610) 492-1000  
Fax: (610) 492-1039

### Subscription inquiries:

United States — (877) 529-1746  
Outside U.S. — (845) 267-3065


### E-mail:

revophthalmology@cambeywest.com  
Website: www.reviewofophthalmology.com





Only dual-action VYZULTA reduces intraocular pressure (IOP) by targeting the trabecular meshwork with nitric oxide and the uveoscleral pathway with latanoprost acid<sup>1</sup>



  
**VYZULTA**  
(latanoprostene  
bunod ophthalmic  
solution), 0.024%

## EXPAND THE TRABECULAR MESHWORK WITH THE POWER OF NITRIC OXIDE<sup>2-6</sup>

### VYZULTA achieved significant and sustained long-term IOP reductions vs Timolol 0.5% in pivotal trials<sup>7</sup>

$P < 0.001$  vs baseline at all pre-specified visits over 12 months in a pooled analysis of APOLLO and LUNAR clinical trials (N=831)

### VYZULTA demonstrated safety profile in clinical trials

Only 6 out of 811 patients discontinued due to ocular adverse events in APOLLO and LUNAR clinical trials<sup>1,8,9</sup>

Visit [VYZULTANOW.com](http://VYZULTANOW.com) to see our efficacy results

### INDICATION

VYZULTA® (latanoprostene bunod ophthalmic solution), 0.024% is indicated for the reduction of intraocular pressure (IOP) in patients with open-angle glaucoma or ocular hypertension.

### IMPORTANT SAFETY INFORMATION

- Increased pigmentation of the iris and periorbital tissue (eyelid) can occur. Iris pigmentation is likely to be permanent
- Gradual changes to eyelashes, including increased length, increased thickness, and number of eyelashes, may occur. These changes are usually reversible upon treatment discontinuation
- Use with caution in patients with a history of intraocular inflammation (iritis/uveitis). VYZULTA should generally not be used in patients with active intraocular inflammation
- Macular edema, including cystoid macular edema, has been reported during treatment with prostaglandin analogs. Use with caution in aphakic patients, in pseudophakic patients with a torn posterior lens capsule, or in patients with known risk factors for macular edema

### IMPORTANT SAFETY INFORMATION cont'd

- There have been reports of bacterial keratitis associated with the use of multiple-dose containers of topical ophthalmic products that were inadvertently contaminated by patients
- Contact lenses should be removed prior to the administration of VYZULTA and may be reinserted 15 minutes after administration
- Most common ocular adverse reactions with incidence  $\geq 2\%$  are conjunctival hyperemia (6%), eye irritation (4%), eye pain (3%), and instillation site pain (2%)

For more information, please see Brief Summary of Prescribing Information on next page.

**References:** 1. VYZULTA Prescribing Information. Bausch & Lomb Incorporated. 2. Cavet ME. *J Ocul Pharmacol Ther.* 2018;34(1):52-60. DOI:10.1089/jop.2016.0188. 3. Wareham LK. *Nitric Oxide.* 2018;77:75-87. DOI:10.1016/j.niox.2018.04.010. 4. Stamer DW. *Curr Opin Ophthalmol.* 2012;23:135-143. DOI:10.1097/ICU.0b013e32834ff23e. 5. Cavet ME. *Invest Ophthalmol Vis Sci.* 2015;56(6):4108-4116. 6. Kaufman PL. *Exp Eye Research.* 2008;86:1-3-17. DOI:10.1016/j.exer.2007.10.007. 7. Weinreb RN. *J Glaucoma.* 2018;27:7-15. 8. Weinreb RN. *Ophthalmology.* 2016;123(5):965-973. 9. Medeiros FA. *Am J Ophthalmol.* 2016;168:250-259.

## BRIEF SUMMARY OF PRESCRIBING INFORMATION

This Brief Summary does not include all the information needed to use VYZULTA safely and effectively. See full Prescribing Information for VYZULTA.

**VYZULTA<sup>®</sup>** (latanoprostene bunod ophthalmic solution), 0.024%, for topical ophthalmic use.

Initial U.S. Approval: 2017

### 1 INDICATIONS AND USAGE

VYZULTA<sup>®</sup> (latanoprostene bunod ophthalmic solution) 0.024% is indicated for the reduction of intraocular pressure (IOP) in patients with open-angle glaucoma or ocular hypertension.

### 4 CONTRAINDICATIONS

None

### 5 WARNINGS AND PRECAUTIONS

#### 5.1 Pigmentation

VYZULTA<sup>®</sup> (latanoprostene bunod ophthalmic solution), 0.024% may cause changes to pigmented tissues. The most frequently reported changes with prostaglandin analogs have been increased pigmentation of the iris and periorbital tissue (eyelid).

Pigmentation is expected to increase as long as latanoprostene bunod ophthalmic solution is administered. The pigmentation change is due to increased melanin content in the melanocytes rather than to an increase in the number of melanocytes. After discontinuation of VYZULTA, pigmentation of the iris is likely to be permanent, while pigmentation of the periorbital tissue and eyelash changes are likely to be reversible in most patients. Patients who receive prostaglandin analogs, including VYZULTA, should be informed of the possibility of increased pigmentation, including permanent changes. The long-term effects of increased pigmentation are not known.

Iris color change may not be noticeable for several months to years. Typically, the brown pigmentation around the pupil spreads concentrically towards the periphery of the iris and the entire iris or parts of the iris become more brownish. Neither nevi nor freckles of the iris appear to be affected by treatment. While treatment with VYZULTA<sup>®</sup> (latanoprostene bunod ophthalmic solution), 0.024% can be continued in patients who develop noticeably increased iris pigmentation, these patients should be examined regularly [see Patient Counseling Information (17) in full Prescribing Information].

#### 5.2 Eyelash Changes

VYZULTA may gradually change eyelashes and vellus hair in the treated eye. These changes include increased length, thickness, and the number of lashes or hairs. Eyelash changes are usually reversible upon discontinuation of treatment.

#### 5.3 Intraocular Inflammation

VYZULTA should be used with caution in patients with a history of intraocular inflammation (iritis/uveitis) and should generally not be used in patients with active intraocular inflammation as it may exacerbate this condition.

#### 5.4 Macular Edema

Macular edema, including cystoid macular edema, has been reported during treatment with prostaglandin analogs. VYZULTA should be used with caution in aphakic patients, in pseudophakic patients with a torn posterior lens capsule, or in patients with known risk factors for macular edema.

#### 5.5 Bacterial Keratitis

There have been reports of bacterial keratitis associated with the use of multiple-dose containers of topical ophthalmic products. These containers had been inadvertently contaminated by patients who, in most cases, had a concurrent corneal disease or a disruption of the ocular epithelial surface.

#### 5.6 Use with Contact Lens

Contact lenses should be removed prior to the administration of VYZULTA because this product contains benzalkonium chloride. Lenses may be reinserted 15 minutes after administration.

### 6 ADVERSE REACTIONS

The following adverse reactions are described in the Warnings and Precautions section: pigmentation (5.1), eyelash changes (5.2), intraocular inflammation (5.3), macular edema (5.4), bacterial keratitis (5.5), use with contact lens (5.6).

#### 6.1 Clinical Trials Experience

Because clinical trials are conducted under widely varying conditions, adverse reaction rates observed in the clinical trials of a drug cannot be directly compared to rates in the clinical trials of another drug and may not reflect the rates observed in practice.

VYZULTA was evaluated in 811 patients in 2 controlled clinical trials of up to 12 months duration. The most common ocular adverse reactions observed in patients treated with latanoprostene bunod were: conjunctival hyperemia (6%), eye irritation (4%), eye pain (3%), and instillation site pain (2%). Approximately 0.6% of patients discontinued therapy due to ocular adverse reactions including ocular hyperemia, conjunctival irritation, eye irritation, eye pain, conjunctival edema, vision blurred, punctate keratitis and foreign body sensation.

### 8 USE IN SPECIFIC POPULATIONS

#### 8.1 Pregnancy

##### Risk Summary

There are no available human data for the use of VYZULTA during pregnancy to inform any drug associated risks.

Latanoprostene bunod has caused miscarriages, abortion, and fetal harm in rabbits. Latanoprostene bunod was shown to be abortifacient and teratogenic when administered intravenously (IV) to pregnant rabbits at exposures  $\geq$  0.28 times the clinical dose. Doses  $\geq$  20  $\mu$ g/kg/day (23 times the clinical dose) produced 100%

embryofetal lethality. Structural abnormalities observed in rabbit fetuses included anomalies of the great vessels and aortic arch vessels, domed head, sternebral and vertebral skeletal anomalies, limb hyperextension and malrotation, abdominal distension and edema. Latanoprostene bunod was not teratogenic in the rat when administered IV at 150 mcg/kg/day (87 times the clinical dose) [see Data].

The background risk of major birth defects and miscarriage for the indicated population is unknown. However, the background risk in the U.S. general population of major birth defects is 2 to 4%, and of miscarriage is 15 to 20%, of clinically recognized pregnancies.

##### Data

##### Animal Data

Embryofetal studies were conducted in pregnant rabbits administered latanoprostene bunod daily by intravenous injection on gestation days 7 through 19, to target the period of organogenesis. The doses administered ranged from 0.24 to 80 mcg/kg/day. Abortion occurred at doses  $\geq$  0.24 mcg/kg/day latanoprostene bunod (0.28 times the clinical dose, on a body surface area basis, assuming 100% absorption). Embryofetal lethality (resorption) was increased in latanoprostene bunod treatment groups, as evidenced by increases in early resorptions at doses  $\geq$  0.24 mcg/kg/day and late resorptions at doses  $\geq$  6 mcg/kg/day (approximately 7 times the clinical dose). No fetuses survived in any rabbit pregnancy at doses of 20 mcg/kg/day (23 times the clinical dose) or greater. Latanoprostene bunod produced structural abnormalities at doses  $\geq$  0.24 mcg/kg/day (0.28 times the clinical dose). Malformations included anomalies of sternum, coarctation of the aorta with pulmonary trunk dilation, retroesophageal subclavian artery with absent brachiocephalic artery, domed head, forepaw hyperextension and hindlimb malrotation, abdominal distention/edema, and missing/fused caudal vertebrae.

An embryofetal study was conducted in pregnant rats administered latanoprostene bunod daily by intravenous injection on gestation days 7 through 17, to target the period of organogenesis. The doses administered ranged from 150 to 1500 mcg/kg/day. Maternal toxicity was produced at 1500 mcg/kg/day (870 times the clinical dose, on a body surface area basis, assuming 100% absorption), as evidenced by reduced maternal weight gain. Embryofetal lethality (resorption and fetal death) and structural anomalies were produced at doses  $\geq$  300 mcg/kg/day (174 times the clinical dose). Malformations included anomalies of the sternum, domed head, forepaw hyperextension and hindlimb malrotation, vertebral anomalies and delayed ossification of distal limb bones. A no observed adverse effect level (NOAEL) was established at 150 mcg/kg/day (87 times the clinical dose) in this study.

#### 8.2 Lactation

##### Risk Summary

There are no data on the presence of VYZULTA in human milk, the effects on the breastfed infant, or the effects on milk production. The developmental and health benefits of breastfeeding should be considered, along with the mother's clinical need for VYZULTA, and any potential adverse effects on the breastfed infant from VYZULTA.

#### 8.4 Pediatric Use

Use in pediatric patients aged 16 years and younger is not recommended because of potential safety concerns related to increased pigmentation following long-term chronic use.

#### 8.5 Geriatric Use

No overall clinical differences in safety or effectiveness have been observed between elderly and other adult patients.

### 13 NONCLINICAL TOXICOLOGY

#### 13.1 Carcinogenesis, Mutagenesis, Impairment of Fertility

Latanoprostene bunod was not mutagenic in bacteria and did not induce micronuclei formation in the *in vivo* rat bone marrow micronucleus assay. Chromosomal aberrations were observed *in vitro* with human lymphocytes in the absence of metabolic activation.

Latanoprostene bunod has not been tested for carcinogenic activity in long-term animal studies. Latanoprost acid is a main metabolite of latanoprostene bunod. Exposure of rats and mice to latanoprost acid, resulting from oral dosing with latanoprost in lifetime rodent bioassays, was not carcinogenic.

Fertility studies have not been conducted with latanoprostene bunod. The potential to impact fertility can be partially characterized by exposure to latanoprost acid, a common metabolite of both latanoprostene bunod and latanoprost. Latanoprost acid has not been found to have any effect on male or female fertility in animal studies.

#### 13.2 Animal Toxicology and/or Pharmacology

A 9-month toxicology study administered topical ocular doses of latanoprostene bunod to one eye of cynomolgus monkeys: control (vehicle only), one drop of 0.024% bid, one drop of 0.04% bid and two drops of 0.04% per dose, bid. The systemic exposures are equivalent to 4.2-fold, 7.9-fold, and 13.5-fold the clinical dose, respectively, on a body surface area basis (assuming 100% absorption). Microscopic evaluation of the lungs after 9 months observed pleural/subpleural chronic fibrosis/inflammation in the 0.04% dose male groups, with increasing incidence and severity compared to controls. Lung toxicity was not observed at the 0.024% dose.

U.S. Patent Numbers: 7,273,946; 7,629,345; 7,910,767; 8,058,467.

VYZULTA is a trademark of Bausch & Lomb Incorporated or its affiliates.

© 2019 Bausch & Lomb Incorporated or its affiliates.

##### Distributed by:

Bausch + Lomb, a division of

Valeant Pharmaceuticals North America LLC

Bridgewater, NJ 08807 USA

Based on 9612402 (Folded), 9612302 (Flat) 6/2018

VYZ.0058.USA.19 Issued: 3/2019



# REVIEW<sup>®</sup> of Ophthalmology

June 2019 • Volume XXVI No. 6 | reviewofophthalmology.com

## Cover Focus

---

### 24 | **MIGS and the General Ophthalmologist**

*Christopher Kent, Senior Editor*

Experts answer 10 questions about how general ophthalmologists can make the most of these procedures.

### 37 | **Why Trabs and Tubes Still Matter**

*James C. Tsai, MD*

A glaucoma expert describes situations where surgeons still need the “big guns.”

## Feature Articles

---

### 42 | **Dry Eye Therapies: What's Next?**

*Michelle Stephenson, Contributing Editor*

Several devices and a multitude of new medications are expected to come to the marketplace in the next few years.

### 46 | **Non Cross-linking Options for Keratoconus**

*Alexandra Skinner, Associate Editor*

Doctors discuss instances in which cross-linking may not be the best choice, and various alternatives for managing the disease.

# Departments

---

3 | [Review News](#)

6 | [Letters](#)

12 | [Technology Update](#)

## **Creating Uncommon Accommodation**

Three intraocular lenses in the pipeline appear to be providing true accommodative vision. Here's the latest on these devices.

18 | [Refractive/Cataract Rundown](#)

## **How to Handle Astigmatism After PRK**

A veteran corneal surgeon reviews the full spectrum of tools and techniques for managing these unique cases.

53 | [Retinal Insider](#)

## **A New Way to Perform a Vitrectomy**

A look at how hypersonic vitrectomy works, and what features it might bring to the table.

56 | [Research Review](#)

## **Cataract Surgery May Not Slow Visual Field Loss**

60 | [Glaucoma Management](#)

## **Easing Your Patients' Financial Burden**

Limiting the cost of glaucoma treatment can improve adherence and create happier patients.

64 | [Plastic Pointers](#)

## **Silent Sinus Syndrome**

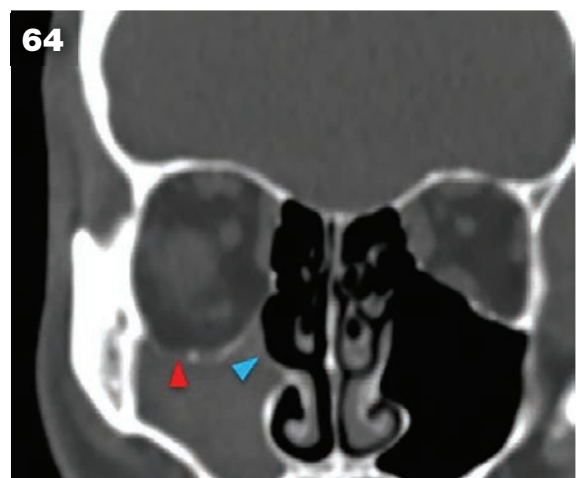

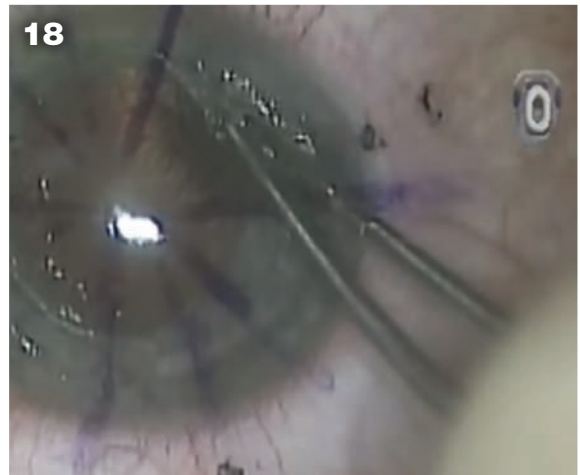
How to detect and manage this rare condition, which can be associated with a range of symptoms.

68 | [Products](#)

70 | [Classifieds](#)

71 | [Wills Eye Resident Case Series](#)

73 | [Ad Index](#)





iStent  
inject®

## TRANSFORMING MIGS IN MORE WAYS THAN ONE.

**Optimized Outflow:** Two multi-directional stents designed to restore natural outflow

**Clinically Proven:** Significant IOP reduction across a wide range of clinical studies<sup>1,2</sup>

**Procedural Elegance:** Predictability and precision to meet the needs of your practice

**Proven Safety:** Safety profile similar to cataract surgery alone<sup>1</sup>



All with the exceptional customer support you've come to expect from Glaukos.

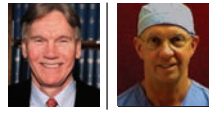TransformMIGS.com | 800.GLAUKOS (452.8567)

**INDICATION FOR USE.** The iStent *inject*® Trabecular Micro-Bypass System Model G2-M-IS is indicated for use in conjunction with cataract surgery for the reduction of intraocular pressure (IOP) in adult patients with mild to moderate primary open-angle glaucoma. **CONTRAINDICATIONS.** The iStent *inject* is contraindicated in eyes with angle-closure glaucoma, traumatic, malignant, uveitic, or neovascular glaucoma, discernible congenital anomalies of the anterior chamber (AC) angle, retrolental tumor, thyroid eye disease, or Sturge-Weber Syndrome or any other type of condition that may cause elevated episcleral venous pressure. **WARNINGS.** Gonioscopy should be performed prior to surgery to exclude congenital anomalies of the angle, PAS, rubeosis, or conditions that would prohibit adequate visualization of the angle that could lead to improper placement of the stent and pose a hazard. **MRI INFORMATION.** The iStent *inject* is MR-Conditional, i.e., the device is safe for use in a specified MR environment under specified conditions; please see Directions for Use (DFU) label for details. **PRECAUTIONS.** The surgeon should monitor the patient postoperatively for proper maintenance of IOP. The safety and effectiveness of the iStent *inject* have not been established as an alternative to the primary treatment of glaucoma with medications, in children, in eyes with significant prior trauma, abnormal anterior segment, chronic inflammation, prior glaucoma surgery (except SLT performed > 90 days preoperative), glaucoma associated with vascular disorders, pseudoexfoliative, pigmentary or other secondary open-angle glaucomas, pseudophakic eyes, phakic eyes without concomitant cataract surgery or with complicated cataract surgery, eyes with medicated IOP > 24 mmHg or unmedicated IOP < 21 mmHg or > 36 mmHg, or for implantation of more or less than two stents. **ADVERSE EVENTS.** Common postoperative adverse events reported in the randomized pivotal trial included stent obstruction (6.2%), intraocular inflammation (5.7% for iStent *inject* vs. 4.2% for cataract surgery only), secondary surgical intervention (5.4% vs. 5.0%) and BCVA loss  $\geq$  2 lines  $\geq$  3 months (2.6% vs. 4.2%). **CAUTION:** Federal law restricts this device to sale by, or on the order of, a physician. Please see DFU for a complete list of contraindications, warnings, precautions, and adverse events.

**REFERENCES:** 1. iStent *inject*® Trabecular Micro-Bypass System: Directions for Use, Part #45-0176. 2. Hengerer FH. Personal experience with second-generation trabecular micro-bypass stents in combination with cataract surgery in patients with glaucoma: 3-year follow-up. ASCRS 2018 Presentation.

© 2018 Glaukos Corporation. Glaukos and iStent *inject* are registered trademarks of Glaukos Corporation. PM-US-0026

GLAUKOS®  
Transforming Glaucoma Therapy



# Creating Uncommon Accommodation

Three intraocular lenses in the pipeline appear to be providing true accommodative vision. Here's the latest on these devices.

*Christopher Kent, Senior Editor*

**A**s everyone knows, the “holy grail” in cataract surgery is an implant that can give patients back a full range of visual accommodation—the kind most of us enjoyed in our youth. A number of implantable lenses currently in development (not yet approved in the United States or elsewhere) are showing the promise of at least coming close to that goal.

Here's the latest on the three frontrunners that may give surgeons a true accommodating lens in the years ahead.

## The Juvene

The Juvene accommodative IOL (LensGen, Irvine California) was recently profiled at the annual meeting of the American Society of Cataract and Refractive Surgery by Eric Donnenfeld, MD, a clinical professor of ophthalmology at New York University Medical Center and a partner at Ophthalmic Consultants of Long Island. (Dr. Donnenfeld is a consultant for LensGen.) He implanted his first Juvene in March of 2018, in Santa Domingo in the Dominican Republic.

“The Juvene is a modular, curva-

ture-changing, fluid-optic IOL that's been in clinical trials in the Dominican Republic and Mexico for four years,” he explains. “It's a two-part lens composed of a base component that fills the capsular bag and a modular second implant that contains a curvature-changing liquid silicone optic. It's biomimetic, meaning that it mimics the natural crystalline lens; when the ciliary muscles contract, the zonules relax and the lens becomes rounder, just like the natural lens. Also, like the natural lens, the Juvene doesn't split the incoming light the way a multifocal lens does. For that reason, vision quality is excellent and optical side effects are minimal.”


Dr. Donnenfeld notes that filling the capsular bag is an advantage. “Because it fills the capsular bag there's no change in the effective lens position and no rotation when it's implanted,” he says. “There's no posterior capsular opacification, and there are fewer flashes and floaters because the vitreous face doesn't come forward. Meanwhile, because of the modular components, it can be inserted through a small 3-mm incision. The two-part design allows the platform to

potentially be used to address issues such as astigmatism via a toric lens, or to deliver drugs inside the eye or perform electronic sensing. Furthermore, we can take the lens section out very easily, so we can come back five years after implantation and exchange it if something better comes along.”

Sumit Garg, MD, vice chair of clinical ophthalmology, medical director and an associate professor of cataract, corneal and refractive surgery at the Gavin Herbert Eye Institute at the University of California, Irvine, agrees that Juvene being a modular lens is advantageous. (Dr. Garg is also a consultant to LensGen.) “The two-part lens consists of a fixed ‘base’ lens and a fluid-filled ‘power’ lens,” he notes. “In early clinical trials, the lens delivered up to 3 D of continuous range of vision, with minimal or no visual side effects. Because the bag is completely filled, there have been no reports of posterior capsular opacity out to four years. Also, with the bag filled, there should be less stress on the vitreous. That has the potential to confer safety advantages with respect to posterior vitreous detachment and retinal tears.”



The Juvene accommodative IOL is a two-part lens composed of a base component that fills the capsular bag and a modular second implant that contains a curvature-changing liquid silicone optic.



can Society of Cataract and Refractive Surgery I presented the one-month follow-up data from that study. The data shows that the lens creates a very reproducible 2.5 D of accommodation, and the subjects report excellent quality of vision. With binocular lens implantation, near vision was even better; subjects achieved 3 D of accommodation.

Dr. Garg adds that he’s had the opportunity to implant a few of the Juvene IOLs. “I found the procedure to be very intuitive, without a significant learning curve,” he says. “The modular lens was easy to implant and manipulate within the eye, and the incision didn’t require any sutures.”

In terms of contraindications, Dr. Donnenfeld says that the Juvene is similar to a standard monofocal lens. “Anyone who can accept a monofocal lens can have this lens implanted,” he explains. “You have to have an intact capsular bag, the capsulotomy has to be good and there has to be good zonular support, but these are the usual concerns with any patient having cataract surgery. Indications for this lens would be the same as for a multifocal lens, except that you can put this lens in patients who have keratoconus, for example, or glaucoma. There are no major contraindications, because it functions as a monofocal lens. There’s no splitting of light, so you don’t have to worry about any loss of contrast sensitivity.”

Dr. Donnenfeld says that the lens design has been through a half-dozen different iterations. “Once they finalized the lens design they started a clinical trial in Mexico called the ‘Grail’ study, involving 44 eyes and multiple surgeons,” he says. “At the recent annual meeting of the Ameri-

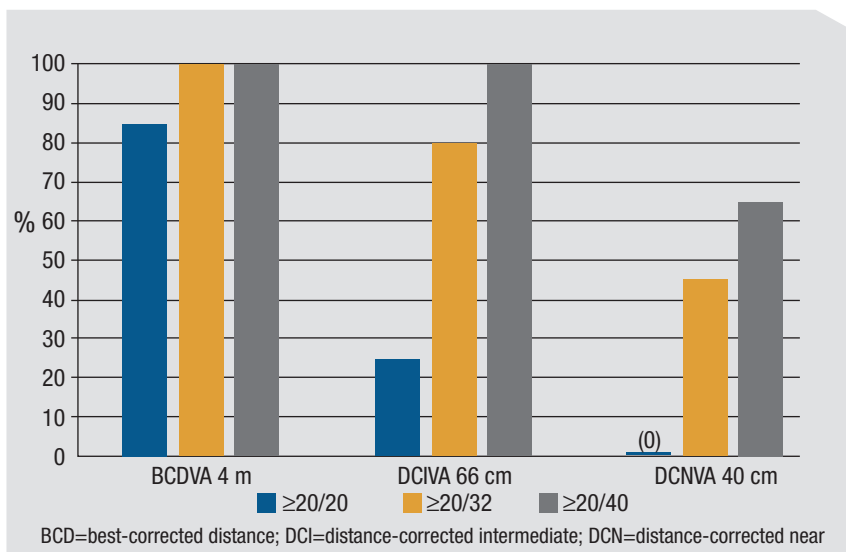
very good. Patient satisfaction was excellent, with no patients reporting glare or halos, although two patients reported very mild starbursting, the kind you might see with a standard monofocal lens.”

Dr. Donnenfeld also says that four-year data is now available for the first patients implanted with the lens. “Those patients are doing very well,” he says. “None of them developed posterior capsular opacification, because the leaflets of the capsule are separated.”

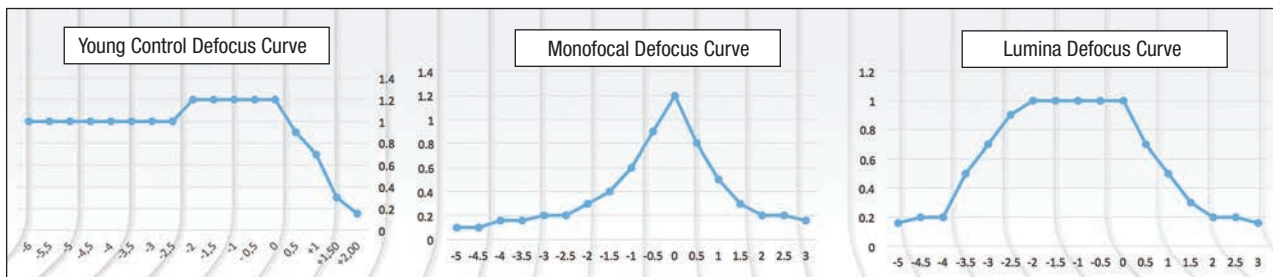
Asked about similarities to the FluidVision accommodating lens (*see page 16*), Dr. Donnenfeld notes that they share the same type of mechanism. “They’re both biomimetic, and they both have silicone optics that change as the patient accommodates,” he says. “The major difference is that the Juvene is a modular lens, so it can go in through a smaller incision.”

Dr. Donnenfeld acknowledges that there’s still plenty of work to be done before the Juvene reaches the marketplace. “The FDA trials will start later this year,” he notes. “Meanwhile, the Grail study will involve a one-year follow-up. If we see that the data is just as good with this version of the lens at

### Juvene: Postop Monocular Visual Acuities (n=20)







one year as it was at one month, then we'll feel much better about it. In the meantime, I remain cautiously optimistic. I think it's a very exciting lens."

## The Lumina

The Lumina accommodative IOL (Akkolens International, the Netherlands) consists of a fixed-power lens that corrects for the refractive error of the aphakic eye, the way a monofocal lens would, and a variable-power lens. The latter is composed of two cubic, progressively powered hydrophilic acrylate optical elements, elastically connected at the rims, that move across each other under pressure from the ciliary muscles. That movement causes a change in focal power. The Lumina is implanted in the sulcus—not in the bag—through a 2.8-mm incision using a standard butterfly-type lens injector. (You can see a Lumina being implanted at [youtu.be/watch?v=2nvaQJaF\\_BI](http://youtu.be/watch?v=2nvaQJaF_BI).) The device has rounded anterior edges to prevent release of iris pigment.

Once in the sulcus, the haptics directly contact the ciliary muscles. When the muscles contract because of an accommodative stimulus, the

The Lumina accommodative lens consists of a fixed-power lens and a variable-power lens. Two optical elements in the latter part of the device move across each other under pressure from ciliary muscle changes, shifting the focal power from distance to near and back. The Lumina is implanted in the sulcus, not inside the capsular bag.

Lumina is compressed by the centripetal force of the muscle contraction. The Lumina's two optical surfaces then slide over each other, altering the refractive power of the dual lens to provide sharp vision at near. Relaxation of the ciliary muscle reverses the process due to the inherent, outward, elasticity of the IOL, for sharp vision at far. The Lumina can provide a focal range of 3 to 4 D when shifted. (The company reports that the shift in position of the two pieces can be seen in ultrasound images.)

Clinical investigators have noted that placing the lens in the sulcus eliminates several factors that might affect the performance of other accommodating lenses that are placed inside the bag, such as less-direct transfer of the ciliary muscle movement, and gradual capsule shrinkage and fibrosis that may restrict a lens's accommodative amplitude. (After the Lumina is implanted, standard YAG can be applied to treat posterior capsular opacity should it occur, with full recovery of visual acuity.)

Several studies showing both subjective and objective accommodation have been conducted to date.<sup>1,2</sup> Early data from 59 eyes of 43 patients implanted with the Lumina, reported by Jorge Alió, MD, PhD, professor and chairman of ophthalmology at the University Miguel Hernandez de Elche in Spain, and medical director of the investigational study of the Lumina, found that it retained its full

range of objective and subjective accommodation for at least two years. At both 12 and 24 months, the subjects displayed an accommodative range of about 3.1 D, although there was some variation among individual patients. According to Dr. Alió, pseudo-accommodation was responsible for less than 30 percent of this result. The company says that long-term stability has been shown by three- to four-year postop evaluations, with patients showing accommodation and excellent contrast sensitivity curves, comparable to monofocal curves, and patients being spectacle-free.

Dr. Alió is the principal investigator for the lens; he performed all of the surgeries and follow-up measurements. He emphasizes that placing the lens in the sulcus is a significant advantage. "Anything that's placed inside the capsular bag is condemned to become fibrotic and blocked over time," he says. "Fibrosis is unavoidable, as we demonstrated in our 2015 paper published in the *Journal of Refractive Surgery*.<sup>3</sup> You have a maximum of six months [of full motion] during the follow-up, due to capsular bag shrinkage and contraction. On the other hand, our studies have shown that the Lumina works even if the capsular bag is broken during surgery (which happened in one case), and following YAG laser capsulotomy."

Asked about potential limitations of this technology, Dr. Alió explains that the range of accom-

# DID YOU KNOW?

# KEELER

*has slit lamps!*

For over 100 years, we have been creating innovative products. The Keeler slit lamp is one of them – designed with you and your patients in mind. The KSL delivers a visually pleasing, customizable device equipped with excellent, high-quality optics.

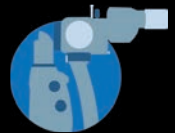## SLIT LAMP FEATURES



Sharp & clear  
Keeler Optics



KSL-H series:  
tower illumination




KSL-Z series:  
lower illumination



Digital-ready  
& full digital units



3x magnification  
drum (10x, 16x, 25x)



5x magnification  
drum (6x, 10x, 16x,  
25x, 40x)



Unique 1mm  
square for Uveitis  
evaluation



Bright & white  
LED illumination

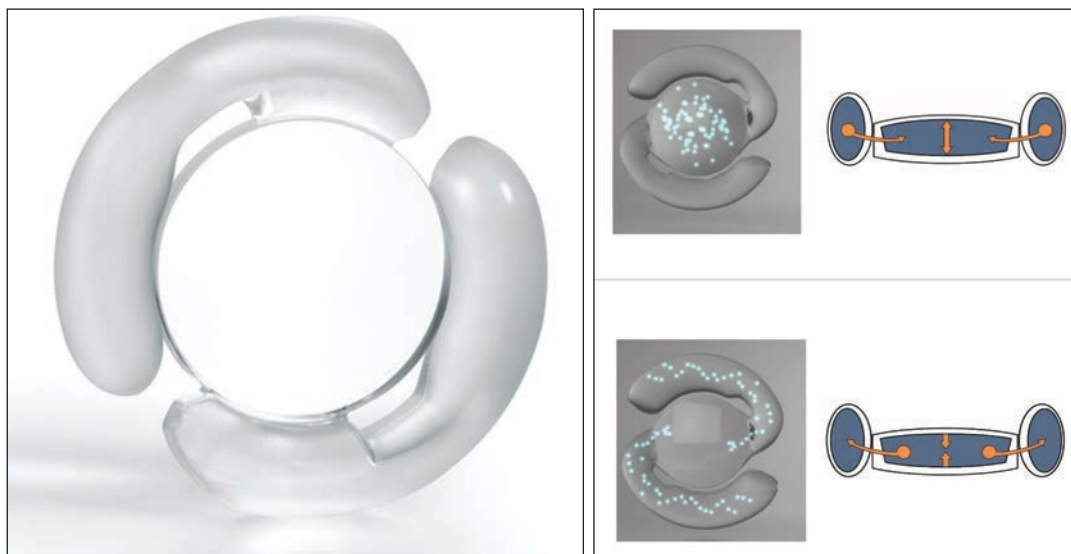


We also carry  
portable slit lamps!

VISIT OUR WEBSITE FOR MORE PRODUCT DETAILS

[www.keelerusa.com](http://www.keelerusa.com) / 800-523-5620

# Keeler



The FluidVision accommodative lens is hollow and filled with liquid silicone—including the haptics. As the ciliary muscles tighten, a small amount of fluid in the haptics is pushed into the optic section of the lens, causing the anterior curvature of the optic to increase, enhancing near vision. When the muscles relax, the reverse occurs.

modation appears to depend on the anatomy of the eye. “The evidence that we have demonstrates that it accommodates from 1.5 D to more than 4 D,” he says. “The main limitation is the variability from eye to eye. That’s the only pitfall.” Dr. Alió adds that his accommodative lens group is the only one reporting clinical outcomes in peer-reviewed journals. “I challenge the others to publish what they have shown in meetings,” he says. “My bet is that intracapsular lenses will not work.”

The company says it’s currently developing new iterations of the Lumina that will allow it to pass through an incision of 2.2 to 2.4 mm. Also in the works are a yellow-tinted Lumina lens for blue-light filtering; a toric Lumina lens; an “add-on” Lumina unit that can be added to existing monofocal lenses to restore accommodation; and a pre-loaded injector.

In the meantime, the Lumina is now beginning large clinical trials in Spain and South America. The company says that approval in Europe is expected in the fourth quarter of 2019, followed by expected commercial expansion in Europe and other

countries that accept the European approval. FDA testing is expected to begin in 2020. Dr. Alió says that he hopes the Lumina lens will be available commercially in about two years.

### The FluidVision Lens

The FluidVision Lens (PowerVision/Alcon) is an acrylic device. The entire lens, including the haptics, is hollow and filled with liquid silicone, which allows the lens to change shape in response to ciliary muscle contraction and relaxation. As the ciliary muscles tighten, a small amount of fluid in the haptics is pushed into the optic section of the lens, causing the anterior curvature of the optic to increase, enhancing near vision. When the muscles relax, the reverse occurs. Earlier versions of the lens required a 3.5-mm incision for implantation; the latest version of the lens with a new injector is able to be implanted through a 3.2-mm wound.

The current version of the device, called the NextGen 20/20 model, is currently undergoing a multicenter international clinical trial. Six-month data, reported in the fall of 2018,

found good visual acuity at every distance, with an average accommodation range of 2 D. Louis D. Nichamin, MD, at the European Society of Cataract and Refractive Surgeons meeting in September 2018, reported data from 28 eyes that underwent monocular implantation with the lens at six sites in South

Africa. Distance vision was 20/20; intermediate was close to that; and near visual acuity ranged from 20/22 to 20/27. He also reported that an in-house autorefractor detected an average of 2 D of accommodation, with some eyes achieving as much as 5 D of accommodation.

Other randomized, controlled, multicenter studies are currently underway. The ORION study is comparing binocular implantation of the FluidVision lens to monofocals in 54 patients at seven sites in South Africa. The CLEAR study is comparing the FluidVision to trifocal intraocular lenses at multiple centers in multiple countries. Meanwhile, the company is developing a prototype toric version of the IOL, and is working on a model that would be refraction-adjustable after implantation. The latter may be implantable through a 2.8-mm incision. **REVIEW**

1. Alió JL, Simonov A, Plaza-Puche AB, et al. Visual outcomes and accommodative response of the Lumina accommodative intraocular lens. *Am J Ophthalmol* 2016;164:37-48.
2. Alió JL, Simonov AN, Romero D, et al. Analysis of accommodative performance of a new accommodative intraocular lens. *J Refract Surg* 2018;34:2:78-83.
3. Alió JL, Ben-Nun J. Study of the force dynamics at the capsular interface related to ciliary body stimulation in a primate model. *J Refract Surg* 2015;31:2:124-8.



# Santen, turning the pressure of glaucoma into progress

With an aging population, we recognize the increasing pressure of managing glaucoma for patients who are living longer and want to maintain independence. At SANTEN, we're committed to developing novel therapeutic solutions that will advance your approach to glaucoma management and help you preserve your patients' vision.

Learn more about our pipeline and our mission to preserve eyesight at [www.SantenUSA.com](http://www.SantenUSA.com)





# How to Handle Astigmatism After PK

A veteran corneal surgeon reviews the full spectrum of tools and techniques for managing these unique cases.

*Majid Moshirfar, Salt Lake City*

**T**hough the use of Descemet's stripping automated endothelial keratoplasty and Descemet's membrane endothelial keratoplasty has become more common, there are still patients for whom penetrating keratoplasty is the only option. For these patients, managing their post-PK astigmatism becomes the next order of business. In this article, I'll review how I treat these cases.

## The Evaluation

When approaching a case of astigmatism after PK, it's important to know the reason the patient had the transplant. This will help guide your management decision.

After practicing for 26 years, I've noticed that patients who develop astigmatism after PK are usually patients with keratoconus. Interestingly, after you remove the sutures from these patients, you'll sometimes see the astigmatism increase year

after year. This occurs because these patients have a further emergence of ectasia in the corneal transplant. The approach to such a patient is different from someone who had a PK due to trauma, herpes or Fuchs' (in older patients who had transplants before the advent of DSAEK and DMEK).

In the first month post-PK, I look at the level of corneal edema and epithelial healing, and focus on surface rehabilitation and dryness. After the first three months, we still evaluate the

ocular surface integrity, dryness, possible tissue rejection and inflammation, but the priority shifts to the topography and the refractive error.

Three months postop, I evaluate the topography in earnest and perform a detailed refraction. We perform and refine the refraction, identifying the axis of astigmatism. When viewing the topographic map, we try to determine if the tissue was distributed properly, the trephination was well-centered, and the corneal tissue was properly

distributed when they sutured it, and we check the eccentricity and quality of the trephination in the donor and the host. We also use tomography. Even though topography is still my number-one tool for deciding how to selectively remove the sutures and get a handle on the astigmatism, tomography helps me see if the corneal thickness and tissue distribution make sense.

The beauty of corneal tomography is that it gives you a volumetric analysis.

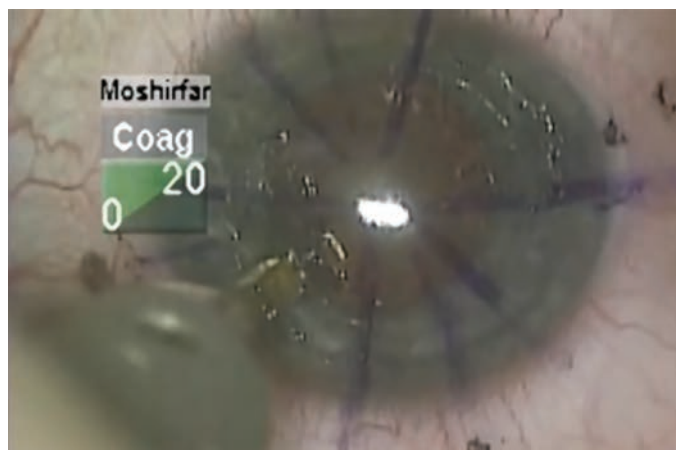


Figure 1. For some post-PK astigmatism, relaxing incisions and compression sutures can be effective. Here, the surgeon makes an incision at the donor-host interface on the steep axis to open the interface.





## MIGS SURGEONS CAN'T IGNORE **THE DATA IN THE ROOM**

Reporting the most medication-free patients and the largest IOP reduction compared to control of any MIGS pivotal trial at 24 months, the Hydrus<sup>®</sup> Microstent sets a new standard for high quality patient outcomes.<sup>1-4,\*</sup>

**Delivering a new confidence.**



©2019 Ivantis, Inc. Ivantis and Hydrus are registered trademarks of Ivantis, Inc. All rights reserved. IM-0007 Rev C



# HYDRUS<sup>®</sup> MICROSTENT

Delivering A New Confidence

**CAUTION:** Federal law restricts this device to sale by or on the order of a physician. **INDICATIONS FOR USE:** The Hydrus Microstent is indicated for use in conjunction with cataract surgery for the reduction of intraocular pressure (IOP) in adult patients with mild to moderate primary open-angle glaucoma (POAG). **CONTRAINDICATIONS:** The Hydrus Microstent is contraindicated under the following circumstances or conditions: (1) In eyes with angle closure glaucoma; and (2) In eyes with traumatic, malignant, uveitic, or neovascular glaucoma or discernible congenital anomalies of the anterior chamber (AC) angle. **WARNINGS:** Clear media for adequate visualization is required. Conditions such as corneal haze, corneal opacity or other conditions may inhibit gonioscopic view of the intended implant location. Gonioscopy should be performed prior to surgery to exclude congenital anomalies of the angle, peripheral anterior synechiae (PAS), angle closure, rubeosis and any other angle abnormalities that could lead to improper placement of the stent and pose a hazard. **PRECAUTIONS:** The surgeon should monitor the patient postoperatively for proper maintenance of intraocular pressure. The safety and effectiveness of the Hydrus Microstent has not been established as an alternative to the primary treatment of glaucoma with medications, in patients 21 years or younger, eyes with significant prior trauma, eyes with abnormal anterior segment, eyes with chronic inflammation, eyes with glaucoma associated with vascular disorders, eyes with preexisting pseudophakia, eyes with uveitic glaucoma, eyes with pseudoexfoliative or pigmentary glaucoma, eyes with other secondary open angle glaucoma, eyes that have undergone prior incisional glaucoma surgery or cilioablativ procedures, eyes that have undergone argon laser trabeculoplasty (ALT), eyes with unmedicated IOP < 22 mm Hg or > 34 mm Hg, eyes with medicated IOP > 31 mm Hg, eyes requiring or having extensive medications prior to surgery, in the setting of complicated cataract surgery with iatrogenic injury to the anterior or posterior segment and when implantation is without concomitant cataract surgery with IOL implantation. The safety and effectiveness of use of more than a single Hydrus Microstent has not been established. **ADVERSE EVENTS:** Common post-operative adverse events reported in the randomized pivotal trial included partial or complete device obstruction (7.3%); worsening in visual field MD by > 2.5 dB compared with preoperative (4.3% vs 5.3% for cataract surgery alone); device malposition (1.4%); and BCVA loss of  $\geq 2$  ETDRS lines  $\geq 3$  months (1.4% vs 1.6% for cataract surgery alone). For additional adverse event information, please refer to the Instructions for Use. **MRI INFORMATION:** The Hydrus Microstent is MR-Conditional meaning that the device is safe for use in a specified MR environment under specified conditions. **Please see the Instructions for Use for complete product information.**

**References:** 1. Samuelson TW, Chang DF, Marquis R, et al; HORIZON Investigators. A Schlemm canal microstent for intraocular pressure reduction in primary open-angle glaucoma and cataract: The HORIZON Study. *Ophthalmology*. 2019;126:29-37. 2. Vold S, Ahmed II, Craven ER, et al; CyPass Study Group. Two-Year COMPASS Trial Results: Suprachiliary Microstenting with Phacoemulsification in Patients with Open-Angle Glaucoma and Cataracts. *Ophthalmology*. 2016;123(10):2103-2112. 3. US Food and Drug Administration. Summary of Safety and Effectiveness Data (SSED): Glaukos iStent<sup>®</sup> Trabecular Micro-Bypass Stent. US Food and Drug Administration website. [https://www.accessdata.fda.gov/cdrh\\_docs/pdf8/PO80030B.pdf](https://www.accessdata.fda.gov/cdrh_docs/pdf8/PO80030B.pdf). Published June 25, 2012. 4. US Food and Drug Administration. Summary of Safety and Effectiveness Data (SSED): iStent inject Trabecular Micro-Bypass System. US Food and Drug Administration website. [https://www.accessdata.fda.gov/cdrh\\_docs/pdf17/P170043b.pdf](https://www.accessdata.fda.gov/cdrh_docs/pdf17/P170043b.pdf). Published June 21, 2018.

\*Comparison based on results from individual pivotal trials and not head to head comparative studies.



©2019 Ivantis, Inc. Ivantis and Hydrus are registered trademarks of Ivantis, Inc. All rights reserved. IM-0007 Rev C

## REVIEW | Refractive/Cataract Rundown

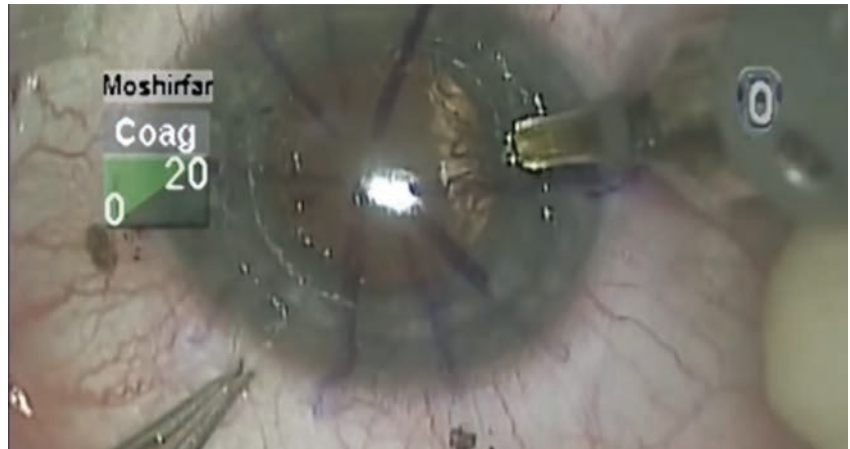


Figure 2. The patient from Figure 1. Now, the surgeon creates another incision in the interface on the steep axis. The incisions relax the severe adhesions in the interface.

It's not just measuring anterior elevation; it also gives some idea of the posterior elevation and the overall corneal thickness. When looking at the topography, I note the K1 and K2 values, and whether the pattern of astigmatism is orthogonal. If it is orthogonal, then the visual recovery will be better. If it's not—which, unfortunately, is often the case—you then attempt to make it more orthogonal by removing certain sutures, which leads us to a discussion of astigmatism management.

### Tackling the Astigmatism

Here are the current approaches to

managing post-PK astigmatism, from early postop to years later.

- **Suture removal.** In the immediate postop period, when the patient still has the transplant sutures in his cornea, you can adjust the astigmatism by manipulating the sutures. If a patient has interrupted sutures, you can judiciously remove some to try to redistribute the tissue and lessen the astigmatism. In evaluating the astigmatism, you may find that the sutures are tighter, and the astigmatism higher, in some meridians. You can remove these systematically to adjust the astigmatism. If I have a patient with interrupted sutures, I usually start remov-

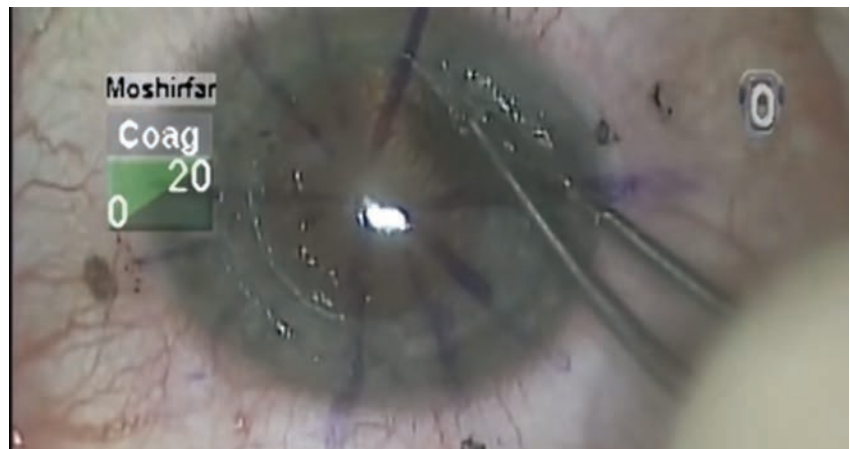


Figure 3. (cont'd from Fig. 2). The surgeon uses Colibri forceps to open the initial dissected adhesions at the interface in the steep meridian to prevent reclosure and fibrosis.

ing them every couple of weeks, starting after the first 12 weeks postop; I usually remove one to three at a visit, based on the topography and the tightness of the sutures.

On the other hand, if the patient has running sutures, it's harder to control the astigmatism with selective suture removal because if you cut the suture anywhere, it all has to come out. However, in some cases of running sutures, I've chosen to take the patient to the minor

procedures room at about four weeks postop, removed the epithelium, and tried to rotate the sutures. I try to loosen the quadrants that are tight, and tighten the sutures in the loose quadrants. This isn't as effective as working with interrupted sutures, of course, and the results are variable.

Once the sutures are out, and it's a year or two postop, you have to look to other options. Usually, this type of patient has a lot of anisometropia, and can't, or won't, tolerate wearing contact lenses. Here are your options:

- **Relaxing incisions/compression sutures.** If the astigmatism is very orthogonal and symmetrical, i.e., it has that nice figure eight configuration, and it's less than 6 D, many times you can do a relaxing incision in the steep meridian of the donor/host interface to reduce the astigmatism. On the other hand, if it's greater than 6 D—more like 8 D—sometimes you need to both place a relaxing incision in the steep meridian at the donor/host interface and place some compression sutures in the flat meridian 90 degrees away. Topography is invaluable for planning both the relaxing incision and the placement of any compression sutures.

- **Toric ICL.** The toric version of the Staar ICL was recently approved, giving us a new option for patients. If

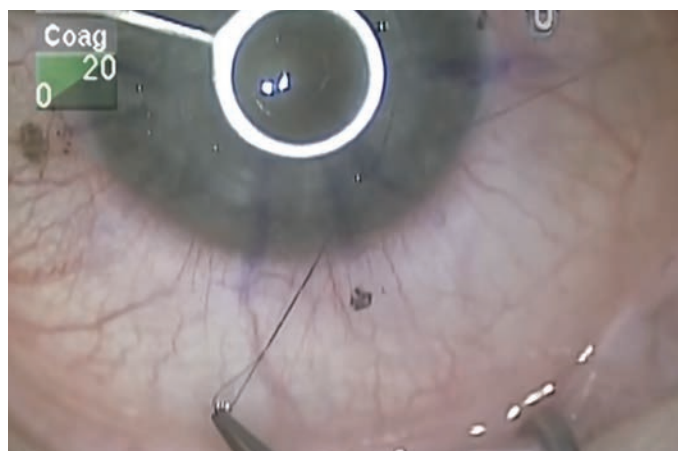


Figure 4. (cont'd from Fig. 3) The surgeon places compression sutures in the flat meridian and uses a Mertz Keratoscope to help titrate the suture tension to create a rounder cornea.

the patient is pseudophakic and has significant but orthogonal and symmetrical astigmatism, a toric ICL could be a good option. The benefit of the toric ICL is that it takes care of any myopia as well as the astigmatism.

- **Refractive lens exchange/toric IOL/femto incisions.** In some cases, if the astigmatism is orthogonal and symmetrical, the patient's cornea is otherwise normal and the patient is in the early cataract age range, sometimes RLE with the placement of a toric intraocular lens is a good option. An example of this would be the 62-year-old post-PK patient who comes to me with high astigmatism and high myopia, and has problems wearing contact lenses.

In some of these RLE patients, their astigmatism is too high to be corrected with just a toric IOL. For them, I follow the surgery with femtosecond-created, intrastromal arcuate keratotomy incisions located about 1 mm inside the donor/host interface. Sometimes I open these incisions at the time of their creation, sometimes not. In the latter, I'll return another day to try to titrate their effect by opening them.

- **Laser refractive surgery.** In the past, surgeons tried LASIK for these patients, but found that the results always regressed. At this point, for selected patients, PRK with adjunctive

mitomycin-C has actually proven to be a better option. The candidates for this are usually anisometric, with unilateral pathology (maybe a corneal laceration), who've had their cornea, iris or lens changed and we're not willing to perform a piggyback IOL procedure on them for some reason.

One note, though: if these patients have an old graft (older than eight years), sometimes they have significant endothelial edema, which will result

in corneal folds and edema for weeks after the PRK before the eye eventually recovers. These patients can have retarded epithelial healing and may still develop haze in spite of the mitomycin use.

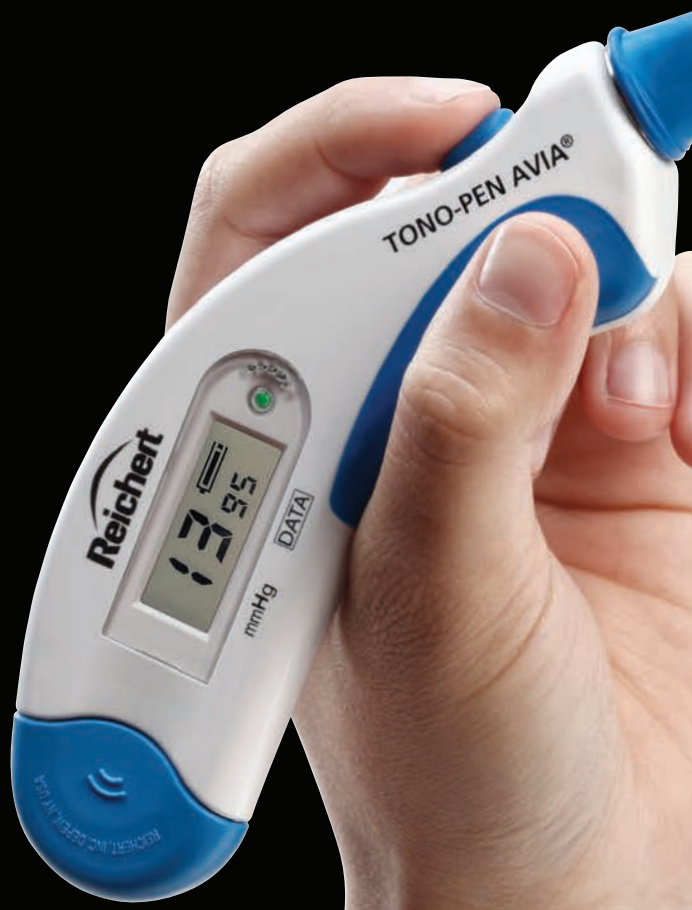
- **Wedge resection.** If the astigmatism is over 8 D, you may have to consider revising the corneal wound by way of a wedge resection. In the wedge resection, we selectively remove some tissue from certain quadrants. It's a classic approach that corneal surgeons have developed to manage a wide range of astigmatism.

- **Regraft.** Some problems are too big for a wedge resection, and require a new graft. For example, if the patient has 12 D of astigmatism eight or nine years postop, a regraft may be the best option. The regraft involves trephinating the cornea with a larger size, and re-transplanting a larger graft.

Though there's not a lot of reimbursement for these post-PK procedures, much of the reward comes from improving patients' vision and overall quality of life. **REVIEW**

*Dr. Moshirfar is medical director of the Hoopes Vision Refractive Research Center in Draper, Utah, and a professor of ophthalmology at the Moran Eye Center at the University of Utah.*

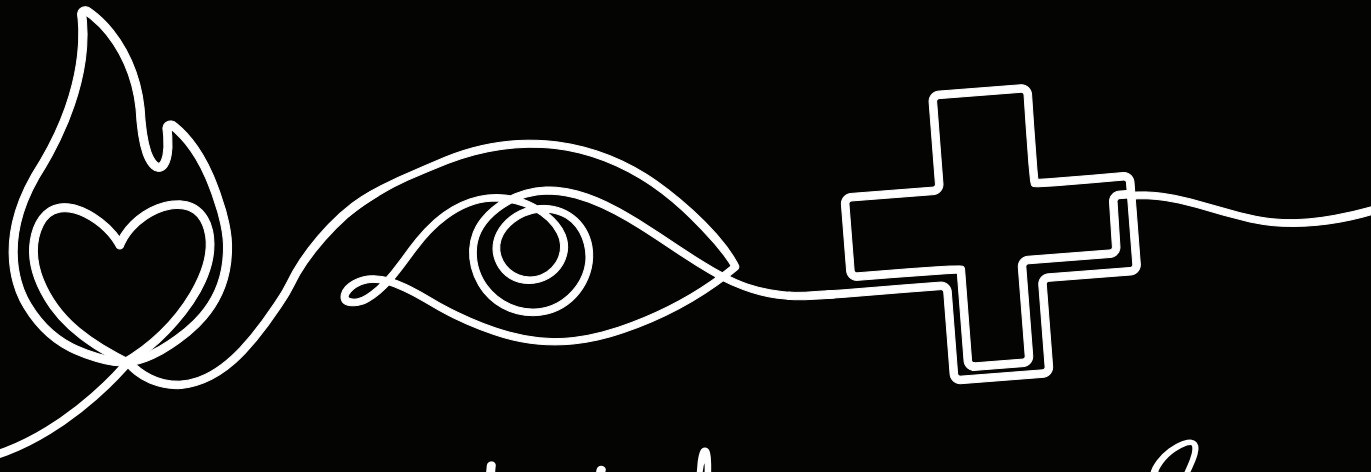




Name:	
08/08/2014	
(R)	10Pcc
(L)	16.7
	16.8
	10Pe
	20.1
	22.0

Reichert





# Passionate about glaucoma care?

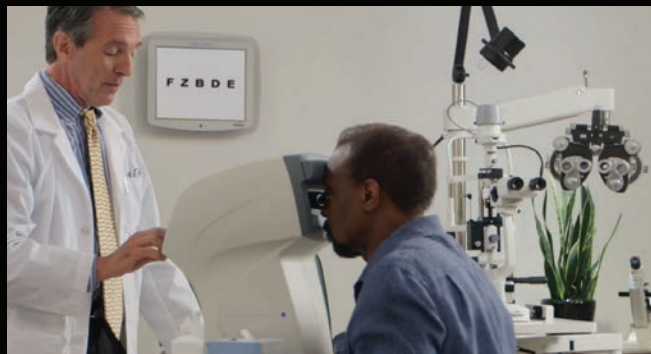
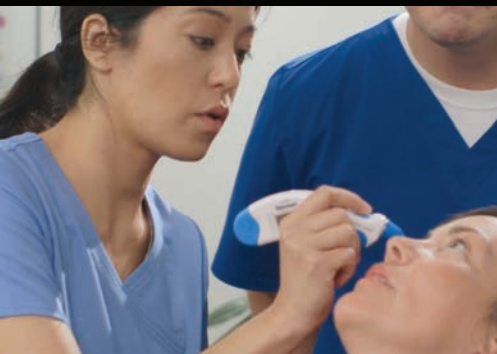FROM CORNEAL HYSTERESIS TO IOP, SO ARE WE.

Only **Ocular Response Analyzer® G3** measures **Corneal Hysteresis** and **Corneal Compensated IOP (IOPcc)** using patented technology to assess the unique corneal biomechanical properties of your patient. Corneal Hysteresis has shown to be an independent risk factor and more predictive of glaucoma development and progression than CCT or IOP<sup>1-3</sup>. Using biomechanics, IOPcc is less influenced by corneal properties than Goldmann applanation tonometry<sup>4</sup>.

Only **Tono-Pen AVIA®** continues to advance handheld tonometry with the all-new **Quick-Tap™** measurement mode. The same ready-to-use, calibration-free, and accurate operation, now with more confidence in fewer measurements. Trusted by clinicians for over 30 years. We share your passion for improving glaucoma care.

VISIT [REICHERT.COM/GLAUCOMACARE](http://REICHERT.COM/GLAUCOMACARE)

**Reichert**  
TECHNOLOGIES  
**AMETEK**



© 2019 AMETEK, Inc. & Reichert, Inc. (05-2019) · Ocular Response Analyzer and Tono-Pen are registered trademarks of Reichert, Inc. · Designed & assembled in USA

References: 1. Medeiros FA, Meira-Freitas D, Lisboa R, Kuang TM, Zangwill LM, Weinreb RN. Corneal hysteresis as a risk factor for glaucoma progression: a prospective longitudinal study. *Ophthalmology*. 2013 Aug;120(8):1533-40. 2. De Moraes CV, Hill V, Tello C, Liebmann JM, Ritch R. Lower corneal hysteresis is associated with more rapid glaucomatous visual field progression. *J Glaucoma*. 2012 Apr-May;21(4):209-13. 3. Susanna CN, Diniz-Filho A, Daga FB, Susanna BN, Zhu F, Ogata NG, Medeiros FA. Am J Ophthalmol. A Prospective Longitudinal Study to Investigate Corneal Hysteresis as a Risk Factor for Predicting Development of Glaucoma. 2018 Mar;187:148-152. doi: 10.1016/j.ajo.2017.12.018. 4. Felipe A, Medeiros, MD and Robert N. Weinreb, MD. Evaluation of the Influence of Corneal Biomechanical Properties on Intraocular Pressure Measurements Using the Ocular Response Analyzer. *J Glaucoma* 2006;15:364-370. CPT is registered trademark of the American Medical Association.

# MIGS and the General Ophthalmologist

*Christopher Kent, Senior Editor*

Experts answer 10 questions about how general ophthalmologists can make the most of these procedures.

Today, minimally invasive glaucoma surgeries, or MIGS, are being adopted by many general ophthalmic surgeons. Unlike many glaucoma surgeries—some of which are complex and involve significant postoperative care—MIGS tend to be straightforward, involving minimal risk and minimal follow-up. However, they also usually have a less-dramatic impact on intraocular pressure, making them best-suited for patients with early glaucoma—and for surgeons less interested in doing extensive patient follow-up.

Michele C. Lim, MD, professor of ophthalmology and vice chair and medical director of the U.C. Davis Eye Center in Sacramento, California, points out that many of the MIGS devices have been specifically marketed for general ophthalmologists. “Comprehensive ophthalmologists tend to do a lot of cataract surgery, and they usually see patients who have glaucoma at the earlier stages of disease,” she notes. “Because many of the MIGS to date work well for early to moderate glaucoma, the companies usually market their MIGS products toward those ophthalmologists.”

Dr. Lim notes, however, that the use of these devices has been somewhat limited by the nature of the FDA approvals. “Some of the devices, like

the iStent and the CyPass, were only approved for reimbursement when performed in combination with cataract surgery,” she says. “That’s kind of a shame, because patients who’ve already had cataract surgery could probably still benefit from these devices.”

Alan Crandall, MD, a clinical professor, senior vice chair of ophthalmology and director of glaucoma and cataract in the Department of Ophthalmology at the Moran Eye Center—part of the University of Utah in Salt Lake City—agrees. “Most MIGS have to be combined with cataract surgery if you want to get reimbursed,” he says. “Using those MIGS as stand-alone procedures would require getting the patient to pay out-of-pocket. For that reason I suspect most cataract surgeons will use them exclusively in combination with cataract surgery.”

Here, surgeons well-acquainted with the MIGS procedures share their answers to key questions that non-glaucoma-specialist surgeons often ask when thinking of adding one or more MIGS procedures to their armamentarium—especially as an option to combine with cataract surgery.

## **I** Which MIGS procedure should I learn?

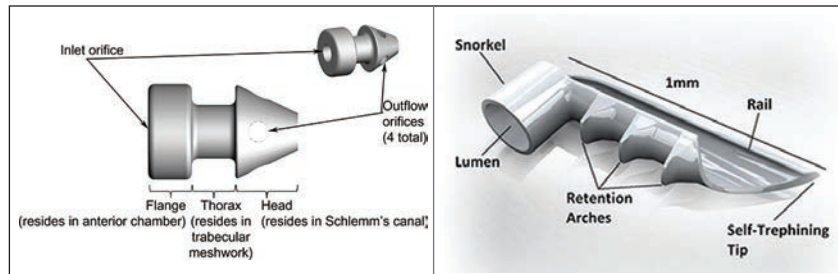
“I haven’t seen any surveys regard-

ing how many general ophthalmologists are using MIGS, or which ones they're using," notes Dr. Lim. "However, based on the referrals I get, I'd say that most general ophthalmologists are doing the iStent. That's most likely because it's one of the easier and safer MIGS to implant. Some of the other MIGS are more complex, and for the most part I've only seen glaucoma specialists do them."

Most MIGS surgeons seem to agree that a trabecular meshwork stent is a good place for a general ophthalmologist to start. "In this situation [when performing MIGS with cataract surgery], I'm a strong proponent of MIGS procedures that work synergistically with the effects of phacoemulsification," says Thomas W. Samuelson, a founding partner and attending surgeon at Minnesota Eye Consultants in Minneapolis and an adjunct professor of ophthalmology at the University of Minnesota. "We now have the results of five major, large-scale, prospective randomized MIGS trials in the literature. In all five of these trials, the control arm—i.e., phaco alone—lowered IOP significantly. The average composite IOP reduction in the control group of these papers was more than 5 mmHg. Thus, for combined surgery, I select MIGS procedures that are least likely to adversely affect that benefit and most likely to be synergistic with normal outflow physiology, such as a canal-stenting device. I'm less likely to use an ablative technique.

"The opposite might be said for procedures in pseudophakic eyes, where the cataract card has already been played," he adds. "Of course, canal stenting devices aren't labeled for standalone surgery anyway—at least for now."

"By far, conventional outflow enhancement with MIGS is the safest way to surgically lower IOP, although it's limited by episcleral venous resistance," says Ike Ahmed, MD, FRCSC, assistant professor of ophthalmology



Surgeons say the iStent Inject (above, left) makes it efficient to implant two stents, has a short learning curve and is easier to use than the original iStent (right). With the original, however, the position after insertion is easier to evaluate and adjust.

and research director at the Kensington Eye Institute at the University of Toronto, and a professor at the University of Utah. "Most MIGS procedures—including stenting, cutting and dilating approaches—work with the trabecular meshwork/Schlemm's canal pathway, and these procedures can be relatively efficiently combined with cataract surgery."

Dr. Crandall believes most general ophthalmologists would have the greatest success with trabecular meshwork stents. "There are a number of MIGS outflow devices to choose from, including iStent, iStent Inject and Hydrus," he points out. "The other MIGS options all have some potential drawbacks for a general cataract surgeon. Endoscopic cyclophotocoagulation, transscleral cyclophotocoagulation and micropulse transscleral cyclophotocoagulation are all reasonable choices for combining with cataract surgery, but the general ophthalmologist has to consider the cost of the machine, as well as the fact that the procedure may need to be redone. MIGS procedures that open the canal—OMNI, GATT, the Kahook Dual Blade and so forth—require wash-out and further care that most general ophthalmologists may not be comfortable with. And some of the others, such as MIGS devices that use the sub-Tenon's space, can be technically challenging, unless the surgeon has the right kind of experience. If the surgeon is comfortable performing trabeculectomy, the latter would be reasonable options." [More

on all of these options below.]

"A surgeon's choice of MIGS procedure should be customized for each individual patient," says Vikas Chopra, MD, medical director of the Doheny Eye Centers Pasadena, an associate professor of ophthalmology at the David Geffen School of Medicine at UCLA, and the director of glaucoma research at the Image Reading Center at the Doheny Eye Institute. "That being said, I think it's probably a good idea to initially try to enhance the patient's own outflow system rather than bypass it. I'd recommend a trabecular meshwork bypass procedure as the first-line choice, especially in patients with mild to moderate glaucoma and/or a desire to reduce topical medication burden.

"However, there may be exceptions," he notes. "For example, an older, monocular patient might not be a good surgical candidate because of systemic or ocular health issues. In that situation, it would make sense to consider a non-incisional procedure like micropulse transscleral cyclophotocoagulation first."

Dr. Lim points out that it's important to base your choice of MIGS procedure on the literature—while also keeping in mind the limits of the available studies. "Surgeons shouldn't base MIGS choices on hype, word-of-mouth or the latest trend," she says. "It's important to perform a review of the literature first. Of course, one caveat when reviewing MIGS literature is that most clinical trials report



short-term outcomes; very few have followed patients beyond 36 months. Longer studies might show even better efficacy—or they might find the opposite. I think we saw that with the original iStent. The data did show superiority with pressure control after one year, but when the two-year study came out, you could see that the pressure control started to wane.

“In terms of different treatment modalities that have the same goal, such as placing an iStent vs. placing a Hydrus, there are no comparative studies at this time showing that one is superior to the other,” she adds. “However, if you’re a surgeon who sees a great deal of glaucoma, I think you should explore multiple treatment options.”

**2** *If I choose the iStent, which should I start with: the iStent or the iStent Inject?*

Dr. Ahmed explains that the original iStent and the iStent Inject each have their own rationale. “First of all, the iStent Inject makes it efficient to put two implants in,” he says. “We believe that does enhance the IOP-lowering ability of the intervention. Another advantage is that the Inject has a shorter learning curve, which is helpful for surgeons that haven’t placed many of the original iStents. I suspect it’s already motivated many comprehensive ophthalmologists to try it.

“However, I’ve had a lot of experience with the classic iStent,” he continues. “Here in Canada I often implant two of the original iStents, and I’ve had good success with that approach. With the first-generation iStent, I’m sure of the placement and I can easily make adjustments. However, when implanting the original iStent, the need to use lateral motion and the turning of the hand poses a technical challenge for a number of surgeons; the iStent Inject obviates that. Another difference between them is that gauging the depth of the

iStent Inject implants can be a bit of a challenge. With the original iStent, you have a better idea of whether or not the stent is inserted into the tissue correctly, and you can adjust it if necessary.

“In short, there are unique features and advantages to both devices,” he concludes. “However, if you’re a surgeon who’s never done MIGS procedures, I think you’ll find the iStent Inject easier to adapt to, with a shorter learning curve.”

*“Surgeons who aren’t interested in bleb management should stick to trabecular-meshwork MIGS.”*

*—Ike Ahmed, MD*

**3** *What about cyclophotocoagulation?*

Dr. Lim says she considers endoscopic cyclophotocoagulation and transscleral cyclophotocoagulation to be MIGS procedures. “I know some people would argue with labeling these procedures MIGS, because they use a laser,” she says. “However, in a way, transcleral cyclophotocoagulation is the ultimate MIGS procedure. It’s one of the most noninvasive things you can do. Then there’s the micropulse CPC, which is being marketed as even less invasive than continuous-wavelength TSCPC. Both CPC and TSCPC have worked well for many of my patients. ECP is more invasive, of course, but many doctors do it in conjunction with cataract surgery.

“The downside of these procedures is that most comprehensive ophthalmologists don’t have access to those types of lasers,” she adds. “In fact, even some glaucoma specialists I

know refer patients to us for that because of laser access issues.”

Dr. Ahmed notes that the newest iteration, micropulse cyclophotocoagulation, is still a novel treatment. “It has some potential to reduce the side effects associated with other forms of CPC,” he notes, “and I do think cycloablation may have a role earlier in the course of treatment than we’ve traditionally used it, especially with the ability to do things in a safer manner. However, with this new approach I think we still need to learn more about the proper dosing and the right treatment for a given patient; we need more studies to determine the optimal settings. What’s the right duty cycle? The right energy delivery? The right timing? I don’t believe we’re ready to use micropulse CPC to treat very early glaucoma, or as initial therapy.”

**4** *What about the subconjunctival MIGS?*

“We have new classes of MIGS that bypass the angle completely and shunt fluid into the subconjunctival space, as a trabeculectomy or tube would do,” notes Dr. Lim. “They’re meant to address moderate to severe levels of glaucoma. The two things in this category are the XEN gel stent and the not-yet-approved InnFocus Microshunt. They’re still considered MIGS because they require less dissection of tissue than traditional surgeries. However, both of these do require manipulating the conjunctiva and injection or application of mitomycin-C. That puts them in a different class from the iStent or Hydrus.

“In general, I think the trickier and less-well-understood the procedure, the fewer comprehensive doctors you’ll find doing it,” she continues. “For example, the XEN is challenging to implant, and it’s a bleb-forming procedure that requires the use of mitomycin-C. Most comprehensive doctors don’t have a lot of experience with MMC, so I think you’re

EVERY MONDAY  
**E-NEWS YOU CAN USE**



**Have you been receiving and reading custom e-blasts from *Review of Ophthalmology*?**

**If not, you're missing out on valuable information!**

You're a busy practitioner and not surprisingly, your e-mail inbox is often full. Fortunately, when you scan through the sender list, determining which messages to delete and which to save or read, you can feel confident knowing that e-blasts from *Review of Ophthalmology*, a Jobson Medical Information LLC publication, contain the most current and comprehensive information available in the field to keep you on the cutting edge.

*Review of Ophthalmology's* online stable of products includes editorial newsletters and promotional information about new products, treatments and surgical techniques, as well as alerts on continuing education courses for ophthalmologists.



Our FREE weekly e-newsletter, *Review of Ophthalmology Online*, brings you the latest in ophthalmic research, as well as industry news. In an effort to keep eyecare professionals informed, this resource is waiting in your inbox **every Monday morning**.



*Retina Online*, our free monthly e-newsletter, is for retina specialists and general ophthalmologists interested in enhancing their knowledge on the topics of retina and related disease diagnosis and treatment, as well as the latest in surgical procedures.

Your time is valuable — and so is your practice. These e-products are the most effective way for you to receive updates on breaking news and research — all just a click away.

**DON'T MISS OUT!**

Unfamiliar with our products? Visit [www.reviewofophthalmology.com](http://www.reviewofophthalmology.com) and check out our newsletter archives.

Go to [www.jobson.com/globalEmail/default.aspx](http://www.jobson.com/globalEmail/default.aspx) to sign up for the e-newsletters that interest you.

less likely to see a non-specialist using the XEN. That goes for the InnFocus Microshunt as well, which isn't FDA-approved, although there's an ongoing U.S. clinical trial underway to try to gain approval."

Dr. Ahmed agrees. "Microstenting and microshunting devices that involve the subconjunctival space fall into a somewhat different category from the others," he says. "In those procedures, the management of the bleb is important, which means that managing those patients postop involves a different learning curve. Of course, a number of general and comprehensive ophthalmologists do feel comfortable managing a bleb, and for them I think performing these procedures is appropriate. For example, many comprehensive surgeons do trabeculectomies; that skill set would be perfect with this type of procedure. But if you're not accustomed to managing a bleb, these procedures will be challenging. Surgeons who aren't interested in bleb management should stick to trabecular-meshwork MIGS."

Dr. Lim notes that these more complex MIGS represent an exciting shift in where MIGS is going. "They give us options for people with more advanced levels of glaucoma," she points out. "We've learned from the previous MIGS that even if you bypass the trabecular meshwork, you're still not likely to get pressures below the mid-teens. People who have significant glaucoma need lower pressures than that. These newer devices are meant to provide treatment options that can compete with trabeculectomy or tube shunts."

## 5 Should I offer more than one MIGS procedure?

"Whether a general ophthalmologist should add more than one MIGS procedure to his or her armamentarium depends on several factors," says Dr. Chopra. "First, how comfortable are you with the type of procedure



The Hydrus Microstent maintains the patency of Schlemm's canal and tensions the canal tissue, improving outflow across a significant portion of the canal.

you're considering adding? Second, are you willing to manage any potential intraoperative and postoperative complications associated with the procedure? And finally, do you have enough surgical volume to allow you to manage the learning curve and continue to get better at the procedure?"

"The priority should be to be good at one MIGS procedure," says Dr. Ahmed. "Ideally, you should have a go-to MIGS and a go-to subconjunctival procedure, giving you two different mechanisms of action. Once you get very good at one MIGS procedure, then you may want to expand a little bit and try some others, just to see if there's a difference in efficacy or adverse events. But first it's important to become good at one procedure."

"I'd recommend becoming comfortable with a canal-stenting device, or at minimum a canal ablation procedure," says Dr. Samuelson. "Once you've mastered the first one, others are far easier to add. Transscleral surgery is a more significant level of commitment."

## 6 In which of my cataract cases should I consider adding MIGS?

"Understanding when it's appropriate to recommend MIGS is an important issue," says Dr. Lim. "I think the iStent is sometimes used in patients that don't really need it, for example, or in patients whose glaucoma is too severe to benefit from it. It's important to read the literature and understand when it's appropriate to implant these devices.

"The FDA put out a guidance paper that talks about who should be includ-

ed in clinical trials for MIGS and who should be excluded," she continues. "One of the excluded groups was people with ocular hypertension. I think the FDA felt that these people should not be subjected to the risk of MIGS surgery. They also recommended not including people with severe glaucoma, because you don't want to put people like that at risk by using an investigative device that has no known track record.

"The point," she concludes, "is that surgeons need to thoughtfully consider who they offer MIGS to. One shouldn't perform a MIGS procedure on every patient because they have an IOP problem or glaucoma. One needs to weigh the risks and benefits, as one would with any other surgery."

Dr. Samuelson says his decision about whether to add MIGS to a cataract surgery depends on the patient's disease status. "If the patient is being actively treated for glaucoma, or needs to be treated for glaucoma, I'd perform a combined procedure," he says.

Dr. Crandall agrees. "MIGS shouldn't be used unless the patient has a diagnosis of glaucoma and is being treated for it," he says. "In that situation, there's no harm, no foul, so to speak, if you add a MIGS procedure to the cataract surgery—although we always need to consider the cost to the patient."

Is there a specific level of disease at which a surgeon should automatically consider adding MIGS? Dr. Chopra says no. "The decision to add MIGS to cataract surgery has to be individualized," he says. "It should be dictated by the level of glaucoma, as well as the patient's ability to tolerate topical anti-glaucoma medications. The goal of adding MIGS to cataract surgery might be to achieve a lower IOP, to maintain the same IOP with a reduction in the medication burden, or to address the patient's topical medication non-compliance, which is quite common. Less-invasive procedures



# HOW TO SAVE WITHOUT COUPONS

Help your patients get affordable eye drops without searching for coupons



## TOTALTEARS®

The simple cash pay model of the Total Tears formulations\* eliminates the need for patients to hunt down coupons and allows for them to purchase their eye drops at affordable prices



Preservative Free Formulations

Klarity Drops®	10mL	Chondroitin sulfate ophthalmic solution	\$20/bottle
Klarity-A™ Drops	3.5mL	Azithromycin 1% / Chondroitin sulfate ophthalmic solution PF	As low as \$40/bottle** <small>When purchased as a pack of 3</small>
Klarity-B™ Drops	5.5mL	Betamethasone 0.1% / Chondroitin sulfate ophthalmic solution PF	As low as \$40/bottle** <small>When purchased as a pack of 3</small>
Klarity-C Drops®	5.5mL	Cyclosporine 0.1% / Chondroitin sulfate ophthalmic emulsion PF	\$50/bottle
Klarity-L™ Drops	5mL	Loteprednol 0.5% / Chondroitin sulfate ophthalmic solution PF	As low as \$40/bottle** <small>When purchased as a pack of 3</small>

No Prior Authorizations | No Coupons | No Pharmacy Hassles

Learn more at [www.TotalTears.com](http://www.TotalTears.com)

\*For professional use only. ImprimisRx specializes in customizing medications to meet unique patient and practitioner needs. ImprimisRx dispenses only to individually identified patients with valid prescriptions. No compounded medication is reviewed by the FDA for safety or efficacy. ImprimisRx does not compound copies of commercially available products. References available upon request.

\*\* Klarity-A, Klarity-B, Klarity-L offers tiered pricing at \$59 for a single bottle, \$99 for 2 bottles, and \$119 for 3 bottles

Total Tears, Klarity Drops, Klarity-A, Klarity-B, Klarity-C Drops, Klarity-L, ImprimisRx are trademarks of Harrow Health, Inc. ©2019 ImprimisRx. All Rights Reserved. IMP00382 04/19

**imprimis** Rx®  
844.446.6979

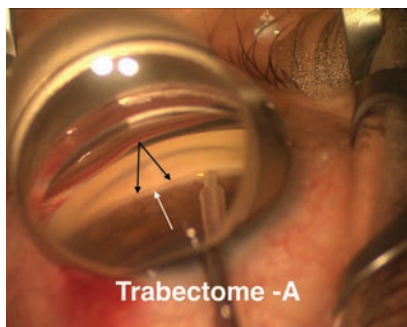
may be safer, so in general I prefer a stepwise approach to choosing a surgical treatment.”

Dr. Ahmed agrees that many factors should be considered. “The decision about whether to add a MIGS procedure to cataract surgery should be based on the disease state; the stability of the disease; the age of the patient; the number of drops the patient is using; how well the drops are tolerated; and how compliant the patient is,” he says. “You may have a patient who’s on one drop but never uses it. Without that drop, his pressures might be 28 mmHg and at risk of getting worse. If you’re performing cataract surgery on that patient, you should consider adding MIGS. Generally, the more drops the patient is on, the more potential value MIGS has, because it may reduce the drop load. But even patients who are only on one medication have a good chance of getting off of their medication with a MIGS procedure.

“At the same time, we do need to remember that cataract surgery will lower IOP on its own,” he notes. “It just seems to be the case that phaco plus MIGS has a greater likelihood of getting patients off of their medications, or resulting in the need for fewer drops. You might say to a patient: ‘I can do a procedure that’s pretty much as safe as cataract surgery alone, but there’s a greater chance that you’ll be able to get off of medication. The chance of that happening might be 50 percent with cataract surgery alone, but 85 percent if I add MIGS.’

“Basically, I think any time you’re performing cataract surgery on a patient who has glaucoma, you should at least consider adding a MIGS procedure,” he says. “If it might help the patient reach the right target pressure and reduce medication use, that person is a candidate. That’s a pretty wide potential range of patients.”

Dr. Ahmed adds that factors such as the system, payer and the patient’s quality of life are important to take



Ronald L. Fellman, MD

The Trabectome unroofs Schlemm’s canal to improve outflow. Above: A Trabectome positioned adjacent to the trabecular meshwork (black arrows). The white arrow points to the scleral spur.

into account. “You have to consider the cost-effectiveness of adding a second procedure,” he notes. “If the patient just has ocular hypertension or very early disease, or the patient is compliant with a minimal amount of medication and 80 years old, maybe adding MIGS wouldn’t be cost-effective. The other side of the coin is a patient who has very bad disease and is uncontrolled. That patient should get something more aggressive than a trabecular-meshwork MIGS, such as a subconjunctival procedure, whether it’s subconjunctival MIGS or a trabeculectomy. A trabecular-meshwork MIGS wouldn’t be enough for someone who’s progressing and needs a very low pressure.”

### **7** *Should the severity of the glaucoma affect my choice for a given patient?*

Dr. Samuelson says his usual choice of a canal-based MIGS procedure to add to cataract surgery might be modified based on current disease severity and his best estimation of the likelihood of future progression. “I generally prefer the stealth nature of the canal-stenting devices,” he says. “The milder the disease and the closer the outflow system is to normal, the less I want to disturb tissue. The canal-stenting devices cause the least tissue disruption. For me, for now, this

means using the iStent.

“On the other hand, the more significant the disease, presumably indicating worse outflow system functionality, the more I’m willing to disrupt tissue,” he continues. “The Hydrus spans more of the coveted inferonasal portion of the canal, which, on the positive side, should convey more device-influenced outflow. However, it’s also more tissue-disruptive. So when selecting among in-dwelling canal devices, I tend to use focal stenting—i.e., the iStent—for lesser disease, and more expansive stenting—i.e., the Hydrus—as I move up the spectrum of disease severity.”

Dr. Samuelson adds that he tends to reserve ablative or incisional canal procedures for standalone interventions without coincident cataract surgery. “In those situations I’ve grown increasingly satisfied with the OMNI device, which can dilate the entire 360 degrees of the canal or a portion thereof, and lets me incise as much of the canal as I wish,” he says. “The Ellex iTrack and the Kahook Dual Blade are also very reasonable choices in this setting.”

Dr. Lim notes that when obstruction of the trabecular meshwork is part of the disease process, MIGS procedures that strip away tissue to unroof Schlemm’s canal might be a good choice. “Patients that could benefit from this might include those with pigment dispersion glaucoma, uveitic glaucoma and maybe pseudoexfoliation,” she says. “I haven’t used the Kahook Dual Blade yet, but I see it as a reasonable option whenever the problem involves an obstruction of the trabecular meshwork.”

### **8** *Which MIGS works best in the presence of inflammation?*

Dr. Samuelson says that inflammation can be an important determinant of the MIGS procedure he chooses. “For example, if a patient is in need of chronic, ongoing steroid therapy,

Hypochlorous Acid Solution  
**NOW Available *Without* a Prescription**

**zenoptiq™**  
Hypochlorous Acid Solution

**zenoptiq™**  
0.01% Hypochlorous Acid

Daily Eyelid  
& Eyelash Hygiene  
Solution

Gentle | Soothing | All Natural



3.38oz (100mL)

**zenoptiq™**  
0.0085% Hypochlorous Acid

Daily Eyelid  
& Eyelash Hygiene  
Solution

Gentle | Soothing | All Natural



2.0oz (60.0mL)

## Daily Eyelid & Eyelash Cleanser

- Naturally removes foreign matter
- Nontoxic, nonirritating
- Has been shown in studies to reduce bacteria/microbes
- Formulated to relieve symptoms of MGD, Blepharitis and Dry Eye
- Available in 0.01 % HOCL spray and 0.085% HOCL gel

LEARN MORE AT  
**zenoptiq.com**



(866) 752-6006 – FocusLaboratories.com

Trademarks: Zenoptiq™ (Paragon BioTeck, Inc.) | Copyright © 2018 Paragon BioTeck, Inc. All Rights Reserved.

FLM191-0119-01



I'm less likely to select a canal-based procedure because, collectively, those procedures are more associated with steroid-related increases in intraocular pressure," he explains. "I'm more likely to perform a subconjunctival outflow MIGS such as a gel stent in this setting. If the disease is severe enough, I might resort to a trab or tube.

"If a general ophthalmologist performing cataract surgery is faced with a glaucoma patient on chronic steroids, I'd recommend skipping canal-based MIGS and performing XEN or trabeculectomy," he says. "If the surgeon is uncomfortable with these procedures, I'd consider referring the patient to a glaucoma specialist."

Dr. Chopra agrees that combining MIGS with cataract surgery in the setting of ocular inflammation can be quite complicated. "You may need to perform concurrent surgical maneuvers such as disrupting posterior synechiae, using pupillary dilators and managing peripheral anterior synechiae," he points out. "Trabecular bypass procedures such as Trabectome and goniotomy with the Kahook Dual Blade can be successful in these situations, but it's important to aggressively control inflammation postoperatively to reduce the risk of trabecular cleft closure due to the development of posterior synechiae."

## 9 *Should the MIGS I consider adding be influenced by the condition of the cataract and zonules?*

"If you detect weak zonules, either preoperatively or intraoperatively, the risk of vitreous loss is greater," Dr. Chopra notes. "In that situation, the benefits of MIGS have to be carefully weighed against the risks of the procedure. It may be safer to avoid MIGS and consider referral to a glaucoma subspecialist for a more traditional glaucoma procedure such as an aqueous tube shunt implantation. In these surgeries the focus should be on suc-

cessful, safe cataract removal, paying special attention to avoiding iatrogenic worsening of the zonulopathy. It may be better to 'live to fight another day' and perform the cataract and glaucoma procedures sequentially instead of concurrently."

*These surgeries require mastery of gonioscopy and a thorough knowledge of angle anatomy.*

Dr. Chopra points out that some cataracts might warrant performing the MIGS procedure before the cataract surgery. "If a patient has a very dense cataract that may require longer cataract surgical time and more phacoemulsification power, as well as greater irrigation and aspiration volume, you may be left with significant corneal edema by the end of the cataract procedure—especially over the incision," he says. "In that situation, it may be prudent to consider performing the trabecular bypass procedure before cataract surgery when the cornea is most clear. If you wait until after the cataract surgery is complete, proper visualization of the angle using the gonioscopic lens may be more challenging because of the corneal edema."

Dr. Ahmed believes the complexity of the cataract is a separate issue. "Combining the surgery with MIGS doesn't necessarily make it more difficult to manage the complexity of the cataract surgery," he says. "Of course, in some cases it could make things more difficult; some MIGS procedures, for example, have a higher chance of causing bleeding in the eye or hyphemas. That could impact the

surgeon's ability to manage a patient who needs more complex cataract surgery, such as a patient with weak zonules, so the surgeon has to consider that. However, in our clinic we have a lot of experience with complex cataract surgery, such as cases involving trauma or pseudoexfoliation. Those patients often have glaucoma associated with their underlying diseases, and most of them do quite well with MIGS. So why not combine the surgeries?"

## 10 *What other strategies will help ensure success?*

Surgeons offer these pearls to general ophthalmologists who are adding MIGS to their cataract surgery options:

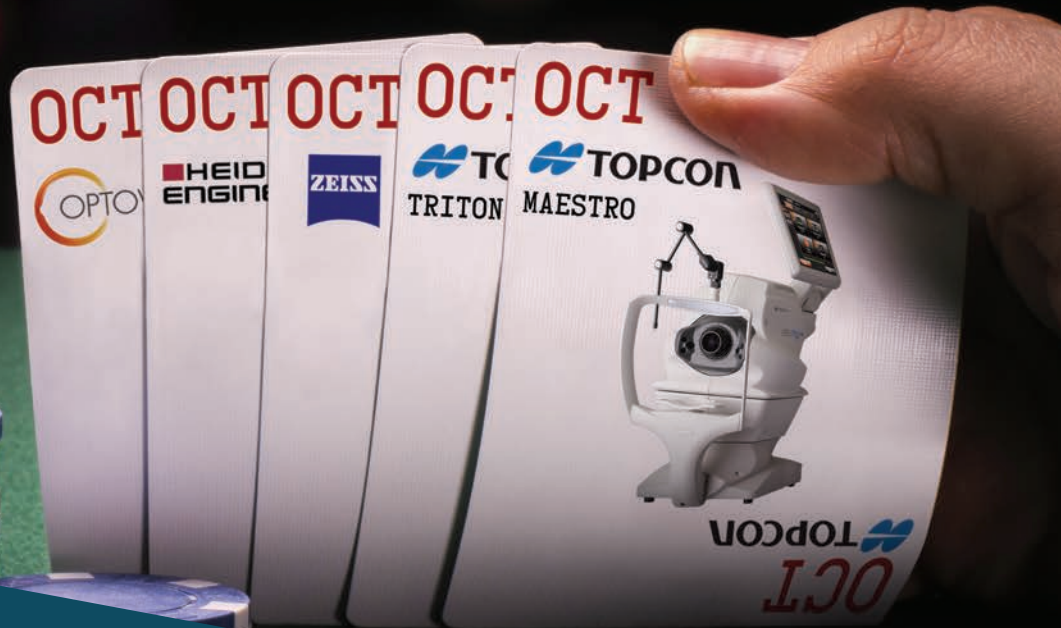- **Do your homework before performing any MIGS surgery.** Practice makes perfect," says Dr. Chopra. "I would strongly encourage any surgeon thinking of adding MIGS to their repertoire to watch surgical videos of the procedure in question to learn the technique; work with industry reps to do 'personalized wet labs'; sign up for surgical wet lab training at meetings like ASCRS and AAO; and talk to colleagues and glaucoma specialists who are well-acquainted with the procedure, to learn tips and surgical pearls."

- **Practice gonioscopy and know the angle anatomy.** All MIGS surgeons agree on one thing: These surgeries require mastery of gonioscopy and a thorough knowledge of angle anatomy. "We get referrals from doctors who implant iStents, and we sometimes find that the placement is incorrect," says Dr. Lim. "The device is either poorly positioned or not in the trabecular meshwork at all. So it's important to perform gonioscopy often, to become familiar with the anatomy of the angle."

"Understanding the surgical anatomy—especially the iridocorneal angle—is incredibly important to a successful MIGS procedure," agrees

# FIVE OF A KIND BEATS ANY DEALER'S HAND.

CONSULT LOMBART AND GET *YOUR* WINNING HAND.



- ✓ BROAD PORTFOLIO OF **NEW AND PRE-OWNED** ADVANCED TECHNOLOGY EQUIPMENT
- ✓ DEDICATED, KNOWLEDGEABLE **ADVANCED TECHNOLOGY DIRECTORS**
- ✓ **CLINICAL SUPPORT TEAM** FOR ONGOING TRAINING
- ✓ CONSULTATIVE APPROACH TO FIND THE **RIGHT SOLUTION FOR YOU**

**LOMBART**  
YOUR OPHTHALMIC PARTNER

Lombart Instrument is the nation's largest distributor of ophthalmic instruments, services, and supplies. Since our founding in 1979, we have been dedicated to creating long-lasting partnerships and serving our customers: optometry and ophthalmology practices, universities, hospitals, and the US government. It is because of the effort of our incredible staff that we have been the industry leader since 1987, and we work hard every day to provide the highest quality service to our customers.

**800.LOMBART**  
LOMBARTINSTRUMENT.COM

CONTACT YOUR LOMBART REPRESENTATIVE TO SEE WHICH OCT BEST FITS *YOUR* PRACTICE.

Dr. Chopra. “That’s often underappreciated. That’s why achieving expertise in clinical and surgical gonioscopy is essential.”

However, Dr. Samuelson says this shouldn’t cause surgeons to be put off. “MIGS procedures are very delicate,” he says. “They involve some of the most precise maneuvers we do as anterior segment surgeons. However, if you’re an accomplished cataract surgeon, you’ll be able to learn and master MIGS. Just don’t try MIGS until you’re very confident with intraoperative gonioscopy. MIGS procedures are very safe, but significant risk may be involved when they’re attempted without good visualization.”

Dr. Ahmed agrees, noting that the positioning of the patient on the table is part of good visualization. “The most important thing, in order to succeed with MIGS procedures, is to hone in on the setup and positioning of the patient, and the visualization—meaning gonioscopy—in the clinic and the OR,” he says. “You can learn these things without even doing MIGS. You can practice with cataract eyes, just tilting the microscope and the head of the patient at the end of the case, to get a better view.”

Dr. Lim adds that an excellent way to improve your angle structure knowledge is to visit [gonioscopy.org](http://gonioscopy.org). “This is a fabulous resource, created by Lee Alward, MD, at the University of Iowa,” she notes.

• **Weigh the risks (usually limited with MIGS surgery) against the benefits.** Dr. Lim points out that, as with any surgery, there’s always some amount of risk to weigh against the potential benefits. “Sometimes the risks take a while to become apparent,” she says, noting that this is another reason to pay attention to the literature. “For example, with the CyPass, adverse events were noted before it was recalled—issues that were not apparent in the original COMPASS trial. Some surgeons reported an unexpected my-

opic shift, while others witnessed a sudden, acute rise in pressure months after the CyPass was implanted. Another example is the iStent. The adverse events reported in the literature were fairly minimal, but I did have one patient who bled profusely during an implantation, and that led to a very high, prolonged IOP rise.”

• **Have realistic expectations.** “It’s important that all surgeons and patients and payers understand that with our current level of knowledge, anything we do to address glaucoma tends to wear off over time, at least to some degree,” Dr. Ahmed says. “That’s true of every option—drops, lasers, trabeculectomy, tubes and MIGS. It’s a result of the nature of the disease, and the way the eye recovers and heals after these surgeries. It shouldn’t surprise anybody, and it certainly hasn’t caused us to stop treating glaucoma.

“When we’re treating glaucoma, we continue to manage the patient over time,” he points out. “We go from one treatment to the next, to the next. The right algorithm and selection of drops and procedures and devices will hopefully stabilize intraocular pressure enough to prevent progression over the course of a patient’s lifetime. Accomplishing that may require multiple modalities, and the iStent and other MIGS are part of that paradigm—especially with their excellent track record of safety.”

### Adding Value for Your Patients

“I think any surgeon doing cataract surgery should be able to offer MIGS to appropriate patients,” says Dr. Ahmed. “The safety of MIGS has been established, and the safety of combining cataract surgery with MIGS doesn’t seem to be much different than regular cataract surgery, which is important. Recovery time doesn’t seem to be any different either. Meanwhile, the potential benefits for the patient are significant. MIGS can help

reduce the patient’s medication load, which can also enhance the patient’s visual recovery by improving the ocular surface, so patients end up seeing better. That can increase the patient’s quality of life, without much downside in terms of complications.”

“Some surgeons would say that MIGS shouldn’t be used at all,” notes Dr. Crandall. “They sometimes refer to these procedures as ‘MEGS,’ or ‘minimally effective glaucoma surgeries.’ I’m not in that group. Many of our patients have glaucoma that’s under control. If a MIGS procedure can get those patients off of even one medication, that’s a good thing. For that reason, I’m happy to see general ophthalmologists using MIGS.

“Again,” he adds, “experience is key. So, I’d suggest that most general ophthalmic surgeons interested in MIGS find a device that works for them and then become good at using it.”

“I’d encourage surgeons to do this,” Dr. Ahmed concludes. “There’s a technical learning curve that surgeons need to master, and appropriate patient selection is important. But I think the day is coming when a cataract surgeon who isn’t able to offer MIGS will be seen as behind the times. If a patient comes in with glaucoma and is taking a number of drops, you have a better chance of reducing his medication burden if you add MIGS to the cataract surgery. So why not offer it?” **REVIEW**

*Dr. Samuelson is a consultant for Alcon Surgical, Johnson & Johnson Vision, AqueSys/Allergan, Equinox, Glaukos and Ivantis. Dr. Ahmed is a consultant for Alcon, Allergan, Equinox, Glaukos, Ivantis and Santen. Dr. Crandall is a consultant for Ivantis, Glaukos and Alcon. Dr. Lim is an investigator for Santen (which now owns the InnFocus device) and has been a speaker for Alcon. Dr. Chopra reports to relevant financial ties to any product mentioned.*



(Continued from page 3)

brought against the company. However, this was significantly less money than the millions Allergan had first sought.

Mark Baum, founder and board member of ImprimisRx, says the ruling was fair, stating that he doesn't think Allergan was harmed. He says that ImprimisRx's attorney made the case that the supposed false statements cited by Allergan didn't seem to matter until Imprimis entered the glaucoma and dry-eye spaces. In regard to the alleged false statements, Mr. Baum notes that they weren't made intentionally and were there for many years before Allergan sued.

Allergan declined to comment on the ruling, stating that the company doesn't discuss litigation.

## Tear Biomarkers and Systemic Disease

Screening for two debilitating diseases, Alzheimer's and Parkinson's, may become part of future eye exam protocols, according to two papers presented at the recent meeting of the Association for Research in Vision and Ophthalmology in Vancouver, Canada.

Researchers investigated the diagnostic potential of tears as a source of peripheral biomarkers for Alzheimer's. They found that tear total-tau and amyloid-beta 42 (A $\beta$ 42) levels have reasonable discriminatory power for the AD state and could be diagnostic markers. They note, however, that studies with larger sample sizes are required to confirm these results.<sup>1</sup>

The team investigated the tear bio-

marker level of total-tau and A $\beta$ 42 in a cohort of 25 patients with AD, mild cognitive impairment (MCI) or subjective cognitive impairment (SCI) and nine healthy controls.<sup>1</sup> The results confirmed that the levels of tear total-tau and A $\beta$ 42 changed with increasing AD stage. They discovered a significant increase in total-tau in tears of AD patients compared with SCI patients and MCI patients.<sup>1</sup>

Future work on biomarkers must be able to characterize a patient's underlying pathophysiology, the study authors argue. This requires an expansion of the current biomarker panel, a critical move to allow a broader characterization of pathology in patients with AD by identifying different subtypes.<sup>1</sup>

While the investigation into tear biomarkers for AD is in its early stages, biomarkers for Parkinson's disease are already well-known. These patients often present with symptoms of cholinergic dysfunction years prior to showing motor symptoms. Tear secretion is greatly stimulated by cholinergic neurons; thus, specific proteins in tears may be altered by changes in the function of nerves regulating lacrimal secretion. Tear proteins are potential biomarkers for PD at different stages of the disease.<sup>2</sup>

Researchers from the University of Southern California found that tear levels of alpha-synuclein ( $\alpha$ -Syn) may be able to discriminate between PD patients and healthy controls. They note that reflex tear  $\alpha$ -Syn levels demonstrated a greater increase and sensitivity in distinguishing PD patients from healthy controls than basal tears and illuminated differences in lactoferrin that aren't seen in basal tears, offering a more reliable and sensitive source of biomarkers for PD.<sup>2</sup>

The team collected basal tears from 93 PD patients of varying disease severities and 82 healthy controls with an anesthetized Schirmer's test. Reflex tears were collected from 84 PD patients and 83 healthy controls with an

un-anesthetized Schirmer's test. They then pooled samples from both eyes to analyze their levels of total  $\alpha$ -Syn, oligomeric  $\alpha$ -Syn, LF and matrix metalloproteinase-9 (MMP-9).

They found total  $\alpha$ -Syn was significantly decreased in basal tears in PD patients relative to healthy controls. On the other hand, oligomeric  $\alpha$ -Syn was significantly increased in basal tears compared with healthy controls. The study findings indicated that there was no difference in LF or MMP-9 between PD patients and healthy controls in basal tears.<sup>2</sup>

In reflex tears, the researchers found oligomeric  $\alpha$ -Syn was significantly increased in PD patients compared with healthy controls and that total  $\alpha$ -Syn was unchanged. They note that a significant difference emerged in LF content in PD patients compared with healthy controls, but not in MMP-9.<sup>2</sup>

This work adds to the body of literature documenting the patterns and presentations of PD signals in human tear-film samples that may form the basis of future clinical testing protocols.

1. Gijs M, Nuijts RM, Ramakers I, et al. Differences in tear protein biomarkers between patients with Alzheimer's disease and controls. ARVO 2019. Abstract 1744.

2. Edman MC, Janga SR, Freire D, et al. Tear biomarkers for Parkinson's disease in basal versus reflex tears. ARVO 2019. Abstract 4196-B0554.

## Novartis Nabs Xiidra

In early May, Novartis bought dry-eye drug Xiidra (lifitegrast ophthalmic solution) 5% from pharmaceutical company Takeda for \$3.4 billion, with milestone payments of up to \$1.9 billion.

For its part, Takeda says it made the sale in order to focus on other business areas, and to eliminate the debt it had amassed following its purchase of Xiidra's original owner, Shire, which launched the drug in 2016. [REVIEW](#)



SAVE THESE DATES



# 3<sup>RD</sup> YEAR RESIDENT PROGRAMS & WET LAB

Dear CSE 3rd-Year Resident Program Director and Coordinator,

We would like to invite you to review the upcoming 3rd-Year Ophthalmology Resident Programs and Wet Lab for 2019 in Fort Worth, Texas. The programs offer a unique educational opportunity for third-year residents by providing the chance to meet and exchange ideas with some of the most respected thought leaders in ophthalmology. The programs are designed to provide your residents with a state-of-the-art didactic and wet lab experience. The programs also serve as an opportunity for your residents to network with residents from other programs.

After reviewing the material, it is our hope that you will select and encourage your residents to attend one of these educational activities, which are CME accredited to ensure fair balance.

Best regards,  
Kendall Donaldson, MD, Yousuf Khalifa, MD, Anjali Tannan, MD, & Mitch Weikert, MD, MS



## Third-Year Resident Wet Lab Programs 2019:

<b>August 2-3</b> (Friday-Saturday) Fort Worth, TX Course Director: Mitch Weikert, MD, MS	<b>August 16-17</b> (Friday-Saturday) Fort Worth, TX Course Director: Yousuf Khalifa, MD	<b>August 23-24</b> (Friday-Saturday) Fort Worth, TX Course Director: Anjali Tannan, MD	<b>September 20-21</b> (Friday-Saturday) Fort Worth, TX Course Director: Kendall Donaldson, MD
---	--	---	--

**Register Now:** [www.revophth.com/ResEdu2019](http://www.revophth.com/ResEdu2019)

**For more information:** Visit the registration site above or  
Email: [dholmes@postgradhealthed.com](mailto:dholmes@postgradhealthed.com) • Call: Denette Holmes 866-627-0714

Courses are restricted to US-based 3rd-year residents enrolled in a US-based ophthalmology resident program and within their third year at the time of the course. There is no registration fee for these activities. Air, ground transportation in Fort Worth, hotel accommodations and modest meals will be provided through an educational scholarship for qualified participants.

**Satisfactory Completion** - Learners must complete an evaluation form to receive a certificate of completion. Your chosen sessions must be attended in their entirety. Partial credit of individual sessions is not available. If you are seeking continuing education credit for a specialty not listed below, it is your responsibility to contact your licensing/certification board to determine course eligibility for your licensing/certification requirement.



**Physicians** - In support of improving patient care, this activity has been planned and implemented by Amedco LLC and Postgraduate Healthcare Education. Amedco LLC is jointly accredited by the Accreditation Council for Continuing Medical Education (ACCME), the Accreditation Council for Pharmacy Education (ACPE), and the American Nurses Credentialing Center (ANCC), to provide continuing education for the healthcare team

JOINTLY ACCREDITED PROVIDER™  
INTERPROFESSIONAL CONTINUING EDUCATION

**Credit Designation Statement** - Amedco designates this live activity for *AMA PRA Category 1 Credits™*. Physicians should claim only the credit commensurate with the extent of their participation in the activity.

Endorsed by:

Jointly provided by:

Supported by an independent medical education grant from:

**Review of Ophthalmology®**

**REG**  
(Review Education Group)



**Alcon**

# Why Trabs and Tubes Still Matter

James C. Tsai, MD, New York

A glaucoma expert describes situations in which surgeons still need the “big guns.”

In recent years, there’s been a lot of excitement about minimally-invasive glaucoma surgery. It’s important, however, to not let all that buzz eliminate thoughts of other, alternative procedures as you diagnose a patient’s glaucoma status and choose the best treatment. Sometimes, the best procedure for a patient with moderate to advanced glaucoma isn’t MIGS; the time-tested options of tube shunts and trabeculectomy are still vital parts of our surgical arsenal and, in these types of cases, may be the better choice.

## MIGS’ Shortcomings

The heart of the matter is that the amount of intraocular pressure reduction achieved by MIGS is often not impressive, though the procedures have proven to be safe overall. A lot of the IOP lowering efficacy of these procedures is likely the result of their being combined with cataract surgery. When I’m discussing the various surgical options with my glaucoma patients, I often use a baseball analogy: MIGS can be viewed as a hitter who doesn’t hit home runs, but instead routinely hits singles and occasionally doubles with very few strikeouts.

In addition to modest amounts of

pressure reduction (which will most likely leave patients on one or two glaucoma medications postoperatively), MIGS has the limitation of needing to be combined with cataract surgery in order for the surgeon to be reimbursed. (Note: The XEN gel stent doesn’t necessarily need to be combined with cataract surgery, but it functions similarly to a modified shunt device, so I view it slightly differently than a conventional cataract surgery-associated MIGS procedure.) This proves to be problematic in patients with glaucoma who have already had cataract surgery—you may not be able to perform a MIGS procedure and have the surgery covered by insurance.

On the alternative side is the patient with glaucoma who has minimal/no cataract, but requires significant IOP reduction. In my opinion, rendering the patient pseudophakic while she’s still capable of accommodation is dreadful. If a patient has a clear lens, it doesn’t make sense to me to just take it out in order to perform a MIGS procedure. Also, uncomplicated cataract surgery isn’t without its own inherent risks, such as an increased long-term risk of retinal detachment in a high myope. Just recently, I saw a fairly young patient with glaucoma who developed a rheg-



matogenous retinal detachment, and his only apparent risk factors were his mild myopia and history of uneventful cataract surgery two years ago.

MIGS also adds costs to the cataract procedure, given the not-insignificant costs of the MIGS devices. These procedures also involve a non-trivial learning curve, new for each MIGS device; in contrast, most glaucoma surgeons have received superb training in trabeculectomy and tube shunt placement.

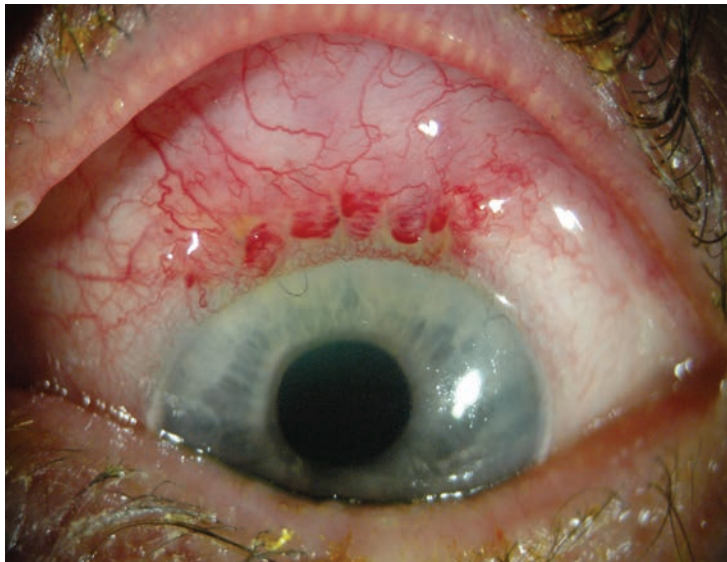
In my opinion, MIGS is also mostly reserved for the garden-variety, primary open-angle glaucoma patient with mild disease, while trabeculectomy and tube shunts can be used in a wider array of glaucomas, such as chronic angle closure, neovascular and inflammatory glaucomas. The jury is still out on MIGS' efficacy in these other glaucoma diagnoses.

Thus, "hitting singles and doubles" with MIGS may be acceptable for certain subsets of patients who can tolerate possibly being on one or more medications after the surgery. But sometimes, you, as the surgeon, need to bring in the heavy hitters.

## Batter Up

If a modest pressure reduction isn't enough for the patient, it's time to consider trabeculectomy or a glaucoma tube shunt.

• **Trabeculectomy's advantages.** For those patients who need significant pressure reduction, this usually means a reduction in IOP of 30 percent or more, a target level often times out of MIGS' average reach. Trabeculectomy, however, is capable



When he performs a trabeculectomy, Dr. Tsai places a releasable suture in the cornea near the trabeculectomy site (above, at 11 o'clock). Postop, he can release the suture to lower IOP more if necessary.

of delivering this amount of IOP lowering efficacy, and at least one study, the Collaborative Initial Glaucoma Treatment Study, demonstrated that trabeculectomy reduced pressures by approximately 48 percent from baseline readings at three years.<sup>1</sup> CIGTS set an aggressive minimum IOP target lowering goal for its patients—at least 30 percent—and, in addition to the 40-percent reduction with trabeculectomy (in the five-year results)—it also reported that medication achieved 35-percent reduction. Thus, for a patient who requires significant pressure reduction, the treatment has to at least be equivalent to the medication arm of CIGTS. Consider a patient who has an uncontrolled pressure of 21 mmHg, and is intolerant of most if not all medications; if I've set a target pressure goal in the low teens, I'll turn to trabeculectomy. When speaking to a patient with a low target IOP range and a need for sustained long-term IOP reduction, I envision that most MIGS procedures would not sufficiently lower IOP into the low teens even with supplemental medications (i.e. a single drop). With

trabeculectomy, on the other hand, you actually have a chance of hitting a home run—great pressure reduction, a healthy appearing, non-ischemic filtering bleb; and a delighted patient who is no longer taking any medications.

Also, since trabeculectomy doesn't involve placing any foreign materials (besides sutures), there's no need to worry that a device will shift its position and/or migrate to a different location. In a similar vein, since trabeculectomy

doesn't involve a device, but instead uses intrinsic ocular tissue to achieve its effect, the procedure is extremely cost-effective. Incidentally, this is one of the reasons some surgeons prefer MIGS such as the Kahook Dual-Blade and the Trabectome, since these procedures don't involve placing materials into the trabecular meshwork or placing a transscleral device like the XEN. In addition, a foreign object can become plugged and/or erode through adjacent tissue.

• **Trabeculectomy's downsides.** The reason, however, we don't place the home-run hitter at the plate in every situation is that along with that potential for the game-changing home run comes the increased risk of striking out.

While MIGS may not be as effective in lowering IOP as trabeculectomy, the former has a lower risk profile, while the latter is associated with such complications as hypotony, bleb infections and suprachoroidal hemorrhage. The Primary Tube vs. Trabeculectomy Study illustrates this point: "Lower IOP with use of fewer glaucoma medications was achieved

# LUMIFY<sup>®</sup>

BRIMONIDINE TARTRATE OPHTHALMIC SOLUTION 0.025%  
REDNESS RELIEVER EYE DROPS

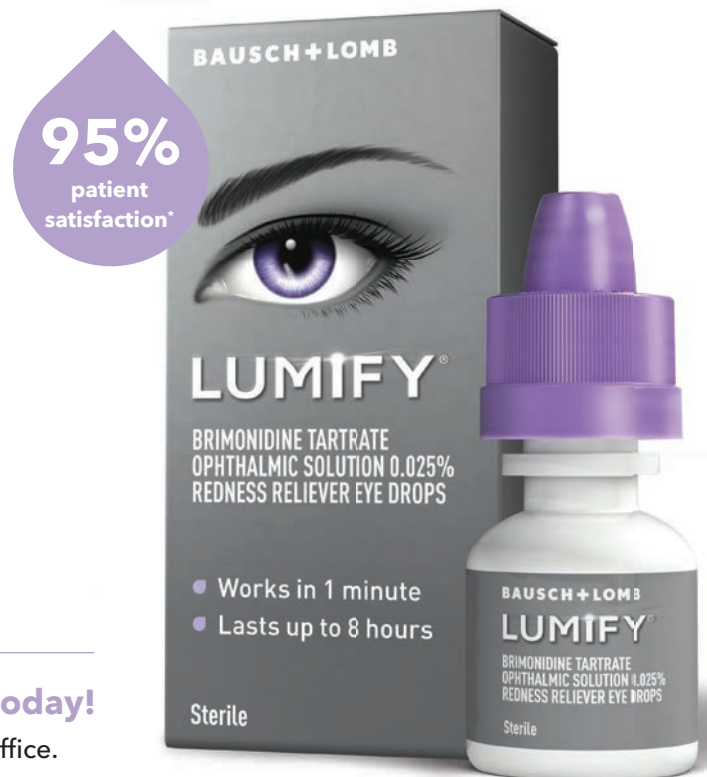

Images representative of clinical trial results.<sup>1</sup> Individual results may vary.

- **The first and only OTC eye drop with low dose brimonidine tartrate (0.025%)**
- **Unique method of action<sup>†</sup> with no tachyphylaxis and virtually no rebound redness in clinical trials<sup>1</sup>**
- **Fast acting and long lasting efficacy<sup>1</sup>**

**Recommend LUMIFY to your patients today!**

Call 1-800-828-9030 to start selling LUMIFY in your office.



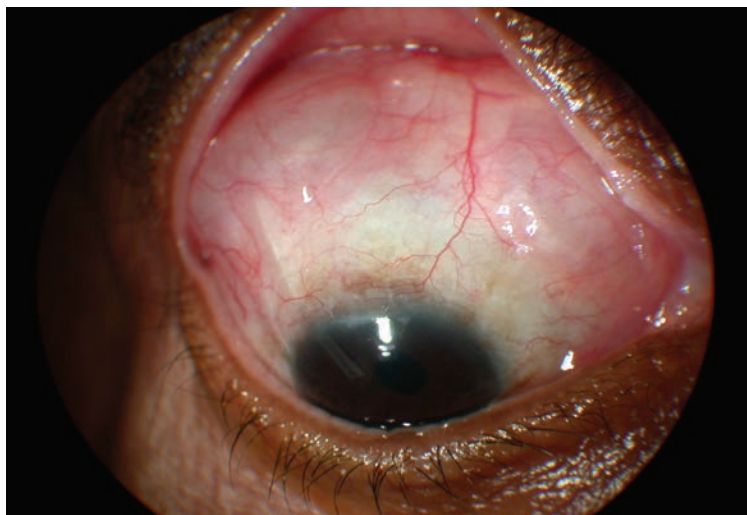
\*In Home Use Test, March 2018. n=301 †LUMIFY is a selective  $\alpha_2$ -AR agonist that selectively constricts the venule while maintaining availability of oxygen to surrounding tissue  
1 McLaurin E, Cavet ME, Gomes PJ, Ciolino JB. Brimonidine ophthalmic solution 0.025% for reduction of ocular redness: A randomized clinical trial. Optom Vis Sci. 2018;95(3):264-271  
LUMIFY is a trademark of Bausch & Lomb Incorporated or its affiliates. © 2019 Bausch & Lomb Incorporated or its affiliates. PN09184 LUM.0193.USA.19

**BAUSCH+LOMB**

Learn more at [LUMIFYDrops.com/Professional](https://LUMIFYDrops.com/Professional)



after trabeculectomy with MMC compared with tube shunt surgery during the first year of follow-up. The frequency of serious complications producing vision loss or requiring reoperation was lower after tube shunt surgery relative to trabeculectomy with MMC.”<sup>2</sup> Also, it’s worth remembering that the type of endophthalmitis associated with trabeculectomy is a more devastating intraocular infection than that which occurs follow-



In terms of efficacy and the risk of complications, the tube shunt, such as this older Molteno model shown here, is situated between minimally-invasive glaucoma surgeries and trabeculectomy, Dr. Tsai says.

ing routine cataract surgery. In trabeculectomy-associated endophthalmitis, the bacteria tend to be more virulent.

Because of these inherent risks, you, as the surgeon, need to choose your trabeculectomy patient very carefully. For example, if the potential patient is in a nursing home and not easily accessible for postoperative follow-up visits (and has a limited support system) trabeculectomy is not an ideal operation, given the higher rates of infection and/or bleb-related complications.

Additionally, most of us who perform trabeculectomies also use adjunctive mitomycin-C. With mitomycin-C, however, there’s an increased risk of bleb avascularity, with an increased risk of bleb leaks that can lead to blebitis and endophthalmitis.

• **Glaucoma tube shunts’ advantages.** When discussing tube shunts with patients and using the baseball analogy, I tell the patients that these procedures are positioned somewhere between the modest base hits of MIGS and the home run potential of trabeculectomy. In my opinion, glaucoma tube shunt implants func-

tion more like consistent doubles hitters, with less risk for the bad strikeouts associated with trabeculectomy. After successful tube shunt surgery, on average, the patient is usually on at least one or two medications and his/her IOP control may not be quite as good as following trabeculectomy. However, the results of tube shunt surgery are usually more consistent than those following trabeculectomy. Even though, admittedly, most tube shunt results are surgeon-dependent, by and large I believe that these surgeries have less variability in their outcome than does performing a trabeculectomy.

Along with this consistency, if not home-run ability, comes fewer “strikeouts,” which translates into a much lower risk of endophthalmitis than trabeculectomy. There’s still a risk of suprachoroidal hemorrhage with a tube shunt, but you can reduce this risk by performing the tube shunt very carefully.

Supporting this idea, the cumulative probability of failure during five years of follow-up in the Tube vs. Trabeculectomy Study was 29.8 percent in the tube group and 46.9 percent

in the trabeculectomy group ( $p=0.01$ ). In terms of efficacy, the IOP result was  $14.4 \pm 6.9$  mmHg in the tube group and  $12.6 \pm 5.9$  mmHg in the trabeculectomy group at one year ( $p=0.01$ ), and the number of glaucoma medications was  $1.4 \pm 1.3$  in the tube group vs.  $1.2 \pm 1.5$  in the trabeculectomy group ( $p<0.001$ ).<sup>3</sup>

When selecting the best patient for tube shunt surgery, look for a patient who might have inconsistent follow-up during the im-

mediate postop period; tube shunts involve less postoperative manipulation than trabeculectomy. The latter procedure can manifest with very high or low pressures postoperatively depending on the condition of the bleb, and your subsequent postop manipulation. A good surgical candidate is also someone who doesn’t need a super-low target pressure. The type of glaucoma also comes into play: Trabeculectomy would be the surgery of choice in patients with normal- or low-tension glaucoma who need significant IOP reduction, whereas a tube shunt is better for patients with neovascular glaucoma, because it seems to work better than a traditional trabeculectomy with an antimetabolite in these types of patients. Also, someone with refractory glaucoma and/or one of the more complicated glaucoma presentations, or a history of glaucoma or other ocular surgery—especially a failed trabeculectomy—would be a good candidate for a tube shunt.

• **Tube shunt disadvantages.** Though the tube shunt is a good middle-of-the-road option between MIGS and trabeculectomy, it’s not without complications. Because the



## My Tips for Trabs

A trabeculectomy can be a powerful pressure-lowering option for your glaucoma patients. Glaucoma surgeons have learned, however, that they can make it even more effective by making their own modifications to the basic technique. Here's what I do to increase my chances for a home run.

When I perform a trabeculectomy, I place a releasable suture in the cornea near the trabeculectomy site. Then, when I see my patient postoperatively, that suture gives me the ability to easily modulate the healing response by pulling the releasable suture at the slit lamp. By releasing the suture at the right moment, I can lower the pressure even more, if it's not already at a level that's satisfactory.

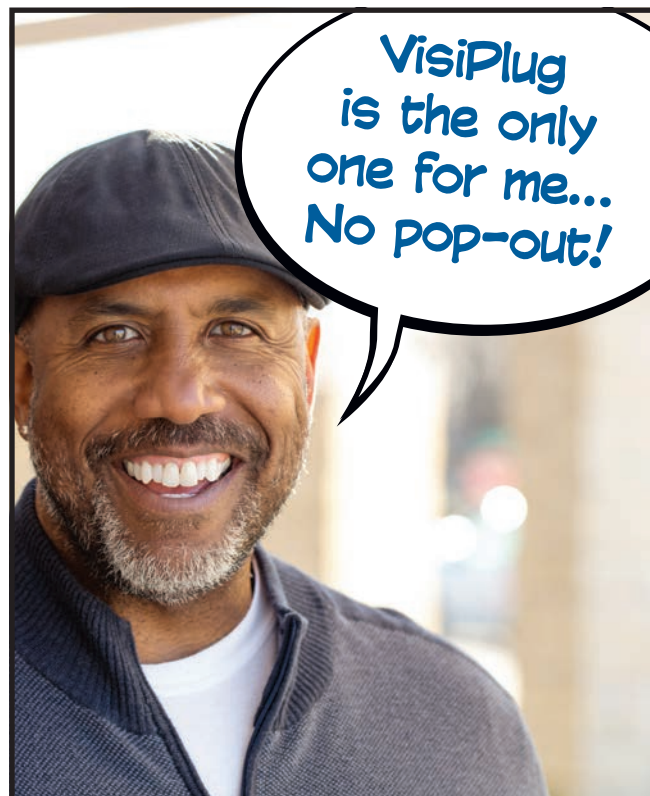
procedure involves the introduction of a foreign body, one of the main complications is extrusion of the implant, in which the tube erodes through either the patch graft or a scleral flap. There's also the aforementioned risk of suprachoroidal hemorrhage and endophthalmitis, but the latter occurs at a lower rate than with trabeculectomy.

A tube implant may not be a good option in a patient with corneal endothelial problems, because there's always the concern of endothelial problems with a tube in the anterior chamber; for example, if the patient rubs his eye, the tube might contact the corneal endothelium. The other type of patient who isn't an ideal candidate is one who can't tolerate having a foreign body sensation under the lid (patients have sometimes reported feeling an uncomfortable sensation of "feeling the implant").

In the end, it's best if you as a glaucoma surgeon don't focus on just one type of procedure, be it MIGS, trabeculectomy or tube shunts. If you only perform one type of procedure, I believe it will be rather difficult to have excellent surgical outcomes when treating all the different types of glaucoma patients. Instead, having a breadth of surgical skills and experience will allow you to recommend the surgery that's most appropriate for a particular patient, rather than trying to make one surgery fit all clinical indications. [REVIEW](#)

*Dr. Tsai is president of New York Eye and Ear Infirmary of Mount Sinai, as well as Delafield-Rodgers professor and system chair of ophthalmology at the Icahn School of Medicine at Mount Sinai.*

1. Feiner L, Piitz-Seymour JR; Collaborative Initial Glaucoma Treatment Study. Collaborative Initial Glaucoma Treatment Study: A summary of results to date. *Curr Opin Ophthalmol* 2003;14:2:106-11.
2. Gedde SJ, Feuer WJ, Shi W. Treatment outcomes in the Primary Tube Versus Trabeculectomy Study after 1 year of follow-up. *Ophthalmology* 2018;125:5:650-663.
3. Gedde SJ, Schiffman JC, Feuer WJ, et al. Treatment outcomes in the Tube Versus Trabeculectomy (TVT) study after five years of follow-up. *Am J Ophthalmol* 2012;153:5:789-803.



Lacrimedics' VisiPlug is not like "other" punctum plugs. We have *no* reported "pop-outs" since VisiPlug's introduction in 2003... and it's distributed in over forty countries!

FDA approved for the treatment of the Dry Eye components of varying Ocular Surface Diseases (OSD), after surgery to prevent complications due to Dry Eye Disease, and to enhance the efficacy of topical medications.

**VisiPlug® –  
a visibly better plug  
to treat dry eye!**



**Lacrimedics®**

**(800) 367-8327**

E-mail: [info@lacrimedics.com](mailto:info@lacrimedics.com)  
[www.lacrimedics.com](http://www.lacrimedics.com)

<sup>1</sup>Dramatization. Not a real patient.  
©2017 Lacrimedics, Inc.

# Dry-Eye Therapies: What's Next?

*Michelle Stephenson, Contributing Editor*

Several devices and a multitude of new medications are expected to come to the marketplace in the next few years.

A recent cross-sectional population-based study has found that more than 16 million American adults have been diagnosed with dry-eye disease. Prevalence is higher among women than men and increases with age.<sup>1</sup> Unfortunately, an ideal treatment modality has yet to be found, but a number of new therapies are in various stages of development. “Dry eye is a huge problem. Everyone wants to be that billion-dollar Restasis (cyclosporine ophthalmic emulsion, 0.05%, Allergan) product,” says Robert Latkany, MD, who is in practice in New York City.

In this article, we'll take a look at what the pipeline holds for dry-eye therapy.

## Devices

Karl G. Stonecipher, MD, and his colleagues are conducting a retrospective review combining low-level light therapy with intense pulsed light using a new device. The device is known as Eye-light outside of the United States and Epi-C PLUS in the United States (Espansione Marketing S.p.A., Bologna, Italy). “We performed the original physician proof-of-concept study and have followed that up with a four-site, five-surgeon data review to evaluate the effects of this type of therapy on

the treatment of dry-eye disease,” explains Dr. Stonecipher, who is in practice in Greensboro, North Carolina.

The study focuses on evaporative and mixed-mechanism dry eye. Most of the patients included in the study were diagnosed with Grade 4 meibomian gland disease and had already failed multiple treatments. (Grade 4 corresponds to no expression from the glands, despite multiple attempts.) The study group they reviewed had Ocular Surface Disease Index scores that were at the severe level (>33), and their tear breakup time were less than six seconds. “The low-level light therapy or photobiomodulation basically heats the glands endogenously, and it's combined with no-gel IPL,” Dr. Stonecipher says. “The results have been exceptional.”

He presented the results of the study at the recent meeting of the European Society of Cataract and Refractive Surgeons in Vienna. “We found that 86 percent of the patients do well with one treatment with one year of follow-up,” he explains. “Fourteen percent of patients required more than one treatment, and, on average, they needed two to three treatments over the course of a year at three- to four-month intervals. But remember, these patients had been treatment failures with multiple [pre-

vious] treatments in all cases.”

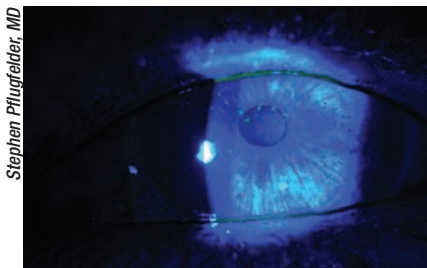
He presented the results of 310 eyes in 155 patients. Patients’ OSDI scores went from 40.2 down to 21.8 between one and three months postoperatively. The average tear breakup time was 3.58 seconds preoperatively and 7.98 seconds between one to three months postop. MGD grading decreased from 4 to 2 (glands expel cloudy or opaque fluid with digital pressure) postoperatively.

“We’ve been really excited by these findings,” Dr. Stonecipher says. “We have taken it one step further. In patients who have meibomian gland disease and rosacea, we now perform Epi-C Plus. This is no-gel IPL plus low-level laser therapy. There’s a red mask for the MGD (633 nm) and a blue mask for acne rosacea (419 nm), which helps reduce the telangiectasias.”

Outside of the United States, ophthalmologists are using white and yellow masks. The white mask is similar to light therapy for seasonal affective disorder. “The yellow mask stimulates the lymphatics and allows an increase in lymphatic drainage,” Dr. Stonecipher says. “The yellow is 519 nm, the red is 633 nm, and the blue is 419 nm.”

However, Dr. Stonecipher has noticed that some patients are poor responders to IPL, so he also uses TempSure (Cynosure), a radiofrequency device for aesthetic applications, for the off-label treatment of MGD. “It’s approved for wrinkles around the eye and on the forehead. We’re now using that in addition to low-level light therapy to see if it will heat and stretch the glands even more than IPL,” he says.

According to Dr. Stonecipher, Epi-C low-level light therapy and IPL are both FDA-approved, but combining them for the treatment of dry eye is off-label. “There are different wavelengths that trigger the endogenous heating of the eyelids,” he says. “We are basically heating these fats or this meibum from the inside out.”



Punctate corneal fluorescein staining in a patient with Level 3 aqueous tear deficiency.

## Medications

Many new medications are in various stages of development. Last year, Cequa (cyclosporine 0.09%, Sun Pharma) was approved by the FDA to treat dry eye, but it hasn’t yet come to the market. The company is currently planning to start distributing it this summer, according to Dr. Lasky.

“This drug has a different mechanism of action than Restasis with regard to how it penetrates the eye,” Dr. Lasky says. “The company says that it has a faster onset of action than Restasis. Whereas Restasis might take four months or more to reach its maximal peak level of efficacy, this one could start working a few weeks into the treatment.”

According to John Sheppard, MD, who is in practice in Norfolk, Virginia, Cequa has a better side-effect profile than Restasis, while looming generic cyclosporine preparations will undoubtedly reveal a more frustrating side-effect profile than Restasis.

He believes that one of the more exciting products in the pipeline right now is Novaliq’s CyclASol A, which is a preservative-free ophthalmic solution of 0.1% cyclosporine A in EyeSol, Novaliq’s water-free technology. “Because of its molecular characteristics, the drops are only 10 µm in diameter, it has excellent adherence to the surface of the eye, it’s comfortable, it doesn’t sting, and it doesn’t require a preservative,” says Dr. Sheppard. “It has great

shelf life, and the risk of infection is low.”

Stephen Pflugfelder, MD, professor and James and Margaret Elkins Chair in Ophthalmology at the Baylor College of Medicine in Houston says that future comparative studies should help ophthalmologists get a clearer picture of where the various new drugs fit in the treatment algorithm. “Unfortunately, right now, there aren’t any head-to-head comparisons between the cyclosporine products, which is really what’s going to be needed in the future to determine where drugs would be used,” he says. “This would include the type of dry eye, the type of profile of signs and symptoms, and the relative efficacy of those things. Additionally, I think a generic cyclosporine will probably come out soon.”

In addition to the new formulations of cyclosporine, Dr. Lasky adds that several versions of loteprednol are in Phase III trials. “Ophthalmologists have been using steroids to treat dry eye for more than 10 years, but everything we are using is off-label,” he says. “Lotemax (loteprednol etabonate ophthalmic gel, 0.5%, Bausch + Lomb) is a higher concentration of loteprednol than Alrex (loteprednol etabonate ophthalmic suspension, 0.2%, Bausch + Lomb), and the side-effect profile of Lotemax is not as high as a stronger steroid, such as prednisolone acetate. Even though it has a low side-effect profile, I don’t feel comfortable letting patients use long-term steroids because of the side effects of glaucoma and cataracts. Alrex is a weaker concentration, and I haven’t seen a lot of side effects with Alrex, even though it is still a steroid. This invites the possibility of weaker concentrations of steroids in the future having some potentially beneficial effect on the treatment of dry eyes without the side effects of cataracts and glaucoma.”

Inveltys (loteprednol etabonate ophthalmic suspension 1%) from Kala Pharmaceuticals was recently ap-



proved by the FDA for the treatment of postoperative inflammation and pain following ocular surgery. It's the first twice-daily ocular corticosteroid approved for this indication. Kala also continues to advance KPI-121 0.25% for dry-eye disease. It's currently in its third Phase III clinical trial.

"KP-121 [was studied against dry eye's] signs in both of the first two Phase III trials, but one of the trials missed symptoms, so that earned them a third trial," explains Dr. Sheppard. "We hope it will be available early next year because it truly addresses an unmet need for prescribers and patients. How that might change things is difficult to say because we already use Lotemax for dry eye. Some doctors with very restrictive insurance companies will welcome a true indication. However, like all new medicines, it's going to be expensive for some insurance plans. But, then again, Lotemax is expensive, too, and we all know that steroids work great for dry eye."

Additionally, Aldeyra Therapeutics has developed a new drug called reproxalap that has a completely different mechanism of action. In Phase IIb clinical trials, the drug demonstrated statistically significant improvement across multiple measures of symptoms and signs. Reproxalap is currently in a Phase III trial. "However, it still could be potentially two to four years before we have it in our hands," Dr. Latkany adds.

According to Dr. Sheppard reproxalap is a new molecule. "[It's] an entirely new product that blocks the formation of a wide variety of inflammatory mediators that are present in numerous disease states, including allergy, dry eye and uveitis in the anterior segment of the eye," he says. Dr. Sheppard recently presented Phase IIb results from the use of the drug at the annual meeting of the Association for Research in Vision and Ophthalmology, and says the data were "quite encouraging."

Dr. Sheppard is impressed at how far the industry has come over the past

couple of decades. "It's been a pretty amazing genesis when you think about the fact that, just 22 years ago, we had nothing that really treated dry eye other than tears," he muses. "Even 10 years ago, we really didn't appreciate what was going on with meibomian gland disease. So, we're looking forward to a lot of new therapies. There are some exciting drugs in the pipeline for meibomian gland disease, which is responsible for approximately 84 percent of dry eyes."

One of these is topical minocycline gel, which is being developed by Hovione. "It's a large company that's just beginning its first foray into eye care," says Dr. Sheppard. "So, we're just beginning a Phase IIb trial with well-established minocycline. It's a highly insoluble drug, which basically has to be given in gel or ointment form. Oral medications, obviously, have their disadvantages, so we're very excited about this trial. Gel seems to be an excellent compromise between an ointment, which most patients don't like, and an oral therapy."

Additionally, Azura Ophthalmics (Tel Aviv, Israel) has proprietary technology (AZR-MD-001) for the desquamation and rejuvenation of the anterior lid margin and squamous dermal epithelium. "We all know that the renewal of that epithelium occurs at a very closely regulated rate in normal patients, but the turnover can be accelerated in patients with inflammatory disease or lid margin disease," says Dr. Sheppard. "This product has been established in dermatology and is being adapted for ocular preparation to control the symptoms and signs of both anterior and posterior blepharitis."

Also, a pharmaceutical company based in London, TopiVert, has developed TOP1630, which is designed to treat the underlying inflammation that occurs with dry-eye disease. It produced promising results in a Phase I/IIa proof-of-concept study for the treatment of dry eye. "It applies kinase-

inhibition technology to the ocular surface," Dr. Sheppard explains. "Kinases are a universal signaler in inflammatory diseases of all types and all organ systems, including ocular surface inflammation for dry eye. So, these may be both proximal and distal to T cell activation on the ocular surface of the dry-eye patient."

Another drug with a new mechanism of action is SJP-0035, which is a peroxisome proliferator-activated receptor delta agonist. SJP-0035 is being developed by Senju Pharmaceutical as an ophthalmic solution to promote corneal epithelial wound healing in patients with corneal epithelial disorders, and for the treatment of dry eye. It's currently being studied in a Phase III trial.

## The Future

"We have some exciting times ahead," Dr. Sheppard says. "We have a couple of drugs that will be out in the next year or two, and then a slew of drugs will be coming out in the next three to five years." Dr. Pflugfelder is more circumspect. "I think eventually there will be new classes of drugs that may be more effective than what we have right now," he says. "But, again, it remains to be seen whether they get approved by the FDA. However, I do see drugs in clinical trials that have the potential to be more efficacious than what's currently available." **REVIEW**

*Dr. Stonecipher is a consultant to Allergan, Alcon, Bausch + Lomb, Espanstone, Hologics, Kala and Shire. Dr. Sheppard is a consultant to Kala, Sun, Novaliq, Hovione, Azura and TopiV-ert. Dr. Pflugfelder is a consultant to Allergan, Shire, Kala and Senju. Dr. Latkany has no financial interest in the companies or products mentioned in this article.*

1. Farrand KF, Fridman M, Stillman IO, Schaumberg DA. Prevalence of diagnosed dry eye disease in the United States among adults aged 18 years and older. *Am J Ophthalmol* 2017;182:90-98.



# nurture THEIR EYES



Take a fresh approach to treating dry eye symptoms with FRESHKOTE® Preservative Free (PF)

**Patented polymer blend** of polyvinyl alcohol and povidone supports all layers of the tear film<sup>1,2</sup>

**Triple-acting formula** reduces evaporation and increases stability of the tear film while high oncotic pressure reduces epithelial cell swelling<sup>1,3</sup>

**Compatible for use with contact lenses<sup>4</sup>**

**State-of-the-art multidose bottle** provides more than a month's worth of preservative-free drops when dosed 4 times a day<sup>5</sup>

RECOMMEND SOOTHING RELIEF

Visit [FRESHKOTE<sup>PF</sup>.com](https://www.freshkotePF.com) to learn more

FRESHKOTE®  
Preservative Free  
LUBRICANT EYE DROPS

References: 1. Holly FJ. Lacrophilic ophthalmic demulcents. *US Ophthalmic Rev.* 2007;3:38-41. 2. FRESHKOTE Drug Facts. Eyeavance Pharmaceuticals LLC; 2018. 3. Holly FJ. *Colloidal Osmosis — Oncotic Pressure*. Grapevine, TX: Dry Eye Institute; 2006. 4. Fuller DG, Connor CG. Safety and efficacy of FreshKote® used as a rewetting agent in Lotrafilcon-A® contact lens wearers. Poster presented at: American Academy of Optometry Annual Meeting; November 17-20, 2010; San Francisco, CA. 5. Nemer. Novelia®. <https://nemer.net/products/ophthalmic-noveliea-eyedropper/>. Accessed March 14, 2019.



© 2019 Eyeavance Pharmaceuticals LLC. All rights reserved.  
FRESHKOTE® is a registered trademark of Eyeavance Pharmaceuticals LLC.  
Novelia is a registered trademark of Nemer Development.  
FPF-19-AD-05.00

# Non Cross-linking Options for Keratoconus

Alexandra Skinner, Associate Editor

Doctors discuss alternatives for managing the disease.

Corneal collagen cross-linking has made significant headway in the United States as a method for halting keratoconus progression. While the procedure is an effective option for the disease, especially for young patients who are quickly progressing, there are some cases in which cross-linking may not be indicated. In this article, specialists describe non cross-linking candidates and methods for managing their keratoconus.

## Non Cross-linking Candidates

Kenneth Beckman, MD, FACS, director of corneal services at Comprehensive Eyecare of Central Ohio, and clinical assistant professor of ophthalmology at Ohio State University, says that in his experience, only a few people are unable to undergo cross-linking. He adds, however, that some patients may not need it.

While criteria for a non cross-linking candidate aren't always clear, here are some special cases in which the procedure is considered unnecessary, or could potentially threaten eye health.

- **The stable patient.** Doctors say that older, stable patients aren't good candidates for cross-linking as the procedure, in many instances, becomes unnecessary over time. Anat Galor, MD, MSPH, associate professor of

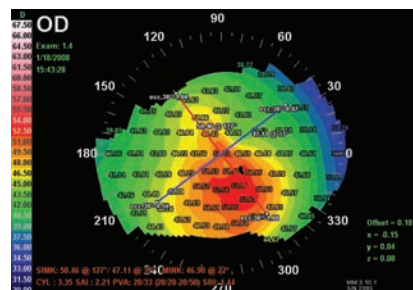


Figure 1. An abnormal topography of a cornea showing keratoconus.

ophthalmology at Bascom Palmer Eye Institute, says that cross-linking is meant to be used in individuals whose keratoconus is progressing. However, “The likelihood of progression goes down with age and most people stop progressing once they get to 35 or 40 years old,” she says. “So cross-linking isn't needed if someone is 60 years old and has stable disease.”

Julie Schallhorn, MD, MS, assistant professor of clinical ophthalmology at the University of California, San Francisco agrees, commenting that young people are much more likely to progress, and at a much more rapid rate. She shares why doctors think this occurs. “Cross-linking essentially bonds collagen fibrils and, as you age, through natural exposure to UV sunlight, the collagen in your cornea stiffens and is naturally cross-linked.”

- **Very thin cornea.** Dr. Schallhorn



says that if the patient's cornea is too thin, he can't undergo cross-linking since there's a risk of damaging the corneal endothelium. "There's a minimum corneal thickness that you need in order to be able to cross-link," Dr. Schallhorn says. "Four hundred microns is what they used in the FDA-approval studies for Avedro, which was recommended based on studies looking at endothelial damage from cross-linking." Wuqaas Munir, MD, associate professor of ophthalmology and visual science, and associate program director for the residency program at the University of Maryland School of Medicine, explains that the current thinking is that the application of UV-light could potentially damage the endothelium during the cross-linking procedure if the cornea isn't thick enough. "So in this case, a patient who wouldn't qualify [for cross-linking] would have too advanced a form of the disease where the cornea has become too thin," he says.

Though doctors note the potentially harmful effects of performing cross-linking on a patient whose cornea is less than 400  $\mu\text{m}$  thick, Dr. Beckman emphasizes that this is just the recommended guideline for minimum thickness. It's not clear-cut as to whether damage is necessarily done to the endothelium if the cornea is below that threshold. "Some have experienced damage when the cornea was thicker than 400 microns, and there are plenty of cases of thinner corneas that haven't had damage," he says.

While a thin cornea may be a sign that a patient isn't a good cross-linking candidate, doctors are investigating different techniques to decrease the risk of harm to the endothelium. This includes changing the intensity of the UV light, altering the duration of treatment, putting a contact lens over a thin cornea to reduce UV-light penetration, and using hypotonic riboflavin (Photrex Viscous, Avedro) to swell the

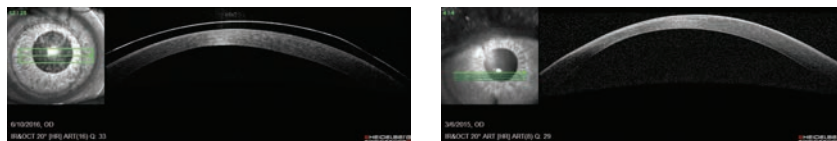


Figure 2. Left: OCT of a keratoconic cornea fitted with a contact lens. Right: OCT of a keratoconic cornea.

cornea.

- **Scarred cornea.** "Corneal scarring could be another issue; but that usually ties in with thinning," says Dr. Munir. "A patient with significant scarring is usually someone whose cornea is so thin that they can't be treated with cross-linking." If the cornea is scarred, especially centrally and significantly, Dr. Beckman says that's going to limit vision. He says a transplant may ultimately be needed in that case, as there may be no visual benefit from cross-linking.

- **Ocular surface disease.** "A person with bad ocular surface disease—like those with a history of herpes or severe dry eye—may not be able to have a cross-linking procedure as these conditions make healing difficult," notes Dr. Beckman. "Herpes patients have trouble re-epithelializing, and in cross-linking you remove the epithelium. Also, ultraviolet light may trigger a herpes flare-up." Dr. Beckman notes, however, that this isn't an absolute contraindication, and says that the physician has to weigh the risks and benefits.

- **Inability to sit still or fixate.** Dr. Beckman adds that a cross-linking procedure could be difficult if a patient is unable to sit still. "For some of those patients, physicians may consider doing the procedure under sedation or even general anesthesia, which has its own risks," he says. "Patients that are very young or have cognitive issues may require this. Fortunately, it's very rare." However, Dr. Beckman notes that this isn't necessary in every one of these cases. He points out that he has treated young patients and patients with Down syndrome without using sedation, and he reports that

they've done very well.

## Management Options

"As of now, the only thing that can change the course of [keratoconus], or halt its progression, is cross-linking," says Dr. Munir. However, there are devices and techniques for managing various stages of the disease when cross-linking isn't the best option. Of course, it's important to note that many of these options aren't exclusively used in non-cross-linking candidates; they're frequently employed before, after and in conjunction with cross-linking.

- **Soft lenses.** The purpose of contact lenses is to help the patient see, says Dr. Munir. "Since keratoconus causes the cornea to steepen, contact lenses aim to negate that steepness and improve the optics of the eye," he explains. "To do this, the lens sits on top of the cornea and when light penetrates the eye it hits a more uniform surface." With that in mind, Dr. Schallhorn says that soft lenses are great for people with regular astigmatism who have little change in the contour of the cornea. "If you have mild keratoconus and can refract well in glasses, then a soft lens generally works," she says. "But for a patient with significant amounts of irregular astigmatism, [someone with moderate to severe keratoconus], he or she won't be able to wear a soft lens."

"The problem with a soft lens is that it's soft," muses Dr. Munir. "It drapes over the cornea and has very limited ability to overcome shape changes. If you have a steep cornea, the soft lens will follow the shape of that steepness and you won't get a smooth contour anymore." Justin Sherman, OD, an

optometrist at Philadelphia Eye Associates, outlines another shortcoming of soft lenses. “In my experience, soft-lens patients tend to overwear their lenses,” he says. “And that comes with the associated complications.”

• **Rigid lenses.** “Rigid gas-permeable small-diameter contact lenses work very well for [more advanced cases of] keratoconus because they cancel out the irregular astigmatism of the cornea,” says Dr. Schallhorn. Dr. Munir says RGPs aren’t limited as much by the shape of the cornea and can be used in steeper forms of keratoconus to achieve better optical quality. And Dr. Sherman notes that being able to change the optical zone sizes and peripheral curve systems [with the use of an RGP], makes it possible to fit a wide variety of cones. “One of the best qualities of RGP lenses is the significantly lower rates of overwear and infection relative to soft lens designs,” he says.

Dr. Sherman adds, however, that these lenses become less effective in patients with severe, more peripheral cones that produce significant differences in peripheral corneal elevation. Dr. Schallhorn agrees. “The problem with RGP lenses is that there’s kind of a limit as to how steep your cornea can be to wear [them],” she says. “They’re also kind of tricky to fit. You need to be working with an optometrist who’s good at fitting RGPs, which is tough because you’re basically fitting on top of a mountain.”

• **Piggybacking.** “Piggybacking a rigid lens on a soft one used to be considered a great way to provide comfort to a patient who can’t comfortably wear their RGPs any longer,” says Dr. Sherman. “However, the need for piggybacking has been dramatically reduced with the advent of irregular cornea RGPs, scleral lenses and hybrid-lens designs. This is great because the complexity of caring for two different lens types with different solutions and replacement schedules would often lead

to patients misusing their contact lenses in some capacity.” Dr. Schallhorn outlines another disadvantage to the technique. “The two-lens combination can cause a lot of corneal hypoxia and could cause corneal neovascularization,” she says. “Those vessels put the patient at higher risk for transplant.” However, Dr. Sherman notes that there are cases in which patients manage their piggybacking technique well and are very happy.

• **Hybrid lenses.** Dr. Munir says that hybrid lenses provide the optical advantage of the rigid lens but the comfort of a soft lens. However, while Dr. Sherman acknowledges the optical and comfort advantages, he outlines a few disadvantages. “[Hybrid lenses] are similar to RGPs in that they begin to misbehave when patients have more peripheral disease,” he says. “They’re probably the most difficult for patients to handle. The edge of the lens has to be pinched to remove it, but many patients have a difficult time knowing where the GP optic ends and the soft skirt begins. Difficulty with insertion and removal is the most common reason I have patients drop out of hybrid-lens wear.” He adds that hybrid lenses are also the most expensive design.

• **Scleral lenses.** “Scleral lenses have revolutionized treatment options,” says Dr. Beckman. “No matter how distorted the cornea may be, if it’s optically clear—meaning there’s no central scar—then you can fit almost any cornea with a scleral lens and get good vision.”

Dr. Beckman says the advantages of scleral lenses include the ability of the lens to vault in front of the cornea without touching it. He says the lens creates a smooth round optical surface, which corrects vision. “Since the lens doesn’t rub on the cornea, scleral lenses are good for patients with dry eye,” he notes. “The patient’s tear film fills in the gap between the lens and cornea, so the surface of the cornea is kept moist as it constantly bathes in liquid.”

Dr. Sherman agrees that scleral lenses can be very therapeutic for ocular-surface disease issues, which many keratoconus patients have. He says that scleral lenses are a great choice for patients with severe, more peripheral cones. “These lenses vault the cornea entirely and are supported by a haptic that lands on the conjunctiva,” he explains. “Because the conjunctiva is much less sensitive than the cornea, these lenses are exceptionally comfortable, so long as they match the patient’s scleral profile. They also have extremely low rates of complication and infection.”

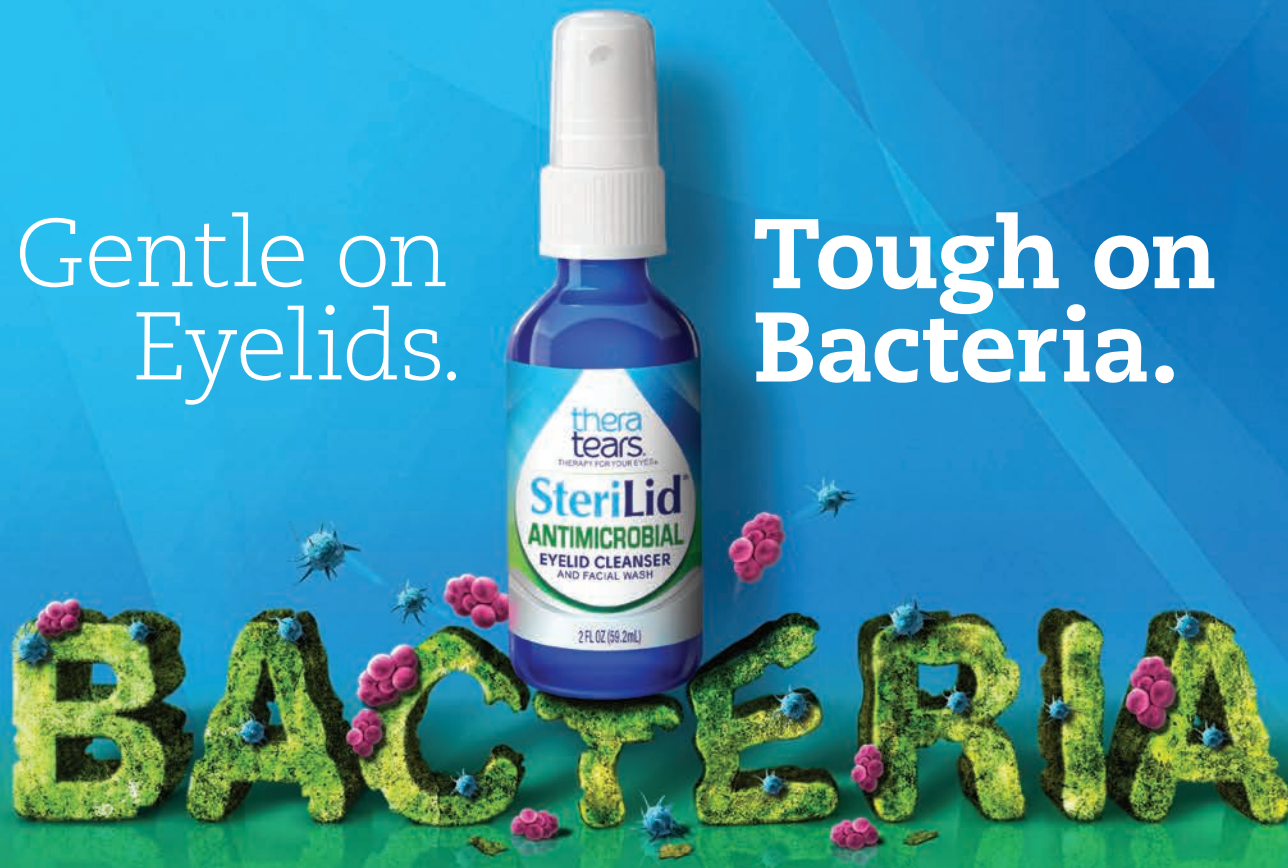Due to advancements over the past few years, Dr. Munir says that in many cases, a steep cornea, which previously may not have been manageable with a rigid lens, can now be fit with a scleral lens. However, Dr. Munir acknowledges a few disadvantages. “[Scleral lenses are] very large and potentially more uncomfortable than a standard RGP,” he says. “It can be difficult to insert and remove scleral lenses because of the large size. The patient instruction is more difficult and it’s harder for patients to build up a tolerance, in terms of lack of comfort.”

Doctors say generic scleral lenses work for almost everybody, but there are still extremely advanced cases of keratoconus where the cornea is too steep for a generic lens. Due to a more recent development in scleral-lens technology, however, doctors say that steep cones can now be fit using custom scleral lenses such as BostonSight’s PROSE and EYEprint’s EyePrintPRO. “[These are both] types of scleral lenses that allow you to customize the lens to fit the contour of the patient’s cornea and therefore fit people with very irregular corneas,” Dr. Galor says. Dr. Schallhorn describes the options: “PROSE is a custom-made scleral lens that can vault over almost any cone,” she says. “EyePrintPRO is another custom scleral lens in which you take a mold of the corneal

new!

Gentle on  
Eyelids.

Tough on  
Bacteria.



RECOMMEND  
THE FIRST FDA-ACCEPTED  
**ANTIMICROBIAL**  
EYELID CLEANSER

- ✓ Advanced Hypochlorous Acid (0.01%) formula for superior cleansing
- ✓ Cleanses away bacteria and irritants
- ✓ pH balanced formula is gentle on eyelids
- ✓ Effective daily eyelid and eyelash hygiene
- ✓ No rinse – soap free



Now available without a prescription at Walgreens, CVS Pharmacy®, Amazon, Rite Aid, and other retailers nationwide

Visit [theratears.com](http://theratears.com) to learn more



Reference: 1. Results from an in vitro laboratory study. TheraTears® SteriLid® Antimicrobial Eyelid Cleanser and Facial Wash showed efficacy in reduction of colony forming units for eight common eyelid organisms. Data was captured at 30 and 60 seconds.

M18-069-00



shape and then make a lens based on that.”

- **Intacs.** “The goal is to insert Intacs to make the cornea more regular and improve contact lens comfort,” says Dr. Galor. “A good candidate for intrastromal rings is an individual who has sufficient corneal thickness and contact-lens intolerance.”

Dr. Beckman says the placement of Intacs may provide better spectacle vision and better-uncorrected vision. He outlines a scenario in which Intacs may be used in order to decrease dependence on contacts. “If progression has stopped and there’s still significant residual astigmatism, patients may try glasses or contacts,” he says. “Often, they get good vision with both but, at other times, they may only get good vision with contacts. For these patients Intacs may be considered.”

Due to advancements in contact-lens technology over the past decade, Dr. Sherman says that fewer and fewer Intacs segments are being implanted. Dr. Galor notes, however, that the world of corneal rings is more varied outside of the United States. “In Europe, they have many different types of intrastromal rings and they’ve developed really sophisticated algorithms that customize the length, thickness, number and location of the rings to counteract a particular shape of the cornea,” she says.

## Transplants

“People that have really advanced keratoconus who are no longer able to fit into generic scleral lenses, who can’t afford or are unable to get custom lenses (which physicians say are, unfortunately, very expensive), or have a history of hydrops with scarring, are people we’re doing transplants on,” says Dr. Schallhorn. She adds that a patient having an episode of hydrops already has extremely advanced keratoconus, and therefore a very thin cornea, which makes for a poor cross-

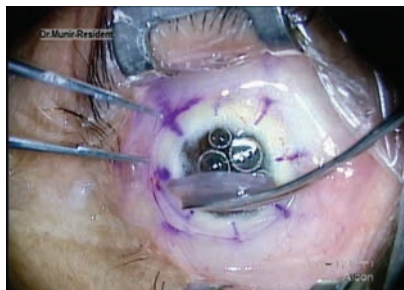


Figure 3. Deep anterior lamellar keratoplasty is also an option in these patients.

linking candidate.

- **DALK.** Since keratoconus doesn’t affect the endothelium, Dr. Munir says deep anterior lamellar keratoplasty is an option. “The endothelial cells are what we consider one of the primary sources of transplant rejection,” says Dr. Munir. “However, we can do a deep anterior lamellar keratoplasty, which will replace everything but the endothelium.” In DALK, the corneal stroma is removed but Descemet’s membrane and the endothelial cells remain. “The risk of rejection is much lower with this type of procedure than it is with a full-thickness penetrating keratoplasty in which the stroma and endothelium are replaced by donor tissue,” Dr. Munir shares.

Dr. Beckman says there are pros and cons to DALK. “The advantages are that you’ve done a procedure without having the eye completely open—just a thin membrane remains—so there’s less risk intraoperatively,” he says. “And since there’s less risk of graft rejection, you could potentially get the patient off steroids quicker. However, disadvantages include the learning curve. Not every doctor performs DALK. It’s a long procedure that’s technically more difficult than PK, and there’s always the possibility of popping through Descemet’s and the endothelium and having to convert to a PK. If the patient has endothelial disease or a distorted cornea that’s too thin and the endothelium decompensates, then DALK wouldn’t be an op-

tion, you’d have to do PK.”

- **Corneal transplant.** “Sometimes, if there’s a lot of scar tissue, as in a patient who has very advanced keratoconus and a thin cornea, you can’t perform DALK,” Dr. Munir says. “In that case we do a PK. The risk with PK is that you have a little more of a chance for rejection since you’re removing the endothelium.”

Dr. Schallhorn notes a few instances where a PK would be indicated. “I find that for patients who have a lot of endothelial scarring from an episode of hydrops, many times you just blow out the area of the old scar with DALK and end up having to do PK,” she says.

Dr. Galor says there are possible long-term concerns for transplant patients. “One issue with DALK and PK is that the integrity of the cornea is never as strong as the native cornea,” she says. “As such, if patients experience trauma to the eye, even years after transplantation, they’re at risk for graft dehiscence, in which the area of the scar opens.” However, she notes that outcomes are good after full-thickness corneal transplants for keratoconus, compared to other indications.

## Outlook: Positive

Ultimately, Dr. Schallhorn says cross-linking is a very exciting technology, especially for younger patients. As for older patients, she says the jury is still out regarding who’s considered a good candidate for cross-linking and who’s at risk for progression. “That’s something people need to address,” she says. “However, I think that referring people to optometrists who are skilled scleral-lens fitters and can get good refractive correction can really change the life of a person who has keratoconus.” **REVIEW**

*Drs. Schallhorn and Beckman are consultants for Avedro. Drs. Galor, Munir and Sherman report no financial interests.*



# NuLids<sup>®</sup> – transformational dry eye therapy



## Transforms your patients' lives

Finally... A doctor directed at-home treatment for dry eye disease that is safe, effective and easy to use.

A multi-center study<sup>1</sup> showed:

- 50% decrease in dry eye symptoms
- 65% improvement in TBUT
- 80% increase in meibomian glands yielding liquid secretions.

<sup>1</sup> Schanzlin, Olkowski, Coble, Gross. NuLids II Study, April 2018



## Transforms your practice

The NuLids System helps reduce patient out-of-pocket expenses while creating an additional revenue stream for the practice – all without impacting overhead costs or disrupting other in-office treatments.

A multi-center study<sup>1</sup> showed 95% were satisfied or very satisfied with the treatment.

For more information visit [www.NuSightMedical.com](http://www.NuSightMedical.com) or call us at 833-468-5437



**NuLids<sup>®</sup>**

*Doctor directed, at-home dry eye relief*






## ENRICH YOUR PRACTICE

*Review of Ophthalmology* delivers current and comprehensive information focusing on topics such as disease diagnosis, surgical techniques and new technologies.

The *Review Group's Ophthalmic Product Guide* brings you the latest products and technology on the market. Published every February and July.



The *Review Group* also distributes a variety of supplements, guides and handbooks with your subscription to *Review of Ophthalmology*. These publications are designed to keep you informed on what's new and innovative in the industry on topics ranging from cataract refractive surgery to ocular surface disease.

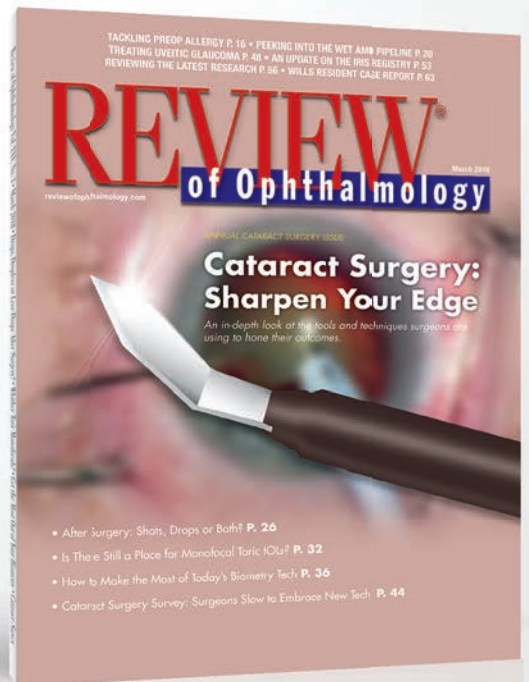


The *Review Group* also offers valuable continuing medical education sessions in both print and online formats, allowing a convenient way for you to earn CME credits. In addition, we also offer an impressive fleet

of free e-newsletters—such as *Review of Ophthalmology Online* and *Review of Ophthalmology's Retina Online*—so you can keep up to date on breaking news and the latest research.



The *Review Group* offers eyecare practitioners quality informational resources dedicated to the growth and education of the profession. The *Review Group* offers a variety of print and online products to enrich your patient care and practice needs.



The *Review Group* also spearheads meetings and conferences, bringing together experts in the field and providing a forum for practitioners that allows you to educate, and learn from others in the profession. These meetings cover a broad range of topics in the form of educational or promotional roundtables and forums.

[www.reviewofophthalmology.com](http://www.reviewofophthalmology.com)



Jobson Medical Information LLC  
The *Review Group*





# A New Way to Perform a Vitrectomy

A look at how hypersonic vitrectomy works, and what features it might bring to the table.

*Sunir Garg, MD, Philadelphia, Kevin J. Blinder, MD, St. Louis, and Carl C. Awh, MD, Nashville*

**G**uillotine cutters have been the standard tools for performing vitrectomy for decades. They are versatile, and have only gotten better over time. Because of this, when a new technology—hypersonic vitrectomy (Vitesse, Bausch + Lomb)—comes along that can remove vitreous in a different way, surgeons are naturally interested in learning more about its operation, strengths and possible limitations. Since only a few hundred cases have been performed with this technology, however, surgeons still don't have a lot of day-to-day experience with it.

In this article, a few of us who have been involved with the development and utilization of hypersonic vitrectomy will try to answer some questions a surgeon might have about it.

## How Does It Work?

To understand how a hypersonic vitrectomy probe differs from a guillotine cutter, it helps to understand how the latter works. Guillotine cutters have a needle-within-a-needle design (Figure 1). The internal needle cuts the vitreous by moving back and forth; then the

vitreous particles are aspirated through the interior lumen of the needle. The evolution of vitreous cutters has led to smaller gauge probes with smaller lumens that can increase resistance and decrease flow. Additionally, with standard guillotine cutters, lower cut rates result in larger particles that can increase vitreous traction and decrease flow. Because of this, we've moved to higher cut rates and more efficient cutters that result in smaller particles, which can decrease traction and in-

crease flow.

The hypersonic vitreous cutter takes a different tack; rather than mechanically cutting the vitreous and then aspirating cut particles, the hypersonic unit uses ultrasonic vibrations, operating at 1.7 million cycles per minute, to liquefy the vitreous gel near the device's port. The probe of the device is a single lumen shaft with a small port that's always open, providing a unique 100-percent duty cycle (the amount of time the port is open; Figure 2). The device liquefies the vitreous at the outer margins of the port and then aspirates the resulting microparticles.<sup>1</sup>

While on a superficial level this technology may seem similar to phacoemulsification, it's actually quite different. Early in their training, all ophthalmologists learn that a phaco handpiece shouldn't be used to remove the vitreous because the phaco handpiece doesn't cut the gel, it aspirates it. This aspiration can cause traction on the retina, which can lead to retinal tears and detachments. In contrast, the hypersonic vitrectomy probe liquefies the vitreous at the port using higher frequency, lower amplitude vibrations.

Additionally, the surgeon has con-

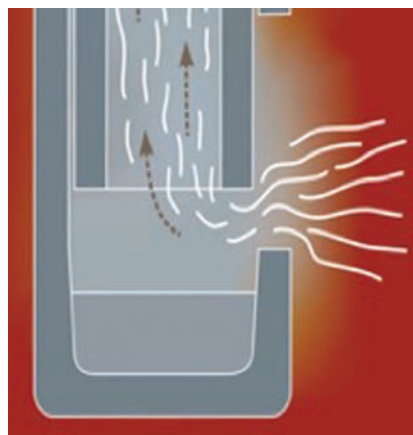


Figure 1. A pneumatic cutter's needle-in-a-needle design. The duty cycle is less than 100 percent and, as the lumen narrows, there's increased resistance to flow.

trol over the oscillation distance of the probe. Longitudinal oscillation in the hypersonic vitrectomy unit (referred to as stroke) ranges between 0 and 60 micrometers. The user can adjust stroke intraoperatively in real time in order to influence the speed and effectiveness of vitreous removal.

We're learning more about optimizing stroke settings with each use of the device. For instance, we now know that for performing a core vitrectomy, or removing dense vitreous hemorrhage or retained lens material, having more stroke (liquefying energy) and vacuum is helpful. When we shave the vitreous, however, particularly over mobile retina, we need less stroke and vacuum. Additionally, in our experience, it appears that hypersonic vitrectomy doesn't require a lot of vacuum to operate efficiently.

A potentially useful feature of a hypersonic vitrectomy handpiece is that the probe can be modified in different ways (Figure 3). Along these lines, curved probes and different port locations are being tested that may be more useful than straight probes in certain situations. For example, it's difficult, if not impossible, to remove the peripheral vitreous 180 degrees from the sclerotomy site without contacting

the crystalline lens. Having a curved tip might enable the removal of this vitreous without hitting the lens.

The hypersonic vitrector runs on electricity, so no pressurized gas—provided by either tanks or in-wall lines—are necessary for its operation. This could be helpful when performing vitrectomy in parts of the world where pressurized gas isn't available, such as remote areas or less-developed regions served by medical missions.

### In Vitro Studies

In our own in vitro studies, we've found the hypersonic vitrectomy cutter to be associated with smooth and continuous vitreous aspiration, primarily because the port is always open. The hypersonic vitrectomy probe creates little traction on the vitreous as the gel is liquefied around the probe opening.

In two histopathologic studies of porcine retinas funded by Bausch + Lomb, the instrument appeared to cause less disruption to the inner retinal layers than a pneumatic cutter (Figure 4).<sup>2,3</sup>


### Human Experience

The first in-human study was conducted at Dr. Agarwal's Eye Hospital in Chennai, India by the University of Manchester's Paulo Stanga, MD, Amar Agarwal, MD, and colleagues. They described their experience on 20 eyes that underwent vitrectomy for macular hole, vitreous hemorrhage and vitreomacular traction. The surgeons were able to perform core vitrectomy on all eyes with the hypersonic unit, and induced a posterior vitreous detachment in 13 of 15 eyes. The peripheral vitreous was shaved with the hypersonic vitrector in 18/20 eyes. However, one eye with a dense, organized vitreous hemorrhage and another with a retinal detachment had the peripheral gel removal completed

with a guillotine cutter. Two eyes developed retinal detachments that were ultimately repaired.<sup>4</sup>

Recently, our group presented on hypersonic vitrectomy at the 2018 American Society of Retina Specialists Meeting in an effort to describe the technology's performance and provide a sense of the pathologies it could be used for.<sup>5</sup> We performed a prospective, multicenter, non-randomized case series of 71 eyes in 71 patients using five different surgeons. We looked at such variables as intraoperative energy (stroke length and time) and fluid usage. The surgeons were also polled regarding the usefulness of the technology, complications and its potential advantages or disadvantages.

The surgeons found that hypersonic vitrectomy could be used for a variety of vitreoretinal cases, including retinal detachment repair, silicone oil aspiration, macular surgery, diabetic traction detachments and removal of retained lens material. The surgeons found that the average vitrectomy actuation time (the time spent stepping on the activation pedal to liquefy vitreous or remove fluid from the vitreous cavity) was approximately 5.5 minutes. In 97 percent of cases, there were no



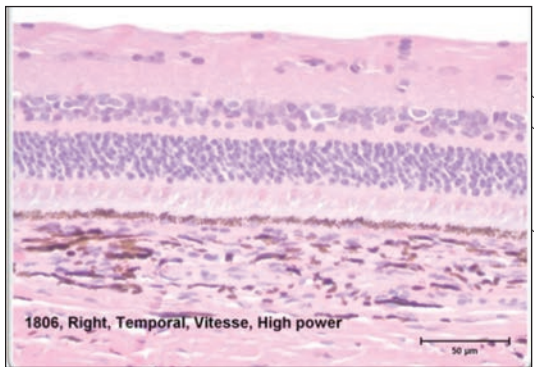
Bausch + Lomb

Figure 2. The hypersonic vitrectomy handpiece has a single lumen shaft, and the port is always open.



Bausch + Lomb

Figure 3. Examples of several tip designs for the hypersonic vitrectomy cutter. The single lumen design means the probe doesn't need to be straight, which allows flexibility in the shapes of the tips that can be created.



Kevin Blinder, MD, and Carl Awh, MD

Figure 4. Histopathology of a pig eye post-hypersonic vitrectomy. There is minimal disruption to the inner retinal layers.

intraoperative complications, although there was one case of a small iatrogenic retinal break in a detached retina, as well as some superficial scoring of the posterior intraocular lens surface (outside the visual axis) during capsulotomy in another eye.

In nearly 90 percent of cases, vitrectomy was performed entirely with the hypersonic vitrectomy probe. However, in cases of traction retinal detachment with thick diabetic membranes, and cases that had a taut posterior hyaloid, some of the study's surgeons preferred the guillotine cutter. The results were similar to a hypersonic probe, however.

The surgeons described little traction when shaving the peripheral vitreous near areas of mobile retina when using hypersonic vitrectomy. Decreased traction is particularly valuable when working near mobile detached retina, and hypersonic vitrectomy doesn't appear to induce much traction as it liquefies the gel. Hypersonic vitrectomy may also be useful in cases of retained lens material, in which the device has been shown to be effective enough to eliminate the need to use a fragmatome, even in cases with dense lens material. Interestingly, the hypersonic device can also remove 1,000 cs and even 5,000 cs silicone oil, possibly eliminating the need for separate silicone oil removal devices.

In conclusion, hypersonic vitrecto-

my represents a new way of removing vitreous gel that may have unique strengths that surgeons can take advantage of. However, as with any new technology, much work remains in order to optimize its use, such as determining its optimal settings, how to adjust stroke and vacuum for different pathologies and creating different probe designs. Guillotine vitrectomy probes have improved over

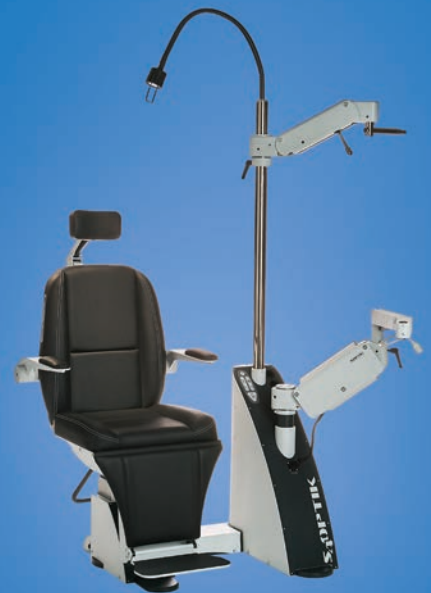the past 40 years due to continuous research, development and routine use. We're optimistic that hypersonic vitrectomy will rapidly improve as well, and be able to achieve excellent outcomes for patients with a variety of intraocular pathologies. **REVIEW**

*Dr. Garg is a professor of ophthalmology at the Sidney Kimmel Medical College at Thomas Jefferson University, an attending physician on the Retina Service at Wills Eye Hospital in Philadelphia, and a partner with MidAtlantic Retina. Dr. Blinder is a professor of clinical ophthalmology & visual sciences at Washington University School of Medicine. Dr. Awh practices at Tennessee Retina in Nashville.*

*The authors are consultants to Bausch + Lomb.*

1. Stanga PE, Pastor-Idoate S, Zambrano I, Carlin P, McLeod D. Performance analysis of a new hypersonic vitrector system. *PLoS One* 2017 Jun 6;12:6:e0178462. doi: 10.1371/journal.pone.0178462. eCollection 2017. PMID: 28586375
2. Ch'ng SW, Irion LD, Bonshek R, Shaw J, Papayannis A, Pastor-Idoate S, Stanga PE. Live porcine thirty days delayed recovery surgery: Qualitative findings with the hypersonic vitrectomy. *PLoS One* 2018 Jun 1;13:6:e0197038. doi: 10.1371/journal.pone.0197038. eCollection 2018. PMID: 29856756
3. Pastor-Idoate S, Bonshek R, Irion L, Zambrano I, Carlin P, Mironov A, Bishop P, McLeod D, Stanga PE. Ultrastructural and histopathologic findings after pars plana vitrectomy with a new hypersonic vitrector system. Qualitative preliminary assessment. *PLoS One* 2017 Apr 11;12:4:e0173883. doi: 10.1371/journal.pone.0173883. eCollection 2017. PMID: 28399127
4. Stanga PE, Williams JI, Shaarawy SA, Agarwal A, Venkataraman A, Kumar DA, You TT, Hope RS. First in human clinical study to investigate the effectiveness and safety of pars plana vitrectomy surgery using a new hypersonic technology. *Retina* 2018 Oct 23. doi: 10.1097/AE.0000000000002365. [Epub ahead of print. PMID: 30358763]
5. Garg SJ, Blinder K, Awh C, Tewari A, Srivastava S, Kolesnichenko V. The utility of hypersonic vitrectomy settings in vitreoretinal surgery. July 22, 2018. American Society of Retina Specialists Annual Meeting, Vancouver, Canada.

## Optimize space and functionality.



## Affordable, space-saving chair & stand solutions.

Small footprint  
41.2" x 34.2"



# Cataract Surgery May Not Slow Field Loss

**A** group of surgeons from Los Angeles, Seoul, South Korea and Milan say that, though cataract surgery tends to lower patients' intraocular pressure, it doesn't seem to have a similar beneficial effect on glaucoma patients' visual field progression post-surgery.

In the study, consecutive open-angle glaucoma patients who underwent cataract surgery and who had at least four visual field tests and at least three years of follow-up before and after surgery were retrospectively reviewed. Mean deviation (MD) rate, visual field index (VFI) rate, pointwise linear regression (PLR), pointwise rate of change (PRC), and the Glaucoma Rate Index (GRI) were compared before and after cataract surgery.

A total of 134 eyes of 99 patients were included. Median (interquartile range) follow-up was 6.5 (4.7 to 8.1) and 5.3 (4.0 to 7.3) years before and after cataract surgery, respectively.

All intraocular-pressure parameters (mean IOP, standard deviation of IOP, and peak IOP) significantly improved ( $p < 0.001$ ) after cataract surgery, but all VF indices indicated an accelerated VF decay rate after cataract surgery:

- MD rate ( $-0.18 \pm 0.40$  dB/year vs.  $-0.40 \pm 0.62$  dB/year,  $p < 0.001$ );
- VFI rate ( $-0.44$  percent  $\pm 1.09$  percent/year vs.  $-1.19$  percent  $\pm 1.85$  percent/year,  $p < 0.001$ );
- GRI ( $-5.5 \pm 10.8$  vs.  $-13.5 \pm 21.5$ ;  $p < 0.001$ ); and

- PRC ( $-0.62$  percent  $\pm 2.47$  percent/year before and  $-1.35$  percent  $\pm 3.71$  percent/year after surgery;  $p < 0.001$ ); and PLR ( $-0.20 \pm 0.82$  dB/year before and  $-0.42 \pm 1.16$  dB/year after surgery;  $p < 0.001$ ) for all VF locations.

Worse baseline MD and postoperative peak IOP were significantly associated with the postoperative VF decay rate and the change in the decay rate after cataract surgery.

The researchers concluded that cataract surgery didn't slow the rate of visual field decay when compared to the rate before cataract surgery was performed.

*Am J Ophthalmol.* 2019;201:19-30  
Kim JH, Rabiolo A, Morales E, et al.

## Unilateral Endothelial Keratoplasty and Quality of Life

In the primary Descemet Endothelial Thickness Comparison Trial, Descemet's membrane endothelial keratoplasty led to superior postoperative visual acuity compared with ultrathin Descemet's stripping automated endothelial keratoplasty. Investigators aimed to determine the effect of DMEK and UT-DSAEK on vision-related quality of life.

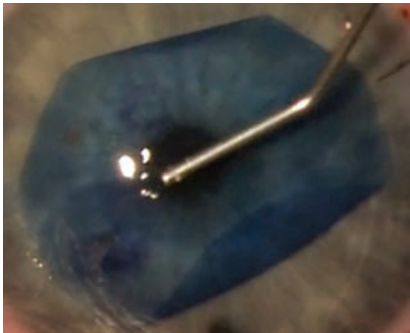
A prespecified, secondary analysis of a two-surgeon, patient- and outcome-masked randomized clinical trial was conducted at the Casey Eye Institute in Portland, Oregon, and Byers Eye Institute in Palo Alto, California. The study was conducted between

January 20, 2015, and April 26, 2017. The study enrolled 38 individuals and included 50 eyes with isolated endothelial dysfunction. Study eyes were randomized to receive either UT-DSAEK or DMEK. Responses to the National Eye Institute Visual Function Questionnaire-39 administered at baseline, and three and 12 months postoperatively were analyzed using the NEI-defined traditional subscales and composite score on a 100-point scale and with a Rasch-refined analysis.

The second eye from a single participant was excluded, along with any questionnaires relating to the first eye after second eye surgery, for evaluation of 38 eyes at baseline and three months, and 26 eyes at 12 months. Mean baseline visual acuity was  $0.35 \pm 0.31$  logMAR in the DMEK arm and  $0.28 \pm 0.22$  logMAR in the UT-DSAEK arm. Each arm consisted of 19 participants: 18 individuals with Fuchs' dystrophy and one participant with pseudophakic bullous keratopathy.

More women participated in both arms of the study (UT-DSAEK: 12 [63 percent]; DMEK: 11 [58 percent]); and mean age was  $68 \pm 11$  years in the UT-DSAEK arm and  $68 \pm 4$  years in the DMEK arm. Here are some of the findings:

- Overall, study participants experienced a 9.1-point improvement

**COMBO**COMBINE WITH OUR  
UNIQUE STAND

Sadleir Hannush, MD

A study found that DMEK may not improve vision-related quality of life more than DSAEK.

in NEI VFQ-39 composite score at three months compared with baseline ( $n=38$ ; CI, 4.9 to 13.3;  $p<0.001$ ), and an 11.6-point improvement at 12 months compared with baseline ( $n=26$ ; CI, 6.8 to 16.4;  $p<0.001$ ).

- Eyes randomized to DMEK had only 0.9 points more improvement in NEI VFQ-39 composite score at three months compared with UT-DSAEK after controlling for baseline NEI VFQ-39 (-6.2 to 8.0;  $p=0.80$ ).

Investigators concluded that improvement in vision-related quality of life wasn't shown to be greater with DMEK than with UT-DSAEK.

*JAMA Ophthalmol* 2019; May 2.  
[Epub ahead of print]  
Ang MJ, Chamberlain W, Lin CC, et al.

### Anterior Chamber IOL vs. Sutured PC-IOL Post Vitrectomy

Surgeons from the East and West Coasts contributed another datapoint to the perennial debate about anterior chamber intraocular lenses vs. scleral-sutured posterior-chamber IOLs after pars plana vitrectomy.

The study was a retrospective, interventional case series of eyes undergoing combined PPV and IOL placement for retained lens material, aphakia or dislocated IOL. Eyes with a history of amblyopia, corneal opacity or retinal or optic nerve disease were excluded. Outcome measures were change in visual acuity, and occurrence of postoperative complications

with minimum follow-up of a year.

The investigators identified 63 eyes of 60 patients. Thirty-three eyes underwent combined PPV and ACIOL placement, while and 30 eyes underwent combined PPV and scleral fixation of a PCIOL using a Gore-Tex suture. Mean follow-up was  $502 \pm 165$  days (median: 450, range: 365 to 1,095 days).

In the ACIOL group, mean visual acuity improved from 20/914 preoperatively to 20/50 postoperatively ( $p<0.001$ ). In the scleral-fixated PCIOL group, mean visual acuity improved from 20/677 preoperatively to 20/46 postoperatively ( $p<0.001$ ). No difference in visual acuity was noted between groups at one year ( $p=0.91$ ) or at the final follow-up ( $p=0.62$ ).

In terms of complications, eyes undergoing ACIOL placement had a significantly higher rate of transient corneal edema (30.3 vs. 6.7 percent,  $p=0.02$ ) compared with eyes undergoing scleral fixation of a PCIOL.

In light of the results, the surgeons say that both modalities resulted in similar visual outcomes.

*Retina* 2019;39:5:860-868.  
Khan MA, Gupta OP, Pendi K, et al.

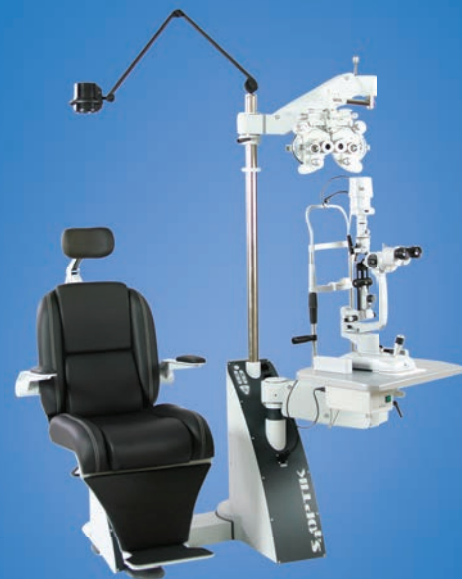### Acanthamoeba Co-infection More Common than Expected

Researchers from the Aravind Eye Hospital and Post-graduate Institute of Ophthalmology in Coimbatore, India say that *Acanthamoeba* co-infection appears to be more often associated with microbial keratitis than some might think.

In this prospective cross-sectional study, patients presenting with stromal keratitis were additionally tested for *Acanthamoeba*, regardless of the clinical diagnosis. The investigators used culture positivity as the gold standard.

Of the 401 cases included in the study, 40 were positive for *Acanthamoeba* (10 percent); of these 40, 16 were positive for both *Acanthamoeba*

## Effortless instrument positioning



## Advanced ergonomics



and fungi (4.5 percent of the study group was *Acanthamoeba*- and fungal keratitis-positive); five (1.2 percent) were positive for *Acanthamoeba* and bacteria; and two (0.5 percent) had a triple infection with *Acanthamoeba*, fungi and bacteria.

The physicians say that ring infiltrates and stromal edema are frequently associated with *Acanthamoeba* keratitis, as well as *Acanthamoeba* coinfections. Ring infiltrates in particular were more frequently seen in the *Acanthamoeba* and fungal keratitis group (8/16) and they were often yellowish with hyphate edges (vs. ring infiltrates only, which are seen in the patients with *Acanthamoeba* alone). Only two patients were contact lens wearers; however, they presented with history of trauma.

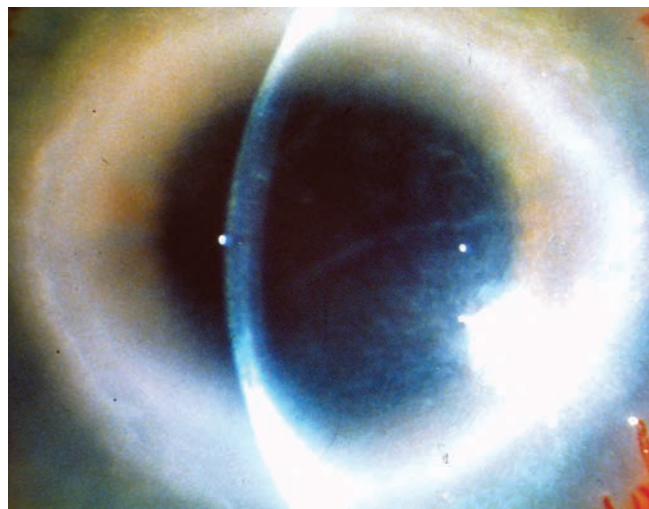
The researchers say that the results appear to show that *Acanthamoeba* infections are much more frequent than most think, and aren't just restricted to contact lens wearers. They add that anticipating coinfections is necessary for establishing a diagnosis, as well as a proper therapy.

*Am J Ophthalmol* 2019;201:31-36.  
Raghavan A, Baidwal S, Venkatapathy N, Rammohan R

### Retinal Characteristics in Eyes With Early AMD

Researchers assessed the features of the retinal pigment epithelium in eyes with early age-related macular degeneration and subretinal drusenoid deposits using optical coherence tomography.

They classified the eyes into three types: nonundulating RPE; undulating RPE; and wedge-shaped RPE. They compared the retinal vessel densities, retinal thickness and chorioidal thickness of a 3-mm-diameter



Researchers from India say that *Acanthamoeba* coinfection in cases of bacterial keratitis may be more common than doctors think.

zone. Their findings included the following:

- A total of 33 eyes were classified as having nonundulating RPE; 27 eyes were classified as having undulating RPE; and 20 eyes were identified as having wedge-shaped RPE.

- The vascular densities of the superficial and deep capillary plexuses showed differences: nonundulating RPE group 23.93 ±2.26 percent and 23.54 ±1.78 percent; undulating RPE group 22.29 ±2.80 percent and 21.94 ±2.42 percent; and wedge-shaped RPE group 21.93 ±2.7 percent and 20.63 ±2.42 percent ( $p=0.010$  and  $p<0.001$ ).

- Mean retinal thicknesses and chorioidal thicknesses were also different. The respective findings were: nonundulating RPE group, (298.26 ±13.81 μm and 180.08 ±55.49 μm); undulating RPE group, (285.29 ±21.88 μm and 148.45 ±55.08 μm); and wedge-shaped RPE group, (274.86 ±20.62 μm and 135.75 ±39.77 μm) ( $p=0.001$  and  $p=0.007$ ).

Researchers reported that altered features of the RPE on optical coherence tomography might indicate advancement in disease and be part of an overall degenerative process in

these eyes.

*Retina* 2019; Apr 2.  
[Epub ahead of print].  
Jang S, Park SY, Ahn SM, et al.

### Beta Blockers and AMD Progression

Researchers from the University of Pennsylvania's Scheie Eye Institute say surgeons and their patients probably don't need to worry about the risk of progression to wet age-related macular degeneration if the patients are using beta blockers.

In a retrospective cohort study of patients from 2000 to 2014, using data from a

large national U.S. insurer's claims database, researchers identified 18,754 beta blocker patients and 12,784 calcium channel blocker patients who met the criteria for inclusion.

After controlling for covariates, patients on beta blockers were at lower risk for neovascular AMD at both 90 and 180 days than patients on calcium channel blockers (HRs: 0.67-0.71;  $p<0.01$  for both) or diuretics (HRs: 0.55-0.62;  $p<0.01$ ). Patients on beta blockers, versus angiotensin-converting enzyme/angiotensin receptor blocker at all time points, and beta blockers versus calcium channel blockers and diuretics at 365 days, didn't have a significantly lower association with neovascular AMD (HR: 0.73-0.85;  $p>0.06$  for all).

A sensitivity analysis yielded similar results, with patients on beta blockers significantly less likely to develop wet AMD at 90 and 180 days (HR: 0.70-0.76;  $p<0.049$  for both) but not at 365 days (HR: 0.88;  $p=0.30$ ) compared with patients on calcium channel blockers.

Ultimately, the researchers say there was no evidence that beta blocker use increased the risk of wet AMD vs. other antihypertensive meds. **REVIEW**

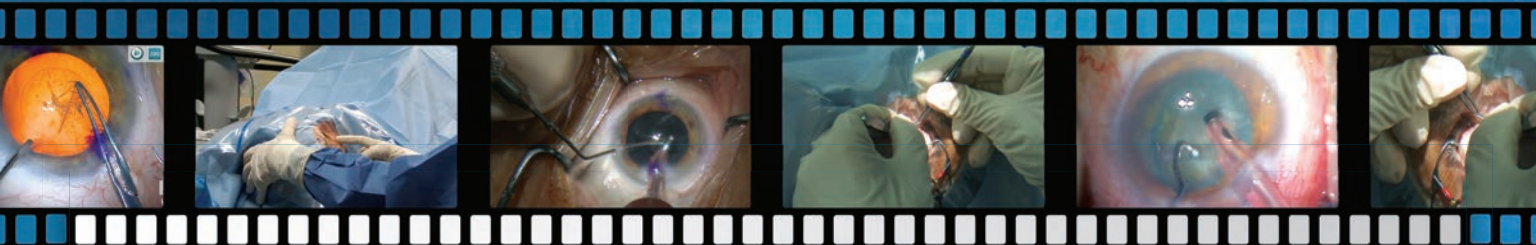




Monthly

# MACKOOL ONLINE CME

## CME SERIES | SURGICAL VIDEOS



To view CME video  
go to:

[www.MackoolOnlineCME.com](http://www.MackoolOnlineCME.com)

### Episode 42: "Posterior Subcapsular Cataract"

Surgical Video by:  
Richard J. Mackool, MD

#### Video Overview:

This patient developed a dense posterior subcapsular cataract following retinal detachment surgery. Here I demonstrate how to remove a thick epithelial layer from the posterior capsule and discuss anterior chamber depth in post-vitreotomized eyes.

### MackoolOnlineCME.com MONTHLY Video Series



Richard J. Mackool, MD

We are excited to continue into our fourth year of Mackool Online CME. With the generous support of several ophthalmic companies, I am honored to have our viewers join me in the operating room as I demonstrate the technology and techniques that I have found to be most valuable, and that I hope are helpful to many of my colleagues. We continue to edit the videos only to either change camera perspective or to reduce down time - allowing you to observe every step of the procedure.

As before, one new surgical video will be released monthly, and physicians may earn CME credits or just observe the case. New viewers are able to obtain additional CME credit by reviewing previous videos that are located in our archives.

I thank the many surgeons who have told us that they have found our CME program to be interesting and instructive; I appreciate your comments, suggestions and questions. Thanks again for joining us on Mackool Online CME.



**CME Accredited Surgical Training Videos Now Available Online:** [www.MackoolOnlineCME.com](http://www.MackoolOnlineCME.com)

Richard Mackool, MD, a world renowned anterior segment ophthalmic microsurgeon, has assembled a web-based video collection of surgical cases that encompass both routine and challenging cases, demonstrating both familiar and potentially unfamiliar surgical techniques using a variety of instrumentation and settings.

This educational activity aims to present a series of Dr. Mackool's surgical videos, carefully selected to address the specific learning objectives of this activity, with the goal of making surgical training available as needed online for surgeons motivated to improve or expand their surgical repertoire.

#### Learning Objective:

*After completion of this educational activity, participants should be able to:*

- perform a method that can be successfully employed to remove an extremely dense layer of epithelial cells from the posterior capsule.

**Satisfactory Completion** - Learners must pass a post-test and complete an evaluation form to receive a certificate of completion. You must listen to/view the entire video as partial credit is not available. If you are seeking continuing education credit for a specialty not listed below, it is your responsibility to contact your licensing/certification board to determine course eligibility for your licensing/certification requirement.



JOINTLY ACCREDITED PROVIDER™  
INTERPROFESSIONAL CONTINUING EDUCATION

**Physicians** - In support of improving patient care, this activity has been planned and implemented by Amedco LLC and Postgraduate Healthcare Education. Amedco LLC is jointly accredited by the Accreditation Council for Continuing Medical Education (ACCME), the Accreditation Council for Pharmacy Education (ACPE), and the American Nurses Credentialing Center (ANCC), to provide continuing education for the healthcare team

**Credit Designation Statement** - Amedco designates this enduring material activity for a maximum of .25 AMA PRA Category 1 Credits™. Physicians should claim only the credit commensurate with the extent of their participation in the activity.

Endorsed by:  
**Review of Ophthalmology®**  
Video and Web Production by:  
**JR Snowdon, Inc**




Jointly provided by:  
**REG**  
(Review Education Group)

Supported by an unrestricted independent  
medical educational grant from:  
**Alcon**

Additionally Supported by:  
**Glaukos  
MST  
Crestpoint Management  
Carl Zeiss Meditec**

In Kind Support:  
**Sony Healthcare  
Solutions**



# Easing Your Patients' Financial Burden

Doing what you can to limit the cost of glaucoma treatment can improve adherence and create happier patients.

*Yvonne Ou, MD, San Francisco*

**E**very ophthalmologist treating glaucoma knows that patients have problems with compliance and adherence, and it's no secret that a lot of this is tied to the cost of treatment. In one study of patient/doctor communication over a series of glaucoma visits, a patient said (on camera), "Sometimes I forget [to buy the drops] purposely, because they're so darned expensive. I figure if I use them half as much, I'll only pay half the money."<sup>1</sup>

There are actually a number of ways to reduce the cost of the medications patients have to purchase, but this fact is rarely discussed when patients are in the clinic. In fact, the same study of patient-physician communication found that medication costs were only discussed in 1.4 percent of visits(!) (See *Table, facing page.*) Another study involving asthma patients found that 40 to 50 percent of patients wanted to discuss medication cost with the doctor, but the patients only brought it up in a tiny fraction of the visits.<sup>2</sup>

Here, I'll share nine ways you can help your patients reduce

the costs associated with glaucoma treatment.

**1** *Talk to your patients about cost and availability concerns.* As noted above, most patients aren't going to bring up their cost concerns, so you, the physician, should bring up the topic. You might say: "Glaucoma is a life-long disease, but we'll work together to create a treatment plan that's sustainable over the long term. Do you have any difficulty paying for your glaucoma medications?" That can open the door to a longer discussion.

Also, in some cases the drug you're prescribing may not be part of the patient's insurance company's formulary. Be sure to address that by advising the patient on the best way to proceed.

**2** *Consider switching the class of medication you're prescribing.* Joshua Stein, MD, and his group did a worldwide price comparison of glaucoma medications, as well as laser trabeculoplasty and trabeculectomy.<sup>3</sup> The price differences among the drug options are significant. (See *chart, page 62.*) As you'd expect, beta blockers are the least expensive, at about 38 cents a day; the price jumps up significantly when you move to combination products. Not surprisingly, the newest medications are the most expensive.

It's worth explaining to the patient the difference between brand name drops and generics, and why the generics are usually—though not always—less expensive (e.g., not having to repeat the animal and



human clinical studies of safety and effectiveness that were required of the brand-name drug, and marketplace competition driving down the cost). It's important to emphasize, however, that the patient should always check the prices to make sure the generic is actually less expensive; factors such as shortages can alter prices.

You should also point out that the generic may not be identical to the brand name drug, since only the active ingredient has to be the same. For that reason, you should advise your patient to let you know in the unlikely case that any problem with side effects arises.

**3 Spell out options in your prescription.** The key here is to allow the patient access to the least expensive form of the prescribed drug (when appropriate). When writing the prescription, consider prescribing generics, or write "generic substitution OK" as a note to the pharmacy. Also, purchasing the components of combination medications separately may be less expensive for the patient. Writing "OK to dispense separate components if costs less" may help remind the patient to ask about this. (You should point out to the patient that this will eliminate some of the convenience of a combination drop, especially since it's important to wait five or 10 minutes between drops to avoid washing out the first drop with the second.)

**4 Encourage the patient to shop for the lowest price.** Patients may not realize that medication prices can vary widely from pharmacy to pharmacy, and even from day to day. There are a number of strategies that can help your patient find the best price on glaucoma drugs:

— *Generics are sometimes less expensive at large chain stores.* For example, as I write this it's possible to purchase a 30-day supply of some

## Communication with Patients During the Examination

Provider behavior	Percentage (#) of visits
Physician asks about a glaucoma medication problem	1.4 (4)
Physician proposes a solution to a potential glaucoma-related cost problem	17.9 (50)
Physician recommends that patient work with pharmacist to lower medication cost	1.1 (3)
Physician asks how much patient is paying for glaucoma medications	2.2 (6)

generics for as little as \$4 at Target and Walgreen's. However, availability may change from year to year. For example, Walmart used to offer timolol for \$4, but it's no longer on their list.

— *Buying a larger supply often lowers the per-day price.* For example, a 90-day supply may be less-expensive per day than a 30-day supply. (Of course, this requires a larger initial outlay, but with an inexpensive generic that may not be a significant issue for most patients. For example, generic timolol might cost \$4 per month, vs. \$10 for a three-month supply.) One important caveat: Don't suggest buying a larger supply to save money until your drug regimen for the patient has been settled.

— *Patients can compare prices by calling their local pharmacies, or by doing a little research online.* Some websites and apps compare local prices for you, although they may not include every local source. One well-known option is [GoodRx.com](http://GoodRx.com), which lists local prices, sometimes offering a free coupon that can be printed out or sent to the patient's phone. GoodRx claims that this can result in cost savings up to 80 percent. (I called the local pharmacies in a listing to see if the listed prices were correct; they were not always accurate to the penny, but they were very close.) The drawback of GoodRx.com is that it doesn't include prices from local independent pharmacies. Often,

independent pharmacies will have pretty good deals, especially for cash-paying patients.

Additional online resources include BlinkHealth, [WeRx.org](http://WeRx.org), SlashRx and several others.

— *The type of pharmacy your patient buys from can make a difference.* Independent pharmacies may offer lower prices on brand-name products, and sometimes will offer a discount if the patient pays cash. On the other hand, for generics, the lowest prices may be at the large chains such as Target and Walgreen's. Some pharmacies also offer prescription savings clubs you can join, although patients already on Medicare or Medicaid probably won't qualify.

— *The drug manufacturer may offer coupons, especially for newer drugs.* These may be a mixed blessing, however, as the manufacturer may find other ways to retake some of the discount by raising the co-pay or changing coverage limits. Also, this type of coupon may not be available to patients already on Medicare or Medicaid.

**5 Be willing to provide a written prescription.** Although most of us today simply send an electronic prescription to the patient's pharmacy, some patients who are interested in shopping around for the best price may need a written prescription so they have something to



**Per-day Glaucoma Drug Price Comparison\***

BB	AA	CAI	PGA	BB+CAI	BB+AA	Netarsudil	LBN
\$0.38	\$0.97	\$1.04	\$1.62	\$1.83	\$5.29	\$8.38	\$12.53

\* Numbers from [GoodRx.com](http://GoodRx.com).

BB=beta blocker; AA=alpha agonist; CAI=carbonic anhydrase inhibitor; PGA=prostaglandin analogue; LBN=latanoprostene bunod.

fax (or scan) to show to the pharmacy.

**6 Warn patients to be careful about buying drops online.**

Even some sources that have been “vetted” by supposedly reliable organizations like PharmacyChecker.com and the Canadian International Pharmacy Association (CIPA) have been charged with misrepresenting the source of the drugs they sell. If your patients want to pursue this, they should visit [fda.gov/ForConsumers/ConsumerUpdates/ucm048396.htm](http://fda.gov/ForConsumers/ConsumerUpdates/ucm048396.htm) for advice from the federal government on how to ensure they’re purchasing their drugs from a reliable source.

**7 Encourage your patient to talk to the pharmacist.**

In the past, pharmacists were prohibited by law from discussing price options with patients. That “gag order” has now been lifted—although it’s still in place until 2020 for patients on Medicare and Medicaid.

This is important, because the lowest price, even in one pharmacy, is not always the one patients expect. For example, the cash price of a drug may actually be lower than the co-pay charged by the insurance company—meaning the patient would shell out less when buying the drug with cash than by using his or her insurance. (This is often the result of having a “pharmacy benefits manager” at the insurance company who negotiates co-pays and other details with the pharmacy.) Most patients wouldn’t expect the cash price to be cheaper, so they pay the co-pay without questioning whether this is actually the best deal.

Here’s a hypothetical example: Suppose the benefits manager has negotiated a \$15 co-pay for a supply of a generic drug. The medicine in question cost the pharmacy \$2.05. If the patient pays the \$15 co-pay, the pharmacy might be reimbursed \$7.22 by the insurance company, resulting in a profit of \$5.17 for the pharmacy. The pharmacy benefits manager claims the remaining \$7.78.

In contrast, the price for a cash sale is set by the pharmacy. Since the drug cost them \$2.05, they could double that to make a profit, and the patient paying cash would be charged \$4.10. That’s a lot less than \$15. Even if the pharmacy quadruples the cost to make a more substantial profit, the patient would pay \$8.20, still substantially less than the \$15 co-pay.

How widespread is the phenomenon of patients paying more than necessary for their drugs? A 2018 study conducted by Dana Goldman, PhD, and colleagues looked at this question using Centers for Medicare & Medicaid Services data from 9.5 million prescriptions purchased in 2013.<sup>4</sup> They found that 23 percent of the time, patients would have been better off paying cash. The average overpayment isn’t huge (\$7.69), but that adds up over time.

Other findings from that study included that overpayment was more likely to occur with a generic than with a brand name. (This makes sense, given the lower price of most generic drugs.) However, the average size of the overpayment was smaller when generics were purchased. The total overpayments for drugs in their data sample totaled \$135 million for the year 2013.

**8 Encourage your patient to take advantage of patient assistance programs.**

There are many programs designed to help patients afford their drug prescriptions. Some are national, some are state-sponsored and some are regional or local.

There are a number of nationwide nonprofit organizations, such as NeedyMeds, Partnership for Prescription Assistance, RxAssist, RxHope and RxOutreach. For some patients, including those for whom English is a second language, the paperwork involved in taking advantage of these resources can be a challenge. RxHope might be a good option for those patients, as it will help those patients complete the paperwork. NeedyMeds also provides a list of programs that are able to help patients with the paperwork.

Many drug manufacturers also have patient-assistance programs. I called up one drug manufacturer to see how this works. It became clear that they don’t provide patient advocates to help patients navigate this process, but the customer service representative I spoke to was pretty helpful.

More information about what the drug companies have to offer can be found online at [medicare.gov/pharmaceutical-assistance-program/](http://medicare.gov/pharmaceutical-assistance-program/). Another strategy is to simply call the drug manufacturer and ask about drug cost assistance, or Google the name of the manufacturer along with “patient assistance program.”

A particularly helpful resource for your patients is [benefitscheckup.org](http://benefitscheckup.org), which is sponsored by the National Council on Aging. I like this resource because it summarizes all kinds of benefits that are available for your patients, including benefits related to health care in general, income assistance, food and nutrition, housing and utilities, tax relief, benefits for veterans and employment assistance.

## Patient Pharmaceuticals: Financial Aid Resources

BenefitsCheckup.org	<a href="http://benefitscheckup.org/">benefitscheckup.org/</a>	
BlinkHealth	<a href="http://blinkhealth.com/">blinkhealth.com/</a>	855-979-8290
FDA	<a href="#">How to Buy Medicines Safely From an Online Pharmacy</a>	888-463-6332
GoodRX	<a href="http://goodrx.com">goodrx.com</a>	855-268-2822
Medicare Pharmaceutical Assistance Program	<a href="http://medicare.gov/pharmaceutical-assistance-program/">medicare.gov/pharmaceutical-assistance-program/</a>	800-633-4227
NeedyMeds	<a href="http://needymeds.org/">needymeds.org/</a>	800-503-6897
Partnership for Prescription Assistance	<a href="http://pparx.org/">pparx.org/</a>	
PharmacyChecker	<a href="http://pharmacychecker.com/">pharmacychecker.com/</a>	718-554-3067
RxAssist	<a href="http://rxassist.org/">rxassist.org/</a>	
RxHope	<a href="http://rxhope.com/">rxhope.com/</a>	
RxOutreach	<a href="http://rxoutreach.org/">rxoutreach.org/</a>	888-796-1234
WeRx	<a href="http://werx.org/">werx.org/</a>	408-638-9379

It asks for some basic demographic information, such as age bracket and income level; then it tells you what kind of benefits you can apply for. Of course, it's up to the patients to take advantage of the programs for which they qualify.

### 9 Consider performing SLT.

We've already seen evidence that selective laser trabeculoplasty is an effective first-line treatment.<sup>5</sup> It's also less expensive for the patient in most cases; the worldwide price comparison of glaucoma medications mentioned earlier<sup>3</sup> found that bilateral laser trabeculoplasty is less expensive than a three-year supply of latanoprost in 71 percent of developing countries—including the United States. Despite this data, old habits die hard. Most physicians, especially in the United States, still start with medications first.

Recently, new evidence was published that suggests that SLT can be as effective—or more effective—than starting treatment with medications.<sup>6</sup> This data came from a multicenter trial looking at patients with POAG

and ocular hypertension that was conducted in the United Kingdom. In this trial, 356 subjects were randomized to laser, 362 to eye drops. The primary outcome was quality of life, and surprisingly, they didn't find any statistically significant difference between the groups. (You might have expected that patients would have complained about their eye drops, compared to a single laser treatment.) However, this was confounded by the fact that patients had individual target IOPs, so even if you had the laser, you might end up back on a drop if you didn't quite reach the target. Furthermore, the quality-of-life instruments used may not have been sensitive enough to detect treatment side effects related to this.

Nevertheless, at 36 months, 74 percent of the SLT group didn't require drops to maintain target IOP, and over the three-year period of the study, there was a 97-percent probability that SLT as first treatment was more cost-effective than starting with eye drops. Furthermore, eyes of patients in the SLT group were at the target IOP at more visits than patients in the

eye-drop group (93 percent vs. 91.3 percent of visits); and no one in the SLT group required glaucoma surgery to lower IOP, while 11 patients in the eye-drop group did. This is pretty compelling data.

## Passing It On

Of course, sharing all of this with patients during an examination might take more time than a physician is able to spend. An alternative would be to make up a sheet summarizing all of the cost-saving suggestions that are relevant, including whatever helpful organizations are based in your state and local area. Another possibility would be to provide patients with a copy of an article I wrote for the Brightfocus Foundation, which was written for patients rather than physicians, that summarizes this information. (You can find the article at [brightfocus.org/glaucoma/article/top-10-tips-reducing-costs-your-glaucoma-medications](http://brightfocus.org/glaucoma/article/top-10-tips-reducing-costs-your-glaucoma-medications).)

Given that the ongoing cost of glaucoma treatment can be a challenge for many of your patients, they'll be grateful for your help. **REVIEW**

*Dr. Ou is an associate professor of ophthalmology, co-director of the glaucoma service and vice chair for postgraduate education in the Department of Ophthalmology at the UCSF School of Medicine in San Francisco.*

1. Slota C et al. Patient-physician communication on medication cost during glaucoma visits. *Optom Vis Sci* 2017;94:1095-1101.
2. Patel MR, Wheeler JR. Physician-patient communication on cost and affordability in asthma care. Who wants to talk about it and who is actually doing it. *Ann Am Thorac Soc* 2014;11:10:1538-44.
3. Zhao PY, Rahmathullah R, Stagg BC, et al. A worldwide price comparison of glaucoma medications, laser trabeculoplasty, and trabeculectomy surgery. *JAMA Ophthalmol* 2018;136:11:1271-1279.
4. Van Nuys K, Joyce G, Ribero R, Goldman DP. Frequency and magnitude of co-payments exceeding prescription drug costs. *JAMA* 2018;319:10:1045-1047.
5. Waisbourd M, Katz LJ. Selective laser trabeculoplasty as a first-line therapy: A review. *Can J Ophthalmol* 2014;49:6:519-22.
6. Gazzard G, Konstantakopoulou E, Garway-Heath D, et al. Selective laser trabeculoplasty versus eye drops for first-line treatment of ocular hypertension and glaucoma (LIGHT): A multicentre randomised controlled trial. *Lancet* 2019;393:10180:1505-1516.



# Silent Sinus Syndrome: Look Past the Eye

How to detect and manage this rare condition, which can be associated with a range of symptoms.

*Ryan A. Rimmer, MD, Judd H. Fastenberg, MD, Marc R. Rosen, MD, Gurston G. Nyquist, MD, and Mindy R. Rabinowitz, MD, Philadelphia*

**D**ue to the close anatomic relationship between the orbit and paranasal sinuses, ophthalmologists must be cognizant of certain sinonasal diseases that may present with ocular manifestations. One such disease process, silent sinus syndrome, is a progressive condition in which maxillary sinus pathology causes inferior displacement of the orbital floor, resulting in enophthalmos and hypoglobus. The pathophysiology involves a negative pressure phenomenon within the sinus leading to inward bowing of the sinus walls. As such, SSS is often referred to as “chronic maxillary sinus atelectasis.”<sup>1</sup>

Since its initial report in the literature in 1994,<sup>2</sup> our understanding of SSS has improved substantially. Although the “silent” nomenclature initially referred to the subclinical nature of sinus symptoms in affected patients, we now understand that patients with SSS may present with a range of different sinonasal or ocular symptoms.<sup>1</sup>

This review will provide an overview of our current understanding of the epidemiology, pathophysiology, diagnosis and management of SSS.

## Epidemiology

SSS is a sparsely reported entity, with only about 150 cases reported in the literature.<sup>3</sup> However, increased awareness of the condition since its initial description, combined with more widespread use of computed tomography (CT) imaging, has demonstrated that the condition may be more common than previously thought.<sup>4</sup>

Most reported cases involve adults during the fourth or fifth decade of life, although SSS has also been described in the pediatric population.<sup>5</sup> There’s no clear gender predilection. However, for unknown reasons, the patient’s right side is slightly more commonly involved.<sup>1,6</sup>

## Pathophysiology

Multiple theories have been proposed to explain the pathophysiology of SSS. Initially, it was suggested that congenital maxillary hypoplasia contributed to enophthalmos; however, this was disproven by cases of patients with normal sinus anatomy on imaging who subsequently developed SSS.<sup>6</sup>

The prevailing theory now involves

hypoventilation of the maxillary sinus due to obstruction of the ostiomeatal complex (OMC). In normally functioning sinuses, the OMC serves as a channel linking drainage from the frontal, anterior ethmoid and maxillary sinuses to the middle meatus. With obstruction, there is impaired drainage of the sinuses. Over time, this blockage may contribute to the resorption of gases by capillaries within the closed sinus walls, resulting in negative pressure within the sinus. This pressure leads to an inward bowing of the sinus walls and subsequent atelectasis.<sup>1</sup>

One limitation of this theory is that it doesn’t explain why most patients with OMC obstruction don’t develop hypoventilation and, instead, develop symptoms of acute or chronic sinusitis.

Several additional pathophysiologic mechanisms have therefore been proposed. These include the possibility that a communication between the afflicted sinus and the pterygopalatine fossa may generate a negative pressure gradient during chewing.<sup>1</sup> Furthermore, patients with SSS often develop thinning of the orbital floor, which contributes to hypoglobus. At the same time, many patients with chronic max-



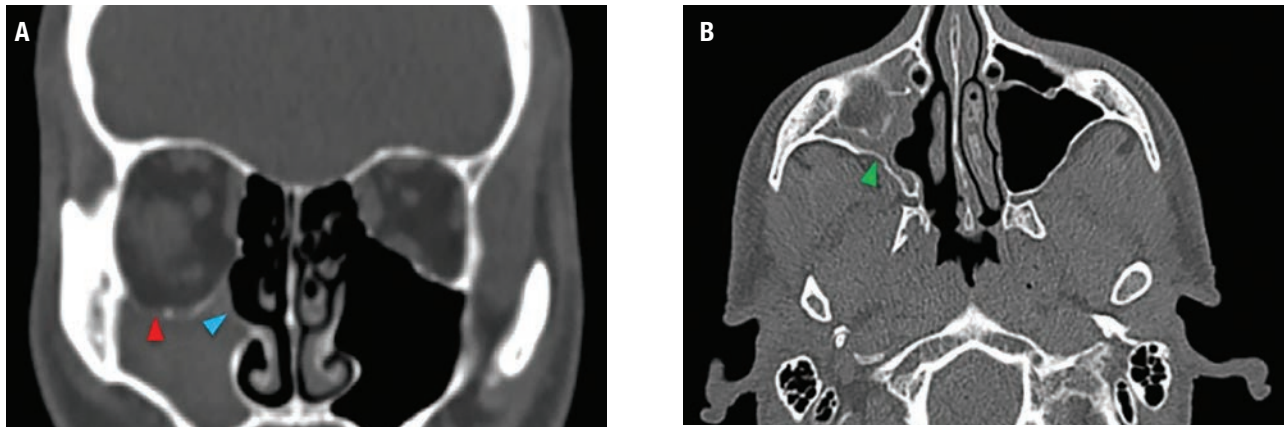


Figure 1. CT scan of a patient with SSS. A) Coronal plane: Note the inferior displacement of the orbital floor (red arrowhead) and lateral displacement of the uncinate process (blue arrowhead) into an opacified right maxillary sinus. B) Axial plane: Note the inward bowing of the right maxillary sinus walls (green arrowhead).

illary sinusitis may develop orbital floor thickening leading instead to proptosis. This contrast supports a theory that there may be poorly understood cytokine-mediated alterations in resorptive activity, sinus pressure and degree of inflammation that determine whether the disease presents with thickened or thinned orbital walls.<sup>1</sup>

## Diagnosis

Following are the signs, symptoms and imaging results to look for when presented with a potential SSS patient.

- **Presentation.** The classic presentation of SSS involves painless enophthalmos and hypoglobus with subclinical sinus disease. A patient series from 2004 reported enophthalmos in the range of 2 to 6 mm (mean: 3.4 mm) and hypoglobus in a range of 1 to 6 mm (mean: 3.2 mm).<sup>4</sup>

Symptom onset is generally considered to be progressive. In a review of 84 published cases, the average duration of symptoms prior to presentation was 6.52 months. Despite this trend, several reports of acute onset of symptoms exist in the literature.<sup>4</sup>

In cases of severe hypoglobus, there may be constriction of the inferior oblique muscle, leading to restriction of upgaze; however, this occurs in a minority of cases.<sup>4</sup> Rates of vertical

diplopia due to hypoglobus muscle restriction range widely, but this is considered to be an uncommon presentation.<sup>7</sup> Other uncommon symptoms include dental pain and dry eye, which may be attributed to lagophthalmos.<sup>1</sup>

On physical exam, there may be hypertropia of the afflicted eye and malar depression. Asymmetric eyelid creases can result from dysfunction of the levator palpebrae superioris, secondary to hypoglobus. Patients may appear to have signs and symptoms consistent with ptosis; however this is commonly pseudoptosis due to enophthalmos and hypoglobus. In some cases, patients may also exhibit pseudoretraction and lid lag as the oculomotor nerve fires to balance the inferior mechanical pull, which simultaneously activates the levator muscle.<sup>1</sup>

Importantly, consideration of sinonasal pathology shouldn't be neglected in the setting of enophthalmos and hypoglobus. Patients should be questioned about symptoms of nasal obstruction, drainage, facial pressure or pain, as well as a history of sinusitis. Even if patients are asymptomatic, any clinical suspicion should prompt referral to an otolaryngologist for comprehensive evaluation, including nasal examination. Septal deviation is common in patients with SSS, and typically deviates to the ipsilateral side of disease.<sup>6</sup>

Additional findings on endoscopic examination to support the diagnosis of SSS include a lateralized uncinate process and enlarged middle meatus due to atelectasis of the maxillary sinus. Concomitant sinonasal inflammation may also be present, including edema and/or polypoid disease in the middle meatus.

- **Radiology.** When considering SSS, radiologic evaluation is critical for establishing a diagnosis, delineating anatomy and planning treatment. A CT scan of the orbit and sinuses is the gold standard for visualizing bony anatomy, although magnetic resonance imaging may also be adequate.

Radiologic hallmarks of SSS include unilateral atelectasis of the maxillary sinus with variable inward bowing of the sinus walls, lateralized uncinate process that may be adhered to lamina papyracea, depression of orbital floor and obstruction of the OMC (*Figure 1*). The maxillary sinus is most commonly opacified, but there are reports of SSS in patients with aerated sinuses.<sup>3</sup>

- **Differential diagnosis.** While the classic symptoms of painless enophthalmos and hypoglobus are suggestive of SSS, they shouldn't be considered pathognomonic. A broad differential diagnosis may include infectious processes (e.g., chronic sinusitis, osteomyelitis), malignancy, inflammatory or

**Table 1: Summary of Clinical and Radiologic Signs of SSS**

CLINICAL	RADIOLOGIC
Deep superior sulcus	Inward bowing of sinus walls
Hypoglobus	Lateralized uncinat process
Enophthalmos	Depression of orbital floor
Pseudoptosis	Obstruction of OMC

vasculitic diseases (pseudotumor, granulomatosis with polyangiitis or scleroderma), trauma or iatrogenic causes (e.g., surgery, external beam radiation). Many of these listed alternatives may present with other clinical signs and symptoms, which may predate the ocular symptoms and suggest something other than SSS. A thorough history and physical should be obtained to identify the most likely etiology and ensure appropriate treatment.<sup>8</sup> (A summary of the clinical and radiologic characteristics of SSS is shown in Table 1, above.)

**Treatment**

Treatment of SSS involves two primary goals: first, to improve maxillary sinus drainage and relieve obstruction in order to prevent disease progression; and, second, to restore normal orbital anatomy. These two goals may be accomplished simultaneously or separately through a variety of techniques.

Functional endoscopic sinus surgery (FESS) performed by an otolaryngologist is the mainstay of treatment for SSS. At a minimum, it entails a maxillary antrostomy that’s performed by completely removing the lateralized uncinat process and widely opening the natural sinus ostium. This procedure promotes improved sinus drainage and improves aeration. Importantly, because in SSS the uncinat process is lateralized and the orbital floor may be lowered, there’s an increased risk of orbital injury when a maxillary antrostomy is performed. Appropriate preoperative consideration of this anatomy is critical.

In some cases, FESS alone may lead

to both improvement of the underlying disease process and resolution of the orbital symptoms.<sup>6,9</sup> Studies have demonstrated bony remodeling of the maxillary sinus walls following FESS with resolution of atelectasis, thickening of bone and decreased symptoms.

For patients with persistent enophthalmos or in patients with such severe disease that complete recovery would be unexpected with FESS alone, orbital floor reconstruction can be performed. The timing of this step is controversial. Given that FESS alone may halt progression of ocular symptoms over time, simultaneous reconstruction of the orbital floor may be unnecessary and cause overcorrection of the deficit. Proponents of this strategy tout its reduced risk, noting that it minimizes anesthesia and trips to the operating room. Alternatively, orbital reconstruction can be performed as a second-stage operation two to six months after FESS. This allows for any orbital changes associated with FESS to occur, potentially avoiding overcorrection with orbital floor reconstruction. Furthermore, a two-stage approach prevents placement of an orbital floor implant into a potentially infected sinus cavity.<sup>1</sup>

Options for surgical floor implants include alloplastic implants (e.g., titanium, hydroxyapatite, silicone, nylon) or autogenous (e.g., septal or costochondral cartilage, calvarial bone grafts). Implants are typically placed via a transconjunctival or subciliary approach and fixated to the orbital rim for stability.<sup>1</sup> Alternatively, a nonsurgical option for treatment of enophthalmos after FESS is injection of hy-

aluronic acid into the intraconal and extraconal space. Studies have shown durable results for six months with this approach.<sup>10</sup>

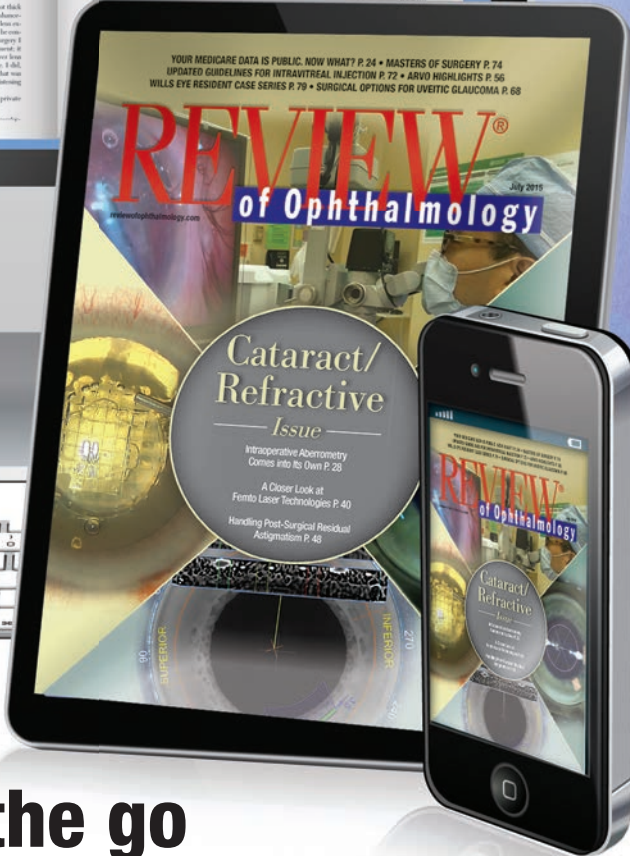
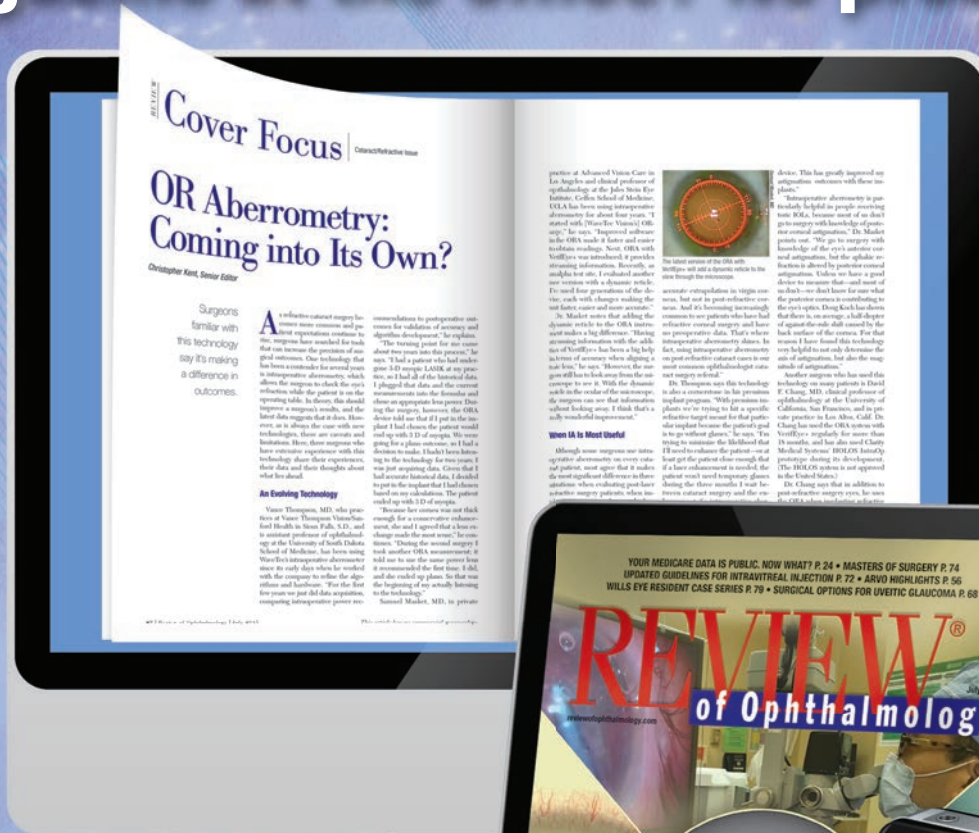In conclusion, SSS is an example of how sinonasal disease can manifest with ocular symptoms. In patients with painless hypoglobus and enophthalmos, a diagnosis of silent sinus syndrome should be suspected. A multidisciplinary approach with referral to an otolaryngologist should be adopted. Management involves functional endoscopic sinus surgery to improve sinus aeration, with or without orbital floor reconstruction. **REVIEW**

*Dr. Rimmer is a fourth year resident in the Department of Otolaryngology-Head and Neck Surgery at Thomas Jefferson University in Philadelphia. Dr. Fastenberg is the Rhinology and Endoscopic Skull Base Surgery fellow in the Department of Otolaryngology-Head and Neck Surgery at Jefferson. Drs. Rosen, Nyquist and Rabinowitz are members of the Division of Rhinology and Skull Base Surgery in the Departments of Otolaryngology-Head and Neck Surgery and Neurological Surgery at Thomas Jefferson University Hospital. They have specialized training in the management of complex diseases of the paranasal sinuses, medial orbit and anterior cranial base.*

1. Pula JH, Mehta M. Silent sinus syndrome. *Curr Opin Ophthalmol* 2014;25:6:480-484.
2. Soparker CN, et al. The silent sinus syndrome. A cause of spontaneous enophthalmos. *Ophthalmology* 1994;101:4:772-8.
3. Lee DS, Murr AH, et al. Silent sinus syndrome without opacification of ipsilateral maxillary sinus. *Laryngoscope* 2018;128:2004-2007.
4. Soparker CN, Patrinely JR, Davidson JK. Silent sinus syndrome—New perspectives? *Ophthalmology* 2004;111:2:414-415.
5. Chang DT, Truong MT. A child with silent sinus syndrome and spontaneous improvement after sinus surgery. *Int J Pediatr Otorhinolaryngol* 2014;78:1993-1995.
6. Martinez-Capoccioni G, Varela-Martinez E, Martin-Martin C. Silent sinus syndrome an acquired condition and the essential role of otorhinolaryngologist consultation: A retrospective study. *Eur Arch Otorhinolaryngol* 2016;273:3183-88.
7. Gomez J, Liu D, Palacios E, Nguyen J. Diplopia: An uncommon presentation of silent sinus syndrome. *Ear Nose Throat J* 2015;94:7:258-60.
8. Numa WA et al. Silent sinus syndrome: A case presentation and comprehensive review of all 84 reported cases. *Ann Otol Rhinol Laryngol* 2005;114:9:688-94.
9. Kram YA, Pletcher SD. Maxillary sinus posterior wall remodeling following surgery for silent sinus syndrome. *Am J Otolaryngol* 2014;35:623-625.
10. Mavrikakis I, Deterakis ET, Yiotakis I, Kandiloros D. Nonsurgical management of silent sinus syndrome with hyaluronic acid gel. *Ophthal Plast Reconstr Surg* 2012;28:e6-e7.



# Left your *Review of Ophthalmology* magazine at the office? No problem!



## Read *Review* on the go from any mobile device!

Simply go to [www.reviewofophthalmology.com](http://www.reviewofophthalmology.com) and click on the digimag link to get your current issue.



# Zeiss Upgrades Its OCT/OCTA Unit

**F**aster, deeper and higher-resolution imaging of the eye is now possible with the new Dual-Speed Swept Source feature for the PLEX Elite 2.0 OCT/OCTA, according to the device's maker, Zeiss. The company says that the new feature provides expanded visualization options, helping reveal how diseases are manifesting. It can now scan at both 200 kHz and 100 kHz, which enables a more detailed analysis of the retina that may enhance the quality of ophthalmic care and research, the company says. With the Dual-Speed Swept-Source OCT/OCTA, the PLEX Elite 2.0 can provide faster scans that visualize from the retinal-vitreous interface down to the choroid, and image conditions such as posterior staphylomas, retinal detachments, high myopia and choroidal tumors. For more



information, visit [zeiss.com/med](http://zeiss.com/med).

## Centurion Modifications

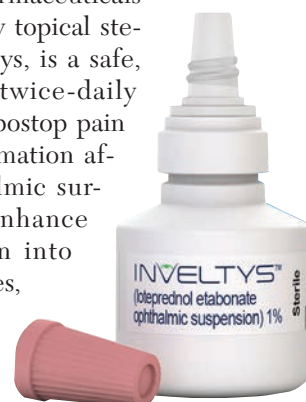Alcon's Centurion Vision System has two new improvements, the Active Sentry Handpiece and Intrepid Hybrid Tip, that Alcon says are intended to improve safety, consistency and control during cataract surgery.

Active Sentry has a built-in fluidics pressure sensor that communicates with the Centurion vision system to detect pressure in real time and alert the system's Active Fluidics technology as fluctuations occur to stabilize the anterior chamber. The Intrepid Hybrid Tip, designed with a rounded polymer edge, can improve patient safety in the operating room by reducing the risk of capsular tears, the company says. Visit [professional.myalcon.com](http://professional.myalcon.com) for more information.



## Ocular Corticosteroid

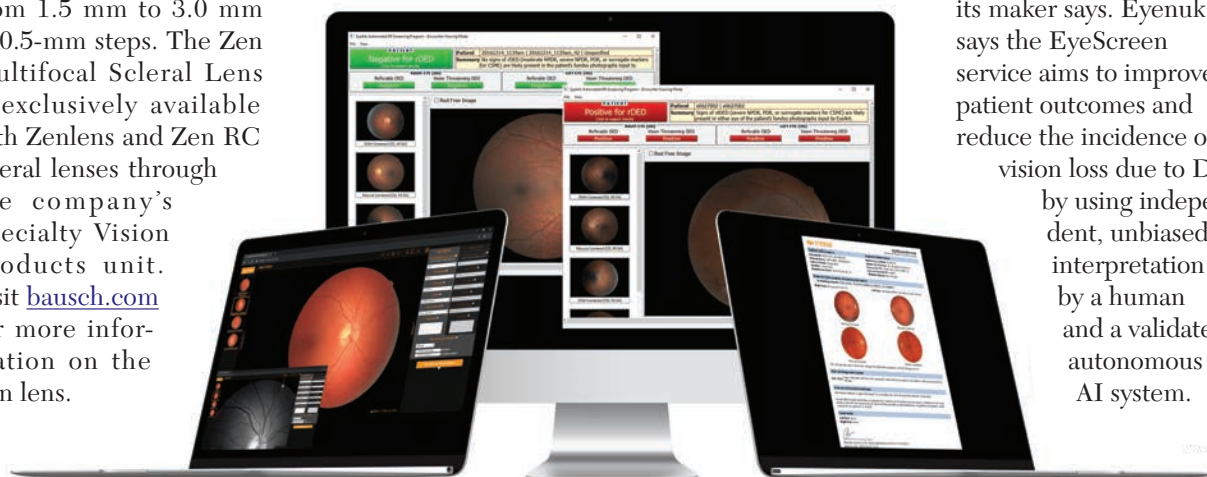Kala Pharmaceuticals says its new topical steroid, Inveltys, is a safe, effective, twice-daily option for postop pain and inflammation after ophthalmic surgery. To enhance penetration into target tissues, Inveltys uses Kala's proprietary Amplify drug-delivery technology, which increases drug delivery by facilitating penetration through tear film mucus. Visit [inveltys.com](http://inveltys.com) for more information.



## Zen Multifocal Scleral Lens

Bauch + Lomb recently released the Zen Multifocal scleral lens for patients with irregular corneas and ocular surface diseases. Eye-care professionals can now fit presbyopes, and those with conditions such as dry eye, says the company. The lenses incorporate decentered optics, which B+L says enable the near power to be positioned over the visual axis, giving patients clear vision over a wide range of distances. Zen Multifocal offers power ranges from +1 to +3.50 D, in 0.25-D steps. The lens design also has variable near zones

from 1.5 mm to 3.0 mm in 0.5-mm steps. The Zen Multifocal Scleral Lens is exclusively available with Zenlens and Zen RC scleral lenses through the company's Specialty Vision Products unit. Visit [bausch.com](http://bausch.com) for more information on the Zen lens.



Eyenuk's EyeScreen Human + AI Diagnostic Service combines artificial intelligence disease detection and human grading to screen for diabetic retinopathy.

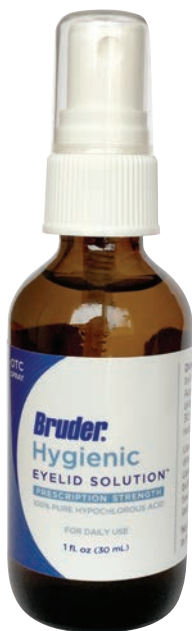its maker says. Eyenuk says the EyeScreen service aims to improve patient outcomes and reduce the incidence of vision loss due to DR by using independent, unbiased interpretation by a human and a validated autonomous AI system.

### Keep a Lid on MGD

Bruder says there's a new eyelid and lash solution available that can provide relief from dry eyes, styes and symptoms caused by blepharitis and meibomian gland dysfunction. Bruder Hygienic Eyelid Solution is a spray that can be applied to closed eyelids that cleans and soothes as it removes foreign material and debris on and around the eyelid margins.

The company says the hygienic spray is good for eyelid health and improves the hygiene of lids, lashes and the palpebral margin. The solution, which can be used daily, is an all-natural, hypoallergenic formula that contains no alcohol, oil, sulfates or parabens, the company says.

For more information, visit [bruder.com](http://bruder.com).



### NuLids for Dry Eye

Patients now have another option for treating dry eye at home with NuSight's recently launched NuLids. The device gently stimulates, "de-caps" and rejuvenates the meibomian glands to improve clinical symptoms and signs of dry eye, the company says. Most dry-eye patients have compromised meibomian gland function, which can result in an unstable tear film and subsequent premature breakdown of tears, says NuSight, adding that NuLids combats this by enhancing the production and flow of meibum. The company says the system is safe, effective and easy to use without any known side effects. Call 1 (833) 3NULIDS.

### AI Screening Tool

Eyenuk's EyeScreen Human + AI Diagnostic Service, a screening tool for diabetic retinopathy, is now available. Combining artificial intelligence disease detection and human grading, the service is designed to increase access to diabetic retinopathy screening, reduce wait times and improve patient compliance,



The company says this can connect primary- and diabetes-care clinics with eye-care specialists, allowing for quicker treatment of progressing DR. Go to [eyenuk.com](http://eyenuk.com) for more information.

### Next Generation OMNI

SightSciences has released its next generation OMNI trabeculotomy system. Commercially launched in 2018, the OMNI is a manually operated device that delivers small amounts of viscoelastic during viscodilation and cuts the trabecular meshwork tissue during trabeculotomy.

SightSciences says its recent modifications to the device have enhanced device preparation, aesthetics, handling and ergonomics. For more information, visit [sightsciences.com](http://sightsciences.com). **REVIEW**

Career Opportunities

**OPHTHALMOLOGISTS**

Danbury, CT

Ophthalmologists to share office with long standing Ophthalmologist in Danbury, CT. High quality equipment. \$2,250 per month or adjoining office without equipment- \$1,750 per month.

203-545-3539 or  
email [mehrimd@aol.com](mailto:mehrimd@aol.com)



**Do you have Products and Services for sale?**

CONTACT US TODAY  
FOR CLASSIFIED ADVERTISING  
Toll free: 888-498-1460  
E-mail: [sales@kerhgroup.com](mailto:sales@kerhgroup.com)



# Targeting Ophthalmologists?

**CLASSIFIED ADVERTISING WORKS**



Contact us today  
for classified advertising:  
Toll free: 888-498-1460  
E-mail: [sales@kerhgroup.com](mailto:sales@kerhgroup.com)



## 26<sup>TH</sup> ANNUAL **OPHTHALMIC** *Product Guide*

Innovative products to enhance your practice

The **future** is in your hands.  
One tap, many possibilities.

Experience the digital edition on your handheld device. Use your smart device to scan the code below or visit:

[www.reviewofophthalmology.com/publications/archive](http://www.reviewofophthalmology.com/publications/archive)



Download a QR scanner app. Launch app and hold your mobile device over the code to view  
[www.reviewofophthalmology.com/publications/archive](http://www.reviewofophthalmology.com/publications/archive).







A 68-year-old man presents to the Wills Eye Glaucoma Service with uncontrolled IOP in his left eye.

*Ranjodh S. Boparai, MD, and Michael J. Pro, MD*

## Presentation

A 68-year-old male presented to the Wills Eye Glaucoma Service with an elevated intraocular pressure in his left eye without any symptoms. He had previously undergone bilateral laser peripheral iridotomies and been diagnosed with mixed mechanism glaucoma in both eyes; he had undergone a trabeculectomy in the right eye. He had no history of ocular trauma, uveitis, infection with herpes simplex or zoster, or steroid use.

## Medical History

There was no past medical history. The past ocular history included lattice corneal dystrophy and cataract surgery in the right eye, in addition to mixed mechanism glaucoma, as noted above. Current medications were latanoprost 0.005% nightly and timolol 0.5% two times a day, in the left eye only. He was intolerant to brimonidine, brinzolamide, dorzolamide and bimatoprost. Family and social histories were non-contributory.

## Examination

On exam, visual acuity was 20/60 OD and 20/40 OS with no improvement on pinhole. Pupils and extraocular motility were normal. Intraocular pressures were 12 mmHg OD and 21 mmHg OS with central corneal thicknesses of 509 and 512  $\mu\text{m}$ , respectively. The angle was open on gonioscopy with a Spaeth classification of C35f, with light trabecular meshwork pigmentation OU. Confrontation visual fields were normal. Slit lamp examination revealed a diffuse, slightly elevated, mildly vascular bleb and a posterior chamber intraocular lens OD, and a nuclear sclerotic cataract OS. On fundus examination, the optic nerves showed a cup-to-disc ratio of 0.8 and 0.7 OD and OS, respectively, with superior notching OU. The remainder of the fundus exam was unremarkable.

***What is your diagnosis? What further workup would you pursue? The diagnosis appears on p. 72***

## Workup, Diagnosis and Treatment

Octopus visual fields showed dense inferior arcuate defects OU with evidence of progression OS (*Figure 1*). OCT of the retinal nerve fiber layer showed corresponding superior thinning OU. Given progression of his glaucoma in the left eye in the presence of maximally tolerated medical therapy, it was recommended that the patient have a surgical intervention to lower his IOP. He didn't want to undergo a trabeculectomy due to the complications he experienced OD, including pain, redness and a lengthy recovery. Since he had a visually significant cataract, minimally-invasive glaucoma surgery options were considered in conjunction with cataract surgery, and the patient de-

ecided to proceed with cataract surgery combined with a XEN Gel Stent (Allergan).

The patient underwent an uncomplicated surgery, and at his one-month postoperative visit, his IOP OS was 14 mmHg, and he was taken off all glaucoma medications. At his three-month visit, the IOP was stable. At six months, however, the IOP in his left eye had increased to 23 mmHg, with notable fibrosis over the XEN Gel Stent. He was restarted on latanoprost and timolol OS. He subsequently underwent surgical XEN revision (*Figure 2*). At his most recent follow-up visits, the IOP was in the low teens, he was off all drops and had stable defects on visual field testing.

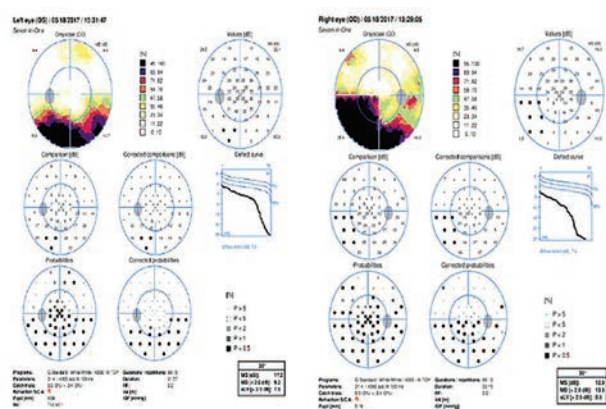


Figure 1. Octopus visual fields of the right and left eyes showing bilateral dense inferior arcuate defects.

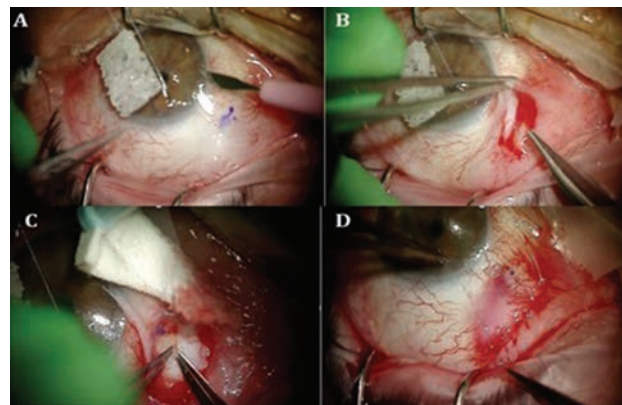


Figure 2. Representative images from the reoperation to revise the fibrotic XEN Gel Stent.

## Discussion

MIGS devices can be divided into: 1) trabecular, which increase outflow through Schlemm's canal; 2) suprachoroidal, which improve uveoscleral outflow via a connection between the anterior chamber and the suprachoroidal space; and 3) subconjunctival, which allow for an alternative pathway of aqueous flow to the subconjunctival space.<sup>1,2</sup> Multiple non-randomized studies show that MIGS devices have better safety profiles and faster recovery than traditional incisional glaucoma surgeries, likely due to reduced surgical trauma with minimal scleral and conjunctival dissection.<sup>3</sup>

The XEN Gel Stent is a subcon-

junctival MIGS device made with gelatin crosslinked with glutaraldehyde. The XEN has a length of 6 mm with an internal diameter of 45  $\mu\text{m}$  and an outer diameter of 150  $\mu\text{m}$ .<sup>4,5</sup> Multiple prospective and retrospective studies have assessed outcomes in patients with XEN implants.<sup>2,6-9</sup> The average IOP reduction after XEN placement ranges from 30 to 45 percent. Topical drop class reduction ranges from 85 to 95 percent, with 40 to 90 percent of patients off all drops.<sup>2,6-9</sup> In our patient, the IOP reduction at postoperative month one was 33 percent, which is similar to the reported literature.

Common complications after XEN

implantation include hypotony (9 to 35 percent), flat anterior chamber requiring refilling (5 to 10 percent), bleb needling (2 to 43 percent), and reoperation (3 to 15 percent).<sup>2,4,7-11</sup> Most cases of hypotony occur early in the postoperative period and resolve spontaneously with conservative management. Other less-common complications include corneal edema, choroidal folds, choroidal detachment, and device extrusion, migration or obstruction.<sup>2,4,7-11</sup> In our patient, XEN placement was complicated by fibrosis, likely leading to device obstruction, requiring surgical revision with a good eventual outcome. In comparison to other MIGS

devices, including iStent and iStent Inject (Glaukos), Hydrus (Ivantis), InnFocus MicroShunt (Santen Pharmaceutical Company) and the recently withdrawn Cy-Pass (Alcon), the XEN carries a comparable IOP lowering effect and topical drop reduction, with a slightly higher needling rate but comparable rate of reoperation.<sup>1,3,12-14</sup> In comparison to trabeculectomy, XEN has a better side-effect profile, while approaching a similar IOP-lowering efficacy.<sup>15</sup>

In conclusion, MIGS devices have become an increasingly utilized alternative to traditional incisional glaucoma surgeries, especially in conjunction with cataract surgery or in the setting of glaucoma progression on maximum medical therapy. MIGS selection is key to achieving the desired target IOP, with disease severity and mechanism of glaucoma as two important factors. Although their safety profile is markedly better than trabeculectomy or tube shunt surgery, MIGS devices aren't without complications, as demonstrated in our patient. Nevertheless, MIGS represents an exciting innovation in the field of glaucoma and a potential pathway towards safer, yet still effective, surgeries. **REVIEW**

*The authors have no financial interest in any products discussed in the case.*

1. Kerr NM, Wang J, Barton K. Minimally invasive glaucoma surgery as primary stand-alone surgery for glaucoma. *Clin Experiment Ophthalmol* 2017;45:4:393-400.
2. Schlenker MB, Gulamhusein H, Conrad-Hengerer I, et al. Efficacy, safety, and risk factors for failure of stand-alone ab interno gelatin microstent implantation versus stand-alone trabeculectomy. *Ophthalmology* 2017;124:11:1579-1588.
3. Chen DZ, Sng CCA. Safety and efficacy of microinvasive glaucoma surgery. *J Ophthalmol* 2017;2017:3182935.
4. Chaudhary A, Salinas L, Guidotti J, Mermoud A, Mansouri K. XEN Gel Implant: A new surgical approach in glaucoma. *Expert Rev Med Devices* 2018;15:1:47-59.
5. De Gregorio A, Pedrotti E, Stevan G, Bertinello A, Morselli S. XEN glaucoma treatment system in the management of refractory glaucomas: A short review on trial data and potential role in clinical practice. *Clin Ophthalmol* 2018;12:773-782.
6. Hohberger B, Welge-Lüssen UC, Lammer R. MIGS: Therapeutic success of combined XEN Gel Stent implantation with cataract surgery. *Graefes Arch Clin Exp Ophthalmol* 2018;256:3:621-625.
7. De Gregorio A, Pedrotti E, Russo L, Morselli S. Minimally invasive combined glaucoma and cataract surgery: Clinical results of the smallest ab interno gel stent. *International ophthalmology* 2018;38:3:1129-1134.
8. Galal A, Bilgic A, Eltanamly R, Osman A. XEN glaucoma implant with mitomycin C 1-year follow-up: Result and complications. *J Ophthalmol* 2017;2017:5457246.
9. Grover DS, Flynn WJ, Bashford KP, et al. Performance and safety of a new ab interno gelatin stent in refractory glaucoma at 12 months. *Amer J Ophthalmol* 2017;183:25-36.
10. Olate-Perez A, Perez-Torregrosa VT, Gargallo-Benedicto A, et al. Prospective study of filtering blebs after XEN45 surgery. *Archivos de la Sociedad Espanola de Oftalmologia* 2017;92:8:366-371.
11. Perez-Torregrosa VT, Olate-Perez A, Cerda-Ibanez M, et al. Combined phacoemulsification and XEN45 surgery from a temporal approach and two incisions. *Archivos de la Sociedad Espanola de Oftalmologia* 2016;91:9:415-421.
12. Agrawal P, Bradshaw SE. Systematic literature review of clinical and economic outcomes of micro-invasive glaucoma surgery (MIGS) in primary open-angle glaucoma. *Ophthalmology and Therapy* 2018;7:1:49-73.
13. Ansari E. An update on implants for minimally invasive glaucoma surgery (MIGS). *Ophthalmology and Therapy* 2017;6:2:233-241.
14. Yook E, Vinod K, Panarelli JF. Complications of micro-invasive glaucoma surgery. *Curr Opin Ophthalmol* 2018;29:2:147-154.
15. Gedde SJ, Herndon LW, Brandt JD, et al. Postoperative complications in the Tube Versus Trabeculectomy (TVT) study during five years of follow-up. *Amer J Ophthalmol* 2012;153:5:804-814 e801.

<b>Akorn Consumer Health</b>	<b>49</b>
Phone	(800) 579-8327
	www.akornconsumerhealth.com
<b>Alcon Laboratories</b>	<b>2</b>
Phone	(800) 451-3937
Fax	(817) 551-4352
<b>Bausch + Lomb</b>	<b>7, 8, 39</b>
Phone	(800) 323-0000
Fax	(813) 975-7762
<b>EyeVance Pharmaceuticals</b>	<b>5, 45</b>
Phone	(817) 677-6120
	eyeavance.com
<b>Focus Laboratories, Inc.</b>	<b>31</b>
Phone	(866) 752-6006
Fax	(501) 753-6021
	www.focuslaboratories.com
<b>Glaukos</b>	<b>11</b>
Phone	(800) 452-8567
	www.glaukos.com
<b>Imprimis Pharmaceuticals, Inc.</b>	<b>29</b>
Phone	(858) 704-4040
Fax	(858) 345-1745
	www.imprimispharma.com
<b>Ivantis, Inc.</b>	<b>19, 20</b>
	info@ivantisinc.com
	www.ivantisinc.com
<b>Keeler Instruments</b>	<b>15</b>
Phone	(800) 523-5620
Fax	(610) 353-7814
<b>Lacrimedics, Inc</b>	<b>41</b>
Phone	(800) 367-8327
Fax	(253) 964-2699
	info@lacrimedics.com
	www.lacrimedics.com
<b>Lombart Instruments</b>	<b>33</b>
Phone	(800) 446-8092
Fax	(757) 855-1232
<b>NuSight Medical Operations</b>	<b>51</b>
Phone	(833) 468-5437
	www.NuSightMedical.com
<b>Reichert Technologies</b>	<b>22-23</b>
Phone	(888) 849-8955
Fax	(716) 686-4545
	www.reichert.com
<b>S4OPTIK</b>	<b>55, 57</b>
Phone	(888) 224-6012
<b>Santen Inc. USA</b>	<b>17</b>
Phone	(415) 268-9100
Fax	(510) 655-5682
	www.santeninc.com
<b>Shire Ophthalmics</b>	<b>75, 76</b>
	www.shire.com

*This advertiser index is published as a convenience and not as part of the advertising contract. Every care will be taken to index correctly. No allowance will be made for errors due to spelling, incorrect page number, or failure to insert.*





# THE RICK BAY FOUNDATION

*for Excellence in Eyecare Education*

[www.rickbayfoundation.org](http://www.rickbayfoundation.org)

*Support the Education of Future Healthcare & Eyecare Professionals*



## **About Rick**

Rick Bay served as the publisher of *The Review* Group for more than 20 years.



To those who worked for him, he was a leader whose essence was based in a fierce and boundless loyalty.


To those in the industry and the professions he served, he will be remembered for his unique array of skills and for his dedication to exceeding the expectations of his customers, making many of them fast friends.

Scholarships are awarded to advance the education of students in both **Optometry** and **Ophthalmology**, and are chosen by their school based on qualities that embody Rick's commitment to the profession, including integrity, compassion, partnership and dedication to the greater good.

**Interested in being a partner with us?**

Visit [www.rickbayfoundation.org](http://www.rickbayfoundation.org)

*(Contributions are tax-deductible in accordance with section 170 of the Internal Revenue Code.)*



**THE RICK BAY FOUNDATION®**  
*for Excellence in Eyecare Education*

*(The Rick Bay Foundation for Excellence in Eyecare Education is a nonprofit, tax-exempt organization under section 501(c)(3) of the Internal Revenue Code.)*



## BRIEF SUMMARY:

Consult the Full Prescribing Information for complete product information.

## INDICATIONS AND USAGE

Xiidra® (lifitegrast ophthalmic solution) 5% is indicated for the treatment of the signs and symptoms of dry eye disease (DED).

## DOSAGE AND ADMINISTRATION

Instill one drop of Xiidra twice daily (approximately 12 hours apart) into each eye using a single-use container. Discard the single-use container immediately after using in each eye. Contact lenses should be removed prior to the administration of Xiidra and may be reinserted 15 minutes following administration.

## CONTRAINDICATIONS

Xiidra is contraindicated in patients with known hypersensitivity to lifitegrast or to any of the other ingredients in the formulation.

## ADVERSE REACTIONS

### Clinical Trials Experience

Because clinical studies are conducted under widely varying conditions, adverse reaction rates observed in clinical studies of a drug cannot be directly compared to rates in the clinical trials of another drug and may not reflect the rates observed in practice. In five clinical studies of dry eye disease conducted with lifitegrast ophthalmic solution, 1401 patients received at least 1 dose of lifitegrast (1287 of which received lifitegrast 5%). The majority of patients (84%) had  $\leq 3$  months of treatment exposure. 170 patients were exposed to lifitegrast for approximately 12 months. The majority of the treated patients were female (77%). The most common adverse reactions reported in 5-25 % of patients were instillation site irritation, dysgeusia and reduced visual acuity. Other adverse reactions reported in 1% to 5% of the patients were blurred vision, conjunctival hyperemia, eye irritation, headache, increased lacrimation, eye discharge, eye discomfort, eye pruritus and sinusitis.

### Postmarketing Experience

The following adverse reactions have been identified during postapproval use of Xiidra. Because these reactions are reported voluntarily from a population of uncertain size, it is not always possible to reliably estimate their frequency or establish a causal relationship to drug exposure.

Rare cases of hypersensitivity, including anaphylactic reaction, bronchospasm, respiratory distress, pharyngeal edema, swollen tongue, and urticaria have been reported. Eye swelling and rash have been reported.

## USE IN SPECIFIC POPULATIONS

### Pregnancy

There are no available data on Xiidra use in pregnant women to inform any drug associated risks. Intravenous (IV) administration of lifitegrast to pregnant rats, from pre-mating through gestation day 17, did not produce teratogenicity at clinically relevant systemic exposures. Intravenous administration of lifitegrast to pregnant rabbits during organogenesis produced an increased incidence of omphalocele at the lowest dose

tested, 3 mg/kg/day (400-fold the human plasma exposure at the recommended human ophthalmic dose [RHOD], based on the area under the curve [AUC] level). Since human systemic exposure to lifitegrast following ocular administration of Xiidra at the RHOD is low, the applicability of animal findings to the risk of Xiidra use in humans during pregnancy is unclear.

### Animal Data

Lifitegrast administered daily by intravenous (IV) injection to rats, from pre-mating through gestation day 17, caused an increase in mean preimplantation loss and an increased incidence of several minor skeletal anomalies at 30 mg /kg /day, representing 5,400-fold the human plasma exposure at the RHOD of Xiidra, based on AUC. No teratogenicity was observed in the rat at 10 mg /kg /day (460-fold the human plasma exposure at the RHOD, based on AUC ). In the rabbit, an increased incidence of omphalocele was observed at the lowest dose tested, 3 mg /kg /day (400-fold the human plasma exposure at the RHOD, based on AUC), when administered by IV injection daily from gestation days 7 through 19. A fetal No Observed Adverse Effect Level (NOAEL) was not identified in the rabbit.

### Lactation

There are no data on the presence of lifitegrast in human milk, the effects on the breastfed infant, or the effects on milk production. However, systemic exposure to lifitegrast from ocular administration is low. The developmental and health benefits of breastfeeding should be considered, along with the mother's clinical need for Xiidra and any potential adverse effects on the breastfed child from Xiidra.

### Pediatric Use

Safety and efficacy in pediatric patients below the age of 17 years have not been established.

### Geriatric Use

No overall differences in safety or effectiveness have been observed between elderly and younger adult patients.

## NONCLINICAL TOXICOLOGY

### Carcinogenesis, Mutagenesis, Impairment of Fertility

*Carcinogenesis:* Animal studies have not been conducted to determine the carcinogenic potential of lifitegrast.

*Mutagenesis:* Lifitegrast was not mutagenic in the *in vitro* Ames assay. Lifitegrast was not clastogenic in the *in vivo* mouse micronucleus assay. In an *in vitro* chromosomal aberration assay using mammalian cells (Chinese hamster ovary cells), lifitegrast was positive at the highest concentration tested, without metabolic activation.

*Impairment of fertility:* Lifitegrast administered at intravenous (IV) doses of up to 30 mg/kg/day (5400-fold the human plasma exposure at the recommended human ophthalmic dose (RHOD) of lifitegrast ophthalmic solution, 5%) had no effect on fertility and reproductive performance in male and female treated rats.



Manufactured for: Shire US Inc., 300 Shire Way, Lexington, MA 02421. For more information, go to [www.Xiidra.com](http://www.Xiidra.com) or call 1-800-828-2088. Marks designated ® and ™ are owned by Shire or an affiliated company. ©2018 Shire US Inc. SHIRE and the Shire Logo are trademarks or registered trademarks of Shire Pharmaceutical Holdings Ireland Limited or its affiliates. Patented: please see <https://www.shire.com/legal-notice/product-patents> Last Modified: 01/2018 S33769



# THERE'S NO SWIITCHING THIS

Xiidra is the only lymphocyte function-associated antigen-1 (LFA-1) antagonist treatment for Dry Eye Disease<sup>1,2</sup>

Xiidra, the first in a class of LFA-1 antagonists for Dry Eye Disease, is a prescription eye drop FDA-approved to treat both signs and symptoms of the disease.<sup>1,3</sup>

There's no substitute.<sup>2,4</sup>  
Check out patient resources, insurance coverage, and more at **Xiidra-ECP.com**

**References:**

1. Xiidra [Prescribing Information]. Lexington, MA: Shire US.
2. TFOS DEWS II Research Subcommittee. Report of the Research Subcommittee of the Tear Film & Ocular Surface Society Dry Eye WorkShop II (2017). *Ocul Surf.* 2017;15(3):269-649.
3. FDA approves new medication for dry eye disease. FDA News Release. July 2016. <http://www.fda.gov/newsevents/newsroom/pressannouncements/ucm510720.htm>. Accessed July 12, 2016.
4. Food and Drug Administration. Electronic Orange Book. <http://www.fda.gov/downloads/Drugs/DevelopmentApprovalProcess/UCM071436.pdf>. Accessed June 26, 2018.

**Indication**

Xiidra® (lifitegrast ophthalmic solution) 5% is indicated for the treatment of signs and symptoms of dry eye disease (DED).

**Important Safety Information**

Xiidra is contraindicated in patients with known hypersensitivity to lifitegrast or to any of the other ingredients.

In clinical trials, the most common adverse reactions reported in 5-25% of patients were instillation site irritation, dysgeusia and reduced visual acuity. Other adverse reactions reported in 1% to 5% of the patients were blurred vision, conjunctival hyperemia, eye irritation, headache, increased lacrimation, eye discharge, eye discomfort, eye pruritus and sinusitis.

To avoid the potential for eye injury or contamination of the solution, patients should not touch the tip of the single-use container to their eye or to any surface.

Contact lenses should be removed prior to the administration of Xiidra and may be reinserted 15 minutes following administration.

Safety and efficacy in pediatric patients below the age of 17 years have not been established.

For additional safety information, see accompanying Brief Summary of Safety Information on the adjacent page and Full Prescribing Information on Xiidra-ECP.com.

