

REVIEW[®] of OPHTHALMOLOGY

July 2023 • reviewofophthalmology.com

Clinical advice you can trust

PLASTICS POINTERS

Treatment for Facial Nerve Palsy
PAGE 13

REFRACTIVE/CATARACT RUNDOWN

Cataract Surgery in Fuchs' Patients
PAGE 21

GLAUCOMA MANAGEMENT

Angle-recession Glaucoma Revisited
PAGE 51

The Recipe for Successful Refractive Surgery

iCare **EIDON** Family

Ultra-Widefield covering 200°



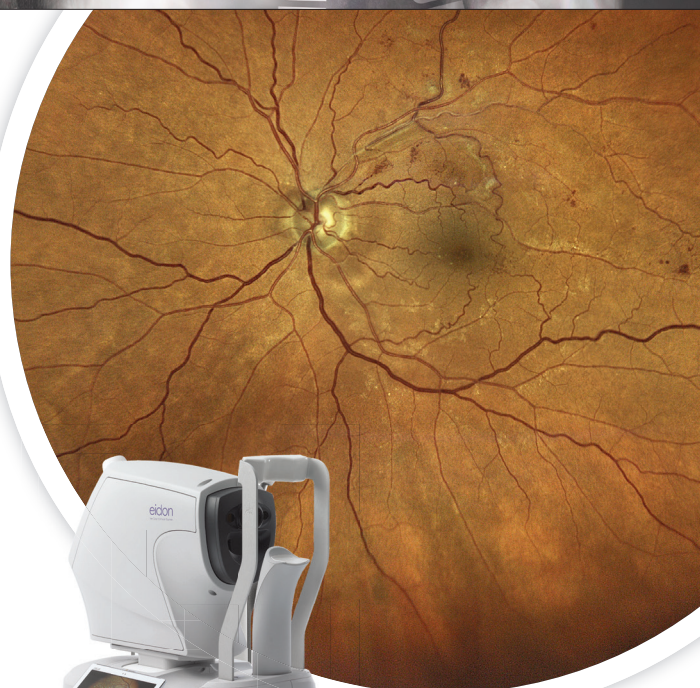Using white LED light provides TrueColor detail rich retinal images from the macula to the periphery



Confocal Technology allows scanning through media opacities resulting in high resolution images through pupils as small as 2.5 mm



Easy-to-use family of products with advanced features and multiple imaging modalities



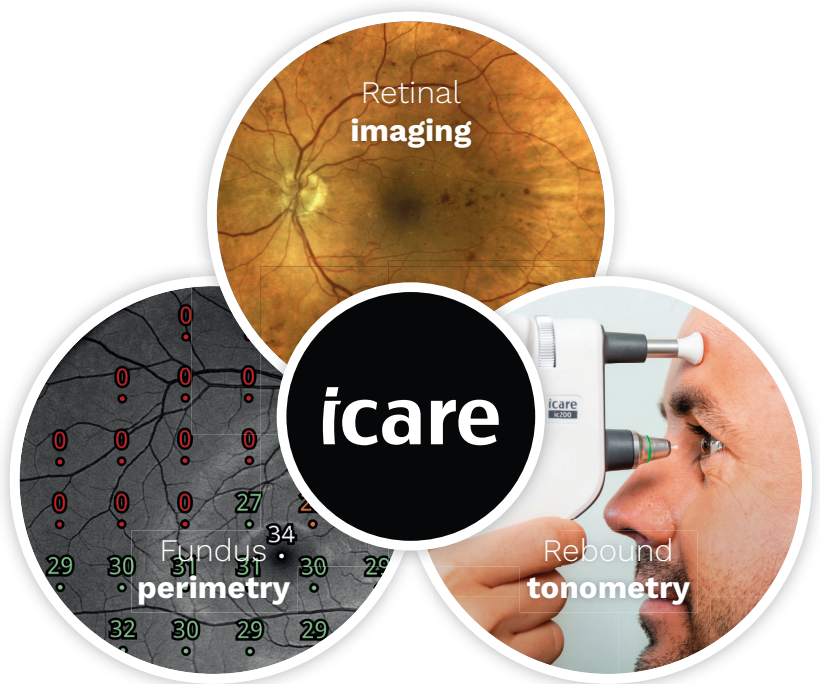
Discover the next level of eye care
with our full line of devices.

Scan or visit www.icare-world.com/USA

icare
For better perception

**You know us
for tonometry.**

**Get to know
iCare for
imaging and
perimetry.**



Discover the next level of eye care
with our full line of devices.

Scan or visit www.icare-world.com/USA



Wills Eye Resident Series: A child with an intraocular mass presents at Wills Eye, p. 63

REVIEW[®] of OPHTHALMOLOGY

July 2023 • reviewofophthalmology.com

Clinical advice you can trust

PLASTICS POINTERS

Treatment for Facial Nerve Palsy
PAGE 13

REFRACTIVE/CATARACT RUNDOWN

Cataract Surgery in Fuchs' Patients
PAGE 21

GLAUCOMA MANAGEMENT

Angle-recession Glaucoma Revisited
PAGE 51

The Recipe for Successful Refractive Surgery

How refractive surgeons identify the proper
candidates for LVC procedures. P. 25

Also inside

- How to Make Phaco More Efficient P. 33
- The Latest Techniques and Tech for DMEK and DSAEK P. 39
- The Impact of DRCR Protocol Studies P. 42
- Managing Acanthamoeba and Other Infections P. 48

Start with the power of 2

VABYSMO™ (faricimab-svoa) is the only treatment that delivers powerful **first-line efficacy** with **1–4 month dosing**^{1-5*†}

*Primary endpoint of non-inferiority vs aflibercept was defined as the mean change from baseline in BCVA (measured by the ETDRS letter score) to 1 year (average of weeks 40, 44, and 48 in nAMD and weeks 48, 52, and 56 in DME) and was tested for non-inferiority using a margin of 4 letters.¹

†After 4 or 6 monthly loading doses.¹
Please see below for more information.

²Verana Health data from Q1–Q4 2022.²

Discover 2 years of DME data at vabysmo-hcp.com/start

Fastest-growing treatment for nAMD and DME^{6†}



Image not intended to be a patient portrayal.

VABYSMO
faricimab-svoa injection 6 mg

†Dosing Information:

DME dosing: at least 4 monthly loading doses followed by extensions ≤ 4 weeks or reductions ≤ 8 weeks based on OCT and visual acuity evaluations OR 6 monthly loading doses followed by Q8W. Q4W dosing may be needed (no added benefit). nAMD dosing: 4 monthly loading doses followed by OCT and visual acuity evaluations 8 and 12 weeks later to inform Q16W (weeks 28 and 44), Q12W (weeks 24, 36, and 48), Q8W (weeks 20, 28, 36, and 44), or Q4W (no added benefit) dosing.¹

INDICATIONS

VABYSMO (faricimab-svoa) is a vascular endothelial growth factor (VEGF) inhibitor and angiopoietin-2 (Ang-2) inhibitor indicated for the treatment of patients with Neovascular (Wet) Age-Related Macular Degeneration (nAMD) and Diabetic Macular Edema (DME).

IMPORTANT SAFETY INFORMATION

Contraindications

VABYSMO is contraindicated in patients with ocular or periocular infection, in patients with active intraocular inflammation, and in patients with known hypersensitivity to faricimab or any of the excipients in VABYSMO. Hypersensitivity reactions may manifest as rash, pruritus, urticaria, erythema, or severe intraocular inflammation.

Warnings and Precautions

Endophthalmitis and Retinal Detachments

Intravitreal injections have been associated with endophthalmitis and retinal detachments. Proper aseptic injection techniques must always be used when administering VABYSMO. Patients should be instructed to report any symptoms suggestive of endophthalmitis or retinal detachment without delay, to permit prompt and appropriate management.

Increase in Intraocular Pressure

Transient increases in intraocular pressure (IOP) have been seen within 60 minutes of intravitreal injection, including with VABYSMO. IOP and the perfusion of the optic nerve head should be monitored and managed appropriately.

Thromboembolic Events

Although there was a low rate of arterial thromboembolic events (ATEs) observed in the VABYSMO clinical trials, there is a potential risk of ATEs following intravitreal use of VEGF inhibitors. ATEs are defined as nonfatal stroke, nonfatal myocardial infarction, or vascular death (including deaths of unknown cause).

The incidence of reported ATEs in the nAMD studies during the first year was 1% (7 out of 664) in patients treated with VABYSMO compared with 1% (6 out of 662) in patients treated with aflibercept.

The incidence of reported ATEs in the DME studies from baseline to week 100 was 5% (64 out of 1,262) in patients treated with VABYSMO compared with 5% (32 out of 625) in patients treated with aflibercept.

Adverse Reactions

The most common adverse reactions ($\geq 5\%$) reported in patients receiving VABYSMO were cataract (15%) and conjunctival hemorrhage (8%).

Pregnancy, Lactation, Females and Males of Reproductive Potential

Based on the mechanism of action of VEGF and Ang-2 inhibitors, there is a potential risk to female reproductive capacity, and to embryo-fetal development. VABYSMO should not be used during pregnancy unless the potential benefit to the patient outweighs the potential risk to the fetus. The developmental and health benefits of breastfeeding should be considered along with the mother's clinical need for VABYSMO and any potential adverse effects on the breastfed child from VABYSMO. Females of reproductive potential are advised to use effective contraception prior to the initial dose, during treatment and for at least 3 months following the last dose of VABYSMO.

You may report side effects to the FDA at (800) FDA-1088 or www.fda.gov/medwatch. You may also report side effects to Genentech at (888) 835-2555.

Please see Brief Summary of full VABYSMO Prescribing Information on the following page.

References: 1. VABYSMO [package insert]. South San Francisco, CA: Genentech, Inc; 2023. 2. Beovu® (brolucizumab-dbl) injection [package insert]. East Hanover, NJ: Novartis Pharmaceuticals Corp; 2022. 3. Eylea® (aflibercept) [package insert]. Tarrytown, NY: Regeneron Pharmaceuticals, Inc; 2022. 4. LUCENTIS® (ranibizumab) [package insert]. South San Francisco, CA: Genentech, Inc; 2018. 5. SUSVIMO™ (ranibizumab injection) [package insert]. South San Francisco, CA: Genentech, Inc; 2022. 6. Data on file. South San Francisco, CA: Genentech, Inc.

BCVA=best corrected visual acuity; ETDRS=Early Treatment Diabetic Retinopathy Study; OCT=optical coherence tomography; Q4W=every 4 weeks; Q8W=every 8 weeks; Q12W=every 12 weeks; Q16W=every 16 weeks.

Genentech
A Member of the Roche Group

THE WINDOW
TO CHANGE

VABYSMO is a registered trademark of Genentech, Inc., and the VABYSMO logo is a trademark of Genentech, Inc. ©2023 Genentech, Inc.; 1 DNA Way, South San Francisco, CA 94080-4990. All rights reserved. M-US-00018679(v1.0) 02/23

VABYSMO[™] (faricimab-svoa) injection, for intravitreal use

This is a brief summary. Before prescribing, please refer to the full Prescribing Information

1 INDICATIONS AND USAGE

VABYSMO is a vascular endothelial growth factor (VEGF) and angiopoietin 2 (Ang-2) inhibitor indicated for the treatment of patients with:

1.1 Neovascular (wet) Age-Related Macular Degeneration (nAMD)
1.2 Diabetic Macular Edema (DME)
4 CONTRAINDICATIONS
4.1 Ocular or Periocular Infections

VABYSMO is contraindicated in patients with ocular or periocular infections.

4.2 Active Intraocular Inflammation

VABYSMO is contraindicated in patients with active intraocular inflammation.

4.3 Hypersensitivity

VABYSMO is contraindicated in patients with known hypersensitivity to faricimab or any of the excipients in VABYSMO. Hypersensitivity reactions may manifest as rash, pruritus, urticaria, erythema, or severe intraocular inflammation.

5 WARNINGS AND PRECAUTIONS
5.1 Endophthalmitis and Retinal Detachments

 Intravitreal injections have been associated with endophthalmitis and retinal detachments [see *Adverse Reactions* (6.1)]. Proper aseptic injection techniques must always be used when administering VABYSMO. Patients should be instructed to report any symptoms suggestive of endophthalmitis or retinal detachment without delay, to permit prompt and appropriate management [see *Dosage and Administration* (2.6) and *Patient Counseling Information* (17)].

5.2 Increase in Intraocular Pressure

 Transient increases in intraocular pressure (IOP) have been seen within 60 minutes of intravitreal injection, including with VABYSMO [see *Adverse Reactions* (6.1)]. IOP and the perfusion of the optic nerve head should be monitored and managed appropriately [see *Dosage and Administration* (2.6)].

5.3 Thromboembolic Events

Although there was a low rate of arterial thromboembolic events (ATEs) observed in the VABYSMO clinical trials, there is a potential risk of ATEs following intravitreal use of VEGF inhibitors. ATEs are defined as nonfatal stroke, nonfatal myocardial infarction, or vascular death (including deaths of unknown cause).

 The incidence of reported ATEs in the nAMD studies during the first year was 1% (7 out of 664) in patients treated with VABYSMO compared with 1% (6 out of 662) in patients treated with aflibercept [see *Clinical Studies* (14.1)].

 The incidence of reported ATEs in the DME studies from baseline to week 100 was 5% (64 out of 1,262) in patients treated with VABYSMO compared with 5% (32 out of 625) in patients treated with aflibercept [see *Clinical Studies* (14.2)].

6 ADVERSE REACTIONS

The following potentially serious adverse reactions are described elsewhere in the labeling:

- Hypersensitivity [see *Contraindications* (4)]
- Endophthalmitis and retinal detachments [see *Warnings and Precautions* (5.1)]
- Increase in intraocular pressure [see *Warnings and Precautions* (5.2)]
- Thromboembolic events [see *Warnings and Precautions* (5.3)]

6.1 Clinical Trial Experience

Because clinical trials are conducted under widely varying conditions, adverse reaction rates observed in the clinical trials of a drug cannot be directly compared to rates in other clinical trials of the same or another drug and may not reflect the rates observed in practice.

 The data described below reflect exposure to VABYSMO in 1,926 patients, which constituted the safety population in four Phase 3 studies [see *Clinical Studies* (14.1, 14.2)].

Table 1: Common Adverse Reactions (≥ 1%)

Adverse Reactions	VABYSMO		Active Control (aflibercept)	
	AMD N=664	DME N=1,262	AMD N=662	DME N=625
Cataract	3%	15%	2%	12%
Conjunctival hemorrhage	7%	8%	8%	7%
Vitreous floaters	3%	4%	2%	3%
Retinal pigment epithelial tear ^a	3%		1%	
Intraocular pressure increased	3%	4%	2%	3%
Eye pain	3%	3%	3%	3%
Intraocular inflammation ^b	2%	1%	1%	1%
Eye irritation	1%	< 1%	< 1%	1%
Lacrimation increased	1%	1%	1%	< 1%
Ocular discomfort	1%	1%	< 1%	< 1%

^aAMD only
^bIncluding iridocyclitis, iritis, uveitis, vitritis

Less common adverse reactions reported in < 1% of the patients treated with VABYSMO were corneal abrasion, eye pruritus, ocular hyperemia, blurred vision, sensation of foreign body, endophthalmitis, conjunctival hyperemia, visual acuity reduced, visual acuity reduced transiently, vitreous hemorrhage, retinal tear and rhegmatogenous retinal detachment.

6.2 Immunogenicity

The immunogenicity of VABYSMO was evaluated in plasma samples. The immunogenicity data reflect the percentage of patients whose test results were considered positive for antibodies to VABYSMO in immunoassays. The detection of an immune response is highly dependent on the sensitivity and specificity of the assays used, sample handling, timing of sample collection, concomitant medications, and underlying disease. For these reasons, comparison of the incidence of antibodies to VABYSMO with the incidence of antibodies to other products may be misleading.

There is a potential for an immune response in patients treated with VABYSMO. In the nAMD and DME studies, the pre-treatment incidence of anti-faricimab antibodies was approximately 1.8% and 0.8%, respectively. After initiation of dosing, anti-faricimab antibodies were detected in approximately 10.4% and 8.4% of patients with nAMD and DME respectively, treated with VABYSMO across studies and across treatment groups. As with all therapeutic proteins, there is a potential for immunogenicity with VABYSMO.

8 USE IN SPECIFIC POPULATIONS
8.1 Pregnancy
Risk Summary

There are no adequate and well-controlled studies of VABYSMO administration in pregnant women.

 Administration of VABYSMO to pregnant monkeys throughout the period of organogenesis resulted in an increased incidence of abortions at intravenous (IV) doses 158 times the human exposure (based on C_{max}) of the maximum recommended human dose [see *Animal Data*]. Based on the mechanism of action of VEGF and Ang-2 inhibitors, there is a potential risk to female reproductive capacity, and to embryo-fetal development. VABYSMO should not be used during pregnancy unless the potential benefit to the patient outweighs the potential risk to the fetus.

All pregnancies have a background risk of birth defect, loss, and other adverse outcomes. The background risk of major birth defects and miscarriage for the indicated population is unknown. In the U.S. general population, the estimated background risk of major birth defects is 2%-4% and of miscarriage is 15%-20% of clinically recognized pregnancies.

Data
Animal Data

 An embryo fetal developmental toxicity study was performed on pregnant cynomolgus monkeys. Pregnant animals received 5 weekly IV injections of VABYSMO starting on day 20 of gestation at 1 or 3 mg/kg. A non-dose dependent increase in pregnancy loss (abortions) was observed at both doses evaluated. Serum exposure (C_{max}) in pregnant monkeys at the low dose of 1 mg/kg was 158 times the human exposure at the maximum recommended intravitreal dose of 6 mg once every 4 weeks. A no observed adverse effect level (NOAEL) was not identified in this study.

8.2 Lactation
Risk Summary

There is no information regarding the presence of faricimab in human milk, the effects of the drug on the breastfed infant, or the effects of the drug on milk production. Many drugs are transferred in human milk with the potential for absorption and adverse reactions in the breastfed child.

The developmental and health benefits of breastfeeding should be considered along with the mother's clinical need for VABYSMO and any potential adverse effects on the breastfed child from VABYSMO.

8.3 Females and Males of Reproductive Potential
Contraception

Females of reproductive potential are advised to use effective contraception prior to the initial dose, during treatment and for at least 3 months following the last dose of VABYSMO.

Infertility

No studies on the effects of faricimab on human fertility have been conducted and it is not known whether faricimab can affect reproduction capacity. Based on the mechanism of action, treatment with VABYSMO may pose a risk to reproductive capacity.

8.4 Pediatric Use

The safety and efficacy of VABYSMO in pediatric patients have not been established.

8.5 Geriatric Use

In the four clinical studies, approximately 60% (1,149/1,929) of patients randomized to treatment with VABYSMO were ≥ 65 years of age. No significant differences in efficacy or safety of faricimab were seen with increasing age in these studies. No dose adjustment is required in patients 65 years and above.

17 PATIENT COUNSELING INFORMATION

 Advise patients that in the days following VABYSMO administration, patients are at risk of developing endophthalmitis. If the eye becomes red, sensitive to light, painful, or develops a change in vision, advise the patient to seek immediate care from an ophthalmologist [see *Warnings and Precautions* (5)].

 Patients may experience temporary visual disturbances after an intravitreal injection with VABYSMO and the associated eye examinations [see *Adverse Reactions* (6)]. Advise patients not to drive or use machinery until visual function has recovered sufficiently.

 VABYSMO[™] [faricimab-svoa]

Manufactured by:

Genentech, Inc.

A Member of the Roche Group

1 DNA Way

South San Francisco, CA 94080-4990

U.S. License No.: 1048

VABYSMO is a trademark of Genentech, Inc.

©2023 Genentech, Inc.

M-US-00013249(v2.0) 2/23

Delphi Panel on Making Premium IOL Recommendations

The European School for Advanced Studies in Ophthalmology recently conducted a study to inform surgeons about presbyopic IOLs.¹ Vito Romano, MD, cornea specialist at University of Brescia, Italy, coordinated the study. “This study was planned because the multifocal IOL market isn’t equally distributed in Europe,” he says. “There are many more surgeons that can plant multifocal IOLs in Spain compared to all the other European countries.”

ESASO’s steering committee sectioned 105 items into four sections: preoperative; intraoperative; postoperative; and IOL selection. “[The committee] took 10 experts throughout Europe, put them all together, and did a Delphi consensus,” says Prof. Romano. “We chose the experts geographically with publication experience, and we asked them to review questions about complications, or complaints, when implanting a presbyopic IOL. We reached a consensus with about 70 percent of them.”

Preoperative considerations included 68 items, and consensus was achieved in 48 of them (70.6 percent). Consensus was reached in 10 out of the 14 intraoperative issues (71.9 percent) and in 10 out of the 13 postoperative considerations (76.9 percent).

Preoperatively, a patient’s age, habits, work type and motivations were all considered important

when recommending a presbyopic IOL. Experts considered age as an important factor, but they didn’t determine an age-range for this study. Researchers noted that age should be balanced with other preoperative aspects, such as the patient’s ocular health.

The steering committee considered variables in the study related to preoperative contraindications. Out of the possible choices, four were agreed upon as contraindications: previous uveitis; previous squint (strabismus) surgery; epiretinal membrane; and previous ocular surgery. There wasn’t an agreement on whether these represented an absolute or relative contraindication.

The experts agreed that the potential postoperative visual acuity is crucial in deciding the type of presbyopic IOL. They noted that patients with a potential postop corrected distance visual acuity less than 0.5 (20/40 Snellen) should consider extended-depth-of-focus IOLs or non-diffractive IOL designs. Those expected to emerge postop with better than 0.5 may benefit from a multifocal lens.

Recommending presbyopic IOLs achieved consensus in categories of refraction, keratometry and IOL power, but axial length saw discrepancy among the panel. Keratometry between 40 to 45 D and IOL power between 10 and 27 D were considered most suitable for a presbyopic IOL. Researchers suggest any eyes

outside these diopter ranges should be managed with caution. Despite axial length discrepancies, agreement on IOL power reveals that short and long eyes should be managed with care.

Pupil size was also considered important, with both small and large pupils potentially causing more risks. Accordingly, the panel of experts agreed that an optimal range of pupil diameter for presbyopic IOLs is larger than 2.8 mm under photopic conditions and smaller than 6 mm under scotopic conditions.

Seven preoperative tests to reduce postoperative complications were agreed upon, including corneal topography and tomography, static pupillometry, biometry/biometry formula, optical coherence tomography for assessment of the retinal nerve fiber layer and macula.

During the study, researchers observed a lack of consensus for IOL selection, and the experts couldn’t agree upon parameters for choosing IOL characteristics. However, consensus was reached on the importance of patient habits for optic design selection. “I think the reason IOL selection didn’t reach a consensus was because it’s difficult to find a surgeon that utilizes all the different kinds of lenses, all the different types of material and optic designs,” says Prof. Romano.

Prof. Romano notes that this study

(Continued on p. 12)

CONTRIBUTORS

CHIEF MEDICAL EDITOR

Mark H. Blecher, MD

CONTACT LENSES

Penny Asbell, MD

CORNEA / ANTERIOR SEGMENT

Thomas John, MD

GLAUCOMA MANAGEMENT

Peter Netland, MD, PHD
Kuldev Singh, MD

MEDICARE Q & A

Mary Pat Johnson,
COMT, CPC

PEDIATRIC PATIENT

Janine Collinge, MD

PLASTIC POINTERS

April Lao, MD

REFRACTIVE SURGERY

Arturo S. Chayet, MD

RETINAL INSIDER

Carl Regillo, MD, FACS
Yoshihiro Yonekawa, MD

TECHNOLOGY UPDATE

Steven T. Charles, MD
Michael Colvard, MD

WILLS RESIDENT CASE SERIES

Bonnie Sklar, MD

ADVISORY BOARD

PENNY A. ASBELL, MD, MEMPHIS, TENN.

BRANDON AYRES, MD, PHILADELPHIA

SURENDRA BASTI, MD, CHICAGO

WILLIAM I. BOND, MD, PEKIN, ILL.

ALAN N. CARLSON, MD, DURHAM, N.C.

Y. RALPH CHU, MD, EDINA, MINN.

ADAM J. COHEN, MD, CHICAGO

JANINE COLLINGE, MD, FARMINGTON, CONN.

UDAY DEVGAN, MD, FACS, LOS ANGELES

ERIC DONNENFELD, MD, ROCKVILLE CENTRE, N.Y.

DANIEL S. DURRIE, MD, KANSAS CITY, MO.

ROBERT EPSTEIN, MD, MCHENRY, ILL.

ROBERT D. FECHTNER, MD, NEWARK, N.J.

BRIAN FRANCIS, MD, Los Angeles

JAMES P. GILLS, MD, TARPON SPRINGS, FLA.

HARRY GRABOW, MD, SARASOTA, FLA.

DOUGLAS K. GRAYSON, MD, NEW YORK CITY

DAVID R. HARDTEN, MD, MINNEAPOLIS

SARA J. HAUG, MD, PHD, DURANGO, COLO.

KENNETH J. HOFFER, MD, SANTA MONICA, CALIF.

JACK T. HOLLADAY, MD, MSEE, HOUSTON

JOHN D. HUNKELER, MD, KANSAS CITY, MO.

THOMAS JOHN, MD, TINLEY PARK, ILL.

ROBERT M. KERSHNER, MD, MS, PALM BEACH GARDENS, FLA.

GUY M. KEZIRIAN, MD, PARADISE VALLEY, ARIZ.

SUMITRA KHADELWAL, MD, HOUSTON

TERRY KIM, MD, DURHAM, N.C.

BRAD KLIGMAN, MD, MANHASSET, N.Y.

TOMMY KORN, MD, SAN DIEGO

APRIL LAO, MD, MEMPHIS

DAVID A. LEE, MD, HOUSTON

FRANCIS S. MAH, MD, LA JOLLA, CALIF.

NICK MAMALIS, MD, SALT LAKE CITY

EDWARD MANCHE, MD, PALO ALTO, CALIF.

MIKE S. MCFARLAND, MD, PINE BLUFF, ARK.

JEFFREY B. MORRIS, MD, MPH, ENCINITAS, CALIF.

KEVIN MILLER, MD, LOS ANGELES

MAJID MOSHIRFAR, MD, DRAPER, UTAH

MARLENE R. MOSTER, MD, PHILADELPHIA

ROBERT J. NOECKER, MD, FAIRFIELD, CONN.

ROBERT OSHER, MD, CINCINNATI

MARK PACKER, MD, WEST PALM BEACH, FLA.

CHRISTOPHER J. RAPUANO, MD, PHILADELPHIA

AUGUST READER III, MD, SAN FRANCISCO

TONY REALINI, MD, MPH, MORGANTOWN, W.V.

KENNETH J. ROSENTHAL, MD, GREAT NECK, N.Y.

ERIC ROTHCHILD, MD, DELRAY BEACH, FLA.

SHERI ROWEN, MD, BALTIMORE

JAMES J. SALZ, MD, LOS ANGELES

INGRID U. SCOTT, MD, MPH, HERSHEY, PA.

JOEL SCHUMAN, MD, PITTSBURGH

GAURAV SHAH, MD, ST. LOUIS

DAVID R. STAGER JR., MD, DALLAS

KARL STONECIPHER, MD, GREENSBORO, N.C.

JAMES C. TSAI, MD, NEW YORK CITY

VANCE THOMPSON, MD, SIOUX FALLS, S.D.

FARRELL C. TYSON, MD, CAPE CORAL, FLA.

R. BRUCE WALLACE III, MD, ALEXANDRIA, LA.



BUSINESS OFFICES

19 CAMPUS BOULEVARD, SUITE 101
NEWTOWN SQUARE, PA 19073
SUBSCRIPTION INQUIRIES (877) 529-1746
(USA ONLY); OUTSIDE USA, CALL (847) 763-9630

BUSINESS STAFF

PUBLISHER

MICHAEL HOSTER

(610) 492-1028 MHOSTER@JOBSON.COM

SENIOR MANAGER, STRATEGIC ACCOUNTS

MICHELE BARRETT

(610) 492-1014 MBARRETT@JOBSON.COM

REGIONAL SALES MANAGER

JONATHAN DARDINE

(610) 492-1030 JDARDINE@JOBSON.COM

DIGITAL MARKETING MANAGER

MATT EGGER

(610) 492-1029 MEGGER@JOBSON.COM

CLASSIFIED ADVERTISING

(888)-498-1460

PRODUCTION MANAGER

KAREN LALLONE

(610) 492-1010 KLALLONE@JOBSON.COM

SUBSCRIPTIONS

\$63 A YEAR, \$99 (U.S.) IN CANADA,
\$158 (U.S.) IN ALL OTHER COUNTRIES.

SUBSCRIPTIONS E-MAIL:

REVOPHTHALMOLOGY@CAMBEYWEST.COM

CIRCULATION

PO BOX 71, CONGERS, NY 10920-0071

(877) 529-1746

OUTSIDE USA: (845) 267-3065

SENIOR CIRCULATION MANAGER

HAMILTON MAHER

(212) 219-7870 hmaher@jhihealth.com

CEO, INFORMATION GROUP SERVICES

BILL SCOTT

SENIOR VICE PRESIDENT, OPERATIONS

JEFF LEVITZ

VICE PRESIDENT, HUMAN RESOURCES

TAMMY GARCIA

VICE PRESIDENT, CREATIVE SERVICES & PRODUCTION

MONICA TETTAMANZI

CORPORATE PRODUCTION DIRECTOR

JOHN ANTHONY CAGGIANO

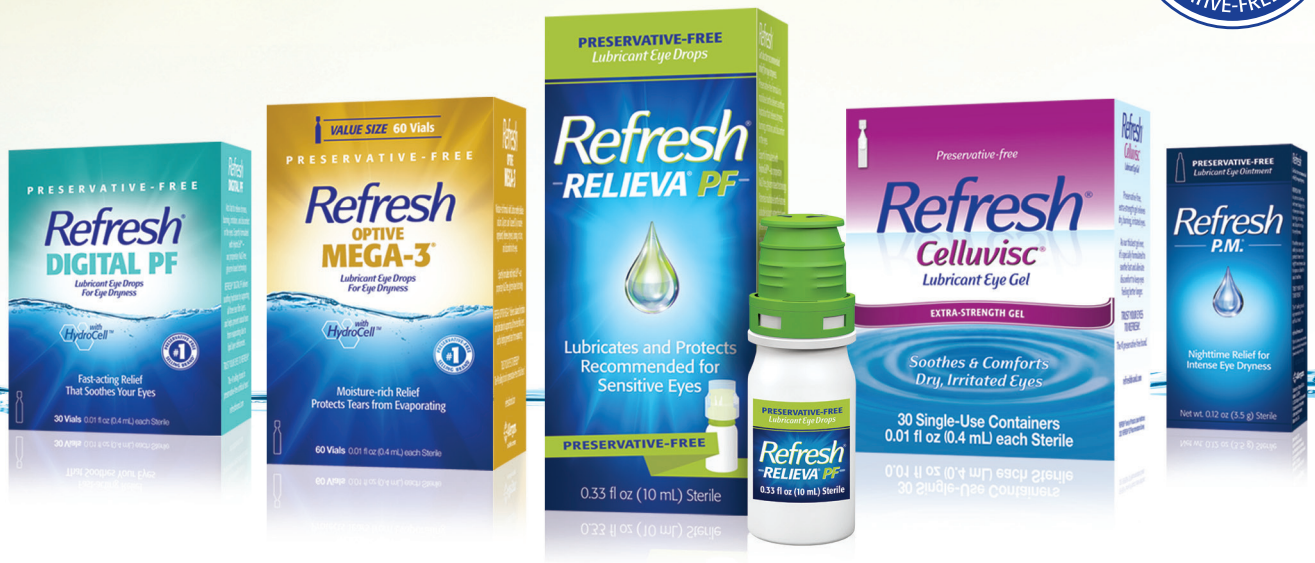VICE PRESIDENT, CIRCULATION

JARED SONNERS

395 Hudson Street, 3rd Floor,
New York, NY 10014

PRESERVATIVE-FREE POWERHOUSE

— SYMPTOM RELIEF FOR DRY EYES —



No two patients' eyes are the same. That's why REFRESH® provides a portfolio of products expertly formulated around your patients' specific needs.

RECOMMEND THE LEADER IN PRESERVATIVE-FREE*

Refresh[®]
Lubricant Eye Drops

refreshbrand.com/doc

*REFRESH® Family of Products, Ipsos Healthcare, 2021 REFRESH® ECP Recommendation Survey
© 2023 AbbVie. All rights reserved. All trademarks are the property of their respective owners.

 **Allergan**[®]
an AbbVie company

US-RFS-230038 03/23

FEATURES

Vol. 30, No. 7 • July 2023

Catch Up on the Latest News
Read Review's weekly newsletter
online at reviewofophthalmology.com.

25

Matching Patients with LASIK, SMILE or PRK

How refractive surgeons identify the optimal candidates for these laser-vision correction procedures.

Christine Yue Leonard
Senior Associate Editor

33

How to Make Phaco More Efficient

A look at the modern technology and machine functions you can tweak.

Andrew Beers
Associate Editor

39

The Latest Techniques And Tech for DMEK and DSAEK

DMEK is the procedure of choice for Fuchs' dystrophy, with DSAEK typically reserved for complex eyes.

Michelle Stephenson
Contributing Editor

42

The Impact of the DRCR Protocol Studies

Researchers in the field of diabetic eye disease discuss how various Protocol trials have influenced treatment planning for PDR, DME and others.

Liz Hunter
Senior Editor

48

Managing Acanthamoeba And Other Infections

A look at infectious keratitis and how to best manage it.

Francis Mah, MD

DEPARTMENTS

July 2023

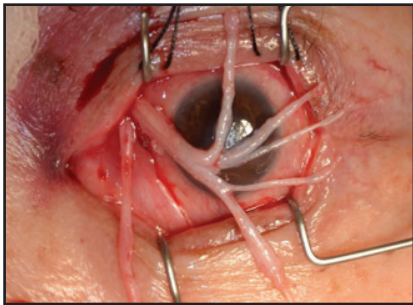
4 News

10

EDITOR'S PAGE

Looking at the Whole Patient

Walter Bethke
Editor in Chief



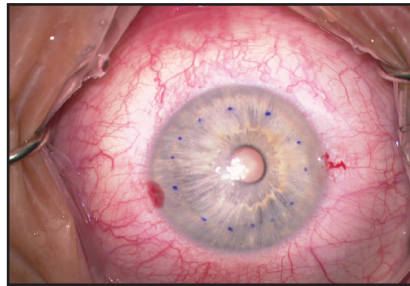
13

PLASTICS POINTERS

Management of Facial Nerve Palsy

Part two of a two-part series exploring the diagnosis and management of facial paralysis.

Cynthia M. Noguera, MD



21

REFRACTIVE/CATARACT RUNDOWN

Considerations for Fuchs' and Cataract

The severity of a patient's Fuchs' may create some challenging variables for treatment. Here's guidance.

Winston Chamberlain, MD, PhD

24

THE FORUM

Water, Water, Everywhere

Mark H. Blecher, MD
Chief Medical Editor

51

GLAUCOMA MANAGEMENT

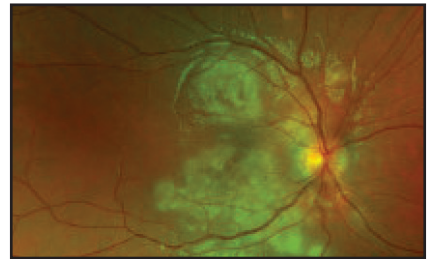
Time for a New Angle?

Angle-recession glaucoma is tricky to treat. Based on the current literature, it might be time to revise our approach.

Daniel B. Moore, MD

54

AD INDEX



56

RETINAL INSIDER

An Update on White Dot Syndromes

Their rarity and different manifestations can make these chorioretinopathies a challenge to deal with. Here's help.

Sruthi Arepalli, MD

62

RESEARCH REVIEW

63

WILLS EYE RESIDENT CASE SERIES

A child with heterochromia, hemorrhage and an intraocular mass presents at Wills Eye

Sandy Wong, MD, and
Carol Shields, MD

 VISIT US ON SOCIAL MEDIA

Facebook www.facebook.com/RevOphth

Twitter twitter.com/RevOphth


Instagram [@revophth](https://www.instagram.com/revophth)

**THE FUTURE IS
CLOSING IN**

iyuzehTM

(latanoprost ophthalmic solution) 0.005%

Prepare now at iyuzeh.com



EDITORIAL STAFF

Editor in Chief

Walter Bethke

(610) 492-1024

wbethke@jobson.com

Senior Editor

Liz Hunter

(610) 492-1025

ehunter@jobson.com

Senior Associate Editor

Christine Leonard

(610) 492-1008

cleonard@jobson.com

Associate Editor

Leanne Spiegle

(610) 492-1026

lspiegle@jobson.com

Associate Editor

Andrew Beers

(570) 856-5156

abeers@jobson.com

Chief Medical Editor

Mark H. Blecher, MD

Senior Art Director

Jared Araujo

(610) 492-1032

jaraujo@jobson.com

Graphic Designer

Lynne O'Connor

(267) 566-6007

lyoconnor@jobson.com

Business Offices

19 Campus Boulevard, Suite 101

Newtown Square, PA 19073

(610) 492-1000

Fax: (610) 492-1039

Subscription inquiries:

United States – (877) 529-1746

Outside U.S. – (845) 267-3065

E-mail:

revophthalmology@cambeywest.com

Website: www.reviewofophthalmology.com



WALTER C. BETHKE, EDITOR IN CHIEF

EDITOR'S PAGE

Looking at the Whole Patient

As physicians quickly find out, when evaluating a patient, one factor or measurement isn't the be-all and end-all, and could actually lead one down a wrong path. However, one measurement can, in many instances, be a good starting point to direct you toward other factors to evaluate, and, taken together, give you a more complete picture of a particular patient's condition.

Take the body-mass index, for example. It's an easy-to-calculate, inexpensive indicator of someone's fitness, at least as far as their weight is concerned: It has standardized cutoff points that can point toward an underweight, normal or obese condition.¹ But, though it's a handy, objective measurement, it's not perfect.

For instance, an athletic patient could have a high BMI, but a lot of their weight is actually muscle.² While, on the other end of the scale, someone could have a normal BMI—maybe a little on the high side. However, when you look at their waist size, it turns out it's more than 40 inches. Studies have shown that carrying most of one's fat in the abdomen area is actually a risk factor for problems such as heart disease, high blood pressure, type 2 diabetes and stroke.³

Also, BMI indexes may need to be broken down by sex and race, as Asians tend to have more body fat than white patients.¹

Despite such limitations, though, BMI is a good quick jumping-off point in a series of exams and measurements that can characterize the patient's condition fully. The BMI can be followed by more intensive

measurements, such as bioelectric impedance and/or underwater weighing.¹

Similarly, surgeons interviewed for this month's cover story on selecting the right laser refractive surgery for a particular patient discuss how just one or two measurements or exams might be useful to a point, but it's when all of the patient's data are taken together that you can make a decision on a procedure. For example, a patient's refractive error may be well within LASIK's zone of efficacy and predictability, but when you look at the cornea, an irregularity might rule out the patient. Similarly, the patient may have an acceptable refraction, corneal topography/tomography and pachymetry, but when you inquire about his hobbies, it turns out he likes to box (a risk for a displaced flap)—so you instead might lean toward surface ablation.

We hope that this deep dive into the key factors involved in laser refractive surgery will help you best align your patient with the right procedure.

— Walter Bethke
Editor in Chief

1. Harvard T.H. Chan School of Public Health. Measuring obesity. <https://www.hsph.harvard.edu/obesity-prevention-source/obesity-definition/how-to-measure-body-fatness/>. Accessed June 23, 2023.

2. Centers for Disease Control and Prevention. Body mass index: Considerations for practitioners. <https://www.cdc.gov/obesity/downloads/bmiforpractitioners.pdf>. Accessed June 26, 2023.

3. National Heart, Lung and Blood Institute. Assessing your weight and health risk. https://www.nhlbi.nih.gov/health/educational/lose_wt/risk.htm. Accessed June 26, 2023.



Alcon
Vision Suite

Complete. Connected.
Working as one.

ARGOS®

with Image Guidance by ALCON®

Faster.¹⁻⁵ Easier.^{5,6*} Better.^{1,2,7,8}

Faster measurements.¹⁻⁵ Superior capture rates.^{1-5†} For better outcomes.^{7,8}



SMARTCataract

Your practice working smarter.

Work more efficiently.^{9,13}

Prepare from anywhere.

Get next-level accuracy.

†Axial Length acquisition rate was significantly higher for ARGOS® (P<0.0001) than for IOLMaster‡ 700; it was also significantly higher for ARGOS® (P<0.0001) than for IOLMaster‡ 700 in patients with Grade IV or higher cataract.

‡ Trademarks are the property of their respective owners.

*Compared to VERION™ Reference Unit

References

1. Tamaoki A, Kojima T, Hasegawa A, et al. Clinical evaluation of a new swept-source optical coherence biometer that uses individual refractive indices to measure axial length in cataract patients. *Ophthalmic Res.* 2019;19:1-13. 2. Shammas HJ, Ortiz S, Shammas MC, Kim SH, Chong C. Biometry measurements using a new large-coherence-length swept-source optical coherence tomographer. *J Cataract Refract Surg.* 2016;42:50-61. 3. Hussaindeen JR, Mariam EG, Arunachalam S, et al. Comparison of axial length using a new swept-source optical coherence tomography-based biometer. *PLOS ONE.* December 2018. 4. ZEISS' IOLMaster‡ 700 510k Submission 2015. 5. ARGOS® Biometer User Manual 2019. 6. VERION™ Reference Unit User Manual, Part I. 2019. 7. Whang W, Yoo Y, Kang M, Joo C. Predictive accuracy of partial coherence interferometry and swept-source optical coherence tomography for intraocular lens power calculation. *Sci Rep.* 2018;8(1):13732. 8. Shammas HJ. Accuracy of IOL power formulas with true axial length versus simulated axial length measurement in 318 eyes using an OCT biometer. 2019 ASCRS ASOA Annual Meeting, May 2019. 9. Alcon Data on File, 2020. 10. Blaylock JF, Hall B. Astigmatic results of a diffractive trifocal toric IOL following intraoperative aberrometry guidance. *Clin Ophthalmol.* 2020;14:4373-4378. doi:10.2147/OPHT.S285711 11. Cionni RJ, Dimalanta R, Breen M, Hamilton C. A large retrospective database analysis comparing outcomes of intraoperative aberrometry with conventional preoperative planning. *J Cataract Refract Surg.* 2018;44(10):1230-1235. doi:10.1016/j.jcrs.2018.07.016 12. Van Vliet EJ, Bredenhoff E, Sermeus W, Kop LM, Sol JCA, Harten WH. Exploring the relation between process design and efficiency in high-volume cataract pathways from a lean thinking perspective. *Int J Qual Health Care.* 2011;23(1):83-93. doi:10.1093/intqhc/mzq071 13. Håkansson I, Lundström M, Stenevi U, Ehinger B. Data reliability and structure in the Swedish National Cataract Register. *Acta Ophthalmol Scand.* 2001;79(5):518-523. doi:10.1034/j.1600-0420.2001.790519.x

Please see the equipment product manuals for Important Product Information

IMPORTANT PRODUCT INFORMATION

ARGOS® Optical Biometer

Caution: Federal (USA) law restricts this device to the sale by or on the order of a physician.

Indications: ARGOS® is a non-invasive, non-contact biometer based on swept-source optical coherence tomography (SS-OCT). The device is intended to acquire ocular measurements as well as perform calculations to determine the appropriate intraocular lens (IOL) power and type for implantation during intraocular lens placement.

Intended Use: The Reference Image functionality is intended for use as a preoperative and postoperative image capture tool. It is intended for use by ophthalmologists, physicians, and other eye-care professionals and may only be used under the supervision of a physician.

Warnings and Precautions:

- Only properly trained personnel with experience may operate the device and control software and interpret the results.
- Factors that influence the measurement of patient's eyes are listed in the User Manual (Table 1): pseudophakic eye, wearing contact lenses, fixation problem, cornea opacity, non-intact cornea, refractive surgery, blood in the vitreous humor, retinal detachment, keratoconus, asteroid hyalosis, ambient light in the room, and deformation of the corneal shape. Please consider the guidance provided in Table 1 when you encounter these factors.
- Optical Radiation - This device is equipped with a Class 1 laser light source.

ATTENTION: Refer to the ARGOS® User Manual for a complete description of proper use and maintenance, optical and technical specifications, as well as a complete list of warnings and precautions.

Alcon

REVIEW NEWS

(Continued from p. 4)

Delphi Panel

merely provides recommended guidelines for ophthalmic surgeons. “The aim was to give guidance to young surgeons and to deliver [information] in an unbiased way,” he says. “[The experts] never talked about brands. They never talked

about lenses that were better than others, but rather their recommendations to let young surgeons, or surgeons who aren't cornea/refractive experts, a chance to learn about these lenses.”

Romano V, Madrid-Costa D, Alfonso JF, et al. Recommendation for presbyopia-correcting intraocular lenses: A Delphi consensus statement by the ESASO study group. *Am J Ophthalmol.* May 24, 2023. [Epub ahead of print].

Isotretinoin and Tear Dysfunction

Isotretinoin was found to alter meibomian gland morphology, causing lipid abnormalities.¹

Known by its brand name Accutane, isotretinoin is the most effective treatment for refractory acne vulgaris cases. The oral medication travels through the bloodstream, affecting oil glands and reducing sebum production all over the body, including in the face and eyelids. Dry eye and meibomian gland dysfunction with isotretinoin use have both been reported in the literature.

To better characterize the drug's ocular side effects, researchers in Poland conducted a study of individuals with an acne vulgaris diagnosis. As a result of their research, they reported increased ocular complaints from the study patients and reversible changes in meibomian glands.

The study included 48 eyes of 24 patients with acne vulgaris. Each patient underwent an ophthalmic exam before initiating isotretinoin therapy, three months after the start of treatment and one month after completion of the treatment.

The researchers reported significant increases in Ocular Surface Disease Index score during and after treatment compared with pretreatment values. During treatment with isotretinoin, there was substantial meibomian gland loss and decreases in meibum quality score and lid margin abnormality score. These

measures improved once treatment was stopped.

Additionally, the authors reported that the frequency of artificial tear use was positively associated with meibomian gland loss during and after treatment. They also noted in their paper that meibomian gland atrophy was significantly correlated with meibum quality scores during and after treatment. During isotretinoin treatment, decreased tear breakup time values correlated with an increase in lid margin abnormality score. Schirmer's test scores and blink rates seemed unaffected by the treatment.

“Systemic therapy with a retinoid derivative is an independent risk factor for dysfunction and atrophy of the meibomian glands in patients with acne vulgaris,” the researchers concluded in their paper. “Interestingly, the statistical analysis carried out in the follow-up study unambiguously showed that the side effects induced by isotretinoin started to subside.” The investigators added that further study into this occurrence will hopefully shed light on the mechanism for meibomian gland regeneration to help patients suffering from meibomian gland dysfunction. ◀

1. Zakrzewska A, Wiacek MP, Słucznanowska-Głabowska S, et al. The effect of oral isotretinoin therapy on meibomian gland characteristics in patients with acne vulgaris. *Ophthalmol Ther.* June 10, 2023. [Epub ahead of print].



EDITED BY PRISCILLA APRIL O. LAO, MD

PLASTIC POINTERS

Management of Facial Nerve Palsy

Part two of a two-part series exploring the diagnosis and management of facial paralysis.

CYNTHIA M. NOGUERA, MD
MEMPHIS, TENN.

In this, the final part of our series on facial nerve palsy, we focus on the medical and surgical management of FNP. The treatment for facial nerve paralysis is a multimodal approach and planning depends on the patient's age, as well as the etiology, severity, timing and duration of the facial paralysis. These factors must be considered to be sure they align with the patient's goals and outcomes.

Medical Management

Medical management of FNP involves several considerations:

- **Treat the underlying cause.** Your approach to medical management depends on whether the cause is idiopathic or infectious.

- **Idiopathic (Bell's palsy).** Corticosteroids within 72 hours of onset have been included in the evidence-based treatment guidelines for Bell's palsy recommended by the American Academy of Neurology and the American Academy of Otolaryngology-Head and Neck Surgery.¹ Clinical guidelines recommend a 10-day course of oral steroids with five days at a high dose (prednisolone 50 mg/day for 10 days or prednisone 60 mg/day for five days) followed by a five-

day taper.² The benefit of antivirals as monotherapy or in combination with steroids is still debated. Some experts prescribe valacyclovir 500 mg by mouth twice a day for seven days along with corticosteroids.¹

- **Infectious.** Infectious etiologies break down to either Ramsay-Hunt Syndrome (RHS) or Lyme disease. Similar to Bell's palsy, RHS should be treated with corticosteroids to decrease vertigo and postherpetic neuralgia.¹ These patients should also be treated with an oral antiviral to improve recovery and decrease complications.³

For Lyme-associated FNP, the typical treatment is a three-week course of oral doxycycline. Unlike Bell's palsy and RHS, corticosteroid treatment in Lyme disease results in worse outcomes.¹

- **Manage the ocular surface.** In the acute phase of FNP, ophthalmologists play a pivotal role in preventing irreversible blindness from corneal exposure.⁴ This is particularly important when ocular signs or symptoms of exposure keratopathy are present. The clinician must also evaluate corneal sensation. Patients with corneal hypesthesia in combination with corneal exposure are at extremely high risk for corneal ulceration and perforation. Artificial tears and thicker gel or ointment-based lubricants are the mainstay

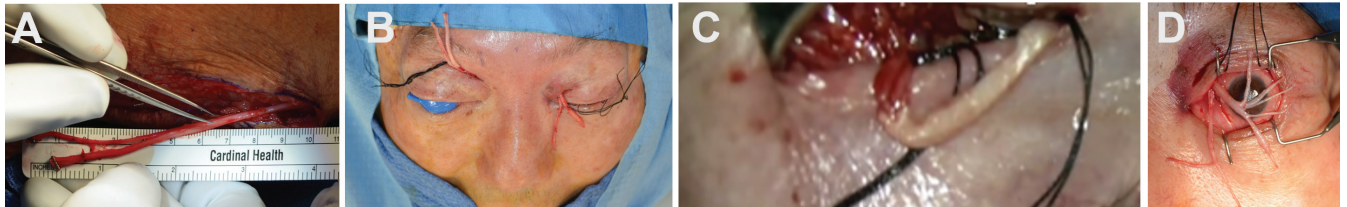
of therapy. If frequent dosing is needed, switch to preservative-free formulations to reduce allergic or toxic reactions. You can also use lipid-enhanced artificial tears. Some clinicians may consider autologous serum tears; however, these can be very expensive for patients.

As the normal blink function is impaired, the normal tear film physiology is dysregulated. Therefore, it's best to take measures to improve the tear film quality. These include the usual eyelid hygiene measures such as warm compresses and eyelid scrubs for meibomian gland dysfunction and blepharitis. Oral medications may include omega-3 supplementation (fish and flaxseed oil), doxycycline or azithromycin. A recent study reported equivalency of effects of azithromycin as compared with doxycycline.⁵ Routine eyelid procedures such as thermal pulsation techniques (Lipiflow)⁶ may alleviate symptoms of MGD,⁶ however, these aren't typically covered by insurance.

Moisture retention methods such as manually taping the eyelids shut, eye masks and humidification goggles/moisture chambers may also provide relief. Patients may consider optimizing their home environment by using humidifiers and turning off oscillating fans. Obstruction of tear outflow with punctal plugs or thermal punctal cautery helps tear retention in aqueous deficient dry eye. Bandage contact lens placement may also be considered; however, this will require antibiotic prophylaxis and patient compliance for regular follow-ups. Scleral contact lenses may be beneficial for patients who require long-term solutions but can be cost-prohibitive as they are not covered by insurance.

This article has no commercial sponsorship.

Dr. Lao is an assistant professor of ophthalmology and neurology at the University of Tennessee Health Science Center/Hamilton Eye Institute in Memphis.



Neurotization steps: (A) Harvesting of sural nerves for grafting; (B) tunneling of sural nerve graft; (C) end-to-end coaptation of SON to sural nerve graft; (D) external photographs of dual sural nerve grafts split into fascicles for corneal grafting.

Image credit: Charlson ES, Pepper JP, Kossler AL. Corneal neurotization via dual nerve autografting. *Ophthalmic Plast Reconstr Surg* 2022;38:1:e17-e19. Used with permission.

Chemical Denervation

Botulinum toxin use has gained popularity in the management of facial nerve paralysis. This neuromodulator may be used to temporarily relax muscles, thereby improving facial symmetry and function. Protective ptosis can be induced with 5 units/0.1 ml of botulinum toxin directly injected into the levator muscle.⁷ The most common adverse effect is diplopia, which can last up to three months and presents as a vertical misalignment that clinically behaves as a superior rectus palsy.⁷ The majority of these will resolve with observation. Botulinum toxin can additionally be used to address symptoms of aberrant facial nerve innervation including hypertonicity of the affected side, synkinesis of facial muscles along with neuromuscular retraining therapy, and gustatory lacrimation (“crocodile tears”).^{8,9}

Surgical Management

Once the cornea is adequately protected and recovery deemed unlikely, longer-term planning for eyelid and facial reanimation may take place in an individualized manner.⁴ The specific surgical approach depends on factors such as the etiology and density of facial paralysis, the patient's overall health and the surgeon's expertise.

• **Occlusive techniques.** Should patient symptoms persist despite conservative measures, or if there are suspected long-term sequelae of their facial nerve palsy, surgical procedures should be considered concurrently with ocular surface

lubrication. Less invasive surgical treatments that may be performed in the clinical setting are temporary tarsorrhaphy or a small permanent tarsorrhaphy. These are the simplest and most common procedures that are also used in conjunction with a variety of oculoplastic procedures. These can also be used as temporizing measures as a bridge for a patient who may not yet be medically optimized for the operating room to undergo general anesthesia. The useful occlusive techniques are the following:

• **Temporary suture tarsorrhaphy to fully close the eyelids.** This is commonly used for patients unable to fully blink, with a poor protective Bell's reflex, and/or with severe lagophthalmos. One must consider the visual status, as these will occlude the visual axis. This approach has also been used longer term for severe neurotrophic ulcers to assist with healing.

• **Lateral permanent tarsorrhaphy is a quick procedure that can be done in the office setting and is the most common form of permanent eyelid closure.** However, closing the temporal palpebral fissure can limit peripheral vision, contribute to mechanical ptosis of the upper eyelid, and not be aesthetically pleasing to the patient.

• **Medial permanent tarsorrhaphies are less commonly performed but can improve the medial descent of the lower eyelid when there's poor orbicularis tone.** These will usually require closure of the puncta simultaneously and can also be helpful for

aqueous deficient dry-eye patients (permanent puncta occlusion).

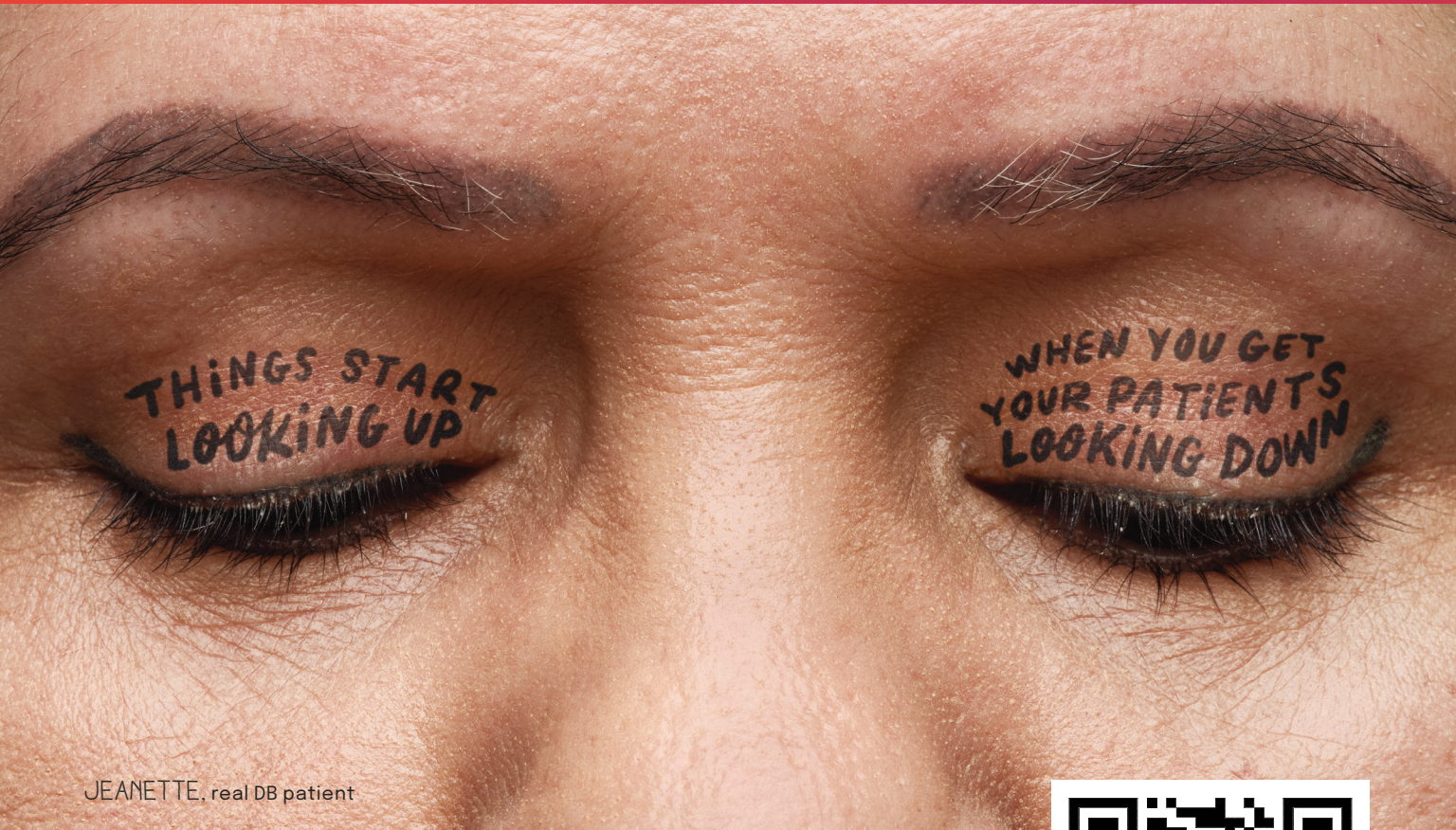Less common measures include botulinum toxin (as detailed in the previous section), hyaluronic acid gel (fillers) and external temporary eyelid weights. The upper eyelid can be mechanically weighed down with hyaluronic acid gel fillers. This is reversible with hyaluronidase. External temporary eyelid weights typically have an adhesive backing that can be applied to the skin of the upper eyelid to assist with immediate closure, however long-term uses of adhesive can cause skin breakdown of the delicate eyelid skin. Although these procedures are less commonly seen, they may provide temporizing measures or may be ideal for the patient who isn't medically stable enough for the operating room.

• **Static techniques.** Static techniques improve the resting symmetry of the face without restoration of movement. FNP is associated with multiple periocular sequelae affecting the dynamic function and static appearance of the eyelids, including lagophthalmos, brow ptosis, upper and lower eyelid retraction, lower eyelid ectropion and secondary skin contracture.¹ Multiple procedures are often required to restore eyelid function and symmetry and protect the ocular surface.¹⁰ Although these are static procedures, restoring the normal anatomical repositioning of the eyelids can augment the natural blink reflex. A few of the most common procedures used to address the specific challenges associated with

Keep an eye out for the root cause of blepharitis.

Demodex mites are the cause of chronic inflammation and associated with two-thirds of blepharitis cases.^{1,2}

Demodex blepharitis (DB) is an important part of eyelid health.^{3,4}



JEANETTE, real DB patient

SEE THE SIGNS OF DB FOR YOURSELF

LOOK *at the* LIDS.COM



@LookAtTheLids



 Tarsus

References: 1. Gao YY, Di Pascuale MA, Li W, et al. High prevalence of *Demodex* in eyelashes with cylindrical dandruff. *Invest Ophthalmol Vis Sci.* 2005;46(9):3089-3094. 2. Trattler W, Karpecki P, Rapoport Y, et al. The prevalence of *Demodex* blepharitis in US eye care clinic patients as determined by collarettes: a pathognomonic sign. *Clin Ophthalmol.* 2022;16:1153-1164. 3. Aumond S, Bitton E. The eyelash follicle features and anomalies: a review. *J Optom.* 2018;11(4):211-222. 4. Fromstein SR, Harthan JS, Patel J, Opitz DL. *Demodex* blepharitis: clinical perspectives. *Clin Optom (Auckl).* 2018;10:57-63.

FNP include:

- **Gold weight implantation.** This involves placing a gold or platinum weight within the upper eyelid to assist with complete eyelid closure. The weight counteracts the weakness or paralysis of the orbicularis muscle responsible for eyelid closure and protection of the cornea.

- **Brow lifts.** A variety of brow lift techniques may be employed to assist with eyelid lifting surgeries. A recent case series described a “switch technique” that uses full-thickness skin grafts from direct brow lift surgery to repair the skin contracture and paralytic lower eyelid ectropion, addressing multiple sequelae into one surgery.¹⁰

- **Ectropion repair.** Paralytic lower eyelid ectropion repair involves repositioning the suspension tissues of the lower eyelid to provide support and improve the natural blink function. This addresses the lower eyelid skin laxity and loss of orbicularis tone seen in FNP.

- **Cheek/midface lift.** In conjunction with lower eyelid ectropion repair, the surgeon must recognize that paralysis of the malar-cheek soft tissues in addition to orbicularis paralysis contributes to the lack of support of the lower eyelid. The paralysis results in the weakening of medial and lateral canthal ligaments and orbitomalar ligaments. When evaluating these patients for reconstruction, the surgeon should consider a simultaneous midface lift. This may include suborbicularis oculi fat repositioning (SOOF lift), lateral orbicularis orbital suspension, and lateral canthopexy and/or canthoplasty with fixation sutures at the lateral orbital rim. These techniques have been shown to be effective in static lower eyelid malposition surgery.

- **Corneal neurotization.** When neurotrophic keratitis is present, corneal neurotization reinstates corneal sensation through the induction of donor nerve tissue. The donor nerve (most commonly the inferior orbital

nerve) is placed subconjunctivally near the corneal limbus. A single case report described the use of a dual nerve grafting approach via simultaneous parallel sural nerve grafts from both the supratrochlear and supraorbital nerves to the affected contralateral cornea with return of sensation by postoperative week 11.¹¹

- **Dynamic techniques.** Facial reanimation surgery, also known as facial nerve reconstruction, is aimed at restoring symmetry of the face with restoration of facial movement. The procedure involves the repair, redirection or replacement of the damaged facial nerve or its branches to reestablish innervation to the facial muscles. Depending on the specific needs of the patient, techniques include:

- **Nerve grafting.** Here, a healthy nerve from another part of the body (typically the sural nerve from the leg) is harvested and used to bridge the gap of the damaged facial nerve.

- **Nerve transfer.** Contralateral facial nerve grafts are also performed where the contralateral (unaffected) facial nerve is bridged to the damaged facial nerve.

- **Muscle transfer.** This involves transferring an adjacent functioning muscle (usually the temporalis muscle) from its original insertion to replace the paralyzed muscles and is connected to the remaining facial nerve or nerve graft to restore movement.

- **Free muscle transfer.** A donor muscle from another part of the body (typically the gracilis muscle in the thigh) is harvested along with its blood supply and transferred to the face.

- **Microneurovascular free flap.** This approach uses microsurgical techniques to carefully dissect and reconnect blood vessels and nerves during the flap transfer, ensuring blood supply and innervation to the newly transplanted tissue.

The goal of facial reanimation

surgery is to restore facial symmetry, improve facial movement, and enhance the patient’s ability to communicate, express emotions and perform daily activities. Post-surgery, patients may require rehabilitation, including physical therapy and exercises, to optimize facial function and achieve the best possible outcomes.

Special Cases

Facial nerve palsy can also occur due to special circumstances, or in unique patient populations.

- **Trauma/iatrogenic.** Because the facial nerve courses through the rigid bony structures of the temporal bone, craniofacial trauma commonly causes FNP either through direct damage from bony fragments or ischemia nerve compression from expansile edema. High-resolution computed tomography is used for the localization of nerve injury in suspected cases of temporal bone trauma. In the absence of gross radiographic abnormalities, electrophysiologic testing helps predict the likelihood of spontaneous recovery. In patients with deteriorating facial nerve injuries by electroneurography, surgical exploration is the preferred management.¹² The accepted recommendation for surgical management is indicated for patients with immediate-onset and complete paralysis. Patients who, due to their severe general condition, can’t undergo early facial nerve decompression may benefit from delayed treatment for up to three months after the injury.¹³

- **Congenital.** There are special considerations in the pediatric population. Although children as young as 2 years old have successfully undergone free tissue transfer for smile restoration,¹⁴ waiting until at least 5 or 6 years of age, around the time the child is school-aged and becomes self-aware, is preferred. Delaying major procedures until this age provides time for the growth of nerves and vessels, whose small caliber may lead to free flap failure, and

allows children to be mature enough to understand and participate in their own care.¹⁴

Postoperative Care

Postoperative healing in FNP patients can be prolonged due to the impaired venous and lymphatic drainage system. Lymphatics play a crucial role in the body's healing process by removing excess fluid, debris and immune cells from the surgical site. In facial paralysis, the physiologic action of the musculoskeletal pump is impaired. There's a lack of rhythmic contraction and relaxation of facial muscles and therefore slowing of venous and lymphatic drainage. Some considerations for postoperative healing in patients with facial paralysis include the following:

- Elevate the surgical site above the heart. Sleep with the head elevated and avoid sleeping on the surgical side as edema will accumulate with gravity.
- Proper wound care involves keeping the surgical site clean, dry and protected from infection. Cool compresses in the immediate postoperative period have also been shown to decrease bruising. Close monitoring of the wound is essential to detect any signs of infection or delayed healing.
- Manual lymphatic massage using gentle pressure creates rhythmic movements that help to mobilize fluid and promote drainage. This may also improve circulation, promote wound healing and reduce swelling. In one study, manual lymphatic drainage has been effective in reducing facial measurements in orthognathic surgery postoperatively. However, when considering the patient's pain and swelling perception, the researchers found no difference.¹⁵
- Close follow-up and monitoring: Patients with poor lymphatics require close monitoring during the postoperative period. Regular follow-up appointments with the surgical team are necessary to assess wound healing, manage complications and

adjust the treatment plan as needed.

Edema is part of the normal healing process after surgery. However, in patients with poor facial muscle function, swelling can be more significant and persistent. The surgeon should set these expectations for the patient and provide education. This can be a challenging period for our patients and requires reassurance and emotional support throughout the postoperative course.

Complications

Prolonged or poorly managed exposure keratopathy can be detrimental, especially in the setting of poor corneal sensation. Concomitant corneal hypesthesia and exposure put the eye at high risk for corneal ulceration, corneal melt with perforation and blindness, which may precede evisceration or enucleation. Facial muscle wasting over time can lead to significant facial asymmetry that may be difficult to manage. The postoperative course after reconstructive surgeries can be prolonged with pronounced periorbital and facial edema. This is mainly due to impaired venous static pumps of the facial lymphatics from lack of muscular impact.

Prognosis

Recovery from facial paralysis varies and depends on the etiology and severity of paralysis at presentation. Patients with idiopathic Bell's palsy typically begin to recover at three weeks and continue to recover for six months. These patients typically don't require surgical management. However, patients with Ramsay-Hunt syndrome carry a poorer prognosis. Although self-limiting, complete recovery occurs in only half of cases.¹ Among patients who present with dense, flaccid paralysis, approximately 61 percent recover with full function.

In contrast, patients who present with facial weakness, but not complete paralysis, recover full function in 94 percent of cases.¹ The most devastating facial nerve paralysis cas-

es are in those instances after trauma or tumor, where the facial nerve must be sacrificed during surgical resection. This results in permanent and complete facial paralysis; these cases should be considered for permanent surgical interventions, including static or dynamic facial nerve reanimation.

In conclusion, the medical and surgical management of FNP is highly individualized, and the specific treatment plan will depend on the underlying cause, severity of symptoms and the patient's overall health. A more general way to approach facial nerve palsy is based on suspected time for improvement for return of facial nerve function and severity of symptoms. Time periods can be generalized by:

- **"Soon" (weeks to months).** This necessitates supportive management with tears, ointment, taping eyelid shut, etc.
- **"Later" (six months to a year).** Depending on the severity of problems (corneal exposure, concomitant corneal hypesthesia with risk for ulceration, functional status, and patient comorbidities), start with conservative measures and after the observation period, you may consider proceeding with surgical management (gold weight, ectropion repair, etc.). These patients may later be considered candidates for facial reanimation.

- **"Never" (i.e., transected facial nerve).** These are the typical facial reanimation patients; however, as nerve regeneration will take one to two years; it's prudent to provide further support with static eyelid and/or facial reconstruction.

While medical and surgical interventions can be promptly initiated, extensive eyelid and facial reconstruction should involve consultation with a skilled oculoplastic or facial plastic surgeon who specializes in facial nerve palsy to determine the most appropriate surgical approach for each patient. ◀

1. MacIntosh PW, Fay AM. Update on the ophthalmic

(Continued on p. 50)

When Selecting a Prescription
Dry Eye Treatment

DON'T

**MAKE
HER
WAIT.**



Not an actual patient.

Indication

Xiidra® (lifitegrast ophthalmic solution) 5% is indicated for the treatment of signs and symptoms of dry eye disease (DED).

Important Safety Information

- Xiidra is contraindicated in patients with known hypersensitivity to lifitegrast or to any of the other ingredients.
- In clinical trials, the most common adverse reactions reported in 5-25% of patients were instillation site irritation, dysgeusia and reduced visual acuity. Other adverse reactions reported in 1% to 5% of the patients were blurred vision, conjunctival hyperemia, eye irritation, headache, increased lacrimation, eye discharge, eye discomfort, eye pruritus and sinusitis.
- To avoid the potential for eye injury or contamination of the solution, patients should not touch the tip of the single-use container to their eye or to any surface.



Novartis Pharmaceuticals Corporation
East Hanover, New Jersey 07936-1080



CHOOSE XIIDRA
Because lasting symptom
relief can start as early as
2 WEEKS^{1*}



Access to Xiidra is
better than ever²

*Xiidra reduced symptoms of eye dryness at 2 weeks (based on Eye Dryness Score compared to vehicle) in 2 out of 4 studies, with improvements observed at 6 and 12 weeks in all 4 studies.^{1†}

Important Safety Information (cont)

- Contact lenses should be removed prior to the administration of Xiidra and may be reinserted 15 minutes following administration.
- Safety and efficacy in pediatric patients below the age of 17 years have not been established.

Please see Brief Summary of Important Product Information on adjacent page.

[†]Pivotal trial data

The safety and efficacy of Xiidra were assessed in four 12-week, randomized, multicenter, double-masked, vehicle-controlled studies (N=2133). Patients were dosed twice daily. **Use of artificial tears was not allowed during the studies.** The study end points included assessment of signs (based on Inferior fluorescein Corneal Staining Score [ICSS] on a scale of 0-4) and symptoms (based on patient-reported Eye Dryness Score [EDS] on a visual analogue scale of 0-100).¹

Effects on symptoms of dry eye disease: A larger reduction in EDS favoring Xiidra was observed in all studies at day 42 and day 84. Xiidra reduced symptoms of eye dryness at 2 weeks (based on EDS) compared to vehicle in 2 out of 4 clinical trials.¹

Effects on signs of dry eye disease: At day 84, a larger reduction in ICSS favoring Xiidra was observed in 3 of the 4 studies.¹

References: 1. Xiidra [package insert]. East Hanover, NJ: Novartis Pharmaceuticals Corp. 2. Data on file. DRF Fingertip Formulary[®] Novartis Pharmaceuticals Corp; July 2022.

XIIDRA, the XIIDRA logo and ii are registered trademarks of Novartis AG.

XIIDRA® (lifitegrast ophthalmic solution), for topical ophthalmic use

Initial U.S. Approval: 2016

BRIEF SUMMARY: Please see package insert for full prescribing information.

1 INDICATIONS AND USAGE

Xiidra® (lifitegrast ophthalmic solution) 5% is indicated for the treatment of the signs and symptoms of dry eye disease (DED).

4 CONTRAINDICATIONS

Xiidra is contraindicated in patients with known hypersensitivity to lifitegrast or to any of the other ingredients in the formulation [see *Adverse Reactions (6.2)*].

6 ADVERSE REACTIONS

The following serious adverse reactions are described elsewhere in the labeling:

- Hypersensitivity [see *Contraindications (4)*]

6.1 Clinical Trials Experience

Because clinical trials are conducted under widely varying conditions, adverse reaction rates observed in clinical trials of a drug cannot be directly compared to rates in the clinical trials of another drug and may not reflect the rates observed in practice.

In five clinical trials of DED conducted with lifitegrast ophthalmic solution, 1401 patients received at least one dose of lifitegrast (1287 of which received lifitegrast 5%). The majority of patients (84%) had less than or equal to 3 months of treatment exposure. One hundred-seventy patients were exposed to lifitegrast for approximately 12 months. The majority of the treated patients were female (77%). The most common adverse reactions reported in 5%-25% of patients were instillation-site irritation, dysgeusia, and reduced visual acuity.

Other adverse reactions reported in 1%-5% of the patients were blurred vision, conjunctival hyperemia, eye irritation, headache, increased lacrimation, eye discharge, eye discomfort, eye pruritus, and sinusitis.

6.2 Postmarketing Experience

The following adverse reactions have been identified during post-approval use of Xiidra. Because these reactions are reported voluntarily from a population of uncertain size, it is not always possible to reliably estimate their frequency or establish a causal relationship to drug exposure.

Rare serious cases of hypersensitivity, including anaphylactic reaction, bronchospasm, respiratory distress, pharyngeal edema, swollen tongue, urticaria, allergic conjunctivitis, dyspnea, angioedema, and allergic dermatitis have been reported. Eye swelling and rash have also been reported [see *Contraindications (4)*].

8 USE IN SPECIFIC POPULATIONS

8.1 Pregnancy

Risk Summary

There are no available data on Xiidra use in pregnant women to inform any drug-associated risks. Intravenous (IV) administration of lifitegrast to pregnant rats, from pre-mating through gestation day 17, did not produce

teratogenicity at clinically relevant systemic exposures. Intravenous administration of lifitegrast to pregnant rabbits during organogenesis produced an increased incidence of omphalocele at the lowest dose tested, 3 mg/kg/day (400-fold the human plasma exposure at the recommended human ophthalmic dose [RHOD], based on the area under the curve [AUC] level). Since human systemic exposure to lifitegrast following ocular administration of Xiidra at the RHOD is low, the applicability of animal findings to the risk of Xiidra use in humans during pregnancy is unclear [see *Clinical Pharmacology (12.3) in the full prescribing information*].

Data

Animal Data

Lifitegrast administered daily by IV injection to rats, from pre-mating through gestation day 17, caused an increase in mean pre-implantation loss and an increased incidence of several minor skeletal anomalies at 30 mg/kg/day, representing 5,400-fold the human plasma exposure at the RHOD of Xiidra, based on AUC. No teratogenicity was observed in the rat at 10 mg/kg/day (460-fold the human plasma exposure at the RHOD, based on AUC). In the rabbit, an increased incidence of omphalocele was observed at the lowest dose tested, 3 mg/kg/day (400-fold the human plasma exposure at the RHOD, based on AUC), when administered by IV injection daily from gestation days 7 through 19. A fetal no observed adverse effect level (NOAEL) was not identified in the rabbit.

8.2 Lactation

Risk Summary

There are no data on the presence of lifitegrast in human milk, the effects on the breastfed infant, or the effects on milk production. However, systemic exposure to lifitegrast from ocular administration is low [see *Clinical Pharmacology (12.3) in the full prescribing information*]. The developmental and health benefits of breastfeeding should be considered, along with the mother's clinical need for Xiidra and any potential adverse effects on the breastfed child from Xiidra.

8.4 Pediatric Use

Safety and efficacy in pediatric patients below the age of 17 years have not been established.

8.5 Geriatric Use

No overall differences in safety or effectiveness have been observed between elderly and younger adult patients.

Distributed by:
Novartis Pharmaceuticals Corporation
One Health Plaza
East Hanover, NJ 07936
T2020-87



EDITED BY ARTURO CHAYET, MD

REFRACTIVE/CATARACT RUNDOWN

Considerations for Fuchs' and Cataract

The severity Fuchs' may create some challenging variables for a patient's treatment. Here's guidance.

WINSTON CHAMBERLAIN, MD, PHD
PORTLAND, OREGON

Cataract surgeons will often come across patients with Fuchs' endothelial corneal dystrophy as well as cataract. The progressive nature of Fuchs' leads to corneal decompensation and vision loss, and it's important to investigate whether their symptoms are due to Fuchs' or to cataract, and the severity of the disease, before determining the appropriate treatment path.

Staging Surgery or Combining It

In the presence of milder Fuchs', if your clinical judgment is that the cataract is a bigger contributor to a patient's vision problem, removing the cataract may result in a significant improvement in vision. However, if the patient has central guttae and they're visually significant, you can consider combining cataract surgery with Descemet's Stripping Only procedure with or without a Rho-associated protein kinase (ROCK) inhibitor, if you have access to them. Studies have shown ROCK inhibitors promote corneal endothelial cell proliferation *in vitro* and migration *in vivo*.¹

When a patient has more extensive guttae, there are three classical pathways a surgeon may consider for this scenario, including staged surgeries or combined procedures (Figure

1). The first steps in staged treatment could be cataract first, followed by Descemet's membrane endothelial keratoplasty vs. DMEK/Ultrathin Descemet's stripping automated endothelial keratoplasty first and cataract second.

There are advantages to each. If you perform cataract surgery first, the subsequent DMEK and IOL stabilization may be easier. DMEK first has numerous advantages and, in my opinion, it's easier to do DMEK on a phakic eye and you may have a better view to the IOL afterwards.

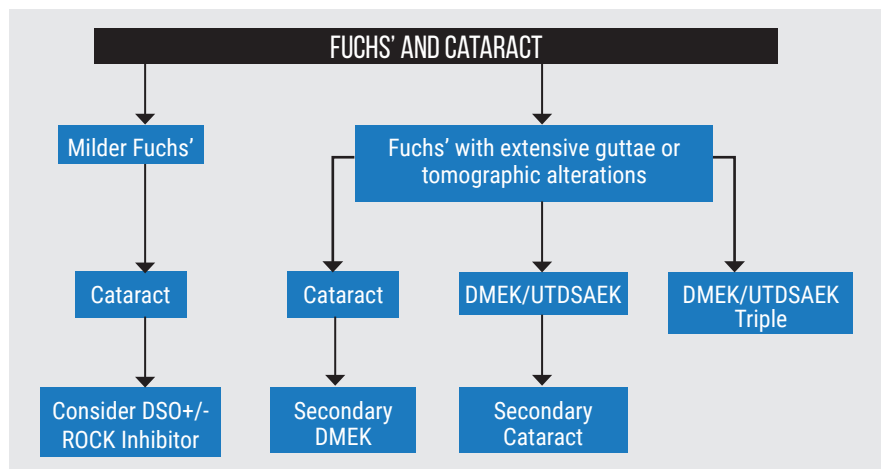
The third approach is combining DMEK/UTDSA/EK with phaco. This approach probably accounts for most of my surgeries in such cases. Many patients prefer having only one surgery, but we have to take certain

variables into consideration.

If the cataract isn't very dense but the guttae are dense in the center, then we might deduce that a bigger proportion of that is attributed to Fuchs' and a smaller portion of that is cataract, which would probably drive us to consider doing the transplant. But then we have to ask ourselves: Should we do the cataract at the same time?

One of the reasons to hold off on cataract surgery is that, if we normalize the cornea first, we actually get it into a more natural state, after which we may achieve a better refractive outcome during cataract surgery. When we combine the cases we tend to get surprises in the refraction. Nowadays, surgeons generally assume in their calculations that a majority of patients are going to shift in the farsighted direction, so they aim a little bit nearsighted on the lens. I would say that works across the population on average fairly well, but there are patients that shift in the opposite direction.

We did a randomized controlled trial looking at this and we actually found that about 38 percent of patients shifted nearsighted in that



This article has no commercial sponsorship.

Dr. Chayet is considered a pioneer in refractive and cataract surgery, and is the medical director of the Codet Vision Institute in Tijuana, Mexico. He is a clinical investigator for RxSight, LensGen and ForSight Vision6.

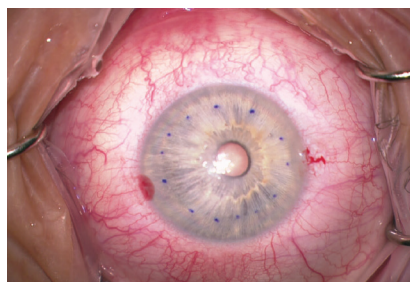
trial.² Because we aimed nearsighted initially, patients ended up more nearsighted than we wanted them to be. There are probably a number of variables driving that—most of them have to do with how the posterior and anterior shape of the cornea change as a result of corneal transplant surgery.

In our trial, we also discovered a dip in the total corneal refractive power at three months, which then reversed partially at six months and 12 months.² We believe there may be a redistribution of endothelial cells at the edge of the graft where there's more damage, causing central thinning faster and then a slight steepening because of redistribution in the periphery. I'd like to see enhanced variables that allow us to predict—based on a patient's grade of Fuchs' or based on their preoperative topographic features—how that cornea is going to change in response to having a DMEK/DSAEK surgery done. This would help us to better predict what lens power we should put in the eye to appropriately match that.

When you consider these factors, an argument could be made for staging the surgery. But of course, if we staged the surgery, we're doing two things: we're exposing the patient to potentially additional risks with two surgeries, and we're exposing them to the risk of damaging the graft after they've healed. It may not be a major threat for most skilled cataract surgeons, but we don't have long-term data to know if grafts actually do a little bit more poorly over time after staged surgery due to the additional trauma from cataract surgery.

The Impact on Lens Calculations

We know that changes after endothelial keratoplasty aren't immediate—they take time. This is a challenge if you're staging patients. The data suggests that the cornea isn't stable yet even if it's clear, and that the cornea will continue to change its shape for six to 12 months after surgery. This raises the question of the appropriate timing for the cataract surgery. I



This 64-year-old male patient presented with Fuchs' and cataract with central corneal guttae and a few small bullae centrally. He complained of foggy vision lasting until noon. I performed phakic DMEK first to normalize the cornea and his visual acuity went from 20/30 to 20/20 at three months postop. Cataract surgery was performed approximately one year later.

don't think we have a good amount of evidence to answer that question yet, but the evidence we do have suggests that you might want to wait at least six months. This is relevant for new lens technologies, including the Light Adjustable Lens from RxSight. Once it's in the eye, the lens power can be changed, which makes it very appealing for eyes with corneal findings—post-keratoplasty, keratoconus or previous radial keratotomy. We can potentially put that lens in and shift its power up to 2 D on label, probably a little bit more off label, in either direction if we're off.

It's not a perfect solution, though. The problem with a changing cornea in a Fuchs' patient is not knowing if that cornea will drift out of that correction, because once you put the LAL in and adjust it, it must be locked in place. After that, it can't be adjusted again. Surgeons may decide not to lock it in place until the cornea stabilizes, but that requires the patient to wear UV-protected goggles (per FDA Label) full time until they're adjusted and locked in. It'll be a little bit trickier to determine when that optimal stabilization point for the cornea is in patients with endothelial keratoplasty. They're going to have to wait longer and accept some sort of a UV protection for their eyes if they go down that path.

DSO with or without ROCK inhibi-

tors is a growing procedure among transplant and cataract surgeons. There's some retrospective data from Greg Maloney's group (Australia) suggesting that there may be a mild myopic shift in patients that undergo DSO vs. the hyperopic shift we see after DMEK or DSAEK. This could be because, in those particular patients, the cornea swells centrally, which causes a central bulging or steepening of the cornea and that could increase power in the cornea. This complicates lens calculations.

Personally, I tend to favor conventional IOLs in Fuchs' patients. I don't usually use toric lenses in these patients because the change in toricity in the cornea is a little less predictable, although the data suggest that it's not the toricity change as much as a change in total corneal power. Total corneal power can affect any lens choice you pick, but if you select a toric lens and the total corneal power changes, then you might be off in two directions—astigmatically and from a basic spherical equivalent standpoint as well, causing the patient to end up more nearsighted or farsighted.

I also avoid multifocal or extended-depth-of-focus lenses in my patients. I know some surgeons are advocates of that, but I feel there's too much unpredictability in a combined surgery to actually get the refractive outcome that the patient would expect when they're paying out of pocket. You might also degrade the optics in the eye a little bit in some of these patients by doing a multifocal or an EDOF lens because of aberrations in the cornea.

There's some emerging data on the LAL, and even though it's not published yet, I think we're going to see some positive results from this. Surgeons are going to have to wait for data that gives us a little bit of guidance on when to adjust that lens or when to put it in. If we combine the cataract and DMEK or DSAEK, we'll need to prepare our patients to wait awhile to get that adjustment, or we're going to have to perform the

endothelial keratoplasty and come back and put the LAL in three to four months later, and then consider doing the adjustment at five to six months, depending on the stability.

Even if they've undergone DMEK, we can't treat Fuchs' eyes as necessarily being optically equivalent to a normal cornea, since that can lead to refractive disappointment, which could then require lens exchanges, or just a lot of postoperative counseling. Surgeons need to be mindful of the choices they make. They're under pressure to provide the best refractive outcomes for patients and, often, that leads them to make decisions that aren't in the patients' best interests and choose a premium lens that won't deliver. Even after endothelial keratoplasty, the cornea may be more aberrated than it is in a normal situation.

Preoperative Imaging

Many surgeons still rely on specular photomicroscopy to grade Fuchs'. I feel specular microscopy in its current form is probably inadequate because the images it generates are central corneal images, and that's where the guttae are most concentrated. It makes it difficult to get an accurate idea of cell count or cell morphology with central guttae. Some of my peers have referred to it as a 'random number generator.' Others have argued that looking at corneal thickness may suggest the level of disease, but in general, there's a lot of variation in corneal thickness in patients with Fuchs' dystrophy and that's probably also misleading in terms of determining the health of the cornea as well as for making a decision. There have been some papers that argued if a cornea is over a certain thickness then you should do endothelial keratoplasty as well—I think that's outdated information, however. There are better ways to look at the health of the cornea specifically by looking at tomographic changes.

One technology that's going to emerge over the next few years is the use of next generation OCT to

better characterize isolated layers of the cornea preoperatively. We currently see value in broader maps of the cornea using the newly approved Optovue Solix OCT-A (Visionix). We're prospectively looking at our Fuchs' patients pre- and postoperatively to see how their corneal OCT maps change as a result of surgery. Total pachymetric maps as well as stromal and epithelial maps as imaged by OCT may return to normal after DMEK based on pattern standard deviation analysis (a method that has been used for years to assess changes in visual field maps). So OCT may be a tool to predict features of corneas preoperatively that allow surgeons to determine whether we should do transplants at the same time as cataract surgery.

Emerging into the mainstream is some of the work that's come out of the Mayo Clinic, specifically from Sanjay Patel, MD, and his group, looking at changes in corneal tomography with Scheimpflug imaging.³ They looked at preoperative features of the cornea that may predict significant deformation or changes in the cornea as a result of Fuchs', namely the loss of circular isopachs, which reflect a bulging in the back side of the cornea as a direct result of swelling from Fuchs'.

Scheimpflug imaging can give you a map of the corneal thickness over a large area, and that thickness gradually increases as you move peripherally and the colors change similar to what we see on topography, but the colors on a pachymetric map actually represent changes in thickness as you go from one region to the next. We expect these to be relatively normal in a normal eye with circular changes, but in an eye with Fuchs' often what we see is a distortion of that pachymetric progression. We see some of the thinnest points will be more off center now because the cornea is actually swelling centrally from the guttae. We see a displacement of that thinnest center point and then we see a loss of regularity in

those isopachs and sometimes they appear more D-shaped or irregular. In our own retrospective analysis, what we've seen is that if you do DMEK on these patients, those shapes return to normal, which suggests that the endothelial cell function that's driving those changes is actually driving optical changes in the cornea as well.

In our study, I recommended looking at the posterior curvature of the cornea, which the Scheimpflug imaging is very good at—you can actually see the posterior axial or sagittal curvature map. Cornea surgeons are used to looking at the front map or the average map on the front and the back, but randomized controlled trials have defined that the biggest changes in the cornea as a result of Fuchs', and also after endothelial keratoplasty, are in the posterior cornea. If we look at the posterior cornea of a patient preoperatively and we see a large irregularity in the axial map, that can be a predictor of what's actually driving optical problems in the eye and may sway the surgeon to decide to do endothelial keratoplasty first or to combine it with cataract surgery. We also see those irregularities or distortions correct or normalize after endothelial keratoplasty is done, which again is a suggestion that the optical problems are being driven by the endothelial cell layer. ◀

1. Kinoshita S, Colby KA, Kruse FE. A close look at the clinical efficacy of rho-associated protein kinase inhibitor eye drops for Fuchs endothelial corneal dystrophy. *Cornea* 2021;40:10:1225-1228.
2. Chamberlain W, Shen E, Werner S, Lin C, Rose-Nussbaumer J. Changes in corneal power up to 2 years after endothelial keratoplasty: Results from the Randomized Controlled Descemet endothelial thickness Comparison Trial. *Am J Ophthalmol* 2023;245:233-241.
3. Sun SY, Wacker K, Baratz KH, Patel SV. Determining subclinical edema in Fuchs Endothelial Corneal Dystrophy: Revised classification using Scheimpflug tomography for preoperative assessment. *Ophthalmology* 2019;126:2:195-204.

ABOUT THE AUTHOR



Dr. Chamberlain is a professor of ophthalmology and chief of the division of cornea and refractive surgery at Casey Eye Institute, Oregon Health & Science University in Portland. He is an investigator in the Kowa trial.



Water, Water, Everywhere

Musings on life, medicine and the practice of ophthalmology.

MARK H. BLECHER
CHIEF MEDICAL EDITOR

The earth is mostly water—71 percent, to be exact. Our bodies are mostly water, between 45 to 70 percent depending on age, body habitus and hydration. Water is kind of important to life, yet I would guess that most of us don't really understand how fragile the flow of potable—or even irrigable—water is.

Water comes from basically three places: the sky; the Earth's surface; and below ground (duh). And its variability as a source is in that order from most variable to least. Also, depending on where you are and your local geography, the relative amounts can vary widely. When we talk about water availability we usually focus on rainfall as it's easy to see and measure. Less rain equals more drought. But more than half of our water is drawn from underground aquifers, and even more is drawn from that source in some areas than others. However, not all aquifers are created equal, and we're draining them far faster than they naturally recharge. So, at some point at current usage, they'll run dry. The Ogallala, underneath most of the Midwest, is our largest aquifer, and estimates are that 70 percent of it will be depleted in the next 50 years.

We can argue over exact numbers, but the fact remains we're using more water than is naturally replenished. That's an issue. It's an issue that's

already led to conflicts in some parts of the world and will likely lead to outright war in the future. It's more likely that we'll fight over water than oil.



Getty

At the moment, Arizona isn't liking California very much because of changes to water distribution from the Colorado river. So, what are we doing about it? We can conserve by using less and by evaluating the relative importance of the industries that use the most water. We can recycle water and we can generate fresh water. But we need to acknowledge the problem and address it together. It's insane that water conservation could be political. Yet some are making fun of low-flow toilets, bans on having a lawn in the desert, or restricting development where there isn't enough water already. I mean I love almonds, but to grow them you have to flood the fields in hot, dry California. Almonds alone use as much water as

all indoor water use in California. And almonds aren't the most water inefficient crop. Sugarcane is. The point of this is we have to look at everything we do to better manage available resources.

But conservation alone won't save this precious resource. We need to rethink everything about water, especially given that rainfall trends are falling, and the air is heating up. Yes, both of those are naturally occurring phenomena. The planet has gone through cycles, but it hasn't seen this much draw down of fresh water before. And it doesn't much matter why there's less rain, or warmer air. Arguing why it's occurring is secondary to acknowledging the reality and doing something about it, or our grandchildren won't have enough. You'd think that fact alone would motivate people, yet it doesn't.

We can create fresh water with desalination, at a cost of energy, of course, among other considerations. But these desalination plants can only work in certain areas, cost a lot to build and operate, and have a very long lead time to construct. They likely need to be a part of a multifaceted plan, along with conservation and recycling. And we need to take a hard look at allowing development in areas without water. Putting people in deserts without knowing how to provide sufficient water should be criminal. But it's not. Sometimes reality conflicts with what you want, and it's difficult to tell Americans what they can and can't do. The reality of continued development, a larger population and changing rainfall patterns is prodding us to act, but not quickly enough. The occasional flooding rain can make this difficult to reconcile, but we could find ourselves with water, water, everywhere and not a drop to drink. ◀

MATCHING PATIENTS WITH LASIK, SMILE OR PRK

How refractive surgeons identify the optimal candidates for these laser-vision correction procedures.

CHRISTINE YUE LEONARD
SENIOR ASSOCIATE EDITOR

Surgeons today have a number of corneal refractive procedures to offer and customize to patients' needs or specific anatomic considerations. But, as surgeons know, more options also mean many more factors to consider when it comes to patient selection, from corneal measurements and co-existing pathology to lifestyle and personality.

Here, experts share how they select patients for LASIK, SMILE and PRK, and the key inclusion and exclusion criteria that help narrow down the options.

Assessing the Cornea

Candidacy for a corneal refractive procedure begins with a thorough screening to ensure that the patient isn't at risk for ectasia, which can develop as a result of corneal biomechanical failure or external factors such as eye rubbing or laser vision correction itself. Beeran Meghpara, MD, co-director of the refractive surgery department at Wills Eye Hospital in Philadelphia, says the gold standard for ectasia screening

is Placido-based corneal topography, which helps to identify subtle areas of inferior steepening, but a host of other complementary modalities is also key.

"Nowadays, we go beyond topography and employ tomography (Pentacam) as well to look for elevation changes in the anterior and the posterior cornea," he explains. "Probably the newest modality we use is OCT epithelial mapping of the cornea, looking for areas of focal thinning. The corneal epithelium is remarkably uniform across the entirety of a patient's cornea and among patients in the general population. Very small changes in epithelial thickness are risk factors for, or potential early signs of, keratoconus. These changes may show up earlier on epithelial mapping than on some other imaging modalities, so all of my patients undergo evaluation with all three."

"The pachymetry, topography and manifest refraction are the three main factors I consider when screening patients, though there are many others to consider," says John Odette, MD, in practice at Austin Eye in Texas. "When I'm trying to decide whether a patient is a good candidate for a pro-

cedure, I start by ruling out patients who have significant corneal risk factors, such as a cornea with irregular topography, a prescription that's too high, and of course, a cornea that's too thin."

Kathryn M. Hatch, MD, director of the refractive surgery service and site director of Massachusetts Eye and Ear in Waltham carefully evaluates several factors when screening patients for laser vision correction. "On corneal topography and tomography, anterior and posterior corneal shape as well as the central corneal thickness are critical when screening patients," she says. "Additionally, it's important to assess for higher order aberrations and consider doing epithelial thickness mapping. "On Pentacam, I check for elevation changes and assess D-score, on the Belin/Ambrosio Enhanced Ectasia Display for keratoconus, which combines nine different keratometric indices and assigns a risk factor for keratoconus. It's usually white when it's normal, yellow when somewhat abnormal and red when clearly abnormal with an extremely high probability of keratoconus. Usually, if the number is less

This article has no commercial sponsorship.

Dr. Meghpara is a consultant for Zeiss and Johnson & Johnson Vision. **Dr. Hatch** is a consultant for Alcon, Zeiss and Johnson & Johnson Vision. **Drs. Silverstein** and **Odette** have no related financial disclosures.

than 1.6, it's safe; however, sometimes the D-score is white but one of the indices is red, and it might still look abnormal. You can't base your decision solely off this score, of course. It's important to look at the indices and the map itself for anything concerning on tomography."

Enough Tissue?

Surgeons must consider the degree of impact that a certain laser procedure would have on the cornea. As in years past, many say they would avoid performing such surgery in patients who have corneas thinner than 500 μm preoperatively.

"LASIK involves the most corneal manipulation of the three procedures since a flap is created in addition to tissue removal," says Dr. Meghpara. "With PRK, no flap is created, so less cornea is affected and treated. With more residual cornea, the biomechanical strength of the cornea is potentially greater compared with LASIK. However, creating this epithelial defect has its associated downsides, such as pain in the immediate postoperative period, a very low risk of haze and a longer healing time. SMILE's impact on the cornea is somewhere between the two. The incision is smaller than in LASIK, and no epithelial defect is created. SMILE usually creates less discomfort than LASIK and more rapid visual recovery than PRK."

There's ongoing debate about the best way to measure residual cornea, says Dr. Odette. Some surgeons go by residual stromal bed thickness while others go by the percentage of corneal tissue altered; many consider both. "I tend to lean toward residual stromal bed thickness, where potential candidates will have at least 300 μm ," he says.

Dr. Meghpara agrees. "Everyone has their own cut off as far as what the residual stromal bed thickness should be," he says. "The traditional number in the literature is 250 μm , but many surgeons including me are more conservative and like to have at

least 300 μm of residual stromal bed thickness.

"With PRK and SMILE, this amount is whatever amount of stroma is left over," he explains.

"With LASIK, we have to take into account the flap thickness as well as how much stroma is removed as a result of the treatment because the flap no longer contributes to the biomechanical strength of the cornea afterwards."

The percentage of tissue altered is a ratio of the amount of cornea altered (flap thickness plus ablation depth) divided by the total preoperative central corneal thickness. "If it's greater than 40 percent," Dr. Meghpara says, "then the procedure will increase the risk of ectasia. Generally, a patient with a PTA greater than 40 percent is a poor candidate for any of the treatments."

Selecting a Procedure

After corneal testing comes the question: What would you do in this patient? "Most patients who come into the clinic for a refractive surgery consultation are probably candidates for multiple procedures and would do fine with a number of them," says Dr. Meghpara. "Trying to explain the different options and which one is best for their lifestyle and recovery goals is the challenge. It's a lot easier if a patient would clearly do better with one option compared with another."

Experts say that LASIK is often the go-to procedure due to its safety and excellent visual outcomes. The treatment is approved for up to -12 D of myopia, up to +6 D of hyperopia and up to 6 D of astigmatism in patients over the age of 18. Many surgeons, however, prefer to wait until patients are in their mid-20s after their prescription has stabilized.

"LASIK has an amazing track record with very good results," Dr. Meghpara says. "In fact, among the general public, LASIK has become synonymous with any sort of laser vision correction procedure. Even if a patient didn't have LASIK—maybe

they had SMILE or PRK—they'll probably still tell their friends that they had LASIK. If someone's a good candidate for LASIK, that's generally the direction we'll go in."

"The vast majority of the time, 20- to 40-year-olds are great candidates for LASIK," Dr. Odette says. "Low to moderate myopes tend to be the best population, even if they have some mixed astigmatism. High myopes and hyperopes tend not to do as well with keratorefractive procedures, on the other hand."

"When a patient comes for a refractive surgery evaluation and they fit all the parameters of LASIK, we really don't have a conversation about other procedures because LASIK is typically the safest and most predictable procedure with the fastest healing," says Steven M. Silverstein, MD, an assistant professor of ophthalmology at the University of Missouri Kansas City Medical School and in practice at Silverstein Eye Centers in Kansas City.

Lifestyle Factors


Of course, LASIK isn't suitable for every patient. In addition to a too-thin cornea, certain lifestyle factors may rule out the option of LASIK due to concerns about flap complications. In these cases, PRK is often preferred. The procedure is approved to treat between -1 and -12 D of myopia, with up to 4 D of astigmatism, and between +1 and +6 D of hyperopia, with up to 4 D of astigmatism in patients over age 18.

"I consider work and recreational activities to be two of the most important aspects to ask patients about because that's where people spend the majority of their day," says Dr. Odette. "Activities such as contact sports, boxing and mixed martial arts, and certain careers such as construction, are risk factors for flap dislocation. If a patient has a high risk of being poked in the eye, a flap procedure might not be the best option."

Dr. Meghpara agrees, adding that professional athletes, police officers



CLAREON®
COLLECTION



THE CLAREON® COLLECTION IS COMPLETE

CLAREON® TORIC

Glistening-free* BioMaterial with unrivaled rotational stability† and predictable performance.1-6

CLAREON® VIVITY®

The first and only non-diffractive wavefront shaping PCIOL with exceptional clarity,2,3* monofocal-quality distance visual acuity, excellent intermediate vision, and functional near vision.4

CLAREON® PANOPTIX®

A full range of vision with exceptional clarity that lasts.7,8*

45%[§] of patients are willing to upgrade to an ATIOL, however, only **18%**^{||} are currently receiving one. Educate your patients on Alcon ATIOLs to meet their expectations.⁹

[Learn more at ClareonIOL.com](https://www.clareoniol.com)

* Defined as modified Miyata grade 0, <25mv/mm² over 3 years (n=138), and over 9 years (n=20), respectively. ATIOL=Advanced Technology IOL.

† In vitro comparison, P <0.05.

‡ Results from a prospective, randomized, parallel group, subject- and assessor-masked, multisite trial of 107 subjects bilaterally implanted with the AcrySof® IQ Vivity® Extended Vision IOL and 113 with the AcrySof® IQ IOL with 6 months follow-up.

¶ Snellen VA was converted from logMAR VA. A Snellen notation of 20/20-2 or better indicates a logMAR VA of 0.04 or better, which means 3 or more of the 5 ETDRS chart letters in the line were identified correctly.

§ N=297.

|| Q4 2022.

IMPORTANT PRODUCT INFORMATION: CLAREON® FAMILY OF IOLS

CAUTION: Federal law restricts these devices to sale by or on the order of a physician.

INDICATION: The family of **Clareon® intraocular lenses (IOLs)** includes the **Clareon® Aspheric Hydrophobic Acrylic** and **Clareon® Aspheric Toric IOLs**, the **Clareon® PanOptix® Trifocal Hydrophobic IOL**, **Clareon® PanOptix® Toric**, **Clareon® Vivivity® Extended Vision Hydrophobic Posterior Chamber IOL** and **Clareon® Vivivity® Toric IOLs**. Each of these IOLs is indicated for visual correction of aphakia in adult patients following cataract surgery. In addition, the **Clareon® Toric IOLs** are indicated to correct pre-existing corneal astigmatism at the time of cataract surgery. The **Clareon® PanOptix®** lens mitigates the effects of presbyopia by providing improved intermediate and near visual acuity, while maintaining comparable distance visual acuity with a reduced need for eyeglasses, compared to a monofocal IOL. The **Clareon® Vivivity®** lens mitigates the effects of presbyopia by providing an extended depth of focus. Compared to an aspheric monofocal IOL, the lens provides improved intermediate and near visual acuity, while maintaining comparable distance visual acuity. All of these IOLs are intended for placement in the capsular bag.

WARNINGS / PRECAUTIONS:

General cautions for all Clareon® IOLs: Careful preoperative evaluation and sound clinical judgment should be used by the surgeon to decide the risk / benefit ratio before implanting any IOL in a patient with any of the conditions described in the Directions for Use that accompany each IOL. Physicians should target emmetropia, and ensure that IOL centration is achieved.

For the **Clareon® Aspheric Toric**, **PanOptix® Toric** and **Vivivity® Toric IOLs**, the lens should not be implanted if the posterior capsule is ruptured, if the zonules are damaged, or if a primary posterior capsulotomy is planned. Rotation can reduce astigmatic correction; if necessary lens repositioning should occur as early as possible prior to lens encapsulation.

For the **Clareon® PanOptix® IOL**, some visual effects may be expected due to the superposition of focused and unfocused multiple images. These may include some perceptions of halos or starbursts, as well as other visual symptoms. As with other multifocal IOLs, there is a possibility that visual symptoms may be significant enough that the patient will request explant of the multifocal IOL. A reduction in contrast sensitivity as compared to a monofocal IOL may be experienced by some patients and may be more prevalent in low lighting conditions. Therefore, patients implanted with multifocal IOLs should exercise caution when driving at night or in poor visibility conditions. Patients should be advised that unexpected outcomes could lead to continued spectacle dependence or the need for secondary surgical intervention (e.g., intraocular lens replacement or repositioning). As with other multifocal IOLs, patients may need glasses when reading small print or looking at small objects. Posterior capsule opacification (PCO), may significantly affect the vision of patients with multifocal IOLs sooner in its progression than patients with monofocal IOLs.

For the **Clareon® Vivivity® IOL**, most patients implanted with the **Vivivity® IOL** are likely to experience significant loss of contrast sensitivity as compared to a monofocal IOL. Therefore, it is essential that prospective patients be fully informed of this risk before giving their consent for implantation of the **Clareon® Vivivity® IOL**. In addition, patients should be warned that they will need to exercise caution when engaging in activities that require good vision in dimly lit environments, such as driving at night or in poor visibility conditions, especially in the presence of oncoming traffic. It is possible to experience very bothersome visual disturbances, significant enough that the patient could request explant of the IOL. In the parent AcrySof® IQ Vivivity® IOL clinical study, 1% to 2% of AcrySof® IQ Vivivity® IOL patients reported very bothersome starbursts, halos, blurred vision, or dark area visual disturbances; however, no explants were reported.

Prior to surgery, physicians should provide prospective patients with a copy of the Patient Information Brochure available from Alcon informing them of possible risks and benefits associated with these IOLs.

ATTENTION: Reference the Directions for Use labeling for each IOL for a complete listing of indications, warnings, and precautions.

REFERENCES: 1. Werner L, Thatthamla I, Ong M, et al. Evaluation of clarity characteristics in a new hydrophobic acrylic IOL. *J Cataract Refract Surg.* 2019;45:1490-1497. 2. Oshika T, Fujita Y, Inamura M, Miyata K. Mid-term and long-term clinical assessments of a new 1-piece hydrophobic acrylic IOL with hydroxyethyl methacrylate. *J Cataract Refract Surg.* 2020 May;46(5):682-687. 3. Maxwell A, Suryakumar R. Long-term effectiveness and safety of a three-piece acrylic hydrophobic intraocular lens modified with hydroxyethyl-methacrylate: an open-label, 3-year follow-up study. *Clin Ophthalmol.* 2018;12:2031-2037. 4. Alcon Data on File, 2017. 5. Lane S, Collins S, Das KK, Maass S, Thatthamla I, Schatz H, Van Noy S, Jain R. Evaluation of intraocular lens mechanical stability. *J Cataract Refract Surg.* 2019 Apr;45(4):501-506. 6. Clareon® Vivivity® Extended Vision Hydrophobic IOL (CNWETO) Directions for Use – US. 7. Clareon® PanOptix® Trifocal Hydrophobic Acrylic IOL Model: CNWTO DFU. 8. Lehmann R, Maxwell A, Lubeck DM, Fong R, Walters TR, Fakadej A. Effectiveness and Safety of the Clareon® Monofocal Intraocular Lens: Outcomes from a 12-Month Single-Arm Clinical Study in a Large Sample. *Clin Ophthalmol.* 2021;15:1647-1657. Published 2021 Apr 20. 9. Alcon Data on File, 2022.

and individuals in the military are also unlikely to be suitable LASIK candidates for this reason. “We steer these individuals away from LASIK because of concerns that such activities could dislocate the flap,” he says. “PRK or SMILE may be better options.”

Recovery and Safety

“Choosing a refractive procedure for a patient requires a comprehensive approach,” Dr. Hatch says. “I go through an algorithm in my head each time, taking into account many different aspects, from personality and lifestyle to ocular anatomy.

“I like to think about LASIK and SMILE as one group and PRK in its own category from a healing perspective,” continues Dr. Hatch, who has been offering SMILE since its FDA approval. “Recovery is an important aspect of surgery to consider, and patients also really like the idea of a smaller incision. So, if a patient is a candidate for all three techniques, I usually offer SMILE as a first choice and always double consent for LASIK as well, so that in the rare situation that we can’t complete SMILE, we can convert to LASIK. I also use similar criteria for SMILE as for LASIK. The patient must be a good candidate for LASIK in order to offer them SMILE.

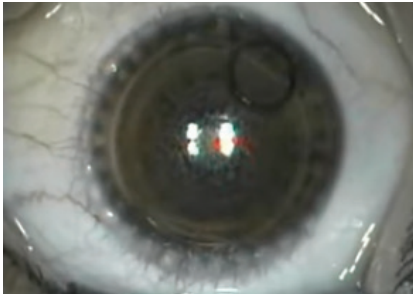
“I don’t believe SMILE is replacing LASIK or excimer lasers,” she adds. “I view it as an additive procedure that will help grow refractive surgery in general and allow surgeons to offer comprehensive refractive surgery procedures to patients.”

“LASIK has the quickest recovery time, so if a rapid recovery is important to the patient, and they’re a candidate, then LASIK may be the best option,” Dr. Meghpara says. “SMILE is next, and PRK has probably the slowest healing or visual rehabilitation time, but relatively speaking, it’s probably the safest of the three procedures. We have to assess where the patient falls on the scale of convenience versus safety. All three surgeries are very safe, but if we want to stack the deck in favor of safety, then PRK may be the best choice.”

“When safety is a principal factor, as far as not creating ectasia, then PRK and sometimes SMILE may be the only options,” Dr. Silverstein says. “That being said, patients generally prefer to heal and return to activities of daily living as quickly as possible, which is why LASIK remains the most popular refractive procedure we offer.”

SMILE’s treatment indications were expanded a few years ago to allow correction up to -10 D of myopia and up to 3 D of astigmatism for patients 22 and older. Dr. Silverstein says, “The SMILE procedure is equally beneficial for people with mild to moderate nearsightedness and mild to moderate astigmatism but there’s typically less opportunity or availability to access that particular machine or laser, with the excimer laser used for LASIK and PRK being much more widely available.”

“For the most part, anyone who’d be a good candidate



Uday Devgan, MD

An ink mark placed at the LASIK flap edge helps to ensure good flap realignment.

for PRK would be a good candidate for SMILE,” Dr. Meghpara says. “The reason I would choose to go with SMILE is that the vision recovers more quickly and there’s less postoperative discomfort. That being said, SMILE isn’t some magic procedure that can be done on everybody. If someone isn’t a good candidate for PRK, then they really shouldn’t be a candidate for SMILE either.”

Managing Expectations

Educating patients to ensure they have realistic goals is an important part of the refractive surgery journey. Dr. Hatch says that “sometimes managing patient expectations and setting them appropriately is the most difficult part.”

“Usually, after we get testing done, and after speaking with the patient, I can make a very good recommendation,” Dr. Odette says. “But once in a while, patients disagree and want something else done, so we have a discussion to figure out why they might want a procedure that may not be the best fit for them, and then figure out whether we could actually do that procedure safely.

“For particular type-A personalities,” Dr. Odette adds, “you need to have a little caution because sometimes these patients won’t like an outcome despite its being quite good.”

“Personality is a significant factor,” says Dr. Silverstein. “We have a very careful conversation and a sign-off by the patient about realistic expectations, including the potential

need for glasses for certain activities, especially reading and night driving in the presbyopic demographic. The patient has to know that they may still require glasses when driving in inclement weather, for example, even after a successful corneal-based refractive procedure. If their expectations can’t be appropriately maintained, they may not be a candidate for any refractive procedure.”

Ensuring older patients understand these visual compromises can be difficult, experts say. “This is a conversation that I have even with patients in their late 30s and early 40s who may need reading glasses within the next five years,” says Dr. Hatch. “Many times, patients will say they don’t need readers, or they already wear contacts, but won’t realize their contacts have a little bit of mini monovision. I find that once we actually put the prescription into the patient’s eyes, it most certainly increases the need for readers. Even when we tell patients again and again, it’s still hard for them to grasp because right now, they don’t need readers. It’s important for them to understand the progressive nature of presbyopia. It’s not a conversation you can hurry.”

Considerations and Contraindications

As with any surgical procedure, it’s important to ensure the risks don’t outweigh the benefits. Potential candidacy for LASIK, PRK and SMILE can be narrowed down beyond corneal parameters, lifestyle and age when medical and medication history—both ocular and systemic—are taken into consideration.

Here are some situations that raise a few red flags:

- **Progressive corneal thinning.** If a patient has any degree of keratoconus or pellucid marginal degeneration, they’re not a candidate for corneal refractive surgery.

“A patient with forme fruste keratoconus may still proceed with careful discussion and if their vision easily

corrects to 20/20 preoperatively,” Dr. Silverstein says. “You can still successfully achieve full correction in mild to moderate refractive cases with minimal risk of surgically induced ectasia. In forme fruste keratoconus, SMILE may be the best option for corneal stability postoperatively. Of course, a lens-based procedure would mitigate the risk of corneal ectasia in these patients, as would an ICL.”

He adds, “In a patient with topography demonstrating against-the-rule astigmatism in a sagging mustache pattern, I’d recommend against all corneal refractive procedures.”

Some surgeons have tried adding simultaneous cross-linking to corneal refractive surgery in order to reduce the risk of iatrogenic ectasia. A review of the current literature on simultaneous accelerated crosslinking reported that this treatment is effective for myopia but it’s still unclear whether the additional crosslinking step reduces ectasia incidence.¹

Dr. Silverstein says he doesn’t perform corneal cross-linking on these patients before a procedure. “First of all, the results of cross-linking aren’t predictable enough, and the long-term effects of cross-linking, as it pertains to refractive procedures and keratoconus isn’t known. I’ve successfully performed LASIK or PRK in forme fruste keratoconic patients many times without the development of ectasia over the last 25 years.”

- **Dry eye.** Dry eye can occur after any corneal refractive surgery, but it may be more severe if the patient has preexisting dry eye. Of the three corneal refractive procedures, LASIK carries the greatest risk for postoperative dry eye, with reported incidences of 94.8 percent, 85.4 percent and 59.4 percent of patients experiencing symptoms at one day, one week and one month, respectively.²

“Severe dry eye is a marked contraindication, and probably our second biggest worry after ectasia,” says Dr. Odette.

“Patients with poorly controlled dry eye shouldn’t undergo any sort

of laser vision correction or corneal refractive surgery unless they receive good, aggressive treatment for it,” agrees Dr. Meghpara. “For patients with a little bit of dry eye or mild dry eye that’s well controlled, we’d potentially avoid LASIK, as SMILE or PRK might be a better option for them.”

Surgeons say that it’s important to wait for the ocular surface to stabilize before performing a procedure. “I’ll treat lid margin disease and ocular surface disease aggressively for six weeks and then reevaluate,” Dr. Silverstein says. “We want to get good, accurate measurements and keratometry before proceeding.”

• **Epithelial basement membrane dystrophy.** EBMD affects the anterior cornea and may cause recurrent corneal erosions and lead to decreased vision. LASIK can worsen the condition.

Dr. Hatch says it’s important to perform a careful slit lamp evaluation to rule out EBMD. “This condition often has a subtle presentation and requires careful examination in every patient,” she explains. “I always check the cornea with fluorescein to assess for the negative staining pattern in addition to assessing the tear film.”

“In patients with EBMD, I typically recommend PRK,” she says. “EBMD can be easily missed and also cause problems preoperatively, intraoperatively and postoperatively, so we need to be very good observers of the epithelium.”

• **Stromal neovascularization.** Corneal neovascularization is a common complication of keratitis and occurs in a number of other pathologies, often leading to decreased visual acuity. “Caution should be used in patients with deep stromal neovascularization, especially when it involves more than one quadrant of vessels,” Dr. Silverstein says.

• **Significant corneal scarring.** “Patients with significant scarring involving the central visual axis who don’t correct to 20/20 may not be good

candidates for refractive procedures,” says Dr. Silverstein. “Other poor candidates may include those with significant anterior stromal scarring from EBMD or those with significant Salzmann’s dystrophy. If the visual axis is uninvolved, which is usually not the case in these two situations, SMILE may be an option.”

• **Corneal guttata.** “If a patient has stable, mild to moderate dystrophy with one to two or more corneal guttae, they could undergo successful LASIK, PRK or SMILE,” Dr. Silverstein says. “However, patients with three or more guttae with any element of endothelial pathology or corneal swelling shouldn’t have a corneal-based procedure.”



It’s important to approach patients with a comprehensive refractive mentality.

— Kathryn M. Hatch, MD



• **Prior radial keratotomy or LASIK.** “If a patient has had RK, I lean toward PRK because I don’t like to make a flap into RK incisions,” Dr. Odette says. “I know many doctors who’ve successfully made flaps into old RK incisions, so I know it can be done, but it’s not my favorite approach. Doing PRK over an old LASIK flap can be problematic as well, with epithelial hyperplasia. There’s no perfect answer on what to do with prior LASIK—do you lift the flap and risk epithelial ingrowth, or do you do PRK over the top? Neither is perfect, unfortunately.”

• **Prior corneal graft.** Dr. Odette says he prefers not to perform corneal refractive procedures over corneal grafts. “I have done a couple PRKs over corneal grafts, but it’s very rare. There’s a risk for graft rejection, so I really lean away from that and don’t recommend it.”

• **Retinal disease.** Dr. Silverstein says it’s important to perform a fully dilated posterior segment exam when screening patients for refractive surgery. “If a patient has significant macular disease, such as macular scarring or soft fluid drusen from macular degeneration, significant diabetic retinopathy or history of vascular occlusive disease (beyond a mild branch retinal vein occlusion in the past, greater than six months prior with a return to 20/20 vision), these patients should be counseled against refractive procedures, not because of safety concerns but because they’ll achieve a less than desired visual outcome.”

• **Glaucoma.** Refractive surgery poses some risks for glaucomatous eyes. During LASIK flap creation, the elevated eye pressure may damage the optic nerve. Additionally, postoperative steroid use, especially after PRK, runs the risk of a patient developing steroid-induced glaucoma. Experts say that SMILE or PRK may be safer for glaucomatous eyes since no flap is involved. Refractive surgery that thins the cornea may also lead to underestimation of IOP on Goldmann applanation tonometry.

• **Pregnancy and lactation.** “Pregnancy and nursing are contraindications for refractive surgery because the patient’s prescription or refraction changes postoperatively,” Dr. Meghpara says.

These changes in the eye’s refractive index are thought to be caused by hormonal changes that cause fluid retention in the cornea³ or by an increase in lens curvature that leads to a myopic shift.⁴ “Patients should wait at least six months from when they delivered their child and three months after they stop nursing to undergo a procedure,” he says.

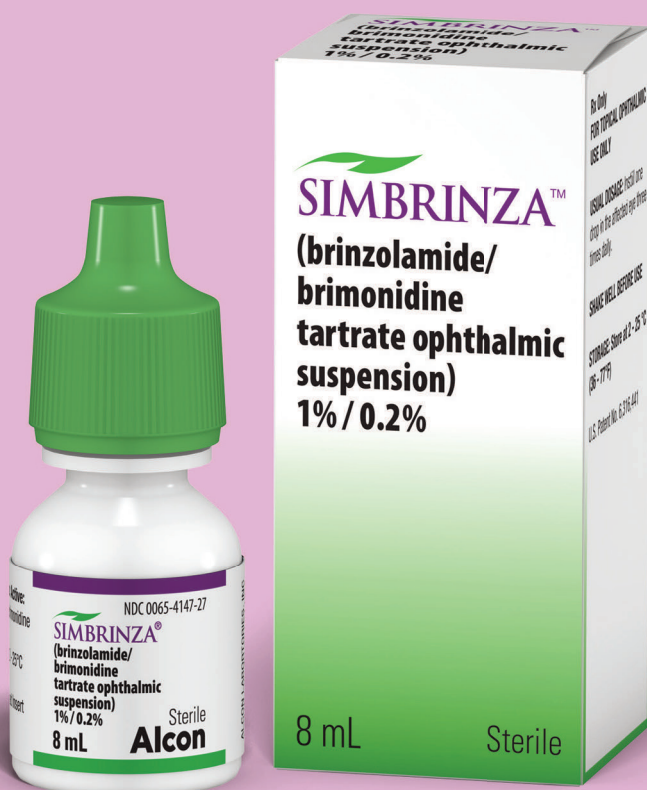• **Systemic diseases.** Autoimmune conditions are often listed among the considerations or contraindications for corneal refractive surgery because their immunosuppressive treatments may hinder the body’s healing re-

HAVE YOU TRIED?



SIMBRINZA[®]

(brinzolamide/brimonidine
tartrate ophthalmic suspension)
1%/0.2%



Talk to your **Alcon sales representative** to find out more.

sponses. Examples include Sjogren's syndrome, type-1 diabetes, systemic lupus erythematosus and rheumatoid arthritis.

"I'd be very hesitant to perform a corneal procedure on a patient being treated for rheumatoid arthritis," Dr. Silverstein says. "Not necessarily a diagnosis of rheumatoid arthritis but being treated systemically for it would be a contraindication.

"Patients who are on systemic treatment for thyroid eye disease need to be consulted about the significance of dry eye caused by LASIK," he adds. "Having abnormal anatomy, where the cornea isn't properly covered and protected, would exclude a patient from corneal refractive procedures."

"Some surgeons consider many autoimmune diseases as red flags or contraindications," Dr. Odette says. "I consider them mild contraindications because many patients with autoimmune diseases are asymptomatic and do quite well with refractive surgery, though I know that that's debated."

"If a patient with an autoimmune condition is well controlled and their dry eye is similarly well controlled, I might avoid LASIK and do SMILE or PRK instead," Dr. Hatch says. "These procedures may have less drying potential and risk for dry eye."

Non-LVC Candidates

Patients who aren't candidates for corneal refractive surgery still have options. In addition to intraocular lenses, experts say implantable collamer lenses or a refractive lens exchange are options:

- **Implantable collamer lenses.** The EVO ICL (Staar) is an artificial lens made of collagen and plastic that's suitable for patients with moderate to high myopia under the age of 50 who don't have cataracts. The lens is implanted between the natural crystalline lens and the iris. Experts say ICLs may be good options for patients with more severe dry-eye disease.

"Now that we have the EVO ICL,

we have more options for patients who have corneal pathology or who may not be the best laser vision correction candidate," Dr. Hatch says. "It's a one-step procedure with no need to perform peripheral iridotomies."

Dr. Silverman says, "An ICL may be the best option for patients who have significant nearsightedness (greater than 6 D) with mild to moderate astigmatism, and for whom a corneal-based procedure isn't appropriate—perhaps due to corneal pathology such as Salzmann's nodules, which can recur even after removal."

- **Refractive lens exchange.**

Experts say that depending on the patient's age and anatomic considerations, a refractive lens exchange with or without femtosecond laser assistance may be a good long-term option.

Dr. Silverstein explains, "For patients in their 50s or older who are presbyopic with mild or greater cataract, this option offers the potential for multifocal lenses that give more range of vision or the Light Adjustable Lens, which can be adjusted after implantation and appropriate corneal healing in order to achieve high postoperative accuracy and predictability in the final refractive outcome."

"Now that we have such advanced IOL technologies, I think it's even more important that we approach the patient with a comprehensive refractive mentality," Dr. Hatch says. "When we see patients 50 and older, for example, with moderately high amounts of refractive error including hyperopia, myopia and astigmatism, we should talk to them about refractive lens exchange. Patients should know there are many different options for treating their presbyopia in addition to their other refractive errors.

"When I have patients come in who are in their 50s—even if they're not interested in a refractive lens exchange and don't have signs of lens changes yet—I still always ask

questions about their vision when they drive at night or in inclement weather," she continues. "I ask whether it's challenging and whether they've noticed any increased difficulty. These are very early indicators that some lens-based changes are happening. I tell these patients, 'If we do laser vision correction on you, this won't improve. In fact, your vision may stay the same or get worse.'

"This can be a determining factor for those with early lens changes," she says. "We may want to advise patients to wait until their cataract develops more. Or, if the patient is really excited or ambitious about having their vision corrected, then doing a refractive lens exchange in older patients may be the best way to go."

Dr. Hatch says she doesn't generally consider performing a refractive lens exchange in a patient under 50. "Patients who are in their forties still have accommodation and attached vitreous, so I tend to wait until they're a bit older," she explains. "That said, I do think we have to approach patients from a comprehensive mentality and explain all the possible options, even those that might open up down the road, and even if you don't offer refractive lens exchange. We also need to make sure they understand the implications of having had prior laser vision correction at the time of cataract surgery. The impact the laser has on their cornea can affect what implant technology we might be able to offer them at the time of cataract surgery due to the shape change of the cornea. Keratometry shape, as we know, is so critical in the IOL selection. ◀

1. Lim EW and Lim L. Review of laser vision correction (LASIK, PRK and SMILE) with simultaneous accelerated corneal crosslinking—Long-term results. *Curr Eye Res* 2019;44:11:1171-1180.
2. Sharma B, Soni D, Saxena H, et al. Impact of corneal refractive surgery on the precorneal tear film. *Indian J Ophthalmol* 2020;68:12:2804-2812.
3. Ebeigbe JA, Ebeigbe PN, Ighoroje AD. Ocular changes in pregnant Nigerian women. *Nigerian J Clin Pract* 2011;15:298-301.
4. Yenerel NM and Küçümen RB. Pregnancy and the eye. *Turk J Ophthalmol* 2015;45:5:213-219.

HOW TO MAKE PHACO MORE EFFICIENT

A look at the modern technology and machine functions that can increase efficiency during phacoemulsification.

ANDREW BEERS
ASSOCIATE EDITOR

Everyone's probably heard the phrase "work smarter, not harder" at least once in their lives. While the basic principles of phaco haven't changed, the technology used for it has advanced over the years, providing surgeons with various options to efficiently improve their operations and work smarter. Here, cataract surgeons provide insight into the latest technology advancements and how they use them to achieve greater efficiency in their cataract procedures.

Machine Settings: Best Practices

There are many different brands and models of phaco machines on the market, but they all come with the same basic settings: power; vacuum; and aspiration flow rate. Normally, a representative from the phaco machine manufacturer will visit a physician's office or operating room to program the machine settings. But, in most cases, the settings can be easily altered pre-

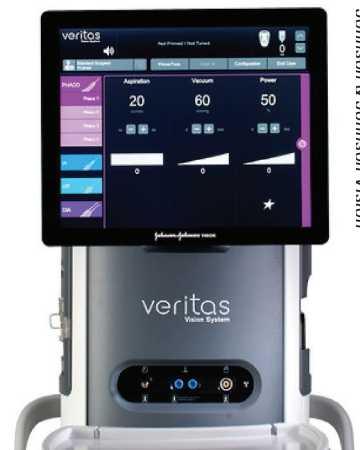intra- and/or postoperatively.

"For each step of the procedure, you'd dial in different parameters," says Kevin Miller, MD, the Kolokotronis Chair in Ophthalmology at UCLA. Dr. Miller received his undergraduate degree in bioengineering from John Hopkins University and consults for many companies in the phaco industry. Because of his technical background, Dr. Miller finds himself modifying his machine settings regularly. "I'm one of those people that likes to tweak things. If I'm struggling at some point in the procedure, then I'll make little tweaks. As I finish the case, and if I like those tweaks, then I'll save them so that they're permanent."

Dr. Miller understands that the factory settings on phaco machines are standardized for cataract surgery, which leads to many surgeons losing efficiency during operation. He says, "I do know that the vast majority of surgeons, once the phaco specialist comes in and sets up the machine and after the surgeon goes through their first five cases, they will never touch the settings. They'll come back 10 years later, and it'll have the

same settings."

To increase efficiency during cataract surgery, Dr. Miller suggests more vacuum, more phaco power and more aspiration flow rate. "That allows you to blast through the cataract, get it out of the eye and rip it out really fast," he says. "But those very same settings that allow



Johnson & Johnson Vision

Veritas' settings are toggled via the touchscreen. Twenty setup options can be programmed onto the machine. The default settings, "Advanced Fluidics Program" and "Advanced Infusion Program," are available on the touchscreen as well.

This article has no commercial sponsorship.

Dr. Miller consults for Alcon and Johnson & Johnson Vision. Drs. Waite and Parker have no financial interests in the products discussed.


you to go faster actually reduce the safety of the procedure. All it takes is for one bad capsule and you could just throw away any efficiency gains that you had gotten for that day.”

If increasing settings reduces safety, then what’s a good practice to adjust settings without jeopardizing a patient’s safety? Aaron Waite, MD, from Waite Vision in Utah, sets his phaco machine, Oertli’s CataRhex 3, to toggle between different settings using the foot pedal. “When you do something as precise as eye surgery you want to make sure your settings are set for all comers,” he says. “Set the settings for the densest lens you’re going to encounter, and then you have the modification of the power to use only when you want. So, if a patient comes in and they have a super dense lens, I’m all ready to go. If they’ve got a soft lens, piece of cake.

“Anytime you’re around a new machine, you have to realize you’re going to have to optimize the settings for you as a surgeon,” Dr. Waite continues. “For example, I’ve used a couple of really good machines that I wasn’t happy with because the settings weren’t optimized, but I know if I had the time to sit down and play with the machine, then I’d probably be completely satisfied with those machines.”

Dr. Miller explains why he believes surgeons are hesitant to touch the machine settings. “[A phaco machine is] a versatile tool with a lot of settings that you can adjust, but most people are afraid to touch them because [they’re afraid to break the device],” he says. “It’s like an 80-year-old who gets an iPhone who doesn’t want to break the phone by pressing on the icons. You can’t break it. You push on it and things pop up, you press on other things and more stuff pops up. You play with it and then eventually you figure out how the phone works. Same thing with a phaco machine. So, there are all these little things

Kevin Miller, MD



In April, during an Alcon Advanced Cataract Surgery Course in Irvine, Calif., surgical residents learned about the technology for the Centurion system. Residents could test the settings and functions of the machine.

you can tweak to make it more comfortable for the patient, optimize your efficiency, and also balance it out with safety. But, it means overcoming the fear of breaking the machine by touching it and getting below the settings. And most of the companies—I would say all the companies—have phaco specialists who would be happy to come back and help you optimize your settings based on how they see the cases that you’re doing.”

Some surgeons find the default settings to be comfortable and familiar to their practice. Vestavia, Alabama’s Jack Parker, MD, believes adjusting the settings can cause issues cognitively when using the machine. “Usually, I don’t do very much adjustment intraoperatively,” he says. “The reason is that once you start fiddling around with things a little bit, you sort of just lose your sense of predictability about what’s happening and then you become a little less familiar of what’s going on at what speed. So, typically I’m more comfortable just leaving everything alone during the case.”

Dr. Miller says that, though the phaco settings are important, they’re

not the end-all be-all when it comes to total efficiency. “The 30,000-foot-view issue is that for most surgeons, the nucleus removal only takes about a minute, so it’s pretty quick no matter how you do it,” he says. “No matter how unsophisticated you are, or how geeky you are, you’re talking about a minute, plus or minus a little bit, for most people to get through the nucleus removal. So, if you’re really trying to eke out efficiency, how much additional time can you shave off of that minute, and do those few seconds really make a difference in terms of the number of cases you’re going to do on a given day? Probably not. I would say most efficiency gains in surgery will have nothing to do with phaco settings. Even though we obsess about it, and there are things you can do to get through the phaco part faster, in the grand scheme of things, they probably don’t amount to a hill of beans.”


Longitudinal, Torsional and Transversal

Years ago, phaco companies altered the movement of the phaco probe in an effort to gain more efficiency and




CLAREON®
COLLECTION

THE CLAREON® COLLECTION IS COMPLETE



CLAREON® VIVITY® The first and only non-diffractive wavefront shaping PCIOL with exceptional clarity,^{1,2*} monofocal-quality distance visual acuity, excellent intermediate vision, and functional near vision.^{3†}



CLAREON® PANOPTIX®

A full range of vision with exceptional clarity that lasts.^{4,5*}

Alcon's unique PCIOL portfolio helps you offer patients full range of vision with both diffractive and non-diffractive IOLs.

Learn more at [ClareonIOL.com](https://www.clareoniol.com)

* Defined as modified Miyata grade 0, <25mv/mm² over 3 years (n=138), and over 9 years (n=20), respectively. PCIOL=Presbyopia Correcting IOL.

† Results from a prospective, randomized, parallel group, subject- and assessor-masked, multisite trial of 107 subjects bilaterally implanted with the AcrySof® IQ Vivity® Extended Vision IOL and 113 with the AcrySof® IQ IOL with 6 months follow-up.

‡ Snellen VA was converted from logMAR VA. A Snellen notation of 20/20-2 or better indicates a logMAR VA of 0.04 or better, which means 3 or more of the 5 ETDRS chart letters in the line were identified correctly.

IMPORTANT PRODUCT INFORMATION: CLAREON® FAMILY OF IOLS

CAUTION: Federal law restricts these devices to sale by or on the order of a physician.

INDICATION: The family of **Clareon® intraocular lenses (IOLs)** includes the **Clareon® Aspheric Hydrophobic Acrylic** and **Clareon® Aspheric Toric IOLs**, the **Clareon® PanOptix® Trifocal Hydrophobic IOL**, **Clareon® PanOptix® Toric**, **Clareon® Vivity® Extended Vision Hydrophobic Posterior Chamber IOL** and **Clareon® Vivity® Toric IOLs**. Each of these IOLs is indicated for visual correction of aphakia in adult patients following cataract surgery. In addition, the **Clareon® Toric IOLs** are indicated to correct pre-existing corneal astigmatism at the time of cataract surgery. The **Clareon® PanOptix®** lens mitigates the effects of presbyopia by providing improved intermediate and near visual acuity, while maintaining comparable distance visual acuity with a reduced need for eyeglasses, compared to a monofocal IOL. The **Clareon® Vivity®** lens mitigates the effects of presbyopia by providing an extended depth of focus. Compared to an aspheric monofocal IOL, the lens provides improved intermediate and near visual acuity, while maintaining comparable distance visual acuity. All of these IOLs are intended for placement in the capsular bag.

WARNINGS/PRECAUTIONS:

General cautions for all Clareon® IOLs: Careful preoperative evaluation and sound clinical judgment should be used by the surgeon to decide the risk/benefit ratio before implanting any IOL in a patient with any of the conditions described in the Directions for Use that accompany each IOL. Physicians should target emmetropia, and ensure that IOL centration is achieved.

For the **Clareon® Aspheric Toric**, **PanOptix® Toric** and **Vivity® Toric IOLs**, the lens should not be implanted if the posterior capsule is ruptured, if the zonules are damaged, or if a primary posterior capsulotomy is planned. Rotation can reduce astigmatic correction; if necessary lens repositioning should occur as early as possible prior to lens encapsulation.

For the **Clareon® PanOptix® IOL**, some visual effects may be expected due to the superposition of focused and unfocused multiple images. These may include some perceptions of halos or starbursts, as well as other visual symptoms. As with other multifocal IOLs, there is a possibility that visual symptoms may be significant enough that the patient will request explant of the multifocal IOL. A reduction in contrast sensitivity as compared to a monofocal IOL may be experienced by some patients and may be more prevalent in low lighting conditions. Therefore, patients implanted with multifocal IOLs should exercise caution when driving at night or in poor visibility conditions. Patients should be advised that unexpected outcomes could lead to continued spectacle dependence or the need for secondary surgical intervention (e.g., intraocular lens replacement or repositioning). As with other multifocal IOLs, patients may need glasses when reading small print or looking at small objects. Posterior capsule opacification (PCO), may significantly affect the vision of patients with multifocal IOLs sooner in its progression than patients with monofocal IOLs.

For the **Clareon® Vivity® IOL**, most patients implanted with the **Vivity® IOL** are likely to experience significant loss of contrast sensitivity as compared to a monofocal IOL. Therefore, it is essential that prospective patients be fully informed of this risk before giving their consent for implantation of the **Clareon® Vivity® IOL**. In addition, patients should be warned that they will need to exercise caution when engaging in activities that require good vision in dimly lit environments, such as driving at night or in poor visibility conditions, especially in the presence of oncoming traffic. It is possible to experience very bothersome visual disturbances, significant enough that the patient could request explant of the IOL. In the parent AcrySof® IQ Vivity® IOL clinical study, 1% to 2% of AcrySof® IQ Vivity® IOL patients reported very bothersome starbursts, halos, blurred vision, or dark area visual disturbances; however, no explants were reported.

Prior to surgery, physicians should provide prospective patients with a copy of the Patient Information Brochure available from Alcon informing them of possible risks and benefits associated with these IOLs.

ATTENTION: Reference the Directions for Use labeling for each IOL for a complete listing of indications, warnings and precautions.

REFERENCES: 1. Oshika T, Fujita Y, Inamura M, Miyata K. Mid-term and long-term clinical assessments of a new 1-piece hydrophobic acrylic IOL with hydroxyethyl methacrylate. *J Cataract Refract Surg.* 2020 May;46(5):682-687. 2. Maxwell A, Suryakumar R. Long-term effectiveness and safety of a three-piece acrylic hydrophobic intraocular lens modified with hydroxyethyl-methacrylate: an open-label, 3-year follow-up study. *Clin Ophthalmol.* 2018;12:2031-2037. 3. **Clareon® Vivity® Extended Vision Hydrophobic IOL (CNWETO) Directions for Use – US.** 4. **Clareon® PanOptix® Trifocal Hydrophobic Acrylic IOL Model: CNWTT0 DFU.** 5. Lehmann R, Maxwell A, Lubeck DM, Fong R, Walters TR, Fakadej A. Effectiveness and Safety of the Clareon® Monofocal Intraocular Lens: Outcomes from a 12-Month Single-Arm Clinical Study in a Large Sample. *Clin Ophthalmol.* 2021;15:1647-1657. Published 2021 Apr 20.

Alcon

Feature PHACO MACHINES

safety. Most phaco machines use longitudinal ultrasound to breakdown the nucleus in the lens. Other platforms like Alcon's Centurion and Johnson & Johnson Vision's Veritas use different forms of ultrasound to reduce thermal energy during surgery. Here's a review of these alterations and what they bring to the table.

Transversal ultrasound, found in the Veritas system, minimizes chatter from the nuclear fragments that are being emulsified. This type of modulation results in the ability of a "side-to-side" movement that may reduce the frictional heat commonly generated by longitudinal movement, according to the company.¹ Alcon says the torsional oscillation effect found in the Centurion system reduces the amount of energy and increases the efficiency required to remove the nucleus by fragmenting the cataract via shearing, in place of the conventional jackhammer effect from longitudinal ultrasound.¹

"There's an efficiency advantage of having pure torsional over pure longitudinal," says Dr. Miller. "In pure longitudinal, the phaco needle basically pistons forward and backward at about 40 kHz. The tip, virtually at full throttle, pistons at about 3.5 mL/min at 40 kHz. With torsional, it's different. For the exact same amount of energy applied into the eye, there's twice as much cutting. So, that's obviously more efficient." Although the frequency of torsional phaco is lower than longitudinal phaco at 32 kHz to 40 kHz, at least one study found that the reduction of the repulsive effect and cutting in the lateral direction by torsional phaco make it efficient.²

J&J's Veritas doesn't use pure transversal ultrasound, but rather a combination of longitudinal and transversal movements.³ In a 2023 study, researchers compared the grooving efficiency between longitudinal and transversal ultrasound handpieces. They didn't observe a significant difference in grooving time between the two phaco probes. Transversal ultrasound had a statistically significant decrease in time as the power settings were increased from 25 to 75 percent (5.22 ±0.758 and 4.63 ±0.69 seconds).⁴ However, researchers speculated that transversal can be more efficient than longitudinal phaco due to increased chatter from longitudinal movements.⁴

Phaco Machines

No two phaco machines are exactly the same, and various models provide features that can increase efficiency when performing phacoemulsification.

• **Bausch + Lomb Stellaris Elite.** Bausch + Lomb's Stellaris Elite Microsurgical System offers both cataract and retina capability in a single platform. The machine features B+L's Adaptive Fluidics with dynamic infusion compensation, which the company says monitors and compensates fluid flow in the eye. B+L says that efficiency gains in fluidics stem from the rotary vane pump that features a low start-up torque and high-flow

capability. Furthermore, instead of traditional longitudinal, the Stellaris uses “Attune” energy. B+L says that this form of energy uses longitudinal ultrasound but combines it with acoustic cavitation technology. Acoustic cavitation is the growth and collapse of preexisting microbubbles under the influence of an ultrasonic field in liquids.⁸

The Stellaris uses a touchscreen display to control machine parameters. Here, surgeons can access phaco power, aspiration flow rate, vacuum and more. Phacoemulsification frequency runs at up to 28.5 kHz with a pulse mode range of 1 to 250 pulses per second. Irrigation can be manipulated using either gravity, pressurized air or both. Air pressure maxes out at 100 mmHg and the vacuum can fluctuate between 0 and

600 mmHg.

The Stellaris is equipped with vitreous removal. B+L’s Bi-Blade vitrectomy cutter is a dual-edge blade that effectively cuts at 15,000 CPM. Another retina feature specific for the Stellaris is the Vitesse hypersonic vitrectomy system. This system produces high-frequency longitudinal vibrations that aim to liquify vitreous, as opposed to a traditional guillotine vitrectomy system that cuts vitreous at a high rate.⁹

• **Alcon Centurion.** The Centurion Vision System is similar to the Alcon Infiniti Vision System. The Centurion is equipped with torsional phaco, and features the “Active Sentry” handpiece. According to Alcon’s website, this handpiece has a built-in pressure sensor that regulates IOP and chamber stability.

“With the Centurion, I have a chop which is on continuous, a chop which is on burst, and a quad which is on pulse,” says Dr. Waite. “The other thing is that it has torsional and longitudinal phaco. So, the phaco tip has sort of a bend to it so if you twist it, [it phacoemulsifies the cataract], where if you have a straight tip and twist it, it does nothing. So, the torsional phaco can only work with a certain type of phaco tip, but the Alcon machine uses what the company calls ‘intelligent phaco,’ which is predominately torsional, but then it kicks into longitudinal once you have occlusion.”

The Centurion begins to become more efficient when torsional power reaches 60 percent.⁵ This occurs when the machine’s vacuum is set at 550 mmHg, aspiration at 50ml/min, and IOP at 50 mmHg.⁵ During a 2016 study, researchers found no efficiency gains after increasing the torsional power above 60 percent. They reported that chatter was highest at 10-percent power and decreased linearly as power was increased up to 60 percent, and chatter didn’t improve above this power level.⁵

• **Johnson & Johnson Vision Veritas.** The Veritas features a dual pump fluidics system, which J&J says increases phaco efficiency by allowing surgeons the ability to switch between peristaltic and Venturi pumps and adapt to clinical needs.

In order to optimize the Veritas system for surgery, researchers determined the most efficient settings for both available pump types. During an *in vitro* laboratory study, researchers hardened porcine lens nuclei with formalin to simulate a human cataract lens.⁶ Using a Venturi pump, researchers concluded that the phaco system became most efficient when the bottle height was set at 100 cm, the vacuum was set to 600 mmHg, and the power was set to 80 percent.⁶ Aspiration flow rate wasn’t measured during the study.

In a separate study using porcine



Kevin Miller, MD

Surgical residents in Southern California test the settings of Bausch + Lomb’s Stellaris Elite. These are not recommended settings, but rather an example of the settings and features presented on the machine.

lens nuclei, researchers determined the most efficient settings with a peristaltic pump attached to the Veritas. They concluded that setting the bottle height at 100 cm, vacuum at 600 mmHg, aspiration rate of 50 or 60 mL/min, and power at 90 percent provided the most efficient parameters.⁷

• **Oertli CataRhex 3.** “There isn’t a traditional software operating system on the CataRhex. It’s a direct push of a button to function, like a handheld calculator. This means there are no software glitches, problems, or updates, and due to this approach, the CataRhex is remarkably low maintenance,” says Dr. Waite. Oertli describes its phaco machine, the CataRhex 3, as compact and portable. The device itself weighs 11 lbs., and all connections and features can be accessed on the front of the device. Also, the CataRhex is equipped with Oertli’s Speep pump, which is a peristaltic-Venturi pump hybrid. The pump allows for surgeons to independently control both the flow and vacuum.

The CataRhex 3 allows surgeons to toggle between what it calls Phaco 1, 2 and 3. Dr. Waite worked closely with an Oertli representative to choose specific parameters



Oertli offers optional accessories such as a carrying case, a sterile touching device and an infusion pole to make the CataRhex 3 simpler to transport, set up and operate in most clinics.

that fit his needs for each phaco settings. “What I use for my Phaco 1, we’re going to call that one ‘sculpt,’ is continuous phaco at 60 percent, flow at 18mL/min and the vacuum set to 100 mmHg. Phaco 2, which is ‘chop,’ is in a burst mode. The burst’s power is at 70 percent, the flow is at 40mL/min and the vacuum is at 475 mmHg. Phaco 3 is the ‘quad’ setting. That’s in a pulse mode. Pulse is at 55 percent, flow is at 40 mL/min and the vacuum is at 565 mmHg,” he says.

Dr. Parker is also a CataRhex 3 user. “We use a low vacuum usually between 60 and 100 mmHg and a higher phaco power: about 80 percent. Flow is usually about 10 mL/min,” he says. “The settings that I quoted aren’t particularly aggressive; they’re the default settings recommended by the company.”

• **DORC EVA System.** Dutch Ophthalmic Research Center offers the EVA Nexus, an ophthalmic surgical system, with the upgraded phaco-vitreotomy system. The integrated footswitch comes with six programmable buttons that allow surgeons the ability to switch between phaco and vitrectomy surgeries. The company offers customizable inlays to allow for alternative foot positions and comfort. Surgeons can control the device’s vacuum and flow using Vacuflow VTi technology. This eliminates the risk of unwanted pulses or flow. The vacuum runs between 0 to 680 mmHg and the flow runs between 0 to 90 mL/min.

The EVA platform is meant for both phacoemulsification and vitrectomy. The vitrectomy handpiece cuts at a max speed of 16,000 CPM, but surgeons can opt for a different device. DORC’s TDC cutter has a cut speed of up to 8,000 CPM and is designed to facilitate cutting tissue on the return of each stroke of the vitrectome. For phacoemulsification, phaco pulse mode runs at a maximum 250 PPS at 40 kHz. In the EVA EquipPhaco platform, DORC provides disposable and reusable

phaco tips in four sizes: 1.8 mm; 2.2 mm; 2.4 mm; and 2.8 mm.

The latest phacoemulsification technology is continuously being advanced through the numerous phaco platforms on the market. “I think the phaco machines of the future will have a little bit of AI, or smart programming, in it to figure out if you’re struggling. It’ll learn how to auto adjust for you so that it happens intuitively. I think things like that will happen down the road,” Dr. Miller speculates. “Things like that smart software that will be running in the background will make novice surgeons look like more experienced surgeons because it’s going to help optimize the technology portion of what they’re doing. But the technology isn’t there, yet. We’re still in the phase where you have to set the things yourself.” ◀

1. Assil KK, Harris L, Cecka J. Transverse vs torsional ultrasound: Prospective randomized contralaterally controlled study comparing two phacoemulsification-system handpieces. *Clin Ophthalmol* 2015;9:1405-11.
2. Kim DH, Wee WR, Lee JH, Kim MK. The comparison between torsional and conventional mode phacoemulsification in moderate and hard cataracts. *Korean J Ophthalmol* 2010;24:6:336-40.
3. Quesada G, Chang DH, Waltz KL, Kao AA, Quesada R, Wang Y, Ji L, Parizadeh D, Atilas L. Clinical performance and surgeon acceptability of a new dual mode phacoemulsification system. *Clin Ophthalmol* 2022;16:2441-2451.
4. Wilkinson SW, Ungricht EL, West WB, Harris JT, Zaugg B, Olson RJ, Pettey JH. Comparison of phacoemulsification grooving efficiency in longitudinal vs transversal handpieces. *Clin Ophthalmology* 2023;17:191-195.
5. Jensen JD, Shi DS, Robinson MS, Kramer GD, Zaugg B, Stagg BC, Pettey JH, Barlow WR Jr, Olson RJ. Torsional power study using Centurion phacoemulsification technology. *Clin Exp Ophthalmol* 2016;44:8:710-713.
6. Wright AJ, Thomson RS, Bohner AD, Bernhisel AA, Zaugg B, Barlow WR, Pettey JH, Olson RJ. Optimization of venturi mode phacoemulsification settings of the Abbott Medical Optics WhiteStar Signature Pro in a porcine lens model. *Int J Ophthalmol Clin Res* 2017;4:077.
7. Wright DD, Wright AJ, Boulter TD, Bernhisel AA, Stagg BC, Zaugg B, Pettey JH, Ha L, Ta BT, Olsen RJ. Optimization of transversal phacoemulsification settings in peristaltic mode using a new transversal ultrasound machine. *JCRS* 2017;43:9:P1202-1206.
8. Ashokkumar M. The characterization of acoustic cavitation bubbles - an overview. *Ultrasonic Sonochemistry* 2011;18:4:P864-872.
9. Stocchino A, Nepita I, Repetto R, Doderio A, Castellano M, Ferrara M, Romano MR. Fluid dynamic assessment of hypersonic and guillotine vitrectomy probes in viscoelastic vitreous substitutes. *Trans Vis Sci Tech* 2020;9:6:9.

THE LATEST TECHNIQUES AND TECH FOR DMEK AND DSAEK

DMEK is the procedure of choice for Fuchs' dystrophy, with DSAEK typically reserved for complex eyes.

MICHELLE STEPHENSON
CONTRIBUTING EDITOR

Descemet's stripping automated endothelial keratoplasty and Descemet's membrane endothelial keratoplasty have advantages over full-thickness corneal transplants, namely a decreased risk of tissue rejection, faster visual recovery and the potential for better vision.

According to Winston Chamberlain, MD, PhD, who is in practice in Portland, Oregon, the primary indication for corneal transplant surgery in the Western world is Fuchs' dystrophy. "Historically, we have thought of it as being a Caucasian disease, but it's actually probably present in many different populations," he says. "The genetic variants that drive it may be different, and it probably accounts for about 60 percent of all corneal transplants now in the United States. Most physicians in the U.S. would choose to perform DMEK on a patient with Fuchs' dystrophy."

Here, experts review the latest

approaches to these transplantation procedures.

Candidates for DMEK/DSAEK

Nandini Venkateswaran, MD, who is in practice in Boston, says DMEK is her go-to procedure for patients with Fuchs' endothelial dystrophy or pseudophakic bullous keratopathy. These are often straightforward cases. "I tend to reserve DSAEK for more complex cases, such as patients who've had prior retinal detachment surgery or prior glaucoma surgery, who may be aphakic or have an

anterior chamber intraocular lens, or who may have a more complex anatomic structure, such as iris defects and atypical anterior chamber depth, that may hinder a DMEK graft from successfully attaching in the eye," she says. "As you incorporate both of these techniques in practice, a lot of your DMEK cases tend to go faster than your DSAEK cases because you self-select the tougher cases for DSAEK. For patients with an existing but edematous penetrating keratoplasty, both DSAEK and DMEK can work, but I tend to do more DSAEK in those scenarios."

Clara Chan, MD, who is in practice in Toronto, agrees. "DMEK is the more anatomically correct way to replace the stripped diseased endothelium and Descemet's membrane," she says. "Tissue handling can be more challenging with DMEK, and being able to visualize inside the anterior chamber is crucial because the donor tissue is inserted as a scroll, which requires a variety of tapping maneuvers in a shallow anterior chamber

Nandini Venkateswaran, MD

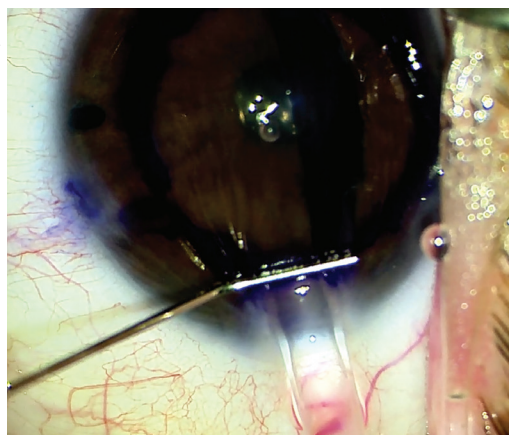


Figure 1. Insertion of DMEK graft with a Geuder cannula.

This article has no commercial sponsorship.

Dr. Venkateswaran has a financial interest in CorneaGen. Drs. Chamberlain and Chan have no financial interest in any of the products or companies mentioned in this article.

to open up and position properly. DSAEK more commonly has a role in complex eyes, such as those with prior vitrectomy, an anterior chamber intraocular lens, multiple iris defects, aniridia, aphakia, or advanced corneal edema such that the view into the anterior chamber is very poor.”

Tips and Techniques for DMEK

According to Dr. Chamberlain, the most common surgical method in the United States for DMEK is to use pre-loaded tissue, which has made the surgery accessible to more corneal surgeons. “This basically means that the eye bank does a lot of the work for the surgeon,” he says. “They cut the graft, peel it off, and put it in an injector/shooter. When the surgeon receives it, the injector/shooter is bathing in a media that supports the corneal cells. And then the surgeon just has to inject or pull it into the eye. There are a few injectors out there, and they are all about equivalent in terms of how much they damage the cells. The most popular ones are made of glass, and there is a bit of a trend toward using narrower openings.

“A Jones Tube-based injector was originally modified by Mike Straiko, MD, and more recently remodified by Gunther Weiss, to be narrower and go through a 2.2-mm wound,” Dr. Chamberlain continues. “The advantage is that you have smaller incisions with a more stable anterior chamber when injecting and manipulating the graft in the eye. One of the dangers of having an unstable chamber is that the graft can shoot back out through the wound, and that can damage the endothelial cells.”

Typically, the endothelium of the graft is rolled out, which is the natural roll. There’s a new trend of forcing the endothelium to face inward by locking the scroll in an inverted orientation inside a narrow injector tube. “We call it endo-in, and the advantage is that you can actually pull it into the eye with an

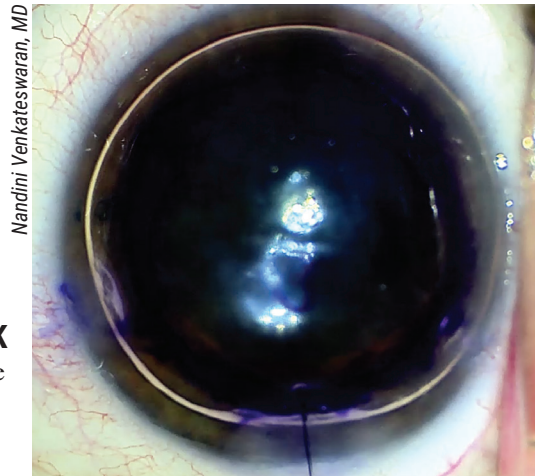


Figure 2. “S” stamp with SF6 gas in DMEK.

instrument and the graft will be in the right orientation in the anterior chamber,” Dr. Chamberlain says. “Experienced DMEK surgeons are probably not as concerned about this orientation issue on routine DMEK surgeries, but there are some theoretical advantages for more complicated eyes, such as those with a damaged iris, aphakia or post-vitrectomy. Because this method puts the graft in the proper orientation, it can be positioned against the posterior cornea while being held in place by the second instrument to keep the surgeon from losing the graft onto the retina in aphakic eyes or pressing it against an intraocular lens in eyes with large or damaged pupils, or where the chamber can’t be shallowed. Several eye banks are starting to provide surgeons with an option to get tissue prepared in that orientation.”

Dr. Chan says that she marks the tissue to ensure the correct orientation, and she pre-places a 10-0 nylon interrupted suture in the main incision. “I try to get the graft into a double-scroll configuration prior to injecting into the eye because then it is much easier to unfold and to orient the endothelium side down,” she says. “The anterior chamber must be shallowed and have a low pressure during the injection or the DMEK tissue risks being ejected out of the wound. Once the DMEK

graft is in the anterior chamber, it has to remain shallow to pin the graft in place. I tie the suture using a slip knot, then I use a couple 27-ga cannulas attached to 3-cc syringes to gently tap open the graft and massage it into position. I do a 10-minute pressurized full fill using approximately 14 percent SF6 gas (0.7 cc SF6 in a 5-cc syringe) and then lock the slip knot while the anterior chamber is in a physiologic shape. Lastly, I reduce the bubble size to about 60 percent, making sure that it covers the diameter of the DMEK graft, by injecting a phenylephrine cocktail similar to that used in floppy iris cataract cases to ensure that the pupil dilates as well. In eyes with tubes or trabs, I will leave in a full gas fill with the IOP around 25. Topical cyclogel is also used followed by a subconjunctival injection of ancef and dexamethasone.”

Tips and Techniques for DSAEK

According to Dr. Chamberlain, DSAEK accounts for approximately one-third of the transplants being performed in the United States. “It is still largely performed by surgeons using a pre-cut graft,” he says. “It’s cut at the eye bank and comes intact on a corneoscleral rim. The surgeons trephinate the tissue to the desired size and put it into the eye. There are various ways to do that. Some surgeons slide it into the eye in the correct orientation on a Sheets glide. Many surgeons use an injector or pull-through method, and there are several available. Some eye banks are now taking these injectors and pre-loading them with DSAEK grafts. The surgeon receives the graft, and he or she just has to pull it in the eye with a microforceps or push it in with fluid. That saves the surgeon some steps in the OR and cuts down on OR time. I personally have been a little concerned about storing DSAEK grafts and those injectors because they’re much thicker than DMEK grafts, and

there may be some crowding, with a reduction in access and diffusion of storage media over the storage time, but several eye banks have validated this storage technique and vouch for its safety.”

Dr. Chan adds that there are many instruments and inserter systems available for both DMEK and DSAEK, and she recommends practicing using these instruments in a wet lab prior to performing live surgery. “Some cornea surgeons prefer a pull-through technique for DSAEK, while others prefer an injector or push-in technique,” she says.

Dr. Venkateswaran primarily uses the EndoSerter from CorneaGen. “The EndoSerter gets attached to the irrigation/aspiration unit on your phaco machine, and it’s nice because it has ongoing irrigation as you’re inserting the graft into the anterior chamber,” she says. “This allows you to maintain the anterior chamber depth and have a smooth and atraumatic insertion of the graft as compared with other techniques like folding forceps or direct pushing of the graft into the eye on a Sheets glide with a small needle. Some ophthalmologists use the Tan Endo-Glide from Innovia Medical, which is also a great tool. I like the fact that the EndoSerter allows for an ongoing infusion with it, so I don’t need to place in an anterior chamber maintainer when I do these cases.”

Dr. Chamberlain adds that some surgeons are using support mechanisms, such as an anchor stitch through the graft, for complicated DSAEKs. “Surgeons can run a stitch through the graft to pull it into the eye and/or anchor it to the back of the cornea,” he explains. “The most common method is probably a single suture superiorly or nasally. It may damage the endothelium at one discrete point, but if it’s done carefully, it’s very effective at reducing postoperative manipulation in the event of a detachment. It doesn’t keep the graft from detaching, but

Francis W. Price Jr., MD

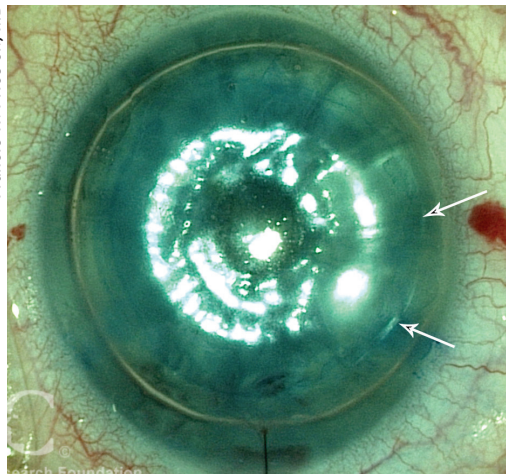


Figure 3. The graft is unfolded and in place; air placed in the anterior chamber helps to hold it there. (Arrows mark the edge of the graft.)

it keeps it from dislocating. This is a useful technique for complicated eyes where the bubble might escape to the back of the eye or go up into a glaucoma shunt or trabeculectomy bleb the night after surgery. It can be easily rebubbled at the slit lamp the next day or at the 1-week visit in clinic if the graft has partially detached from the posterior cornea, similar to a DMEK rebubbling step.”

Dr. Chan says that, for DSAEK, she uses an anterior chamber maintainer hooked up to the irrigation on a phaco machine with IOP set to 40 mmHg with a pull-through technique using the Tan curved DSAEK forceps and a reusable inserter device, such as the Macaluso or Busin glide. For DMEK, she uses the Geuder glass cannula attached to a 3-cc syringe filled with balanced salt solution to inject the tissue. “DSAEK tissue, no matter how thin, will typically open up in the correct orientation,” she says. “I like to pre-place a 10-0 nylon suture in the main incision. Before the forceps lets go of the tissue, I inject a small air bubble underneath the graft to keep it floating against the cornea. Then, I tie the slip knot and bump the graft into position using the 19-gauge cannula, which is usually attached to a large BSS bottle, then pressurize the eye to an IOP of about 40 with a full air

fill in the anterior chamber for 10 minutes. I finish tying off the suture at the main incision now that the anterior chamber is physiologic in shape before reducing the air bubble to about 60 percent, ensuring that it covers the diameter of the graft. In complex eyes at no risk for pupil block, I will release some air to bring the IOP down to about 25 mmHg, but will keep the anterior chamber completely filled with air.”

She adds that patients are kept supine in the recovery area for one hour after DSAEK and for two hours after DMEK. Instructions are given to maintain supine positioning as much as possible or on the opposite side to the surgical eye so that the bubble covers the temporal incision (a frequent location for graft detachments especially in DMEK if the graft overlaps the irregular internal main wound). “Patients’ vision and IOP are then checked in the clinic and a drop of cyclogel and antibiotics is instilled, before being repatched and shielded and checked again the next morning,” she says. “Having a consistent technique and being detail-oriented with each surgical step helps to ensure consistent successful results with a low rebubble rate.”

The Future

Dr. Venkateswaran says that advances to these corneal procedures will continue. “DSAEK tissue didn’t come pre-loaded until recently. Now, we’re seeing multiple eye banks and insertion devices having pre-loaded DSAEK tissue, just like we have pre-loaded DMEK tissue. This simplifies and shortens your surgical and procedural time and increases efficiency, and I think many surgeons are transitioning over to these techniques. I do think that corneal surgery will continue to play a role, but we’re seeing the advent of injectable endothelial cell therapy, which may supplant surgical options in the future,” she says. ◀

THE IMPACT OF DRCR PROTOCOL STUDIES

Researchers in the field of diabetic eye disease discuss how various Protocol trials have influenced treatment planning for PDR, DME and others.

LIZ HUNTER
SENIOR EDITOR

For the past two decades, the Diabetic Retinopathy Clinical Research Network has centered its mission on collaborative research that sheds light on benefits and risks to certain treatments for patients with diabetic retinopathy and other retinal diseases. Ophthalmologists perhaps know better than any other type of physician the ubiquity of diabetes and its consequences to individuals. The advent of therapies such as anti-VEGF have given retina specialists a lot to consider in their approach to treatment, and there's constantly something new to keep an eye on.

We spoke with some of the researchers who took part in a few of the DRCR's key studies in recent years and asked how each Protocol trial has impacted treatment paradigms and what questions are yet to be answered.

Protocol S

Protocol S caused a significant shift in treatment of proliferative diabetic retinopathy. Published in 2015, it compared panretinal photocoagulation vs. the anti-VEGF ranibizumab.¹ At the time, PRP was the standard of care, but there were recognized risks associated with it, such as retinal damage that could result in peripheral vision loss or worsening diabetic macular edema. Protocol S questioned if ranibizumab as first-line treatment would be non-inferior to PRP.

A total of 305 adults with PDR were randomized into the ranibizumab group (n=191 eyes): intravitreal 0.5 mg ranibizumab with PRP if treatment failed; ranibizumab as needed for DME; and the PRP group (n=203 eyes): PRP; ranibizumab as needed for DME.¹ Visual acuity results showed treatment with ranibizumab was non-inferior to PRP treatment at two years. The ranibizumab group had a mean visual acuity letter improvement of +2.8 at two years vs. +0.2 in the PRP group.

Five-year results of Protocol S showed severe vision loss and PDR complications were rare in both the ranibizumab and PRP groups, although the ranibizumab group had lower rates of developing diabetic macular edema and less visual field loss.² Protocol S gave confidence in anti-VEGF as initial treatment, however, there were patient factors for every ophthalmologist to consider before diving into it, including patient compliance. Even with the DRCR's considerable resources to reach patients—including investigators, coordinators and a third-party search service—the five-year results showed relatively high rates of loss-to-follow-up: 74 eyes in the ranibizumab group didn't complete their five-year visit (53 withdrawn, 21 died); and 80 eyes in the PRP group (65 withdrawn, 15 died).²

Jennifer K. Sun, MD, MPH, an associate professor of ophthalmology at Harvard University, helps lead the DRCR Retina Network's diabetes research initiatives, and says, de-

This article has no commercial sponsorship.

Dr. Maturi is a consultant for Allegro, Allergan, Allgenesis, Eli Lilly, Dutch Ophthalmic, Novartis, neurotech and Jaeb Center for Health Research. He receives research support from Allergan, Genentech, Ophthea, Kalvista, Samsung Bioepies, Graybug, Santen, Thrombogenics, Gyroscope, Gemini, Boehringer Ingelheim, Allegro, Senju, Ribomic, NGM biopharmaceuticals, Unity, Graybug and Clearside. He's also the Safety Committee Chair of Aiviv. **Dr. Pieramici** receives research funding from and consults for Genentech, Inc. and Regeneron Pharmaceuticals. **Dr. Sun** discloses research support from Adaptive Sensory Technologies, Boehringer Ingelheim, Janssen, Novartis, Novo Nordisk, Optovue, Physical Sciences, Inc. and Genentech/Roche.

spite Protocol S' consistent results, it spurred discussions among those in the field.

"There's been a lot of discussion in the years since the primary results of Protocol S were released in 2015 around the fact that anti-VEGF intervention is a very effective therapy in terms of regressing retinal neovascularization, but frequently it's not a durable therapy," she says. "Patients with proliferative retinopathy are at pretty high risk for missing follow-up visits, and there's a whole variety of reasons why that happens. Even though they may have been doing very well with anti-VEGF, once that effect wears off and the vessels start growing again, if they miss follow-up visits, occasionally we'll see patients come back in who have really florid retinal neovascularization with potential vitreous hemorrhage, retinal detachments. We just hope we can get back in and treat that before they have irreversible vision loss."

Dr. Sun says the majority of clinicians these days in practice are probably using a combination of the two treatments for many of their patients. "One of the next studies I'd like to see would be a very careful characterization of combination treatment therapy with both anti-VEGF and PRP—to understand what the outcomes are," she says. "Would that give us a more durable response than anti-VEGF therapy alone over the long term while still reducing rates of diabetic macular edema compared to PRP alone?"

Protocol T and Protocol AC

It's not uncommon for the results of one Protocol study to inspire another. For example, Protocol I, published in 2010, looked at treatments for center-involved DME and determined that eyes treated with ranibizumab 0.5 mg, with prompt or deferred focal/grid laser demonstrated superior visual improvements vs. the other groups: laser alone vs. intravitreal triamcinolone plus focal/grid laser.³ Prior to ranibizumab's FDA approval for DME,

bevacizumab (Avastin) was being used off-label, spurring the DRCR to organize Protocol T to compare ranibizumab and bevacizumab for DME. However, in the process of beginning the study, the FDA approved aflibercept for neovascular AMD, thus it was added to Protocol T.

In the study, 660 eyes with a visual acuity ranging from 20/32 to 20/320 and center-involving DME were randomized into one of the three anti-VEGF treatment groups. Study participants couldn't have undergone anti-VEGF therapy in the previous 12 months, nor any laser or steroids for DME in the prior four months.⁴ The primary outcome was the mean change in visual acuity letter score from baseline to one year. Aflibercept showed the greatest improvement, with a mean of +13.3 letters gained, vs. +11.2 with ranibizumab vs. +9.7 with bevacizumab. However, at two years, aflibercept and ranibizumab showed no differences between the two groups, yet bevacizumab remained inferior to aflibercept but not ranibizumab.

"Protocol T needed to tackle this question of finding out if one or more of these therapies were better than the others not only to help us give the most effective treatment, but also because there's a huge cost difference between these agents," says Dante Pieramici, MD, a member of the DRCR Protocol T writing committee and a private practitioner in Santa Barbara, California. "Avastin is less than \$100 per injection, while the others are upwards of \$1,500 to \$2,000 each.

"Over a two-year period, both of the more expensive drugs turned out to be better at improving vision and reducing retinal thickness, but most of this was driven by patients who had worse disease," he continues. "So, if you did a subgroup analysis of patients who had vision better than 20/50 compared to those that had 20/50 vision or worse at baseline, you found that there really wasn't a big difference between the drugs as far as visual acuity was concerned. Whereas

in the patients who had worse vision at baseline (20/50 or worse), most of that difference was driven by this group of patients."

Further questions were raised from Protocol T, though, particularly in response to insurance mandates on step therapy.

"It was very clear that after Protocol T, the standard of care became treatment with aflibercept or possibly ranibizumab in eyes with moderate or worse vision impairment," says Dr. Sun. "That being said, we know that there are also differences in terms of cost and availability of medications and we were starting to see, as practitioners, that step therapy was being mandated by private payers more frequently over the previous few years. No one had actually done a careful study to say 'would this kind of approach potentially be harmful to patients?'"

This was the origin of Protocol AC in which patients were either started on bevacizumab and transitioned to aflibercept at 12 weeks or later (if criteria were met) or were placed in an aflibercept monotherapy group.⁵

"We wanted to know, if you started with the less expensive therapy and switched, if there wasn't a good response, would that put the patients at a disadvantage?" says Dr. Pieramici. Medicare data in the study reports the cost of aflibercept at \$1,830 vs. \$70 per dose of bevacizumab.

"We had very specific switch criteria," says Dr. Sun. As stated in the study, switch criteria included: persistent center-involved diabetic macular edema (defined as the central subfield thickness being above the eligibility threshold); an adequately treated eye (administration of bevacizumab injections at the previous two consecutive visits); no recent improvement in eye condition (no improvement of visual acuity by ≥ 5 letters and no decrease in central subfield thickness of ≥ 10 percent as compared with each of the two preceding visits or between each of the two preceding visits); and suboptimal vision (visual acuity, 20/50

or worse before 24 weeks or 20/32 or worse at 24 weeks or later).⁵

“Over the course of the study, the huge majority of eyes in the bevacizumab group did end up switching—about 70 percent by the end of two years,” continues Dr. Sun. “The majority of them switched within the first year of treatment, but we found that over two years, we really didn’t see differences in terms of mean change in visual acuity from baseline to two years.” At two years, the mean change in visual acuity from baseline was 14.7 ± 14.5 letters in the aflibercept-monotherapy group (in 132 eyes) and 15.9 ± 12.4 letters in the bevacizumab-first group (in 128 eyes), with an adjusted between-group difference of -1.8 letters (95% CI, -4.9 to 1.2).⁵

“When we look at the retinal thickness outcomes, the eyes that were treated with aflibercept first probably had slightly better improvement in retinal thickness early on, but again, by the end of two years, the bevacizumab-first group had caught up very nicely and had very similar results,” Dr. Sun says. The study reported similar percentages of eyes with a central subfield thickness below thresholds for diabetic macular edema: 60 percent in the aflibercept-monotherapy group and 55 percent in the bevacizumab-first group.⁵

“The similarity between the visual acuity results in the two groups is there, whether you look at mean change in vision or whether you look at thresholds of vision improvement,” Dr. Sun summarizes. “What Protocol AC does to some extent is give us a standardized retreatment regimen and criteria for step therapy that we haven’t had before in the community, with very good characterization of what happens if you use the bevacizumab-first strategy with rescue with aflibercept as needed (if you do it the way we did in the study). If we’re using that kind of approach, then we’re able to reassure our patients and ourselves that the visual outcomes are excellent over two years and very similar to treating with aflibercept

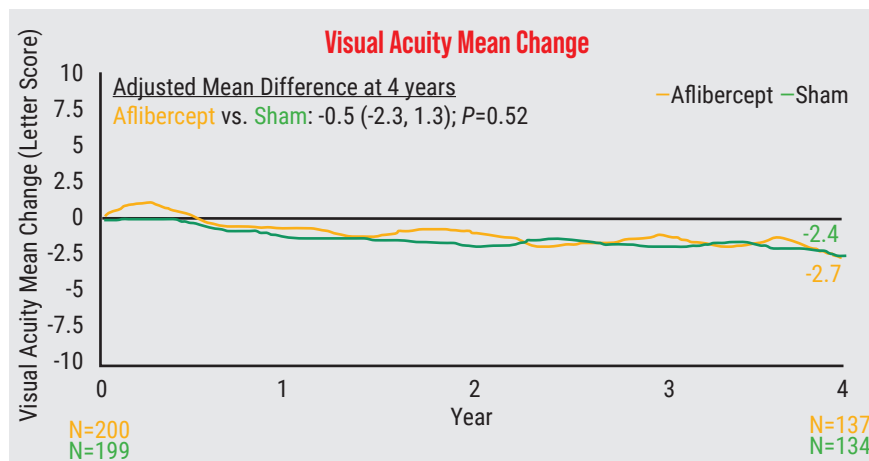


Figure 1. Four-year findings from Protocol W showed that patients with non-proliferative diabetic retinopathy gained no visual acuity benefit with early anti-VEGF treatment.

from the beginning.”

She warns other practitioners not to take this study as blanket approval for any step-therapy regimen. “If you use different anti-VEGF agents or a different treatment algorithm, you may end up with different results. Another factor that’s important to recognize is that we followed these patients very carefully in the clinical study. We were getting very frequent imaging, frequent follow-up visits, and those are things to pay attention to, not just that you’re using the same agents, but that you’re also following and managing the patient similarly,” she says.

Both Dr. Sun and Dr. Pieramici say this study may be further challenged as new agents come to market, such as faricimab (Vabysmo), high-dose aflibercept (Eylea) and biosimilars for bevacizumab.

“Now we’re wondering how these will fit into treatment. What would it look like if we start our diabetic macular edema patients on Vabysmo or Eylea? And if there’s a biosimilar for Avastin, then it will likely increase the price of Avastin, which eliminates the cost savings,” says Dr. Pieramici.

“The question will always arise as new agents come into the market and are approved, how they compare to what’s already out there,” adds Dr. Sun. “It’s difficult to know when it’s optimal to perform the next comparative effectiveness study. There will be

questions about how different agents perform. There are a lot of new treatments that are out there and biosimilars are coming to the market. It’s hard to do a study that addresses each and every single one of them, but it’s something that every now and then might be worth doing so that patients have the best data possible to make their decisions.”

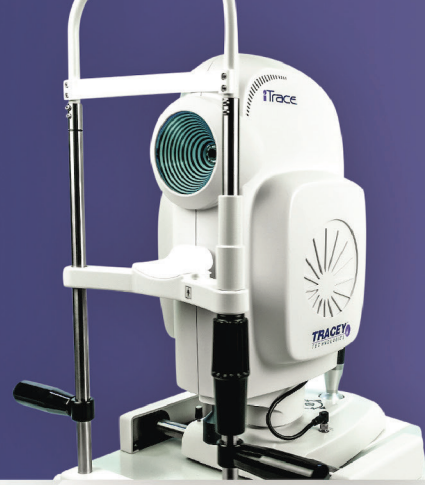Protocol V

There’s no shortage of questions about when and which anti-VEGF therapies to use on diabetes patients, and Protocol V asked: “Should we be starting anti-VEGF immediately in everybody who has center-involved diabetic macular edema, or in eyes that start with good vision, despite CI-DME, is it okay to hold off on injections?”

Dr. Sun says Protocol V stemmed from Protocol I and Protocol T. “We know that DME can wax and wane, and sometimes you can improve spontaneously,” she says. “Protocol V (published in 2019) arose from a discussion I was having with a fellow of mine at Joslin Diabetes Center, who saw a patient in clinic right after the Protocol I results were released, showing anti-VEGF should really be the new treatment standard for CI-DME. And she said, ‘Dr. Sun, this patient has CI-DME and I know that the new study shows that we should

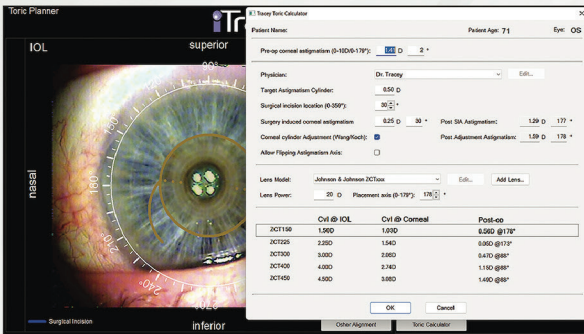
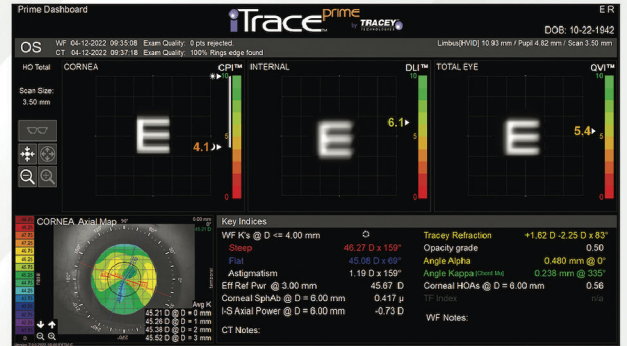


VISUAL FUNCTION MADE SIMPLE.



BEFORE SURGERY:

- ✓ The Prime Dashboard - separates quality of vision metrics between optical components and provides DLI™, CPI™ and QVI™
- ✓ Takes guesswork out of premium lens candidacy - know in advance if a patient's tear film, potential corneal performance and optical alignment will support a premium lens

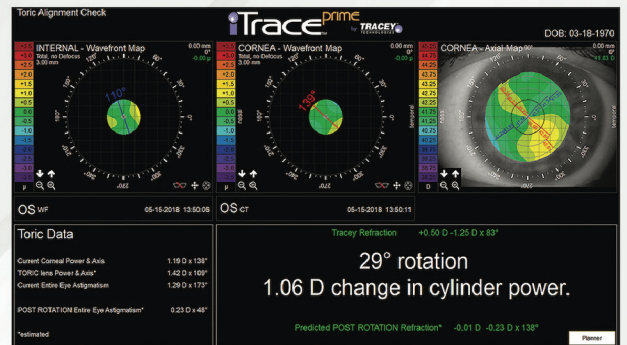


PLANNING SURGERY:

- ✓ Most accurate tool of its kind when classifying HOAs
- ✓ Uniquely provides precise Wavefront Ks for selecting the optimal Toric IOL power and axis

AFTER SURGERY:

- ✓ Only device that can scan through IOLs in situ without needing to dilate because of inherent, true ray-tracing technology
- ✓ With simple post-op scan, review the placement and power of a toric lens and see the exact amount of rotation needed to optimize correction



VISIT US TO LEARN MORE



CALL TO SCHEDULE YOUR PERSONAL DEMO

281-949-7517



16720 Hedgcroft Drive, Suite 208, Houston, Texas 77060-3619
 Email: sales@traceytechnologies.com | Web: www.traceytechnologies.com

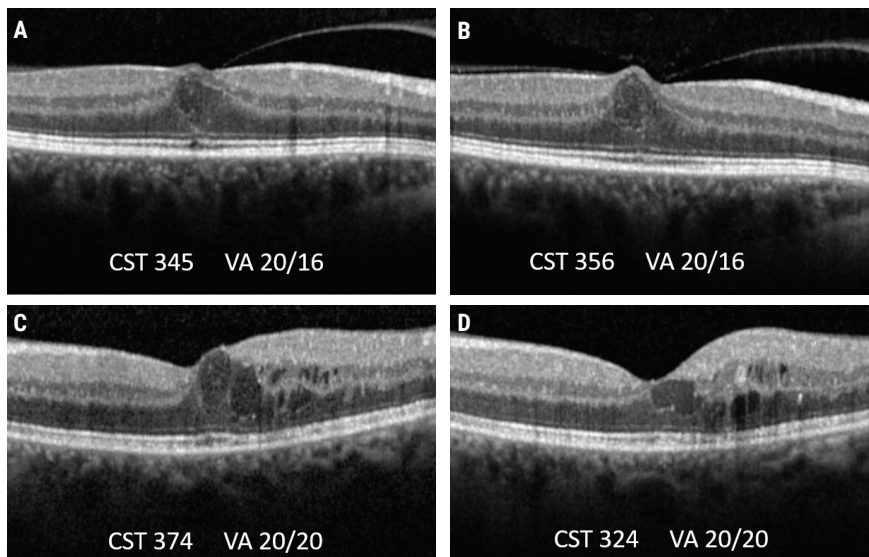


Figure 2. Protocol V investigated the idea of observation vs. injections for patients with center-involved DME but good visual acuity. In these OCT scans of two patients with center-involved DME who were observed and didn't receive treatment over a two-year period (baseline A and C, two-year follow-up B and D), both patients had residual edema yet maintained their baseline visual acuity.

use anti-VEGF treatment, but her vision is 20/20 and she has no visual symptoms. Is it really worth starting multiple years' worth of injections for her in this eye that's seeing so well?"

Up until this time, all of the DRCR studies had included eyes with some level of visual impairment, usually 20/32 or worse, she explains. "In Protocol V, which included eyes that were seeing well (20/25 or better) despite having CI-DME, we randomized them to either immediate anti-VEGF, laser treatment or just observation initially," says Dr. Sun. "Again, these were just initial management strategies. Over the course of the study, if the eyes in the laser or the observation groups were starting to lose vision, then we went ahead and treated them with anti-VEGF. At two years we found that the groups all did very similarly; they all did very well. The average vision at the end of the two-year study was 20/20 in each of the groups and so we concluded that it's pretty safe to hold off on treatment initially in eyes with good vision and CI-DME, as long as you're following them carefully and you're instituting anti-VEGF therapy if the vision starts to worsen."⁶

Since these results were released, Dr. Sun thinks there's been a fairly widespread recognition that this is a reasonable strategy. "But, this isn't to say that in any individual patient there might be characteristics that might make you choose to be more aggressive about starting therapy," she says. "Some patients have a faster need for visual recovery that makes them interested in starting therapy earlier. I think overall there's been pretty good uptake across the community that there's not a need to rush into treatment for everyone with center-involved DME as long as the starting vision is good and they are able to follow-up as recommended."

Protocol W

In the same wheelhouse as Protocol V, the more recent Protocol W also weighed the risks of monitoring disease progression vs. immediate anti-VEGF therapy, this time for patients with non-proliferative diabetic retinopathy. Earlier this year, four-year results from Protocol W were released and confirmed that early treatment of NPDR with anti-VEGF offered no long-term visual acuity benefit.⁷

"The goal was to figure out when

is the best time to start anti-VEGF for patients," says Raj Maturi, MD, of Indiana University School of Medicine and Retina Partners Midwest and chair of the protocol report. "We already know that anti-VEGF works really well when patients have diabetic macular edema and when they have proliferative diabetic retinopathy. However, what we don't know is, is it useful to utilize these drugs even before the onset of these two key complications of diabetes, would it give better visual acuity outcomes?"

Protocol W was designed as a four-year study, he continues. The study included 328 patients (399 eyes) who were randomized into 2-mg aflibercept injections vs. sham injections. Injections were administered at one month, two months, four months and every four months for the first two years, and then continued quarterly through year four unless the eye improved to mild disease. Any eyes that developed vision-threatening complications were given additional anti-VEGF injections as needed.

"First, we wanted to see if there would be a difference in retinopathy development progression with anti-VEGF vs. observation. At two years we did see retinopathy levels decrease with treatment. Around this same time, the PANORAMA trial results were released and confirmed our findings as well," Dr. Maturi says.

PANORAMA was a randomized clinical trial that investigated if treatment of moderately severe to severe NPDR with aflibercept injections would result in 2-step or greater improvement on the Diabetic Retinopathy Severity Scale in more eyes, fewer vision-threatening complications, and fewer center-involved diabetic macular edema events from baseline through 100 weeks compared with sham injections.⁸

Next was the more important question of visual acuity. "We needed four years to observe what would happen and we showed that there was no visual acuity difference at all between patients who got early treatment vs.

who were observed until they developed one of the two key features PDR or DME,” says Dr. Maturi. The four-year cumulative probability of developing PDR or center-involved DME was 33.9 percent in the aflibercept group and 56.9 percent in the sham group ($p < 0.001$). The mean change in visual acuity from baseline to four years was -2.7 ± 6.5 letters in the aflibercept group and -2.4 ± 5.8 letters in the sham group ($p = 0.52$).⁷

Dr. Maturi admits to being a little surprised by the results. “As physicians, we want to treat patients with the goal of getting a functionally beneficial outcome,” he says. “Looking at the outcomes and how similar they were, it tells us, if it’s still functionally beneficial to wait, then maybe holding off on treatment is reasonable.”

The researchers involved in the study also looked closely at subgroups to see if they could find statistically significant results. “We created a subgroup analysis based on baseline diabetic retinopathy level, the presence of non-central DME, race and sex to see if any of these criteria mattered and none of these groups cleared zero, which is none of them favored aflibercept in a statistically significant manner,” Dr. Maturi says.

Some may argue that even if there’s no difference in visual outcomes, treating the patient anyway will help improve their diabetic retinopathy levels. Dr. Maturi says to consider the burden, cost and risk of injections on the patient’s behalf. “The patients who were randomized to the aflibercept group ended up getting 13 injections over this four-year period and in the sham group, the average was only 3.5—almost 10 injection difference between the two groups,” he says, amounting to an average cost of \$20,000 per patient.

Dr. Maturi says Protocol W establishes what the right level before treatment is, yet there are always outliers. “There might be a few patients who still, despite the study, end up getting treated a little earlier—maybe they’re on dialysis, are at risk for loss-

to-follow-up, are worried about their fellow eye that has severe disease and have NPDR in the fellow eye. It may be warranted to treat those eyes earlier,” he says. “We didn’t study certain subgroups, and clinician judgment is paramount. However, large studies like this give us some really good data that we can bank on as to which general, large groups of patients need treatment and at what point.”

He remains concerned about the progression of diabetic retinopathy even with treatment. “I think the biggest takeaway here is that with or without injections, diabetic retinopathy is a disease that progresses rapidly. The majority of patients progressed to PDR when they had baseline NPDR and not to DME with vision loss. Looking for signs of PDR in these patients that follow up is a really important thing. If you have a patient with NPDR, especially if it’s in the moderate to severe range, every three to four month follow-up is essentially what the AAO practice guidelines say,” Dr. Maturi says. “Considering other treatment modalities—PRP or even vitrectomy—may be beneficial in patients with diabetic retinopathy to halt their progression.”

Final Takeaways

Dr. Sun says, “We’ve now had about 20 years’ worth of studies in diabetic eye disease performed by the DRCR Network and it’s really been a privilege to be part of this era with the introduction of anti-VEGF. I think the take-home message that we see across our studies is that anti-VEGF is a very effective treatment for diabetic macular edema and proliferative retinopathy. It’s first-line treatment for many of our patients with diabetic macular edema and vision loss and it works very well for our patients that have proliferative disease.

“Some of the importance of the recent studies has also been to show us not just when eyes should get treated with anti-VEGF and how to treat them with anti-VEGF, but also when you can hold back on treatment,

when it’s safe to not give injections, as long as you know that this patient will be good with follow up, will come in routinely and that you’re going to be doing the appropriate imaging and evaluations,” she continues.

Dr. Maturi reminds his fellow ophthalmologists of the longevity of diabetes. “Even though Protocol W (for example) was a four-year study, diabetes is not a four-year disease. Diabetes is a lifetime disease and it’s likely the next 30 to 40 years for that patient,” says Dr. Maturi. “We’ve done a great job with clinical medicine to increase diabetics’ lifespan, and the disease in the eye is not going away on its own.” ◀

1. Writing Committee for the Diabetic Retinopathy Clinical Research Network; Gross JG, Glassman AR, Jampol LM, Inusah S, Aiello LP, Antoszyk AN, Baker CW, Berger BB, Bressler NM, Browning D, Elman MJ, Ferris FL 3rd, Friedman SM, Marcus DM, Melia M, Stockdale CR, Sun JK, Beck RW. Panretinal photocoagulation vs intravitreal ranibizumab for proliferative diabetic retinopathy: A randomized clinical trial. *JAMA* 2015;24:314:20:2137-2146.

2. Gross JG, Glassman AR, Liu D, Sun JK, Antoszyk AN, Baker CW, Bressler NM, Elman MJ, Ferris FL 3rd, Gardner TW, Jampol LM, Martin DF, Melia M, Stockdale CR, Beck RW; Diabetic Retinopathy Clinical Research Network. Five-year outcomes of panretinal photocoagulation vs intravitreal ranibizumab for proliferative diabetic retinopathy: A randomized clinical trial. *JAMA Ophthalmol* 2018;1:136:10:1138-1148.

3. Diabetic Retinopathy Clinical Research Network; Elman MJ, Aiello LP, Beck RW, Bressler NM, Bressler SB, Edwards AR, Ferris FL 3rd, Friedman SM, Glassman AR, Miller KM, Scott IU, Stockdale CR, Sun JK. Randomized trial evaluating ranibizumab plus prompt or deferred laser or triamcinolone plus prompt laser for diabetic macular edema. *Ophthalmology* 2010;117:6:1064-1077.e35.

4. Diabetic Retinopathy Clinical Research Network; Wells JA, Glassman AR, Ayala AR, Jampol LM, Aiello LP, Antoszyk AN, Arnold-Bush B, Baker CW, Bressler NM, Browning DJ, Elman MJ, Ferris FL, Friedman SM, Melia M, Pieramici DJ, Sun JK, Beck RW. Aflibercept, bevacizumab, or ranibizumab for diabetic macular edema. *N Engl J Med* 2015;26:372:13:1193-203.

5. Jhaveri CD, Glassman AR, Ferris FL 3rd, Liu D, Maguire MG, Allen JB, Baker CW, Browning D, Cunningham MA, Friedman SM, Jampol LM, Marcus DM, Martin DF, Preston CM, Stockdale CR, Sun JK; DRCR Retina Network. Aflibercept monotherapy or bevacizumab first for diabetic macular edema. *N Engl J Med* 2022;25:387:8:692-703.

6. Baker CW, Glassman AR, Beaulieu WT, et al. Effect of initial management with aflibercept vs laser photocoagulation vs observation on vision loss among patients with diabetic macular edema involving the center of the macula and good visual acuity: A randomized clinical trial. *JAMA* 2019;321:1880-1894.

7. Maturi RK, Glassman AR, Josic K, et al. Four-year visual outcomes in the Protocol W randomized trial of intravitreal aflibercept for prevention of vision-threatening complications of diabetic retinopathy. *JAMA* 2023;329:5:376-385.

8. Brown DM, Wyckoff CC, Boyer D, et al. Evaluation of intravitreal aflibercept for the treatment of severe nonproliferative diabetic retinopathy: Results from the PANORAMA randomized clinical trial. *JAMA Ophthalmol* 2021;139:9:946-955.

MANAGING ACANTHAMOEBA AND OTHER INFECTIONS

A look at infectious keratitis and how to best manage it.

FRANCIS MAH, MD
LA JOLLA, CALIF.

Corneal ulcers are a leading cause of blindness worldwide with at least 1.5 to 2 million cases estimated annually. Because progression can lead to significant corneal melt, perforation, endophthalmitis and corneal blindness, diagnosis and management are time sensitive.

Epidemiology

Infectious keratitis is particularly prevalent in developing countries that have difficult access to medical care, risk for trauma related to agricultural work, and worse health at baseline.

In more developed countries, the incidence of microbial keratitis is increasing, due to the prevalence of contact lens use and instances of poor contact lens hygiene.

The specific pathogens of infectious keratitis have geographic differences based on climate-related flora and

type of trauma, including contact lens wear. In Europe, North America and Australia, for example, microbial keratitis is typically *Staphylococcus epidermidis*, *Staphylococcus aureus* or *Pseudomonas aeruginosa*.¹ In contrast, the Asia Corneal Society Infectious Keratitis Study reports a predominance of fungal keratitis, *Fusarium*, in India and China. The worldwide prevalence of *Acanthamoeba* is about 1 to 3 percent of infectious keratitis.²

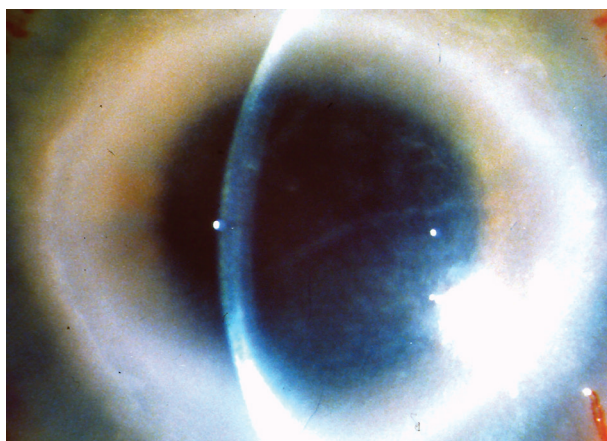
Diagnosis

The definitive diagnosis of infectious keratitis can be achieved via the following:

- **Clinical presentation.** Bacterial keratitis typically presents as an epithelial defect with a suppurative stromal infiltrate that can progress to varying degrees of thinning. Surrounding structures exhibit inflammation, such as lid swelling, ciliary flush, corneal edema and iritis with or without a sterile hypopyon.

Certain causes of infectious keratitis are more clinically indistinguishable from each other, making diagnosis difficult. *Acanthamoeba* and herpes simplex virus both start with irregular epithelia and photophobia. For *Acanthamoeba*, the photophobia and pain are out of proportion with what is seen on the clinical exam, meaning the patient's pain is worse than what's seen clinically. In more advanced stages, a pathognomonic ring-shaped infiltrate or perineuritis can develop.

The risk factors for *Acan-*



In cases of *Acanthamoeba* infection, the patient's photophobia and pain are out of proportion with what is seen on the clinical exam.

This article has no commercial sponsorship.

Dr. Mah is director of the Cornea and External Disease department, and co-director of Refractive Surgery, at the Scripps Clinic in La Jolla.

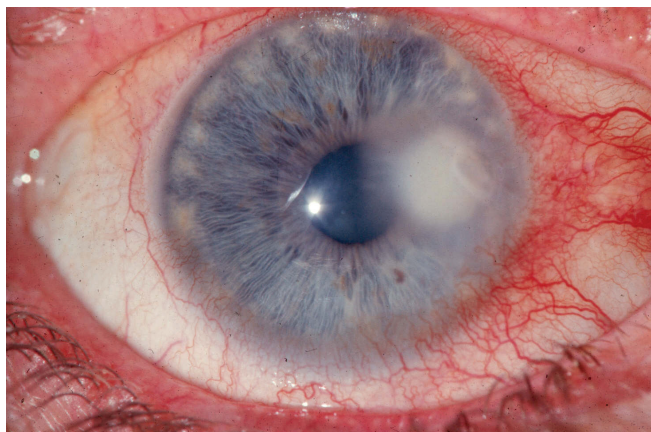
thamoeba keratitis are contact lens use, freshwater exposure (e.g., swimming pools and hot tubs) and agricultural trauma. For HSV, a history of hypoesthesia, cold sores, recurrent unilateral eye infections and a history of dendritic or geographic epithelial defects are characteristic of herpetic keratitis.

• **Microbiology workup.**

A consensus published by the AAO Preferred Practice Pattern recommends staining and culture for ulcers that are larger than 2 mm, vision-threatening by depth of involvement, show stromal melt, have a central location, are refractory, or those that appear in eyes that have undergone ocular surgery.³ Specimens for stains and cultures are obtained at the leading edge of infiltrates. Ways to maximize yield include collecting specimens with a broth-moistened calcium alginate swab, Dacron swab or a sterile metallic instrument. Avoid tetracaine and BAK use in order to preserve the viability of the pathogen. Careful sample collection prevents contact with lashes and the conjunctiva where the normal flora can confound the results.³

Microbial culture is considered the gold standard, because identifying the organism often confirms the diagnosis.³ A major challenge with cultures is their limited yield. The sensitivity of using blood, chocolate, thioglycolate and mannitol bacterial media is approximately 42 to 58 percent. Sensitivity is even more limited for *Acanthamoeba* at about 33 to 60 percent, in either buffered charcoal yeast extract or *E. coli* overlay on non-nutrient agar.

The low sensitivity of cultures and prolonged incubation periods warrant adjunctive methods to quickly identify pathogens with staining methods. Gram stains can be used to visualize bacteria, fungi and *Acanthamoeba*. The sensitivity for



The American Academy of Ophthalmology criteria for staining and culturing for ulcers includes such factors as a size larger than 2 mm, a central location and stromal melt.

identifying bacteria ranges from 36 to 75 percent. KOH wet mounts are 68 to 98 percent sensitive for fungal species, whereas it's higher at 84 to 91 percent for *Acanthamoeba*.⁴

Polymerase chain reactions and PCR-based assays have a sensitivity of 73 to 90 percent, with a specificity of 94.7 to 98 percent for both bacteria and fungi. PCR can also identify *Acanthamoeba*.

Confocal microscopy can aid in identifying atypical organisms and in assessing the depth of corneal involvement. Using this technology, *Acanthamoeba* appears as a hyperreflective, spherical and well-defined double-walled cyst.⁵ Bacteria are too small and obscured by a sea of inflammatory cells to be detectable. One exception is *Nocardia*.

Several challenges exist with confocal microscopy, however: it's mainly a research tool, limiting access; it's poorly reimbursed by insurance, therefore patients may have to pay for the test; the false-negative and false-positive rates are high; and the person administering the test should have significant experience, since identifying normal—let alone pathology—is difficult for the novice.

Treatment

Treatment is targeted to the etiology to reduce ocular morbidity and

visual impairment. Empiric therapy for bacterial ulcers involves frequent dosing of broad-spectrum antibiotics. Loading doses can be applied initially, followed by hourly dosing while awake, until clinical improvement. Then, the dose can decrease to q2hrs until re-epithelialization of the cornea, followed by further reduction to q.i.d until resolution.³

Treatment for *Acanthamoeba* keratitis requires clearance of both cystic and trophozoite forms of the

parasite. Early amoebic keratitis is mainly intraepithelial, and debridement reduces the microbial burden while facilitating antimicrobial penetration. First-line therapy are the biguanides, chlorhexidine gluconate 0.02% to 0.2% or polyhexamethylene biguanide (PHMB) 0.02% to 0.06%, with monotherapy a consideration for early cases. For chronic or later stages, dual therapy with propamidine isethionate 0.1% or oral or topical voriconazole 1% may be needed to reduce resistance to therapy. Dosing is hourly for a continuous 48 hours, followed by hourly while awake for the next 72 hours, then q2 to q3h for three to four weeks. Dosing for the oral anti-fungal agent is 200 mg b.i.d. Response to therapy may not be apparent for up to two weeks.⁶ For refractory cases lasting three to four months, miltefosine (Impavido, Profounda) is an FDA-approved oral medication for *Acanthamoeba* keratitis dosed at 50 mg t.i.d. and continued until resolution of the keratitis.⁷

Concomitant severe inflammation can present as a sterile hypopyon, synechiae formation and scleritis (most commonly inflammatory instead of infectious scleritis). Adjunctive use of oral NSAIDs, immunosuppressive drugs and judicious use of steroids may be indicated. Case reports reveal some success with

phototherapeutic keratectomy and cross-linking, but further studies are needed to demonstrate efficacy. In these cases of severe inflammation, the duration of treatment is prolonged from three to 12 months, and recurrences have been reported up to three months after treatment cessation. *Acanthamoeba* eradication is difficult to assess because it's indistinguishable by PCR, and dead and viable cysts are both visible on confocal microscopy. Therefore, repeat cultures, scrapings and biopsy may be needed. Of note: There is a minority of cases in which *Acanthamoeba* are polymicrobial with concomitant HSV or fungal keratitis, so clinical suspicion should remain high when assessing response to therapy.⁶

Close monitoring is required to assess response to empiric antibiotic use. Up to 94 percent of bacterial ulcers will resolve.⁴ If there's no clinical stability by 48 hours or improvement within four to seven days, further evaluation is recommended. A lack of clinical stability could be medication non-compliance, incorrect empiric drug choice or frequency, or a polymicrobial infection. Repeat stain and culture can be performed while on the current regimen or after cessation of antibiotics for 12 to 24 hours. To obtain a specimen that might be embedded deeper in the cornea, a braided (e.g., 7-0 or 8-0 vicryl or silk) suture can be passed through the abscess. A biopsy of the cornea may be needed to submit a specimen for histology and microbiology. With this technique, a 2 mm to 3 mm diameter dermatic punch is used to construct a partial thickness trephination to extract a strip of affected corneal stroma.³

Achieving Success

Infectious keratitis is an ophthalmic emergency that can progress to significant visual impairment from corneal melt and scarring. Even worse, endophthalmitis, perforation and loss of intraocular contents can occur. For these severe cases,

temporizing measures during this infectious and inflammatory phase are required to delay deep anterior lamellar keratoplasty, or optical penetrating keratoplasty should be performed to avoid graft failure. Adjunctive measures to secure the



Case reports reveal some success with phototherapeutic keratectomy and corneal cross-linking, but further studies are needed to demonstrate efficacy.



structure of the cornea may require cyanoacrylate sealant, amniotic membrane grafting, and tectonic or therapeutic penetrating keratoplasty. With high suspicion, immediate introduction of treatment, judicious guidance from the microbiology laboratory, and excellent follow-up and patient compliance to management, complications from microbial keratitis can be mitigated. ◀

1. Khor W-B, Prajna VN, Garg P, et al. The Asia Cornea Society infectious keratitis study: A prospective multicenter study of infectious keratitis in Asia. *Am J Ophthalmol* 2018;195:161-70.
2. Ung L, Bispo PJM, Shanbhag SS, Gilmore MS, Chodosh J. The persistent dilemma of microbial keratitis: Global burden, diagnosis, and antimicrobial resistance. *Surv Ophthalmol* 2019;64:3:255-271.
3. Lin A, Rhee MK, Akpek EK, Amescua G, Farid M, Garcia-Ferrer FJ, Varu DM, Musch DC, Dunn SP, Mah FS; American Academy of Ophthalmology Preferred Practice Pattern Cornea and External Disease Panel. Bacterial keratitis preferred practice pattern. *Ophthalmology* 2019;126:1:P1-P55.
4. Moshirfar M, Hopping GC, Vaidyanathan U, Liu H, Somani AN, Ronquillo YC, Hoopes PC. Biological staining and culturing in infectious keratitis: Controversy in clinical utility. *Med Hypothesis Discov Innov Ophthalmol* 2019;8:3:145-151.
5. Hau SC, Dart JK, Vesaluoma M, et al. Diagnostic accuracy of microbial keratitis with in vivo scanning laser confocal microscopy. *Br J Ophthalmol* 2010;94:8:982-7.
6. Lorenzo-Morales J, Khan NA & Walochnik J: An update on *Acanthamoeba* keratitis: Diagnosis, pathogenesis and treatment. *Parasite* 2015;22:10.
7. Hirabayashi KE, Lin CC, Ta CN. Oral miltefosine for refractory *Acanthamoeba* keratitis. *Am J Ophthalmol Case Rep* 2019;16:100555.

(Continued from p. 17)

management of facial paralysis. *Surv Ophthalmol* 2019;64:1:79-89.

2. Baugh RF, Basura GJ, Ishii LE, Schwartz SR, Drumheller CM, Burkholder R, Deckard NA, Dawson C, Driscoll C, Gillespie MB, Gurgel RK, Halperin J, Khalid AN, Kumar KA, Micco A, Munsell D, Rosenbaum S, Vaughan W. Clinical practice guideline: Bell's palsy. *Otolaryngol Head Neck Surg* 2013;149(3 Suppl):S1-27.
3. Monsanto RD, Bittencourt AG, Bobato Neto NJ, Beilke SC, Lorenzetti FT, Salomone R. Treatment and prognosis of facial palsy in Ramsay Hunt Syndrome: Results based on a review of the literature. *Int Arch Otorhinolaryngol* 2016;20:4:394-400.
4. Rahman I, Sadiq SA. Ophthalmic management of facial nerve palsy: A review. *Surv Ophthalmol* 2007;52:2:121-44.
5. Upaphong P, Tangmonkongvoragul C, Phinyo P. Pulsed oral azithromycin vs 6-week oral doxycycline for moderate to severe meibomian gland dysfunction: A randomized clinical trial. *JAMA Ophthalmol* 2023;141:5:423-429.
6. Hu J, Zhu S, Liu X. Efficacy and safety of a vectored thermal pulsation system (Lipiflow) in the treatment of meibomian gland dysfunction: A systematic review and meta-analysis. *Graefes Arch Clin Exp Ophthalmol* 2022;260:1:25-39.
7. Ellis MF, Daniell M. An evaluation of the safety and efficacy of botulinum toxin type A (BOTOX) when used to produce a protective ptosis. *Clin Exp Ophthalmol* 2001;29:6:394-9.
8. Jeong J, Lee JM, Kim J. Neuromuscular retraining therapy combined with preceding botulinum toxin A injection for chronic facial paralysis. *Acta Otolaryngol* 2023;143:5:446-451.
9. Jeffers J, Lucarelli K, Akella S, Setabutr P, Wojno TH, Aakalu V. Lacrimal gland botulinum toxin injection for epiphora management. *Orbit* 2022;41:2:150-161.
10. Nagendran ST, Butler D, Malhotra R. Direct brow lift and skin contraction in facial nerve palsy: A switch technique. *Ophthalmic Plast Reconstr Surg* 2021;37(3 Suppl):S130-S131.
11. Charlson ES, Pepper JP, Kossler AL. Corneal neurotization via dual nerve autografting. *Ophthalmic Plastic and Reconstructive Surgery* 2022;38:1:17-19.
12. Davis RE, Telischi FF. Traumatic facial nerve injuries: Review of diagnosis and treatment. *J Craniomaxillofac Trauma* 1995;1:3:30-41.
13. Marszał J, Bartochowska A, Gawęcki W, Wierzbicka M. Efficacy of surgical treatment in patients with post-traumatic facial nerve palsy. *Otolaryngol Pol* 2021;75:4:1-6.
14. Banks CA, Hadlock TA. Pediatric facial nerve rehabilitation. *Facial Plast Surg Clin North Am* 2014;22:4:487.
15. Yaeudú RYF, Mello MAB, Tucunduva RA, da Silveira JSZ, Takahashi MPMS, Valente ACB. Postoperative orthognathic surgery edema assessment with and without manual lymphatic drainage. *J Craniofac Surg* 2017;28:7:1816-1820.
16. Fay AM, Dolman PJ. Diseases and disorders of the orbit and ocular adnexa. Section 7: Neurologic disorders. In: *Management of Facial Nerve Palsy*. New York: Elsevier, 2016:593-600.

ABOUT THE AUTHOR



Dr. Noguera is an oculofacial plastics and reconstructive surgery fellow at the University of Tennessee Health Science Center/Hamilton Eye Institute in Memphis.



EDITED BY KULDEV SINGH, MD, MPH,
AND PETER A. NETLAND, MD, PHD

GLAUCOMA MANAGEMENT

Time for A New Angle?

Angle-recession glaucoma is tricky to treat. Based on the current literature, it might be time to revise our approach.

DANIEL B. MOORE, MD
LEXINGTON, KY.

As glaucoma goes, angle recession is likely more common than we realize, but it's still a relatively rare subtype. As such, it's hard to gather data on the condition, especially considering that it usually occurs decades after the inciting event, making prospective studies difficult to carry out. In fact, since the 1960s, no more than eight studies have been published in a single year on this topic.

Given the dearth of studies on angle-recession glaucoma, many of which are quite small and decades old, it's worth reviewing the original literature on which we base our current management approaches. Here, I'll discuss how I approach these cases and which treatments have the most robust evidence behind them.

Pathophysiology

Angle recession is the traumatic separation of the circular and longitudinal fibers of the ciliary body.^{1,2} Clinically, it's noted on gonioscopy as an irregularly widened ciliary body. However, the widening often appears uniformly throughout the entire angle and can look quite symmetric. It's

often only with the evaluation of the fellow eye that the asymmetry becomes apparent. This is why it's important to compare the angle appearance in both eyes when evaluating for recession.

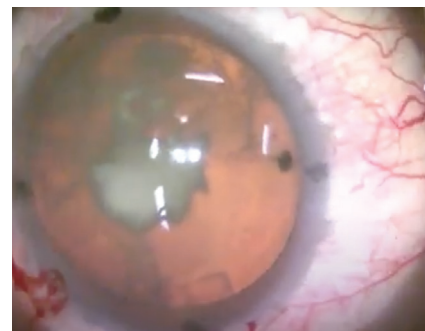
Mechanism of Action

Angle recession is the result of non-penetrating or blunt trauma to the eye. With this type of trauma, the force extends anterior to posterior, causing expansion along the equator of the eye, with greatest risk of damage to equatorial structures such as the ciliary body.³

The ciliary body is made up of longitudinal and circular fibers that act in a contradictory fashion. The longitudinal outermost fibers contract anteriorly-posteriorly while the circular innermost fibers contract equatorially. There's a poorly understood and weaker oblique middle zone between these two areas, and that's the part at greatest risk of injury. When there's sudden equatorial expansion, the oblique fibers can be torn. Aqueous humor is also jettisoned toward the ciliary body when there's sudden change in globe shape, potentially contributing further to injury.

Demographics

After blunt trauma, some individuals will have immediate IOP issues,



Uday Devgan, MD

A traumatic cataract with dense central opacity. Blunt ocular trauma may damage a number of structures, including the lens, angle and ciliary body. Delayed onset of angle-recession glaucoma can occur decades after the inciting event.

often due to hyphema or other obstruction of the traditional outflow pathway. But typically, when we think of angle-recession or traumatic glaucoma, we're looking at the patient population experiencing delayed onset of the disease, usually decades after the inciting event.

A substantial number of patients with a history of trauma have angle recession. Studies have identified angle recession in 71 to 86 percent of traumatized eyes using careful gonioscopy.⁴ The percentage of eyes with angle recession that go on to develop glaucoma is relatively small at around 10 percent, but this is still a considerable number of patients who often aren't getting routine eye care because they have no reason to think they're at risk decades later. The better we can educate patients at the time of trauma, the better chance they'll have of potentially being seen over the long term to help with risk management.

Risk Factors

Risk factors for glaucoma secondary to angle recession include age and

This article has no commercial sponsorship.

Dr. Singh is a professor of ophthalmology and chief of the Glaucoma Division at Stanford University School of Medicine. He is a consultant to Alcon, Allergan, Santen, Sight Sciences, Glaukos and Ivantis. **Dr. Netland** is Vernah Scott Moyston Professor and Chair at the University of Virginia in Charlottesville.

sex (young males are more likely to experience eye trauma), severity of the trauma, and the clinical findings, such as a large amount of angle recession (>240 degrees),⁵ increased trabecular meshwork pigmentation,⁶ elevated IOP at presentation⁷ and hyphema.⁸⁻¹⁰ In general, the worse the trauma, the higher the risk of secondary glaucoma.

Interestingly, while traumatic glaucoma is unilateral, these patients are more likely to have typical open-angle glaucoma in their fellow eye compared with the normal population. There are a few reasons why this may be, though there's no definitive answer. One possibility is that these patients are already being monitored and treated for their traumatic glaucoma, and therefore open-angle glaucoma in the fellow eye is identified at a much higher rate than in the standard population.

Another possibility is that patients who develop traumatic glaucoma, particularly decades later, may already be predisposed to open-angle glaucoma in both eyes to begin with, owing to some underlying cause for a compromised outflow system. The trauma may just speed up the disease process and/or increase its severity. These are patients who may have bilateral but still highly asymmetric disease.

Lastly, there may be an autoimmune component to this phenomenon. Trauma to one eye may cause some systemic changes, leading the other eye to develop open-angle glaucoma. However, none of these explanations is fully substantiated, and it's likely a combination of factors leading to the predisposition.

Clinical Exam

In angle-recession patients, anterior segment findings may include corneal scars, iris trauma such as iridodialysis or traumatic iris de-

fects. The initial trauma may also have caused cataracts or zonular damage leading to a subluxated lens, phacodonesis or pseudo-phacodonesis.

Gonioscopy of the anterior segment is a key part of the clinical exam for angle recession. The main finding is the widened ciliary body band. Any patient who's had trauma to the eye should undergo gonioscopy,¹¹ once the eye is stable and any hyphema has resolved. This can help prognosticate future risk for traumatic glaucoma based on the risk factors above. As noted before, it's important to compare findings with the fellow eye to avoid mistaking uniform widening for normal anatomy.

“ Trauma is likely a much more common cause of glaucoma than we think.

—Daniel B. Moore, MD

Routine visual fields and OCT as well as a posterior segment exam for glaucoma should also be performed. On the posterior exam, you may see retinal manifestations of prior trauma, such as chorioretinal lesions.

Unilateral glaucoma is atypical, so it's important to maintain suspicion for a non-glaucomatous etiology of an optic neuropathy, especially in the absence of elevated intraocular pressure and other compelling factors. Rule out

compressive lesions to the optic nerve; infectious, nutritional or autoimmune conditions; and vascular insults to the nerve or within the brain itself.

Management

Intraocular pressure management in patients with angle-recession glaucoma is challenging because their disease can be recalcitrant to more conservative measures. These patients tend to proceed to surgery much more quickly or consistently than the standard open-angle glaucoma patient. Since unilateral vision loss may go unnoticed for years, if the patient has one fully functioning eye, they often aren't aware of their risk and frequently present late with severely elevated pressures and advanced disease. On the other hand, having a fellow eye with disease can reduce the patient's overall functional vision loss and impact on activities of daily living.

As mentioned before, as a rarer glaucoma subtype, there are relatively few robust published studies on angle-recession glaucoma. Many of our current management approaches are based on a handful of small, retrospective studies from decades ago.

Is it time to revise some of our management approaches? Here's what the literature says:

- **Medical management.** Pilocarpine is relatively contraindicated in angle-recession glaucoma because it's said to cause a paradoxical rise in intraocular pressure. It's presumed to decrease uveoscleral outflow, and patients who already have a compromised traditional outflow system could experience a pressure increase.

TABLE 1. IRIS REGISTRY SLT FAILURE RATES IN ANGLE RECESSION VS. OVERALL¹⁵

	Angle Recession (n=560)	Overall (n=79,332)
Failure at six months (%)	21	6
Failure at 18 months (%)	48	41

TABLE 2. SUMMARY OF TRABECULECTOMY SUCCESS RATES¹⁸⁻²⁰

Mermoud A, et al. 1993 (n=35)	57 percent (overall)
Manners T, et al. 2001 (n=43)	85 percent at one year; 66 percent at three years
Senthil S, et al. 2022 (n=32)	88 percent at one year; 77 percent at two to five years

The data supporting this contraindication comes from a single case report in 1979.¹² A single patient was given pilocarpine and their pressure went up. They were then administered a cycloplegic and their pressure came back down. Despite this limited data, I think there's reason to worry about this effect. There's likely a good amount of anecdotal information supporting this finding, and certainly, it makes sense mechanistically. The traditional medical management approach for glaucoma is otherwise reasonable for this angle-recession subtype.

• **Laser trabeculoplasty.** SLT is traditionally contraindicated in traumatic glaucoma, or at least highly discouraged. One of the presumed mechanisms of traumatic glaucoma is an epithelial membrane that forms across the trabecular meshwork, one that isn't penetrated with traditional laser trabeculoplasty. In fact, treating the trabecular meshwork with ALT was found to produce a blanching effect in some cases, similar to what you'd see with epithelial downgrowth. This was thought to prove that a membrane grows with angle recession and that laser trabeculoplasty doesn't work well.

Our three major glaucoma textbooks and our BCSC residency educational series all recommend against SLT. This information comes from two retrospective, single-center studies in the early 1980s that looked at a broad range of indications for ALT.¹³⁻¹⁴ One study included six patients and the

other had four patients with angle recession. All did relatively poorly, compared with the broader range of other disease states. However, we rarely use ALT nowadays, and it has a slightly different mechanism of action from SLT.

More recently, a much larger 2021 study using IRIS Registry data¹⁵⁻¹⁶ looked into factors associated with favorable laser trabeculoplasty outcomes (*Table 1*). Overall, 79,332 patients had SLT. A total of 560 had angle recession. (Limited conclusions can be drawn since the study didn't specify the indication for SLT or any patient characteristics.)

For the angle-recession patients who underwent SLT, the study reported a 21-percent failure rate at six months and a 48-percent failure rate at 18 months. While these rates are high, the overall SLT failure rate was 6 percent at six months and 41 percent at 18 months—a mere 7-percent difference between angle recession and all other forms of glaucoma in the study. This difference is statistically significant, but what about the clinical significance? According to this study, there's a 50-percent chance that SLT will “work” (i.e., avoid surgery). On this basis, I would argue it's not unreasonable to consider doing SLT in an appropriate patient with angle recession, especially if the next step is surgery.

There certainly is a legitimate concern for the abnormal pathology of the angle compared to other indications for SLT. Laser may not be as effective in these patients.

However, we simply don't have sufficient data to demonstrate whether or not that's truly the case, and angle recession probably can't be reduced to a single mechanism. We're limited diagnostically in terms of identifying what specific angle malfunction a patient has or whether or not an individual patient would respond well or poorly to SLT.

• **Trabs and tubes.** Angle-recession patients commonly require incisional glaucoma surgery earlier in the treatment algorithm, and despite that they may still do poorly—this mantra is commonly taught for the management of angle-recession glaucoma. However, it's based on only a few single-center retrospective studies with small sample sizes.

Before mitomycin-C was routinely used with trabeculectomy, a 1993 study reported 43-percent treatment success and 0-percent long-term success after six years in angle-recession glaucoma.¹⁷ With antimetabolites, failure rates of roughly 50 percent two to three years after incisional surgery were reported in older studies. As a secondary procedure, trabeculectomy plus antimetabolite was successful in four of seven cases (57 percent) in a retrospective 1993 study of 65 patients undergoing drainage procedures.¹⁸ Among tube shunt procedures in the same study, success rates were 56 percent at one year and 27 percent at five years using Molteno single-plate implantation (n=20).¹⁸

These are all small studies with significant limitations to them, but more recent surgical results from other single-center retrospective studies demonstrate that the outcomes are better than what we've traditionally believed (*Tables 2 and 3*). A 2001 retrospective study of 43 trabeculectomy procedures using mitomycin-C reported 85-percent success at one year and 66-percent success at three years.¹⁹ In 2022, a

study of 32 eyes reported complete survival of trabeculectomy with mitomycin-C in 88 percent of eyes at one year and 77 percent two to five years postoperatively.²⁰

In 2001, a study reported Molteno success rates for 38 procedures of 80 percent at five years and 72 percent at 10 years.²¹ Success rates reported in 2017 for Ahmed (n=10) and Baerveldt (n=7) tubes were 83 percent at one year.²² In 2022, a study reported a 90-percent success rate for Ahmed tubes at two-and-a-half years (n=38).²³

With the caveat that failure and inclusion criteria differ, the outcomes reported in these small retrospective studies surprisingly show higher success rates than those reported in our largest randomized trials, the Tube Versus Trabeculectomy Study,^{24,25} the Ahmed Versus Baerveldt Study and the Ahmed Baerveldt Comparison Study,²⁶ which demonstrated failure rates at five years between 34 and 49 percent, with more than a quarter of patients requiring additional procedures within five years.²⁷ Whether these higher success rates in the smaller studies hold true in clinical practice remains to be seen, but the more recent, albeit limited, literature we have is a bit more encouraging. I think the takeaway is that the literature doesn't give us the same impression as what's taught, nor is the literature as conclusive as we tend to think when it comes to treating angle-recession glaucoma with tube shunts and trabeculectomies.

• **MIGS.** Considering that minimally invasive glaucoma surgeries are relatively new procedures, there's little in the literature about their use in angle-recession glaucoma. However, a retrospective single-center study published in 2022 found that penetrating canaloplasty may be an effective treatment option.²⁸ The study included 40 eyes of 40 patients with angle recession and reported

TABLE 3. SUMMARY OF TUBE SUCCESS RATES^{18, 21-23}

Mermoud A, et al. 1993 (n=20 Molteno)	56 percent at one year; 27 percent at five years
Fuller JR, et al. 2001 (n=38 Molteno)	80 percent at five years; 72 percent at 10 years
Yadgarov A, et al. 2017 (n=10 Ahmed, n=7 BVT)	83 percent at one year
Kaushik J, et al. 2022 (n=38 Ahmed)	90 percent at two and a half years

success rates of 87.5 percent at six months and 89.5 percent at 12 months. Mean IOP decreased from baseline 37.8 ±12.3 mmHg to 14.8 ±3.6 mmHg on 0.1 ±0.5 medications at 12 months postop (p<0.05).

The authors advocate that if MIGS is an option, an angle penetrating surgery—either an *ab externo* or *ab interno* penetrating canaloplasty—should be performed, rather than a stenting procedure or a non-penetrating or limitedly penetrating angle-based procedure, based on the presumed mechanism of a functional obstruction of the trabecular meshwork.

Importantly, if performing MIGS on an angle-recession patient, carefully monitor the frequency and duration of postoperative topical steroids because these patients may be more prone to an IOP spike. In 1967, George Spaeth, MD, demonstrated a correlation between steroid responsiveness and angle recession,²⁹ and a more recent study published in 2022 found that patients with angle recession were much more likely to have a steroid response (defined as an IOP increase >5 mmHg beginning at least three days after surgery) after MIGS.³⁰

• **Cyclodestructive procedures.**

Patients with more severe and advanced glaucoma may be amenable to a cyclodestructive procedure such as transscleral laser or potentially endoscopic cyclophotocoagulation.

In summary, trauma is likely a much more common cause of glaucoma than we think. Many patients forget they've had trauma unless it was very significant, but even minor trauma can cause this disease, so be sure to perform a good and careful gonioscopy in these patients and maintain suspicion for angle-recession glaucoma, especially if the presentation is asymmetric. Additionally, since angle-recession glaucoma remains a more difficult disease to manage than open-angle glaucoma, it's important to counsel patients appropriately so they're aware of what they may be facing. Lastly, consider SLT in appropriate patients, especially if the next step on the decision tree is surgery. ◀

1. Wolff SM, Zimmerman LE. Chronic secondary glaucoma. *American Journal of Ophthalmology* 1962;54:4:547-563.
2. Collins ET, Edward T. University College LLS. On the pathological examination of three eyes lost from concussion. London: Ophthalmological Society of the United Kingdom 1892.
3. Pujari A, Selvan H, Behera AK, et al. The probable mechanism of traumatic angle recession and cyclodialysis. *Journal of Glaucoma* 2020;29:1:67-70.
4. Herschler J. Trabecular damage due to blunt anterior segment injury and its relationship to traumatic glaucoma. *Trans Am Acad Ophthalmol Otolaryngol* 1977;83:239.
5. Mooney D. Angle recession and secondary glaucoma. *Br J Ophthalmol* 1973;57:8:608-612.
6. Mansoori T, Reddy AA, Balakrishna N. Identification and quantitative assessment of Schlemm's canal in the eyes with 360° angle recession glaucoma. *J Curr Glaucoma Pract* 2020;14:1:25-29.
7. Tonjum AM. Intraocular pressure and facility of outflow late after ocular contusion. *Acta Ophthalmol* 1968;46:5:886-908.
8. Blanton FM. Anterior chamber angle recession and secondary glaucoma: A study of the after effects of traumatic hyphemas. *Arch Ophthalmol* 1964;72:1:39-44.
9. Howard GM, Hutchinson BT, Fredrick AR Jr.

Hyphema resulting from blunt trauma: Gonioscopic, tonographic, and ophthalmoscopic observation following resolution of the hemorrhage. *Trans Am Acad Ophthalmol Otolaryngol* 1965;69:294e306.

10. Sihota R. Early predictors of traumatic glaucoma after closed globe injury: Trabecular pigmentation, widened angle recess, and higher baseline intraocular pressure. *Arch Ophthalmol* 2008;126:7:921.

11. Alper MG. Contusion angle deformity and glaucoma. *Arch Ophthalmol* 1963;69:4:455-467.

12. Bleiman BS, Schwartz AL. Paradoxical intraocular pressure response to pilocarpine: A proposed mechanism and treatment. *Arch Ophthalmol* 1979;97:1305-6.

13. Goldberg I. Argon laser trabeculoplasty and the open-angle glaucomas. *Australian and New Zealand Journal of Ophthalmology* 1985;13:3:243-248.

14. Robin AL, Pollack JP. Argon laser trabeculoplasty in secondary forms of open-angle glaucoma. *Arch Ophthalmol* 1983;101:3:382-4.

15. Chang TC, Vanner EA, Fujino D, et al. Factors associated with laser trabeculoplasty response duration: Analysis of a large clinical database (IRIS Registry). *Journal of Glaucoma* 2021;30:10:902-910.

16. Chang TC, Parrish RK, Fujino D, Kelly SP, Vanner EA. Factors associated with favorable laser trabeculoplasty response: IRIS Registry analysis. *American Journal of Ophthalmology* 2021;223:149-158.

17. Mermoud A, Salmon JF, Straker C. Post-traumatic angle recession glaucoma: A risk factor for bleb failure after trabeculectomy. *Br J Ophthalmol* 1993;77:631-4.

18. Mermoud A, Salmon JF, Barron A, et al. Surgical

management of post-traumatic angle recession glaucoma. *Ophthalmol* 1993;100:5:634-42.

19. Manners T, Salmon JF, Barron A, et al. Trabeculectomy with mitomycin C in the treatment of post-traumatic angle recession glaucoma. *Br J Ophthalmol* 2001;85:159-163.

20. Senthil S, Dangeti D, Battula M, et al. Trabeculectomy with mitomycin C in post-traumatic angle recession glaucoma in phakic eyes with no prior intraocular intervention. *Semin Ophthalmol* 2022;37:2:171-6.

21. Fuller JR, Bevin TH, Molteno ACB. Long-term follow-up of traumatic glaucoma treated with Molteno implants. *Ophthalmology* 2001;108:1796-1800.

22. Yadgarov A, Liu D, Crane ES, et al. Surgical outcomes of Ahmed or Baerveldt tube shunt implantation for medically uncontrolled traumatic glaucoma. *J Curr Glaucoma Pract* 2017;11:1:16-21.

23. Kaushik J, Parihar JKS, Sing A, et al. Evaluation of primary Ahmed glaucoma valve implantation in post-traumatic angle recession glaucoma in Indian eyes. *Int Ophthalmol* 2022;42:3:817-27.

24. Gedde SJ, Schiffman JC, Feuer WJ, on behalf of the Tube versus Trabeculectomy Study Group. Treatment outcomes in the tube versus trabeculectomy (TVT) study after five years of follow-up. *Am J Ophthalmol* 2012;153:789-803.

25. Gedde SJ, Feuer WJ, Lim SH. Primary tube versus trabeculectomy study group. Treatment outcomes in the primary tube versus trabeculectomy (PTVT) study after 5 years of follow-up. *Ophthalmology* 2022;129:12:1344-56.

26. Christakis PG, Zhang D, Budenz DL, ABC-AVB

Study Groups. Five-year pooled data analysis of the Ahmed Baerveldt Comparison Study and the Ahmed Versus Baerveldt Study. *Am J Ophthalmol* 2017;176:118-26.

27. Craven ER, Singh IP, Yu TM, et al. Reoperation rates and disease costs for primary open-angle glaucoma patients in the United States treated with incisional glaucoma surgery. *Ophthalmol Glaucoma* 2022;5:3:297-305.

28. Cheng H, Ye W, Zhang S, et al. Clinical outcomes of penetrating canaloplasty in patients with traumatic angle recession glaucoma: A prospective interventional case series. *Br J Ophthalmol*. Published online March 22, 2022.

29. Spaeth GL. Traumatic hyphema, angle recession dexamethasone hypertension, and glaucoma. *Arch Ophthalmol* 1967;78:6:714-21.

30. Abtahi M, Rudnisky CJ, Nazarali S, Damji KF. Incidence of steroid response in microinvasive glaucoma surgery with trabecular microbypass stent and ab interno trabeculectomy. *Canadian Journal of Ophthalmology* 2022;57:3:167-174.

ABOUT THE AUTHOR



Dr. Moore is an associate professor of ophthalmology at the University of Kentucky. He has no related financial disclosures.

ADVERTISER INDEX

This advertiser index is published as a convenience and not as part of the advertising contract. Every care will be taken to index correctly. No allowance will be made for errors due to spelling, incorrect page number, or failure to insert.

Alcon	27, 28
.....	(800) 451-3937
.....	www.clareonvivity.com
Alcon	35, 36
.....	www.myalcon.com/professional/cataract-surgery/iols/clareon-panoptix
Alcon	31
.....	(800) 451-3937
.....	www.simbrinza.myalcon.com
Alcon Laboratories	11, 12
.....	www.myalcon.com/professional/cataract-surgery/surgical-equipment/alcon-smart-solutions
Allergan, Inc.	6
.....	www.refresheyedrops.com
Apellis	66, Cover 3
.....	www.apellis.com
Genentech	Cover 2, 3
.....	www.vabysmo.com

Glaukos	Cover 4
.....	(800) 452-8567
.....	www.glaukos.com
Icare USA	Cover Tip
.....	(888) 422-7313
.....	infoUSA@icare-world.com
.....	www.icare-world.com/USA
Mededicus	Polybag Insert
Novartis Pharmaceuticals	18-20
.....	www.novartis.com
Tarsus	15
.....	tarsusrx.com
Thea Pharma	9
.....	www.iyuzeh.com
Tracey Technologies	45
.....	www.traceytechnologies.com



EDITED BY CARL REGILLO, MD,
AND YOSHIHIRO YONEKAWA, MD

RETINAL INSIDER

An Update on White Dot Syndromes

Their rarity and different manifestations can make these chorioretinopathies a challenge to deal with. Here's help.

SRUTHI AREPALLI, MD
ATLANTA

The heterogeneous group of inflammatory chorioretinopathies that make up the disease entity commonly known as “white dot syndrome” can result in multiple visual and anatomic sequelae, and can be challenging to diagnose due to their rarity and varying pathogenesis and other factors. This review will detail each disease separately and cover predisposing conditions and pathogenesis, genetic factors, clinical features and treatments.

WDS Background

The white dot syndromes group includes a heterogeneous mix of inflammatory chorioretinopathies. Patients typically present with blurred vision, scotomas, photopsias and floaters. On examination, the main commonality between these disorders lies in the presence of white, yellow-white, or gray-white lesions involving the outer retina, retinal pigment epithelium and choroid. The white dot syndrome category includes: multiple evanescent white dot syndrome (MEWDS); acute posterior multifocal placoid pigment epitheliopathy (APMPPE); idiopathic multifocal choroiditis (IMFC); punctate inner chorioreti-

nopathy (PIC); serpiginous chorioretinopathy; acute zonal occult outer retinopathy (AZOOR); and birdshot chorioretinopathy (BSCR).¹

These diseases are relatively rare, with an estimated incidence of 0.45 in 100,000 per year.² The rarity of the condition makes it difficult to conduct studies assessing the predisposing factors for disease development; thus, the exact pathogenesis of these syndromes is undetermined. Patients often describe a viral prodrome, but the WDS have also been linked to a variety of other inciting factors, including—but not limited to—bacterial infections, vaccinations and certain haplotypes.³

Initial reports believed that all white dot syndromes fell on a common inflammatory spectrum and shared a similar pathogenesis.⁴ Recently, multi-modal imaging has improved our understanding of the pathophysiology of these diseases, and it's become evident that not all of these conditions may fit along the same continuum. In particular, MEWDS, APMPPE, IMFC, PIC and serpiginous may fit into one group, while AZOOR and BSCR have distinct inflammatory profiles.¹

Multiple Evanescent White Dot Syndrome

MEWDS has been linked to mul-

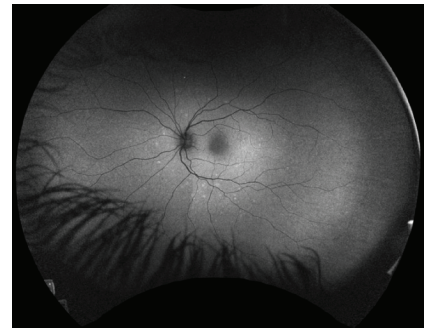


Figure 1. A 19-year-old female presented with photopsias and blurred vision. Fundus examination revealed a slight granularity to the macula, composed of pinpoint, yellow-white lesions. These are demonstrated on autofluorescence with a hyperfluorescent pattern.

iple exposures, the two most common of which include viruses and vaccinations, such as the Epstein-Barr, hepatitis A and B, human papilloma and herpesviridae family.^{5,6} One of the proposed mechanisms of MEWDS explains the phenomenon as an immune reaction to a viral infection, or the result of a complex interplay of genetic and environmental factors. Three main hypotheses exist to explain the pathophysiology of MEWDS based on in-depth imaging analysis: 1) hypoperfusion of the choriocapillaris leading to ischemic damage to overlying tissue; 2) immune damage of the RPE causing photoreceptor decline; or an immune attack targeting photoreceptors themselves.

MEWDS has traditionally been classified as monophasic and unilateral, but recent reports have shown evidence of it being an asymmetrical, bilateral process, with a recurrence rate of about 10 percent.⁷⁻⁹ There can be no overlying inflammation but, occasionally, mild intraocular inflam-

This article has no commercial sponsorship.

Dr. Regillo is the director of the Retina Service of Wills Eye Hospital, a professor of ophthalmology at Thomas Jefferson University School of Medicine and the principle investigator for numerous major international clinical trials.

Dr. Yonekawa is an assistant professor of ophthalmology at Sidney Kimmel Medical College at Thomas Jefferson University. He serves on the Education Committee of the American Society of Retina Specialists and on the Executive Committee for the Vit Buckle Society, where he is also the vice president for academic programming.



3RD YEAR OPHTHALMOLOGY RESIDENT PROGRAMS AND WET LABS

Dear CSE 3rd-Year Resident Program Director and Coordinator,

We would like to invite you to review the upcoming 3rd-Year CSE Ophthalmology Resident CME Programs and Wet Labs for 2023 in Fort Worth, Texas. The programs offer a unique educational opportunity for third-year residents by providing the chance to meet and exchange ideas with some of the most respected thought leaders in ophthalmology. The programs are designed to provide your residents with **in-depth didactic program and state-of-the-art wet lab experience with one-on-one wet lab guidance from faculty**. The courses also serve as an opportunity for your residents to network with residents from other programs.

After reviewing the material, it is our hope that you will select and encourage your residents to attend one of these educational activities, which are CME accredited to ensure fair balance.

Best regards,

Kendall Donaldson, MD, MS, Yousuf Khalifa, MD, and Mitchell P. Weikert, MD, MS

SAVE THE DATE

JULY 28–29, 2023
(FRIDAY–SATURDAY)

Course Director
Mitchell P. Weikert, MD, MS

REGISTER NOW

AUGUST 18–19, 2023
(FRIDAY–SATURDAY)

Course Director
Kendall Donaldson, MD, MS

MEETING IS FULL
REGISTER FOR WAIT LIST

SEPTEMBER 22–23, 2023
(FRIDAY–SATURDAY)

Course Director
Yousuf Khalifa, MD

MEETING IS FULL
REGISTER FOR WAIT LIST

Registration open www.ReviewEdu.com/CSE3rdYr2023

Courses are restricted to US-based 3rd-year residents enrolled in a US-based ophthalmology resident program and within their third year at the time of the course. There is no registration fee for these activities. Air, partial ground transportation in Fort Worth, hotel accommodations and modest meals will be provided through an educational scholarship for qualified participants.

Satisfactory Completion – Learners must complete an evaluation form to receive a certificate of completion. Your chosen sessions must be attended in their entirety. Partial credit of individual sessions is not available. If you are seeking continuing education credit for a specialty not listed below, it is your responsibility to contact your licensing/certification board to determine course eligibility for your licensing/certification requirement.



Accreditation Statement – In support of improving patient care, this activity has been planned and implemented by Amedco LLC and Review Education Group. Amedco LLC is jointly accredited by the Accreditation Council for Continuing Medical Education (ACCME), the Accreditation Council for Pharmacy Education (ACPE), and the American Nurses Credentialing Center (ANCC), to provide continuing education for the healthcare team.

Physicians (ACCME) Credit Designation – This live activity has been approved for **AMA PRA Category 1 Credit(s)**[™].

For more information visit the registration site above or call Denette Holmes at 866-627-0714 or email dholmes@postgradhealthd.com

Jointly provided by



Supported by an independent medical education grant from **Alcon**

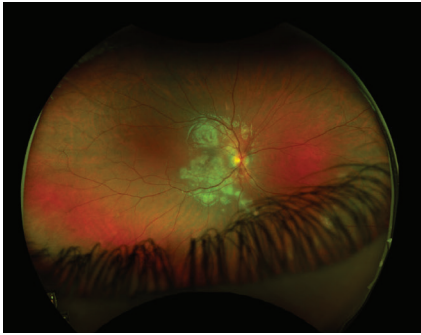


Figure 2. A 10-year-old male presents with blurred vision and creamy, yellow-white lesions throughout the fundus consistent with APMPPE. Given the widespread distribution, the patient was started on oral steroids, with resolution of the lesions.

mation exists, with typical findings including vitritis or optic nerve edema.¹⁰ An enlargement of the blind spot may also occur. Interestingly, many initial cases of MEWDS were wrongly categorized as acute idiopathic blind spot enlargement (AIBSE).¹¹ On dilated examination, small, discrete or confluent yellow-white dots are visible, usually ranging in size from 100 μm to 200 μm through the outer retina or the RPE. These are typically located in the macula but they can also involve the mid-periphery.¹² Additionally, a macular granular change can occur; in rare cases this granularity may be the only finding if the deep retinal or RPE dots have resolved.

Likely with all white dot syndromes, multi-modal imaging is instrumental in making the diagnosis. Optical coherence tomography often reveals photoreceptor damage, and fluorescein angiography shows retinal pigment epithelium abnormalities. These most often present with a typical wreath pattern of early hyperfluorescence and late staining of the lesions, while indocyanine green angiography is helpful, as it reveals more hypofluorescence lesions than appreciated on examination. Autofluorescence can show areas of hyperfluorescence that correlate to the lesions seen on ICGA, and the presence of hyperfluorescence can indicate cur-

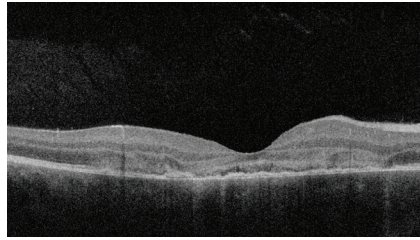


Figure 3. OCT shows outer retinal disorganization and photoreceptor loss, consistent with changes from APMPPE.

rent or recent activity (*Figure 1*). The enlarged blind spot can be confirmed with visual field testing.

Acute Posterior Multifocal Placoid Pigment Epitheliopathy

Similarly to MEWDS, APMPPE has been connected to infectious primers, including viruses, tuberculosis or vaccinations.¹³ Other immune conditions linked to APMPPE include psoriasis, sarcoidosis, erythema nodosum, granulomatosis with polyangiitis, polyarteritis nodosa and diabetes.¹⁴ The most recent literature identifies the choriocapillaris as the primary site of immune attack, which results in destruction of the overlying photoreceptors.¹⁴

APMPPE often presents as an acute, bilateral disorder in young healthy adults. Fundoscopy shows multifocal, creamy to yellowish placoid lesions in the posterior pole¹⁰ (*Figure 2*). OCT confirms disturbance of the outer retina and photoreceptors, along with RPE hyperreflectivity (*Figure 3*). Early phases of fluorescein angiography reveal hypofluorescent lesions, which later become hyperfluorescent, and ICGA demonstrates hypofluorescence in both early and late phases.¹⁵ Cases are usually self-limited and don't require therapy, although the use of oral steroids have been advocated, especially in foveal threatening disease. Despite being traditionally characterized as a self-resolving disease, there are variations of APMPPE that have a worse prognosis, including persistent placoid maculopathy and relentless placoid chorioretinitis. Their clinical

course is prolonged and characterized by multiple relapses.¹⁶

Of note, patients who present with signs of APMPPE should also be assessed for neurological symptoms. Clinicians should have a low threshold for obtaining neurological imaging. In one review, half of patients with neurological symptoms in the setting had cerebral vasculitis. Other, more unusual complications include meningoencephalitis, viral meningitis, cavernous sinus thrombosis, and sixth-nerve palsy.¹⁷ Rarely, death can result from cerebrovascular complications.¹⁸

IMFC and PIC

Both idiopathic multifocal choroiditis and punctate inner chorioretinopathy have been linked to a viral prodrome or vaccination, but a definitive cause remains elusive. Characteristically, IMFC is chronic and recurrent, with unilateral or bilateral involvement. The hallmark of this disease requires subretinal lesions located throughout the macula and peripheral retina, with possible overlying vitreous inflammation. These lesions range from 50 to 350 μm and are yellow to yellow-white, while hyperfluorescence can demonstrate areas of activity¹⁹ (*Figure 4*). Vision loss occurs when these lesions result in chorioretinal atrophy or choroidal neovascular membrane (CNVM) development.¹⁰ The OCT demonstrates loss of photoreceptors, with retinal architectural changes tracking to the inner retina. Optical coherence tomography angiography can also be very helpful in these

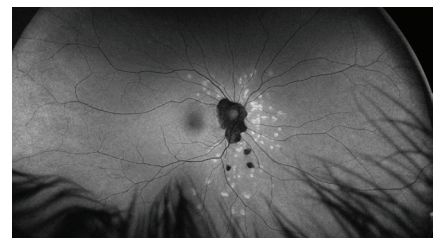


Figure 4. Multiple chorioretinal lesions throughout the fundus in a 27-year-old female consistent with idiopathic multifocal choroiditis. Hyperfluorescent areas demonstrate areas of recent activity.



Find qualified ophthalmic technicians fast

Finding a qualified ophthalmic technician for your practice can be difficult. That's why private practices and large employers alike trust Eyes On Eyecare® for specialized job posting and recruiting services.

SOURCE TALENT MORE EFFICIENTLY WITH OUR:

- ✓ Large talent pool of active and passive jobseekers
- ✓ Syndication to major job platforms and cross-promotion to our affiliate network
- ✓ Dedicated recruiting team with years of eyecare experience sourcing talent for specialized positions

"I had such a wonderful experience using Eyes On Eyecare. It was so easy to post a job and they walk you through the entire process. I recommend them to everyone I know."

- Ashley Wojcik



PROUD PARTNER OF JOBSON OPTICAL GROUP

Learn more at eyesoneyecare.com/hire-now



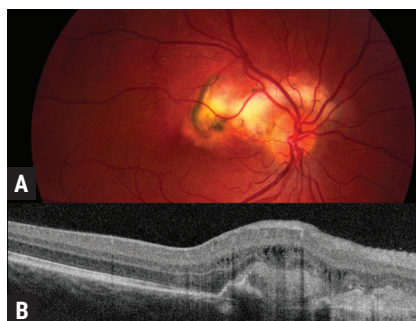


Figure 5. A) A 34-year-old female presents with blurred vision, with fundus examination showing peripapillary scarring extending into the macula consistent with serpiginous choroidopathy. B) On OCT, a choroidal neovascular membrane formed at the peripheral edge, requiring anti-VEGF injections.

cases, and confirm dropout of mid-sized vessels in the choriocapillaris. Additionally, in patients presenting with bilateral MEWDS, or MEWDS that recurs with chorioretinal scarring, IMFC should be considered, as it can initially present as MEWDS.¹²

PIC shares many of the same features of IMFC, and differentiation of the two may be difficult. In classic cases, traditional PIC lesions are located in the posterior pole and range from 100 to 300 μm . The disease is almost always bilateral, even if the patient initially presented with unilateral disease.²⁰ In contrast to IMFC, PIC has no inflammation, but does carry with it a high risk of CNVM development.

Serpiginous Chorioretinopathy

Much like the other white dot syndromes, a viral prodrome has been described before symptom onset with serpiginous chorioretinopathy. PCR testing of the aqueous humor in these eyes has revealed herpes virus in a subset of patients, but this hasn't been universally true.²¹ Serpiginous chorioretinitis most often has a geographic yellow to yellow-grey choroiditis that extends from the optic nerve with no to very little overlying inflammation (Figure 5A). Recurrences usually occur at the margins of prior scarring,

and concurrent active and inactive lesions typify the disease. Reactivation is common (50 percent within five years), and macular involvement occurs in approximately 90 percent of untreated patients.²² In cases where the serpiginous disease isn't treated, the chorioretinitis typically burns out over two decades, but leaves extensive scarring and fibrosis behind.²² Optical coherence tomography demonstrates outer retinal disorganization and hyperreflectivity of the RPE, and hyperfluorescent areas can delineate areas of early disease activity or recurrence.²³ CNV can also develop at the margin of impacted tissue (Figure 5B).

While the above five diseases (MEWDS, APMPE, IMFC, PIC, serpiginous) all involve occlusion or non-perfusion to the choroid, differences exist in the caliber of vessels involved. MEWDS is thought to preferentially impact the end capillary vessels, while APMPE, IMFC and PIC involve the mid-sized choriocapillaris vessels, and serpiginous is hypothesized to destroy the larger choriocapillaris.²⁴ Of note, certain researchers believe that IMFC and PIC are variations of the same disease, and that MEWDS may represent early IMFC if it recurs.²⁵

Acute Zonal Occult Outer Retinopathy (AZOOR)

Unlike the previously described diseases that mainly involve the choriocapillaris, AZOOR refers to an inflammation aimed at the photoreceptors, but the exact mechanism is poorly understood. Some believe that a viral infection also predisposes the body to attack the photoreceptors but this hasn't been proven.²⁶ The disease mainly impacts young to middle aged myopic women, with 75 percent developing bilateral symptoms. Initially, the fundus examination may be inconspicuous, but ultimately a faint, white to greyish white line delineating the normal area from the involved retina may appear.²⁷ It's rare to

have overlying inflammation in the vitreous. The OCT shows photoreceptor destruction, and fluorescein angiography either demonstrates leakage or staining over these areas. Fundus autofluorescence can reveal a stereotypical trizonal pattern: hypofluorescence over the area that has already been involved, a hyperfluorescence area at the border, and normal pattern after the area of AZOOR (Figure 6). AZOOR usually stabilizes at six months, and patients often maintain good vision. You can consider treatment with local or oral steroids however, especially in foveal threatening disease or recurrence. In a large report, the recurrence rate was documented in 15 percent of patients.²⁸

Birdshot Chorioretinopathy (BSCR)

BSCR is hypothesized to be an inflammation of both the retina and choroid and linked to the haplotype HLA-A29. This link is so strong that, in a patient with negative HLA-A29, testing should raise the possibility of an alternative diagnosis. It's also important to note that HLA-A29 positivity is already present in 7 percent of the general population; therefore, its presence does not guarantee a diagnosis of birdshot. Recent studies have also shown a link between BSCR and endoplasmic reticulum aminopeptidase 2 (ERAP2). ERAP2, like HLA-A29,

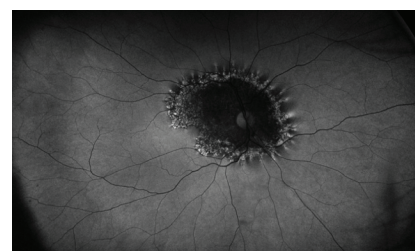


Figure 6. A 47-year-old male presents with bilateral blurred vision, and fundus examination shows a faintly pigmented changes around the nerve. Autofluorescence shows the typical trizonal pattern, including inner hypofluorescence, a rim of hyperfluorescence, and normal retina outside of the area of involvement.

is involved in the antigen presentation process, and the increase of this may activate the immune response in those with the HLA-A29 phenotype, but the true mechanism remains poorly understood.²⁹

BSCR presents with the typical range of WDS symptoms, in addition to visual field constriction. Unlike most of the other WDS, patients tend to develop BSCR later in life. Fundus examination reveals vitritis overlying scattered choroidal creamy yellow-white lesions, with a high concentration located inferonasally (*Figure 7*). Fluorescein angiography can reveal disc edema, macular leakage or retinal vascular leakage. Like other WDS, ICGA can reveal choroidal lesions that aren't seen on fundus photography. OCT can show macular edema, photoreceptor and ellipsoid zone disruption as well as choroidal thinning. Visual field monitoring is important, since the earliest signs can be peripheral visual loss. Given its chronic and progressive nature, treatment is important in patients with BSCR. The treatment regimen is usually stepwise, initially beginning with local or oral steroids, with subsequent progression to steroid-sparing therapy.³⁰

In conclusion, prompt recognition of these diseases is essential to obtain the best visual outcomes. Multi-modal imaging has provided new insights into the classification and understanding of the pathophysiology of these diseases. In certain cases, the patient can be watched, but in severe cases, involving foveal-threatening disease, or complications such as choroidal neovascular membranes, treatment is necessary. ◀

1. Mount GR, Kaufman EJ. White dot syndromes. StatPearls. Treasure Island (FL): StatPearls Publishing 2022.
2. Abu-Yaghi NE, Hartono SP, Hodge DO, Pulido JS, Bakri SJ. White dot syndromes: A 20-year study of incidence, clinical features, and outcomes. Ocular immunology and inflammation 2011;19:6:426-430.
3. Crawford CM, Igboeli O. A review of the inflammatory chorioretinopathies: The white dot syndromes. ISRN inflammation 2013;2013:783190.
4. Ben Ezra D, Forrester JV. Fundal white dots: The spec-

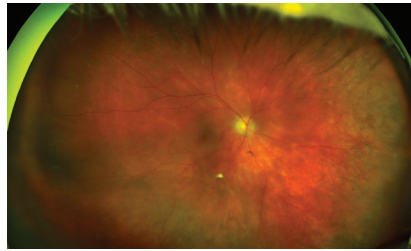


Figure 7. A 63-year-old woman presents with a two-year history of blurred vision. Fundus examination revealed 1+ vitritis and creamy yellow-white lesions throughout the fundus, concentrated more inferotemporally.

trum of a similar pathological process. The British journal of ophthalmology 1995;79:9:856-860.

5. Yang CS, Hsieh MH, Su HI, Kuo YS. Multiple evanescent white dot syndrome following acute Epstein-Barr virus infection. Ocular immunology and inflammation 2019;27:2:244-250.
6. Haw YL, Yu TC, Yang CS. A CARE-compliant article: A case report of possible association between recurrence of multiple evanescent white dot syndrome and the Herpesviridae family. Medicine 2020;99:15:e19794.
7. Veronese C, Maioli C, Morara M, Armstrong GW, Ciardella AP. Bilateral multiple evanescent white dot syndrome. International Ophthalmology 2018;38:5:2153-2158.
8. Bosello F, Westcott M, Casalino G, et al. Multiple evanescent white dot syndrome: Clinical course and factors influencing visual acuity recovery. British Journal of Ophthalmology 2022;106:1:121-127.
9. Ramakrishnan MS, Patel AP, Melles R, Vora RA. Multiple evanescent white dot syndrome: Findings from a large Northern California cohort. Ophthalmology Retina 2021;5:9:850-854.
10. Testi I, Modugno RL, Pavesio C. Multimodal imaging supporting the pathophysiology of white dot syndromes. Journal of Ophthalmic Inflammation and Infection 2021;11:1:32.
11. Fletcher WA, Imes RK, Goodman D, Hoyt WF. Acute idiopathic blind spot enlargement. A big blind spot syndrome without optic disc edema. Archives of Ophthalmology 1988;106:1:44-49.
12. Papasavvas I, Mantovani A, Tugal-Tutkun I, Herbort CP, Jr. Multiple evanescent white dot syndrome (MEWDS): Update on practical appraisal, diagnosis and clinicopathology; A review and an alternative comprehensive perspective. Journal of Ophthalmic Inflammation and Infection 2021;11:1:45.
13. Gonome T, Suzuki Y, Metoki T, Takahashi S, Nakazawa M. Acute posterior multifocal placoid pigment epitheliopathy and granulomatous uveitis following influenza vaccination. American Journal Of Ophthalmology Case Reports 2016;4:60-63.
14. Testi I, Vermeirsch S, Pavesio C. Acute posterior multifocal placoid pigment epitheliopathy (APMPPE). Journal of Ophthalmic Inflammation and Infection 2021;11:1:31.
15. Mrejen S, Sarraf D, Chexal S, Wald K, Freund KB. Choroidal involvement in acute posterior multifocal placoid pigment epitheliopathy. Ophthalmic Surgery, Lasers &

Imaging Retina 2016;47:1:20-26.

16. Mirza RG, Jampol LM. Relentless placoid chorioretinitis. International ophthalmology clinics 2012;52:4:237-242.
17. Algahtani H, Alkhotani A, Shirah B. Neurological manifestations of acute posterior multifocal placoid pigment epitheliopathy. Journal of Clinical Neurology (Seoul, Korea) 2016;12:4:460-467.
18. El Sanhoury A, Sisk RA, Petersen MR. Mortality from cerebral vasculitis associated with rapid steroid taper during treatment of acute posterior multifocal placoid pigment epitheliopathy. Archives of Ophthalmology 2012;130:7:935-937.
19. Papasavvas I, Neri P, Mantovani A, Herbort CP, Jr. Idiopathic multifocal choroiditis (MFC): Aggressive and prolonged therapy with multiple immunosuppressive agents is needed to halt the progression of active disease. An offbeat review and a case series. Journal of Ophthalmic Inflammation and Infection 2022;12:1:2.
20. Gerstenblith AT, Thorne JE, Sobrin L, et al. Punctate inner choroidopathy: A survey analysis of 77 persons. Ophthalmology 2007;114:6:1201-1204.
21. Rodman J, Pizzimenti J. Serpiginous choroiditis in a herpes-positive patient. Optometry and Vision Science 2011;88:6:776-780.
22. Weiss H, Annesley WH, Jr., Shields JA, Tomer T, Christopherson K. The clinical course of serpiginous choroidopathy. Am J Ophthalmol 1979;87:2:133-142.
23. Nazari Khanamiri H, Rao NA. Serpiginous choroiditis and infectious multifocal serpiginous choroiditis. Survey of Ophthalmology 2013;58:3:203-232.
24. Papasavvas I, Mantovani A, Herbort CP. Acute posterior multifocal placoid pigment epitheliopathy (APMPPE): A comprehensive approach and case series: Systemic corticosteroid therapy is necessary in a large proportion of cases. Medicina (Kaunas, Lithuania) 2022;58:8.
25. Lages V, Mantovani A, Papadia M, Herbort CP. MEWDS is a true primary choriocapillaritis and basic mechanisms do not seem to differ from other choriocapillaritis entities. Journal of Current Ophthalmology 2018;30:4:281-286.
26. Herbort CP, Arapi I, Papasavvas I, Mantovani A, Jeannin B. Acute zonal occult outer retinopathy (AZOOR) results from a clinicopathological mechanism different from choriocapillaritis diseases: A multimodal imaging analysis. Diagnostics (Basel, Switzerland) 2021;11:7.
27. Tsang SH, Sharma T. Acute zonal occult outer retinopathy (AZOOR) and related diseases. Advances in Experimental Medicine and Biology 2018;1085:233-237.
28. Monson DM, Smith JR. Acute zonal occult outer retinopathy. Survey of Ophthalmology 2011;56:1:23-35.
29. Donvito B, Monnet D, Tabary T, et al. A New HLA extended haplotype containing the A*2910 allele in birdshot retinochoroidopathy: Susceptibility narrowed to the HLA molecule itself. Investigative Ophthalmology & Visual Science 2010;51:5:2525-2528.
30. Standardization of Uveitis Nomenclature (SUN) Working Group. Classification Criteria for Birdshot Chorioretinitis. Am J Ophthalmol. 2021;228:65-71.

ABOUT THE AUTHOR



Dr. Arepalli is an assistant professor in the Vitreoretinal and Uveitis Service at Emory University.

Systemic Adverse Events And Anti-VEGF

Investigators wrote that anti-vascular endothelial growth factor agents are the mainstay of treatment for diabetic retinopathy. Although effective, data on their systemic safety remains inconclusive, particularly in high-risk patient groups. As such, they looked at the systemic safety of intravitreal anti-VEGF agents among patients with diabetes, as part of a retrospective, longitudinal population-based analysis of the Corporate Data Warehouse database of patients within the U.S. Veteran Health Affairs.

All patients 18 years and older with type 2 diabetes seen at any Veterans Affairs health-care facility between January 1, 2011, and December 31, 2012, were identified. Data were then extracted by incident systemic adverse events among the patient cohort from January 1, 2013, to December 31, 2017. All individuals with diabetes who did and didn't receive anti-VEGF injections were included. Patients with a history of prior systemic adverse events and those who received an intravitreal injection between January 1, 2011, and December 31, 2012, were excluded. Data were analyzed from October 2019 to March 2023.

The main outcomes and measures included the proportion of patients with any incident systemic adverse event, acute myocardial infarction, cardiovascular disease or kidney disease at one-, three- and five-year follow-up.

A total of 1,731,782 patients (mean [SD] age, 63.8 [12.3] years; 1,656,589 [95.7 percent] male) with type 2 dia-

betes were included. Here are some of the findings:

- DR was present in 476,013 patients (27.5 percent), and 14,022 (0.8 percent) received injections.
- Of the type 2 diabetes patients, 321,940 (18.6 percent) developed systemic adverse events between 2013 and 2017.
- The five-year cumulative incidence of any systemic adverse event was 37 percent (5,187/14,022) in the injection group vs. 18.4 percent (316,753/1,717,760) in the non-injection group ($p < 0.001$).
- Anti-VEGF injections were independently associated with a higher likelihood of developing any systemic adverse event (OR, 1.8; CI, 1.7 to 1.9) when controlling for age, race, sex, ethnicity, tobacco use, severity of DR, Deyo-Charlson Comorbidity Index score, mean hemoglobin A1c, number of injections and statin use.

Though investigators found that intravitreal anti-VEGF injections were independently associated with a higher likelihood of systemic adverse events among patients with diabetes, a commentary on the study indicates that further study is warranted before any definitive conclusion can be reached.

*JAMA Ophthalmol 2023; Jun 1.
[Epub ahead of print].
Zafar S, Walder A, Virani S, et al.*

Diabetes, Fuchs' Associations

Scientists assessed risk for demographic variables and other health conditions associated with Fuchs' endothelial corneal dystrophy.

They developed a case-control algorithm based on structured electronic health record data and confirmed accuracy by individual review of charts at three Veterans Affairs Medical Centers. This algorithm was applied to the Department of VA Million Veteran Program cohort from whom sex, genetic ancestry, comorbidities, diagnostic phecodes and laboratory values were extracted. Single-variable and multiple variable logistic regression models helped determine the association of these risk factors with FECD diagnosis.

Here are some of the findings:

- Being a FECD case was associated with female sex, European genetic ancestry and a greater number of comorbidities.
- Of 1,417 diagnostic phecodes evaluated, 213 had a significant association with FECD and with ocular and non-ocular conditions, including diabetes mellitus.
- Five of 69 laboratory values were associated with FECD, with four being consistent with diabetes mellitus.
- Insulin dependency and type 1 diabetes mellitus raised risk to a greater degree than type 2 diabetes mellitus, like other microvascular diabetic complications.

Scientists concluded that female sex, European ancestry and multimorbidity increased Fuchs' endothelial corneal dystrophy risk. Endocrine/metabolic clinic encounter codes and altered patterns of laboratory values supported diabetes mellitus increasing FECD risk, and a threshold model revealed that a FECD phenotype was intensified by diabetes mellitus and potentially other health conditions that alter corneal physiology. ◀

*Cornea 2023; May 12. [Epub ahead of print].
Nealon CL, Halladay CW, Gorman BR, et al.*



EDITED BY COLLIN ROZANSKI, MD

WILLS EYE RESIDENT CASE REPORT

A child with heterochromia, hemorrhage and an intraocular mass presents at Wills Eye.

SANDY WONG, MD, AND CAROL SHIELDS, MD
PHILADELPHIA

Presentation

A 5-year-old male presents with incidentally found heterochromia. Approximately one year prior to presentation, the patient's mother noted that the child's left eye was darker than his right eye. The patient himself did not report any symptoms or visual changes. An optometrist's examination at the time was reportedly normal. One year later, the patient was evaluated by an ophthalmologist who noted vitreous hemorrhage in the left eye with presence of an intraocular mass. The patient was then referred for evaluation by the Wills Ocular Oncology Service.

History

The patient was born at full term without complications, and didn't have any notable past medical or ocular history. He didn't take any medications. Family history didn't reveal any cases of cancers or early childhood blindness. Review of systems was negative.

Examination

Ocular examination demonstrated visual acuity of 20/25 in the right eye and light perception in the left eye. Pupils were reactive with no evidence of an afferent pupillary defect. Extraocular movements were full bilaterally. Intraocular pressures were 13 mmHg bilaterally.

Anterior segment evaluation revealed heterochromia with green-colored iris in the right eye and brown-colored iris in the left eye (*Figure 1*). There was no iris neovascularization. In the left eye, there was a dilated, tortuous sentinel episcleral vessel overlying the inferotemporal quadrant of the left sclera (*Figure 1*). The left eye had a dense cataract obscuring the view to the fundus.

Dilated fundus examination revealed normal findings in the right eye, including clear vitreous without hemorrhage or cells (*Figure 2*). The left vitreous was noted to have pigment dispersion in the anterior vitreous with hazy view to the optic nerve, macula and vessels (*Figure 2*). There was a large intraocular mass appearing to arise from the inferotemporal ciliary body measuring 16 by 16 mm.

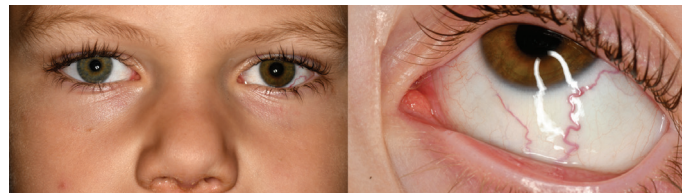

Figure 1. External photographs showing green colored iris of the right eye and brown colored iris of the left eye with an inferotemporal episcleral sentinel vessel.

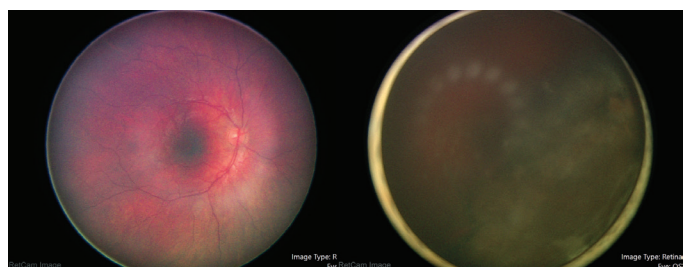


Figure 2. Fundus photography of the right and left eye during examination under anesthesia, showing normal findings in the right and hazy view with an inferotemporal intraocular mass in the left eye.

What's your diagnosis? What further work-up would you pursue? The diagnosis appears on p. 64.

Work-up, Diagnosis and Treatment




Figure 3. Transscleral illumination highlighting an inferotemporal mass extending from 2 to 6 o'clock in the left eye.

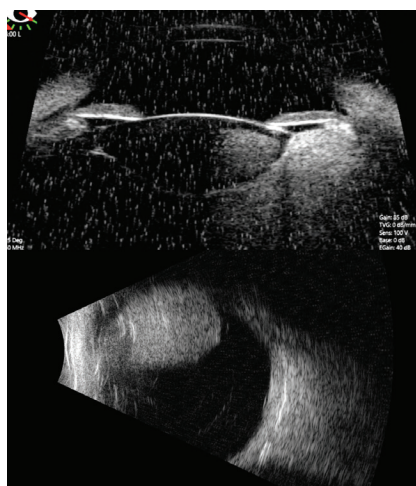


Figure 4. A/B-scan ultrasonography and ultrasound biomicroscopy showing the mass arises from the ciliary body and measures 11.8 mm in thickness and 13.5 mm at its base.

Our suspicion was for ciliochoroidal melanoma, but since the patient was only 5 years of age, we performed fine needle aspiration biopsy to differentiate melanoma from melanocytoma, pigmented medulloepithelioma or adenoma. The patient was taken to the operating room for an examination under anesthesia. Scleral transillumination revealed an anteriorly located tumor extending from 2 to 6 o'clock (*Figure 3*). A/B-scan ultrasound showed a ciliochoroidal mass with a thickness of 11.8 mm and a base of 13.5 mm (*Figure 4*). Ultrasound biomicroscopy showed the mass originated within the ciliary body, with the tumor pushing on the lens causing cataract (*Figure 4*). There was no evidence of extraocular extension. Fluorescein angiography demonstrated a hyperfluorescent tumor posterior to the lens with no view of the retinal vessels (*Figure 5*).

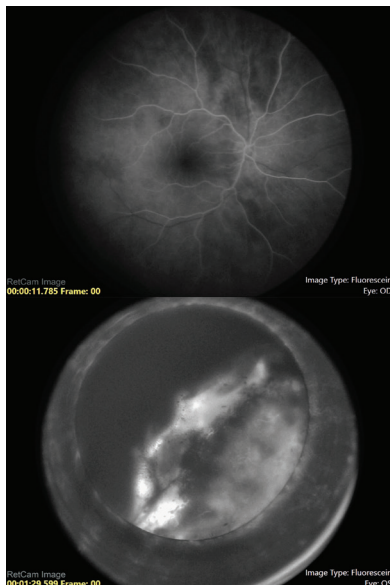


Figure 5. Fluorescein angiography of the right and left eye, respectively, showing a hyperfluorescent tumor posterior to the lens in the left eye with no view of the retinal vessels.

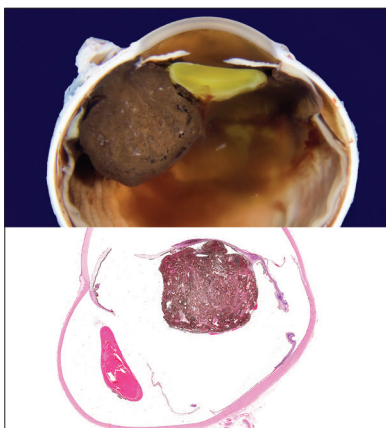


Figure 6. Gross pathology of the enucleated eye showing a tumor based in the ciliary body stroma and mushrooming into the ocular cavity.

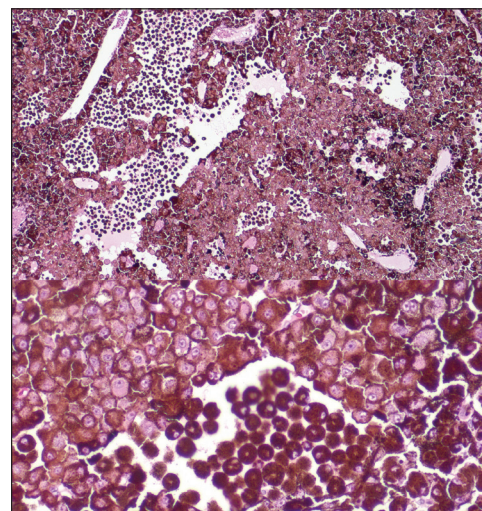


Figure 7. (Top) Microscopic examination of the tumor cells show dyscohesive epithelioid cells with loosened intercellular connections, a feature of malignancy. (Bottom) A zoomed view of these tumor cells, adjacent to a population of melanophages.

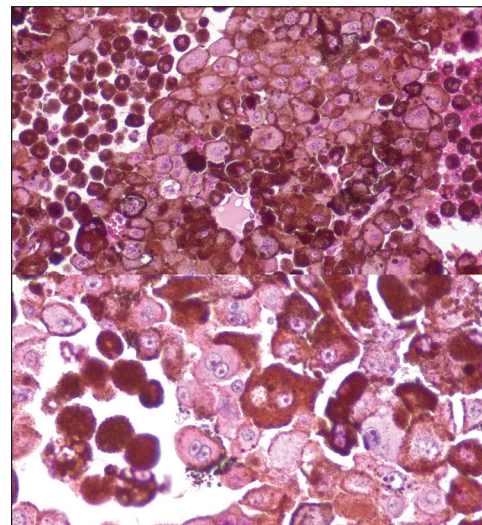


Figure 8. Close examination of the epithelioid cells shows low mitotic figures and prominent pleomorphism, with many binucleate and trinucleate tumor cells.

The patient underwent fine needle aspiration biopsy of the mass, which revealed epithelioid cell type malignant melanoma. Given the pathologic diagnosis and extent of the malignant tumor, a decision was made to proceed with enucleation. Gross pathology of the globe is shown in *Figure 6*. Microscopic examination was notable for dyscohesive cells with loosened intercellular connections, a feature of malignancy (*Figure 7*). Interestingly, the specimen contained many binucleate and trinucleate cells with relatively few mitotic figures (*Figure 8*).

Discussion

Our patient is a 5-year-old male who first presented with asymptomatic acquired heterochromia. The differential diagnosis for acquired heterochromia includes sympathetic-innervation heterochromia, ocular trauma, Fuchs' heterochromic uveitis, iris neovascularization and pigment dispersion on the iris whether from nevus or melanoma. In sympathetic-innervation heterochromia such as Horner syndrome or neuroblastoma, unilateral lack of sympathetic innervation interferes with melanin production in melanocytes. In contrast, cases of melanocyte infiltration such as diffuse nevus or melanoma cause increased iris pigmentation in the affected eye.¹ In this case, the acquired heterochromia was related to congenital uveal melanocytosis that gradually darkened in the first few years of life and led to development of the ciliary body melanoma that was ultimately treated with enucleation.

Uveal melanoma is a rare intraocular tumor that arises from the melanocytes of the iris, ciliary body or choroid.² It's the most common primary intraocular malignancy in adults, with a prevalence of 5.1 per million.³ The majority are located posterior to the equator. Ciliary body location is the least common site for uveal melanoma but portends the least favorable prognosis. Tumors with epithelioid cells also have poorer prognosis compared to spindle or mixed spindle-epithelioid cell types.⁴⁻⁷

The biggest advance in prognostication has been through understanding the molecular mechanisms driving this malignancy. In a large retrospective cohort study of 1,001 eyes with uveal melanoma, cases were categorized according to The Cancer Genome Atlas based on tumor DNA and followed for melanoma-related metastasis at five and 10 years. The Kaplan-Meier rate of liver metastasis, lung metastasis or any distant metastasis was highest in class D tumors with monosomy 3 and gain of chromosome 8q. Rates of metastasis were lowest in class-A tumors with disomy 3 and disomy 8. This classification strategy is used to guide treatment, particularly for class-C and -D tumors that may require adjuvant therapy.⁸

Compared to that of the adult general population, uveal melanoma in pediatric patients is much rarer and with more favorable prognosis. Based on a large series of 8,033 patients with uveal melanoma, only 1 percent occurred in patients aged 20 years or younger, whereas 53 percent were diagnosed in patients aged 21 to 60 years old and 45 percent diagnosed in patients over the age of 60. Patients under 20 years old with uveal melanoma were more likely to be non-white with lower rates of tumor-related metastasis and death compared to adults, similar to cutaneous melanoma. These patients were more likely to have melanoma located in the iris, more remote from the fovea and optic disc, and with smaller tumor diameter and thickness. It's speculated that younger patients have a more favorable prognosis indepen-

dently of tumor size due to declining host defense mechanisms with advancing age.⁹

Focusing specifically on pediatric choroidal and ciliary body melanomas, a 2016 survey by the European Ophthalmic Oncology Group studied 299 patients, of whom 114 were children younger than 18 years of age and 185 were young adults between the ages of 18 and 25 years. Patients with iris melanoma were excluded from the study. The authors found that adjusting for TNM stage and gender, children with choroidal and ciliary body melanoma have more favorable survival than young adults. Male children tended to have a more favorable survival compared to female children. Similar to the general adult population, higher TNM staging and monosomy 3 with 8q gain predicted the highest risk for metastasis.¹⁰

In conclusion, our patient presented with asymptomatic acquired heterochromia that was found to be secondary to a case of pediatric ciliary body melanoma. Cases of pediatric uveal melanoma are rare and require special consideration. Compared to adult uveal melanomas, pediatric cases tend to carry a more favorable prognosis. They share many of the same molecular and genetic basis as their adult counterparts, with similar metastatic outcomes based on The Cancer Genome Atlas categorization. The cytogenetic analysis of tumor DNA and genomic testing for conditions, including BAP1 tumor predisposition syndrome, is still pending to complete the work-up for this unique case. ◀

1. National Center for Biotechnology Information. Heterochromia Iridis - StatPearls - NCBI Bookshelf. In: StatPearls. Treasure Island (FL): StatPearls Publishing, 2022. <https://www.ncbi.nlm.nih.gov/books/NBK574499/>. Accessed June 8, 2023.

2. Ho A, Brown G, McNamara J, Recchia F, Regillo C, Vander J. Retina: Color Atlas of Synopsis of Clinical Ophthalmology. 2nd Ed. Philadelphia: Lippincott Williams & Wilkins, 2012.

3. Singh AD, Turell ME, Topham AK. Uveal melanoma: Trends in incidence, treatment, and survival. *Ophthalmology* 2011;118:9:1881-5.

4. Singh AD, Kalyani P, Topham A. Estimating the risk of malignant transformation of a choroidal nevus. *Ophthalmology* 2005;12:10:50-54.

5. Shields CL, Dalvin LA, Ancona-Lezama D, Yu MD, Di Nicola M, Williams BK Jr, Lucio-Alvarez JA, Ang SM, Maloney S, Welch RJ, Shields JA. Choroidal nevus imaging features in 3,806 cases and risk factors for transformation into melanoma in 2,355 cases: The 2020 Taylor R. Smith and Victor T. Curtin Lecture. *Retina* 2019;26:10:28-36.

6. Shields CL, Kaliki S, Shah SU, Luo W, Furuta M, Shields JA. Iris melanoma: features and prognosis in 317 children and adults. *JAAPOS* 2012;19:2:23-29.

7. Shields JA, Sanborn GE, Augsburger JJ. The differential diagnosis of malignant melanoma of the iris. A clinical study of 200 patients. *Ophthalmology* 1983;90:6:716-20.


8. Shields CL, Mayro EL, Bas Z, Dockery PW, Yaghy A, Lally SE, Ganguly A, Shields JA. Ten-year outcomes of uveal melanoma based on The Cancer Genome Atlas (TCGA) classification in 1001 cases. *Indian J Ophthalmol* 2021;28:7:22-30.

9. Shields CL, Kaliki S, Furuta M, Mashayekhi A, Shields JA. Clinical spectrum and prognosis of uveal melanoma based on age at presentation in 8,033 cases. *Retina* 2013;20:7:40-45.

10. Al-Jamal RT, Cassoux N, Desjardins L, Damato B, Konstantinidis L, Coupland SE, Heimann H, Petrovic A, Zografos L, Schalenbourg A, Velazquez-Martin JP, Krema H, Bogdali A, Markiewicz A, Romanowska-Dixon B, Metz CH, Biewald E, Bornfeld N, Kiratli H, Bronkhorst IH, Jager MJ, Marinkovic M, Fili M, Seregard S, Frenkel S, Pe'er J, Salvi SM, Rennie IG, Rospond-Kubiak I, Kociecki J, Kiilgaard JF, Heegaard S, Cohen VM, Sagoo MS, Amiryani A, Saakyan S, Eide N, Krohn J, Midena E, Parrozzani R, Grange JD, Kilic E, Blasi MA, Saomil MA, Kivelä TT. The pediatric choroidal and ciliary body melanoma study: A survey by the European Ophthalmic Oncology Group. *Ophthalmology* 2016;23:4:45-52.

iStent
infinite® ...

THE POWER OF 3



The Beginning of the Interventional Glaucoma Revolution

infinite possibilities

Brought to you by the founder of MIGS, iStent infinite® is the first-ever micro-invasive, standalone implantable alternative. Built on the #1 MIGS platform worldwide, it is designed to provide powerful technology that delivers foundational, 24/7, long-term IOP control in glaucoma patients who have failed prior medical and surgical intervention.¹

REFERENCE

1. Glaukos Data on File.

iStent infinite® IMPORTANT SAFETY INFORMATION

INDICATION FOR USE. The iStent infinite® Trabecular Micro-Bypass System Model iS3 is an implantable device intended to reduce the intraocular pressure (IOP) of the eye. It is indicated for use in adult patients with primary open-angle glaucoma in whom previous medical and surgical treatment has failed. **CONTRAINDICATIONS.** The iStent infinite is contraindicated in eyes with angle-closure glaucoma where the angle has not been surgically opened, acute traumatic, malignant, active uveitic, or active neovascular glaucoma, discernible congenital anomalies of the anterior chamber (AC) angle, retrobulbar tumor, thyroid eye disease, or Sturge-Weber Syndrome or any other type of condition that may cause elevated episcleral venous pressure. **WARNINGS.** Gonioscopy should be performed prior to surgery to exclude congenital anomalies of the angle, PAS, rubeosis, or conditions that would prohibit adequate visualization that could lead to improper placement of the stent and pose a hazard. **MRI INFORMATION.** The iStent infinite is MR-Conditional, i.e., the device is safe for use in a specified MR environment under specified conditions; please see Directions for Use (DFU) label for details. **PRECAUTIONS.** The surgeon should monitor the patient postoperatively for proper maintenance of IOP. Three out of 61 participants (4.9%) in the pivotal clinical trial were phakic. Therefore, there is insufficient evidence to determine whether the clinical performance of the device may be different in those who are phakic versus in those who are pseudophakic. **ADVERSE EVENTS.** The most common postoperative adverse events reported in the iStent infinite pivotal trial included IOP increase ≥ 10 mmHg vs. baseline IOP (8.2%), loss of BSCVA ≥ 2 lines (11.5%), ocular surface disease (11.5%), perioperative inflammation (6.6%) and visual field loss ≥ 2.5 dB (6.6%). **CAUTION:** Federal law restricts this device to sale by, or on the order of, a physician. Please see DFU for a complete list of contraindications, warnings, precautions, and adverse events.

Glaukos® and iStent infinite® are registered trademarks of Glaukos Corporation. All rights reserved. ©2022

PM-US-0909

GLAUKOS®