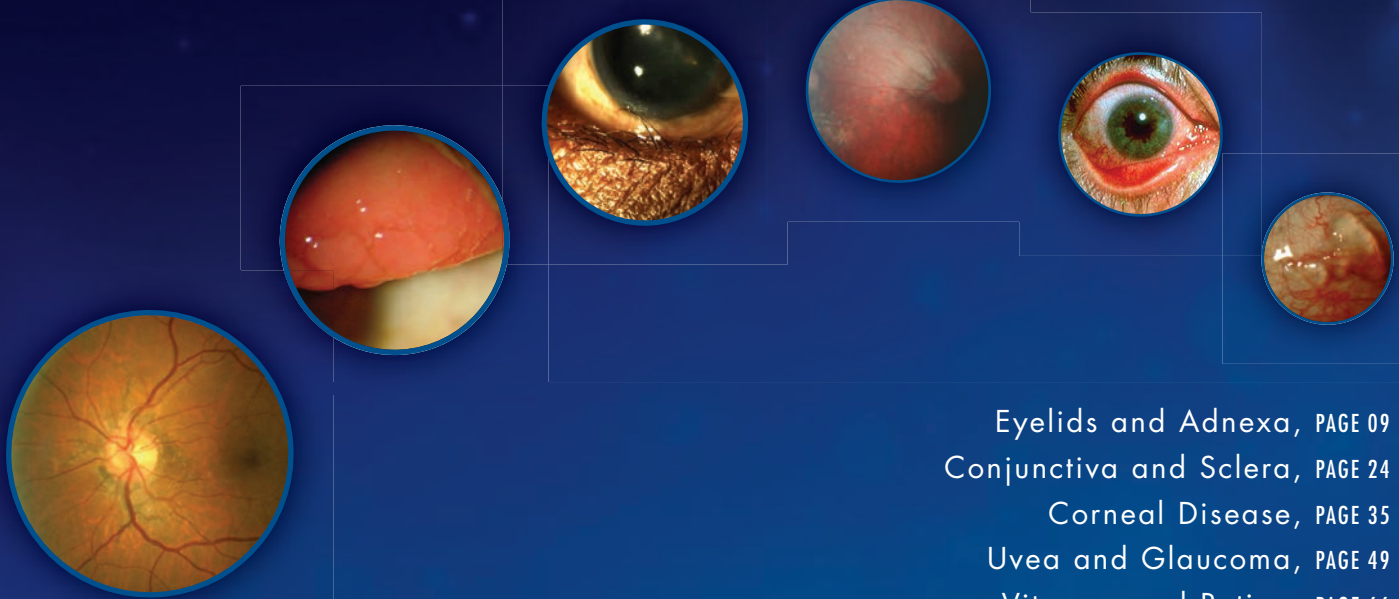


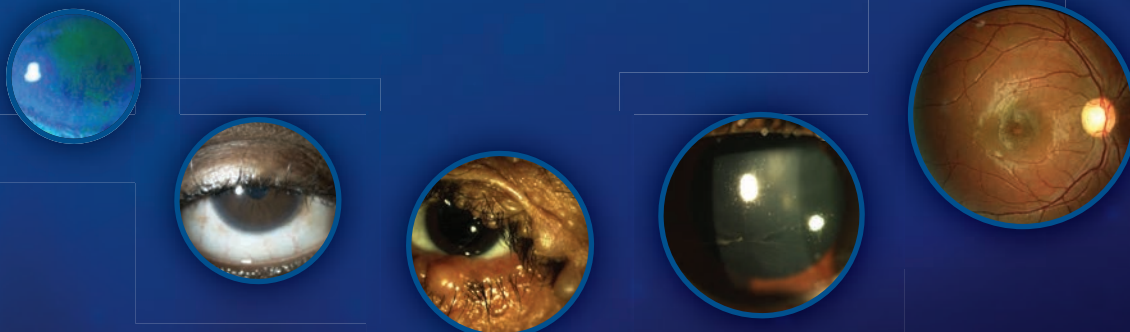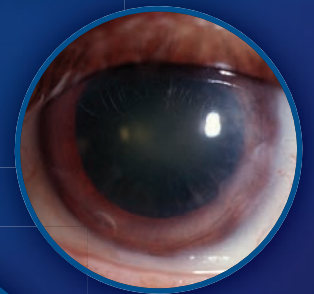
Joseph W. Sowka, OD
Andrew S. Gurwood, OD
Alan G. Kabat, OD



Eyelids and Adnexa, PAGE 09
Conjunctiva and Sclera, PAGE 24
Corneal Disease, PAGE 35
Uvea and Glaucoma, PAGE 49
Vitreous and Retina, PAGE 66
Neuro-Ophthalmic Disease, PAGE 79

The Handbook of
**OCULAR DISEASE
MANAGEMENT**

18TH EDITION



Supplement to

REVIEW[®]
OF OPTOMETRY

JUNE 15, 2016

www.reviewofoptometry.com



Dr. Sowka



Dr. Gurwood



Dr. Kabat

★ ★ ★ THE MAIN EVENT ★ ★ ★



ZYLET[®]

"A ONE-TWO COMBO"

VS

BLEPHARITIS

**HELP PUT RELIEF
IN YOUR CORNER**

INDICATIONS AND USAGE

ZYLET[®] (loteprednol etabonate 0.5% and tobramycin 0.3% ophthalmic suspension) is a topical anti-infective and corticosteroid combination for steroid-responsive inflammatory ocular conditions for which a corticosteroid is indicated and where superficial bacterial ocular infection or a risk of bacterial ocular infection exists.

Please see additional Indications and Usage information on adjacent page, including list of indicated organisms.

INDICATIONS AND USAGE (continued)

Ocular steroids are indicated in inflammatory conditions of the palpebral and bulbar conjunctiva, cornea and anterior segment of the globe such as allergic conjunctivitis, acne rosacea, superficial punctate keratitis, herpes zoster keratitis, iritis, cyclitis, and where the inherent risk of steroid use in certain infective conjunctivides is accepted to obtain a diminution in edema and inflammation. They are also indicated in chronic anterior uveitis and corneal injury from chemical, radiation or thermal burns, or penetration of foreign bodies.

The use of a combination drug with an anti-infective component is indicated where the risk of superficial ocular infection is high or where there is an expectation that potentially dangerous numbers of bacteria will be present in the eye.

The particular anti-infective drug in this product (tobramycin) is active against the following common bacterial eye pathogens: *Staphylococci*, including *S. aureus* and *S. epidermidis* (coagulase-positive and coagulase-negative), including penicillin-resistant strains. *Streptococci*, including some of the Group A-beta-hemolytic species, some nonhemolytic species, and some *Streptococcus pneumoniae*, *Pseudomonas aeruginosa*, *Escherichia coli*, *Klebsiella pneumoniae*, *Enterobacter aerogenes*, *Proteus mirabilis*, *Morganella morganii*, most *Proteus vulgaris* strains, *Haemophilus influenzae*, and *H. aegyptius*, *Moraxella lacunata*, *Acinetobacter calcoaceticus* and some *Neisseria* species.

IMPORTANT SAFETY INFORMATION

- ZYLET® is contraindicated in most viral diseases of the cornea and conjunctiva including epithelial herpes simplex keratitis (dendritic keratitis), vaccinia, and varicella, and also in mycobacterial infection of the eye and fungal diseases of ocular structures.
- Prolonged use of corticosteroids may result in glaucoma with damage to the optic nerve, defects in visual acuity and fields of vision. Steroids should be used with caution in the presence of glaucoma. If this product is used for 10 days or longer, intraocular pressure should be monitored.
- Use of corticosteroids may result in posterior subcapsular cataract formation.
- The use of steroids after cataract surgery may delay healing and increase the incidence of bleb formation. In those diseases causing thinning of the cornea or sclera, perforations have been known to occur with the use of topical steroids. The initial prescription and renewal of the medication order should be made by a physician only after examination of the patient with the aid of magnification such as a slit lamp biomicroscopy and, where appropriate, fluorescein staining.
- Prolonged use of corticosteroids may suppress the host response and thus increase the hazard of secondary ocular infections. In acute purulent conditions, steroids may mask infection or enhance existing infections. If signs and symptoms fail to improve after 2 days, the patient should be re-evaluated.
- Employment of corticosteroid medication in the treatment of patients with a history of herpes simplex requires great caution. Use of ocular steroids may prolong the course and exacerbate the severity of many viral infections of the eye (including herpes simplex).
- Fungal infections of the cornea are particularly prone to develop coincidentally with long-term local steroid application. Fungus invasion must be considered in any persistent corneal ulceration where a steroid has been used or is in use.
- Most common adverse reactions reported in patients were injection and superficial punctate keratitis, increased intraocular pressure, burning and stinging upon instillation.

Please see Brief Summary of Prescribing Information on the following page.

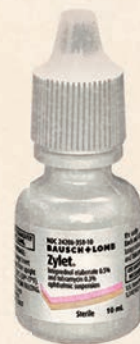With a one-two combo in
the treatment of blepharitis
and other steroid-responsive
ocular conditions with the
risk of bacterial infection,
PRESCRIBE ZYLET® TODAY.

BAUSCH + LOMB

©/™ are trademarks of Bausch & Lomb Incorporated or its affiliates.

© 2015 Bausch & Lomb Incorporated. All rights reserved. Printed in USA. US/ZYL/15/0013a

Zylet®
loteprednol etabonate
0.5% and tobramycin 0.3%
ophthalmic suspension



BRIEF SUMMARY OF PRESCRIBING INFORMATION

This Brief Summary does not include all the information needed to use Zylet safely and effectively. See full prescribing information for Zylet.

Zylet® (loteprednol etabonate 0.5% and tobramycin 0.3% ophthalmic suspension)
Initial U.S. Approval: 2004

DOSE AND ADMINISTRATION

2.1 Recommended Dosing

Apply one or two drops of Zylet into the conjunctival sac of the affected eye every four to six hours. During the initial 24 to 48 hours, the dosing may be increased, to every one to two hours. Frequency should be decreased gradually as warranted by improvement in clinical signs. Care should be taken not to discontinue therapy prematurely.

2.2 Prescription Guideline

Not more than 20 mL should be prescribed initially and the prescription should not be refilled without further evaluation [see *Warnings and Precautions* (5.3)].

CONTRAINDICATIONS

4.1 Nonbacterial Etiology

Zylet, as with other steroid anti-infective ophthalmic combination drugs, is contraindicated in most viral diseases of the cornea and conjunctiva including epithelial herpes simplex keratitis (dendritic keratitis), vaccinia, and varicella, and also in mycobacterial infection of the eye and fungal diseases of ocular structures.

WARNINGS AND PRECAUTIONS

5.1 Intraocular Pressure (IOP) Increase

Prolonged use of corticosteroids may result in glaucoma with damage to the optic nerve, defects in visual acuity and fields of vision. Steroids should be used with caution in the presence of glaucoma.

If this product is used for 10 days or longer, intraocular pressure should be monitored.

5.2 Cataracts

Use of corticosteroids may result in posterior subcapsular cataract formation.

5.3 Delayed Healing

The use of steroids after cataract surgery may delay healing and increase the incidence of bleb formation. In those diseases causing thinning of the cornea or sclera, perforations have been known to occur with the use of topical steroids. The initial prescription and renewal of the medication order should be made by a physician only after examination of the patient with the aid of magnification such as a slit lamp biomicroscopy and, where appropriate, fluorescein staining.

5.4 Bacterial Infections

Prolonged use of corticosteroids may suppress the host response and thus increase the hazard of secondary ocular infections. In acute purulent conditions of the eye, steroids may mask infection or enhance existing infection. If signs and symptoms fail to improve after 2 days, the patient should be re-evaluated.

5.5 Viral Infections

Employment of a corticosteroid medication in the treatment of patients with a history of herpes simplex requires great caution. Use of ocular steroids may prolong the course and may exacerbate the severity of many viral infections of the eye (including herpes simplex).

5.6 Fungal Infections

Fungal infections of the cornea are particularly prone to develop coincidentally with long-term local steroid application. Fungus invasion must be considered in any persistent corneal ulceration where a steroid has been used or is in use. Fungal cultures should be taken when appropriate.

5.7 Aminoglycoside Hypersensitivity

Sensitivity to topically applied aminoglycosides may occur in some patients. If hypersensitivity develops with this product, discontinue use and institute appropriate therapy.

ADVERSE REACTIONS

Adverse reactions have occurred with steroid/anti-infective combination drugs which can be attributed to the steroid component, the anti-infective component, or the combination.

Zylet:

In a 42 day safety study comparing Zylet to placebo, ocular adverse reactions included injection (approximately 20%) and superficial punctate keratitis (approximately 15%). Increased intraocular pressure was reported in 10% (Zylet) and 4% (placebo) of subjects. Nine percent (9%) of Zylet subjects reported burning and stinging upon instillation.

Ocular reactions reported with an incidence less than 4% include vision disorders, discharge, itching, lacrimation disorder, photophobia, corneal deposits, ocular discomfort, eyelid disorder, and other unspecified eye disorders.

The incidence of non-ocular reactions reported in approximately 14% of subjects was headache; all other non-ocular reactions had an incidence of less than 5%.

Loteprednol etabonate ophthalmic suspension 0.2% - 0.5%:

Reactions associated with ophthalmic steroids include elevated intraocular pressure, which may be associated with infrequent optic nerve damage, visual acuity and field defects, posterior subcapsular cataract formation, delayed wound healing and secondary ocular infection from pathogens including herpes simplex, and perforation of the globe where there is thinning of the cornea or sclera.

In a summation of controlled, randomized studies of individuals treated for 28 days or longer with loteprednol etabonate, the incidence of significant elevation of intraocular pressure (≥ 10 mm Hg) was 2% (15/901) among patients receiving loteprednol etabonate, 7% (11/164) among patients receiving 1% prednisolone acetate and 0.5% (3/583) among patients receiving placebo.

Tobramycin ophthalmic solution 0.3%:

The most frequent adverse reactions to topical tobramycin are hypersensitivity and localized ocular toxicity, including lid itching and swelling and conjunctival erythema. These reactions occur in less than 4% of patients. Similar reactions may occur with the topical use of other aminoglycoside antibiotics.

Secondary Infection:

The development of secondary infection has occurred after use of combinations containing steroids and antimicrobials. Fungal infections of the cornea are particularly prone to develop coincidentally with long-term applications of steroids.

The possibility of fungal invasion must be considered in any persistent corneal ulceration where steroid treatment has been used.

Secondary bacterial infection following suppression of host responses also occurs.

USE IN SPECIFIC POPULATIONS

8.1 Pregnancy

Teratogenic effects: Pregnancy Category C. Loteprednol etabonate has been shown to be embryotoxic (delayed ossification) and teratogenic (increased incidence of meningocele, abnormal left common carotid artery, and limb fixtures) when administered orally to rabbits during organogenesis at a dose of 3 mg/kg/day (35 times the maximum daily clinical dose), a dose which caused no maternal toxicity. The no-observed-effect-level (NOEL) for these effects was 0.5 mg/kg/day (6 times the maximum daily clinical dose). Oral treatment of rats during organogenesis resulted in teratogenicity (absent innominate artery at ≥ 5 mg/kg/day doses, and cleft palate and umbilical hernia at ≥ 50 mg/kg/day) and embryotoxicity (increased post-implantation losses at 100 mg/kg/day and decreased fetal body weight and skeletal ossification with ≥ 50 mg/kg/day). Treatment of rats at 0.5 mg/kg/day (6 times the maximum daily clinical dose) during organogenesis did not result in any reproductive toxicity. Loteprednol etabonate was maternally toxic (significantly reduced body weight gain during treatment) when administered to pregnant rats during organogenesis at doses of ≥ 5 mg/kg/day.

Oral exposure of female rats to 50 mg/kg/day of loteprednol etabonate from the start of the fetal period through the end of lactation, a maternally toxic treatment regimen (significantly decreased body weight gain), gave rise to decreased growth and survival and retarded development in the offspring during lactation; the NOEL for these effects was 5 mg/kg/day. Loteprednol etabonate had no effect on the duration of gestation or parturition when administered orally to pregnant rats at doses up to 50 mg/kg/day during the fetal period.

Reproductive studies have been performed in rats and rabbits with tobramycin at doses up to 100 mg/kg/day parenterally and have revealed no evidence of impaired fertility or harm to the fetus. There are no adequate and well controlled studies in pregnant women. Zylet should be used during pregnancy only if the potential benefit justifies the potential risk to the fetus.

8.3 Nursing Mothers

It is not known whether topical ophthalmic administration of corticosteroids could result in sufficient systemic absorption to produce detectable quantities in human milk. Systemic steroids that appear in human milk could suppress growth, interfere with endogenous corticosteroid production, or cause other untoward effects. Caution should be exercised when Zylet is administered to a nursing woman.

8.4 Pediatric Use

Two trials were conducted to evaluate the safety and efficacy of Zylet® (loteprednol etabonate and tobramycin ophthalmic suspension) in pediatric subjects age zero to six years; one was in subjects with lid inflammation and the other was in subjects with blepharoconjunctivitis.

In the lid inflammation trial, Zylet with warm compresses did not demonstrate efficacy compared to vehicle with warm compresses. Patients received warm compress lid treatment plus Zylet or vehicle for 14 days. The majority of patients in both treatment groups showed reduced lid inflammation.

In the blepharoconjunctivitis trial, Zylet did not demonstrate efficacy compared to vehicle, loteprednol etabonate ophthalmic suspension, or tobramycin ophthalmic solution. There was no difference between treatment groups in mean change from baseline blepharoconjunctivitis score at Day 15.

There were no differences in safety assessments between the treatment groups in either trial.

8.5 Geriatric Use

No overall differences in safety and effectiveness have been observed between elderly and younger patients.

NONCLINICAL TOXICOLOGY

13.1 Carcinogenesis, Mutagenesis, Impairment of Fertility

Long-term animal studies have not been conducted to evaluate the carcinogenic potential of loteprednol etabonate or tobramycin.

Loteprednol etabonate was not genotoxic *in vitro* in the Ames test, the mouse lymphoma TK assay, a chromosome aberration test in human lymphocytes, or in an *in vivo* mouse micronucleus assay.

Oral treatment of male and female rats at 50 mg/kg/day and 25 mg/kg/day of loteprednol etabonate, respectively, (500 and 250 times the maximum clinical dose, respectively) prior to and during mating did not impair fertility in either gender. No impairment of fertility was noted in studies of subcutaneous tobramycin in rats at 100 mg/kg/day (1700 times the maximum daily clinical dose).

PATIENT COUNSELING INFORMATION

This product is sterile when packaged. Patients should be advised not to allow the dropper tip to touch any surface, as this may contaminate the suspension. If pain develops, redness, itching or inflammation becomes aggravated, the patient should be advised to consult a physician. As with all ophthalmic preparations containing benzalkonium chloride, patients should be advised not to wear soft contact lenses when using Zylet.

MANUFACTURER INFORMATION

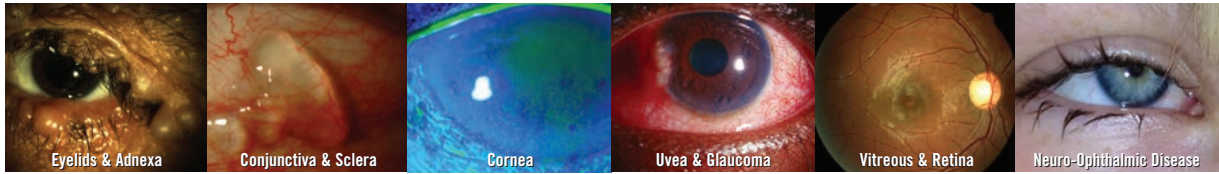
BAUSCH & LOMB INCORPORATED

TAMPA, FLORIDA 33637 USA

©Bausch & Lomb Incorporated

Zylet is a registered trademark of Bausch & Lomb Incorporated.

TABLE OF CONTENTS



EYELIDS AND ADNEXA

Acquired Ectropion	9
Ocular Rosacea	11
Neurofibromatosis.....	13
Verruca and Papilloma	16
Trichiasis.....	18

CONJUNCTIVA AND SCLERA

Conjunctivochalasis.....	24
Conjunctival Intraepithelial Neoplasia	26
Conjunctival Cysts.....	28
Mucus Fishing Syndrome	29
Giant Papillary Conjunctivitis.....	31

CORNEA

Acanthamoeba Keratitis.....	35
Toxic Keratoconjunctivitis	37
Vortex Keratopathy and Hurricane Keratopathy.....	40
Keratoconus and Corneal Hydrops	42
Terrien's Marginal Degeneration.....	45

UVEA AND GLAUCOMA

Phacomorphic Glaucoma.....	49
Phacolytic Glaucoma.....	53
Primary Chronic Angle Closure Glaucoma	55
Uveitic Glaucoma	57
Choroidal Rupture.....	60

VITREOUS AND RETINA

Angioid Streaks	66
Retinopathy of Prematurity.....	67
Solar Retinopathy.....	70
Idiopathic Macular Telangiectasis	72
Retinal Artery Occlusion.....	75

NEURO-OPHTHALMIC DISEASE

Ocular Myasthenia Gravis	79
Cranial Nerve III Palsy.....	81
Cranial Nerve IV Palsy	84
Cranial Nerve VI Palsy	87

This publication addresses the management of various conditions with support from the best available peer-reviewed literature. This is done to provide the most up-to-date management of patients with various conditions and to indicate when patient referral is appropriate. In many cases, the management may necessitate treatment from a specialist or subspecialist. This manuscript does not recommend that any doctor practice beyond the scope of licensure or level of personal comfort. It is up to the reader to understand the scope of state licensure and practice only within those guidelines.

A Peer-Reviewed Supplement

The articles in this supplement were subjected to *Review of Optometry's* peer-review process. The magazine employs a double-blind review system for clinical manuscripts in which experts in each subject review the manuscript before publication. This supplement was edited by the *Review of Optometry* staff.



IN MEMORIAM: LARRY ALEXANDER, OD

Larry Alexander was our friend. We could call him any time and ask a personal or professional question. He never failed to pick up the phone, not even in the middle of a busy day. He was a giant in the profession of optometry, not because of the committees he served on or the papers he wrote or the books he authored, but because he was revered by everybody who knew him. Like Muhammad Ali, Michael Jordan and Wayne Gretzky, he brought out the best in the people he touched and always found a way to make those who were around him better—better doctors and better human beings.

We met Larry early in our careers when we began lecturing at conferences. Larry was a legend then and his textbook, *Primary Care of the Posterior Segment*, was the quintessential optometric reference on the subject. It had both color and black-and-white photographs, along with magnificent schematic illustrations that clearly depicted the pathophysiology of each entity. It was well written, easy to understand and well referenced, permitting the reader to return to the original references if they wanted additional in-depth information.

Larry was in the audience but didn't introduce himself until after the program. He was not critical of us novices, but offered compliments and advice on how the talks could be made stronger, and volunteered to assist. He even offered access to his material. Larry proffered his business card and joked that it was like the "Bat Signal"—when called, he would help. He always did.

Larry was fun to be with. He had a great sense of humor and never took himself too seriously. He didn't suffer fools gladly either. He was forever humble. At a conference just last year, we were sitting together when Larry turned to us during a break and announced that he was going to get refreshments, and asked if he could bring us anything. Imagine—we were forever students in Larry's shadow, and yet, he was willing to wait on us. He was, simply put, the nicest man in the world.

Larry was a passionate guy who always took a stand. He was a participant, but you knew how Larry felt about what was being discussed. And he wasn't easily manipulated. He never shied away from taking the floor and always had a lot to say. Larry might not have been the best, but the best asked him the questions.

When Larry died, we watched as every major player in the profession expressed sadness, grief, disbelief and soul-searching remorse. Dr. Larry Alexander made us all better practitioners, and we are all better people for knowing him. Don McLean wrote the song "American Pie" to celebrate the life of Buddy Holly, proclaiming his death "the day the music died." To us, Larry Alexander's passing was the day the ophthalmoscope died. We lost a dear friend, colleague and mentor—a true original in the optometric world.



Larry Alexander



Joseph W. Sowka, OD, FAAO, Dipl., is a professor of optometry, program supervisor of the Primary Care with Emphasis in Ocular Disease Residency, instructor in glaucoma and retinal disease, and Chair of the Clinical Sciences Department at Nova Southeastern University College of Optometry. At the college's Eye Care Institute, he is the director of the Glaucoma Service and chief of the Advanced Care Service. Dr. Sowka is a founding member of the Optometric Glaucoma Society, the Optometric Retina Society and the Neuro-ophthalmic Disorders in Optometry Special Interest Group. He is currently the Chair of the Optometric Glaucoma Society Foundation. He is an American Academy of Optometry Diplomate in glaucoma. Dr. Sowka lectures nationally and internationally on topics in ocular disease. He can be reached at (954) 262-1472 or at jsowka@nova.edu.



Andrew S. Gurwood, OD, is a professor of clinical sciences, an attending optometric physician and co-chief in Suite 3 of the Eye Institute of the Pennsylvania College of Optometry at Salus University and a member of the clinical staff of Albert Einstein Medical Center Department of Ophthalmology. He is a founding member of the Optometric Retina Society and a member of the Optometric Glaucoma Society. Dr. Gurwood has lectured and published nationally and internationally on a wide range of subjects in ocular disease. He can be reached at agurwood@salus.edu.



Alan G. Kabat, OD, FAAO, is a professor at the Southern College of Optometry in Memphis, Tenn., where he teaches courses in ocular disease and clinical procedures. He is an attending physician at The Eye Center as well as clinical care consultant at TearWell Advanced Dry Eye Treatment Center. A recognized expert in the area of ocular surface disease, Dr. Kabat is a founding member of both the Optometric Dry Eye Society and the Ocular Surface Society of Optometry. He is also associate clinical editor of *Review of Optometry*. He can be reached at (901) 252-3691 or at alan.kabat@alankabat.com.

The authors have no direct financial interest in any product mentioned in this publication.



The PROLENSA® Effect POWERED FOR PENETRATION

Advanced Formulation to Facilitate
Corneal Penetration¹⁻³

PROLENSA® delivers potency and
corneal penetration with QD dosing
at a low concentration¹⁻³

INDICATIONS AND USAGE

PROLENSA® (bromfenac ophthalmic solution) 0.07% is a nonsteroidal anti-inflammatory drug (NSAID) indicated for the treatment of postoperative inflammation and reduction of ocular pain in patients who have undergone cataract surgery.

IMPORTANT SAFETY INFORMATION ABOUT PROLENSA®

- PROLENSA® contains sodium sulfite, a sulfite that may cause allergic type reactions including anaphylactic symptoms and life-threatening or less severe asthmatic episodes in certain susceptible people. The overall prevalence of sulfite sensitivity in the general population is unknown and probably low. Sulfite sensitivity is seen more frequently in asthmatic than in non-asthmatic people.
 - All topical nonsteroidal anti-inflammatory drugs (NSAIDs), including bromfenac, may slow or delay healing. Concomitant use of topical NSAIDs and topical steroids may increase the potential for healing problems.
 - There is the potential for cross-sensitivity to acetylsalicylic acid, phenylacetic acid derivatives, and other NSAIDs, including bromfenac. Use with caution in patients who have previously exhibited sensitivities to these drugs.
 - There have been reports that ocularly applied NSAIDs may cause increased bleeding of ocular tissues (including hyphemas) in conjunction with ocular surgery. Use with caution in patients with known bleeding tendencies or who are receiving other medications which may prolong bleeding time.
- Use of topical NSAIDs may result in keratitis. Patients with evidence of corneal epithelial breakdown should immediately discontinue use of topical NSAIDs, including bromfenac, and should be closely monitored for corneal health. Patients with complicated ocular surgeries, corneal denervation, corneal epithelial defects, diabetes mellitus, ocular surface diseases (e.g., dry eye syndrome), rheumatoid arthritis, or repeat ocular surgeries within a short period of time may be at increased risk for corneal adverse events which may become sight threatening. Topical NSAIDs should be used with caution in these patients. Post-marketing experience with topical NSAIDs suggests that use more than 24 hours prior to surgery or use beyond 14 days post-surgery may increase patient risk for the occurrence and severity of corneal adverse events.
 - PROLENSA® should not be instilled while wearing contact lenses. The preservative in PROLENSA®, benzalkonium chloride, may be absorbed by soft contact lenses. Lenses may be reinserted after 10 minutes following administration of PROLENSA®.
 - The most commonly reported adverse reactions in 3%-8% of patients were anterior chamber inflammation, foreign body sensation, eye pain, photophobia, and blurred vision.

Please see brief summary of full Prescribing Information for PROLENSA® on adjacent page.

References: 1. PROLENSA Prescribing Information, April 2013. 2. Data on file, Bausch & Lomb Incorporated. 3. Baklayan GA, Patterson HM, Song CK, Gow JA, McNamara TR. 24-hour evaluation of the ocular distribution of [¹⁴C]-labeled bromfenac following topical instillation into the eyes of New Zealand white rabbits. *J Ocul Pharmacol Ther.* 2008;24(4):392-398.

PROLENSA is a registered trademark of Bausch & Lomb Incorporated or its affiliates.
© Bausch & Lomb Incorporated. All rights reserved. Printed in USA. PRA.0188.USA.15

BAUSCH + LOMB

PROLENSA®
(bromfenac ophthalmic
solution) 0.07%

Brief Summary

INDICATIONS AND USAGE

PROLENSA® (bromfenac ophthalmic solution) 0.07% is indicated for the treatment of postoperative inflammation and reduction of ocular pain in patients who have undergone cataract surgery.

DOSAGE AND ADMINISTRATION**Recommended Dosing**

One drop of PROLENSA® ophthalmic solution should be applied to the affected eye once daily beginning 1 day prior to cataract surgery, continued on the day of surgery, and through the first 14 days of the postoperative period.

Use with Other Topical Ophthalmic Medications

PROLENSA ophthalmic solution may be administered in conjunction with other topical ophthalmic medications such as alpha-agonists, beta-blockers, carbonic anhydrase inhibitors, cycloplegics, and mydriatics. Drops should be administered at least 5 minutes apart.

CONTRAINDICATIONS

None

WARNINGS AND PRECAUTIONS**Sulfite Allergic Reactions**

Contains sodium sulfite, a sulfite that may cause allergic-type reactions including anaphylactic symptoms and life-threatening or less severe asthmatic episodes in certain susceptible people. The overall prevalence of sulfite sensitivity in the general population is unknown and probably low. Sulfite sensitivity is seen more frequently in asthmatic than in non-asthmatic people.

Slow or Delayed Healing

All topical nonsteroidal anti-inflammatory drugs (NSAIDs), including bromfenac, may slow or delay healing. Topical corticosteroids are also known to slow or delay healing. Concomitant use of topical NSAIDs and topical steroids may increase the potential for healing problems.

Potential for Cross-Sensitivity

There is the potential for cross-sensitivity to acetylsalicylic acid, phenylacetic acid derivatives, and other NSAIDs, including bromfenac. Therefore, caution should be used when treating individuals who have previously exhibited sensitivities to these drugs.

Increased Bleeding Time

With some NSAIDs, including bromfenac, there exists the potential for increased bleeding time due to interference with platelet aggregation. There have been reports that ocularly applied NSAIDs may cause increased bleeding of ocular tissues (including hyphemas) in conjunction with ocular surgery.

It is recommended that PROLENSA® ophthalmic solution be used with caution in patients with known bleeding tendencies or who are receiving other medications which may prolong bleeding time.

Keratitis and Corneal Reactions

Use of topical NSAIDs may result in keratitis. In some susceptible patients, continued use of topical NSAIDs may result in epithelial breakdown, corneal thinning, corneal erosion, corneal ulceration or corneal perforation. These events may be sight threatening. Patients with evidence of corneal epithelial breakdown should immediately discontinue use of topical NSAIDs, including bromfenac, and should be closely monitored for corneal health.

Post-marketing experience with topical NSAIDs suggests that patients with complicated ocular surgeries, corneal denervation, corneal epithelial defects, diabetes mellitus, ocular surface diseases (e.g., dry eye syndrome), rheumatoid arthritis, or repeat ocular surgeries within a short period of time may be at increased risk for corneal adverse events which may become sight threatening. Topical NSAIDs should be used with caution in these patients.

Post-marketing experience with topical NSAIDs also suggests that use more than 24 hours prior to surgery or use beyond 14 days post-surgery may increase patient risk for the occurrence and severity of corneal adverse events.

Contact Lens Wear

PROLENSA should not be instilled while wearing contact lenses. Remove contact lenses prior to instillation of PROLENSA. The preservative in PROLENSA, benzalkonium chloride may be absorbed by soft contact lenses. Lenses may be reinserted after 10 minutes following administration of PROLENSA.

ADVERSE REACTIONS**Clinical Trial Experience**

Because clinical trials are conducted under widely varying conditions, adverse reaction rates observed in the clinical trials of a drug cannot be directly compared to rates in the clinical trials of another drug and may not reflect the rates observed in clinical practice.

The most commonly reported adverse reactions following use of

PROLENSA® ophthalmic solution following cataract surgery include: anterior chamber inflammation, foreign body sensation, eye pain, photophobia and vision blurred. These reactions were reported in 3 to 8% of patients.

USE IN SPECIFIC POPULATIONS**Pregnancy**

Treatment of rats at oral doses up to 0.9 mg/kg/day (systemic exposure 90 times the systemic exposure predicted from the recommended human ophthalmic dose [RHOD] assuming the human systemic concentration is at the limit of quantification) and rabbits at oral doses up to 7.5 mg/kg/day (150 times the predicted human systemic exposure) produced no treatment-related malformations in reproduction studies. However, embryo-fetal lethality and maternal toxicity were produced in rats and rabbits at 0.9 mg/kg/day and 7.5 mg/kg/day, respectively. In rats, bromfenac treatment caused delayed parturition at 0.3 mg/kg/day (30 times the predicted human exposure), and caused dystocia, increased neonatal mortality and reduced postnatal growth at 0.9 mg/kg/day.

There are no adequate and well-controlled studies in pregnant women. Because animal reproduction studies are not always predictive of human response, this drug should be used during pregnancy only if the potential benefit justifies the potential risk to the fetus. Because of the known effects of prostaglandin biosynthesis-inhibiting drugs on the fetal cardiovascular system (closure of ductus arteriosus), the use of PROLENSA® ophthalmic solution during late pregnancy should be avoided.

Nursing Mothers

Caution should be exercised when PROLENSA is administered to a nursing woman.

Pediatric Use

Safety and efficacy in pediatric patients below the age of 18 have not been established.

Geriatric Use

There is no evidence that the efficacy or safety profiles for PROLENSA differ in patients 70 years of age and older compared to younger adult patients.

NONCLINICAL TOXICOLOGY**Carcinogenesis, Mutagenesis and Impairment of Fertility**

Long-term carcinogenicity studies in rats and mice given oral doses of bromfenac up to 0.6 mg/kg/day (systemic exposure 30 times the systemic exposure predicted from the recommended human ophthalmic dose [RHOD] assuming the human systemic concentration is at the limit of quantification) and 5 mg/kg/day (340 times the predicted human systemic exposure), respectively, revealed no significant increases in tumor incidence. Bromfenac did not show mutagenic potential in various mutagenicity studies, including the reverse mutation, chromosomal aberration, and micronucleus tests. Bromfenac did not impair fertility when administered orally to male and female rats at doses up to 0.9 mg/kg/day and 0.3 mg/kg/day, respectively (systemic exposure 90 and 30 times the predicted human exposure, respectively).

PATIENT COUNSELING INFORMATION**Slowed or Delayed Healing**

Advise patients of the possibility that slow or delayed healing may occur while using NSAIDs.

Sterility of Dropper Tip

Advise patients to replace bottle cap after using and to not touch dropper tip to any surface, as this may contaminate the contents. Advise patients that a single bottle of PROLENSA® ophthalmic solution, be used to treat only one eye.

Concomitant Use of Contact Lenses

Advise patients to remove contact lenses prior to instillation of PROLENSA. The preservative in PROLENSA, benzalkonium chloride, may be absorbed by soft contact lenses. Lenses may be reinserted after 10 minutes following administration of PROLENSA.

Concomitant Topical Ocular Therapy

If more than one topical ophthalmic medication is being used, the medicines should be administered at least 5 minutes apart.

Rx Only

Manufactured by: Bausch & Lomb Incorporated, Tampa, FL 33637
Under license from:
Senju Pharmaceuticals Co., Ltd.
Osaka, Japan 541-0046

Pro lensa is a trademark of Bausch & Lomb Incorporated or its affiliates.
© Bausch & Lomb Incorporated.

9317600

US/PRA/14/0024

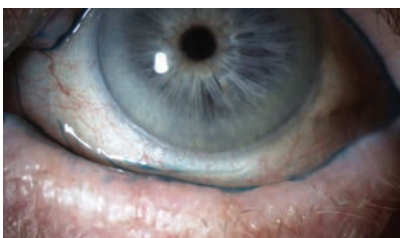
ACQUIRED ECTROPION

Signs and Symptoms

Ectropion represents a condition of eyelid malpositioning in which the lid margin rotates outward, away from the ocular surface.¹⁻⁶ This phenomenon may occur unilaterally or bilaterally and may involve the upper or lower eyelids, although the lower lids are affected far more frequently.⁵

Clinically, patients will demonstrate exposure of the posterior lid margin and palpebral conjunctiva to a variable degree. Often, the condition is first noted to affect the nasal aspect of the lid, causing punctal ectropion; over time, the medial and, ultimately, the temporal aspect may turn outward as well. When inferior ectropion is encountered, the lower eyelid will be seen to droop, resulting in greater visibility of the inferior bulbar conjunctiva and sclera (sometimes referred to as “inferior scleral show”). The eyelids may not close fully during sleep or when blinking, a condition known clinically as lagophthalmos. Loss of lid/globe apposition also frequently results in epiphora, as normal tear clearance through the punctum and lacrimal canaliculus is hindered.²

The increased exposure of the ocular surface associated with ectropion may result in signs of conjunctival hyperemia and punctate keratopathy.¹ Reported symptoms may include dryness, burning, foreign body sensation or nonspecific ocular irritation related to exposure



Clinically, patients with ectropion demonstrate exposure of the posterior lid margin and palpebral conjunctiva.

keratopathy. Vision may be variably affected, depending upon the stability of the tear film at the time of examination, or the extent and location of corneal damage. Untreated, ectropion may instigate keratinization and thickening of the palpebral conjunctiva, leading to greater symptomatology.

Pathophysiology

Acquired ectropion may result from any of four processes: *involutional*, *cicatricial*, *mechanical* or *paralytic* etiologies.

Involutional ectropion—sometimes referred to as senile ectropion—is generally associated with increasing age, and is considered the most common type of acquired ectropion.⁵ This condition affects the lower lids only, a result of gravity’s impact under the weight of the midfacial structures.⁶ Over time, structural changes—including dehiscence and disinsertion of the lower lid retractors, laxity of the medial and lateral canthal tendons, and atrophy or degeneration of the orbicularis oculi—cause the lower lid margin to lose its normal apposition to the globe and turn outward.⁵⁻⁷

Cicatricial ectropion may affect the upper or lower eyelids, and occurs as a result of improper healing following insult or inflammation. Causes may include: mechanical, chemical or thermal injury; toxic, infectious, infiltrative or autoimmune dermatopathies; or iatrogenic changes following excisional surgery or overly aggressive blepharoplasty.^{1,2,5-9} In each of these instances, a resulting vertical shortening of the anterior lamella (consisting of the skin and orbicularis portions of the eyelid) causes outward rotation of the lid margin.

Mechanical ectropion is encountered when a mass lesion, such as a large tumor or cyst, imparts its weight to the lower eyelid, causing it to droop and turn away from the globe.^{1,5,6} This may also occur with extreme cases of herniated orbital fat in the lower lid.¹

Finally, *paralytic ectropion* results from a loss of innervation by the facial nerve (cranial nerve VII), as may occur in cases of stroke, nerve damage due to surgery or trauma, compressive tumor or Bell’s palsy.¹ Patients with paralytic ectropion typically manifest a concurrent ptosis of the upper brow and lid, drooping of the corner of the mouth and a relative loss of muscular control on the ipsilateral side.

Management

Appropriate management for acquired ectropion depends upon the underlying etiology as well as the severity of the condition. Since the potential exists for permanent ocular surface compromise, intervention must be active rather than passive. Supportive therapy with artificial tears and/or ointments can help temporarily mitigate the desiccative effects of exposure, as can the use of moist chamber spectacles. It may be particularly helpful to employ a bland ointment while sleeping, with or without a mask, patch or eyelid taping to keep the eyelid closed as much as possible.

Mild cases of involutional ectropion that do not warrant surgery (or cases in which patients are averse to surgery) may be managed with the use of adhesive strips to temporarily restore appropriate lid-globe apposition.¹⁰ Pre-sized Steri-Strip elastic skin closures (3M Healthcare) in the 50mm x 100mm size can be ideal for this purpose; alternatively, clear surgical tape such as Transpore or Nexcare (3M Healthcare) can be cut to size by the patient. The adhesive should be affixed about 5mm to 10mm below the midline of the lower eyelid and directed superotemporally, securing it to the zygomatic region.

Surgery remains the definitive treatment for involutional ectropion, although numerous procedures may be applicable. Cases of punctal ectro-

pion alone may be managed using a medial spindle procedure; this suturing technique removes a small, diamond-shaped area of palpebral conjunctiva and tarsus from the lower eyelid and tightens the underlying lid retractors, helping to turn the lid margin inward.^{5,6,11} More pronounced involuntional ectropion may require a subsequent or concomitant lateral tarsal strip procedure, which serves to overcome horizontal eyelid laxity.^{3,5,6} In this technique, a full-thickness wedge of eyelid tissue is dissected away from the lateral canthus, after which the canthal tendon is reattached to orbital periosteum, stretching the lower lid taut.³ If laxity persists at the nasal aspect of the lid, a medial canthal tendon plication procedure can further tighten the nasal aspect of the eyelid by anchoring the tendon to the anterior periosteum.¹²

Cicatricial ectropion often requires surgical intervention, though milder cases caused by toxicity or actinic changes may respond to local massage with a topical steroid preparation (e.g., hydrocortisone 1% cream twice daily for two weeks).^{6,13} The use of hyaluronic acid filler injections has also been used successfully in some cases of lower lid ectropion associated with actinic skin damage.¹⁴

Surgical management is aimed at lengthening of the anterior lamella, release of scar tissue and horizontal tightening of the affected eyelid.^{5,6} Z-plasty, a procedure that involves the simple transposition of two interdigitating triangular flaps of tissue along the scar line, produces a substantial gain in length in the involved meridian.¹⁵ More severe scarring may necessitate the use of a full-thickness skin graft, usually harvested from the retroauricular space.^{5,6}

Mechanical ectropion management is straightforward, involving surgical excision of the inciting mass lesion with the subsequent application of skin grafting

as necessary.^{6,16} In cases of herniated orbital fat resulting in ectropion, lower lid blepharoplasty using a transconjunctival approach may improve both cosmesis and eyelid apposition.

Paralytic ectropion represents the one category that can demonstrate spontaneous recovery. Hence, the clinician should employ conservative therapy initially, monitoring for improvement. This is particularly true in cases attributable to Bell's palsy, which typically resolves within three weeks of onset, regardless of treatment.¹⁷ Those cases that persist may be addressed using management strategies similar to those for involuntional ectropion. Although lateral tarsal strip procedures are most common, periosteal flap canthoplasty has recently been used successfully to overcome horizontal eyelid laxity and elevate the lower eyelid in cases of paralytic ectropion.¹⁸

Clinical Pearls

- In contrast to acquired ectropion, congenital ectropion may be encountered at birth. This phenomenon is exceedingly rare and typically associated with other developmental anomalies such as euryblepharon, blepharoptosis, epicanthus inversus and blepharophimosis syndrome.⁵

- Focused physical testing can aid in the diagnosis of ectropion. One such examination technique is the "snap-back" test. The patient is asked to look up slightly while the examiner pulls the lower eyelid inferiorly; if the eyelid fails to return to its normal anatomical position within one or two seconds prior to blinking, it is indicative of pathological laxity.¹⁹ Another diagnostic technique is the dislocation or distraction test. This is performed by grasping the lower eyelid and pulling it anteriorly away from the globe. If the lid can be pulled more than 7mm from the globe, it is again indicative of increased horizontal lid laxity and ectropion.¹⁹

- While involuntional ectropion is the most common form of ectropion encountered clinically, physicians must be careful not to overlook cicatricial etiologies. Numerous dermatological conditions can lead to cicatricial ectropion, including actinic changes, chronic contact dermatitis, discoid lupus erythematosus, Stevens-Johnson syndrome, psoriatic arthritis, lymphoma, ichthyosis, herpes zoster ophthalmicus, pyoderma gangrenosum and others.^{2,6,14,15,20-24}

- In cases of paralytic ectropion associated with Bell's palsy, treatment with high-dose systemic corticosteroid therapy is indicated, and should be initiated within the first 72 hours after onset. Generally, a 10-day course of therapy is recommended, e.g., prednisone 60mg PO daily for five days, then tapered down by 10mg each day for another five days.¹⁷ Remember, too, that Bell's palsy is a diagnosis of exclusion, and should only be entertained after other etiologies are effectively ruled out; these include stroke, demyelinating disease, parotid gland tumor, Lyme disease, Ramsay-Hunt syndrome, diabetes and trauma.

1. Piskiniene R. Eyelid malposition: lower lid entropion and ectropion. *Medicina (Kaunas)*. 2006;42(11):881-4.
2. Gracitelli CP, Osaki TH, Valdrighi NY, et al. Cicatricial ectropion secondary to psoriatic arthritis. *Case Rep Ophthalmol Med*. 2015;2015:315465.
3. Kam KY, Cole CJ, Bunce C, et al. The lateral tarsal strip in ectropion surgery: is it effective when performed in isolation? *Eye (Lond)*. 2012;26(6):827-32.
4. Li XQ, Wang JQ. Orbicularis oculi myocutaneous flap for upper cicatricial ectropion. *J Craniofac Surg*. 2016;27(1):70-3.
5. Bedran EG, Pereira MV, Bernardes TF. Ectropion. *Semin Ophthalmol*. 2010;25(3):59-65.
6. Vallabhanath P, Carter SR. Ectropion and entropion. *Curr Opin Ophthalmol*. 2000;11(5):345-51.
7. Damasceno RW, Avgitidou G, Belfort R Jr, et al. Eyelid aging: pathophysiology and clinical management. *Arq Bras Oftalmol*. 2015;78(5):328-31.
8. Kopsachilis N, Tsaousis KT, Tourtas T, et al. Severe chronic blepharitis and scarring ectropion associated with discoid lupus erythematosus. *Clin Exp Optom*. 2013;96(1):124-5.
9. Bandyopadhyay R, Chatterjee A, Banerjee S, et al. Frontal osteomyelitis presenting as upper eyelid ectropion: a cautionary tale. *Saudi J Ophthalmol*. 2015;29(3):238-41.
10. Schrom T, Habermann A. Temporary ectropion therapy by adhesive taping: a case study. *Head Face Med*. 2008;4:12.
11. Nowinski TS, Anderson RL. The medial spindle procedure for involuntional medial ectropion. *Arch Ophthalmol*. 1985;103(11):1750-3.

12. Olver JM. Surgical tips on the lateral tarsal strip. *Eye (Lond)*. 1998;12(Pt 6):1007-12.
13. Hegde V, Robinson R, Dean F, et al. Drug-induced ectropion: what is best practice? *Ophthalmology*. 2007;114(2):362-6.
14. Fezza JP. Nonsurgical treatment of cicatricial ectropion with hyaluronic acid filler. *Plast Reconstr Surg*. 2008;121(3):1009-14.
15. Barreiros H, Goulão J. Z-Plasty: useful uses in dermatologic surgery. *An Bras Dermatol*. 2014;89(1):187-8.
16. Miletic D, Elabjer BK, Bosnar D, et al. Our approach to operative treatment of lower lid ectropion. *Acta Clin Croat*. 2010;49(3):283-7.
17. Patel DK, Levin KH. Bell palsy: Clinical examination and management. *Cleve Clin J Med*. 2015;82(7):419-26.
18. Korteweg SF, Stenekes MW, van Zyl FE, et al. Paralytic ectropion treatment with lateral periosteal flap canthoplasty and introduction of the ectropion severity score. *Plast Reconstr Surg Glob Open*. 2014;2(5):e151.
19. Skopin L Jr. A review of entropion and its management. *Cont Lens Anterior Eye*. 2003;26(2):95-100.
20. Probst LE, Burt WL, Heathcote JG. Mucosin fungoides causing lower lid ectropion. *Can J Ophthalmol*. 1993;28(7):333-8.
21. Hutchinson JK, Gurwood AS. Iatrogenically induced Stevens-Johnson syndrome after a car accident. *Optometry*. 2011;82(1):9-14.
22. Mucous membrane graft for cicatricial ectropion in lamellar ichthyosis: an approach revisited. *Ophthalmol Plast Reconstr Surg*. 2011;27(6):e155-6.
23. Sanghvi C, Leatherbarrow B, Ataulah S. Cicatricial ectropion due to herpes zoster ophthalmicus. *J Postgrad Med*. 2006;52(2):153-4.
24. Procianny F, Barbato MT, Osowski LE, et al. Cicatricial ectropion correction in a patient with pyoderma gangrenosum: case report. *Arq Bras Oftalmol*. 2009;72(3):384-6.
25. Hohman MH, Hadlock TA. Etiology, diagnosis, and management of facial palsy: 2000 patients at a facial nerve center. *Laryngoscope*. 2014;124(7):E283-93.

OCULAR ROSACEA

Signs and Symptoms

Ocular rosacea is a common, chronic inflammatory centro-facial dermatosis.¹⁻⁹ The condition affects approximately 16 million Americans, with up to 7% experiencing some form of ocular surface abnormality.^{9,10} It is characterized by facial dermatologic flushing, redness and dilated blood vessels (erythematotelangiectatic rosacea), pimples and pustules (papulopustular rosacea), and thickening of the skin (phymatous rosacea)—with these forms often occurring simultaneously, specifically around the nose and eyes.^{1,2}

The ocular tissues and eyelids may become involved through simultaneous evolution of a related blepharoconjunctivitis (ocular rosacea).¹⁻⁶ Thickening, with vascular changes of the skin

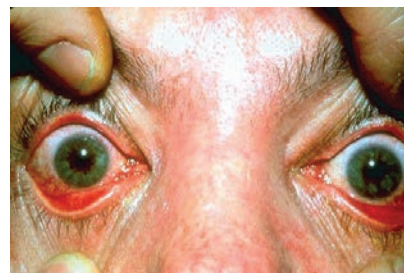around the affected areas, results from chronic, recurring or unmanaged disease leading to tissue enlargement (phyma).² An example of this is the classic sign of chronic disease: the asymmetric and bulbous enlargement of the nose, known as rhinophyma (sometimes referred to in the medical community as “W.C. Fields nose”).^{1,2}

Rosacea prevalence is highest (i.e., between 2.7% and 10%) in patients of Northern European or Celtic heritage.^{5,6} Individuals with fair skin seem to be more frequently affected, with the Asian and African races less so.^{5,6} Since there is a racial predilection, and because the condition is often present in multiple family members, a genetic component is suspected but, to date, has not been confirmed.^{5,7,8} The disease is more common among female patients, with a peak incidence between the ages of 30 and 50 years.⁶

Ocular signs and symptoms are consistent with seborrheic blepharitis: adnexal and lid skin redness with dermatologic dandruff and lid debris, crusting and matting of the cilia, foreign body sensation, ocular irritation, dryness, ocular burning, hordeolum formation, chalazion formation, injection of the conjunctiva with lacrimation and, in the worst cases, development of a lateral canthal fissure with resultant epiphora. Chronic inflammatory and mechanical vectors can compromise conjunctivo-corneal homeostasis, leading to: inferior punctate keratopathy, recurrent corneal epithelial defects, basement membrane pathology; the movement of white blood cells into the affected cornea, producing subepithelial infiltrates, keratolysis, and thinning or scarring; subclinical and clinical iritis, development of pannus, and, in extreme, unmanaged cases, fibrosis and symblepharon.⁵⁻¹⁰

Pathophysiology

Four distinct subtypes of rosacea have been recognized.¹⁻¹¹ The classifications



Bilateral ocular rosacea with classic inferior bulbar and palpebral conjunctival injection is evident here.

are labeled by their characteristics: *erythematotelangiectatic rosacea* (exhibiting transient and non-transient facial flushing with telangiectasia), *papulopustular rosacea* (inflammatory papules and pustules), *phymatous rosacea* (enlargement of the skin around the affected areas) and *ocular rosacea*.⁵⁻⁸

Although the exact pathogenesis of rosacea remains unknown, dysregulation of the innate immune system, overgrowth of skin organisms (bacteria such as *Staphylococcus* species, streptococcal species and *Chlamydia trachomatis*) and aberrant neurovascular signaling have all been implicated.¹⁻¹³ Theories regarding pathogenesis extrapolated from clinical and experimental data include: 1) exposure to ultraviolet (UV) radiation; 2) reactive oxygen species (including superoxide and hydroxyl radicals, hydrogen peroxide and singlet oxygen); 3) vascular hyper-reactivity; 4) neuropeptide expansion; 5) exacerbation of innate immune response; 6) microbes, in particular *Helicobacter pylori*, and environmental aggressors such as the *Demodex* mite.¹³

While the ophthalmic and dermatologic communities have pulled back on the impact of *H. pylori* as a causative factor, citing too many contradictory reports, *Demodex folliculorum* has been implicated in subtype II—papulopustular rosacea—created by the expansion of blood and lymphatic vessels, the leakage of fluid and accumulation of cellular infiltrate.^{6,12,13} Greater numbers of mites have been identified in the

lashes of these patients. Further, it has been hypothesized the mites themselves harbor bacteria that exacerbate the immune/inflammatory process.^{6,13} The organisms activate immune mechanisms in predisposed rosacea patients, serving as a trigger leading to the papular and/or pustular phenotype.⁶ Other unknown cofactors may be present as well.⁶

In contradistinction to other common inflammatory skin diseases such as psoriasis, lupus erythematosus or atopic dermatitis, the formula of cytokines and chemokines that orchestrate the initiation and perpetuation of rosacea are not fully known.⁶ The zinc-dependent endopeptidase, matrix metalloproteinase (MMP), specifically MMP-2 and MMP-9, have been isolated in the tear fluid of patients with corneal melting (keratolysis), recurrent corneal erosion and ocular rosacea.¹⁴ These substances have the potential to degrade all types of extracellular matrix.¹⁴

During the early stages of disease, the innate immune system—along with neurovascular dysregulation—drives the dermatologic and ocular pathophysiology.⁵⁻¹³ Activation of the innate and adaptive immune systems and enhanced neuroimmune communications induce blood vessel and lymphatic vessel changes, with chemical messengers activating resident cells in the overlying skin, creating the red and scaly appearance of the adnexa.⁵⁻¹⁰ The local immunoinflammatory cascade induces the ocular complications. The reactive model also accounts for the classic effect of the speculated trigger activators, which can episodically induce acute episodes.^{6,8-13}

Sun exposure with its UV radiation and thermal signature raises the temperature of the skin, promoting flushing and response of the immune system.^{6,8,11} Spicy food, smoking, noxious chemicals, alcohol and temperature fluctuations (like being exposed to steam or the dry heat of a sauna, and even aggressive exercise) are also capable of

modulating vascular function.^{6,8,11} The effect of bacterial protein production can activate sensory nerves and prompt the immune system to start the aberrant cascade, although it is still unclear whether neuronal activation precedes or follows the inflammatory infiltrate.⁵⁻¹¹ Finally, the autonomic and/or sensory nervous system and its effect on neuronal dysregulation has received attention as its modulation (via alpha-adrenergic receptors or beta-adrenergic blockers) seems to help some patients.^{6,11}

Management

True ocular rosacea is not curable, merely controllable. Once the disease has been identified, patient education should be delivered so that as many triggers as possible can be avoided.¹⁻¹³ Since the signs and symptoms of ocular rosacea are generated by local and systemic components, both should be addressed.¹⁴⁻²²

Lid scrubs can maintain normal eyelid and adnexal skin flora and cleanliness. Topical lubricants can keep the ocular surface moist and free from frictional and mechanical trauma. Topical antibiotics and antibiotic/steroid combinations can be employed to eradicate local infection and suppress ocular inflammation. If recurrent erosions are present, bandage contact lenses and amniotic membranes may assist healing. Topical dermatologic antibiotic gels such as metronidazole, clindamycin, erythromycin and ivermectin can be prescribed QD or BID to resolve low-level skin infections, and can be used over long periods of time to maintain control during periods of acute aggravation.¹⁵⁻¹⁷ Use of topical vasoconstrictive agents such as azelaic acid 15% gel or brimonidine tartrate 0.5% gel, QD or BID, can improve cosmesis and quell symptoms.^{3,15,18,19} A three-week course of oral antibiotics such as doxycycline 100mg BID, tetracycline 250mg QID or an azythromycin taper will cure infec-

tion through antimicrobial control, while reducing systemic inflammation through MMP, interleukin and tumor necrosis factor-alpha suppression.²⁰

Low-dose oral antibiotics such as Periostat (20mg doxycycline hyclate QD) and Oracea (30mg immediate-release and 10mg delayed-release doxycycline monohydrate, QD) can be prescribed for long-lasting chronic therapy in recalcitrant or severe conditions.²¹

Topical cyclosporine ophthalmic emulsion has demonstrated effectiveness as well for ocular manifestations of rosacea.³

D. folliculorum and *Demodex brevis* infestation can be diagnosed by taking a complete-lash sample (one must get the root/follicle as that is where the organisms reside) and placing it under a light microscope to observe inhabiting organisms. If *Demodex* is found in the setting of blepharitic disease, treatment may be started with topical tea tree oil derived from the plant species *Melaleuca alternifolia*, which can be purchased from most natural health care stores or the commercially available Cliradex towelettes (4-terpineol, Bio-Tissue) BID to the affected areas over a 60-day period.^{22,23}

Clinical Pearls

- Triggers in susceptible patients with an altered vascular dysregulation system include: thermal heat and heat generated from chemicals in therapeutic ointments, creams, spicy foods and UV radiation (e.g., tanning bed); poor hygiene or chronic exposure to undesirable matter such as dirt, dust, oils, aerosolized chemicals, cigarette or cigar smoke; as well as illness or malaise.

- Ocular rosacea does occur in individuals with pigmented skin but may be harder to identify, as the chronic skin changes may be overlooked.

- The hallmark of ocular rosacea is that it responds well to topical steroids but reoccurs quickly when the medication is discontinued.

Blepharoconjunctivitis that returns following cessation of a topical antibiotic/steroid combination must be suspected as ocular rosacea.

- “Steroid addiction” is a common complication of the disease. As patients realize the benefits of prescribed or over-the-counter topical steroids, they often begin to self-administer, creating complications that range from thinning epidermal and dermal layers to the manifestation of a new condition known as perioral dermatitis.

- When treating *Demodex*, the initial eradication of the mites will not account for the 30-day incubation period; as such, a minimum of 60 days of treatment is recommended, with maintenance depending upon the individual.^{22,23}

1. Libon F, El Hayderi L, Nikkels-Tassoudji N, et al. Rosacea. *Rev Med Liege*. 2015;70(4):179-85.

2. Mokos ZB, Kummer A, Mosler EL, et al. Perioral dermatitis; still a therapeutic challenge. *Acta Clin Croat*. 2015;54(2):179-85.

3. van Zuuren EJ, Fedorowicz Z, Carter B, et al. Interventions for rosacea. *Cochrane Database Syst Rev*. 2015;4:CD003262.

4. Two AM, Wu W, Gallo RL, et al. Rosacea: part I. Introduction, categorization, histology, pathogenesis, and risk factors. *J Am Acad Dermatol*. 2015;72(5):749-58.

5. Steinhoff M, Schaubert J, Leyden JJ. New insights into rosacea pathophysiology: a review of recent findings. *J Am Acad Dermatol*. 2013;69(6 Suppl 1):S15-26.

6. Steinhoff M, Buddenkotte J, Aubert J, et al. Clinical, cellular, and molecular aspects in the pathophysiology of rosacea. *J Invest Dermatol Symp Proc*. 2011;15(1):2-11.

7. Feldman SR, Huang WW, Huynh TT. Current drug therapies for rosacea: a chronic vascular and inflammatory skin disease. *J Manag Care Spec Pharm*. 2014;20(6):623-9.

8. Schaubert J, Homey B, Steinhoff M. Current insights into the pathophysiology of rosacea. *Hautarzt*. 2013;64(7):481-8.

9. Jenkins MS, Brown SI, Lempert SL, et al. Ocular rosacea. *Metab Pediatr Syst Ophthalmol*. 1982;6(3-4):189-95.

10. Afonso AA, Sobrin L, Monroy DC, et al. Tear fluid gelatinase B activity correlates with IL-1 α concentration and fluorescein clearance in ocular rosacea. *Invest Ophthalmol Vis Sci*. 1999;40(11):2506-12.

11. Del Rosso JQ, Gallo RL, Kircik L, et al. Why is rosacea considered to be an inflammatory disorder? The primary role, clinical relevance, and therapeutic correlations of abnormal innate immune response in rosacea-prone skin. *J Drugs Dermatol*. 2012;11(6):694-700.

12. Gallo R, Drago F, Paolino S, et al. Rosacea treatments: What's new and what's on the horizon? *Am J Clin Dermatol*. 2010;11(5):299-303.

13. Mc Aleer MA, Lacey N, Powell FC. The pathophysiology of rosacea. *G Ital Dermatol Venereol*. 2009;144(6):663-71.

14. Sakimoto T, Sawa M. Metalloproteinases in corneal diseases: degradation and processing. *Cornea*. 2012;31(11 Suppl 1):S50-6.

15. van Zuuren EJ, Fedorowicz Z. Interventions for Rosacea. *JAMA*. 2015;314(22):2403-4.

16. Ali ST, Alinia H, Feldman SR. The treatment of rosacea with topical ivermectin. *Drugs Today (Barc)*. 2015;51(4):243-50.

17. Taieb A, Ortonne JP, Ruzicka T, et al. Superiority of ivermectin 1% cream over metronidazole 0.75% cream in treating inflammatory lesions of rosacea: a randomized, investigator-blinded trial. *Br J Dermatol*. 2015;172(4):1103-10.

18. Fowler JI, Jarratt M, Moore A, et al. Once-daily topical brimonidine tartrate gel 0.5% is a novel treatment for moderate to severe facial erythema of rosacea: results of two multicentre, randomized and vehicle-controlled studies. *Br J Dermatol*. 2012;166(3):633-41.

19. Del Rosso JQ, Kircik LH. Update on the management of rosacea: a status report on the current role and new horizons with topical azelaic acid. *J Drugs Dermatol*. 2014;13(12):s101-7.

20. Akhyani M, Ehsani AH, Ghiasi M, et al. Comparison of efficacy of azithromycin vs. doxycycline in the treatment of rosacea: a randomized open clinical trial. *Int J Dermatol*. 2008;47(3):284-8.

21. Shehwaro N, Langlois AL, Gueutin V, et al. Doxycycline or how to create new with the old? *Therapie*. 2014;69(2):129-41.

22. Cheng AM, Sheha H, Tseng SC. Recent advances on ocular *Demodex* infestation. *Curr Opin Ophthalmol*. 2015;26(4):295-300.

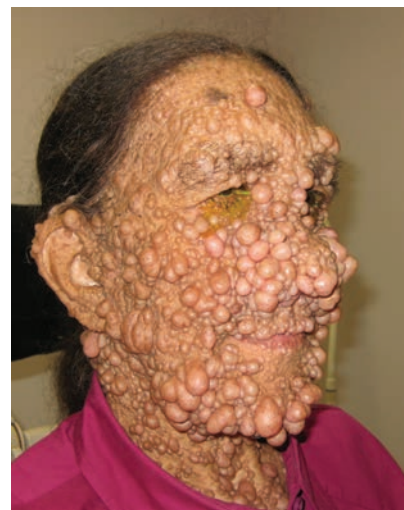23. Randon M, Liang H, El Hamdaoui M, et al. In vivo confocal microscopy as a novel and reliable tool for the diagnosis of *Demodex* eyelid infestation. *Br J Ophthalmol*. 2015;99(3):336-41.

NEUROFIBROMATOSIS

Signs and Symptoms

Neurofibromatosis (NF) is a rare, congenital, multisystem disorder that potentially involves the skin, eyes, nerves, brain and/or bones. The two basic forms of NF include type 1 (NF1) and type 2 (NF2), although NF1 is far more common, representing more than 90% of cases encountered clinically.^{1,2} Patients with NF1 display a variety of characteristic findings, some of which may be noted at birth; however, the majority of signs and symptoms typically develop in early childhood and progress throughout life. NF2 is usually diagnosed later in life, typically between ages 20 and 30, although children may sometimes manifest the disease.³ NF1 and NF2 may be encountered in both genders and in all races. Roughly half of all cases present with a family history of the disease, while the other half appear to be the result of a spontaneous mutation.⁴

A diagnosis of NF1 may be established by the identification of two or more of the following clinical features:



Cutaneous neurofibromas and/or plexiform neurofibromas are the hallmark skin finding in neurofibromatosis type 1, presenting in late childhood/early adolescence and potentially increasing in size and number throughout life.

- *Café-au-lait macules (CALM)*.

These hyperpigmented skin lesions, seen in up to 95% of individuals with NF1, may be present at birth or appear later. They typically increase in size and number during the first decade of life.^{2,4} In order to be diagnostic for NF1, six or more CALM must be present, with a linear diameter of ≥ 5 mm in prepubescent individuals or ≥ 15 mm in postpubescent individuals.¹⁻⁴

- *Skinfold freckling*. Sometimes referred to as *Crowe sign*, these freckles are typically small and classically noted in the axillary (armpit) and inguinal (groin) region.^{2,5} Additional sites for freckling may include areas superior to the eyelids, beneath the breasts and around the neck.²

- *Cutaneous neurofibromas and/or plexiform neurofibromas*. Cutaneous neurofibromas are the hallmark skin finding in NF1, representing dysplastic tumors formed by axonal processes, Schwann cells, fibroblasts, perineural cells and mast cells.⁴ These lesions usually present in late childhood or early adolescence, and may increase in size and number throughout life. They

are typically skin-colored and soft-textured, protruding from the skin surface. Cutaneous neurofibromas may vary considerably in size, sometimes achieving diameters of 5cm or larger.⁴ In most cases, cutaneous neurofibromas are not painful; however, some patients may report itching and tenderness to touch. When they involve the eyelids and adnexa, these lesions may preclude normal ocular hygiene and predispose the patient to blepharitis. They may also induce mechanical ptosis or ectropion.

In contrast to cutaneous neurofibromas, plexiform neurofibromas are seen in only about 30% of patients. They arise from multiple nerve fascicles and tend to grow lengthwise along the nerves, invading surrounding structures including the skin, fascia, muscle, bone and even internal organs.² Like cutaneous neurofibromas, these lesions are typically seen in childhood, but continue to develop through adolescence and early adulthood. Unlike cutaneous neurofibromas, plexiform neurofibromas may cause significant pain by virtue of their extension into adjacent tissue. Additionally, they may cause substantial disfigurement as they expand. In order to be diagnostic for NF1, the patient must present with two or more cutaneous neurofibromas, or one plexiform neurofibroma.¹⁻⁴

• **Lisch nodules.** These raised, pigmented iris lesions represent focal hamartomas within the iris stroma and are highly diagnostic for NF1.^{1,2,4,6} Lisch nodules can be visualized on biomicroscopy in NF patients as young as six years of age. They appear as focal, well-circumscribed, dome-shaped lesions projecting from the surface of the iris, and varying in color from clear yellow to brown.^{4,6} Unlike iris nodules seen in other systemic disorders such as sarcoidosis or tuberculosis, Lisch nodules are not associated with anterior uveitis and patients generally remain asymp-

tomatic.⁴ In order to be diagnostic for NF1, two or more Lisch nodules must be present.¹⁻⁴

• **Optic pathway gliomas.** These tumors represent the most common intracranial neoplasm in patients with NF1.⁷ They affect roughly 15% of children with NF1, and typically arise during the first decade of life.^{2,7-9} As compared with spontaneously occurring gliomas, NF1-associated gliomas are most often located along the optic nerve as opposed to the chiasmal or postchiasmal regions.⁸ While most patients manifesting these lesions are asymptomatic at the time of diagnosis, others may suffer from proptosis (sometimes displaying choroidal folds), visual acuity or visual field deficit, relative afferent pupillary defect, strabismus and optic disc edema or atrophy.^{9,10} Confirmatory diagnosis of optic pathway gliomas involves neuroimaging, specifically computed tomography (CT) or magnetic resonance imaging (MRI) of the orbit, chiasm and brain.

• **Osseous lesions.** Patients with NF1 are prone to a wide range of skeletal dysplasias. These may include *sphenoid wing dysplasia* (typically unilateral, abnormal development of the sphenoid bone resulting in orbital enlargement with subsequent enophthalmos or downward displacement of the globe), *dystrophic scoliosis* (curvature of the spine in a sideways or lateral orientation), *tibial pseudoarthrosis* (abnormal thinning and bowing of the leg bone, predisposing affected individuals to pathologic weight-bearing fractures and simulating the appearance of a false joint), *pectus excavatum* and *pectus carinatum* (deformities of the chest and sternum resulting in either a sunken or protruding appearance, respectively), *macrocephaly* (enlargement of the skull and head in excess of two standard deviations of the normal circumference for any developmental age) and overall short stature.^{1-4,11,12}

• **Familial involvement.** Any first-degree relative with NF is substantial, and is considered a diagnostic feature when associated with any of the aforementioned clinical findings.¹⁻⁴

Manifestations of NF2 are primarily limited to the central nervous system, but this condition can also demonstrate ocular involvement. The distinguishing feature of NF2 is the presence of bilateral vestibular schwannomas (also known as acoustic neuromas, acoustic neurinomas or acoustic neurilemmomas), which are benign, typically slow-growing tumors that affect the vestibulocochlear nerve (CN VIII).^{3,13,14} Hearing loss due to vestibular schwannomas is the most common symptom associated with NF2, and may be accompanied by tinnitus and balance problems. Additional neurological findings may include multiple meningiomas, cranial nerve tumors and tumors of the spinal column.^{3,13,14}

Specific ocular findings may include visual field loss from optic gliomas, peripheral cranial nerve VII palsy with lagophthalmos associated with acoustic neuroma or, more commonly, juvenile cataracts of the posterior subcapsular or cortical variety.^{3,13,14} Cataracts are believed to occur in 60% to 80% of patients with NF2, although they tend not to cause visual debilitation and rarely require surgery.¹⁴ Cutaneous lesions may also be encountered in NF2, but are not the classic neurofibromas seen in NF1, and likely represent small schwannomas of peripheral nerve origin.³

Pathophysiology

Both NF1 and NF2 are considered autosomal dominant genetic disorders with variable expression. NF1 results from a germline, loss-of-function mutation at the *NF1* gene locus on chromosome 17q11.2, resulting in alteration or elimination of the gene's primary protein product, neurofibromin.^{2,15} It is believed that neurofibromin nor-

mally serves to limit cell growth, and its absence or diminished expression results in increased cell growth.^{1,2} This in turn impacts the development of tissues derived from embryonic neuroectoderm, including melanocytes, neurons, nerve ganglia, Schwann cells, oligodendrocytes and astrocytes.¹⁶ More than 500 different mutations of the *NF1* gene have been identified, and presumably this is why so many different clinical manifestations may be encountered.¹

NF2 is the result of mutations in the NF2 tumor-suppressor gene on chromosome 22q12-2.^{3,13,14} The NF2 gene codes for a protein known as merlin (moesin-ezrin-radixin-like protein), which, much like neurofibromin, functions to regulate growth in certain tissues, particularly neural tissue like Schwann cells.^{13,14,17} In the absence of merlin, tumors subsequently develop in susceptible target organs, giving rise to the clinical presentation seen in NF2.¹³

Management

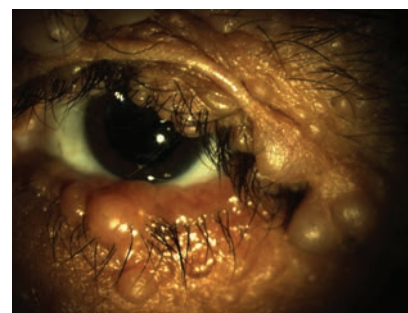
Management of NF1 and NF2 is primarily aimed at appropriate diagnosis and identification of all potential manifestations of the disease. Individuals suspected of having NF should undergo a thorough physical evaluation to include dermatological, orthopedic, cardiovascular, ophthalmic, auditory and neurological assessment. Some also advocate a routine brain MRI at the time of diagnosis, although this remains controversial.¹ Prenatal genetic counseling may be of value to individuals who are affected by, or are at risk for, the disease. Prenatal testing can also be performed for those at increased risk for NF via DNA analysis using fetal cells obtained by amniocentesis.¹

Treatment for NF is limited to addressing the individual manifestations and pathologies associated with the disease. In NF1, surgical intervention may be attempted for discrete cutaneous

or subcutaneous neurofibromas that are disfiguring or located in inconvenient locations (e.g., along the temple, precluding the use of spectacles); however, it may be impractical or impossible to successfully remove all cutaneous neurofibromas.¹ Treatment of plexiform neurofibromas is more challenging due to their intimate involvement with nerve tissue and tendency for recurrence at the site of removal.¹⁸ Surgical removal may be attempted for disfiguring lesions, but should be guided by MRI to ensure the best outcome. Radiation therapy of plexiform neurofibromas is contraindicated, as it has been shown to increase the risk of developing malignant peripheral nerve sheath tumors in some patients.¹⁹ Children with NF1 who develop optic pathway gliomas generally do not require treatment, but chemotherapy is the treatment of choice for tumors that show evidence of progression.^{8,20}

Management of skeletal manifestations in NF1 is primarily supportive, although corrective procedures may be undertaken. Bracing can be employed for long-bone bowing to prevent fractures, but surgical attempts to correct pseudoarthrosis are often unsatisfactory.¹¹ Likewise, bracing is frequently employed for NF1-affected children with milder forms of dystrophic scoliosis; more severe scoliosis may be addressed via surgical fusion or the insertion of growing rods, but the outcome of such interventions is highly variable.¹¹ Surgical correction may also be attempted for patients with sphenoid wing dysplasia, although techniques and outcomes vary widely.²¹⁻²³ Chest wall deformities such as pectus excavatum and pectus carinatum are primarily a cosmetic issue in most cases, and hence surgical intervention is optional and at the discretion of the patient.¹

NF2 presents a number of management dilemmas. The primary form of intervention involves microsurgical



Clinical presentation of ocular neurofibromatosis.

removal of symptomatic cranial and spinal tumors.¹⁴ Since hearing is the most impacted sense in NF2, removal of vestibular schwannomas is the most important consideration; however, timing, experience of the surgical team and the concurrent use of radiotherapy all impact the level of success.¹⁴ Poor surgical outcome can result in abrupt hearing loss, but auditory rehabilitation with cochlear or auditory brainstem implants may help preserve and enhance some auditory function.

Optic nerve meningiomas present a similarly challenging clinical scenario. Because of their anatomical location, complete surgical resection of these lesions has been associated with substantial neurological morbidity.¹³ Stereotactic radiosurgery—sometimes referred to as gamma knife or cyber knife treatment—has been used as an adjuvant or alternative to conventional excision.^{24,25} However, as is the case with NF1, the use of radiotherapy for tumor removal in NF2 can be of concern due to the potential for radiation-induced malignant transformation and adjacent tumor development.^{3,26}

Cutaneous lesions in NF2 are typically only addressed if they present a cosmetic concern or result in a functional impairment, e.g., when they occur on the hand or the foot.³ Surgical intervention for these tumors is identical to that employed for non-NF2 patients, and outcomes appear to be equally favorable.²⁷

Clinical Pearls

- NF1 is sometimes referred to as *von Recklinghausen disease*. Friedrich Daniel von Recklinghausen, a German pathologist, first documented the constellation of findings seen with neurofibromatosis in 1882.

- Due to the potential for intracranial mass lesions in NF1, developmental and/or cognitive impairment remains an ever-present concern. Children diagnosed with NF1 should be sent for neuropsychological assessments as early as possible. Learning issues in these individuals often include visuospatial deficits, visuomotor deficits and language disorders, as well as fine and gross motor coordination deficits.²⁸

- The off-label use of anti-VEGF drugs such as bevacizumab has been shown to help improve function and, in some cases, diminish tumor size in patients with NF2-related vestibular schwannomas.^{29,30} These medications, which are primarily indicated for the treatment of specific cancers, are given by intravenous infusion.

1. Jett K, Friedman JM. Clinical and genetic aspects of neurofibromatosis 1. *Genet Med*. 2010;12(1):1-11.

2. Williams VC, Lucas J, Babcock MA, et al. Neurofibromatosis type 1 revisited. *Pediatrics*. 2009;123(1):124-33.

3. Slattery WH. Neurofibromatosis type 2. *Otolaryngol Clin North Am*. 2015;48(3):443-60.

4. Antônio JR, Goloni-Bertollo EM, Tridico LA. Neurofibromatosis: chronological history and current issues. *An Bras Dermatol*. 2013;88(3):329-43.

5. López Aventura D, Gilaberte M, Pujol RM. Multiple café au lait macules and crowe sign. *Arch Dermatol*. 2011;147(6):735-40.

6. Maharaj A, Singh VR, Lalchan SA. Lisch and the importance of his nodules. *West Indian Med J*. 2014;63(7):799-802.

7. Rosser T, Packer RJ. Intracranial neoplasms in children with neurofibromatosis 1. *J Child Neurol*. 2002; 17(8):630-7; discussion 646-51.

8. Listernick R, Ferner RE, Liu GT, et al. Optic pathway gliomas in neurofibromatosis-1: controversies and recommendations. *Ann Neurol*. 2007;61(3):189-98.

9. Sylvester CL, Drohan LA, Sergott RC. Optic-nerve gliomas, chiasmal gliomas and neurofibromatosis type 1. *Curr Opin Ophthalmol*. 2006;17(1):7-11.

10. King A, Listernick R, Charrow J, et al. Optic pathway gliomas in neurofibromatosis type 1: the effect of presenting symptoms on outcome. *Am J Med Genet A*. 2003;122A(2):95-9.

11. Elefteriou F, Kolanczyk M, Schindeler A, et al. Skeletal abnormalities in neurofibromatosis type 1: approaches to therapeutic options. *Am J Med Genet A*. 2009;149A(10):2327-38.

12. Jacquemin C, Bosley TM, Svedberg H. Orbit deformities in craniofacial neurofibromatosis type 1. *AJNR Am J Neuroradiol*. 2003;24(8):1678-82.

13. Asthagiri AR, Parry DM, Butman JA, et al. Neurofibromatosis type 2. *Lancet*. 2009;373(9679):1974-86.

14. Evans DG. Neurofibromatosis type 2 (NF2): a clinical and molecular review. *Orphanet J Rare Dis*. 2009;4:16.

15. Viskochil D. Genetics of neurofibromatosis 1 and the NF1 gene. *J Child Neurol*. 2002;17(8):562-70; discussion 571-2, 646-51.

16. Zhu Y, Parada LF. The molecular and genetic basis of neurological tumours. *Nat Rev Cancer*. 2002;2(8):616-26.

17. Schulz A, Zoch A, Morrison H. A neuronal function of the tumor suppressor protein merlin. *Acta Neuropathol Commun*. 2014;2:82.

18. Serletis D, Parkin P, Bouffet E, et al. Massive plexiform neurofibromas in childhood: natural history and management issues. *J Neurosurg*. 2007;106(suppl 5):363-7.

19. Evans DG, Baser ME, McGaughran J, et al. Malignant peripheral nerve sheath tumours in neurofibromatosis 1. *J Med Genet*. 2002;39(5):311-4.

20. Dalla Via P, Opocher E, Pinello ML, et al. Visual outcome of a cohort of children with neurofibromatosis type 1 and optic pathway glioma followed by a pediatric neuro-oncology program. *Neuro Oncol*. 2007;9(4):430-7.

21. Lotfy M, Xu R, McGirt M, et al. Reconstruction of skull base defects in sphenoid wing dysplasia associated with neurofibromatosis I with titanium mesh. *Clin Neurol Neurosurg*. 2010;112(10):909-14.

22. Friedrich RE. Reconstruction of the sphenoid wing in a case of neurofibromatosis type 1 and complex unilateral orbital dysplasia with pulsating exophthalmos. *In Vivo*. 2011;25(2):287-90.

23. Niddam J, Bosc R, Suffee TM, et al. Treatment of sphenoid dysplasia with a titanium-reinforced porous polyethylene implant in orbitofrontal neurofibroma: report of three cases. *J Craniomaxillofac Surg*. 2014;42(8):1937-41.

24. Wentworth S, Pinn M, Bourland JD, et al. Clinical experience with radiation therapy in the management of neurofibromatosis associated central nervous system tumors. *Internat J Radiat Onc Biol Phys*. 2009;73(1):208-13.

25. Liu A, Kuhn EN, Lucas JT Jr, et al. Gamma Knife radiosurgery for meningiomas in patients with neurofibromatosis Type 2. *J Neurosurg*. 2015;122(3):536-42.

26. Evans DGR, Birch JM, Ramsden RT, et al. Malignant transformation and new primary tumours after therapeutic radiation for benign disease: substantial risks in certain tumour prone syndromes. *J Med Genet*. 2006; 43(4):289-94.

27. Bendon CL, Furniss D, Giele HP. Comparison of outcomes of peripheral nerve schwannoma excision in neurofibromatosis type 2 patients and non-neurofibromatosis type 2 patients: A case control study. *J Plast Reconstr Aesthet Surg*. 2015;68(9):1199-203.

28. Hyman SL, Shores A, North KN. The nature and frequency of cognitive deficits in children with neurofibromatosis type 1. *Neurology*. 2005;65(7):1037-44.

29. Alanin MC, Klausen C, Caye-Thomasen P, et al. The effect of bevacizumab on vestibular schwannoma tumour size and hearing in patients with neurofibromatosis type 2. *Eur Arch Otorhinolaryngol*. 2015;272(12):3627-33.

30. Sponghini AP, Platini F, Rondonotti D, et al. Bevacizumab treatment for vestibular schwannoma in a patient with neurofibromatosis type 2: hearing improvement and tumor shrinkage. *Tumori*. 2015;101(6):e167-70.

VERRUCA AND PAPILLOMA

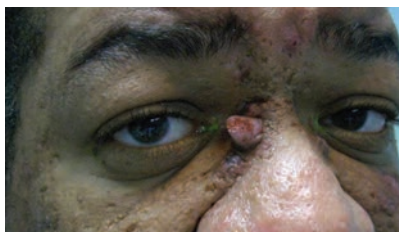Signs and Symptoms

Verruca vulgaris is defined as a small, multi-lobulated, firm-but-moveable

growth of the outer layers of the skin or mucus membranes.¹⁻⁸ Warts, as they are commonly known, come in varied shapes and sizes; *verruca vulgaris* (the common wart) is raised with a roughened surface commonly found on the hands and knees; *verruca plana* (flat warts) are small, smooth, flattened lesions that are tan or flesh-colored, occurring in large numbers and commonly found on the face, neck, hands, wrists and knees; *filiform*, or *digitate warts*, are finger-like warts most commonly encountered on the face, especially near the eyelids and lips.⁸

Human papillomavirus (HPV), a papovavirus, is the causative agent of all warts.¹⁻¹¹ Verruca are estimated to occur in approximately 7% of the population, with a peak incidence of occurrence in the mid-teens.⁷ At least 63 subtypes of the virus are known.¹⁻¹¹ The non-carcinogenic serotypes are tethered to particular locations. Cutaneous (common) verrucas occur on the face, body, tops of the hands and tops of feet. Plantar warts occur on the sole of the foot. Venereal warts occur on the genitals.¹⁻¹¹ The human papillomavirus virus is transmitted by direct contact, occurring from a wart on someone else or on oneself (autoinoculation).¹⁻⁴ Warts are not associated with pain, but are a cosmetic nuisance. Unless they sprout in a critical or visible location, they have no impact on function or cosmesis. They tend to occur in the young but can be found on individuals at any age, without a preponderance for gender.¹⁻⁷

The carcinogenic HPV strains are associated with lesions that evolve into malignancies of the cervix, vagina, vulva, penis, anal area and oropharynx.¹⁻⁴ A carcinogenic variant of the benign squamous papilloma with *verruca vulgaris* (warts of the mouth) is the conjunctival lesion known as ocular surface squamous neoplasia (OSSN).⁹⁻¹¹ HPV subtypes such as HPV-6, HPV-11 and HPV-16 increase the risk of



Cutaneous verrucas occur on the skin or mucous membrane, including face, body, tops of the hands and tops of feet.

cancerous conversion.^{1,10,11} The incidence of OSSN increases in individuals with extensive exposure to ultraviolet (UV) radiation, human immunodeficiency virus (HIV) and exposure to HPV.^{10,11} Africa has the highest rates of OSSN in the world.¹⁰

Most lesions occur at the nasal limbus within the interpalpebral fissure, as this region receives the greatest exposure to sunlight.⁹ The lesions appear as pink, soft, moveable, translucent, lobulated, gelatinous lesions projecting from the bulbar conjunctiva onto the surface of the cornea.^{10,11} They are painless and generally do not interrupt function.^{10,11}

Squamous cell papillomas are among the most common of benign eyelid lesions.¹²⁻¹⁸ The other frequent lesions include nevi, seborrheic keratoses, hidrocystomas, xanthelasma lesions and epidermal cysts.^{12,13} Like verruca, squamous cell papillomas are caused by HPV. They appear with no gender or racial bias, predominantly in patients older than 30 years.¹²⁻¹⁸ They are painless and only inhibit function when they arise in an area that permits it, adding weight to the superior eyelid, producing ptosis or becoming sufficiently large to obstruct vision. The lesions appear as soft, round, moveable, pedunculated lesions.¹²⁻¹⁴ They may be singular or multiple in configuration and can be smooth or have a cauliflower appearance.¹²⁻¹⁸ These lesions, sometimes referred to as skin tags, may also occur on the conjunctiva, in which case they are known as conjunctival papil-

loma.¹²⁻¹⁸ These, too, are classified by gross clinical appearance, as either pedunculated or sessile. Highly recurrent, they may return in the same position or in multiple positions, even creating symblepharon and lesions in the nasolacrimal drainage system.^{14,17,18}

Pathophysiology

Verruca vulgaris lesions represent benign epidermal proliferations of the outer layers of the epidermis.⁷ Though verruca represent a proliferative process, they do remain stable and are typically benign. The lesions are caused by HPV-invading epithelial cells, with consequent cell proliferation and nodule/plaque formation.⁷ They usually occur in wet and macerated skin areas of the body that touch rough surfaces.⁷ Abrasions in the epidermis are sites of entry for HPV, which moves into basal keratinocytes of the epithelium.⁷ Scratching, shaving or traumatizing the skin are all vectors for spreading HPV to other locations.⁷ Since a strong immune response is not created by the viral agent, the lesion is permitted a self-limited silent growth period for months or even years.⁷

The clinical presentations (size and appearance) of verruca vulgaris lesions vary according to the viral subtype that causes them and the anatomical site infected.⁷ Benign verruca vulgaris lesions include squamous papilloma with verruca vulgaris (warts of the tongue and palate), focal epithelial hyperplasia (warts of the buccal mucosa-Heck disease) and condyloma (clustered warts of the mouth or genitals). Verruca vulgaris is most commonly induced by HPV-2, HPV-4 or HPV-40.⁷

Squamous cell papillomas have pathophysiology similar to verruca: they are caused by direct contact with another wart containing HPV (HPV 6,11), and represent inflammatory hypertrophy of the outer layers of the skin (hence their name) with viral inclu-

sions.^{14,15} They are made up of multiple branching fronds emanating from a narrow pedunculated base.¹⁴ Individual fronds are surrounded by connective tissue, each having a central vascularized core inundated with inflammatory cells.¹⁴ The epithelium is acanthotic, nonkeratinized stratified squamous epithelium.¹⁴ Squamous cell papillomas grow slowly exophytically and may be self-limiting or continue to grow, but rarely transform into a malignant lesion.^{14,15} Conjunctival papilloma may be noninfectious, arising from UV radiation exposure.^{14,15} Although rare, inverted conjunctival papillomas (endophytic growth pattern) sometimes are referred to as mucoepidermoid papillomas because these lesions possess both a mucous component and an epidermoid component.¹⁴⁻¹⁶

Management

Verruca are usually slow-growing, self-limiting lesions. The key to observational management is accurate measurement via a detailed drawing and/or photodocumentation. Patients should be reexamined at regular intervals and counseled to immediately report changes in size, shape, color, elevation or growth pattern. Spontaneous resolution may take months to years or not occur at all, and spontaneous clearance rates are painfully low (23% at two months, 30% at three months, and 65% to 78% at two years). Since the lesions are contagious and capable of replicating, intervention may be suggested.⁴

If removal is warranted secondary to compromised function or poor cosmesis, patients must be advised that verruca are known to be recurrent and resistant to therapy.⁴ As a contagious disorder, verruca, when removed, can cause viral particles to be transmitted to other areas where additional warts may form as a consequence. Removal should be completed by a specialist skilled in dermatology, such as an ophthalmologist trained

in oculoplastics, or a dermatologist.¹⁹⁻²¹

Topical 10% zinc solutions applied TID can be tried with and without oral supportive zinc therapy (10mg/kg/day) for two months.¹⁹ Topical cantharidin has been used as a blistering agent for the removal of warts and molluscum since the 1950s.²⁰ Imiquimod (Aldara) is an immunomodulator that stimulates immune response through cytokine release, approved for the treatment of external genital warts.⁴ Not well absorbed through the skin, it is infrequently used in cutaneous warts. In an open-label, uncontrolled study, 5% Imiquimod cream applied on five successive days over 16 weeks yielded variable success with minimal recurrence.⁴ Mild transient local inflammation was the only side effect.⁴ Topical green tea catechins (Polyphenon E, MediGene) is a defined extract of catechins of the green tea leaves of the species *Camellia sinensis*. Containing tea polyphenols and flavonoids (i.e., antioxidants that inhibit the transcription of HPV viral proteins), it is typically applied to the affected area TID.⁴

Other therapies include cryotherapy, chemical cauterization (alkali water, silver nitrate pencil), curettage, electrodesiccation and laser removal.^{4,8,19-22}

Clinical Pearls

- While HPV lesions are benign, they are effectively contagious; if they are abraded, they can incite additional lesions to grow if the viral particles gain access to another location.

- All tumor lesions should be inspected for moveability (mobile is better than bound down), firmness (soft is better than hard), size (<6mm is better), shape (symmetry is good), color (uniformity and less dark is better) and elevation. Changes in any of these suggest fluctuation worthy of consultation with a specialist skilled in dermatology and complete removal and biopsy if necessary.

- Tumor lesions should be photodocumented and measured at regular six month intervals.

1. Miller DM, Brodell RT, Levine MR. The conjunctival wart: report of a case and review of treatment options. *Ophthalmic Surg.* 1994;25(8):545-8.
2. Word AP, Nezaifati KA, Cruz PD Jr. Treatment of warts with contact allergens. *Dermatitis.* 2015;26(1):32-7.
3. Verma SB. Eyebrow threading: a popular hair-removal procedure and its seldom-discussed complications. *Clin Exp Dermatol.* 2009;34(3):363-5.
4. Sinha S, Reihan V, Garg VK. Immunomodulators in warts: Unexplored or ineffective? *Indian J Dermatol.* 2015;60(2):118-29.
5. Kwok CS, Gibbs S, Bennett C, et al. Topical treatments for cutaneous warts. *Cochrane Database Syst Rev.* 2012;9:CD00178.
6. Garland SM, Molesworth EG, Machalek DA, et al. How to best measure the effectiveness of male human papillomavirus vaccine programmes? *Clin Microbiol Infect.* 2015;21(9):834-41.
7. Ural A, Arslan S, Ersoz S, et al. *Verruca vulgaris* of the tongue: a case report with a literature review. *Bosn J Basic Med Sci.* 2014;14(3):136-8.
8. Sekhar Namburi UR, Omprakash, Babu G. A review on management of warts in Ayurveda. *Ayu.* 2011;32(1):100-2. 8520.85739.
9. Dunne EF, Markowitz LE, Taylor LD, et al. Human papilloma virions in the laboratory. *J Clin Virol.* 2014;61(2):196-8.
10. Gichuhi S, Ohnuma S, Sagoo MS, et al. Pathophysiology of ocular surface squamous neoplasia. *Exp Eye Res.* 2014;129:172-82.
11. Woods M, Chow S, Heng B, et al. Detecting human papillomavirus in ocular surface diseases. *Invest Ophthalmol Vis Sci.* 2013;54(13):8069-78.
12. Gundogan FC, Yolcu U, Ta A, et al. Eyelid tumors: clinical data from an eye center in Ankara, Turkey. *Asian Pac J Cancer Prev.* 2015;16(10):4265-9.
13. Asproudis I, Sotiropoulos G, Gartzios C, et al. Eyelid Tumors at the University Eye Clinic of Ioannina, Greece: A 30-year Retrospective Study. *Middle East Afr J Ophthalmol.* 2015;22(2):230-2.
14. Duong H, Burkat CN, Goel S. *Conjunctival Papilloma*. Available at: <http://eyewiki.aaopt.org/> (last accessed January 18, 2016).
15. Minchiotti S, Masucci L, Serapiao Dos Santos M, et al. Conjunctival papilloma and human papillomavirus: identification of HPV types by PCR. *Eur J Ophthalmol.* 2006;16(3):473-7.
16. Kalantzis G, Papaconstantinou D, Georgalas I, et al. Different types of conjunctival papilloma presenting in the same eye. *Orbit.* 2010;29(5):266-8.
17. Lauer SA. Recurrent conjunctival papilloma causing nasolacrimal duct obstruction. *Am J Ophthalmol.* 1990;110(5):580-1.
18. Migliori ME, Putterman AM. Recurrent conjunctival papilloma causing nasolacrimal duct obstruction. *Am J Ophthalmol.* 1990;110(1):17-22.
19. Gupta M, Mahajan VK, Mehta KS, et al. Zinc therapy in dermatology: a review. *Dermatol Res Pract.* 2014;2014(7):709152.
20. Torbeck R, Pan M, DeMolle E, et al. Cantharidin: a comprehensive review of the clinical literature. *Dermatol Online J.* 2014;20(6). pii:13030/qt45r512w0.
21. Kim M, Jung HY, Park HJ. Topical pdt in the treatment of benign skin diseases: principles and new applications. *Int J Mol Sci.* 2015;16(10):23259-78.
22. Yazar S, Başaran E. Efficacy of silver nitrate pencils in the treatment of common warts. *J Dermatol.* 1994;21(5):329-33.


TRICHIASIS

Signs and Symptoms

Trichiasis is defined as the misdirection of one or more eyelashes toward the ocular surface.¹⁻³ By definition, *minor trichiasis* involves fewer than five cilia, while *major trichiasis* affects five or more.^{1,2} Worldwide, the most common cause of trichiasis is trachoma, a cicatrizing ocular infection instigated by the obligate intracellular parasite, *Chlamydia trachomatis*. In highly developed nations such as the United States, however, trachoma is exceedingly rare, and trichiasis is typically associated with blepharitis, inflammatory conjunctivitis, eyelid trauma or neoplasms affecting the eyelid margin.¹⁻⁵ The condition may occur unilaterally or bilaterally depending upon the etiology, and can affect the upper or lower eyelid with equivalent frequency. There is no known racial or gender predilection, but the frequency of trichiasis does appear to increase with age.^{1,2}

Patients with trichiasis are symptomatic in the vast majority of cases, commonly reporting foreign body sensation in the affected eye. Other subjective complaints may include dryness, burning, pain, photophobia, redness, mucus discharge and epiphora.¹ In extreme cases, patients may present with blepharospasm due to unrelenting ocular discomfort.¹ Biomicroscopy of patients with trichiasis typically reveals the errant lash or lashes, although some cases may prove more difficult to diagnose, particularly when the follicles project from the superior lid and are associated with dermatochalasis or epicanthal folds. In such instances, it may be helpful to look for secondary ocular signs including focal or diffuse conjunctival hyperemia and localized disruption of the corneal epithelium as noted by sodium fluorescein staining.²

With persistent or severe trichiasis comes increased risk of potentially



Besivance[®]

besifloxacin ophthalmic
suspension, 0.6%

When treating your patients with bacterial conjunctivitis –

Unleash power against pathogens of concern.

- The first and only topical ophthalmic chlorofluoroquinolone¹
- Provides long-lasting tear concentrations²
- Proven efficacy against a broad spectrum of pathogens including^{1,3}:
 - *S. aureus*, *S. epidermidis*, *S. pneumoniae*, and *H. influenzae*
 - *Pseudomonas aeruginosa*

Indication

BESIVANCE[®] (besifloxacin ophthalmic suspension) 0.6% is a quinolone antimicrobial indicated for the treatment of bacterial conjunctivitis caused by susceptible isolates of the following bacteria: *Aerococcus viridans*^{*}, CDC coryneform group G, *Corynebacterium pseudodiphtheriticum*^{*}, *Corynebacterium striatum*^{*}, *Haemophilus influenzae*, *Moraxella catarrhalis*^{*}, *Moraxella lacunata*^{*}, *Pseudomonas aeruginosa*^{*}, *Staphylococcus aureus*, *Staphylococcus epidermidis*, *Staphylococcus hominis*^{*}, *Staphylococcus lugdunensis*^{*}, *Staphylococcus warneri*^{*}, *Streptococcus mitis* group, *Streptococcus oralis*, *Streptococcus pneumoniae*, *Streptococcus salivarius*^{*}

^{*}Efficacy for this organism was studied in fewer than 10 infections.

Important Safety Information about BESIVANCE[®]

- BESIVANCE[®] is for topical ophthalmic use only, and should not be injected subconjunctivally, nor should it be introduced directly into the anterior chamber of the eye.
- As with other anti-infectives, prolonged use of BESIVANCE[®] may result in overgrowth of non-susceptible organisms, including fungi. If super-infection occurs, discontinue use and institute alternative therapy.
- Patients should not wear contact lenses if they have signs or symptoms of bacterial conjunctivitis or during the course of therapy with BESIVANCE[®].
- The most common adverse event reported in 2% of patients treated with BESIVANCE[®] was conjunctival redness. Other adverse events reported in patients receiving BESIVANCE[®] occurring in approximately 1-2% of patients included: blurred vision, eye pain, eye irritation, eye pruritus and headache.
- BESIVANCE[®] is not intended to be administered systemically. Quinolones administered systemically have been associated with hypersensitivity reactions, even following a single dose. Patients should be advised to discontinue use immediately and contact their physician at the first sign of a rash or allergic reaction.
- Safety and effectiveness in infants below one year of age have not been established.

Please see brief summary of Prescribing Information on adjacent page.

To learn more about BESIVANCE[®] call your Bausch + Lomb sales representative today.

References: 1. BESIVANCE[®] Prescribing Information, September 2012. 2. At 12 hours, the concentration of besifloxacin in tears was >10 µg/mL. Proksch JW, Granvil CP, Siou-Mermet R, Comstock TL, Paterno MR, Ward KW. Ocular pharmacokinetics of besifloxacin following topical administration to rabbits, monkeys, and humans. *J Ocul Pharm Ther.* 2009;25(4):335-344. 3. Comstock TL, Paterno MR, Usner DW, Pichichero ME. Efficacy and safety of besifloxacin ophthalmic suspension 0.6% in children and adolescents with bacterial conjunctivitis: a post hoc, subgroup analysis of three randomized, double-masked, parallel-group, multicenter clinical trials. *Paediatr Drugs.* 2010;12(2):105-112.

BAUSCH + LOMB

Besivance is a trademark of Bausch & Lomb Incorporated or its affiliates.
© 2015 Bausch & Lomb Incorporated. All rights reserved. US/BES/15/0010



Besivance[®]
besifloxacin ophthalmic
suspension, 0.6%

BRIEF SUMMARY OF PRESCRIBING INFORMATION

This Brief Summary does not include all the information needed to use Besivance safely and effectively. See full prescribing information for Besivance.

Besivance (besifloxacin ophthalmic suspension) 0.6%

Sterile topical ophthalmic drops

Initial U.S. Approval: 2009

1 INDICATIONS AND USAGE

Besivance® (besifloxacin ophthalmic suspension) 0.6%, is indicated for the treatment of bacterial conjunctivitis caused by susceptible isolates of the following bacteria:

*Aerococcus viridans**, CDC coryneform group G, *Corynebacterium pseudodiphtheriticum**, *Corynebacterium striatum**, *Haemophilus influenzae*, *Moraxella catarrhalis**, *Moraxella lacunata**, *Pseudomonas aeruginosa**, *Staphylococcus aureus*, *Staphylococcus epidermidis*, *Staphylococcus hominis**, *Staphylococcus lugdunensis**, *Staphylococcus warneri**, *Streptococcus mitis* group, *Streptococcus oralis*, *Streptococcus pneumoniae*, *Streptococcus salivarius**

*Efficacy for this organism was studied in fewer than 10 infections.

2 DOSAGE AND ADMINISTRATION

Invert closed bottle and shake once before use.

Instill one drop in the affected eye(s) 3 times a day, four to twelve hours apart for 7 days.

4 CONTRAINDICATIONS

None

5 WARNINGS AND PRECAUTIONS

5.1 Topical Ophthalmic Use Only NOT FOR INJECTION INTO THE EYE.

Besivance is for topical ophthalmic use only, and should not be injected subconjunctivally, nor should it be introduced directly into the anterior chamber of the eye.

5.2 Growth of Resistant Organisms with Prolonged Use As with other anti-infectives, prolonged use of Besivance (besifloxacin ophthalmic suspension) 0.6% may result in overgrowth of non-susceptible organisms, including fungi. If super-infection occurs, discontinue use and institute alternative therapy. Whenever clinical judgment dictates, the patient should be examined with the aid of magnification, such as slit-lamp biomicroscopy, and, where appropriate, fluorescein staining.

5.3 Avoidance of Contact Lenses Patients should not wear contact lenses if they have signs or symptoms of bacterial conjunctivitis or during the course of therapy with Besivance.

6 ADVERSE REACTIONS

Because clinical trials are conducted under widely varying conditions, adverse reaction rates observed in one clinical trial of a drug cannot be directly compared with the rates in the clinical trials of the same or another drug and may not reflect the rates observed in practice.

The data described below reflect exposure to Besivance in approximately 1,000 patients between 1 and 98 years old with clinical signs and symptoms of bacterial conjunctivitis.

The most frequently reported ocular adverse reaction was conjunctival redness, reported in approximately 2% of patients.

Other adverse reactions reported in patients receiving Besivance occurring in approximately 1-2% of patients included: blurred vision, eye pain, eye irritation, eye pruritus and headache.

8 USE IN SPECIFIC POPULATIONS

8.1 Pregnancy Pregnancy Category C. Oral doses of besifloxacin up to

1000 mg/kg/day were not associated with visceral or skeletal malformations in rat pups in a study of embryo-fetal development, although this dose was associated with maternal toxicity (reduced body weight gain and food consumption) and maternal mortality. Increased post-implantation loss, decreased fetal body weights, and decreased fetal ossification were also observed. At this dose, the mean C_{max} in the rat dams was approximately 20 mcg/mL, >45,000 times the mean plasma concentrations measured in humans.

The No Observed Adverse Effect Level (NOEL) for this embryo-fetal development study was 100 mg/kg/day (C_{max} 5 mcg/mL, >11,000 times the mean plasma concentrations measured in humans).

In a prenatal and postnatal development study in rats, the NOELs for both fetal and maternal toxicity were also 100 mg/kg/day. At 1000 mg/kg/day, the pups weighed significantly less than controls and had a reduced neonatal survival rate. Attainment of developmental landmarks and sexual maturation were delayed, although surviving pups from this dose group that were reared to maturity did not demonstrate deficits in behavior, including activity, learning and memory, and their reproductive capacity appeared normal. Since there are no adequate and well-controlled studies in pregnant women, Besivance should be used during pregnancy only if the potential benefit justifies the potential risk to the fetus.

8.3 Nursing Mothers Besifloxacin has not been measured in human milk, although it can be presumed to be excreted in human milk. Caution should be exercised when Besivance is administered to a nursing mother.

8.4 Pediatric Use The safety and effectiveness of Besivance® in infants below one year of age have not been established. The efficacy of Besivance in treating bacterial conjunctivitis in pediatric patients one year or older has been demonstrated in controlled clinical trials [see CLINICAL STUDIES (14)].

There is no evidence that the ophthalmic administration of quinolones has any effect on weight bearing joints, even though systemic administration of some quinolones has been shown to cause arthropathy in immature animals.

8.5 Geriatric Use No overall differences in safety and effectiveness have been observed between elderly and younger patients.

12 CLINICAL PHARMACOLOGY

12.1 Mechanism of Action Besifloxacin is a fluoroquinolone antibacterial [see CLINICAL PHARMACOLOGY (12.4)].

12.3 Pharmacokinetics Plasma concentrations of besifloxacin were measured in adult patients with suspected bacterial conjunctivitis who received Besivance bilaterally three

times a day (16 doses total). Following the first and last dose, the maximum plasma besifloxacin concentration in each patient was less than 1.3 ng/mL. The mean besifloxacin C_{max} was 0.37 ng/mL on day 1 and 0.43 ng/mL on day 6. The average elimination half-life of besifloxacin in plasma following multiple dosing was estimated to be 7 hours.

12. Microbiology

Besifloxacin is an 8-chloro fluoroquinolone with a N-1 cyclopropyl group. The compound has activity against Gram-positive and Gram-negative bacteria due to the inhibition of both bacterial DNA gyrase and topoisomerase IV. DNA gyrase is an essential enzyme required for replication, transcription and repair of bacterial DNA. Topoisomerase IV is an essential enzyme required for partitioning of the chromosomal DNA during bacterial cell division. Besifloxacin is bactericidal with minimum bactericidal concentrations (MBCs) generally within one dilution of the minimum inhibitory concentrations (MICs).

The mechanism of action of fluoroquinolones, including besifloxacin, is different from that of aminoglycoside, macrolide, and β -lactam antibiotics. Therefore, besifloxacin may be active against pathogens that are resistant to these antibiotics and these antibiotics may be active against pathogens that are resistant to besifloxacin. *In vitro* studies demonstrated cross-resistance between besifloxacin and some fluoroquinolones.

In vitro resistance to besifloxacin develops via multiple-step mutations and occurs at a general frequency of $< 3.3 \times 10^{-10}$ for *Staphylococcus aureus* and $< 7 \times 10^{-10}$ for *Streptococcus pneumoniae*.

Besifloxacin has been shown to be active against most isolates of the following bacteria both *in vitro* and in conjunctival infections treated in clinical trials as described in the INDICATIONS AND USAGE section:

*Aerococcus viridans**, CDC coryneform group G, *Corynebacterium pseudodiphtheriticum**, *C. striatum**, *Haemophilus influenzae*, *Moraxella catarrhalis**, *M. lacunata**, *Pseudomonas aeruginosa**, *Staphylococcus aureus*, *S. epidermidis*, *S. hominis**, *S. lugdunensis**, *S. warneri**, *Streptococcus mitis* group, *S. oralis*, *S. pneumoniae*, *S. salivarius**

*Efficacy for this organism was studied in fewer than 10 infections.

13 NONCLINICAL TOXICOLOGY

13.1 Carcinogenesis, Mutagenesis, Impairment of Fertility Long-term studies in animals to determine the carcinogenic potential of besifloxacin have not been performed. No *in vitro* mutagenic activity of besifloxacin was observed in an Ames test (up to 3.33 mcg/plate) on bacterial tester strains *Salmonella typhimurium* TA98, TA100, TA1535, TA1537 and *Escherichia coli* WP2uvrA. However, it was mutagenic in *S. typhimurium* strain TA102 and *E. coli* strain WP2(pKM101). Positive responses in these strains have been observed with other quinolones and are likely related to topoisomerase inhibition.

Besifloxacin induced chromosomal aberrations in CHO cells *in vitro* and it was positive in an *in vivo* mouse micronucleus assay at oral doses $\times 1500$ mg/kg. Besifloxacin did not induce unscheduled DNA synthesis in hepatocytes cultured from rats given the test compound up to 2,000 mg/kg by the oral route. In a fertility and early embryonic development study in rats, besifloxacin did not impair the fertility of male or female rats at oral doses of up to 500 mg/kg/day. This is over 10,000 times higher than the recommended total daily human ophthalmic dose.

14 CLINICAL STUDIES

In a randomized, double-masked, vehicle controlled, multicenter clinical trial, in which patients 1-98 years of age were dosed 3 times a day for 5 days, Besivance was superior to its vehicle in patients with bacterial conjunctivitis. Clinical resolution was achieved in 45% (90/198) for the Besivance treated group versus 33% (63/191) for the vehicle treated group (difference 12%, 95% CI 3% - 22%). Microbiological outcomes demonstrated a statistically significant eradication rate for causative pathogens of 91% (181/198) for the Besivance treated group versus 60% (114/191) for the vehicle treated group (difference 31%, 95% CI 23% - 40%). Microbiologic eradication does not always correlate with clinical outcome in anti-infective trials.

17 PATIENT COUNSELING INFORMATION

Patients should be advised to avoid contaminating the applicator tip with material from the eye, fingers or other source.

Although Besivance is not intended to be administered systemically, quinolones administered systemically have been associated with hypersensitivity reactions, even following a single dose. Patients should be advised to discontinue use immediately and contact their physician at the first sign of a rash or allergic reaction.

Patients should be told that although it is common to feel better early in the course of the therapy, the medication should be taken exactly as directed. Skipping doses or not completing the full course of therapy may (1) decrease the effectiveness of the immediate treatment and (2) increase the likelihood that bacteria will develop resistance and will not be treatable by Besivance or other antibacterial drugs in the future.

Patients should be advised not to wear contact lenses if they have signs or symptoms of bacterial conjunctivitis or during the course of therapy with Besivance.

Patients should be advised to thoroughly wash hands prior to using Besivance.

Patients should be instructed to invert closed bottle (upside down) and shake once before each use. Remove cap with bottle still in the inverted position. Tilt head back and with bottle inverted, gently squeeze bottle to instill one drop into the affected eye(s).

Manufactured by: Bausch & Lomb Incorporated

Tampa, Florida 33637

Besivance® is a registered trademark of Bausch & Lomb Incorporated.

©Bausch & Lomb Incorporated

U.S. Patent Nos. 6,685,958; 6,699,492; 5,447,926

†DuraSite is a trademark of InSite Vision Incorporated

US/BES/15/0019

Based on 9142605(flat)-9142705(folded)

sight-threatening complications, including corneal ulceration, infection, vascularization and scarring.^{2,3,5-7}

Pathophysiology

Trichiasis is an umbrella term for disorders characterized by contact between the eyelashes and the globe. The literature describes a number of related conditions that present with lash/globe contact, including distichiasis and metaplastic or aberrant lashes.⁸ However, trichiasis should not be considered synonymous with *entropion*, which refers to a disorder of eyelid malpositioning in which all or part of the lid margin rotates inward against the ocular surface. When this occurs, secondary trichiasis inherently results.^{1-3,9} Trichiasis can ensue independently, with the lid margin maintaining a normal orientation to the globe.

In healthy patients, eyelash follicles emanate from the distal aspect of the anterior lamella, curving out and away from the ocular surface. Trichiasis occurs when one or more cilia deviate from this pattern and instead turn inward toward the ocular surface. Lid inflammation (and the pathological changes that follow) has been heralded as the most common etiology of this transformation.^{1-4,6} Disorders such as chronic blepharitis have been implicated in trichiasis, but more severe inflammatory conditions such as Stevens-Johnson syndrome, ocular cicatricial pemphigoid, chemical and mechanical trauma, leprosy, trachoma and herpes zoster ophthalmicus have been associated as well.¹⁻³ Malignancies and other dermatological conditions of the eyelid can also potentially induce trichiasis.^{1,4}

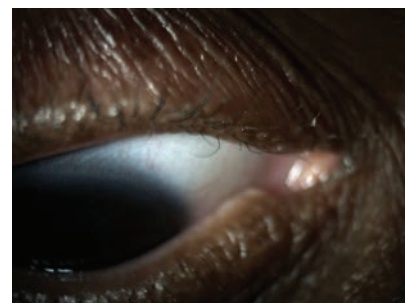While little has been written regarding the actual morphological changes associated with this condition, researchers in 1998 evaluated 116 patients with a provisional diagnosis of trichiasis in order to better characterize and classify the various presentations.⁸ They

found that a majority of their subjects (69%) displayed metaplastic conjunctivalization of the meibomian gland orifices as well as anterior displacement of the mucocutaneous junction of the lid. These changes were verified using scanning electron microscopy. The authors described this condition as *lid border entropion*, but distinguished it from involutional entropion in that it was nearly clinically indiscernible by gross evaluation; a constant, rather than intermittent finding; and not invoked by forced closure of the eyelids.⁸ In 15% of their subjects, trichiasis was attributed to focal notches in the lid margin as a result of prior surgery (tarsorrhaphy or tumor excision). These patients displayed a normal lash line except in the notched area, where distortion of the hair follicles resulted in misdirected lashes.⁸ Only about 6% of the subjects in this study presented with misdirected lashes and an entirely normal lid margin configuration; another 6% were found not to have any actual trichiasis, despite being symptomatic and having been previously diagnosed by a clinician.⁸

Hence, based on this study, it seems that the pathophysiology of trichiasis commonly involves changes to the tissue of the supporting lid, not to the lash itself.

Management

The primary goal in managing trichiasis is amelioration or elimination of lash/globe contact, thereby improving patient comfort and deterring pathological changes to the ocular surface. Conservative, nonsurgical interventions may be appropriate for those with minor trichiasis as a temporary measure in individuals awaiting surgery, or for those who refuse to or cannot undergo surgical intervention. The most common options include ocular lubricants, bandage contact lenses and mechanical epilation with forceps.^{1,2} Epilation is quick, easy to perform and quite effec-



Trichiasis may occur unilaterally or bilaterally depending upon the etiology, and can affect the upper or lower eyelid (in this case, upper) with equivalent frequency.

tive, often providing instantaneous relief of symptoms. Unfortunately, follicles typically regrow in four to six weeks, resulting in recurrence of the condition and subjective discomfort.^{1,2,10} Additionally, if the lash breaks low along the follicle during epilation rather than at the root, the resulting sharp stub may be even more irritating to the patient.⁶ Hence, conservative measures need to be repeated and frequently monitored; they are rarely viable for long-term management.¹¹

A variety of surgical modalities and techniques for trichiasis have been described.^{10,12-21} Electrolysis—employing the use of electrical current along a fine needle to destroy the hair follicle—has been used to treat trichiasis since before the turn of the last century.¹² This procedure is best employed in minor or isolated trichiasis, since the removal of multiple eyelashes may induce scarring and leave the globe unprotected. Electrolysis also has reported recurrence rates of approximately 50%.¹⁰

A more effective and generally safer technique is radiofrequency ablation. Like electrolysis, it is rapid and relatively inexpensive, with a success rate of up to 65% with a single treatment.^{14,15} Adjunctive use of topical mitomycin C appears to significantly improve the success rate of radiofrequency ablation.¹⁴ Complications are usually minor,

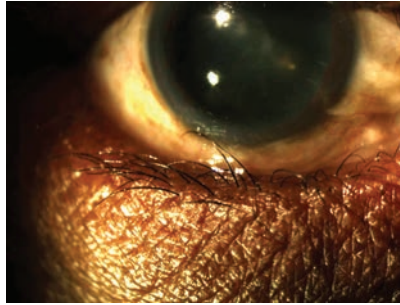
including short-lived edema and/or hematoma of the treated lids.¹

Laser ablation is comparable to radiofrequency, and may be performed with a variety of platforms, including argon, neodymium yttrium-aluminium-garnet (Nd:YAG), diode and ruby lasers.¹⁶⁻¹⁹ Advantages of laser treatment include less thinning of the tarsus, less damage to the pilosebaceous units surrounding the follicle and less inflammation overall. Disadvantages include procedure time and cost of the equipment.¹⁶ Cryotherapy is sometimes used for treating large, confluent areas of trichiasis, but it carries significant risk of complications, such as lid depigmentation, lid notching and xerosis.²⁰ Surgically splitting the eyelid at the gray line and treating the anterior lid lamella with selective cryotherapy may diminish these potential complications.²⁰

Finally, incisional surgery may be required for diffuse trichiasis, or when less invasive methods fail. Eyelash trephination involves the use of a hollow, small-gauge tube to effectively bore out the lash follicle and bulb under local anesthesia.¹⁰ The concurrent use of electrocautery and trephination demonstrated a success rate of 89% in one recent, small study.²¹ More extensive or recalcitrant trichiasis often requires specialized and intricate surgical procedures, including partial excision of the anterior lamella, anterior lamella repositioning, or eyelid splitting with mucocutaneous or oral mucosal graft.^{1,22} These procedures are typically only performed by highly skilled and experienced ophthalmic surgeons.

Clinical Pearls

- *Distichiasis* represents a congenital disorder in which an additional row of lashes arises from the meibomian gland orifices.
- *Metaplastic lashes*, also known as *aberrant lashes*, are identical in presentation to distichiasis, but represent an



Trichiasis present in lower eyelid margin.

acquired rather than a congenital dysfunction. Metaplastic lashes are most commonly seen in trachoma or in late-stage Stevens-Johnson syndrome.^{23,24}

- In both distichiasis and metaplastic lashes, the meibomian glands assume the hair-bearing state of their progenitor pilosebaceous unit, and develop a lash follicle where one should not be present.⁸
- Trichiasis (including distichiasis and metaplastic lashes) must be differentiated from entropion, which often results from horizontal lid laxity. The clinician should also look carefully for areas of symblepharon and fornix scars.¹
- Detecting trichiasis does not pose a great diagnostic challenge in most cases, but thorough assessment is critical in order to identify related conditions that may alter the management strategy.
- Careful examination of the lids should be performed to identify any potential malignancies, especially basal cell carcinoma.
- Application of lissamine green can help identify Marx's line at the mucocutaneous junction. Anterior displacement of this line such that it is coincident with or anterior to the meibomian gland orifices is indicative of lid border ectropion (a known progenitor of trichiasis).⁸
- It is not uncommon to see hair follicles growing from the lacrimal caruncle at the medial canthus. For the most part, this is a normal physiological phenomenon and does not warrant intervention.

1. Ferreira IS, Bernardes TF, Bonfioli AA. Trichiasis. *Semin Ophthalmol.* 2010;25(3):66-71.
2. Kirkwood BJ, Kirkwood RA. Trichiasis: characteristics and management options. *Insight.* 2011;36(2):5-9.
3. Choo PH. Distichiasis, trichiasis, and entropion: advances in management. *Int Ophthalmol Clin.* 2002;42(2):75-87.
4. Rajan N, Varma D, Chapman F, et al. Painful eye caused by basal cell carcinoma of the eyelid: tumour enlargement resulting in trichiasis. *Acta Derm Venereol.* 2008;88(1):66.
5. Shiu M, McNab AA. Cicatricial entropion and trichiasis in an urban Australian population. *Clin Experiment Ophthalmol.* 2005;33(6):582-5.
6. Rajak SN, Collin JR, Burton MJ. Trachomatous trichiasis and its management in endemic countries. *Surv Ophthalmol.* 2012;57(2):105-35.
7. Burton MJ, Bowman RJ, Faal H, et al. The long-term natural history of trachomatous trichiasis in the Gambia. *Invest Ophthalmol Vis Sci.* 2006;47(3):847-52.
8. Barber K, Dabbs T. Morphological observations on patients with presumed trichiasis. *Br J Ophthalmol.* 1988;72(1):17-22.
9. Piskiniene R. Eyelid malposition: lower lid entropion and ectropion. *Medicina (Kaunas).* 2006;42(11):881-4.
10. McCracken MS, Kikkawa DO, Vasani SN. Treatment of trichiasis and distichiasis by eyelash trephination. *Ophthal Plast Reconstr Surg.* 2006;22(5):349-51.
11. Khandwala M, Dey S, Hussain M, et al. Time-consuming eyelashes: an audit of trichiasis management. *Clinical Audit.* 2010;2:83-7.
12. Benson A. On the treatment of partial trichiasis by electrolysis. *Br Med J.* 1882;2(1146):1203-4.
13. Sakarya Y, Sakarya R, Yildirim A. Electrolysis treatment of trichiasis by using ultra-fine needle. *Eur J Ophthalmol.* 2010;20(4):664-8.
14. Kim GN, Yoo WS, Kim SJ, et al. The effect of 0.02% mitomycin C injection into the hair follicle with radiofrequency ablation in trichiasis patients. *Korean J Ophthalmol.* 2014;28(1):12-8.
15. Kormann RB, Moreira H. [Treatment of trichiasis with high-frequency radio wave electrocautery]. *Arq Bras Oftalmol.* 2007;70(2):276-80.
16. Salour H, Rafati N, Falahi MR, et al. A comparison of argon laser and radiofrequency in trichiasis treatment. *Ophthal Plast Reconstr Surg.* 2011;27(5):313-6.
17. Al-Bdour MD, Al-Till MI. Argon laser: a modality of treatment for trichiasis. *Int J Biomed Sci.* 2007;3(1):56-9.
18. Pham RT, Biesman BS, Silkiss RZ. Treatment of trichiasis using an 810-nm diode laser: an efficacy study. *Ophthal Plast Reconstr Surg.* 2006;22(6):445-7.
19. Moore J, De Silva SR, O'Hare K, et al. Ruby laser for the treatment of trichiasis. *Lasers Med Sci.* 2009;24(2):137-9.
20. Khafagy A, Mostafa MM, Fooshan F. Management of trichiasis with lid margin split and cryotherapy. *Clin Ophthalmol.* 2012;6:1815-7.
21. Han JH, Doh SH. Treatment for trichiasis through a combination of eyelash trephination and electrocautery. *Acta Ophthalmol.* 2012;90(3):e211-3.
22. Fu Y, Liu J, Tseng SC. Oral mucosal graft to correct lid margin pathologic features in cicatricial ocular surface diseases. *Am J Ophthalmol.* 2011;152(4):600-608.e1.
23. Rajak SN, Habtamu E, Weiss HA, et al. The outcome of trachomatous trichiasis surgery in Ethiopia: risk factors for recurrence. *PLoS Negl Trop Dis.* 2013;7(8):e2392.
24. Sharma N, Thenarasun SA, Kaur M, et al. Adjuvant role of amniotic membrane transplantation in acute ocular Stevens-Johnson Syndrome: A randomized control trial. *Ophthalmology.* 2016;123(3):484-91.

UNCOVER

A POTENTIAL SYSTEMIC
CAUSE OF DRY EYE
BEFORE IT TAKES HOLD

Sjö®

Diagnostic test for early detection of Sjögren's syndrome in patients with dry eye

For more information about the Sjö® Diagnostic Test, please call or email Bausch + Lomb Support Services at 855-696-4269 or support@bldiagnostics.com.

BAUSCH + LOMB

Sjö is a trademark of Valeant Pharmaceuticals International, Inc. or its affiliates.
© Bausch & Lomb Incorporated US/SJO/15/0069

CONJUNCTIVOCHALASIS

Signs and Symptoms

Conjunctivochalasis (CCh) represents an ocular surface condition in which there is atypical redundancy and laxity of the bulbar conjunctiva, without the presence of edema.¹⁻⁴ It is most commonly seen with aging, and may present with a wide range of symptoms that are usually ascribed to dry eye disease. These may include irritation or foreign body sensation, burning, dryness, itching, intermittent tearing, epiphora and contact lens intolerance.^{1,2} Often more prominent in the morning upon awakening, symptoms are exacerbated by rapid or vigorous blinking.^{3,4} Visual discomfort may also be noted and is typically more bothersome in downgaze, such as when the patient is reading.^{3,4} Additionally, patients are often cosmetically symptomatic, as blood vessels in the redundant conjunctiva crowd together to create a “bloodshot” or hyperemic appearance. CCh is most commonly a bilateral condition, although symptoms may be more pronounced in one eye than the other.⁴

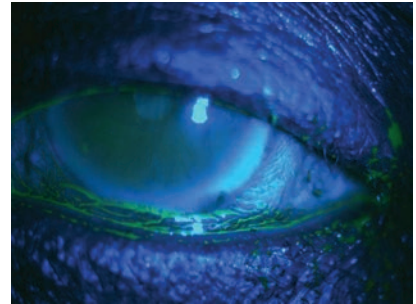Biomicroscopy in patients with CCh reveals pleated folds in the conjunctival tissue, sometimes referred to as *lid-parallel conjunctival folds* (LIPCOF).⁵ These are most evident inferiorly, just above the lower lid margin; they may be seen more readily when digital pressure is applied to the lower lid, or when the patient’s gaze is directed downward.² LIPCOF are typically graded by the scale first proposed by Höh and associates in 1995 (*grade 0*: no persistent folds; *grade 1*: single, small fold; *grade 2*: more than two folds and not higher than the tear meniscus; *grade 3*: multiple folds and higher than the tear meniscus).⁵ CCh less commonly affects the superior bulbar conjunctiva, where it can give rise to a condition resembling superior limbic keratoconjunctivitis (SLK) of Theodore.⁶ Additional signs that have been associated with CCh include swollen lacrimal

puncta³ and subconjunctival hemorrhage.^{1,4,7}

Specific testing can help to identify CCh and, more importantly, differentiate it from aqueous-deficient dry eye (ADDE). In CCh, vital dyes such as lissamine green or sodium fluorescein may be seen to collect between the redundant conjunctival folds, greatly enhancing their visibility. In these areas, the tear meniscus often appears to be diminished or absent, despite being evident along the junction between the lower lid and cornea.⁸ Fluorescein tear break-up time (FTBUT) is typically normal in mild and moderate cases, assuming there is no concurrent pathology of the cornea. A diminished FTBUT, which is considered diagnostic in cases of ADDE, is usually only encountered in the most severe cases of CCh (i.e., grade 3).⁴ Similarly, tear osmolarity, which is elevated in ADDE, remains normal in all but the most severe cases of CCh.⁹ Schirmer test scores (and, by association, phenol red thread test scores) are also characteristically normal in cases of CCh, despite the fact that the tear meniscus is displaced.⁴ Conversely, Schirmer scores are inherently diminished in cases of ADDE.

Pathophysiology

At least nine different factors contributing to the development of conjunctival folds in CCh were proposed between 1921 and 2000; these include eye movement, lid relaxation, lid pressure, chronic conjunctivitis, obstruction of lymphatic flow, degeneration of elastic fibers, tear deficiency, actinic action and delayed tear clearance.¹ A degenerative basis for CCh seems most likely, since the majority of patients with this condition are over the age of 50. Additionally, documented associations have been established between CCh and both pinguecula and dermatochalasis—degenerative disorders of the conjunctiva and eyelid, respectively.^{1,3,4,10,11} Yet, histopathologic studies of conjunctivae taken from patients



With conjunctivochalasis, dyes such as NaFl can collect between the redundant conjunctival folds, enhancing visibility to differentiate the condition from aqueous-deficient dry eye.

with CCh reveal normal cytology in the majority of cases, with lymphangiectasia and inflammatory infiltrate being observed in a small percentage of subjects.^{12,13} Given the myriad possibilities, it seems that the pathogenesis of conjunctival folds in CCh is likely multifactorial in nature, resulting from a combination of senescent, traumatic and immunologic effects.¹³

The cascade of events occurring at the ocular surface level once CCh becomes manifest is more certain. Conjunctival folds disrupt the tear meniscus and interfere with normal tear outflow through the inferior punctum, a phenomenon referred to as delayed tear clearance (DTC).^{1,3,14-16} DTC may be seen in a variety of ocular surface disorders, and is independently associated with symptoms of ocular irritation as well as corneal epithelial disease.¹⁷ Moreover, DTC is believed to promote inflammation, due to accumulation of tear cytokines, proteolytic enzymes and cytotoxic factors in the tear fluid.^{9,17,18} Such inflammatory elements have been demonstrated in the tears of patients with more severe cases of CCh.¹⁹⁻²¹ Mechanically, CCh also causes a displacement of the normal space between the ocular surface and lower lid. Redundant conjunctival folds move downward with gravity and occupy the inferior fornix, effectively negating its function as a tear reservoir.^{14,22} The combined effects of disrupted tear flow

and loss of the normal reservoir result in epiphora and dry eye disease, both common in CCh.

In the most extreme cases of CCh, conjunctival folds may actually protrude across the lid margin and create a physical barrier to normal lid closure, resulting in further exposure and desiccation of the ocular surface.^{1,4} Patients with these severe changes may secondarily suffer from nocturnal lagophthalmos, a condition that can often be corroborated by family members or significant others.^{10,16}

Management

Intervention for patients with CCh typically depends upon the severity of the condition and its related signs and symptoms. It is common for clinicians to ignore CCh in asymptomatic individuals, although the progressive nature of this condition dictates, at the very least, a more focused history along with patient education regarding ocular surface disorders.²³ Mild irritation can often be managed successfully with ophthalmic lubricants and short-term treatment directed at associated pathologies (e.g., night patching for nocturnal lagophthalmos). A recent study demonstrated clinical improvement in patients treated conservatively with a novel, preservative-free artificial tear (Conheal; PannonPharma) containing isotonic glycerol and 0.015% hyaluronic acid in purified water.²⁴ This formulation is, unfortunately, not yet available in the United States.

Despite the fact that CCh has been associated with increased levels of inflammatory mediators, topical anti-inflammatory agents such as corticosteroids or NSAIDs have not been proven to resolve the issue. Although symptoms may initially improve, evidence does not exist that topical anti-inflammatory drugs can restore the conjunctiva in CCh to a normal configuration. Moreover, the retention of these drugs and their preservatives on the ocular surface may actually aggravate the condition, in light of

delayed tear clearance.¹ Ultimately, most symptomatic patients with CCh will require surgical intervention to achieve symptomatic resolution.

While there is no clear consensus regarding the surgical technique of choice for CCh, the goal is to eliminate (or at least reduce) the laxity and redundancy of the conjunctiva, while helping to reconstruct a normal tear meniscus. Less invasive measures that have shown some degree of success include both thermal cauterization and high-frequency radiowave electrocautery of the lax tissue along the inferior bulbar conjunctiva.²⁵⁻²⁸ Surgical resection of the inferior bulbar conjunctiva in a crescent-shaped pattern is another treatment option, which more definitively eliminates redundant conjunctival tissue.^{10,28-30} Modifications on this technique include the use of amniotic membrane grafts over the resected area and the employment of fibrin glue in lieu of sutures.²⁸⁻³²

The latest and most elaborate surgical technique for treating CCh has been described as the “reservoir restoration procedure.”³³ In addition to resecting the redundant conjunctiva from the inferior bulbar region, this technique includes: excision of mobile and degenerated Tenon’s fascia from the episcleral surface and the underside of the conjunctiva; fornix deepening reconstruction with ablation of prolapsed orbital fat, and conjunctival recession into the fornix; and cryopreserved amniotic membrane transplantation to the affected area using tissue glue under topical anesthesia.^{22,33}

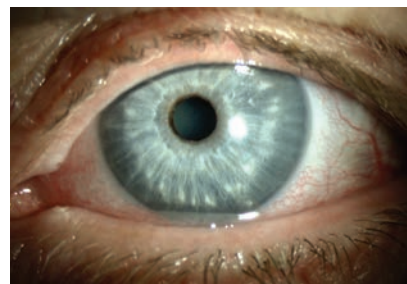
Clinical Pearls

- A key differential of CCh is conjunctival chemosis associated with allergic conjunctivitis. CCh results in characteristic folds of the conjunctiva that disappear when the lower lid is depressed or withdrawn. The “boggy” edema associated with allergy tends to be constant and often produces a “watchglass” effect around the limbus.

- Patients presenting with CCh affecting the nasal conjunctiva often have more pronounced symptoms, decreased Schirmer scores, increased meibomian gland dropout and increased eyelid vascularity compared with individuals whose CCh do not involve the nasal conjunctiva.⁸ This discrepancy is presumably due to physical blockade of the inferior punctum, causing a cascade effect of altered distribution, composition and stability of tears.⁸

- Although CCh is typically thought of as an age-related ocular surface disorder, research has identified a strong association between this condition and autoimmune thyroid disease.³⁴ Additionally, cases of CCh have been described in association with both Ehlers-Danlos syndrome and cutis laxa.^{35,36} Hence, a thorough medical history in these patients remains essential.

- While CCh and dry eye disease represent distinctly different pathologies with often disparate clinical findings, more severe cases of CCh appear to present with increasingly similar test results, including diminished Schirmer values, elevated matrix metalloproteinase (MMP)-9 levels, increased tear osmolarity and more extensive vital dye staining of the ocular surface.^{4,8,9,18-21} Hence, patients with severe CCh may actually convert to dry eye disease due to pathological changes at the ocular surface level and the close relationship of all structures comprising the lacrimal functional unit.¹⁷ Still, conventional treatments for dry eye



Note the large fold of conjunctiva obscuring the inferior corneal margin in a patient with conjunctivochalasis.

disease such as topical cyclosporine or punctal occlusion therapy may be of little value until definitive treatment of CCh has been employed.

- A modified form of conjunctivochalasis surgery has been marketed in various parts of the United States as a cosmetic procedure (i.e., “eye whitening”³⁷). It is important to distinguish between this elective surgery and reparative CCh surgery when discussing options with patients.

- Murube J. Characteristics and etiology of conjunctivochalasis: historical perspective. *Ocul Surf*. 2005;3(1):7-14.
- Mimura T, Usui T, Yamamoto H, et al. Conjunctivochalasis and contact lenses. *Am J Ophthalmol*. 2009;148(1):20-5.e1.
- Di Pascuale MA, Espana EM, Kawakita T, et al. Clinical characteristics of conjunctivochalasis with or without aqueous tear deficiency. *Br J Ophthalmol*. 2004;88(3):388-92.
- Balci O. Clinical characteristics of patients with conjunctivochalasis. *Clin Ophthalmol*. 2014;8:1655-60.
- Höh H, Schirra F, Kienecker C, et al. Lid-parallel conjunctival folds are a sure diagnostic sign of dry eye. *Ophthalmologie*. 1995; 92(6):802-8.
- Kheirkhah A, Casas V, Esquenazi S, et al. New surgical approach for superior conjunctivochalasis. *Cornea*. 2007;26(6):685-91.
- Mimura T, Usui T, Yamagami S, et al. Subconjunctival hemorrhage and conjunctivochalasis. *Ophthalmology*. 2009;116(10):1880-6.
- Chhadva P, Alexander A, McClellan AL, et al. The impact of conjunctivochalasis on dry eye symptoms and signs. *Invest Ophthalmol Vis Sci*. 2015;56(5):2867-71.
- Fodor E, Kosina-Hagyó K, Bausz M, et al. Increased tear osmolarity in patients with severe cases of conjunctivochalasis. *Curr Eye Res*. 2012;37(1):80-4.
- Meller D, Tseng SC. Conjunctivochalasis: literature review and possible pathophysiology. *Surv Ophthalmol*. 1998;43(3):225-32.
- Mimura T, Mori M, Obata H, et al. Conjunctivochalasis: associations with pinguecula in a hospital-based study. *Acta Ophthalmol*. 2012;90(8):773-82.
- Watanabe A, Yokoi N, Kinoshita S, et al. Clinicopathologic study of conjunctivochalasis. *Cornea*. 2004;23(3):294-8.
- Francis IC, Chan DG, Kim P, et al. Case-controlled clinical and histopathological study of conjunctivochalasis. *Br J Ophthalmol*. 2005;89(3):302-5.
- Huang Y, Sheha H, Tseng SC. Conjunctivochalasis interferes with tear flow from fornix to tear meniscus. *Ophthalmology*. 2013;120(8):1681-7.
- Yokoi N, Komuro A, Nishii M, et al. Clinical impact of conjunctivochalasis on the ocular surface. *Cornea*. 2005;24(8 Suppl):S24-S31.
- Erdogan-Poyraz C, Mocan MC, Irkeç M, et al. Delayed tear clearance in patients with conjunctivochalasis is associated with punctal occlusion. *Cornea*. 2007;26(3):290-3.
- de Paiva CS, Pflugfelder SC. Tear clearance implications for ocular surface health. *Exp Eye Res*. 2004;78(3):395-7.
- Wang Y, Dogru M, Matsumoto Y, et al. The impact of nasal conjunctivochalasis on tear functions and ocular surface findings. *Am J Ophthalmol*. 2007;144(6):930-7.
- Acera A, Rocha G, Vecino E, et al. Inflammatory markers in the tears of patients with ocular surface disease. *Ophthalmic Res*. 2008;40(6):315-21.

- Ward SK, Wakamatsu TH, Dogru M, et al. The role of oxidative stress and inflammation in conjunctivochalasis. *Invest Ophthalmol Vis Sci*. 2010;51(4):1994-2002.
- Acera A, Vecino E, Duran JA. Tear MMP-9 levels as a marker of ocular surface inflammation in conjunctivochalasis. *Invest Ophthalmol Vis Sci*. 2013;54(13):8285-91.
- Cheng AM, Yin HY, Chen R, et al. Restoration of fornix tear reservoir in conjunctivochalasis with fornix reconstruction. *Cornea*. 2016; Feb 17. [Epub ahead of print].
- Gumus K, Pflugfelder SC. Increasing prevalence and severity of conjunctivochalasis with aging detected by anterior segment optical coherence tomography. *Am J Ophthalmol*. 2013;155(2):238-242.e2.
- Kiss HJ, Németh J. Isotonic glycerol and sodium hyaluronate containing artificial tear decreases conjunctivochalasis after one and three months: a self-controlled, unmasked study. *PLoS One*. 2015;10(7):e0132656.
- Haefliger IO, Vysniauskienė I, Figueiredo AR, et al. Superficial conjunctiva cauterization to reduce moderate conjunctivochalasis. *Klin Monbl Augenheilkd*. 2007;224(4):237-9.
- Nakasato S, Uemoto R, Mizuki N. Thermocautery for inferior conjunctivochalasis. *Cornea*. 2012;31(5):514-9.
- Chan TC, Ye C, Ng PK, et al. Change in tear film lipid layer thickness, corneal thickness, volume and topography after superficial cauterization for conjunctivochalasis. *Sci Rep*. 2015;5:12239.
- Youm DJ, Kim JM, Choi CY. Simple surgical approach with high-frequency radio-wave electrocautery for conjunctivochalasis. *Ophthalmology*. 2010;117(11):2129-33.
- Kheirkhah A, Casas V, Blanco G, et al. Amniotic membrane transplantation with fibrin glue for conjunctivochalasis. *Am J Ophthalmol*. 2007;144(2):311-3.
- Brod baker E, Bahar I, Slomovic AR. Novel use of fibrin glue in the treatment of conjunctivochalasis. *Cornea*. 2008;27(8):950-2.
- Maskin SL. Effect of ocular surface reconstruction by using amniotic membrane transplant for symptomatic conjunctivochalasis on fluorescein clearance test results. *Cornea*. 2008;27(6):844-9.
- Doss LR, Doss EL, Doss RP. Paste-pinch-cut conjunctivoplasty: subconjunctival fibrin sealant injection in the repair of conjunctivochalasis. *Cornea*. 2012;31(8):959-62.
- Salinger CL. Reservoir restoration for the treatment of conjunctivochalasis. Available at: https://cdh2.hubspot.net/hubfs/341698/Blog_Images_Documents/Documents/Reservoir-Restoration-for-the-Treatment-of-Conjunctivochalasis.pdf (last accessed April 29, 2016).
- de Almeida SF, de Sousa LB, Vieira LA, et al. Clinicocytologic study of conjunctivochalasis and its relation to thyroid autoimmune diseases: prospective cohort study. *Cornea*. 2006;25(7):789-93.
- Whitaker JK, Alexander P, Chau DY, et al. Severe conjunctivochalasis in association with classic type Ehlers-Danlos syndrome. *BMC Ophthalmol*. 2012;12:47.
- Kantaputra PN, Kaewgahya M, Wivatwongwana A, et al. Cutis laxa with pulmonary emphysema, conjunctivochalasis, nasolacrimal duct obstruction, abnormal hair, and a novel FBLN5 mutation. *Am J Med Genet A*. 2014;164A(9):2370-7.
- Kabat AG, Sowka JW. Eye whitening 90210. *Review of Optometry* 2011;148(2):114-5.

CONJUNCTIVAL INTRAEPITHELIAL NEOPLASIA

Signs and Symptoms

Conjunctival intraepithelial neoplasia (CIN) is the most common neoplasm of the ocular surface in immunocompetent

individuals.¹⁻⁴ It is the precursor to conjunctival squamous cell carcinoma in situ (CIS or SCC) of the conjunctival epithelium, the most common ocular surface neoplasm in all patient populations.^{2,3} Ocular surface squamous neoplasia (OSSN) is an alternate term used in the literature to describe neoplastic epithelial abnormalities of the conjunctiva and cornea, ranging from squamous dysplasia to invasive squamous cell carcinoma.³⁻⁸

The clinical features of CIN include a hyperemic, soft, movable nodular mass with well-defined borders on the conjunctiva within the palpebral fissure, possibly extending to involve the palpebral conjunctiva or peripheral cornea. The mass is often greater than 2mm in vertical height and, depending upon the ability of it to remain moistened by tears, may contain areas of drying and necrosis.³ No consistent clinical criteria exist for distinguishing CIS from the more invasive SCC.⁶ The presence of intrinsic feeder vessels in a nodular lesion should raise suspicion of invasive SCC.⁶ OSSN usually presents either as a fleshy, gelatinous, elevated lesion or as a sessile papilloma within the temporal or nasal interpalpebral region.⁶

In all of these variants, vision is rarely affected, as the lesions do not tend to encroach onto the cornea over the visual axis.⁶ Patients may complain of a regional swelling with redness and irritation. Cases left unmanaged can expand in size, infiltrating the cornea and sclera. In the worst circumstances, the tumor can invade the orbit, causing proptosis.^{6,8}

Risk factors for CIN include exposure to ultraviolet light, the vapors of petroleum products and first- or second-hand cigarette smoke, and having light hair, a light complexion and a family history for CIN or CIS.³ Another significant risk factor is exposure to cutaneous human papilloma virus (HPV).¹⁻⁵ CIN is known to affect men more frequently than women after the sixth decade of life.³ CIS accounts for approximately 39%

of all malignant lesions of the conjunctiva. About 75% occur in men; 75% are diagnosed in older patients, with 75% of lesions occurring at the limbus.⁶ These tumors in young patients are seen in concert with human immunodeficiency virus (HIV) or acquired immune deficiency syndrome (AIDS).¹⁻⁶

Pathophysiology

Conjunctival intraepithelial neoplasia is a malignant neoplasm arising from limbal stem cells.³ CIN invades through epithelial basement membrane into the conjunctival or corneal stroma and, though rare, into the globe or orbit.^{2,3,6,8} CIN is characterized by involvement of nonkeratinized epithelium occurring at the transition zones of the surface epithelium.³⁻⁸ Partial-thickness replacement of the epithelium occurs by anaplastic cells that lack normal maturation.⁶

The pathogenesis of CIN transformation into the more invasive squamous cell carcinoma (SSC) involves pathologic changes associated with immunosuppression in the setting of coinfection with HPV.¹⁻⁸ Histopathic examination shows epithelial dyskeratosis with spindle cells that have prominent nuclei.^{6,8} Invasive SCC breaches the basement membrane of the basal epithelial cells and becomes well differentiated into a neoplasm composed of abnormal mitotic epithelial cells and keratin.⁴⁻⁸ Occasionally, pleomorphic cells, numerous mitotic figures, anaplasia and dyskeratosis are present.⁸

The American Joint Committee on Cancer (AJCC) provides a section committed to staging tumors of the ocular surface.⁹ A simplified accounting of the AJCC classification for ocular surface tumors is: *T1* (tumor ≤ 5 mm in greatest dimension); *T2* (tumor >5 mm in greatest dimension, without invasion of adjacent structures); *T3* (tumor invades adjacent structures, excluding the orbit) and *T4* (tumor invades orbit with or without further extension).^{9,10}

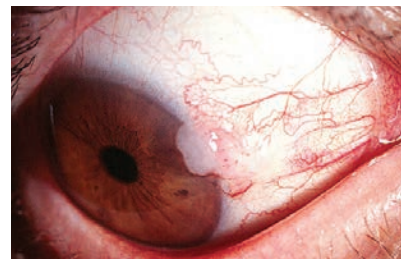Management

As the diagnosis of OSSN and its variants is typically made by observation of appearance and biopsy, it is unclear if OCT use provides additional benefits other than accurate and repeatable measurement, the ability to noninvasively screen tissues for changes associated with the disease, and an ability to monitor progress following the employment of surgical and nonsurgical interventions.¹¹

Treatment for CIN and its variants has historically been surgery; however, nonsurgical interventions are rising in popularity because of their ability to remove the lesion while protecting the ocular surface from the formation of additional lesions.^{10,12-14} Nonsurgical solutions eliminate the risks associated with surgical complications, as ocular surface surgery is rarely simple.^{10,13}

Excisional biopsies involve resection, cryotherapy (applied to the margin of the tumor to kill tumor-margin cells), proton beam radiation, corneal epitheliectomy with alcohol application when the cornea is involved, lamellar sclerectomy and alcohol application to the tumor base when the episclera is breached. Tumor resections often require complicated ocular surface reconstructions that may or may not involve the placement of cryopreserved amniotic membrane.^{10,12-17} Surgical removal carries a good prognosis with reduced risk for recurrence.^{10,12-16} Tumors with higher recurrence risk are those with tarsal involvement, pathologic presence of positive margins and a nasal location. Tumors treated with cryotherapy have been associated with a decreased risk of tumor recurrence.⁹⁻¹¹

Medical treatments for ocular surface tumors include intralesional mitomycin-C, 5-fluorouracil, cidofovir and interferon 2b.^{8,12-14} Mitomycin-C (MMC 0.02–0.04%) QID four days a week for four weeks has been shown to be highly effective, but not without short- and long-term side effects, including conjunctival hyperemia and punctate



The clinical features of conjunctival intraepithelial neoplasia include a hyperemic, soft, movable nodular mass with well-defined borders on the conjunctiva within the palpebral fissure, possibly extending onto the cornea.

corneal erosions.¹²⁻¹⁴ Prolonged use may lead to scleral melt.^{8,12-14} The side effects makes this intolerable treatment for some patients. Topical interferon 2b (IFN) and 5-fluorouracil have been found to have similar efficacy to MMC with better patient tolerability.^{12,13} The beneficial role of interferon includes reduced recurrences by way of immunomodulation, antiproliferative effects and antiviral effects.^{8,12-14} The reported success rate is 83% with topical IFN at one million international units (IU) administered four times daily for six to 12 months.^{12,13} The most common complication of IFN therapy is transient, flu-like symptoms.¹²

Due to the known association of CIN with cervical intraepithelial neoplasia (caused by either HPV or immunosuppression), appropriate gynecological referrals and testing should be recommended.³

Clinical Pearls

- Since CIN may indicate reduced immune competence, appropriate testing should be initiated.
- As CIN has a connection with cervical cancer, an appropriate referral in female cases is warranted.
- Differential diagnoses include Kaposi's sarcoma, amelanotic melanoma and conjunctival basal cell carcinoma.
- New sensitive anterior segment instrumentation may permit imaging of suspicious lesions. Biopsy remains the

standard of care. Imaging and photography have the potential to accurately document these lesions so changes in size, shape, color or elevation can be more easily observed by the clinician who is monitoring the lesion.

1. Starita N, Annunziata C, Waddell KM, et al. Identification of human herpesvirus 8 sequences in conjunctiva intraepithelial neoplasia and squamous cell carcinoma of ugandan patients. *Biomed Res Int*. 2015;2015(10):801353.
2. Rishi P, Shields CL, Eagle RC. Conjunctival intraepithelial neoplasia with corneal furrow degeneration. *Indian J Ophthalmol*. 2014;62(7):809-11.
3. Dugel PU, Thach AB. Ocular neoplasms related to the human immunodeficiency virus. In: Yanoff M, Duker JS. *Ophthalmology*. Mosby-Elsevier, St. Louis, MO. 2009:1229-32.
4. Shields CL, Shields JA. Tumors of the conjunctiva and cornea. *Surv Ophthalmol*. 2004;49(1):3-24.
5. Carrilho C, Gouveia P, Yokohama H, et al. Human papillomaviruses in intraepithelial neoplasia and squamous cell carcinoma of the conjunctiva: a study from Mozambique. *Eur J Cancer Prev*. 2013;22(6):566-8.
6. Dandala PP, Malladi P, Kavitha. Ocular surface squamous neoplasia (ossn): a retrospective study. *J Clin Diagn Res*. 2015;9(11):10-13.
7. Honavar SG, Manjandavida FP. Tumours of the ocular surface: A review. *Indian J Ophthalmol*. 2015;63(3):187-203.
8. Nicholson DH, Herschler J. Intraocular extension of squamous cell carcinoma of the conjunctiva. *Arch Ophthalmol*. 1977;95(5):843-6.
9. Chen VW, Ruiz BA, Hsieh MC, et al. Analysis of stage and clinical/prognostic factors for lung cancer from SEER registries: AJCC staging and collaborative stage data collection system. *Cancer*. 2014;120(12) Suppl 23:3781-92.
10. Galor A, Karp CL, Oellers P, et al. Predictors of ocular surface squamous neoplasia recurrence after excisional surgery. *Ophthalmology*. 2012;119(10):1974-81.
11. Thomas BJ, Galor A, Nanji AA, et al. Ultra-high-resolution anterior segment optical coherence tomography in the diagnosis and management of ocular surface squamous neoplasia. *Ocul Surf*. 2014;12(1):46-58.
12. Zarei-Ghanavati S, Alizadeh R, Deng SX. Topical interferon alpha-2b for treatment of noninvasive ocular surface squamous neoplasia with 360° limbal involvement. *J Ophthalmic Vis Res*. 2014;9(4):423-6.
13. Nanji AA, Sayyad FE, Karp CL. Topical chemotherapy for ocular surface squamous neoplasia. *Curr Opin Ophthalmol*. 2013;24(4):336-42.
14. Rudkin AK, Dempster L, Muecke JS. Management of diffuse ocular surface squamous neoplasia: efficacy and complications of topical chemotherapy. *Clin Experiment Ophthalmol*. 2015;43(1):20-5.
15. Palamar M, Kaya E, Egrilmez S, et al. Amniotic membrane transplantation in surgical management of ocular surface squamous neoplasias: long-term results. *Eye (Lond)*. 2014;28(9):1131-5.
16. Crim N, Forniés-Paz ME, Monti R, et al. In situ carcinoma of the conjunctiva: surgical excision associated with cryotherapy. *Clin Ophthalmol*. 2013;7(9):1889-93.
17. El-Assal KS, Salvi SM, Rundle PA, et al. Treatment of invasive ocular surface squamous neoplasia with proton beam therapy. *Eye (Lond)*. 2013;27(10):1223-4.

CONJUNCTIVAL CYSTS

Signs and Symptoms

The term *cyst* is derived from the Greek word *kystis*, meaning “bladder” or “pouch,” and describes the sac-like nature of these common lesions. Conjunctival cysts are generally seen as thin-walled vesicles containing clear or, less commonly, turbid fluid.¹⁻³ Epithelial debris may also sometimes be seen at the base of these lesions.⁴ They may arise from virtually any aspect of the conjunctival anatomy, including the tarsus, but are more commonly noted affecting the bulbar conjunctiva and fornix.⁵

When seen on the bulbar conjunctiva, they often resemble a raised blister, with conjunctival blood vessels coursing over and around the lesion. In the fornix, small conjunctival cysts may be flat-surfaced and appear as “window defects,” demonstrating fluid with or without cellular material beneath. Larger cysts in the fornix may present with a dome-shaped appearance similar to that seen with cysts on the bulbar conjunctiva.⁶

Patients with conjunctival cysts may present with a variety of complaints; they may also be entirely asymptomatic, depending upon the size and location of the lesion. Most often, cysts of the bulbar conjunctiva present merely a cosmetic concern.⁷ As they become larger, however, the likelihood of awareness and/or irritation increases. Impairment of lid closure can result in exposure and dry eye symptoms, including burning, scratchiness and foreign body sensation. Large cysts within the fornices can also present as a cosmetic concern, but typically the complaint is related to perceived swelling of the eyelid.^{6,7} Larger cysts can also act like space-occupying lesions, potentially restricting ocular motility.^{8,9} Visual acuity is rarely affected.¹⁰ Conjunctival cysts may be encountered in all races, in either gender and at virtually any age. A history of prior ocular surgery may also be noted.^{3,7,11,12}

Pathophysiology

Two distinct types of conjunctival cysts are known to occur: *retention cysts* and *inclusion cysts*.¹³ Although they are often depicted as synonymous in the ophthalmic vernacular, each has a unique etiology and pathophysiology.

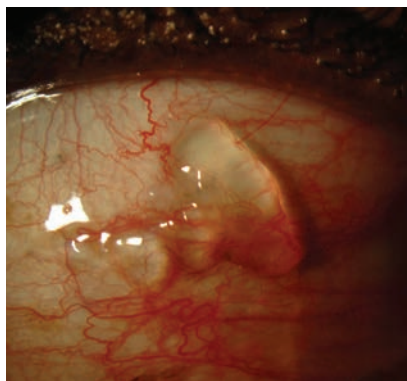
By definition, retention cysts are produced by obstruction of a duct leading from a secreting organ, with the consequent retention of its normal secretions. In the conjunctiva, retention cysts may occur at the apex of the tarsus or fornix, and are typically associated with the accessory lacrimal glands of Krause and Wolfring.¹⁴⁻¹⁶ The term *dacryops* is sometimes used to describe this condition, although more commonly this refers to a cystic lesion affecting the ducts of the primary lacrimal gland.^{16,17}

Inclusion cysts, as the name implies, are formed due to the inclusion of a small portion of epithelium within the connective tissue of the conjunctiva. Inclusion cysts may be congenital, but are most commonly associated with trauma, prior surgery or other inflammatory processes.⁹ Viable superficial epithelial cells become trapped within the underlying substantia propria; proliferation of these cells then results in a focal mass, which ultimately cavitates and forms an epithelial-lined cyst.¹³

Inclusion cysts have been identified in association with vernal keratoconjunctivitis, toxic keratoconjunctivitis, Stevens-Johnson syndrome, pterygia, small-incision cataract surgery, sub-Tenon's injections, strabismus surgery, glaucoma filtering surgery and scleral buckling surgery.^{2,3,7,8,10-12,18-20} Inclusion cysts are far more common than retention cysts, representing approximately 80% of all cystic lesions affecting the conjunctiva.^{5,18}

Management

The management of conjunctival cysts begins with proper diagnosis. It is important to differentiate these from other raised conjunctival lesions such



Conjunctival inclusion cysts, as the name implies, are formed due to the inclusion of a small portion of epithelium within the connective tissue of the conjunctiva.

as squamous or limbal papillomas, pseudoepitheliomatous hyperplasia, pingueculae, dermoids, pyogenic granulomas, lymphangiomas or lymphangiectasias. Moreover, it is crucial to rule out potentially malignant lesions of the conjunctiva, such as lymphoma, ocular surface squamous neoplasia or conjunctival melanoma. Clinicians should note any characteristic features of malignancy such as rapid growth, feeder vessels or acquired variations in pigmentation. If there is any doubt as to the nature of the lesion, consultation with an experienced ophthalmic surgeon should be facilitated and biopsy obtained.

The management for symptomatic conjunctival cysts is typically surgical. Although many of these lesions could simply be addressed via benign neglect, most patients seeking consultation ultimately wish to have the condition alleviated. Based upon their appearance, it would seem that a simple stab incision would suffice; however, the reality is that a vast majority of these lesions will recur if treated with puncture/aspiration.^{1,21,22} Most sources advocate complete surgical excision of the cyst using conventional methods.^{2,3,7,10,12,13,15,16,18} Alternatively, some success has been achieved with less invasive techniques, including local injection of 70% isopropyl alcohol, laser photocoagulation and thermocautery.²¹⁻²³

Clinical Pearls

- Cystic inclusions are a common feature of conjunctival nevi. Studies suggest that 57% to 80% of nevi demonstrate intrinsic cysts on biomicroscopy. These may be verified by the use of anterior segment optical coherence tomography.²⁴⁻²⁶ The presence of cysts is considered an important factor in the differentiation between conjunctival nevi and conjunctival melanoma.^{25,26}
- Conjunctival concretions, sometimes referred to as lithiasis, have been described as inclusion cysts filled with keratin (a protein constituent of epidermis and hair) and epithelial debris within the inferior and superior palpebral conjunctiva.²⁷ Immature conjunctival concretions are often seen to have a small, cystic lesion adjacent to or overlying it.
- Lymphangiectasia is another rare condition that may mimic conjunctival cysts. These lesions represent dilation of the normal lymphatic vessels within the bulbar conjunctiva, and can manifest as either a diffuse enlargement or a linear series of small cysts.²⁸ Lymphangiectasia may be associated with a variety of other medical disorders, most notably nephrotic syndrome, malnutrition, thyroid eye disease, cavernous sinus thrombosis and carotid-cavernous fistula.²⁸ It is important that patients be screened for associated lymphadenopathy and undergo appropriate medical evaluation if lymphangiectasia is suspected.

1. Bowling B. *Kanski's Clinical Ophthalmology: A Systematic Approach*, 8th Edition. Atlanta: Elsevier, 2016. 165.
2. Lee SW, Lee SC, Jin KH. Conjunctival inclusion cysts in long-standing chronic vernal keratoconjunctivitis. *Korean J Ophthalmol*. 2007;21(4):251-4.
3. Salagar KM, Pujari MR, Murthy CN. A rare case report of conjunctival cyst. *J Clin Diagn Res*. 2015;9(11):ND01-2.
4. Honavar SG, Manjandavida FP. Tumors of the ocular surface: A review. *Indian J Ophthalmol* 2015;63:187-203.
5. Nath K, Gogi R, Zaidi N, Johri A. Cystic lesions of conjunctiva. *Indian J Ophthalmol* 1983;31:1-4.
6. Yoon HS, Lee MJ. A case of conjunctival inclusion cyst managed with marsupialization. *J Korean Ophthalmol Soc*. 2014;55(2):289-92.
7. Narayanappa S, Dayananda S, Dakshayini M, et al. Conjunctival inclusion cysts following small incision cataract surgery. *Indian J Ophthalmol*. 2010;58(5):423-5.
8. Singh G, Rajaraman R, Raghavan A, et al. Bilateral conjunctival retention cysts in the aftermath of Stevens-Johnson syndrome. *Indian J Ophthalmol*. 2008;56(1):70-2.

9. Kim DH, Khwarg SI, Oh JY. Atypical manifestation of conjunctival epithelial inclusion cyst: a case report. *Case Rep Ophthalmol*. 2014;5(2):239-42.
10. Kiratti H, Bilgiç S, Gököz O, et al. Conjunctival epithelial inclusion cyst arising from a pterygium. *Br J Ophthalmol*. 1996;80(8):769-70.
11. Vishwanath MR, Jain A. Conjunctival inclusion cyst following sub-Tenon's local anaesthetic injection. *Br J Anaesth*. 2005;95(6):825-6.
12. Guadilla AM, de Líaño PG, Merino P, et al. Conjunctival cysts as a complication after strabismus surgery. *J Pediatr Ophthalmol Strabismus*. 2011;48(5):298-300.
13. Völcker HE, Naumann GOH. *Conjunctiva*. In: Naumann GOH, Apple DJ, eds. *Pathology of the Eye*. New York: Springer-Verlag New York, Inc., 1986. 249-316.
14. Khoury NJ, Haddad MC, Tawil AN, et al. Ductal cysts of the accessory lacrimal glands: CT findings. *AJNR Am J Neuroradiol*. 1999;20(6):1140-2.
15. Jakobiec FA, Roh M, Stagner AM, et al. Caruncular dacryops. *Cornea*. 2015;34(1):107-9.
16. Jastrzebski A, Brownstein S, Jordan DR, et al. Dacryops of Krause gland in the inferior fornix in a child. *Arch Ophthalmol*. 2012;130(2):252-4.
17. Lam K, Brownstein S, Jordan DR, et al. Dacryops: a series of 5 cases and a proposed pathogenesis. *JAMA Ophthalmol*. 2013;131(7):929-32.
18. Thatte S, Jain J, Kinger M, et al. Clinical study of histologically proven conjunctival cysts. *Saudi J Ophthalmol*. 2015;29(2):109-15.
19. Kothari MT, Jain S, Kothari KJ. Giant inclusion cyst of the cornea following filtering surgery. *Indian J Ophthalmol*. 2006;54(2):117-8.
20. Johnson DW, Bartley GB, Garrity JA, et al. Massive epithelium-lined inclusion cysts after scleral buckling. *Am J Ophthalmol*. 1992;113(4):439-42.
21. Kothari M. A novel method for management of conjunctival inclusion cysts following strabismus surgery using isopropyl alcohol with paired injection technique. *J AAPOS*. 2009;13(5):521-2.
22. Han SB, Yang HK, Hyon JY. Removal of conjunctival cyst using argon laser photocoagulation. *Can J Ophthalmol*. 2012;47(3):e6-8.
23. Hawkins AS, Hamming NA. Thermal cautery as a treatment for conjunctival inclusion cyst after strabismus surgery. *J AAPOS*. 2001;5(1):48-9.
24. Leveque L, De Potter P, Jamart J. Conjunctival nevi: clinical features and therapeutic outcomes. *Ophthalmology*. 2010;117(1):35-40.
25. Shields CL, Demerci H, Karatza E, et al. Clinical survey of 1643 melanocytic and nonmelanocytic conjunctival tumors. *Ophthalmology* 2004;111(9):1747-54.
26. Shields CL, Belinsky I, Romanelli-Gobbi M, et al. Anterior segment optical coherence tomography of conjunctival nevi. *Ophthalmology*. 2011;118(5):915-9.
27. Friedman NJ, Kaiser PK. *Essentials of Ophthalmology*, 1st edition. Philadelphia: Saunders Elsevier, 2007. 160.
28. Welch J, Srinivasan S, Lyall D, et al. Conjunctival lymphangiectasia: a report of 11 cases and review of literature. *Surv Ophthalmol*. 2012;57(2):136-48.

MUCUS FISHING SYNDROME

Signs & Symptoms

Patients with mucus fishing syndrome (MFS) present with a chief complaint of chronic or excessive stringy discharge from one or both eyes, as well as varying degrees of accompanying ocular irritation.¹⁻⁵ There may be a history of having used one or more topical agents (artificial

tears, allergy drops, antibiotic drops, etc.) with little or no success. Both men and women may be affected, but the condition has been documented more frequently in women.¹ Often, patients will have preexisting or concurrent diagnoses related to ocular surface disease, including one or more of the following: dry eye disease, keratoconjunctivitis sicca, exposure keratopathy, anterior blepharitis, foreign body or chronic allergic conjunctivitis.¹ Examination often reveals a compromised precorneal tear film, as evidenced by diminished fluorescein tear break up time; occasionally, mucus filaments or strands may be visible in the tear film as well.²

The application of either lissamine green or rose bengal dye reveals areas of confluent conjunctival staining, typically inferior to the cornea, or in the adjacent limbal or pericanthal regions. This vital dye staining represents areas of mechanical trauma to the bulbar and/or palpebral conjunctiva, and is considered pathognomonic for MFS. When questioned directly as to how the mucus is eliminated, patients will characteristically describe or demonstrate the physical removal of these strands using their finger, fingernail or some other implement such as a cotton-tipped applicator, cotton ball, tissue or washcloth.^{1,2} Paradoxically, the same patients may state emphatically that they never touch the eye. Hence, psychological factors may be at play with this condition.

Pathophysiology

MFS was first reported in the literature in 1985. At that time, the authors postulated that the condition represented the conjunctival tissue's cyclical and progressive inflammatory response to repeated mechanical irritation in the presence of an incipient ocular surface disease state.¹ In 2001, researchers suggested that, in addition to mechanical injury, the recurrent introduction of extrinsic antigens by means of the patient's fin-

gernail or other object might additionally stimulate mucus production via the complementary cascade, mast cell degranulation, histamine release and prostaglandin synthesis.^{2,3} Additional etiologic factors have yet to be considered, but the action of repeatedly removing mucus from the ocular surface or conjunctival cul-de-sac is widely believed to initiate the cascading cycle of MFS, which persists until the stimulus is removed.

Since MFS is uncommonly encountered in individuals with ocular surface disease, logic suggests that there may be another common factor in the genesis of this condition. Authors have hinted at a psychological element in patients with MFS, indicating some degree of patient embarrassment as well as a reluctance to discontinue the behavior, even when informed that the mere act of removing the mucus strands may be the main causative element in this disease.^{1,2} In fact, it has been speculated that MFS may represent an ocular form of obsessive-compulsive disorder.⁶

Management

Management of MFS must begin with patient education regarding the deleterious effects of chronic, mechanical self-removal of mucus strands.¹⁻⁵ It should be clearly communicated that the condition cannot resolve fully until this habit is discontinued. Beyond this, addressing the underlying ocular surface disorder becomes paramount. Efforts should be aimed at reducing contributory ocular surface inflammation and irritating stimuli by using palliative, pharmaceutical and/or surgical treatment options.

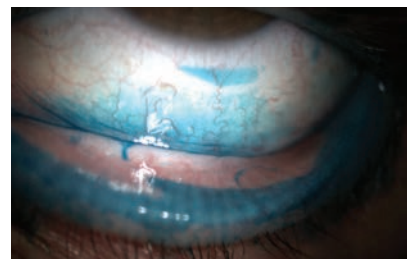
Ocular lubricants can be helpful in flushing excess mucus from the ocular surface, in lieu of direct mechanical removal. Liberal use of nonpreserved artificial tears should be encouraged for all patients with MFS. Those who still complain of mucus accumulation may benefit from topical 5% or 10% N-acetylcysteine drops.²

N-acetylcysteine is a mucolytic agent, generally employed in the treatment of respiratory conditions such as emphysema or cystic fibrosis. It works by breaking the disulfide bridges of high molecular weight glycoproteins, resulting in diminished mucus accumulation and overall reduction of secretion viscosity.⁷ While not commercially available in the United States or Canada, this formulation can be obtained via a compounding pharmacist for ophthalmic use, and is typically administered four times daily for approximately one month. Should an allergic component be present or suspected, topical antihistamine/mast cell stabilizing agents (e.g., alcaftadine 0.25% once daily or bepotastine 1.5% twice daily) can be employed as well.^{2,4,5}

Once the cycle has been broken, attention should be directed toward long-term management of contributory ocular surface disorders. Since dry eye disease is one of the more common etiologies of MFS, the use of topical cyclosporine 0.05% twice daily can be of benefit.⁸ Additional considerations include punctal occlusion and, in severe cases, autologous serum eye drops.⁹

Clinical Pearls

- MFS must be differentiated from *facititious conjunctivitis*, also known as ocular Munchausen syndrome. In this condition, patients knowingly but surreptitiously induce injury to the ocular surface for the purpose of gaining emotional attention and/or financial ben-



Lissamine green staining representing areas of mechanical trauma to the bulbar and palpebral conjunctiva; this is considered pathognomonic for mucus fishing syndrome.

efit.¹⁰ While both MFS and factitious conjunctivitis may involve self-inflicted mechanical injury, patients with MFS generally have no ulterior motive.

- MFS may represent a form of *body-focused repetitive behavior disorder* (BFRBD). Patients engage in recurrent problematic behaviors directed toward their bodies, often without comprehending or acknowledging the result of their actions. Other conditions that carry this classification include trichotillomania (hair pulling), dermatillomania (skin picking) and onychophagy (nail biting).^{11,12}

- For patients with severe and persistent cases of MFS, psychiatric consultation and therapy may be of benefit.⁶

1. McCulley JP, Moore MB, Matoba AY. Mucus fishing syndrome. *Ophthalmology*. 1985;92(9):1262-5.

2. Slagle WS, Slagle AM, Brough GH. Mucus fishing syndrome: case report and new treatment option. *Optometry*. 2001;72(10):634-40.

3. Maskati QB. Dry eye – A review. *eJournal of Ophthalmology*. <http://www.ejournalofophthalmology.com/ejo/ejo42.html>. Accessed April 6, 2016.

4. Epstein AB, Quinn CJ. Diseases of the Conjunctiva. In Bartlett JD, Jaanus SD, eds. *Clinical Ocular Pharmacology*, Fifth Edition. St. Louis; Butterworth-Heinemann 2008:437-82.

5. Bruijic M, Kabat A, Kading D, et al. Updates in ocular surface wellness. Part 1: Ocular allergy. *Review of Optometry* 2014; 151(3):Supplement.

6. Williams D. An unusual presentation of trichotillomania and mucus fishing syndrome in a patient with obsessive compulsive disorder exacerbated by amphetamine use. Poster presented at the American Academy of Ophthalmology meeting, November 19, 2010. San Francisco, CA.

7. Ramaesh T, Ramaesh K, Riley SC, et al. Effects of N-acetylcysteine on matrix metalloproteinase-9 secretion and cell migration of human corneal epithelial cells. *Eye (Lond)*. 2012;26(8):1138-44.

8. Kaçmaz RO, Kempen JH, Newcomb C, et al. Cyclosporine for ocular inflammatory diseases. *Ophthalmology*. 2010;117(3):576-84.

9. Marshall LL, Roach JM. Treatment of dry eye disease. *Consult Pharm*. 2016;31(2):96-106.

10. Pokroy R, Marcovich A. Self-inflicted (factitious) conjunctivitis. *Ophthalmology*. 2003;110(4):790-5.

11. Roberts S, O'Connor K, Bélanger C. Emotion regulation and other psychological models for body-focused repetitive behaviors. *Clin Psychol Rev*. 2013;33(6):745-62.

12. Roberts S, O'Connor K, Aardema F, et al. The impact of emotions on body-focused repetitive behaviors: evidence from a non-treatment-seeking sample. *J Behav Ther Exp Psychiatry*. 2015;46:189-97.

GIANT PAPILLARY CONJUNCTIVITIS

Signs and Symptoms

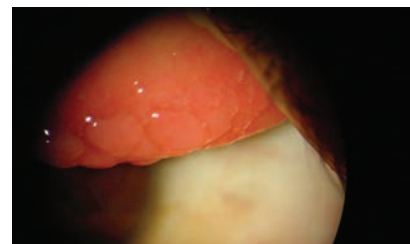Giant papillary conjunctivitis (GPC) is an inflammation initiated by micro-

trauma to the superior palpebral conjunctiva. It is associated with mechanical stimulation from either a contact lens, sutures or a prosthesis.¹⁻⁴ Characterized by the formation of large papillae on the superior tarsal conjunctiva, GPC is similar in appearance to vernal conjunctivitis but classically without significant corneal involvement.²⁻⁵ While the condition can develop secondary to chronic exposure to either a rigid gas permeable (RGP) or soft contact lens, the complication is far more predominant with the latter.^{4,7-15} Non-silicone, ionic, low-water, large-diameter, extended wear lenses and generic contact lens solutions have been implicated in higher rates of incidence.^{2,4,6-8,13,14} Poor contact lens hygiene, noncompliance with prescribed wear schedules and individual biochemistry consistent with the formation of contact lens surface deposits (jelly bumps) are known etiologies.^{2,6-8,14} Inspection of a contact lens, prosthesis or contact lens case will often yield telltale debris and deposits.^{2,6,8}

The symptoms of GPC occur after prolonged exposure to the lens or prosthesis and may exist in the absence of significant signs.¹⁻¹⁵ Patients often complain of excessive mucus in the inner canthus upon awakening and coating the lens or prosthesis as the day progresses, disrupting comfort or vision; an inordinate amount of lens or prosthesis movement; decreased comfortable wearing time; and symptoms like photophobia, itching or burning after the lens or prosthesis is removed.¹⁻¹⁵

The signs of GPC include superior conjunctival hyperemia with conjunctival tissue thickening; large papillae formation; and an increase in, and the subsequent loss of, conjunctival translucence with formation of multiple, white, elevated opacities secondary to conjunctival immune cell infiltration.^{2,12}

Papillae normally present may expand in number before enlarging to 0.5mm–1.0mm in diameter (macropapillae).²



Giant papillary conjunctivitis is an inflammation initiated by microtrauma to the superior palpebral conjunctiva.

Left untreated, the papillae can enlarge to 1.0mm–2.0mm in diameter, becoming true giant papillae.² A simultaneous immuno-allergic response may rarely produce a series of round, contiguous, gelatinous infiltrations of the limbal conjunctiva surrounding the cornea (Horner-Trantas dots).^{16,17} These can be observed in greater detail with the instillation of sodium fluorescein dye, as the characteristic round, gelatinous mounds are accentuated by the dye that settles around them. Upon eyelid eversion, thick mucus may be seen to reside in between the papillae.

Pathophysiology

GPC is a conjunctival immune response (type IV, delayed, basophil-mediated hypersensitivity with components of a type I immediate immunoglobulin [IgE] response) to the biochemical ingredients and frictional interaction of the contact lens or prosthesis.¹⁻¹⁶ The condition takes time to develop. A similar response of roughening of the superficial corneal layers and conjunctiva (papillae formation) has been observed after glaucoma filtration surgery.⁸ Here, as with a contact lens or prosthesis, the mechanical forces of the bleb adjacent to conjunctival tissues produce conjunctival thickening, inflammation and macropapillae formation.⁸

In GPC, the conjunctival epithelium becomes injured or chemically irritated. In contact with the conjunctiva-associated lymphoid tissue, chemokines and chemo-attractants signal for lymphocytes from underlying lymphoid follicles to

become active. As they respond, they gather into intraepithelial “pockets,” forming conjunctival epithelial invaginations, with papillae the resultant elevations.¹² Membranous epithelial cells (M cells), designed for the binding and translocation of antigens and or pathogens, play a key role in the pathogenesis of papillae.¹² Cellular and chemical elements of the allergic response are present in GPC, but not nearly in the numbers seen in a true type I allergic response.^{2,3,8,12} Histologically, cases of GPC feature thickened conjunctival epithelium over formed papillae with abnormal conjunctival epithelial down-growth into the conjunctival stroma.²

Management

Treating GPC begins with removal (if possible) of the offending device (e.g., discontinuation of contact lens wear or removal of a prosthesis).¹⁻¹⁶ Since GPC conjunctival tissue injury is driven by the response to aggravating agents, the recovery process begins when they are removed. Cold compresses BID may feel soothing to affected tissues and constricts blood vessels, limiting the movement and distribution of the chemical mediators of inflammation. Artificial tears can add lubrication, provide temporary ocular surface protection and flush antigens from the area.^{2,3}

If symptoms persist, adding topical antihistamines, mast cell stabilizers or topical nonsteroidal anti-inflammatory (NSAID) preparations may provide relief. Topical steroids may also be prescribed for symptomatic relief.¹⁻¹⁸ Recalcitrant cases can sometimes require topical immunomodulation, and topical tacrolimus 0.03% ointment applied to the lower fornix twice a day over two to three weeks has been shown to be effective.¹¹ In cases recalcitrant to therapy, papillae can be surgically resected with or without adjunctive cryotherapy, supported by

amniotic membrane tissue placement over the wound.^{11,19}

Once the condition has been resolved, a contact lens refit can be considered with frequent replacement lens materials and solutions known to be stubborn against the formation of GPC. A reduced wearing schedule, compliance with lens replacement timing, solution selection and hygiene must all be discussed. Scleral lenses may also have an application in cases of GPC.²⁰ Recently, research has investigated use of scleral contact lenses for keratoconic corneal surfaces at risk of compromise from ongoing vernal keratoconjunctivitis (VKC).²⁰ Similarly, eyes with a risk of shield ulceration from severe GPC may also be protected using this modality, as the eyelid inflammation is remedied with topical therapies. Scleral lenses may be considered in patients who have developed GPC from other contact lenses.

Clinical Pearls

- GPC is an inflammatory conjunctival reaction to a contact lens, suture, bleb, prosthesis or other foreign body.
- While GPC is on the continuum of allergic conjunctivitis, it is not a true allergic conjunctivitis.
- The symptoms of an evolving GPC often precede exaggerated signs.
- Contact lens or prosthetic materials, generic cleaning and disinfecting solutions, poor contact lens or prosthesis hygiene, noncompliance with wearing schedules and delayed action during foreshadowing foreboding symptoms all play a role in the development of a full-blown event.
- Treatment begins with device removal, then topical supportive therapy (cold compresses, artificial tears), topical antihistamine drops, topical NSAIDs, topical steroids; topical immunomodulatory agents can be added in a graded fashion, depending upon the condition's severity.

- If topical steroidal medications are used, intraocular pressure (IOP) must be monitored to rule out “steroid-response” glaucoma. In the event of a pressure rise, therapy must continue. A topical aqueous suppressant can help get IOP under control.

1. Ackerman S, Smith LM, Gomes PJ. Ocular itch associated with allergic conjunctivitis: latest evidence and clinical management. *Ther Adv Chronic Dis*. 2016;7(1):52-67.
2. Rubenstein JB, Jick SL. Disorders of the conjunctiva and limbus. In: Yanoff M, Duker JS. *Ophthalmology*. Mosby-Elsevier, St. Louis, MO. 2009:397-412.
3. La Rosa M, Lionetti E, Reibaldi M, et al. Allergic conjunctivitis: a comprehensive review of the literature. *Ital J Pediatr*. 2013;39(3):18.
4. Donshik PC, Ehlers WH, Ballow M. Giant papillary conjunctivitis. *Immunol Allergy Clin North Am*. 2008;28(1):83-103.
5. Pleyer U, Leonardi A. Vernal keratoconjunctivitis. *Ophthalmologie*. 2015;112(2):177-89.
6. Forister JF, Forister EF, Yeung KK. Prevalence of contact lens-related complications: UCLA contact lens study. *Eye Contact Lens*. 2009;35(4):176-80.
7. Lee SY, Kim YH, Johnson D, et al. Contact lens complications in an urgent-care population: the University of California, Los Angeles, contact lens study. *Eye Contact Lens*. 2012;38(1):49-52.
8. Bischoff G. Giant papillary conjunctivitis. *Klin Monbl Augenheilkd*. 2014;231(5):518-21.
9. Molinari JF. The clinical management of giant papillary conjunctivitis. *Am J Optom Physiol Opt*. 1981;58(10):886-91.
10. Jackson WB. Differentiating conjunctivitis of diverse origins. *Surv Ophthalmol*. 1993;38(7-8) Suppl:91-104.
11. Kymionis GD, Goldman D, Ide T, et al. Tacrolimus ointment 0.03% in the eye for treatment of giant papillary conjunctivitis. *Cornea*. 2008;27(2):228-9.
12. Zhong X, Liu H, Pu A, et al. M cells are involved in pathogenesis of human contact lens-associated giant papillary conjunctivitis. *Arch Immunol Ther Exp (Warsz)*. 2007;55(3):173-7.
13. Ehlers WH1, Donshik PC. Giant papillary conjunctivitis. *Curr Opin Allergy Clin Immunol*. 2008;8(5):445-9.
14. Donshik PC. Giant papillary conjunctivitis. *Trans Am Ophthalmol Soc*. 1994;92(6):687-744.
15. Irkeç MT, Orhan M, Erdener U. Role of tear inflammatory mediators in contact lens-associated giant papillary conjunctivitis in soft contact lens wearers. *Ocul Immunol Inflamm*. 1999;7(1):35-8.
16. Lee SW, Lee SC, Jin KH. Conjunctival inclusion cysts in long-standing chronic vernal keratoconjunctivitis. *Korean J Ophthalmol*. 2007;21(4):251-4.
17. Vichayanond P, Pacharn P, Pleyer U, Leonardi A. Vernal keratoconjunctivitis: a severe allergic eye disease with remodeling changes. *Pediatr Allergy Immunol*. 2014;25(4):314-22.
18. Wilson DJ, Schutte SM, Abel SR. Comparing the efficacy of ophthalmic nsoids in common indications: a literature review to support cost-effective prescribing. *Ann Pharmacother*. 2015;49(6):727-34.
19. Guo P, Khairkhan A, Zhou WW, Qin L, et al. Surgical resection and amniotic membrane transplantation for treatment of refractory giant papillae in vernal keratoconjunctivitis. *Cornea*. 2013;32(6):816-20.
20. Rathi VM1, Sudharman Mandathara P, et al. Fluid-filled scleral contact lenses in vernal keratoconjunctivitis. *Eye Contact Lens*. 2012;38(3):203-6.

For allergic conjunctivitis¹

THE POWER TO CALM THE ITCH



**BEPREVE® — FIRST-LINE, YEAR-ROUND,
WITH BROAD-SPECTRUM ALLERGEN COVERAGE**

INDICATION AND USAGE

BEPREVE® (bepotastine besilate ophthalmic solution) 1.5% is a histamine H₁ receptor antagonist indicated for the treatment of itching associated with allergic conjunctivitis.

IMPORTANT SAFETY INFORMATION

- BEPREVE® is contraindicated in patients with a history of hypersensitivity reactions to bepotastine or any of the other ingredients.
- BEPREVE® is for topical ophthalmic use only. To minimize risk of contamination, do not touch the dropper tip to the eyelids or to any surface. Keep the bottle closed when not in use.
- BEPREVE® should not be used to treat contact lens-related irritation. Remove contact lens prior to instillation of BEPREVE®. Lenses may be reinserted 10 minutes after BEPREVE® administration.
- The most common adverse reaction occurring in approximately 25% of patients was a mild taste following instillation. Other adverse reactions occurring in 2%-5% of patients were eye irritation, headache, and nasopharyngitis.

Please see the accompanying full Prescribing Information for BEPREVE® on the following page.

Reference: 1. BEPREVE [package insert]. Tampa, FL: Bausch & Lomb Incorporated; 2012.

BAUSCH + LOMB

For product-related questions and concerns, call 1-800-323-0000 or visit www.bausch.com.

BEPREVE is a trademark of Bausch & Lomb Incorporated or its affiliates.

© Bausch & Lomb Incorporated. BEP.0014.USA.16

Made by the respected eye-care
specialists at **BAUSCH + LOMB**

BEPREVE®
(bepotastine besilate
ophthalmic solution) 1.5%

BEPREVE® (bepotastine besilate ophthalmic solution) 1.5%

HIGHLIGHTS OF PRESCRIBING INFORMATION

These highlights do not include all the information needed to use BEPREVE® (bepotastine besilate ophthalmic solution) 1.5% safely and effectively. See full prescribing information for BEPREVE®.

BEPREVE® (bepotastine besilate ophthalmic solution) 1.5%
Initial U.S. Approval: 2009

RECENT MAJOR CHANGES

Contraindications (4) 06/2012

INDICATIONS AND USAGE

BEPREVE® is a histamine H₁ receptor antagonist indicated for the treatment of itching associated with allergic conjunctivitis. (1)

DOSAGE AND ADMINISTRATION

Instill one drop into the affected eye(s) twice a day (BID). (2)

DOSAGE FORMS AND STRENGTHS

Solution containing bepotastine besilate, 1.5%. (3)

CONTRAINDICATIONS

Hypersensitivity to any component of this product. (4)

FULL PRESCRIBING INFORMATION: CONTENTS*

- 1 INDICATIONS AND USAGE
- 2 DOSAGE AND ADMINISTRATION
- 3 DOSAGE FORMS AND STRENGTHS
- 4 CONTRAINDICATIONS
- 5 WARNINGS AND PRECAUTIONS
 - 5.1 Contamination of Tip and Solution
 - 5.2 Contact Lens Use
 - 5.3 Topical Ophthalmic Use Only
- 6 ADVERSE REACTIONS
 - 6.1 Clinical Trial Experience
 - 6.2 Post-Marketing Experience
- 8 USE IN SPECIFIC POPULATIONS
 - 8.1 Pregnancy
 - 8.3 Nursing Mothers
 - 8.4 Pediatric Use
 - 8.5 Geriatric Use

FULL PRESCRIBING INFORMATION

1 INDICATIONS AND USAGE

BEPREVE® (bepotastine besilate ophthalmic solution) 1.5% is a histamine H₁ receptor antagonist indicated for the treatment of itching associated with signs and symptoms of allergic conjunctivitis.

2 DOSAGE AND ADMINISTRATION

Instill one drop of BEPREVE into the affected eye(s) twice a day (BID).

3 DOSAGE FORMS AND STRENGTHS

Topical ophthalmic solution containing bepotastine besilate 1.5%.

4 CONTRAINDICATIONS

Bepreve is contraindicated in patients with a history of hypersensitivity reactions to bepotastine or any of the other ingredients [see *Adverse Reactions* (6.2)].

5 WARNINGS AND PRECAUTIONS

5.1 Contamination of Tip and Solution

To minimize contaminating the dropper tip and solution, care should be taken not to touch the eyelids or surrounding areas with the dropper tip of the bottle. Keep bottle tightly closed when not in use.

5.2 Contact Lens Use

Patients should be advised not to wear a contact lens if their eye is red. BEPREVE should not be used to treat contact lens-related irritation.

BEPREVE should not be instilled while wearing contact lenses. Remove contact lenses prior to instillation of BEPREVE. The preservative in BEPREVE, benzalkonium chloride, may be absorbed by soft contact lenses. Lenses may be reinserted after 10 minutes following administration of BEPREVE.

5.3 Topical Ophthalmic Use Only

BEPREVE is for topical ophthalmic use only.

6 ADVERSE REACTIONS

6.1 Clinical Trials Experience

Because clinical trials are conducted under widely varying conditions, adverse reaction rates observed in the clinical trials of a drug cannot be directly compared to rates in the clinical trials of another drug and may not reflect the rates observed in clinical practice.

WARNINGS AND PRECAUTIONS

- To minimize the risk of contamination, do not touch dropper tip to any surface. Keep bottle tightly closed when not in use. (5.1)
- BEPREVE should not be used to treat contact lens-related irritation. (5.2)
- Remove contact lenses prior to instillation of BEPREVE. (5.2)

ADVERSE REACTIONS

The most common adverse reaction occurring in approximately 25% of patients was a mild taste following instillation. Other adverse reactions which occurred in 2-5% of subjects were eye irritation, headache, and nasopharyngitis. (6)

To report SUSPECTED ADVERSE REACTIONS, contact Bausch & Lomb Incorporated, at 1-800-323-0000, or FDA at 1-800-FDA-1088 or www.fda.gov/medwatch.

See 17 for PATIENT COUNSELING INFORMATION

Revised: 10/2012

11 DESCRIPTION

12 CLINICAL PHARMACOLOGY

- 12.1 Mechanism of Action
- 12.3 Pharmacokinetics

13 NONCLINICAL TOXICOLOGY

- 13.1 Carcinogenesis, Mutagenesis and Impairment of Fertility

14 CLINICAL STUDIES

16 HOW SUPPLIED/STORAGE AND HANDLING

- 17.1 Topical Ophthalmic Use Only
- 17.2 Sterility of Dropper Tip
- 17.3 Concomitant Use of Contact Lenses

*Sections or subsections omitted from the full prescribing information are not listed

The most common reported adverse reaction occurring in approximately 25% of subjects was a mild taste following instillation. Other adverse reactions occurring in 2-5% of subjects were eye irritation, headache, and nasopharyngitis.

6.2 Post Marketing Experience

Hypersensitivity reactions have been reported rarely during the post-marketing use of BEPREVE. Because these reactions are reported voluntarily from a population of unknown size, it is not always possible to reliably estimate their frequency or establish a causal relationship to drug exposure. The hypersensitivity reactions include itching, body rash, and swelling of lips, tongue and/or throat.

8 USE IN SPECIFIC POPULATIONS

8.1 Pregnancy

Pregnancy Category C: Teratogenicity studies have been performed in animals. Bepotastine besilate was not found to be teratogenic in rats during organogenesis and fetal development at oral doses up to 200 mg/kg/day (representing a systemic concentration approximately 3,300 times that anticipated for topical ocular use in humans), but did show some potential for causing skeletal abnormalities at 1,000 mg/kg/day. There were no teratogenic effects seen in rabbits at oral doses up to 500 mg/kg/day given during organogenesis and fetal development (>13,000 times the dose in humans on a mg/kg basis). Evidence of infertility was seen in rats given oral bepotastine besilate 1,000 mg/kg/day; however, no evidence of infertility was observed in rats given 200 mg/kg/day (approximately 3,300 times the topical ocular use in humans). The concentration of radiolabeled bepotastine besilate was similar in fetal liver and maternal blood plasma following a single 3 mg/kg oral dose. The concentration in other fetal tissues was one-third to one-tenth the concentration in maternal blood plasma.

An increase in stillborns and decreased growth and development were observed in pups born from rats given oral doses of 1,000 mg/kg/day during perinatal and lactation periods. There were no observed effects in rats treated with 100 mg/kg/day.

There are no adequate and well-controlled studies of bepotastine besilate in pregnant

women. Because animal reproduction studies are not always predictive of human response, BEPREVE® (bepotastine besilate ophthalmic solution) 1.5% should be used during pregnancy only if the potential benefit justifies the potential risk to the fetus.

8.3 Nursing Mothers

Following a single 3 mg/kg oral dose of radiolabeled bepotastine besilate to nursing rats 11 days after delivery, the maximum concentration of radioactivity in milk was 0.40 mcg-eq/mL 1 hour after administration; at 48 hours after administration the concentration was below detection limits. The milk concentration was higher than the maternal blood plasma concentration at each time of measurement.

It is not known if bepotastine besilate is excreted in human milk. Caution should be exercised when BEPREVE (bepotastine besilate ophthalmic solution) 1.5% is administered to a nursing woman.

8.4 Pediatric Use

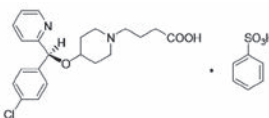
Safety and efficacy of BEPREVE (bepotastine besilate ophthalmic solution) 1.5% have not been established in pediatric patients under 2 years of age. Efficacy in pediatric patients under 10 years of age was extrapolated from clinical trials conducted in pediatric patients greater than 10 years of age and from adults.

8.5 Geriatric Use

No overall difference in safety or effectiveness has been observed between elderly and younger patients.

11 DESCRIPTION

BEPREVE (bepotastine besilate ophthalmic solution) 1.5% is a sterile, topically administered drug for ophthalmic use. Each mL of BEPREVE contains 15 mg bepotastine besilate. Bepotastine besilate is designated chemically as (+)-4-[(S)-p-chloro-alpha-2-pyridylbenzyl]oxy]-1-piperidine butyric acid monobenzenesulfonate. The chemical structure for bepotastine besilate is:



Bepotastine besilate is a white or pale yellowish crystalline powder. The molecular weight of bepotastine besilate is 547.06 daltons. BEPREVE® ophthalmic solution is supplied as a sterile, aqueous 1.5% solution, with a pH of 6.8. The osmolality of BEPREVE (bepotastine besilate ophthalmic solution) 1.5% is approximately 290 mOsm/kg.

Each mL of BEPREVE® (bepotastine besilate ophthalmic solution) 1.5% contains:

Active: Bepotastine besilate 15 mg (equivalent to 10.7 mg bepotastine)

Preservative: benzalkonium chloride 0.005%

Inactives: monobasic sodium phosphate dihydrate, sodium chloride, sodium hydroxide to adjust pH, and water for injection, USP.

12 CLINICAL PHARMACOLOGY

12.1 Mechanism of Action

Bepotastine is a topically active, direct H₁-receptor antagonist and an inhibitor of the release of histamine from mast cells.

12.3 Pharmacokinetics

Absorption: The extent of systemic exposure to bepotastine following topical ophthalmic administration of bepotastine besilate 1% and 1.5% ophthalmic solutions was evaluated in 12 healthy adults. Following one drop of 1% or 1.5% bepotastine besilate ophthalmic solution to both eyes four times daily (QID) for seven days, bepotastine plasma concentrations peaked at approximately one to two hours post-instillation. Maximum plasma concentration for the 1% and 1.5% strengths were 5.1 ± 2.5 ng/mL and 7.3 ± 1.9 ng/mL, respectively. Plasma concentration at 24 hours post-instillation were below the quantifiable limit (2 ng/mL) in 11/12 subjects in the two dose groups.

Distribution: The extent of protein binding of bepotastine is approximately 55% and independent of bepotastine concentration.

Metabolism: *In vitro* metabolism studies with human liver microsomes demonstrated that bepotastine is minimally metabolized by CYP450 isozymes.

In vitro studies demonstrated that bepotastine besilate does not inhibit the metabolism of various

cytochrome P450 substrate via inhibition of CYP3A4, CYP2C9, and CYP2C19. The effect of bepotastine besilate on the metabolism of substrates of CYP1A2, CYP2C8, CYP2D6 was not studied. Bepotastine besilate has a low potential for drug interaction via inhibition of CYP3A4, CYP2C9, and CYP2C19.

Excretion: The main route of elimination of bepotastine besilate is urinary excretion (with approximately 75-90% excreted unchanged in urine).

13 NONCLINICAL TOXICOLOGY

13.1 Carcinogenesis, Mutagenesis and Impairment of Fertility

Long-term dietary studies in mice and rats were conducted to evaluate the carcinogenic potential of bepotastine besilate. Bepotastine besilate did not significantly induce neoplasms in mice receiving a nominal dose of up to 200 mg/kg/day for 21 months or rats receiving a nominal dose of up to 97 mg/kg/day for 24 months. These dose levels represent systemic exposures approximating 350 and 200 times that achieved with human topical ocular use. The no observable adverse effect levels for bepotastine besilate based on nominal dose levels in carcinogenicity tests were 18.7 to 19.9 mg/kg/day in mice and 9.6 to 9.8 mg/kg/day in rats (representing exposure margins of approximately 60 and 20 times the systemic exposure anticipated for topical ocular use in humans).

There was no evidence of genotoxicity in the Ames test, in CHO cells (chromosome aberrations), in mouse hepatocytes (unscheduled DNA synthesis), or in the mouse micronucleus test.

When oral bepotastine was administered to male and female rats at doses up to 1,000 mg/kg/day, there was a slight reduction in fertility index and surviving fetuses. Infertility was not seen in rats given 200 mg/kg/day oral bepotastine besilate (approximately 3,300 times the systemic concentration anticipated for topical ocular use in humans).

14 CLINICAL STUDIES

Clinical efficacy was evaluated in 2 conjunctival allergen challenge (CAC) studies (237 patients). BEPREVE (bepotastine besilate ophthalmic solution) 1.5% was more effective than its vehicle for relieving ocular itching induced by an ocular allergen challenge, both at a CAC 15 minutes post-dosing and a CAC 8 hours post dosing of BEPREVE.

The safety of BEPREVE was evaluated in a randomized clinical study of 861 subjects over a period of 6 weeks.

16 HOW SUPPLIED/STORAGE AND HANDLING

BEPREVE® (bepotastine besilate ophthalmic solution) 1.5% is supplied in a white low density polyethylene plastic squeeze bottle with a white controlled dropper tip and a white polypropylene cap in the following size:

- 5 mL (NDC 24208-629-02)
- 10 mL (NDC 24208-629-01)

STORAGE

Store at 15° – 25°C (59° – 77°F).

17 PATIENT COUNSELING INFORMATION

17.1 Topical Ophthalmic Use Only

For topical ophthalmic administration only.

17.2 Sterility of Dropper Tip

Patients should be advised to not touch dropper tip to any surface, as this may contaminate the contents.

17.3 Concomitant Use of Contact Lenses

Patients should be advised not to wear a contact lens if their eye is red. Patients should be advised that BEPREVE should not be used to treat contact lens-related irritation.

Patients should also be advised to remove contact lenses prior to instillation of BEPREVE. The preservative in BEPREVE, benzalkonium chloride, may be absorbed by soft contact lenses. Lenses may be reinserted after 10 minutes following administration of BEPREVE.

Manufactured by: Bausch & Lomb Incorporated
Tampa, FL 33637
Under license from:
Senju Pharmaceutical Co., Ltd.
Osaka, Japan 541-0046
®/TM are trademarks of Bausch & Lomb Incorporated or its affiliates
© 2012 Bausch & Lomb Incorporated.

ACANTHAMOEBA KERATITIS

Signs and Symptoms

Corneal infection by *Acanthamoeba* is a rare occurrence. Patients are most often soft contact lens wearers, although this is not universal; additional historical elements may include recent ocular trauma and exposure to soil or contaminated water.¹⁻⁹ *Acanthamoeba* keratitis may also be seen following ocular surgery.^{1,10,11}

The onset of *Acanthamoeba* keratitis is typically insidious rather than acute, with a unilateral red eye being the characteristic presentation. Pain is the most commonly reported symptom, often in tandem with photophobia, tearing and blepharospasm. In early stages of infection, pain is often severe and seemingly disproportionate to clinical appearance; however, patients may present with little or no pain, particularly as the disease progresses.^{1,3,7,12} Reduced visual acuity is common and directly related to the degree of corneal compromise, which is in turn related to the stage of the disease.

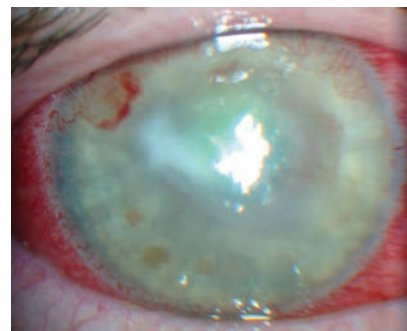
Biomicroscopy reveals generalized conjunctival hyperemia with a propensity for limbitis—an inflammation of the corneoscleral junction. A wide array of corneal manifestations can be seen with *Acanthamoeba* keratitis, depending upon the stage of the infection. Early epithelial involvement may take the form of punctate keratopathy, pseudodendritic keratopathy, microcystic edema and/or epithelial infiltrates.^{1,3,7,13} As the infection progresses, additional corneal findings could include subepithelial and perineural infiltrates. The finding of perineural infiltrates (also known as *radial perineuritis* or *radial keratoneuritis*) is considered the most pathognomonic sign for mid-stage *Acanthamoeba* keratitis, noted in up to 63% of cases.³ Stromal ring infiltrate has been described as the classic sign of *Acanthamoeba* infection. This is true with regard to late-stage disease, but overall ring infiltrate is noted in less than 20% of patients.^{1,3,13}

Other late-stage findings include frank corneal ulceration, disciform corneal edema, endothelial plaques and abscess formation. At this stage, anterior uveitis is also common, often with associated hypopyon. Complications in untreated cases may include corneal melt, corneal perforation, scleritis, cataract and glaucoma.³

Pathophysiology

Acanthamoeba are ubiquitous organisms, inhabiting virtually all sources of water, including lakes, rivers, oceans, chlorinated swimming pools, hot tubs and domestic tap water.⁷ In addition, these pathogens can be borne in soil, dust, sewage and even air.⁷ *Acanthamoeba* are resistant to cold, surviving at temperatures as low as -20°C (-4°F); however, they are typically susceptible to heat above 42°C (107°F).⁷ Under adverse conditions, *Acanthamoeba* transition from their motile trophozoite phase to a cystic phase, in which they can survive and maintain their virulence for years.⁵ Eight species of *Acanthamoeba* have been associated with keratitis, but *Acanthamoeba castellanii* and *Acanthamoeba polyphaga* are by far the most common.^{1,3}

The critical first step in the pathogenesis of *Acanthamoeba* keratitis, as with all corneal infections, is introduction and adhesion of the microbe to the ocular surface. Contact lenses are believed to act as a mechanical vector, aiding the transmission of *Acanthamoeba* to the cornea from contaminated media.⁸ In addition, contact lenses induce microtrauma to the corneal epithelium, allowing for easier access by these pathogens.⁹ Direct injury to the cornea (e.g., corneal abrasion) and concurrent or subsequent exposure to contaminated materials are other potential avenues for infection. Pathogenic *Acanthamoeba* appears to be mediated by mannose-binding protein (MBP), which facilitates adhesion of the organism to the epithelium.^{4,14} Once bound, MBP directs a potent cytopathic effect on the



Ring infiltrate, a hallmark late-stage feature of *Acanthamoeba* keratitis, can be seen here.

cornea. Release of multiple proteases allows for degradation of the epithelial basement membrane and penetration of the organism deep into the stroma, causing cell death via cytolysis, phagocytosis and apoptosis.^{4,9,15} Trophozoites then tend to cluster around corneal nerves, resulting in clinically observed perineuritis.^{9,13} Inflammatory and infiltrative processes ensue, producing the myriad of signs discussed previously. Unfortunately, this response is incapable of fully eradicating *Acanthamoeba* infection in the immune-privileged cornea; thus, aggressive medical therapy is required.

Management

Definitive diagnosis of *Acanthamoeba* infection can be difficult and time-consuming. It requires tissue samples from the involved eye that, despite multiple diagnostic techniques, yield a high number of false-negative results. Typical testing involves the staining and culture of corneal scrapings. Smear samples can be evaluated by microscopy using various stains, although the most common today appear to be acridine orange and calcofluor white.^{1,5,9} Corneal cultures are typically performed using non-nutrient agar overlaid with *Escherichia coli* or *Enterobacter aerogenes*.^{1,3,5,7,9} These cultures are usually evaluated daily for up to 10 days, as it may take that long to observe a definitive yield.⁷ Still, the effectiveness of isolating *Acanthamoeba* in cultures is reportedly only 30% to 60%.^{3,9}

Polymerase chain reaction (PCR) is sometimes used in the analysis of corneal samples. PCR is useful for detecting pathogens that are difficult to culture in vitro, or which require a long cultivation period such as *Acanthamoeba*.¹⁶ Unfortunately, the process is highly technical and expensive, and, consequently, not widely available outside of specialized tertiary care centers or academic medical institutions. Confocal microscopy enables noninvasive, real-time corneal evaluation at the cellular level, and is capable of demonstrating cysts and trophozoites in infected corneas.^{1,5} While confocal microscopy is an important addition to the diagnosis of *Acanthamoeba* keratitis, cost and lack of standardized interpretation preclude its widespread use.¹

Therapeutic management of *Acanthamoeba* keratitis is complex and challenging. Trophozoites are responsive to a variety of medications, including certain antibiotics, antiseptics, antifungals, antiprotozoals, antivirals and antineoplastic drugs.^{1,3,5,9,12} *Acanthamoeba* cysts, though, are susceptible to just a few select agents, particularly the biguanides and diamidines.^{1,3,5,9,12} The treating physicians will often initiate two or more concurrent medications at the outset of therapy. A typical starting regimen involves a biguanide, such as polyhexamethaline biguanide (PHMB) 0.02% or chlorhexidine 0.02%, in combination with a diamidine, such as propamidine isethionate (Brolene, Sanofi) 0.1% or hexamidine 0.1%. These are dosed every hour around the clock for the first 48 hours following corneal debridement, then reduced to hourly (daytime only) for one or more weeks.^{3,9} Corneal toxicity is not uncommon, particularly with the diamidines, and should be a consideration in discontinuation or modification of the regimen.^{5,9} Oral itraconazole is sometimes advocated as adjunctive therapy, although this is not universal.^{3,7,10} In general, the goal is to reduce administration of topical medications to approxi-

mately four times a day, but therapy may be required for months to ensure eradication of encysted organisms.⁹

As with most cases of microbial keratitis, topical corticosteroid use in *Acanthamoeba* keratitis is highly controversial, particularly during the active phase. Evidence exists that corticosteroids may accelerate proliferation of trophozoites, increasing cytopathic effects.¹⁷ Also, steroids appear to inhibit macrophage phagocytosis and the destruction of *Acanthamoeba* cysts by neutrophils.¹⁸ A recent study linked use of topical corticosteroids prior to definitive diagnosis of *Acanthamoeba* keratitis with a fourfold increase in the likelihood of suboptimal outcome (VA <20/80, corneal perforation or need for keratoplasty).¹⁹ However, another study showed that use of topical steroids in conjunction with antiamebic therapy did not increase the risk of suboptimal outcome.²⁰

The current literature consensus on a protocol appears to be avoidance of topical corticosteroids for at least two weeks after diagnosis and initiation of aggressive antiamebic treatment; if, at that point, significant inflammatory complications are present (e.g., anterior scleritis, severe pain, indolent ulcers, corneal inflammation and/or anterior uveitis), a steroid may be added.^{1,3} Likewise, authors recommend that antiamebic therapy be continued for several weeks after steroids are stopped.^{3,5,9}

Clinicians need to be watchful for persistent epithelial defects in *Acanthamoeba* keratitis, which may be indicative of drug toxicity, concurrent herpes infection, bacterial superinfection or resistant *Acanthamoeba* strains.^{1,3,9} Repeating cultures can help rule out the latter two of these etiologies. In cases unresponsive to medical therapy alone, lamellar keratectomy of the necrotic tissue may be a beneficial therapeutic adjunct.³ Published case reports also suggest that corneal collagen crosslinking and phototherapeutic keratectomy may be of benefit in the

management of *Acanthamoeba* keratitis, but, to date, no large-scale prospective clinical studies have examined either modality.²¹⁻²⁵ While penetrating keratoplasty (PK) is no longer considered a viable means of eradicating *Acanthamoeba* from the cornea, it remains a therapeutic consideration for corneal perforation unresponsive to repeated gluing, significant cataract or severe corneal abscess.^{3,9} PK may also be employed in quiescent eyes after treatment has been completed to address scarred or irregular corneas as a means of improving vision.⁹

The prognosis for individuals with *Acanthamoeba* keratitis depends largely on the severity of the disease at presentation and the amount of time prior to initiating therapy.^{3,9,26,27} Initial visual acuity below 20/50 and stromal infiltration is associated with a worse prognosis.²⁶ Likewise, a delay in initiating antiamebic therapy of more than three weeks is associated with a worse prognosis.²⁷ In a series of 229 cases seen over 12 years at Moorfields Eye Hospital, 65.5% achieved final visual acuity of 20/20 or better in the involved eye, and 96% overall were 20/40 or better following successful treatment.^{3,28,29}

Clinical Pearls

- The primary food source for *Acanthamoeba* is bacteria, including normal ocular flora such as *Staphylococcus epidermidis* and *S. aureus*. Hence, these organisms can persist indefinitely in a bacteria-rich ocular environment. For this reason, bacterial corneal ulcers are always susceptible to superinfection by *Acanthamoeba* in at-risk patients, particularly contact lens wearers.

- Although rare, *Acanthamoeba* keratitis should be suspected in several specific instances: cases involving contact lens wear, particularly when improper lens care and hygiene are apparent; corneal trauma associated with soil or unclean water sources; patient reports of pain that is extreme and disproportionate to the

corneal presentation; appearance of radial perineuritis and/or stromal ring infiltrate; and persistent corneal infections that do not respond to seemingly appropriate, conventional therapy.

- *Acanthamoeba* keratitis can present initially as a pseudodendritic keratitis similar to herpes simplex keratitis, with one critical exception: the classic “terminal end bulbs” seen in herpetic keratitis are characteristically absent.

- *Acanthamoeba* keratitis is partially amenable to non-protozoan treatments, including some topical antibiotics (e.g., neomycin) and antiviral agents. These formulations, as well as the preservatives that they contain, create a hostile environment for the microbe; in response, *Acanthamoeba* will encyst and become dormant. While symptoms and signs may improve temporarily, the keratitis waxes and wanes until definitive anti-amoebic therapy is prescribed.

- Cycloplegia is another component in mitigating pain and associated uveitis.

- Graffi S, Peretz A, Jabaly H, et al. *Acanthamoeba* keratitis. *Isr Med Assoc J*. 2013;15(4):182-5.
- Joslin CE, Tu EY, McMahon TT, et al. Infectious disease of the external eye: Microbial and parasitic infections. In: Skuta GL, Cantor LB, Weiss JS, eds. *External disease and cornea*, Volume 8. San Francisco: American Academy of Ophthalmology, 2011: 167-9.
- Dart JK, Saw VP, Kilvington S. *Acanthamoeba* keratitis: diagnosis and treatment update 2009. *Am J Ophthalmol*. 2009;148(4):487-499.e2.
- Panjwani N. Pathogenesis of *acanthamoeba* keratitis. *Ocul Surf*. 2010;8(2):70-9.
- Lorenzo-Morales J, Khan NA, Walochnik J. An update on *Acanthamoeba* keratitis: diagnosis, pathogenesis and treatment. *Parasite*. 2015;22:10.
- Joslin CE, Tu EY, Shoff ME, et al. The association of contact lens solution use and *Acanthamoeba* keratitis. *Am J Ophthalmol*. 2007;144(2):169-180.
- Chong EM, Dana MR. *Acanthamoeba* keratitis. *Int Ophthalmol Clin*. 2007;47(2):33-46.
- Beattie TK, Tomlinson A, McFadyen AK. Attachment of *Acanthamoeba* to first- and second-generation silicone hydrogel contact lenses. *Ophthalmology*. 2006;113(1):117-25.
- Maycock NJ, Jayaswal R. Update on *Acanthamoeba* keratitis: Diagnosis, treatment, and outcomes. *Cornea*. 2016;35(5):713-20.
- Kaldawy RM, Sutphin JE, Wagoner MD. *Acanthamoeba* keratitis after photorefractive keratectomy. *J Cataract Refract Surg*. 2002;28(2):364-8.
- Balasubramanya R, Garg P, Sharma S, et al. *Acanthamoeba* keratitis after LASIK. *J Refract Surg*. 2006;22(6):616-7.
- Alkharashi M, Lindsley K, Law HA, et al. Medical interventions for *acanthamoeba* keratitis. *Cochrane Database Syst Rev*. 2015;2:CD010792.

- Patel DV, McGhee CN. *Acanthamoeba* keratitis: a comprehensive photographic reference of common and uncommon signs. *Clin Experiment Ophthalmol*. 2009;37(2):232-8.
- Garate M, Marchant J, Cubillos I, et al. In vitro pathogenicity of *Acanthamoeba* is associated with the expression of the mannose-binding protein. *Invest Ophthalmol Vis Sci*. 2006;47(3):1056-62.
- Clarke DW, Niederkorn JY. The pathophysiology of *Acanthamoeba* keratitis. *Trends Parasitol*. 2006;22(4):175-80.
- Yamamoto Y. PCR in diagnosis of infection: detection of bacteria in cerebrospinal fluids. *Clin Diagn Lab Immunol*. 2002;9(3):508-14.
- McClellan K, Howard K, Niederkorn JY, et al. Effect of steroids on *Acanthamoeba* cysts and trophozoites. *Invest Ophthalmol Vis Sci*. 2001;42(12):2885-93.
- Hurt M, Howard K, Cavanagh HD, et al. Tear IgA and serum IgG antibodies against *Acanthamoeba* in patients with *Acanthamoeba* keratitis. *Cornea*. 2001;20(6):622-7.
- Robaei D, Carnt N, Minassian DC, et al. The impact of topical corticosteroid use before diagnosis on the outcome of *Acanthamoeba* keratitis. *Ophthalmology*. 2014;121(7):1383-8.
- Carnt N, Robaei D, Watson SL, et al. The impact of topical corticosteroids used in conjunction with antimicrobial therapy on the outcome of *Acanthamoeba* keratitis. *Ophthalmology*. 2016;123(5):984-90.
- Garduño-Vieyra L, Gonzalez-Sanchez CR, Hernandez-Da Mota SE. Ultraviolet-A light and riboflavin therapy for *Acanthamoeba* keratitis: a case report. *Case Rep Ophthalmol*. 2011;2(2):291-5.
- Khan YA, Kashiwabuchi RT, Martins SA, et al. Riboflavin and ultraviolet light A therapy as an adjuvant treatment for medically refractive *Acanthamoeba* keratitis: report of 3 cases. *Ophthalmology*. 2011;118(2):324-31.
- Chan E, Snibson GR, Sullivan L. Treatment of infectious keratitis with riboflavin and ultraviolet-A irradiation. *J Cataract Refract Surg*. 2014;40(11):1919-25.
- Taenaka N, Fukuda M, Hibino T, et al. Surgical therapies for *Acanthamoeba* keratitis by phototherapeutic keratectomy and deep lamellar keratoplasty. *Cornea*. 2007;26(7):876-9.
- Kandori M, Inoue T, Shimabukuro M, et al. Four cases of *Acanthamoeba* keratitis treated with phototherapeutic keratectomy. *Cornea*. 2010;29(10):1199-202.
- Chew HF, Yildiz EH, Hammersmith KM, et al. Clinical outcomes and prognostic factors associated with *Acanthamoeba* keratitis. *Cornea*. 2011;30(4):435-41.
- Clairhout I, Goegebuer A, van Den BC, et al. Delay in diagnosis and outcome of *Acanthamoeba* keratitis. *Graefes Arch Clin Exp Ophthalmol*. 2004;242(8):648-53.
- Radford CF, Lehmann OJ, Dart JK. *Acanthamoeba* keratitis: multicentre survey in England 1992–1996. National *Acanthamoeba* Keratitis Study Group. *Br J Ophthalmol*. 1998; 82(12):1387-92.
- Bacon AS, Frazer DG, Dart JK, et al. A review of 72 consecutive cases of *acanthamoeba* keratitis, 1984–1992. *Eye (Lond)*. 1993;7 (Pt 6):719-25.

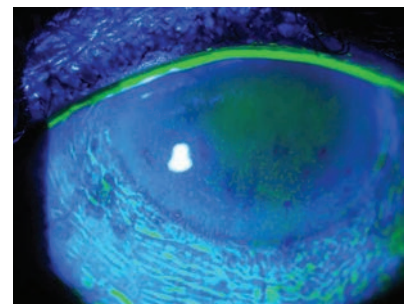
TOXIC KERATOCONJUNCTIVITIS

Signs and Symptoms

Toxic keratoconjunctivitis (TKC), sometimes referred to as *chemical keratitis* or *toxic follicular conjunctivitis*, describes a condition in which the ocular surface is exposed to a noxious substance either acutely or chronically, with resultant deleterious effects to the structure and function of these tissues.¹⁻⁶ Often,

patients will have knowledge of the offending agent, reporting a history of inadvertent (e.g., splashing of a cleaning agent) or purposeful (e.g., instillation of a topical medication) ocular contact. Other patients may present with an unexplained painful red eye, oblivious to a causative vector until the history is explored. TKC may be observed unilaterally or bilaterally, and can affect any individual regardless of age, race or gender. Patients commonly present with some degree of ocular discomfort, which may manifest as itching, burning, photophobia, foreign body sensation or discrete pain. Blurred vision and excessive tearing are also frequently reported.

TKC may impact the cornea, bulbar conjunctiva and/or palpebral conjunctiva, and occasionally presents with collateral involvement of the eyelids and adnexa.¹ Characteristic conjunctival manifestations include hyperemia, often with chemosis (conjunctival edema). In some cases, where the exposure is diffuse, the palpebral conjunctiva swells 360 degrees around the cornea, mimicking a watch's bezel around the crystal. This is sometimes referred to as “watch glass” edema. Papillary and/or follicular reactions may also be seen, but typically only in cases involving chronic exposure to irritant substances.⁷ The classic corneal finding in TKC is a coarse punctate epitheliopathy that stains brightly with sodium



Toxic keratoconjunctivitis caused by generic difluprednate drops. TKC may impact the cornea, bulbar conjunctiva and/or palpebral conjunctiva, and sometimes presents with collateral involvement of the eyelids and adnexa.

fluorescein.^{2,4,5} Filamentary keratopathy or pseudodendrites may also be seen.^{2,4} Pseudodendrites are most classically associated with herpes zoster ophthalmicus, so the history and presentation of the lids and adnexa are important features for differential diagnosis. More prolonged or severe exposure can lead to the development of persistent epithelial defects, corneal edema, ulcerative keratitis, stromal melting and corneal perforation.^{1,2,8} The lids and adnexa occasionally demonstrate a hypersensitivity reaction similar to atopic dermatitis, with eczema, edema and erythema of the periocular skin.¹

Pathophysiology

The pathophysiology of TKC is complex, involving a variety and, in some cases, a combination of mechanisms.^{1,4} The type of response may differ depending upon the nature of the substance or solution involved. Direct cytotoxicity to the cornea and/or conjunctiva often results from extremes in pH or osmolarity; in rare instances, exposure can induce a photosensitivity reaction.¹ Some organic substances contain bioactive proteins and proteolytic enzymes, which can have significant local destructive effects at the level of the epithelium or stroma.⁹ Direct toxic effects are usually seen upon initial contact or within hours thereafter. Exposure to toxic substances may also evoke an inflammatory response via immunologic pathways.¹ This may take the form of either a type I hypersensitivity (initiated by allergen binding and degranulation of mast cells), type II to III hypersensitivity reaction (characterized by antibody-specific and immune-complex mediated effects) or a type IV hypersensitivity reaction, also known as delayed or adaptive hypersensitivity reaction (involving T-lymphocytes and lymphokines that become activated when a sufficient volume of antigen stimulates the system). A type IV reaction may take one exposure or 100 exposures.^{1,10}

Topical medications and the preserva-

tives used to formulate them represent the most common source of TKC (the term *medicamentosa* is sometimes used to describe this phenomenon). While we collectively refer to these reactions as toxic, in many cases the pathogenic event is primarily immune-mediated via type I or type IV hypersensitivity reactions, rather than the result of direct toxicity.^{1,3,11-13} While a broad range of topical agents may induce TKC, a few are well known in this capacity, including: aminoglycoside antibiotics (especially neomycin and gentamicin), fluoroquinolone antibiotics (particularly ciprofloxacin), intraocular pressure-lowering medications (especially timolol and dorzolamide), nonsteroidal anti-inflammatory drugs (NSAIDs, particularly diclofenac) and topical anesthetics, though typically only in instances where they are overused or abused.¹¹⁻¹⁵ Ophthalmic preservatives such as thimerosal and benzalkonium chloride (BAK) have also been widely implicated in TKC.^{11,14,16} While thimerosal has been removed from most commercially available ocular medications and contact lens solutions in the United States, a few products still incorporate this potentially toxic, mercurial compound (e.g., Viroptic [Pfizer] and Neosporin ophthalmic solution [Monarch Pharmaceuticals]).^{17,18} BAK is presently the most common preservative employed in ophthalmic medications, despite its recognized potential for hypersensitivity.¹¹ Using an animal model, researchers have shown that BAK breaks down rabbit corneal epithelial barrier function in a dose-dependent fashion; with high concentrations and/or prolonged exposure, it induces stromal edema and endothelial cell damage.¹¹

TKC may also be the result of caustic substances entering the eye through unintentional or undesired means. These substances range from common household agents (e.g., chlorine, ammonia, alcohol or kerosene) to weaponized chemicals (e.g., pepper spray [oleoresin

capsicum] or tear gas [ortho-chlorobenzylidene malononitrile]), and toxic secretions produced by animals and plants (e.g., cobra venom, toxins from marine coral, sap of the *Dieffenbachia* plant).^{5,9,19-22} These agents are less likely to induce a simple allergic (type I) reaction and more likely to result in epithelial cell damage from direct toxicity. Secondary inflammatory effects follow, potentially leading to scar formation.^{9,20,21}

Management

The management objectives in TKC are essentially the same as in any instance of chemical trauma to the eye: identification and elimination of the causative agent, mitigation of damage to ocular surface tissues and implementation of strategies to diminish symptomatology.^{1,23}

Individuals who experience an acute chemical exposure should be instructed to identify the substance and proper removal strategy for accidental exposure to the eye. Copious water lavage is not always the correct course of action; some chemicals such as aluminum bromide or potassium hydroxide react violently to water, stripping the oxygen from the hydrogen, releasing heat and potentially inducing further injury. In the event the acute injury calls for water lavage, and the patient has called the office, instruct the patient to copiously lavage the eye(s) for at least 30 minutes by placing their face down into their water-filled cupped hands, blinking profusely to effect the rinse. This should be done before coming to the office so as not to prolong exposure. This technique also ensures that the chemical or agent is removed without contaminating the patient's clothing or risking exposure to other body locations. Upon presentation, irrigation can be augmented in the office by using a sterile eye wash applied forcefully and directly to all surfaces, or by flushing the eye with a sterile, intravenous saline solution run through a Morgan Lens apparatus (MorTan).²⁴

In chronic TKC, the most important aspect of management is recognizing and discontinuing the substance responsible for the reaction. A thorough review of all topicals used by the patient should be conducted, including prescription and OTC formulations. Once identified, a suitable alternative should be sought for any chronic-use product (e.g., intraocular pressure-lowering medications, contact lens solutions, etc.). Wherever possible, use of nonpreserved or alternatively preserved options should be considered.

Therapeutically, mild cases of TKC may be addressed with cold compresses and lubricating drops or ointments to help soothe and protect the ocular surface. Use of nonpreserved agents is preferred for this population. Topical antihistamine/mast cell stabilizers (e.g., alcaftadine 0.25% QD or bepotastine besylate 1.5% BID) may help address the itching, redness and swelling of ocular tissues associated with type I hypersensitivity reactions. For presentations that demonstrate a significant inflammatory component in the form of conjunctival and/or corneal edema, conjunctival follicles, generalized punctate keratopathy or anterior uveitis, topical steroids (e.g., loteprednol etabonate 0.5% or prednisolone acetate 1%) may be of significant benefit. Dosing of topical steroids varies with the severity of the inflammatory response, but in most cases therapy can be initiated four times per day. The use of a prophylactic topical antibiotic (e.g., moxifloxacin 0.5% TID or besifloxacin 0.6% TID) may be prudent in cases of severe keratopathy or corneal erosion.

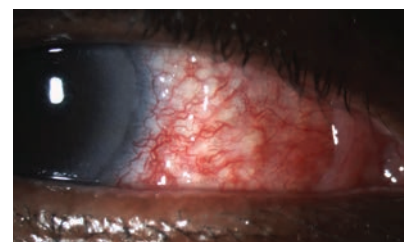
Acute pain should be addressed first with an appropriate cycloplegic (e.g., atropine 1% BID). Topical NSAIDs (e.g., bromfenac 0.09% QD or ketorolac tromethamine 0.5% QID) can also help ameliorate associated pain; however, the clinician should note that these agents have a potential for toxicity in their own right, and employing them in this capacity represents an "off-label" use.¹³

If topical agents are insufficient to control discomfort, use of oral analgesics (e.g., tramadol hydrochloride 50mg to 100mg PO Q four to six hours, or acetaminophen/hydrocodone bitartrate 325mg/5mg, one to two tabs PO Q four to six hours) is recommended. Finally, to facilitate healing as well as reduce discomfort for diffuse and severe cases, bandage contact lenses can be used.

Severe corneal compromise in the form of ulcerative keratitis or corneal melting warrants aggressive therapy. Referral to a fellowship-trained corneal specialist is strongly advised.

Clinical Pearls

- Diagnosis of TKC is often based more upon the history and disease course than the actual clinical presentation.
- TKC can appear similar to other conditions including dry eye disease, allergic conjunctivitis and epidemic keratoconjunctivitis.^{3,4} TKC should always be in the differential diagnosis when the patient reports initiation of a new eye drop, cosmetic agent or contact lens product during the prior three weeks.
- The absence of a palpable preauricular node is of significant value in differentiating TKC from infectious ocular disorders such as viral conjunctivitis.
- Mild cases of TKC will typically resolve within eight days regardless of treatment, providing that the offending agent is discontinued. However, liberal use of topical lubricants greatly facilitates ocular surface restoration and improves patient comfort.
- Topical steroids and antibiotics may be required concurrently in advanced cases. Some clinicians prefer the convenience of combination antibiotic/steroid preparations over separate agents.
- Amniotic membrane transplantation has been shown to be of great value in preventing debilitating vision loss for the most severe cases of TKC.⁸
- Toxic substances of terrorism, such as mustard gas, may necessitate the use



TKC demonstrating a significant inflammatory component as bulbar conjunctival follicles.

of the national poison control system. If circumstances surrounding exposure are suspicious, the patient should be quarantined and authorities called immediately after first aid has been dispensed.

1. Graue-Hernández EO, Navas A, Ramírez-Miranda A. Toxic keratoconjunctivitis. In: Holland EJ, Mannis MJ, Lee WB (eds). Ocular surface disease: cornea, conjunctiva and tear film. Atlanta: Elsevier, 2013. 189-93.
2. Patel S, Dhakhwa K, Rai SKC, et al. Clinical profile of toxic keratoconjunctivitis after ocular trauma with insect. Journal of Universal College of Medical Sciences. 2013;1(4):41-4. <http://www.nepjol.info/index.php/JUCMS/article/view/9573>. Date accessed: May 17, 2016.
3. Rubino P, Orsoni JG, Rampini A, Mora P. Over-treated corneal abscess may be toxic keratopathy. Case Rep Ophthalmol. 2010;1(1):20-23.
4. Dart J. Corneal toxicity: the epithelium and stroma in iatrogenic and factitious disease. Eye (Lond). 2003;17(8):886-92.
5. Teberik K, Ozer PA, Ozek D, et al. Frog saliva-induced toxic keratopathy: a case report. Int Ophthalmol. 2012;32(6):611-3.
6. Reilly CD, Mannis MJ. Toxic conjunctivitis. In: Krachmer JH, Mannis MJ, Holland EJ (eds). Cornea – Fundamentals, Diagnosis and Management. St. Louis: Mosby, 2011. 613-21.
7. Li J, Tripathi RC, Tripathi BJ. Drug-induced ocular disorders. Drug Saf. 2008;31(2):127-41.
8. Tok OY, Tok L, Atay IM, et al. Toxic keratopathy associated with abuse of topical anesthetics and amniotic membrane transplantation for treatment. Int J Ophthalmol. 2015;8(5):938-44.
9. Goldman DR, Seefeld AW. Ocular toxicity associated with indirect exposure to African spitting cobra venom. Wilderness Environ Med. 2010;21(2):134-6.
10. Guglielmetti S, Dart JK, Calder V. Atopic keratoconjunctivitis and atopic dermatitis. Curr Opin Allergy Clin Immunol. 2010;10(5):478-85.
11. Chen W, Li Z, Hu J, et al. Corneal alternations induced by topical application of benzalkonium chloride in rabbit. PLoS One. 2011;6(10):e26103.
12. Yeniad B, Canturk S, Esin Ozdemir F, et al. Toxic keratopathy due to abuse of topical anesthetic drugs. Cutan Ocul Toxicol. 2010;29(2):105-9.
13. Vignesh AP, Srinivasan R, Karanth S. A case report of severe corneal toxicity following 0.5% topical moxifloxacin use. Case Rep Ophthalmol. 2015;6(1):63-5.
14. Fraunfelder FW. Corneal toxicity from topical ocular and systemic medications. Cornea. 2006;25(10):1133-8.
15. Lee JS, Kim YH, Park YM. The toxicity of nonsteroidal anti-inflammatory eye drops against human corneal epithelial cells in vitro. J Korean Med Sci. 2015;30(12):1856-64.
16. Nguyen DQ, Srinivasan S, Hiscott P, et al. Thimerosal-induced limbal stem cell failure: report of a case and review of the literature. Eye Contact Lens. 2007;33(4):196-8.

17. Pfizer, Inc. Viroptic package insert. New York, NY. June 2014.

18. Monarch Pharmaceuticals, Inc. Neosporin package insert. Bristol, TN. July 2011.

19. Yeung MF, Tang WY. Clinicopathological effects of pepper (oleoresin capsicum) spray. *Hong Kong Med J*. 2015;21(6):542-52.

20. Kim YJ, Payal AR, Daly MK. Effects of tear gases on the eye. *Surv Ophthalmol*. 2016. pii: S0039-6257(15)30044-8. [Epub ahead of print].

21. Moshirfar M, Khalifa YM, Espandar L, et al. Aquarium coral keratoconjunctivitis. *Arch Ophthalmol*. 2010;128(10):1360-2.

22. Hsueh KF, Lin PY, Lee SM, et al. Ocular injuries from plant sap of genera *Euphorbia* and *Dieffenbachia*. *J Chin Med Assoc*. 2004;67(2):93-8.

23. Spector J, Fernandez WG. Chemical, thermal, and biological ocular exposures. *Emerg Med Clin North Am*. 2008;26(1):125-36, vii.

24. Ikeda N, Hayasaka S, Hayasaka Y, et al. Alkali burns of the eye: effect of immediate copious irrigation with tap water on their severity. *Ophthalmologica*. 2006;220(4):225-8.

VORTEX KERATOPATHY & HURRICANE KERATOPATHY

Signs and Symptoms

Vortex keratopathy, also known as *corneal verticillata*, describes a unique presentation of corneal deposition in a classic arborizing or whorl-shaped pattern. The condition occurs secondary to exogenous medications or systemic disease.¹⁻¹⁰

Hurricane keratopathy—a term that is sometimes used synonymously but erroneously for vortex keratopathy—represents a physiological phenomenon with a similar whorled presentation that may be seen (especially with the addition of fluorescein dye) in specific instances, such as following penetrating keratoplasty.¹¹

Patients with vortex keratopathy may be entirely asymptomatic, with the condition noted fortuitously upon routine ocular exam. Up to 40% of patients may complain of glare or mild difficulties perceiving color when questioned directly; halos and cloudy or reduced vision have also been reported, though less commonly.^{2,3,5,6,12} Ocular discomfort is rare except in advanced cases, in which the pigment may assume cystic formations and rupture, leading to pronounced pain and the potential for abscess.³

Vortex keratopathy is predominantly associated with systemic drug therapy, most notably amiodarone.^{1,10}

Other known agents that can induce this condition include atovaquone, AZD9291, chloroquine, chlorpromazine, hydroxychloroquine, indomethacin, mepacrine, meperidine, suramin, tamoxifen, tilorone hydrochloride and vandetanib.^{1,4,5,8,10,13-15} Alternatively, vortex keratopathy may be seen in some systemic lipid storage diseases, most notably Fabry disease.^{9,16,17}

Vortex keratopathy is typically a bilateral phenomenon, although some monocular exceptions have been reported.^{6,7} The condition may be seen at any age and in either gender; in Fabry disease, however, there appears to be a male predominance, and verticillata may be observed at a much earlier age.^{16,17}

Vortex keratopathy associated with amiodarone or other drug therapy is typically encountered in adults, for obvious reasons. Biomicroscopy of these patients reveals a variable accumulation of grayish to golden-brown corneal microdeposits at the level of the basal epithelium. This finding is initially noted at the interpalpebral fissure (i.e., lower one-third of the cornea). A grading system first proposed in 1983 is still used today (*grade 1*: small punctate opacities that coalesce to form a horizontal line [often resembling a Hudson-Stähli line]; *grade 2*: several, small, curvilinear outcroppings branching off of the original linear formations and sweeping upward; *grade 3*: more dramatic increase in the number and extent of these branches, assuming the characteristic vortex pattern; and *grade 4*: irregular brown clumps of pigment accompanying the branching pattern).¹⁸ In contradistinction to drug-induced vortex keratopathy, the corneal vortices associated with Fabry disease are more apparent and more fully developed in the upper one-third of the cornea.¹⁷

Hurricane keratopathy has not been reported extensively in the literature. A study published in 2000 involving 30 patients represents the largest prospective analysis of this phenomenon to date.¹¹

In this report, symptoms associated with hurricane keratopathy consisted of mild ocular irritation, foreign body sensation, lacrimation, photophobia and slight blurring of vision.¹¹ The subjects in this series had a history of penetrating keratoplasty or rigid contact lens wear.¹¹ A 1993 study involved six subjects with hurricane keratopathy, none of whom had undergone ocular surgery but 83% of whom were using long-term topical steroids for a variety of anterior segment disorders.¹⁹ In the vast majority of these patients, the whorl pattern was located centrally in the cornea and had a clockwise orientation.^{11,19} The fine lines of the vortex pattern were visible by slit-lamp exam as white epithelial lines, but were more readily identifiable after the addition of 2% sodium fluorescein. About 25% of patients displayed a small epithelial defect at the apex of the vortex.¹¹

Pathophysiology

Vortex keratopathy results from intralysosomal accumulation of material within basal corneal epithelial cells, forming lipid-bearing inclusion bodies.^{10,13} The characteristic whorl-shaped pattern is believed to arise from the centripetal migration of deposit-laden limbal epithelial cells.²⁰ This reflects the normal pattern of cell replication and movement from the limbal stem cells circumferentially around the cornea.^{19,20} Drugs that are associated with vortex keratopathy, while having diverse pharmacologic



Vortex keratopathy describes a unique presentation of corneal deposition in a classic arborizing or whorl-shaped pattern.

actions, typically possess cationic, amphiphilic (i.e., both hydrophilic and lipophilic) properties. This allows them to penetrate lysosomes, where the drugs and/or their metabolites bind with cellular lipids.¹⁰ The resultant complexes are too large to be extruded from the cells and/or are resistant to enzymatic degradation. This phenomenon is not unique to the cornea; in fact, many of these drugs may also be associated with patterned deposition affecting the lens and macula. A loose association with optic neuropathy has also been reported.^{13,21}

The pathogenesis of corneal verticillata in Fabry disease is similar. Fabry is a hereditary, X-linked disorder that leads to deficient production of the lysosomal enzyme alpha-galactosidase A.^{16,17} An absence of this enzyme leads to subsequent accumulation of glycosphingolipids (primarily globotriaosylceramide) in cells throughout the body.^{17,22} This substance is deposited by limbal blood vessels and accumulates within the epithelial basement membrane, but spares the stroma and endothelium.²³ As is the case with systemic drug therapy, Fabry disease can also affect other ocular structures, most notably the lens, conjunctiva and retina.¹⁷

Hurricane keratopathy likely represents an exaggerated presentation of the migration path taken by corneal epithelial cells undergoing normal replication. This process is not generally apparent to biomicroscopic exam. However, the migration during states of increased replicative epithelial turnover is significantly more rapid, and tight intercellular adhesions may not form as readily.¹¹ This in turn permits fluorescein to penetrate between cells or groups of cells, highlighting the pattern.¹⁹ Penetrating keratoplasty and the use of rigid contact lenses are the most commonly reported predisposing factors, while the concurrent or subsequent use of topical steroids appears to hasten and amplify the effect.^{11,19} While researchers are unclear as to why cells consistently migrate in this clockwise,

vortex pattern, the most widely held theory is that it reflects the influence of inherent electromagnetic fields of the eye on the replicating epithelium.^{11,19,20}

Management

In general, no medical or surgical treatments exist for vortex keratopathy or hurricane keratopathy. The whorl pattern observed in both conditions will persist as long as the pathological process driving it endures. Drug-induced vortex keratopathy is, in most cases, fully reversible upon cessation of the drug, although it may take many months for complete resolution.^{8,13} However, since this phenomenon is rarely sight-threatening, it would be ill-advised to discontinue any medication that has effectively managed a serious systemic malady. This is typically the case with amiodarone; cessation should not even be suggested unless visual function is severely compromised. At most, decreasing the regimen to a lower dose may be considered upon consultation and approval by the managing physician. Unfortunately, the vortex keratopathy encountered in inherited lysosomal storage disorders such as Fabry disease is progressive and irreversible.¹³

Hurricane keratopathy is transient in nearly all cases, and resolution often hastens with discontinuation of topical steroids as well as the use of topical lubricants.¹¹

For patients with irritating glare from these keratopathies, spectacle lenses with a neutral tint can often alleviate symptoms. Refractive errors should be fully corrected to maximize potential visual acuity. Ocular surface irregularities may be addressed with nonpreserved artificial tears or ointments as needed to improve comfort and or tear stability.

Clinical Pearls

- While vortex keratopathy is a unique clinical diagnosis, it must be differentiated from other pigmented corneal phenomena. These include: *Stocker's*

line (hemosiderin line noted at the leading edge of a long standing pterygium), *Hudson-Stähli line* (corneal epithelial iron deposition on the lower third of the cornea secondary to normal aging or excessive interaction with the lower eyelid and the tear lake), *Kayser-Fleischer ring* (limbal copper deposition in Descemet's membrane secondary to Wilson's disease), *Fleisher ring* (corneal epithelial deposit at the base of a cone in keratoconus) and *Ferry's line* (corneal epithelial iron deposit at the edge of a filtering bleb).

- Because vortex keratopathy is directly associated with specific medications or grave systemic disorders, a thorough medical and drug history is obligatory whenever it is seen or suspected.

- In addition to Fabry disease, corneal verticillata has been noted in association with multiple myeloma—a highly malignant form of cancer that involves plasma cells (mature B cell lymphocytes) and typically arises in the bone marrow.⁵

- Vortex keratopathy is not the only ocular sign associated with Fabry disease. Because the vascular system is greatly impacted by glycosphingolipid deposition, acquired tortuosity of the conjunctival and retinal vessels is quite common.¹⁷ These patients may also be predisposed to retinal vaso-occlusive disorders such as branch and central retinal vein occlusion, branch and central retinal artery occlusion, and cilioretinal artery occlusion.²⁴⁻²⁷

1. Chia PL, John T. Vortex keratopathy presumed secondary to AZD9291. *J Thorac Oncol.* 2015;10(12):1807-8.
2. Agarwal AK, Ram J. Cat's whiskers & corneal verticillata secondary to amiodarone intake. *Indian J Med Res.* 2015;141(3):370.
3. Dowie JM, Gurwood AS. Acute onset of halos and glare: bilateral corneal epithelial edema with cystic eruptions—atypical presentation of amiodarone keratopathy. *Optometry.* 2006;77(2):76-81.
4. Dossó A, Rungger-Brändle E. In vivo confocal microscopy in hydroxychloroquine-induced keratopathy. *Graefes Arch Clin Exp Ophthalmol.* 2007;245(2):318-20.
5. Sharma P, Madi HA, Bonshek R, et al. Cloudy corneas as an initial presentation of multiple myeloma. *Clin Ophthalmol.* 2014;8:813-7.
6. Chilov MN, Moshogov CN, Booth F. Unilateral amiodarone keratopathy. *Clin Experiment Ophthalmol.* 2005;33(6):666-8.
7. Bhatt PR, Ramaesh K. Unilateral amiodarone keratopathy: occlusive contact lens spares development in the contralateral eye. *Eye (Lond).* 2007;21(2):296-8.

8. Shah GK, Cantrill HL, Holland EJ. Vortex keratopathy associated with atovaquone. *Am J Ophthalmol.* 1995;120(5):669-71.
9. Spada M, Enea A, Morrone A, et al. Cornea verticillata and Fabry disease. *J Pediatr.* 2013;163(2):609.
10. Ahn J, Wee WR, Lee JH, et al. Vortex keratopathy in a patient receiving vandetanib for non-small cell lung cancer. *Korean J Ophthalmol.* 2011;25(5):355-7.
11. Dua HS, Gomes JA. Clinical course of hurricane keratopathy. *Br J Ophthalmol.* 2000;84(3):285-8.
12. Erdurmus M1, Selcoki Y, Yagci R, et al. Amiodarone-induced keratopathy: full-thickness corneal involvement. *Eye Contact Lens.* 2008;34(2):131-2.
13. Hollander DA, Aldave AJ. Drug-induced corneal complications. *Curr Opin Ophthalmol.* 2004;15(6):541-8.
14. Ma X, He L, He D, et al. Chloroquine keratopathy of rheumatoid arthritis patients detected by in vivo confocal microscopy. *Curr Eye Res.* 2012;37(4):293-9.
15. Yam JC, Kwok AK. Ocular toxicity of hydroxychloroquine. *Hong Kong Med J.* 2006;12(4):294-304.
16. Costa AL, Roisman V, Martins TG. Cornea verticillata caused by Fabry disease. *Einstein (Sao Paulo).* 2014;12(4):527-8.
17. Sivley MD. Fabry disease: a review of ophthalmic and systemic manifestations. *Optom Vis Sci.* 2013;90(2):e63-78.
18. Orlando RG, Dangel ME, Schaaf SF. Clinical experience and grading of amiodarone keratopathy. *Ophthalmology.* 1984;91(10):1184-7.
19. Dua HS, Watson NJ, Mathur RM, et al. Corneal epithelial cell migration in humans: hurricane and blizzard keratopathy. *Eye (Lond).* 1993;7 (Pt 1):53-8.
20. Dua HS, Singh A, Gomes JA, et al.: Vortex or whorl formation of cultured human corneal epithelial cells induced by magnetic fields. *Eye (Lond).* 1996;10 (Pt 4):447-50.
21. Cheng HC, Yeh HJ, Huang N, et al. Amiodarone-associated optic neuropathy: a nationwide study. *Ophthalmology.* 2015;122(12):2553-9.
22. El-Abassi R, Singhal D, England JD. Fabry's disease. *J Neurol Sci.* 2014;344(1-2):5-19.
23. Mastropasqua L, Nubile M, Lanzini M, et al. Corneal and conjunctival manifestations in Fabry disease: in vivo confocal microscopy study. *Am J Ophthalmol.* 2006;141(4):709-18.
24. Morier AM, Minteer J, Tyszko R, et al. Ocular manifestations of Fabry disease within a single kindred. *Optometry.* 2010;81(9):437-49.
25. Oto S, Kart H, Kadayifçilar S, et al. Retinal vein occlusion in a woman with heterozygous Fabry's disease. *Eur J Ophthalmol.* 1998;8(4):265-7.
26. Mitchell KT, Bradley JC, Gilmore LS, et al. Sequential bilateral central retinal artery occlusions in a female carrier of Fabry disease. *Clin Experiment Ophthalmol.* 2009;37(7):748-50.
27. Dantas MA, Fonseca RA, Kaga T, et al. Retinal and choroidal vascular changes in heterozygous Fabry disease. *Retina.* 2001;21(1):87-9.

KERATOCONUS AND HYDROPS

Signs and Symptoms

Keratoconus is the most common cause of degenerative corneal ectasia worldwide and the single most common reason for keratoplasty in the developed world.¹⁻⁵ It is a non-inflammatory pathology wherein the cornea aberrantly assumes a cone shape, leading to corneal protrusion, tissue thinning, myopia,

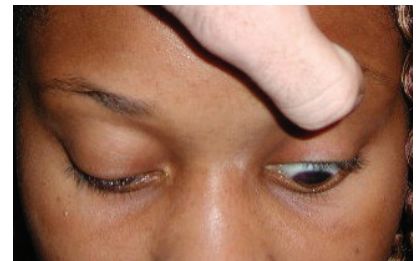irregular astigmatism, metamorphosis and vision impairment.¹⁻⁸

Keratoconus affects all ethnic groups and both genders, surfacing in the second decade of life.^{5,7,9} One report in recent literature recognized that individuals of African and Latino descent had adjusted odds indicating a statistically higher likelihood of being affected than their Caucasian counterparts.¹⁰ Other conditions found to have increased odds of producing keratoconus include those suffering from sleep apnea, asthma and Down's syndrome.¹⁰ The same paper reported that individuals of Asian descent had reduced odds of being affected compared to Caucasian counterparts. Other individuals who had statistically lower odds of being affected with keratoconus compared to age-matched normals were individuals with uncomplicated diabetes mellitus, individuals with diabetes whose disease was complicated by end-organ damage and individuals afflicted by collagen vascular disease.¹⁰

Environmental factors (ocular allergy with chronic eye rubbing), inflammation, corneal scarring and genetics are documented contributors to pathogenesis.¹⁻⁷ Some researchers have suggested a slightly higher prevalence in cooler climates that receive less sunlight in patients with Down's syndrome and in patients with tapetoretinal degenerations.⁷⁻⁹ Family-based linkage studies, twin studies, genetic mutation and genome-wide association studies have all supported the notion that, at the least, genetic components are common.^{4,7}

The prevalence of keratoconus varies worldwide from 0.3/100,000 in Russia to 2,300/100,000 in central India; the overall average incidence rate in the United States has been estimated at 2.0/100,000 with a prevalence rate of 54.5/100,000 population.⁸ The disease may be unilateral but is typically bilateral.⁸ The disease has a progressive and varied course through the fourth decade of life.^{2,5-9}

The most familiar ocular manifesta-



Classic Munson's sign in downgaze.

tion of keratoconus is corneal steepening or "cone" formation.¹⁻¹⁵ Corneal steepening with tissue thinning at the apex of the cone creates topographic geometries that include the vertical bowtie pattern, the inferior global cone pattern and the inferotemporal global cone pattern (seen more commonly in older patients).^{2,9-15}

Temporal cone location is most common in younger patients.¹⁵ Corneal protrusion can be seen on profile and in creating the classic Munson's sign in downgaze.¹⁻¹⁹ Standard keratometry may not pick up the disturbance, as it measures only a small portion of the central corneal cap.¹⁸ Distorted keratometric mires along with a complaint of irregular vision is an indication for advanced topographic investigation, including placido disc and topography.^{18,19} Retinoscopy (observation of the classic "scissors motion"), observing the focusing of a penlight as the beam is directed through the cornea from one side to the other (Rizzuti's sign) and visualizing the dark circular reflex in the area of the cone upon dilated indirect ophthalmoscopy (Charleaux's sign) can uncover the optical distortions created by the conical corneal shape.^{2,16-19}

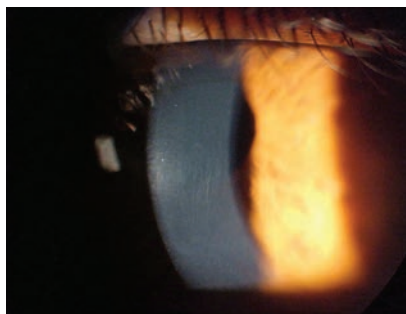
Biomicroscopic examination may uncover clearing zones and scarring in Bowman's membrane along with vertical, and rarely, horizontal deep stromal/Descemet's stress lines known as Vogt's striae.¹⁷⁻¹⁹ A faint brown ring of hemosiderin (iron particles) often can be seen encircling the base of the cone (Fleischer's ring). Changes in the posterior cornea and inferior corneal thinning

are early-noted changes.^{2,13,17-19} Modern imaging modalities such as ultrasound biomicroscopy, anterior segment optical coherence tomography and in vivo confocal microscopy can be used to further define the extent and nature of the cornea shape and thinning. Differential diagnosis includes pellucid marginal degeneration and post-LASIK ectasia.

Corneal hydrops is characterized by acute stromal edema, which occurs secondary to the seepage of aqueous humor through a tear in the Descemet's membrane.¹⁹⁻²² Presenting signs and symptoms include sudden decreased vision, photophobia, pain, conjunctival hyperemia, stromal and epithelial microcystic edema, intrastromal cysts and clefts with a variable anterior chamber reaction.¹⁹⁻²⁵ The location where hydrops can occur is variable and not always predictable.²⁰ The corneal edema can be graded according to its extent; grade 1 is defined by a circle <3mm in diameter; grade 2 between 3mm to 5mm and grade 3mm>5mm in diameter.¹⁹ Many cases of hydrops experience minimal epitheliopathy.

Pathophysiology

The pathophysiology that causes keratoconus is largely unknown.^{2,3,6,12,26-29} The commonly proposed pathogenesis includes a genetic predisposition to biochemical corneal alteration that is set into motion by an inciting event, such as eye rubbing. The trauma is often



Fine vertical lines produced by deep stromal and Descemet's membrane compression create Vogt's striae.

brought about by chronic ocular allergy or a behavioral idiosyncrasy. The insult induces the release of inflammatory mediators and cytokines, which alter the normal homeostatic properties of the cornea.^{2,3,6,12,20,26-29}

The cornea is a viscoelastic tissue.^{12,28} When stress or pressure is applied, inherent viscosity and architecture (250 to 400 interwoven, stacked lamellae with uniform spacing composed of type I/V collagen) orchestrate energy dissipation.²⁸ In keratoconus the preferred orthogonal fibril orientation of approximately one-third of the tissue becomes altered, creating biomechanical instability.²⁹ An imbalance between proteolytic breakdown and repair, and a reduction in the concentration and activity of the crosslinking enzyme lysyl oxidase produces a substantial reduction in stiffness.²⁸ The structure deforms under natural conditions, inciting corneal warpage/protrusion, irregular astigmatism, clefting, cyst formation, fibrosis, scarring and decreased vision.^{2,3,6,12,26-29} Accumulations of ferritin particles in the widened intercellular spaces and cytoplasmic vacuoles of the corneal epithelium create the Fleischer ring.¹³ Fine vertical lines produced by deep stromal and Descemet's membrane compression create Vogt's striae.¹⁹

Acute corneal hydrops is an incompletely understood complication of keratoconus. Through chronic microtrauma (eye rubbing) or a significant singular event, a focal break in Descemet's membrane permits aqueous humor to enter into the cornea, producing significant edema.^{20,21,23} As the fluid percolates into the cornea, it leads to the separation of the collagen lamellae, producing the formation of large, fluid-filled stromal pockets.²⁰ The reparative process causes the breached endothelium to grow over the Descemet's defect, creating a seal so that the seepage is prevented from withdrawing. The sequestered edema incites inflammation and some degree of

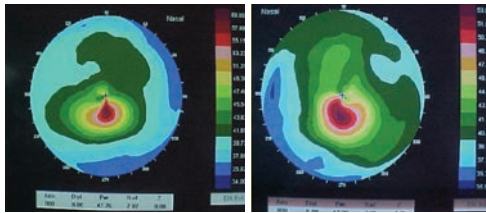
epitheliopathy. If the injury occurs where the cornea is thinnest, anterior rupture is possible creating a full thickness perforation.²⁰⁻²⁴

Management

Medical treatment for acute hydrops is centered on providing symptomatic relief until spontaneous resolution occurs.²⁰⁻²⁵ Topical lubricants, topical antibiotics QID, topical cycloplegics (i.e., atropine QD-BID) will prophylax against infection and reduce pain and photophobia. Hypertonic eye drops QID or ointment BID theoretically aid in the removal of excess corneal fluid, but clinically, the results are not impressive. Topical anti-glaucoma medications lessen the hydrodynamic forces placed on the posterior cornea, which can reduce edema. Topical steroids and nonsteroidal anti-inflammatory drugs can further reduce inflammation.²⁰ Over-the-counter oral analgesics such as acetaminophen or ibuprofen may be indicated to provide pain relief in the acute stages. If the corneal epithelium is compromised or a full-thickness perforation is detected, a bandage soft contact lens can be placed as part of the first aid can be placed as part of the first aid.²⁰⁻²⁴ Cyanoacrylate tissue adhesive and amniotic membrane placement with cauterization can be employed.²⁰⁻²⁵

In recalcitrant cases, an intracameral air/gas injection can increase intracorneal pressure and shorten the persistence of the corneal edema. Various agents include air, 20% sulfur hexafluoride (SF6) and 14% perfluoropropane (C3F8).²⁰ The agents produce a tamponade effect that prevents aqueous from penetrating into the stroma while also unrolling the torn ends of the ruptured Descemet's membrane.²⁰

The long-term treatments for keratoconus have two goals: improve function and lifestyle, and slow or stabilize progression.²⁶⁻³⁷ Shape stabilization, using recently approved epithelium-off corneal collagen crosslinking (CXL) or



Representative topographic maps can aid in advanced investigation of keratoconus.

transepithelial technique where the riboflavin is delivered using enhancers that increase epithelial permeability rather than epithelial debridement is a treatment intended to arrest and, in some cases, regress the progression of keratoconus.^{28-29,35-37} The two procedures can also be combined for an exaggerated effect.

CXL is a technique that uses ultraviolet A (UVA) light and riboflavin (photosensitizer, vitamin B2) to create a photochemical reaction in the stroma, leading to the development of chemical bonds between collagen fibrils, thereby strengthening the cornea.^{36,37} The procedure can slow or stop progression of keratoconus and other corneal ectasias.^{28-30,35-37} The procedure is well tolerated, with effects persisting 15 years or more. CXL can be repeated if necessary and combined with other modalities, such as contact lenses or intrastromal corneal ring placement.^{28-30,35,36} Side effects include risk of bacterial infection, light corneal haze that typically resolves over the course of eight to 12 months and stromal corneal scar formation.³⁵

The common methods of vision correction (improving visual function) range from spectacles (for patients who are contact lens and surgery intolerant) and contact lenses, to collagen crosslinking and corneal replacement surgery.²⁶⁻³⁵ Intralase rigid gas permeable (RGP) and hybrid (soft peripheral skirt with a RGP center) contact lenses fit using the first diameter apical clearance (FDCL) model, outlined by the Collaborative Longitudinal Evaluation of Keratoconus (CLEK) Study Group,

have been a mainstay of visual correction.²⁷ While the modality has not demonstrated a benefit for arresting KC it is well tolerated, providing excellent visual results while minimizing the risk of scar formation.²⁷

New materials and lens designs have paved the way for a resurgence of scleral lenses.^{30,31} These large-diameter lenses (true scleral lenses: >18mm; mini-scleral lenses: 15mm to 18mm) rest on the sclera and vault over the cornea.^{30,31} The lenses consist of three parts: the scleral or haptic portion (the component that rests on sclera), the vault (responsible for corneal and limbal clearance) and the optical portion.³⁰ The optical portion is designed to be 0.2mm larger than the horizontal visible iris diameter.³¹ The expertise in fitting these is maximizing “on-eye” performance with comfort. Properly fitted, vision should be improved in the setting of good comfort with no lens movement.³¹ Materials with improved oxygen solubility, supported with air-ventilated (fenestrated) or fluid-ventilated (non-fenestrated) designs provide healthy corneal physiology.³¹

Penetrating keratoplasty (PK) has been the traditional surgical procedure for keratoconus.³² While it continues to be commonly performed, it carries risk of infection, long-term inflammation, poor functional outcome and risk of immunologic graft rejection.³² Maximum depth or deep anterior lamellar keratoplasty (MDALK or DALK) has evolved as a surgical replacement for PK.²⁰ DALK preserves the native Descemet’s membrane and endothelium, reducing the host immune system reaction and risk of graft rejection.²⁰ As there is no “open sky,” the risk of infection is also reduced. Manual dissection to the Descemet’s membrane is completed creating room for the donor implant.²⁰

The DALK technique has led to significant improvements in both recovery times and visual outcomes. The big

bubble technique of DALK has become the most popular among the variations.²⁰ Intralase-enabled keratoplasty (IEK), also known as femtosecond laser-assisted keratoplasty (FLAK), is a full-thickness and anterior lamellar procedure where both the patient and recipient corneas are altered with the laser, as opposed to the traditional trephine (a specialized, circular blade).³⁸ The laser-assisted technique shows promise for shorter time to suture removal whereas the more conventional DALK technique seems to provide more stable refractive outcomes.³⁸ The literature compares each to the other, citing that the choice may come down to case-specific advantages.³⁸

Clinical Pearls

- Keratoconus is the most common cause of corneal ectasia worldwide.
- Keratoconic changes typically occur in young adulthood and are provoked by both environmental and genetic factors.
- When the visual acuity cannot be corrected to predicted levels in the absence of ocular pathology, consider topography to rule keratoconus.
- Acute corneal hydrops is characterized by sudden decreased vision, photophobia, stromal edema, conjunctival hyperemia and variable iritis, usually following an event of eye rubbing.
- Acute hydrops can appear superficially similar in presentation to infectious keratitis. The main differentiating factor in hydrops is a typically intact epithelium.
- Hydrops will resolve by itself. The aim of first aid is to assist in improving comfort and speed the recovery of vision.
- Differential diagnosis includes marginal pellucid degeneration and post-LASIK ectasia.

1. Farjadnia M, Naderan M. Corneal cross-linking treatment of keratoconus. *Oman J Ophthalmol.* 2015;8(2):86-91.
 2. Joel S. Stromal corneal dystrophies and ectasias. In: Yanoff M, Duker JS. *Ophthalmology.* Mosby-Elsevier, St. Louis, MO. 2009:436-45.
 3. Gordon-Shaag A, Millodot M, Shneur E, et al. The genetic and environmental factors for keratoconus. *Biomed Res Int.* 2015;2015(5):795738.

4. Wheeler J, Hauser MA, Afshari NA, et al. The Genetics of Keratoconus: A Review. *Reprod Syst Sex Disord*. 2012;3(Suppl 6). pii: 001.
5. Davidson AE, Hayes S, Hardcastle AJ, et al. The pathogenesis of keratoconus. *Eye (Lond)*. 2014;28(2):189-95.
6. Sharma N, Rao K, Maharana PK, et al. Ocular allergy and keratoconus. *Indian J Ophthalmol*. 2013;61(8):407-9.
7. Gokhale NS. Epidemiology of keratoconus. *Indian J Ophthalmol*. 2013;61(8):382-3.
8. Kennedy RH, Bourne WM, Dyer JA. A 48-year clinical and epidemiologic study of keratoconus. *AmJ Ophthalmol*. 1986;101(3):267-73.
9. Krachmer JH, Feder RS, Belin MW. Keratoconus and related noninflammatory corneal thinning disorders. *Surv Ophthalmol*. 1984;28(4):293-322.
10. Woodward MA, Blachley TS, Stein JD. The Association Between Sociodemographic Factors, Common Systemic Diseases, and Keratoconus: An Analysis of a Nationwide Health Care Claims Database. *Ophthalmology*. 2016;123(3):457-65.
11. Shirayama-Suzuki M, Amano S, Honda N, et al. Longitudinal analysis of corneal topography in suspected keratoconus. *Br J Ophthalmol*. 2009;93(6):815-9.
12. Sugar J, Macsai MS. What causes keratoconus? *Cornea*. 2012;31(6):716-Second hit concept c genetic predisposition.
13. Iwamoto T, DeVoe AG. Electron microscopical study of the Fleisher ring. *Arch Ophthalmol*. 1976;94(9):1579-84.
14. Naderan M, Shoar S, Kamaledin MA, et al. Keratoconus Clinical Findings According to Different Classifications. *Cornea*. 2015;34(9):1005-11.
15. Ertan A, Kamburoglu G, Colin J. Location of steepest corneal area of cone in keratoconus stratified by age using Pentacam. *J Refract Surg*. 2009;25(11):1012-6.
16. Goebels S, Käsmann-Kellner B, Eppig T, et al. Can retinoscopy keep up in keratoconus diagnosis? *Cont Lens Anterior Eye*. 2015;38(4):234-9.
17. Güngör IU, Beden U, Sönmez B. Bilateral horizontal Vogt's striae in keratoconus. *Clin Ophthalmol*. 2008;2(3):653-5.
18. Edrington TB, Zadnik K, Barr JT. Keratoconus. *Optom Clin*. 1995;4(3):65-73.
19. Romero-Jiménez M, Santodomingo-Rubido J, Wolffsohn JS. Keratoconus: a review. *Cont Lens Anterior Eye*. 2010;33(4):157-66.
20. Maharana PK, Sharma N, Vajpayee RB. Acute corneal hydrops in keratoconus. *Indian J Ophthalmol*. 2013;61(8):461-4.
21. Barsam A, Petruskhin H, Brennan N, et al. Acute corneal hydrops in keratoconus: a national prospective study of incidence and management. *Eye (Lond)*. 2015;29(4):469-74.
22. Fuentes E, Sandali O, El Sanharawi M, et al. Anatomic Predictive Factors of Acute Corneal Hydrops in Keratoconus: An Optical Coherence Tomography Study. *Ophthalmology*. 2015;122(8):1653-9.
23. Fan Gaskin JC, Patel DV, McGhee CN. Acute corneal hydrops in keratoconus - new perspectives. *Am J Ophthalmol*. 2014;157(5):921-8.
24. Lahoud S, Brownstein S, Latlamme MY, Poleski SA. Keratoconus with spontaneous perforation of the cornea. *Can J Ophthalmol*. 1987;22(4):230-3.
25. Yeh S, Smith JA. Management of acute hydrops with perforation in a patient with keratoconus and cone dystrophy: case report and literature review. *Cornea*. 2008;27(9):1062-5.
26. Priyadarsini S, McKay TB, Sarker-Nag A, et al. Keratoconus in vitro and the key players of the TGF- β pathway. *Mol Vis*. 2015;21(5):577-88.
27. Szczotka LB, Barr JT, Zadnik K. A summary of the findings from the Collaborative Longitudinal Evaluation of Keratoconus (CLEK) Study. CLEK Study Group. *Optometry*. 2001;72(9):574-84.
28. Sorkin N, Varssano D. Corneal collagen crosslinking: a systematic review. *Ophthalmologica*. 2014;232(1):10-27.
29. Alhayek A, Lu PR. Corneal collagen crosslinking in keratoconus and other eye disease. *Int J Ophthalmol*. 2015;8(2):407-18.
30. Shetty R, Kaveri L, Pahuja N, et al. Current review and a simplified "five-point management algorithm" for keratoconus. *Indian J Ophthalmol*. 2015;63(1):46-53.
31. Rathi VM, Mandathara PS, Taneja M, et al. Scleral lens for keratoconus: technology update. *Clin Ophthalmol*. 2015;9(10):2013-8.
32. Fogla R. Deep anterior lamellar keratoplasty in the management of keratoconus. *Indian J Ophthalmol*. 2013;61(8):465-8.
33. Park J, Gritz DC. Evolution in the use of intrastromal corneal ring segments for corneal ectasia. *Curr Opin Ophthalmol*. 2013;24(4):296-301.
34. Poulsen DM, Kang JJ. Recent advances in the treatment of corneal ectasia with intrastromal corneal ring segments. *Curr Opin Ophthalmol*. 2015;26(4):273-7.
35. Gore DM, Shortt AJ, Allan BD. New clinical pathways for keratoconus. *Eye (Lond)*. 2013;27(3):329-39.
36. Kankariya VP, Kymionis GD, Diakonis VF, et al. Management of pediatric keratoconus - evolving role of corneal collagen cross-linking: an update. *Indian J Ophthalmol*. 2013;61(8):435-40.
37. Agrawal A. Long-term results of cornea collagen crosslinking with riboflavin for keratoconus. *Indian J Ophthalmol*. 2013;61(8):433-4.
38. Mashor RS, Rootman DB, Bahar I, et al. Outcomes of deep anterior lamellar keratoplasty versus intralase enabled penetrating keratoplasty in keratoconus. *Can J Ophthalmol*. 2011;46(5):403-7.

TERRIEN'S MARGINAL DEGENERATION

Signs and Symptoms

Terrien's marginal degeneration is one of the peripheral corneal degenerations.¹⁻¹⁰ The entity has been recognized for more than 90 years.³ It may be unilateral or bilateral, affect individuals at any age (but typically begins between the second and fourth decade) and is more predominant in women by a ratio of 3:1.^{2,3} The condition is slowly progressive and associated with evolving corneal neovascularization, opacification, lipid deposition and thinning.¹⁻⁷ Corneal architectural changes produce large amounts of peripheral corneal steepening and against-the-rule, or oblique, astigmatism.¹⁻¹⁰ Episcleral and scleral inflammation are possible, inducing pain, photophobia and lacrimation.¹⁻⁵

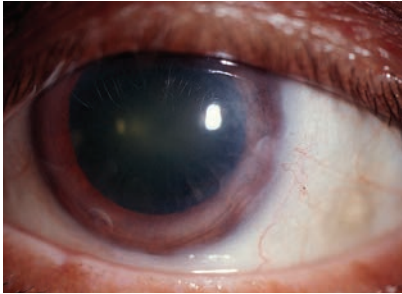
Initially, signs are typically exhibited superiorly with mild punctate epitheliopathy and anterior stromal inflammatory opacities.² A clear region will exist between the boundaries of the opacities and the limbus. This is followed by the

development of a peripheral superficial vascular pannus that progresses onto the cornea, provoking additional inflammatory consequences and corneal opacification.¹⁻¹¹ Corneal thinning begins at the limbus in the vicinity of the lipid deposition. This causes the cornea to take on a steeper slope at the advancing edge. Corneal thinning and sloping will progress circumferentially, but the overlying epithelium will remain intact. The pannus can be significant and resembles a pterygium as it broadens and flattens. However, unlike true pterygia, which grow classically nasally and temporally, these degenerations are found at oblique axes.² In severe and advanced cases, keratoconus may develop.⁹ Perforation and hydrops have been rarely reported.^{2,6,10,11}

Other than visual changes secondary to the induced corneal astigmatism, most patients remain asymptomatic because the disease rarely creates uncomfortable epithelial defects.² As such, the general risk for secondary microbial infection is low. The diagnosis of Terrien's marginal degeneration is made based on the constellation of poor vision in the setting of a changing cylindrical refraction, observed biomicroscopic signs and corneal topography.⁹⁻¹² The disease has been associated with posterior polymorphous dystrophy.⁷ Differential diagnosis includes marginal furrow degeneration, pellucid marginal degeneration, keratolysis and Mooren's ulcer.²

Pathophysiology

The cause of Terrien's marginal degeneration is unknown.¹⁻¹³ Research suggests an immunological etiology.² Inflammatory and degenerative mechanisms have also been proposed.² The disease presents in two forms: Type 1 occurs primarily in older populations, producing painless, slowly progressive cornea thinning with associated visual degradation; Type 2 characteristically is found in younger patients, with associated episcleritis and scleritis.²



Signs of Terrien's marginal degeneration are typically exhibited superiorly, with mild punctate epitheliopathy and anterior stromal inflammatory opacities.

Terrien's marginal degeneration is distinguished from other peripheral corneal thinning disorders by its absence of an overlying epithelial defect. The slowly progressive nature with lipid deposition and vascular pannus formation in the absence of painful sequelae is the differentiating sign. The corneal epithelium is intact, but altered. It may be thickened or thinned, and include underlying degeneration of Bowman's membrane.² In extreme cases, thinning may cause frank keratoconus and fracture Descemet's membrane with hydrops.^{1-6,11,12} The process typically leads to fibrillar collagen degeneration of the stroma.² Lamellar specimens have demonstrated CD4 and CD8 T-lymphocytes.²

The disease progresses in stages.^{9,12} In the first stage, the superior peripheral cornea slowly narrows. In the second stage, a sharp, yellowish-white border containing lipid deposits forms creating a leading edge between the narrowed and normal corneal portions. In the third stage, the lipid-affected cornea becomes increasingly thinner, generating irregular astigmatism. In the fourth stage, keratoconus forms. In the fifth, hydrops or spontaneous/traumatic perforation may occur due to exaggerated thinning.^{9,12}

Management

The treatment for Type 1 Terrien's marginal degeneration is copious lubrication, updated spectacle or contact

lens prescriptions to keep pace with the visual changes and close observation. Toric soft lenses and spherical and toric rigid contact lenses can be used initially to improve vision. As the condition progresses, scleral lens designs may be beneficial.^{13,14} In the event that Type 2 Terrien's is present, topical and oral anti-inflammatory therapy (steroids, non-steroidal anti-inflammatories and possibly immunomodulators) along with topical cycloplegia should be initiated to minimize scarring and decrease painful symptoms. In the rare event that hydrops occurs, topical hypertonic solutions and ointments can be started to reduce corneal edema. Anti-glaucoma agents can be added to reduce the hydrostatic pressure placed on the endothelium.¹⁵⁻²¹

In cases where thinning threatens perforation, patch grafts are preferred options due to the peripheral location.^{22,23} Peripheral deep anterior lamellar keratoplasty has been shown to be effective at minimizing the risk of graft failure and rejection, while offering a reasonable chance toward achieving acceptable visual outcomes.²³

Clinical Pearls

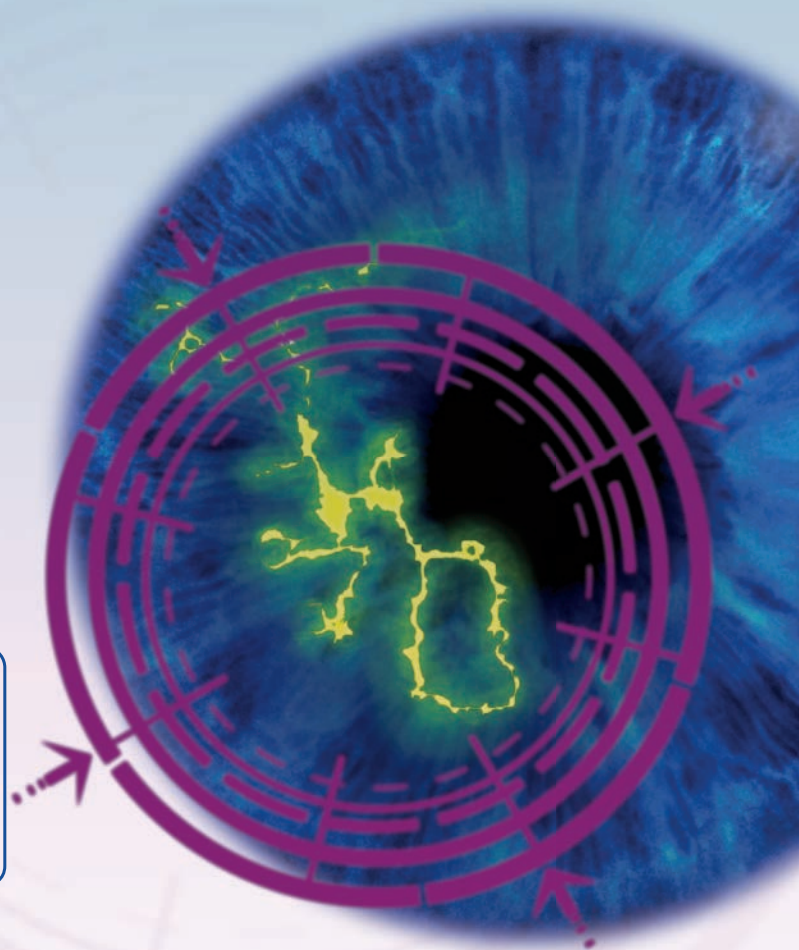
- Terrien's marginal degeneration is a slowly progressive disease of the peripheral cornea that frequently is painless.
- The condition occurs in five stages, typically beginning in the region of the peripheral cornea.
- As the peripheral cornea steepens, astigmatism may be induced, causing the initial symptom of vision changes.
- Type 2 Terrien's can be painful and present with varied conjunctival hyperemia, episcleritis, iritis and scleritis.
- In advanced cases, keratoconus may form with hydrops and perforation.
- Recent advances in design, manufacturing and materials have made scleral lenses a reasonable modality for improving vision and corneal physiology in Terrien's patients.

1. Bouchard CS. Non-infectious keratitis. In: Yanoff M, Duker JS. *Ophthalmology*. Mosby-Elsevier, St. Louis, MO. 2009:454-65.
2. Wang N, Wang CX, Lian XF, et al. Staging of development in Terrien's degeneration based on corneal curvatures detected by optical coherence tomography. *Graefes Arch Clin Exp Ophthalmol*. 2015;253(10):1757-64.
3. Golubović S. Terrien's marginal corneal degeneration. *Srp Arh Celok Lek*. 1994;122(3-4):110-2.
4. Wilson SE, Lin DT, Klyce SD, et al. Terrien's marginal degeneration: corneal topography. *Refract Corneal Surg*. 1990;6(1):15-20.
5. Guyer DR, Barraquer J, McDonnell PJ, et al. Terrien's marginal degeneration: clinicopathologic case reports. *Graefes Arch Clin Exp Ophthalmol*. 1987;225(1):19-27.
6. Ashenhurst M, Slomovic A. Corneal hydrops in Terrien's marginal degeneration: an unusual complication. *Can J Ophthalmol*. 1987;22(6):328-30.
7. Wagoner MD, Teichmann KD. Terrien's marginal degeneration associated with posterior polymorphous dystrophy. *Cornea*. 1999;18(5):612-5.
8. Zarei-Ghanavati S1, Javadi MA, Yazdani S. Bilateral Terrien's marginal degeneration and posterior polymorphous dystrophy in a patient with rheumatoid arthritis. *J Ophthalmic Vis Res*. 2012;7(1):60-3.
9. Zhang Y, Jia H. Terrien's marginal degeneration accompanied by latticed stromal opacities. *Optom Vis Sci*. 2014;91(5):e110-6.
10. Thurschwell LM. Terrien's marginal degeneration. *J Am Optom Assoc*. 1983;54(5):441-6.
11. Vejdani AH, Khakshoor H, McCaughey MV, et al. Partial and total Descemet's detachments in a patient with severe Terrien's marginal degeneration and juvenile idiopathic arthritis. *Case Rep Ophthalmol Med*. 2014;2014(7):279491.
12. Wang N, Wang CX, Lian XF, et al. Staging of development in Terrien's degeneration based on corneal curvatures detected by optical coherence tomography. *Graefes Arch Clin Exp Ophthalmol*. 2015;253(10):1757-64.
13. Mahadevan R, Fathima A, Rajan R, et al. An ocular surface prosthesis for keratoglobus and Terrien's marginal degeneration. *Optom Vis Sci*. 2014;91(4 Suppl 1):S34-9.
14. Maharana PK, Dubey A, Jhanji V, et al. Management of advanced corneal ectasias. *Br J Ophthalmol*. 2016;100(1):34-40.
15. Romero-Jiménez M, Santodomingo-Rubido J, Wolffsohn JS. Keratoconus: a review. *Cont Lens Anterior Eye*. 2010;33(4):157-66.
16. Maharana PK, Sharma N, Vajpayee RB. Acute corneal hydrops in keratoconus. *Indian J Ophthalmol*. 2013;61(8):461-4.
17. Barsam A, Petrushkin H, Brennan N, et al. Acute corneal hydrops in keratoconus: a national prospective study of incidence and management. *Eye (Lond)*. 2015;29(4):469-74.
18. Fuentes E, Sandali O, El Sanharawi M, et al. Anatomic predictive factors of acute corneal hydrops in keratoconus: an optical coherence tomography study. *Ophthalmology*. 2015;122(8):1653-9.
19. Fan Gaskin JC, Patel DV, McGhee CN. Acute corneal hydrops in keratoconus - new perspectives. *Am J Ophthalmol*. 2014;157(5):921-8.
20. Lahoud S, Brownstein S, Laflamme MY, et al. Keratoconus with spontaneous perforation of the cornea. *Can J Ophthalmol*. 1987;22(4):230-3.
21. Yeh S, Smith JA. Management of acute hydrops with perforation in a patient with keratoconus and cone dystrophy: case report and literature review. *Cornea*. 2008;27(9):1062-5.
22. Fernandes M, Vira D. Patch graft for corneal perforation following trivial trauma in bilateral Terrien's marginal degeneration. *Middle East Afr J Ophthalmol*. 2015;22(2):255-7.
23. Huang D, Qiu WY, Zhang B, et al. Peripheral deep anterior lamellar keratoplasty using a cryopreserved donor cornea for Terrien's marginal degeneration. *J Zhejiang Univ Sci B*. 2014;15(12):1055-63.



SELECTIVELY AND EFFECTIVELY TARGET VIRUS INFECTED CELLS

- Inactive in healthy corneal cells¹
- Up to 77% of dendritic ulcers resolved at Day 7^{2,3,*}



*As demonstrated in a phase 3 open-label, randomized, controlled, multicenter clinical trial (N=164) in which patients with herpetic keratitis received either ZIRGAN[®] or acyclovir ophthalmic ointment 3%, administered 5 times daily until healing of ulcer and then 3 times daily for 1 week. Clinical resolution (healed ulcers) at day 7 was achieved in 77% (55/71) of patients treated with ZIRGAN[®] versus 72% (48/67) treated with acyclovir (difference, 5.8%; 95% CI, -9.6%-18.3%). ZIRGAN[®] was noninferior to acyclovir in patients with dendritic ulcers.

Indication

ZIRGAN[®] (ganciclovir ophthalmic gel) 0.15% is a topical ophthalmic antiviral that is indicated for the treatment of acute herpetic keratitis (dendritic ulcers).

Important Safety Information about ZIRGAN[®]

- ZIRGAN[®] is indicated for topical ophthalmic use only.
- Patients should not wear contact lenses if they have signs or symptoms of herpetic keratitis or during the course of therapy with ZIRGAN[®].
- Most common adverse reactions reported in patients were blurred vision (60%), eye irritation (20%), punctate keratitis (5%), and conjunctival hyperemia (5%).
- Safety and efficacy in pediatric patients below the age of 2 years have not been established.

Please see brief summary of Prescribing Information on the adjacent page.

References: 1. Foster CS. Ganciclovir gel—a new topical treatment for herpetic keratitis. *US Ophthalmic Rev.* 2008;3(1):52-56.
2. ZIRGAN Prescribing Information, April 2014. 3. Croxtall JD. Ganciclovir Ophthalmic Gel 0.15% in Acute Herpetic Keratitis (Dendritic Ulcers). *Drugs.* 2011;71(5):603-610.

BAUSCH + LOMB

Zirgan is a trademark of Laboratoires Théa Corporation used under license.
© 2015 Bausch & Lomb Incorporated. All rights reserved. US/ZGN/15/0002



BRIEF SUMMARY OF PRESCRIBING INFORMATION

This Brief Summary does not include all the information needed to use Zirgan safely and effectively. See full prescribing information for Zirgan.

Zirgan ganciclovir ophthalmic gel 0.15%
Initial U.S. Approval: 1989

1 INDICATIONS AND USAGE

ZIRGAN (ganciclovir ophthalmic gel) 0.15% is indicated for the treatment of acute herpetic keratitis (dendritic ulcers).

2 DOSAGE AND ADMINISTRATION

The recommended dosing regimen for ZIRGAN is 1 drop in the affected eye 5 times per day (approximately every 3 hours while awake) until the corneal ulcer heals, and then 1 drop 3 times per day for 7 days.

3 DOSAGE FORMS AND STRENGTHS

ZIRGAN contains 0.15% of ganciclovir in a sterile preserved topical ophthalmic gel.

4 CONTRAINDICATIONS

None.

5 WARNINGS AND PRECAUTIONS

5.1 Topical Ophthalmic Use Only

ZIRGAN is indicated for topical ophthalmic use only.

5.2 Avoidance of Contact Lenses

Patients should not wear contact lenses if they have signs or symptoms of herpetic keratitis or during the course of therapy with ZIRGAN.

6 ADVERSE REACTIONS

Most common adverse reactions reported in patients were blurred vision (60%), eye irritation (20%), punctate keratitis (5%), and conjunctival hyperemia (5%).

8 USE IN SPECIFIC POPULATIONS

8.1 Pregnancy: Teratogenic Effects

Pregnancy Category C: Ganciclovir has been shown to be embryotoxic in rabbits and mice following intravenous administration and teratogenic in rabbits. Fetal resorptions were present in at least 85% of rabbits and mice administered 60 mg/kg/day and 108 mg/kg/day (approximately 10,000x and 17,000x the human ocular dose of 6.25 mcg/kg/day), respectively, assuming complete absorption. Effects observed in rabbits included: fetal growth retardation, embryolethality, teratogenicity, and/or maternal toxicity. Teratogenic changes included cleft palate, anophthalmia/microphthalmia, aplastic organs (kidney and pancreas), hydrocephaly, and brachygnathia. In mice, effects observed were maternal/fetal toxicity and embryolethality. Daily intravenous doses of 90 mg/kg/day (14,000x the human ocular dose) administered to female mice prior to mating, during gestation, and during lactation caused hypoplasia of the testes and seminal vesicles in the month-old male offspring, as well as pathologic changes in the nonglandular region of the stomach (see Carcinogenesis, Mutagenesis, and Impairment of Fertility).

There are no adequate and well-controlled studies in pregnant women. ZIRGAN should be used during pregnancy only if the potential benefit justifies the potential risk to the fetus.

8.3 Nursing Mothers

It is not known whether topical ophthalmic ganciclovir administration could result in sufficient systemic absorption to produce detectable quantities in breast milk. Caution should be exercised when ZIRGAN is administered to nursing mothers.

8.4 Pediatric Use

Safety and efficacy in pediatric patients below the age of 2 years have not been established.

8.5 Geriatric Use

No overall differences in safety or effectiveness have been observed between elderly and younger patients.

12 CLINICAL PHARMACOLOGY

12.1 Mechanism of Action

ZIRGAN (ganciclovir ophthalmic gel) 0.15% contains the active ingredient, ganciclovir, which is a guanosine derivative that, upon phosphorylation, inhibits DNA replication by herpes simplex viruses (HSV). Ganciclovir

is transformed by viral and cellular thymidine kinases (TK) to ganciclovir triphosphate, which works as an antiviral agent by inhibiting the synthesis of viral DNA in 2 ways: competitive inhibition of viral DNA-polymerase and direct incorporation into viral primer strand DNA, resulting in DNA chain termination and prevention of replication.

12.3 Pharmacokinetics

The estimated maximum daily dose of ganciclovir administered as 1 drop, 5 times per day is 0.375 mg. Compared to maintenance doses of systemically administered ganciclovir of 900 mg (oral valganciclovir) and 5 mg/kg (IV ganciclovir), the ophthalmically administered daily dose is approximately 0.04% and 0.1% of the oral dose and IV doses, respectively, thus minimal systemic exposure is expected.

13 NONCLINICAL TOXICOLOGY

13.1 Carcinogenesis, Mutagenesis, and Impairment of Fertility

Ganciclovir was carcinogenic in the mouse at oral doses of 20 and 1,000 mg/kg/day (approximately 3,000x and 160,000x the human ocular dose of 6.25 mcg/kg/day, assuming complete absorption). At the dose of 1,000 mg/kg/day there was a significant increase in the incidence of tumors of the preputial gland in males, forestomach (nonglandular mucosa) in males and females, and reproductive tissues (ovaries, uterus, mammary gland, clitoral gland, and vagina) and liver in females. At the dose of 20 mg/kg/day, a slightly increased incidence of tumors was noted in the preputial and harderian glands in males, forestomach in males and females, and liver in females. No carcinogenic effect was observed in mice administered ganciclovir at 1 mg/kg/day (160x the human ocular dose). Except for histocytic sarcoma of the liver, ganciclovir-induced tumors were generally of epithelial or vascular origin. Although the preputial and clitoral glands, forestomach and harderian glands of mice do not have human counterparts, ganciclovir should be considered a potential carcinogen in humans. Ganciclovir increased mutations in mouse lymphoma cells and DNA damage in human lymphocytes in vitro at concentrations between 50 to 500 and 250 to 2,000 mcg/mL, respectively.

In the mouse micronucleus assay, ganciclovir was clastogenic at doses of 150 and 500 mg/kg (IV) (24,000x to 80,000x human ocular dose) but not 50 mg/kg (8,000x human ocular dose). Ganciclovir was not mutagenic in the Ames Salmonella assay at concentrations of 500 to 5,000 mcg/mL. Ganciclovir caused decreased mating behavior, decreased fertility, and an increased incidence of embryolethality in female mice following intravenous doses of 90 mg/kg/day (approximately 14,000x the human ocular dose of 6.25 mcg/kg/day). Ganciclovir caused decreased fertility in male mice and hypospermatogenesis in mice and dogs following daily oral or intravenous administration of doses ranging from 0.2 to 10 mg/kg (30x to 1,600x the human ocular dose).

14 CLINICAL STUDIES

In one open-label, randomized, controlled, multicenter clinical trial which enrolled 164 patients with herpetic keratitis, ZIRGAN was non-inferior to acyclovir ophthalmic ointment, 3% in patients with dendritic ulcers. Clinical resolution (healed ulcers) at Day 7 was achieved in 77% (55/71) for ZIRGAN versus 72% (48/67) for acyclovir 3% (difference 5.8%, 95% CI - 9.6%-18.3%). In three randomized, single-masked, controlled, multicenter clinical trials which enrolled 213 total patients, ZIRGAN was non-inferior to acyclovir ophthalmic ointment 3% in patients with dendritic ulcers. Clinical resolution at Day 7 was achieved in 72% (41/57) for ZIRGAN versus 69% (34/49) for acyclovir (difference 2.5%, 95% CI - 15.6%-20.9%).

17 PATIENT COUNSELING INFORMATION

This product is sterile when packaged. Patients should be advised not to allow the dropper tip to touch any surface, as this may contaminate the gel. If pain develops, or if redness, itching, or inflammation becomes aggravated, the patient should be advised to consult a physician. Patients should be advised not to wear contact lenses when using ZIRGAN.

Revised: April 2014

ZIRGAN is a trademark of Laboratoires Théa Corporation licensed by Bausch & Lomb Incorporated.

Bausch & Lomb Incorporated
Tampa, FL 33637
© Bausch & Lomb Incorporated

US/ZGN/15/0005
Based on 9224702 (flat)-9224802 (folded)

PHACOMORPHIC GLAUCOMA

Signs and Symptoms

Patients presenting with phacomorphic glaucoma are typically elderly, female and of small stature with moderate hyperopia. Frequently, an advanced cataract will be present in the affected eye.

In these cases, visual acuity is poor, often reduced to 20/400 or worse. There will be a shallow anterior chamber and possibly iris bombé. In eyes with markedly asymmetric cataract formation, the depth of the anterior chambers may be accordingly disparate. Patients may present with an acute onset of ocular redness and pain with an edematous cornea and elevated intraocular pressure (IOP), as typically seen in an acute angle closure attack. Gonioscopically, minimal to no anterior chamber angle structures will be visible during an acute event.¹⁻³ The resultant secondary angle closure may be either acute, subacute or chronic, and can occur in eyes with previously open angles, as well as in those with previously narrow, occludable angles.⁴⁻⁶ In cases of chronic angle closure occurring from phacomorphism, no symptoms will be present.

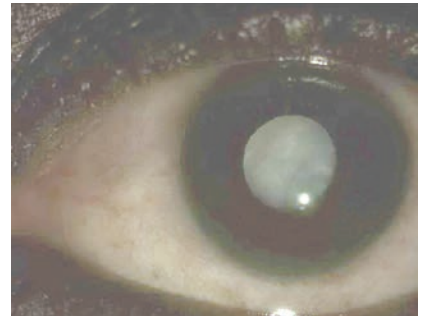
Phacomorphic glaucoma can also occur in the absence of an intumescent cataract. In these cases, a spherical shape of the lens (spherophakia, microspherophakia or nanophthalmos) can induce both pupil block and secondary angle closure. While isolated spherophakia has been reported, typically it occurs in the presence of a related syndrome such as Weill-Marchesani syndrome, Marfan syndrome, Alport syndrome, Klinefelter syndrome, Fanconi anemia and homocystenemia.⁷⁻¹¹ These patients will typically have a clear crystalline lens and a high degree of lenticular myopia.¹²

Pathophysiology

Phacomorphic glaucoma develops secondary to the shape of the lens. As the lens becomes intumescent and thickened through the process of cataractogenesis, a relative pupil block with secondary angle closure can occur, including all of the attendant signs and symptoms of an acute angle closure attack. The glaucomatous mechanism is secondary angle closure with pupil block. Intermittent angle closure with sporadic symptoms or asymptomatic chronic angle closure can also occur.¹² Alternately, the swelling of the lens may press upon the iris and ciliary body, forcing them anteriorly, and shallowing the anterior chamber without true pupil block. Thus, an angle closure may be created that does not respond to laser peripheral iridotomy (LPI).^{4,5,13}

Phacomorphic glaucoma can easily be confused with acute primary angle closure. Gonioscopic examination of the fellow anterior chamber looking for asymmetry of the anterior chamber angle depth should be performed. Asymmetric anterior chamber depths would suggest a secondary angle closure rather than a primary angle closure patient. Anterior segment optical coherence tomography (AS-OCT) can also assist in differentiating these conditions.

Phacomorphic angle closure eyes have greater axial length and lens vault, and lesser anterior chamber depth than acute primary angle closure eyes. Anterior chamber depth <1.59mm and lens vault >1,042µm are two sensitive biometric parameters that could highly discriminate phacomorphic angle closure from acute primary angle closure eyes.¹⁴ Similarly, phacomorphic angle closure can be confused with eyes that have primary angle closure and mature cataract, but without a true phacomorphic component. Again, low anterior chamber depth and volume, and high lens vault on AS-OCT serve to identify true phacomorphic angle closure.¹⁵



Intumescent cataract causing phacomorphic glaucoma.

Management

As with acute primary angle closure glaucoma, medical therapy is initially used to acutely lower the IOP. Beta-blockers, alpha-2 adrenergic agonists, topical corticosteroids, topical or oral carbonic anhydrase inhibitors, and oral hyperosmotics may be all systematically employed. Miotics are controversial in the treatment of phacomorphic glaucoma and should probably be avoided. An exceptional effect of prostaglandin analogs in managing the IOP of patients with chronic angle closure glaucoma before and following LPI has been reported.¹⁶⁻¹⁸ Aggressive IOP control and preoperatively shortening the duration of the attack is essential to improving the final visual outcome.¹⁹

In cases where pupil block precipitates the angle closure, LPI is indicated following medical treatment to attempt to relieve the resultant aqueous congestion and IOP rise.²⁰ This is especially true when a relative pupil block secondary to the unusual lens anatomy is the main pathogenesis. In cases in which pupil block is not the primary component of the angle closure, argon laser peripheral iridoplasty (ALPI) can be attempted to pull the peripheral iris from the angle apposition and temporize the condition until the patient has lens extraction.^{21,22} One study suggests that ALPI offers greater safety, consistency and efficacy than systemic IOP-lowering medications as initial

treatment for acute phacomorphic angle closure.²³

Should ALPI and/or argon laser iridoplasty combined with topical anti-glaucoma medications relieve pupil block and successfully lower and stabilize IOP, then patients with phacomorphic glaucoma could potentially continue medical therapy, especially if poor visual potential following lens removal is suspected or surgical complications are anticipated. Lens extraction ultimately relieves the condition. The decision in these cases is contingent upon the potential visual improvement with lens removal. Extracapsular cataract extraction, either with or without secondary lens implantation, has historically been the most common procedure to correct phacomorphic glaucoma.²⁴⁻²⁶ Manual small-incision cataract surgery is safe and effective in controlling IOP and restoring visual function.^{27,28} Phacoemulsification combined with anterior vitrectomy is also an option in these cases.^{29,30} Femtosecond laser-assisted cataract surgery may be a viable option.³¹

Acute phacomorphic angle closure attack has been shown to accelerate retinal nerve fiber layer thinning.³² Often, the patient has a poor visual outcome secondary to both surgical complications as well as lens-induced glaucoma.²⁴ This is especially true for patients over 60 years of age and those in whom the glaucoma has persisted beyond five days.³²⁻³⁴ Thus, acute phacomorphic angle closure attacks must be managed expeditiously for the best visual outcome.

Clinical Pearls

- While acute primary angle closure is typically symmetrical, phacomorphic glaucoma is not. Be aware of the possibility of a narrow angle and shallow chamber in patients with advanced, unilateral cataract.
- Long-term miotic usage in patients with mature cataracts may predispose

the patient to phacomorphic glaucoma.

- Primary open angle glaucoma patients may develop angle closure and phacomorphic glaucoma with continued cataract development. Perform gonioscopy at least every two years on all glaucoma patients and perhaps more frequently in patients with developing cataracts.
- Highly myopic patients experiencing any form of pupil block angle closure should be suspected of having phacomorphic glaucoma secondary to spherophakia, especially in the absence of cataract.
- Prostaglandin analogs are an excellent medical choice for patients with chronic angle closure and phacomorphic glaucoma, but should be avoided in acute angle closure cases.
- Phacomorphic glaucoma is the most common lens-induced glaucoma and is seen more frequently in developing countries with limited medical care.

- Abramson DH, Franzen LA, Coleman DJ. Pilocarpine in the presbyope: Demonstration of an effect on the anterior chamber and lens thickness. *Arch Ophthalmol* 1973; 89(2):100-2.
- Gorin G. Angle closure glaucoma induced by miotics. *Am J Ophthalmol* 1966; 62(6):1063-6.
- Gayton JL, Ledford JK. Angle closure glaucoma following a combined blepharoplasty and ectropion repair. *Ophthalm Plast Reconstr Surg*. 1992;8(3):176-7.
- Pradhan D, Hennig A, Kumar J, et al. A prospective study of 413 cases of lens-induced glaucoma in Nepal. *Indian J Ophthalmol*. 2001;49(2):103-7.
- Prajna NV, Ramakrishnan R, Krishnadas R, et al. Lens induced glaucomas—visual results and risk factors for final visual acuity. *Indian J Ophthalmol*. 1996;44(3):149-55.
- Angra SK, Pradhan R, Garg SP. Cataract induced glaucoma—an insight into management. *Indian J Ophthalmol*. 1991;39(3):97-101.
- Kaushik S, Sachdev N, Pandav SS, et al. Bilateral acute angle closure glaucoma as a presentation of isolated microspherophakia in an adult: case report. *BMC Ophthalmol*. 2006;6:29.
- Taylor JN. Weill-Marchesani syndrome complicated by secondary glaucoma. Case management with surgical lens extraction. *Aust N Z J Ophthalmol*. 1996;24(3):275-8.
- Chung JL, Kim SW, Kim JH, et al. A case of Weill-Marchesani syndrome with inversion of chromosome 15. *Korean J Ophthalmol*. 2007;21(4):255-60.
- Elgohary MA, Lim KS, Siriwardena D, et al. Increased crystalline lens thickness and phacomorphic glaucoma in patients with Fanconi anemia. *J Cataract Refract Surg*. 2006;32(10):1771-4.
- Kanamori A, Nakamura M, Matsui N, et al. Goniosynechialysis with lens aspiration and posterior chamber intraocular lens implantation for glaucoma in spherophakia. *J Cataract Refract Surg*. 2004;30(2):513-6.

- Sowka J, Giris N, Bilateral phacomorphic angle-closure glaucoma in a highly myopic patient secondary to isolated spherophakia. *Optometry*. 2010;81(9):432-6.
- Sowka J. Phacomorphic glaucoma: case and review. *Optometry*. 2006;77(12):586-9.
- Moghimi S, Ramezani F, He M, et al. Comparison of anterior segment-optical coherence tomography parameters in phacomorphic angle closure and acute angle closure eyes. *Invest Ophthalmol Vis Sci*. 2015;56(13):7611-7.
- Senthil S, Chinta S, Rao HL, et al. Comparison of cataract surgery alone versus cataract surgery combined with trabeculectomy in the management of phacomorphic glaucoma. *J Glaucoma*. 2016;25(3):e209-13.
- How AC, Kumar RS, Chen YM, et al. A randomised crossover study comparing bimatoprost and latanoprost in subjects with primary angle closure glaucoma. *Br J Ophthalmol*. 2009;93(6):782-6.
- Chen MJ, Chen YC, Chou CK, et al. Comparison of the effects of latanoprost and bimatoprost on intraocular pressure in chronic angle-closure glaucoma. *J Ocul Pharmacol Ther*. 2007;23(6):559-66.
- Chen MJ, Chen YC, Chou CK, et al. Comparison of the effects of latanoprost and travoprost on intraocular pressure in chronic angle-closure glaucoma. *J Ocul Pharmacol Ther*. 2006;22(6):449-54.
- Das JC, Chaudhuri Z, Bhomaj S, et al. Combined extracapsular cataract extraction with ahmed glaucoma valve implantation in phacomorphic glaucoma. *Indian J Ophthalmol*. 2002;50(1):25-8.
- Tomey KF, al-Rajhi AA. Neodymium:YAG laser iridotomy in the initial management of phacomorphic glaucoma. *Ophthalmology*. 1992;99(5):660-5.
- Thyagarajan S. Immediate argon peripheral iridoplasty (ALPI) as initial treatment phacomorphic glaucoma: a safe and cost-effective treatment? *Eye*. 2005;19(7):778-83.
- Yip PP, Leung WY, Hon CY, et al. Argon laser peripheral iridoplasty in the management of phacomorphic glaucoma. *Ophthalmic Surg Lasers Imaging*. 2005;36(4):286-91.
- Lee JW, Lai JS, Yick DW, et al. Argon laser peripheral iridoplasty versus systemic intraocular pressure-lowering medications as immediate management for acute phacomorphic angle closure. *Clin Ophthalmol*. 2013;7:63-9.
- Prajna NV, Ramakrishnan R, Krishnadas R, et al. Lens induced glaucomas—visual results and risk factors for final visual acuity. *Indian J Ophthalmol*. 1996;44(3):149-55.
- McKibbin M, Gupta A, Atkins AD. Cataract extraction and intraocular lens implantation in eyes with phacomorphic or phacolytic glaucoma. *J Cataract Refract Surg*. 1996;22(5):633-6.
- Rao SK, Padmanabhan P. Capsulorhexis in eyes with phacomorphic glaucoma. *J Cataract Refract Surg*. 1998;24(7):882-4.
- Venkatesh R, Chang DF, Muralikrishnan R, et al. manual small incision cataract surgery: a review. *Asia Pac J Ophthalmol (Phila)*. 2012;1(2):113-9.
- Ramakrishnan R, Maheshwari D, Kader MA, et al. Visual prognosis, intraocular pressure control and complications in phacomorphic glaucoma following manual small incision cataract surgery. *Indian J Ophthalmol*. 2010;58(4):303-6.
- Dada T, Kumar S, Gadia R, et al. Sutureless single-port transconjunctival pars plana limited vitrectomy combined with phacoemulsification for management of phacomorphic glaucoma. *J Cataract Refract Surg*. 2007;33(6):951-4.
- Miura S, Ieki Y, Ogino K, et al. Primary phacoemulsification and aspiration combined with 25-gauge single-port vitrectomy for management of acute angle closure. *Eur J Ophthalmol*. 2008;18(3):450-2.

A white plastic bottle of ALREX eye drops with a pink cap sits on a grassy hillside. The background is a vibrant field of wildflowers and greenery under a clear blue sky. The bottle label reads: Bausch & Lomb, Alrex, loteprednol etabonate ophthalmic suspension 0.2%.

ALREX®:

TREATS THE ITCH AND MORE.

SHORT-TERM TREATMENT FOR
THE FULL SPECTRUM OF SAC*
SIGNS AND SYMPTOMS¹⁻³

*Seasonal allergic conjunctivitis.

INDICATION

ALREX® (loteprednol etabonate ophthalmic suspension) is indicated for the temporary relief of the signs and symptoms of seasonal allergic conjunctivitis.

IMPORTANT SAFETY INFORMATION

ALREX® is contraindicated in most viral diseases of the cornea and conjunctiva, including epithelial herpes simplex keratitis (dendritic keratitis), vaccinia, and varicella, and also in mycobacterial infection of the eye and fungal diseases of the ocular structures. ALREX® is also contraindicated in individuals with known or suspected hypersensitivity to any of the ingredients of this preparation and to other corticosteroids.

Prolonged use of ALREX® is associated with several warnings and precautions, including glaucoma with optic nerve damage, defects in visual acuity, cataract formation, secondary ocular infections, and exacerbation or prolongation of viral ocular infections (including herpes simplex).

If this product is used for 10 days or longer, intraocular pressure should be monitored. The initial prescription and renewal of the medication order beyond 14 days should be made by a physician only after reexamination of the patient with the aid of magnification. Fungal infections of the cornea may develop with prolonged use of corticosteroids.

Ocular adverse reactions occurring in 5-15% of patients treated with loteprednol etabonate ophthalmic suspension (0.2%-0.5%) in clinical studies included abnormal vision/blurring, burning on instillation, chemosis, discharge, dry eyes, epiphora, foreign body sensation, itching, infection, and photophobia.

Please see brief summary of full Prescribing Information on the following page.

References: 1. ALREX [package insert]. Tampa, FL: Bausch & Lomb Incorporated; 2013. 2. Dell SJ, Lowry GM, Northcutt JA, Howes J, Novack GD, Hart K. A randomized, double-masked, placebo-controlled parallel study of 0.2% loteprednol etabonate in patients with seasonal allergic conjunctivitis. *J Allergy Clin Immunol.* 1998;102(2):251-255. 3. Shulman DG, Lothringer LL, Rubin JM, et al. A randomized, double-masked, placebo-controlled parallel study of loteprednol etabonate 0.2% in patients with seasonal allergic conjunctivitis. *Ophthalmology.* 1999;106(2):362-369.

BAUSCH + LOMB

ALREX is a trademark of Bausch & Lomb Incorporated or its affiliates.
©Bausch & Lomb Incorporated. US/ALX/15/0001a

Alrex®

loteprednol etabonate
ophthalmic suspension 0.2%

BRIEF SUMMARY OF PRESCRIBING INFORMATION

This Brief Summary does not include all the information needed to use Alrex® (loteprednol etabonate ophthalmic suspension 0.2%) safely and effectively. See full prescribing information for Alrex.

Alrex®

loteprednol etabonate
ophthalmic suspension 0.2%

Sterile Ophthalmic Suspension

Rx only

INDICATIONS AND USAGE

ALREX Ophthalmic Suspension is indicated for the temporary relief of the signs and symptoms of seasonal allergic conjunctivitis.

CONTRAINDICATIONS

ALREX, as with other ophthalmic corticosteroids, is contraindicated in most viral diseases of the cornea and conjunctiva including epithelial herpes simplex keratitis (dendritic keratitis), vaccinia, and varicella, and also in mycobacterial infection of the eye and fungal diseases of ocular structures. ALREX is also contraindicated in individuals with known or suspected hypersensitivity to any of the ingredients of this preparation and to other corticosteroids.

WARNINGS

Prolonged use of corticosteroids may result in glaucoma with damage to the optic nerve, defects in visual acuity and fields of vision, and in posterior subcapsular cataract formation. Steroids should be used with caution in the presence of glaucoma.

Prolonged use of corticosteroids may suppress the host response and thus increase the hazard of secondary ocular infections. In those diseases causing thinning of the cornea or sclera, perforations have been known to occur with the use of topical steroids. In acute purulent conditions of the eye, steroids may mask infection or enhance existing infection.

Use of ocular steroids may prolong the course and may exacerbate the severity of many viral infections of the eye (including herpes simplex). Employment of a corticosteroid medication in the treatment of patients with a history of herpes simplex requires great caution.

PRECAUTIONS

General: For ophthalmic use only. The initial prescription and renewal of the medication order beyond 14 days should be made by a physician only after examination of the patient with the aid of magnification, such as slit lamp biomicroscopy and, where appropriate, fluorescein staining. If signs and symptoms fail to improve after two days, the patient should be re-evaluated.

If this product is used for 10 days or longer, intraocular pressure should be monitored.

Fungal infections of the cornea are particularly prone to develop coincidentally with long-term local steroid application. Fungus invasion must be considered in any persistent corneal ulceration where a steroid has been used or is in use. Fungal cultures should be taken when appropriate.

Information for Patients: This product is sterile when packaged. Patients should be advised not to allow the dropper tip to touch any surface, as this may contaminate the suspension. If redness or itching becomes aggravated, the patient should be advised to consult a physician.

Patients should be advised not to wear a contact lens if their eye is red. ALREX should not be used to treat contact lens related irritation. The preservative in ALREX, benzalkonium chloride, may be absorbed by soft contact lenses. Patients who wear soft contact lenses **and whose eyes are not red**, should be instructed to wait at least ten minutes after instilling ALREX before they insert their contact lenses.

Carcinogenesis, Mutagenesis, Impairment of Fertility: Long-term animal studies have not been conducted to evaluate the carcinogenic potential of loteprednol etabonate. Loteprednol etabonate was not genotoxic *in vitro* in the Ames test, the mouse lymphoma tk assay, or in a chromosome aberration test in human lymphocytes, or *in vivo* in the single dose mouse micronucleus assay. Treatment of male and female rats with up to 50 mg/kg/day and 25 mg/kg/day of loteprednol etabonate, respectively, (1500 and 750 times the maximum clinical dose, respectively) prior to and during mating did not impair fertility in either gender.

Pregnancy: Teratogenic effects: Pregnancy Category C. Loteprednol etabonate has been shown to be embryotoxic (delayed ossification) and teratogenic (increased incidence of meningocele, abnormal left common carotid artery, and limb flexures) when administered orally to rabbits during organogenesis at a dose of 3 mg/kg/day (85 times the maximum daily clinical dose), a dose which caused no maternal toxicity. The no-observed-effect-level (NOEL) for these effects was 0.5 mg/kg/day (15 times the maximum daily clinical dose). Oral treatment of rats during organogenesis resulted in teratogenicity (absent innominate artery at ≥ 5 mg/kg/day doses, and cleft palate and umbilical hernia at ≥ 50 mg/kg/day) and embryotoxicity (increased postimplantation losses at 100 mg/kg/day and decreased fetal body weight and skeletal ossification with ≥ 50 mg/kg/day). Treatment of rats with 0.5 mg/kg/day (15 times the maximum clinical dose) during organogenesis did not result in any reproductive toxicity. Loteprednol etabonate was maternally toxic (significantly reduced body weight gain during treatment) when administered to pregnant rats during organogenesis at doses of ≥ 5 mg/kg/day.

Oral exposure of female rats to 50 mg/kg/day of loteprednol etabonate from the start of the fetal period through the end of lactation, a maternally toxic treatment regimen (significantly decreased body weight gain), gave rise to decreased growth and survival, and retarded development in the offspring during lactation; the NOEL for these effects was 5 mg/kg/day. Loteprednol etabonate had no effect on the duration of gestation or parturition when administered orally to pregnant rats at doses up to 50 mg/kg/day during the fetal period.

There are no adequate and well controlled studies in pregnant women. ALREX Ophthalmic Suspension should be used during pregnancy only if the potential benefit justifies the potential risk to the fetus.

Nursing Mothers: It is not known whether topical ophthalmic administration of corticosteroids could result in sufficient systemic absorption to produce detectable quantities in human milk. Systemic steroids appear in human milk and could suppress growth, interfere with endogenous corticosteroid production, or cause other untoward effects. Caution should be exercised when ALREX is administered to a nursing woman.

Pediatric Use: Safety and effectiveness in pediatric patients have not been established.

ADVERSE REACTIONS

Reactions associated with ophthalmic steroids include elevated intraocular pressure, which may be associated with optic nerve damage, visual acuity and field defects, posterior subcapsular cataract formation, secondary ocular infection from pathogens including herpes simplex, and perforation of the globe where there is thinning of the cornea or sclera.

Ocular adverse reactions occurring in 5-15% of patients treated with loteprednol etabonate ophthalmic suspension (0.2% - 0.5%) in clinical studies included abnormal vision/blurring, burning on instillation, chemosis, discharge, dry eyes, epiphora, foreign body sensation, itching, injection, and photophobia. Other ocular adverse reactions occurring in less than 5% of patients include conjunctivitis, corneal abnormalities, eyelid erythema, keratoconjunctivitis, ocular irritation/pain/discomfort, papillae, and uveitis. Some of these events were similar to the underlying ocular disease being studied.

Non-ocular adverse reactions occurred in less than 15% of patients. These include headache, rhinitis and pharyngitis.

In a summation of controlled, randomized studies of individuals treated for 28 days or longer with loteprednol etabonate, the incidence of significant elevation of intraocular pressure (≥ 10 mm Hg) was 2% (15/901) among patients receiving loteprednol etabonate, 7% (11/164) among patients receiving 1% prednisolone acetate and 0.5% (3/583) among patients receiving placebo. Among the smaller group of patients who were studied with ALREX, the incidence of clinically significant increases in IOP (≥ 10 mm Hg) was 1% (1/133) with ALREX and 1% (1/135) with placebo.

DOSAGE AND ADMINISTRATION

SHAKE VIGOROUSLY BEFORE USING.

One drop instilled into the affected eye(s) four times daily.

Revised: August 2013.

Bausch & Lomb Incorporated, Tampa, Florida 33637

©Bausch & Lomb Incorporated

Alrex® is a registered trademark of Bausch & Lomb Incorporated

Based on 9007904-9005504

US/ALX/15/0004

Issued: 02/2015

31. Kránitz K, Takács AI, Gyenes A, et al. Femtosecond laser-assisted cataract surgery in management of phacomorphic glaucoma. *J Refract Surg.* 2013;29(9):645-8.
32. Lee JW, Lai JS, Yick DW, et al. Prospective study on retinal nerve fibre layer changes after an acute episode of phacomorphic angle closure. *Int Ophthalmol.* 2012;32(6):577-82.
33. Lim TH, Tan DT, Fu ER. Advanced cataract in Singapore—its prognosis and complications. *Ann Acad Med Singapore.* 1993;22(6):891-4.
34. Lee JW, Lai JS, Yick DW, et al. Retrospective case series on the long-term visual and intraocular pressure outcomes of phacomorphic glaucoma. *Eye (Lond).* 2010;24(11):1675-80.

PHACOLYTIC GLAUCOMA

Signs and Symptoms

Phacolytic glaucoma is a secondary glaucoma caused by an autoimmune inflammation due to a hypermature cataract that is leaking lens proteins. It typically develops in elderly patients with a history of progressively worsening vision from hypermaturing cataracts. There is often a longstanding history of vision loss in the affected eye. There appears to be no gender predilection.^{1,2} Vision typically is reduced to light perception or worse, due to the presence of a hypermature cataract or end-stage glaucoma, and the patient may experience ocular pain from a uveitis or acute rise in intraocular pressure (IOP).¹

The acute process is characterized by anterior segment inflammation with an anterior chamber reaction; a hypermature lens is invariably present. Lens intumescence prevents ophthalmoscopic observation of the fundus, and IOP may be quite elevated, possibly exceeding 50mm Hg to 70mm Hg.^{1,2} The resultant glaucoma is typically unilateral or asymmetric, depending upon the degree of cataractogenesis. Synechiae, either anterior or posterior, are uncommon.

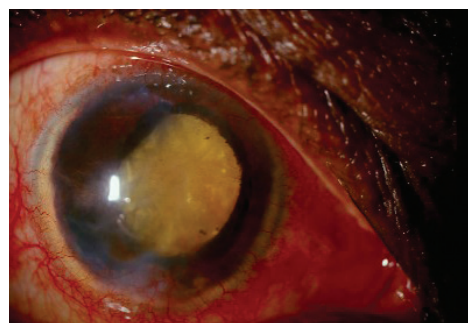
Pathophysiology

Upon cataract hypermaturation, the lens cortex undergoes spontaneous lysis and absorption, with secondary lens nucleus shrinkage and capsule wrinkling.^{3,4} This allows internal lens proteins to leak out through an intact (though permeable)

lens capsule.¹ Scanning electron microscopy has shown that disruptions of the anterior lens capsule enables nuclear contents to be released.⁵ The internal lens proteins, though part of the host's own body tissue, have never been exposed to the anterior chamber, as a result of their envelopment by the lens capsule. Thus, when the body detects these internal lens proteins, it interprets them as foreign and antigenic. Subsequently, a lens-induced inflammatory reaction ensues.³ Chemotactic activity induced by the internal lens proteins contributes to the invasion of the anterior chamber by inflammatory cells in an antigen-antibody immune response.⁴ There is a pronounced macrophage response occurring in the anterior chamber.⁶ Numerous macrophages containing phagocytized degenerated lens material (phacolytic cells) can be found in the anterior chamber.⁶

White patches consisting of aggregated macrophages may be seen on the lens surface, often indicating the site of lens protein leakage.^{7,8} Other constituents of the anterior chamber in phacolysis have been demonstrated to include free-floating, degenerated lens material, erythrocytes and dehemoglobinized ghost erythrocytes.⁷ Lipofuscin granules and phagocytic vacuoles containing lens proteins have also been found.⁶

Elevated levels of high molecular weight (HMW) soluble proteins of sufficient size to block trabecular aqueous outflow have been found in patients with phacolytic glaucoma, and studies have demonstrated that HMW soluble proteins can directly obstruct aqueous outflow.^{9,10} It may be that macrophages are scavenger cells that attempt to remove lens material and reestablish normal aqueous outflow.⁹ Further, during the uveitic process, breakdown of the blood-aqueous barrier occurs with subsequent influx of proteins and



In a hypermature lytic cataract, as seen here, phacolysis can develop quite rapidly.

inflammatory cells. These constituents are considered to have a major impact on IOP elevation as well. Obstruction of the trabecular meshwork by inflammatory cells and proteins, as well as trabeculitis (inflammation of the trabecular meshwork), likely contribute to the secondary open angle glaucoma.¹¹

Phacolytic glaucoma appears to have several variations. One type is characterized by a hyperacute presentation caused by rapid leakage of degenerated lens proteins into the aqueous humor; a second type presents with a more gradual onset and with phacolytic macrophages in the aqueous humor resulting from an immunologic response to liquefied lens proteins.¹²

Phacolysis can be considered an innate evolutionary response to cataractogenesis. Prior to the advent of surgical lens removal, many individuals would become blind from cataract formation. The subsequent lytic process and inflammatory degradation would effectively remove the visual obstruction. Unfortunately, the eye would be left aphakic and often irreparably damaged from glaucoma. Spontaneous absorption of cataracts through the phacolytic process have been reported, which supports this evolutionary role of phacolysis.^{13,14} It should be emphasized that, while the cataract maturation process is typically quite slow, once a lens has become hypermature, phacolysis can develop quite rapidly.⁸

Management

The first step in the management of any case of acute glaucoma is gonioscopy. Once angle status has been determined and phacolytic glaucoma diagnosed, quieting the acute inflammatory reaction and ameliorating the elevated intraocular pressure becomes the immediate goal.¹⁵ Topical corticosteroids are indicated, just as they would be for any anterior uveitis. Cycloplegics are also indicated. The choice should be dictated by the severity of the uveitic response and the patient's degree of discomfort.

Many cases of phacolytic glaucoma may involve loss of zonular support to the lens, manifesting as phacodonesis. In cases where there is poor zonular support, cycloplegia with attendant pupil dilation may result in anterior dislocation of the lens, possibly into the anterior chamber. If poor zonular support to the lens is suspected, cycloplegia should be avoided.

The secondary glaucoma accompanying phacolysis is often improved by a reduction in inflammation with topical steroid therapy. However, if additional pressure reduction is necessary, then aqueous suppressants are advocated, pending no systemic contraindications. Miotics and prostaglandin analogs should be avoided due to their propensity to aggravate the disease.¹⁵ In extreme cases, oral agents may be necessary.

In most cases, it is necessary to remove the antigenic lens in order to fully manage phacolytic glaucoma. Historically, extracapsular—and even intracapsular—cataract extraction has been used to remove the antigenic lens with either anterior or posterior chamber intraocular lens implantation.¹⁶ Manual small-incision cataract surgery with trypan blue staining of the anterior lens capsule is a safe and effective method of cataract extraction for patients with phacolytic glaucoma, as is

phacoemulsification.¹⁷⁻¹⁹ If there is loss of zonular support, a capsular tension ring can be used to stabilize the intraocular lens implant.²⁰

In cases where there has been a long duration prior to surgery, trabeculectomy may additionally be needed in order to control IOP.²¹ Removal of the antigenic lens and control of the glaucoma should be done quickly. One study found that patients over 60 years and in whom the glaucoma was present for more than five days had a significantly higher risk of poor visual outcome postoperatively.²² More recently, reports have noted a poor visual outcome with delayed surgery.²³⁻²⁵

The addition of trabeculectomy to cataract extraction is typically unnecessary in the control of IOP in patients with phacolytic glaucoma who are operated on within two to three weeks of the onset of symptoms. Light perception without projection is not a contraindication for cataract surgery in phacolytic glaucoma, as postoperative visual recovery to some degree is possible.²⁶

Clinical Pearls

- Phacolytic glaucoma develops only in eyes with hypermature cataracts. Vision typically ranges from counting fingers to light perception. If vision is better than 20/400, consider another cause for the glaucoma and inflammation.
- Be careful to assess lens zonular integrity before employing a cycloplegic in the management of phacolytic glaucoma.
- The benefits of inflammation control in phacolytic glaucoma greatly outweigh the potential risks of steroid-induced pressure complications.
- Ultimately, phacolytic glaucoma is a surgically managed condition, though medical therapy may be initially employed to reduce inflammation and IOP.

- In eyes with phacolytic glaucoma that have no visual recovery potential whereby pain and inflammation can be managed with topical corticosteroids, aqueous suppressants and cycloplegics, lensectomy can potentially be deferred.

1. Podhorecki J, Munir A. Result of operations for hypermature cataract complicated with phacolytic glaucoma. *Klin Oczna*. 2002;104(5-6):350-3.
2. Rijal AP, Karki DB. Visual outcome and IOP control after cataract surgery in lens induced glaucomas. *Kathmandu Univ Med J (KUMJ)*. 2006;4(1):30-3.
3. Opreacu M. The etiopathology of phacoantigenic uveitis and phacolytic glaucoma. *Oftalmologia* 1992; 36(3):207-13.
4. Rosenbaum JT, Samples JR, Seymour B, et al. Chemotactic activity of lens proteins and the pathogenesis of phacolytic glaucoma. *Arch Ophthalmol* 1987;105(11):1582-4.
5. Yoo WS, Kim BJ, Chung IY, et al. A case of phacolytic glaucoma with anterior lens capsule disruption identified by scanning electron microscopy. *BMC Ophthalmol*. 2014;14:133.
6. Filipe JC, Palmares J, Delgado L, et al. Phacolytic glaucoma and lens-induced uveitis. *Int Ophthalmol*. 1993;17(5):289-93.
7. Ueno H, Tamai A, Iyota K, et al. Electron microscopic observation of the cells floating in the anterior chamber in a case of phacolytic glaucoma. *Jpn J Ophthalmol*. 1989;33(1):103-13.
8. Sowka J, Vollmer L, Falco L. Rapid onset phacolysis. *Optometry*. 2004;75(9):571-6.
9. Epstein DL, Jedziniak JA, Grant WM. Identification of heavy molecular weight soluble protein in aqueous humor in human phacolytic glaucoma. *Invest Ophthalmol Vis Sci* 1978; 17(5):398-402.
10. Epstein DL, Jedziniak JA, Grant WM. Obstruction of aqueous outflow by lens particles and by heavy molecular weight soluble lens proteins. *Invest Ophthalmol Vis Sci* 1978; 17(3):272-7.
11. Pleyer U, Ruokonen P, Heinz C, et al. Intraocular pressure related to uveitis. *Ophthalmologie*. 2008;105(5):431-7.
12. Mavarakanas N, Axmann S, Issum CV, et al. Phacolytic glaucoma: are there 2 forms? *J Glaucoma*. 2012;21(4):248-9.
13. Blaise P, Duchesne B, Guillaume S, et al. Spontaneous recovery in phacolytic glaucoma. *J Cataract Refract Surg*. 2005;31(9):1829-30.
14. Mohan M, Bartholomew RS. Spontaneous absorption of a cataractous lens. *Acta Ophthalmol Scand*. 1999;77(4):476-7.
15. Sung VC, Barton K. Management of inflammatory glaucomas. *Curr Opin Ophthalmol*. 2004;15(2):136-40.
16. Singh G, Kaur J, Mall S. Phacolytic glaucoma—its treatment by planned extracapsular cataract extraction with posterior chamber intraocular lens implantation. *Indian J Ophthalmol*. 1994;42(3):145-7.
17. Venkatesh R, Tan CS, Kumar TT, et al. Safety and efficacy of manual small incision cataract surgery for phacolytic glaucoma. *Br J Ophthalmol*. 2007;91(3):279-81.
18. Jaggernath J, Gogate P, Moodley V, et al. Comparison of cataract surgery techniques: safety, efficacy, and cost-effectiveness. *Eur J Ophthalmol*. 2014;24(4):520-6.
19. Venkatesh R, Chang DF, Murallikrishnan R, et al. Manual small incision cataract surgery: a review. *Asia Pac J Ophthalmol (Phila)*. 2012;1(2):113-9.
20. Rai G, Sahai A, Kumar PR. Outcome of Capsular Tension Ring (CTR) Implant in Complicated Cataracts. *J Clin Diagn Res*. 2015;9(12):NC05-7.

21. Braganza A, Thomas R, George T, et al. Management of phacolytic glaucoma: experience of 135 cases. *Indian J Ophthalmol.* 1998;46(3):139-43.
22. Prajna NV, Ramakrishnan R, Krishnadas R, et al. Lens induced glaucomas—visual results and risk factors for final visual acuity. *Indian J Ophthalmol.* 1996;44(3):149-55.
23. Kothari R, Tathe S, Gogri P, et al. Lens-Induced Glaucoma: The need to spread awareness about early management of cataract among rural population. *ISRN Ophthalmol.* 2013;2013:581727.
24. Yaakub A, Abdullah N, Siti Raihan I, et al. Lens-induced glaucoma in a tertiary centre in northeast of Malaysia. *Malays Fam Physician.* 2014;9(2):48-52.
25. Azhary Y, Hemalatha C, Nani D, et al. Sequelae of neglected senile cataract. *Malays Fam Physician.* 2013;8(1):33-7.
26. Mandal AK, Gothwal VK. Intraocular pressure control and visual outcome in patients with phacolytic glaucoma managed by extracapsular cataract extraction with or without posterior chamber intraocular lens implantation. *Ophthalmic Surg Lasers.* 1998;29(11):880-9.

PRIMARY CHRONIC ANGLE CLOSURE GLAUCOMA

Signs and Symptoms

The patient with primary chronic angle closure glaucoma (PCACG) typically is older and asymptomatic.¹ Women are more commonly affected than men. Typically patients will have moderate degrees of hyperopia. Patients of Asian descent are the most predisposed to PCACG, with native Alaskans being the most represented group with this condition. Caucasian patients are affected to a lesser extent and patients of African descent are affected even less.¹

Biomicroscopically, there will be a shallow anterior chamber and narrow angles by van Herick estimation method. However, the chamber depth is typically deeper in PCACG than primary acute angle closure glaucoma. There will be characteristic glaucomatous damage to the retinal nerve fiber layer, optic disc and visual field.

The distinguishing characteristic is the absence of gonioscopically visible anterior chamber angle structures. The angle may be appositionally closed and able to be opened upon manual pressure with a 4-mirror gonioscope, or the angle may be closed with broad areas of peripheral anterior synechiae (PAS).

The superior and temporal quadrants of the anterior angle may be the earliest sites of synechial angle closure, with gradual extension to the nasal quadrant, until the angle closes in the inferior quadrant.²

Pathophysiology

Anatomical features act in concert to cause shallowing of the anterior chamber. As a patient ages, thickening of the crystalline lens leads to a relative pupil block that exacerbates and partially contributes to the condition. This acts to put the iris into apposition with the trabecular meshwork or cornea. In the absence of secondary causes, this is considered to be a primary angle closure. Because the closure happens slowly, there is an absence of symptoms that would typify an acute angle closure. Thus, patients are unaware of the process.⁴

Chronic angle closure denotes an angle with areas that are closed permanently with PAS. In angles that have closure without the formation of PAS, the term *chronic appositional closure* is often used. However, over time appositional closure will lead to PAS if unaddressed. In PCACG, the intraocular pressure (IOP) may be initially normal, elevating asymptotically as more of the angle becomes compromised. Peripheral anterior synechiae may occur after acute or subacute attacks of angle closure.

While in most cases, there is asymmetric closure (involving the superior angle first), there can also be an even, circumferential process that slowly progresses to symmetrical closure. This has been termed *creeping angle closure* and appears as an angle that becomes progressively more shallow over time.⁵ In PCACG, pupillary block is not as strong a force as it is in acute primary angle closure. Thus, there is minimal iris bombé. There is more of a multi-mechanism with some degree of

pupillary block as well as an anteriorly located lens and forward-rotated ciliary body that causes shallowing of the anterior chamber and an overall congestion of the angle leading to progressive synechial closure. Other features of PCACG that lead to angle closure and subsequent PAS include a smaller corneal diameter, shorter axial length, shallower anterior chamber, swelling of ciliary process and anterior rotation of ciliary body.^{3,6}

Management

Primary angle closure resulting from any degree of pupil block is typically treated with laser peripheral iridotomy (LPI). This allows a communication for aqueous to flow from the posterior chamber to the anterior chamber, bypassing any pupil block that may be present. This can allow for the backward relaxation of the iris and a deepening of the chamber and opening of the angle. This is a safe method to attempt to open the angle following chronic closure.^{7,8}

However, while LPI can alter the anatomic status of the angle, a significant number of patients will manifest residual angle closure after LPI from PAS.⁷ Additionally, there often will be elevated IOP despite a laser-induced open anterior chamber angle.⁹ This is due to damage to the trabecular meshwork from appositional and synechial closure. In PCACG eyes, the trabecular architecture has lost its regular arrangement, with fewer and narrower trabecular spaces and fusion of the trabecular beams in areas. In addition, there is evidence of loss of endothelial cells and reactive repair processes.¹⁰

Despite the presence of a patent LPI, most eyes with PCACG present with elevated IOP, optic disc and visual field damage, indicating that further treatment to control IOP, including possible trabeculectomy and medical therapy, is needed.^{11,12}

Medical therapy that has been successful in lowering IOP in eyes with PCACG include beta-blockers, miotics, alpha-2 adrenergic agonists, and prostaglandin analogs (PGAs).^{13,14} However, in recent years, it has come to light that PGAs are especially efficacious in eyes with PCACG that need IOP reduction both before and after LPI.¹⁵⁻¹⁸ These medications are thought to lower IOP by increasing matrix metalloproteinase activity, which subsequently reduces the amount of extracellular matrix material surrounding the ciliary muscle fiber bundles that results in enhanced uveoscleral outflow.¹⁹ Once-daily dosing of any of the commercially available PGAs (travoprost, bimatoprost, latanoprost, tafluprost) reduces IOP in eyes with PCACG that have residually elevated IOP following LPI. The degree of pressure lowering seems to be similar to that seen in primary open angle glaucoma.

While the method of IOP reduction from prostaglandin analogs is well accepted to be enhanced uveoscleral outflow, it seems contradictory that these medications would have an effect in eyes where the uveoscleral meshwork is physically blocked by the iris. However, Aung et al. noted that the IOP-reducing efficacy of latanoprost was not affected by the degree of angle narrowing or extent of synechial angle closure.²⁰ In a study of 14 eyes with PCACG and total occlusion of the angle by 360 degrees (evidenced by ultrasound biomicroscopy) secondary to PAS with no visible ciliary body face, once-daily dosing with latanoprost achieved a significant reduction in IOP.²⁰

Clearly, the mechanism of action of prostaglandin analogs in eyes with complete angle closure is not completely understood. Possibly, uveoscleral tissues other than the ciliary muscle are targeted or these agents reach the uveoscleral meshwork by way of the peripheral iris.²¹

Argon laser iridoplasty has been seen as another option for the management of PCACG. This iridoretraction procedure will subsequently allow aqueous to reach the drainage meshwork by affecting the positioning of the peripheral iris and preventing this condition from deteriorating.^{22,23}

In that the crystalline lens can contribute to the development of PCACG, lensectomy remains a viable option for some eyes. Phacoemulsification and intraocular lens implantation can lower IOP, reduce or remove the critical anatomical characteristics that produce pupillary block, and subsequently increase angle width.²⁴ It has been demonstrated in eyes with PCACG and co-existing cataract that phacoemulsification cataract extraction alone can significantly reduce both IOP and the requirement for topical therapy.²⁵⁻²⁷ A meta analysis showed that phacoemulsification lowered IOP by 30% and reduced preoperative medications by 58% in PCACG.²⁸

It has been suggested that phaco may be a primary treatment for eyes with PCACG and co-existent cataract.²⁹ In comparing cataract removal to standard LPI, phacoemulsification results in greater anterior chamber depth and volume. Consequently, phacoemulsification has greater efficacy in lowering IOP and preventing its long-term increase in patients with PCACG and cataract.³⁰

In PCACG medically controlled with co-existent cataract, there appears to be no difference in IOP control with cataract extraction by phacoemulsification alone vs. the combined procedure phacotrabeculectomy.³¹ However, in eyes where preoperative IOP control with medications is not acceptable, a combined procedure with phacotrabeculectomy is superior in restoring cataract-related vision loss and postoperatively controlling IOP than

phacoemulsification alone.³² In another study, it was recommended that phacotrabeculectomy be employed for an angle closed 180 degrees continually or more, while phacoemulsification alone was sufficient for angles closed less than 180 degrees.³³ Additional goniosynechialysis does not appear to enhance IOP reduction more than phacoemulsification alone.³⁴ Be aware that glaucoma surgery for PCACG places the eye at risk for subsequent postoperative malignant glaucoma.³⁵

An additional consideration for refractory chronic angle-closure cases involves another surgical approach. While anecdotally reported recently, cyclocryodestruction may offer an alternative in selected cases.³⁶

While phacoemulsification and posterior chamber IOL placement has been clearly shown to be a very effective management for PCACG and co-existent cataract, the role of clear lensectomy (extraction of the non-cataractous lens) in patients with PCACG is unclear. Clear lens extraction has been shown to effectively lower IOP in eyes with PCACG.³⁷ However, its role still requires elucidation and scientific evidence.

The Effectiveness in Angle Closure Glaucoma of Lens Extraction (EAGLE) study—a prospective randomized clinical trial now underway—will compare the safety and effectiveness of LPI and medical therapy to clear lens extraction for patients with newly diagnosed PCACG.³⁸ It is hoped that the results of EAGLE will help guide the management of these challenging patients.

Clinical Pearls

- After the anterior chamber angle has been successfully opened by LPI, the IOP may still be elevated. Many will erroneously think that the patient has now developed primary open angle glaucoma. In actuality, the trabecular

meshwork has been damaged by the chronic appositional closure. This situation is comparable to the trabecular dysfunction seen in angle recession glaucoma.

- Gonioscopy must be done on all open angle glaucoma patients at least every two years to ascertain that the patient is not developing a concurrent angle closure mechanism.
- While it is not advocated to intentionally dilate an eye with PCACG, it is likely not to harm the patient if done unintentionally. Many patients have been dilated inadvertently without knowing the status of the angle, and there are often no ill effects.

1. Bonomi L, Marchini G, Marraffa M, et al. Epidemiology of angle-closure glaucoma: prevalence, clinical types, and association with peripheral anterior chamber depth in the Egna-Neumarkt Glaucoma Study. *Ophthalmology*. 2000;107(5):998-1003.
2. Mok KH, Lee VW. Synchial angle closure pattern in Chinese chronic primary angle-closure glaucoma patients. *J Glaucoma*. 2001;10(5):427-8.
3. Wang T, Liu L, Li Z, et al. Studies of mechanism of primary angle closure glaucoma using ultrasound biomicroscope. *Zhonghua Yan Ke Za Zhi*. 1998;34(5):365-8.
4. Tarongoy P, Ho CL, Walton DS. Angle-closure glaucoma: the role of the lens in the pathogenesis, prevention, and treatment. *Surv Ophthalmol*. 2009;54(2):211-25.
5. Lowe RF. Primary creeping angle closure glaucoma. *Br J Ophthalmol* 1964;48:544.
6. Marchini G, Chemello F, Berzaghi D, Zampieri A. New findings in the diagnosis and treatment of primary angle-closure glaucoma. *Prog Brain Res*. 2015;221:191-212.
7. He M, Friedman DS, Ge J, et al. Laser peripheral iridotomy in primary angle-closure suspects: biometric and gonioscopic outcomes: the Liwan Eye Study. *Ophthalmology*. 2007;114(3):494-500.
8. Hsiao CH, Hsu CT, Shen SC, et al. Mid-term follow-up of Nd:YAG laser iridotomy in Asian eyes. *Ophthalmic Surg Lasers Imaging*. 2003;34(4):291-8.
9. Chen MJ, Cheng CY, Chou CK, et al. The long-term effect of Nd:YAG laser iridotomy on intraocular pressure in Taiwanese eyes with primary angle-closure glaucoma. *J Chin Med Assoc*. 2008;71(6):300-4.
10. Sihota R, Lakshmaiah NC, Wallia KB, et al. The trabecular meshwork in acute and chronic angle closure glaucoma. *Indian J Ophthalmol*. 2001;49(4):255-9.
11. Rosman M, Aung T, Ang LP, et al. Chronic angle-closure with glaucomatous damage: long-term clinical course in a North American population and comparison with an Asian population. *Ophthalmology*. 2002;109(12):2227-31.
12. Cumba RJ, Nagi KS, Bell NP, et al. Clinical outcomes of peripheral iridotomy in patients with the spectrum of chronic primary angle closure. *ISRN Ophthalmol*. 2013 Jun 26;2013:828972.
13. Ruangvaravate N, Kitnarong N, Metheerairat A, et al. Efficacy of brimonidine 0.2 per cent as adjunctive therapy to beta-blockers: a comparative study between POAG and CACG in Asian eyes. *J Med Assoc Thai*. 2002;85(8):894-900.
14. Aung T, Wong HT, Yip CC, et al. Comparison of the intraocular pressure-lowering effect of latanoprost and timolol in patients with chronic angle closure glaucoma: a preliminary study. *Ophthalmology*. 2000;107(6):1178-83.

15. How AC, Kumar RS, Chen YM, et al. A randomised crossover study comparing bimatoprost and latanoprost in subjects with primary angle closure glaucoma. *Br J Ophthalmol*. 2009;93(6):782-6.
16. Chen MJ, Chen YC, Chou CK, et al. Comparison of the effects of latanoprost and bimatoprost on intraocular pressure in chronic angle-closure glaucoma. *J Ocul Pharmacol Ther*. 2007;23(6):559-66.
17. Chen MJ, Chen YC, Chou CK, et al. Comparison of the effects of latanoprost and travoprost on intraocular pressure in chronic angle-closure glaucoma. *J Ocul Pharmacol Ther*. 2006;22(6):449-54.
18. Lou H, Zong Y, Ge YR, Cheng JW, Wei RL. Efficacy and tolerability of latanoprost compared with timolol in the treatment of patients with chronic angle-closure glaucoma. *Curr Med Res Opin*. 2014;30(7):1367-73.
19. Lindsey JD, Kashiwagi K, Kashiwagi F, et al. Prostaglandins alter extracellular matrix adjacent to human ciliary muscle cells in vitro. *Invest Ophthalmol Vis Sci* 1997;38:2214-23.
20. Aung T, Chan YH, Chew PT; EXACT Study Group. Degree of angle closure and the intraocular pressure-lowering effect of latanoprost in subjects with chronic angle-closure glaucoma. *Ophthalmology*. 2005;112(2):267-71.
21. Kook MS, Cho HS, Yang SJ, et al. Efficacy of latanoprost in patients with chronic angle-closure glaucoma and no visible ciliary-body face: a preliminary study. *J Ocul Pharmacol Ther*. 2005;21(1):75-84.
22. Zou J, Zhang F, Zhang L, et al. A clinical study on laser peripheral iridoplasty for primary angle-closure glaucoma with positive provocative tests after iridectomy. *Chung Hua Yen Ko Tsa Chih*. 2002;38(12):708-11.
23. Ritch R, Tham CC, Lam DS. Argon laser peripheral iridoplasty (ALPI): an update. *Surv Ophthalmol*. 2007;52(3):279-88.
24. Pachimkul P, Intajak Y. Effect of lens extraction on primary angle closure in a Thai population. *J Med Assoc Thai*. 2006;91(3):303-8.
25. Lai JS, Tham CC, Chan JC. The clinical outcomes of cataract extraction by phacoemulsification in eyes with primary angle-closure glaucoma (PACG) and co-existing cataract: a prospective case series. *J Glaucoma*. 2006;15(1):47-52.
26. Hata H, Yamane S, Hata S, et al. Preliminary outcomes of primary phacoemulsification plus intraocular lens implantation for primary angle-closure glaucoma. *J Med Invest*. 2008;55(3-4):287-91.
27. Brown RH, Zhong L, Whitman AL, et al. Reduced intraocular pressure after cataract surgery in patients with narrow angles and chronic angle-closure glaucoma. *J Cataract Refract Surg*. 2014;40(10):1610-4.
28. Chen PP, Lin SC, Junk AK, et al. The Effect of Phacoemulsification on Intraocular Pressure in Glaucoma Patients: A Report by the American Academy of Ophthalmology. *Ophthalmology*. 2015;122(7):1294-307.
29. Emanuel ME, Parrish RK 2nd, Gedde SJ. Evidence-based management of primary angle closure glaucoma. *Curr Opin Ophthalmol*. 2014;25(2):89-92.
30. Dias-Santos A, Ferreira J, Abegão Pinto L, et al. Phacoemulsification versus peripheral iridotomy in the management of chronic primary angle closure: long-term follow-up. *Int Ophthalmol*. 2015;35(2):173-8.
31. Tham CC, Kwong YY, Leung DY, et al. Phacoemulsification versus combined phacotrabeculectomy in medically controlled chronic angle closure glaucoma with cataract. *Ophthalmology*. 2008;115(12):2167-73.
32. Tham CC, Kwong YY, Leung DY, et al. Phacoemulsification versus combined phacotrabeculectomy in medically uncontrolled chronic angle closure glaucoma with cataracts. *Ophthalmology*. 2009;116(4):725-31.
33. Zhang X, Teng L, Li A, et al. The clinical outcomes of three surgical managements on primary angle-closure glaucoma. *Yan Ke Xue Bao*. 2007;23(2):65-74.
34. Lee CK, Rho SS, Sung GJ, et al. Effect of Goniosynechialysis During Phacoemulsification on IOP in Patients With Medically Well-controlled Chronic Angle-Closure Glaucoma. *J Glaucoma*. 2015;24(6):405-9.

35. Foreman-Larkin J, Netland PA, Salim S. Clinical Management of Malignant Glaucoma. *J Ophthalmol*. 2015;2015:283707.
36. Yusuf IH, Shah M, Shaikh A, James CB. Transscleral cyclophotocoagulation in refractory acute and chronic angle closure glaucoma. *BMJ Case Rep*. 2015 Sep 30;2015. pii: bcr2015209552. doi: 10.1136/bcr-2015-209552.
37. Dada T, Rathi A, Angmo D, et al. Clinical outcomes of clear lens extraction in eyes with primary angle closure. *J Cataract Refract Surg*. 2015;41(7):1470-7.
38. Azuara-Blanco A, Burr JM, Cochran C, et al. Effectiveness in Angle-closure Glaucoma of Lens Extraction (EAGLE) Study Group. The effectiveness of early lens extraction with intraocular lens implantation for the treatment of primary angle-closure glaucoma (EAGLE): study protocol for a randomized controlled trial. *Trials*. 2011;12:133.

UVEITIC GLAUCOMA

Signs and Symptoms

Patients with uveitic glaucoma typically fall into one of two categories: those that develop acute anterior uveitis replete with pain, photophobia and lacrimation, and those experiencing lesser symptoms from chronic uveitis.¹⁻⁴ Younger patients usually demonstrate greater amounts of inflammation, with uveitic glaucoma developing secondary to acute disease. On the other hand, older patients frequently exhibit lesser amounts of inflammation, with glaucoma developing more commonly from chronic disease, often with contributory long-term steroid use.¹

One study reported the incidence of secondary intraocular pressure (IOP) elevation occurs in 18% of eyes with uveitis.⁴ As a rule, elevated IOP is a manifestation of chronic intraocular inflammation rather than acute anterior uveitis. In this particular study, the IOP elevation occurred from uveitis in 19% of patients overall, with 12% of acute cases and 26% of chronic cases being responsible.⁵

Another study noted raised IOP overall in 42% of eyes with uveitis, with IOP elevation occurring in 26% of eyes with acute anterior uveitis and 46% in eyes with chronic uveitis.¹ In many cases, use of topical corticosteroids contribute to the rise in IOP, especially in chronic cases.¹⁻⁴

Biomicroscopically, there will be varying levels of inflammation—from few inflammatory cells and flare in chronic anterior uveitis (often in older patients), to plasmoid aqueous in acute disease in younger patients. Occasionally, secondary IOP elevation can occur in association with posterior uveitis as well.^{4,6} Structural changes such as posterior synechiae, seclused pupil with pupil block and iris bombé, angle closure and peripheral anterior synechiae (PAS) are all possible findings.¹⁻⁴ IOP elevation may be modest (not requiring intervention) or dramatic, with possible rapid damage ensuing to the retinal nerve fiber layer (RNFL), optic disc and visual field.

Pathophysiology

There are a plethora of possible pathophysiologic mechanisms accounting for the elevation of IOP in patients with uveitis. Secondary IOP elevation occurs from abnormal aqueous humor dynamics precipitated by increased protein content and increased aqueous viscosity. This, combined with other factors, leads to a reduction in outflow through the trabecular meshwork.

The anterior chamber angle may be open or closed. In the case of a closed angle, there may be pupil block present due to extensive posterior synechiae. Gonioscopy is crucial in determining the precise mechanism of uveitic glaucoma. In cases of extensive posterior synechiae, the pupil becomes seclused, leading to pupil block, iris bombé and secondary angle closure, with PAS forming quickly. However, pupil block and iris bombé are not required for a patient with uveitis to develop synechial angle closure. Due to sticky inflammatory debris accumulation and fibrin membrane formation in the angle itself, PAS form and extend in a zippering, rapidly creeping fashion, producing angle closure by creating an environment that allows the iris to be

“stuck” against the Schwalbe’s line of the cornea. Here, patients with deep anterior chambers not otherwise at risk of angle closure encounter a secondary angle closure without pupil block.²

In yet another possible mechanism, the trabecular meshwork outflow can be impeded both by the accumulation of inflammatory cells as well as the inherent outflow infacility of proteinacious aqueous humor in patients with excessive flare.⁷⁻¹¹ Thus, the mechanism is secondary open angle glaucoma. Flare is more of a factor in the development of IOP elevation than the amount of inflammatory cells, as outflow facility is greatly reduced in patients with excessive amounts of aqueous protein, irrespective of the number of inflammatory cells.¹¹ This is due to increased viscosity of the aqueous humor. The source of the increased protein content found in the aqueous humor of patients with uveitis is from dilated vessels in the iris and ciliary body as a result of the inflammatory cascade.¹²

Accumulation of inflammatory cells can unquestionably impede aqueous humor outflow through the trabecular meshwork. However, the inflammatory cellular debris also leads to cellular depopulation of the trabecular meshwork. This is more significant than simple blockade of the trabecular meshwork by inflammatory cells.² Outflow impedance is also increased by release of inflammatory mediators that alter trabecular meshwork cell function and composition.²

Though unsubstantiated by histological evaluation, there may be direct inflammation of the trabecular meshwork itself (trabeculitis), leading to a decreased ability to filter aqueous humor. This is suggested by conditions such as glaucomatocyclitic crisis, where the IOP may be dramatically elevated despite minimally detectable anterior chamber inflammation.

Finally, corticosteroids may also contribute to the IOP rise in uveitic glaucoma. While a clinically significant steroid-induced rise in IOP may take several weeks, the response may be shorter in cases involving uveitis where abnormalities in the trabecular meshwork and alteration of aqueous humor composition and dynamics are already occurring.

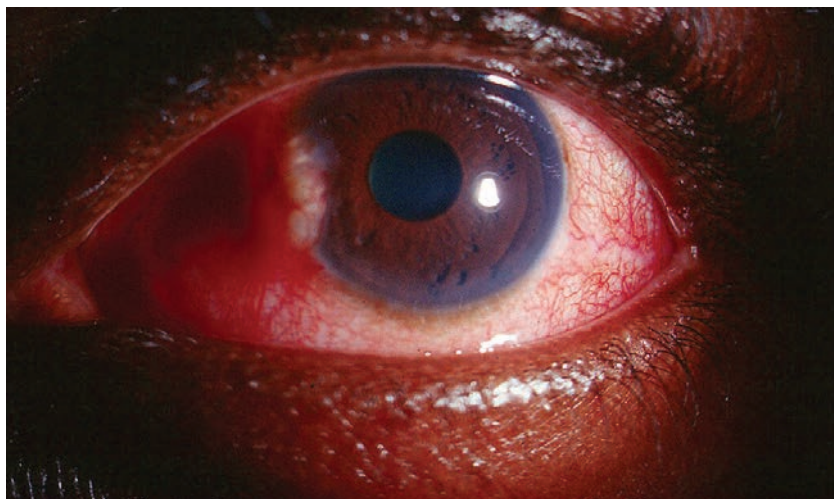
The increased prevalence of glaucoma in chronic uveitis reflects the cumulative effects of inflammation and steroid use. In older patients, minimal amounts of inflammation may overcome a trabecular meshwork with declining function. In younger patients, severe inflammation is usually necessary to overcome a healthy, functional trabecular meshwork.²

Caution must be exercised in evaluating the possible rapid damage that can occur from uveitic glaucoma. Normal-appearing measurements of RNFL thickness on OCT in patients with uveitic IOP elevation should be interpreted critically. Continued thinning of the RNFL and increased optic disc damage, despite intraocular pressure control in such eyes, may be due to resolution of edema of the RNFL that often occurs from uveitis.¹³

Management

In all cases, control of inflammation is necessary to successfully manage uveitic glaucoma. While concerns may exist about additional IOP elevation from corticosteroid use, improperly treating the inflammation—which is the root source of the glaucoma—is unwise and potentially dangerous.^{1-4,7-10,14}

In acute anterior uveitis with heavy amounts of inflammation, loading doses of a potent steroid such as prednisolone acetate 1% every 30 minutes for several hours, followed by hourly administration while awake until initial follow-up, is recommended. Follow-through dosing every two hours while



A case of uveitis causing glaucoma.

awake is often necessary to overtake the initial event. Alternately in recalcitrant cases, difluprednate 0.05% QID may offer better inflammatory control.¹⁵ Appropriate cycloplegia using atropine 1% or homatropine 5% QD-TID will serve to relieve pain and stabilize the normal blood vasculature, minimizing leaking. In many cases, IOP elevation associated with acute anterior uveitis is self-limiting and will resolve as the uveitis resolves.⁵

Aqueous suppressants have been the mainstay of treatment of uveitis-related IOP rise. However, the efficacy of glaucoma medications may be variable and unpredictable in uveitic glaucoma. Topical beta-blockers are a viable option, though they may have poor to no effect in uveitic glaucoma.² Interestingly, topical carbonic anhydrase inhibitors have been seen to work especially well in lowering the IOP in uveitic glaucoma.^{2,3} An alpha-2 adrenergic agonist is also an acceptable option. Oral carbonic anhydrase inhibitors (acetazolamide and methazolamide) may also be considered. Miotics must be avoided, as they increase vascular permeability and can worsen inflammation in anterior uveitis.¹⁶

Prostaglandin analogs (PGAs) have

long been avoided due to the concern that they may potentiate inflammation and possibly contribute to the formation of cystoid macular edema and reactivation of herpes virus in herpetic uveitis.¹⁷ However, little evidence indicates that PGAs disrupt the blood-aqueous barrier, and only anecdotal evidence suggests an increased risk of these rare findings. PGAs may be used in uveitic glaucoma when other topical treatments have not lowered IOP to the patient's target range. They have been shown to be effective in lowering IOP without increasing inflammation.¹⁸⁻²⁰

Studies have highlighted the role of viruses (e.g., cytomegalovirus, herpes simplex virus, and, more recently, Ebola) in the pathogenesis of uveitic glaucoma. Antiviral therapy may be beneficial in eyes with detectable viral DNA, eyes with uveitis suspected of viral origin and potentially cases unresponsive to conventional therapy. Topical ganciclovir, as well as oral acyclovir, famciclovir and valacyclovir may be employed.^{14,21}

In cases of uveitic glaucoma that cannot be controlled medically, surgery remains an option. Angle closure caused by pupil block is a surgical

emergency necessitating laser peripheral iridotomy (LPI). However, in the face of widespread inflammation, the procedure is frequently unsuccessful, and surgical iridectomy may be necessary.²² Laser trabeculoplasty tends to be ineffective in managing uveitic glaucoma due to the structural alteration of the trabecular meshwork.²³

Trabeculectomy is a favored procedure for patients with uncontrolled uveitic glaucoma.²⁴ In order to have the greatest possibility for success, inflammation must be well controlled prior to surgery. However, trabeculectomy performed without adjunctive antimetabolites has a high failure rate due to the young age of many of the patients and the active inflammation that leads to fibrosis and scarring of the sclerostomy site.^{23,24} For this reason, mitomycin C is frequently administered intraoperatively to reduce fibrous proliferation and scarring. Adjunctive use of this antimetabolite greatly increases the surgical success rate of trabeculectomy.²⁵⁻³¹ Glaucoma drainage devices such as the Ahmed valve and Baerveldt implant are commonly used to enhance surgical success in patients with refractory uveitic glaucoma, especially in cases of previous trabeculectomy failure.³²⁻³⁶

A newer approach involves the placement of a fluocinolone acetonide implant along with a glaucoma drainage tube in a single surgical session. Observed favorable results suggest that fluocinolone acetonide implantation can be safely combined with glaucoma tube shunt placement in a single surgical session in eyes with uveitis and elevated IOP receiving maximum-tolerated, IOP-lowering therapy. It has been shown that uveitis recurrences decreased, visual acuity improved and IOP decreased with no adverse events during insertion of the fluocinolone acetonide implant and placement of the glaucoma tube shunt.^{37,38}

Clinical Pearls

- Increasing flare can induce an elevation in IOP, even in patients being otherwise well managed for chronic uveitis. However, it can be clinically difficult to detect increases in flare.

Typically, though, patients will report diminishment of vision, which they describe as “hazy” or “smoky,” commensurate with increased aqueous humor protein content. Often, when patients report these visual symptoms, we find IOP elevations as well. This self-reporting by patients is indicative of their inflammation not being well controlled, indicating a need for steroid amplification.

- It is an error to undertreat uveitic glaucoma for fear of further raising IOP with steroid use.

- We have seen the IOP rise in uveitis to levels that could not be measured on the Goldmann applanation scale.

- Acute uveitic glaucoma can appear similar to acute primary angle closure glaucoma. Always be sure of the diagnosis of acute primary angle closure before using pilocarpine.

- Oral anti-inflammatory medications can help control the overall inflammatory condition, provided there is a noninfectious etiology for the uveitis. In cases where the cause of the uveitis remains undiagnosed, an appropriate laboratory workup is required.

- Herbert HM, Viswanathan A, Jackson H, et al. Risk factors for elevated intraocular pressure in uveitis. *J Glaucoma*. 2004;13(2):96-9.
- Kok H, Barton K. Uveitic glaucoma. *Ophthalmol Clin North Am*. 2002;15(3):375-87.
- Sung VC, Barton K. Management of inflammatory glaucomas. *Curr Opin Ophthalmol*. 2004;15(2):136-40.
- Takahashi T, Ohtani S, Miyata K, et al. A clinical evaluation of uveitis-associated secondary glaucoma. *Jpn J Ophthalmol*. 2002;46(5):556-62.
- Panek WC, Holland GN, Lee DA, et al. Glaucoma in patients with uveitis. *Br J Ophthalmol* 1990;74:223-7.
- Westfall AC, Lauer AK, Suhler EB, et al. Toxoplasmosis retinochoroiditis and elevated intraocular pressure: a retrospective study. *J Glaucoma*. 2005;14(1):3-10.
- Souissi K, El Afrit MA, Trojet S, et al. Etiopathogeny of intraocular pressure modifications in uveitis. *J Fr Ophthalmol*. 2006;29(4):456-61.

- Moorthy RS, Mermoud A, Baerveldt G, et al. Glaucoma associated with uveitis. *Surv Ophthalmol*. 1997;41(5):361-94.
- Mermoud A. Physiopathology of uveitic glaucoma. *Klin Monatsbl Augenheilkd*. 1997;210(5):269-73.
- Dietlein TS. Glaucoma and uveitis. Causes of and treatment options for increased intraocular pressure in cases of inflammatory ophthalmology. *Ophthalmologe*. 2003;100(11):991-1006.
- Ladas JG, Yu F, Loo R, et al. Relationship between aqueous humor protein level and outflow facility in patients with uveitis. *Invest Ophthalmol Vis Sci*. 2001;42(11):2584-8.
- Barsotti MF, Bartels SP, Freddo T, et al. The source of protein in the aqueous humor of the normal monkey eye. *Invest Ophthalmol Vis Sci* 1990; 31; 339-46.
- Asrani S, Moore DB, Jaffe GJ. Paradoxical changes of retinal nerve fiber layer thickness in uveitic glaucoma. *JAMA Ophthalmol*. 2014;132(7):877-80.
- Muñoz-Negrete FJ, Moreno-Montañés J, Hernández-Martínez P, et al. Current approach in the diagnosis and management of uveitic glaucoma. *Biomed Res Int*. 2015;2015:742792.
- Foster CS, Davanzo R, Flynn TE, et al. Durezol (difluprednate ophthalmic emulsion 0.05%) compared with pred forte 1% ophthalmic suspension in the treatment of endogenous anterior uveitis. *J Ocul Pharmacol Ther*. 2010;26(5):475-83.
- Mori M, Araie M, Sakurai M, et al. Effects of pilocarpine and tropicamide on blood-aqueous barrier permeability in man. *Invest Ophthalmol Vis Sci* 1992; 33:416-23.
- Sacca S, Paschetto A, Siniscalchi C, et al. Ocular complications of latanoprost in uveitic glaucoma: three case reports. *J Ocul Pharmacol Ther*. 2001;17(2):107-13.
- Takeuchi M, Kanda T, Taguchi M, et al. Evaluation of efficacy and safety of latanoprost/timolol versus travoprost/timolol fixed combinations for ocular hypertension associated with uveitis. *Ocul Immunol Inflamm*. 2016 Jan 22:1-6. [Epub ahead of print].
- Taylor SR, Gurbaxani A, Sallam A, et al. Topical prostaglandin analogues and conjunctival inflammation in uveitic glaucoma. *Open Ophthalmol J*. 2012;6:75-8.
- Horsley MB, Chen TC. The use of prostaglandin analogs in the uveitic patient. *Semin Ophthalmol*. 2011;26(4-5):285-9.
- Sng CC, Ang M, Barton K. Uveitis and glaucoma: new insights in the pathogenesis and treatment. *Prog Brain Res*. 2015;221:243-69.
- Spencer NA, Hall AJ, Stawell RJ. Nd:YAG laser iridotomy in uveitic glaucoma. *Clin Experiment Ophthalmol*. 2001;29(4):217-9.
- Robin AL, Pollack IP. Argon laser trabeculoplasty in secondary forms of open-angle glaucoma. *Arch Ophthalmol*. 1983;101(3):382-4.
- Souissi K, El Afrit MA, Trojet S, et al. Trabeculectomy for the management of uveitic glaucoma. *J Fr Ophthalmol*. 2006;29(2):153-6.
- Mietz H, Raschka B, Krieglstein GK. Risk factors for failures of trabeculectomies performed without antimetabolites. *Br J Ophthalmol*. 1999;83(7):814-21.
- Novak-Laus K, Mandic Z, Ivekovic R, et al. Trabeculectomy with mitomycin C in glaucoma associated with uveitis. *Coll Antropol*. 2005;29 Suppl 1:17-20.
- Prata JA Jr, Neves RA, Minckler DS, et al. Trabeculectomy with mitomycin C in glaucoma associated with uveitis. *Ophthalmic Surg*. 1994;25(9):616-20.
- Yalvac IS, Sungur G, Turhan E, et al. Trabeculectomy with mitomycin-C in uveitic glaucoma associated with Behcet disease. *J Glaucoma*. 2004;13(6):450-3.
- Ceballos EM, Beck AD, Lynn MJ. Trabeculectomy with antiproliferative agents in uveitic glaucoma. *J Glaucoma*. 2002;11(3):189-96.

- Almobarak FA, Alharbi AH, Morales J, et al. Outcomes of Trabeculectomy With Mitomycin-C in Uveitis Associated With Vogt-Koyanagi-Harada Disease. *J Glaucoma*. 2016 Feb 19. [Epub ahead of print].
- Iwao K, Inatani M, Seto T, et al. Long-term outcomes and prognostic factors for trabeculectomy with mitomycin C in eyes with uveitic glaucoma: a retrospective cohort study. *J Glaucoma*. 2014;23(2):88-94.
- Da Mata A, Burk SE, Netland PA, et al. Management of uveitic glaucoma with Ahmed glaucoma valve implantation. *Ophthalmology*. 1999;106(11):2168-72.
- Ceballos EM, Parrish RK 2nd, Schiffman JC. Outcome of Baerveldt glaucoma drainage implants for the treatment of uveitic glaucoma. *Ophthalmology*. 2002;109(12):2256-60.
- Gil-Carrasco F, Salinas-VanOrman E, Recillas-Gispert C, et al. Ahmed valve implant for uncontrolled uveitic glaucoma. *Ocul Immunol Inflamm*. 1998;6(1):27-37.
- Ozdam PC, Vianna RN, Deschenes J. Ahmed valve implantation in glaucoma secondary to chronic uveitis. *Eye*. 2006;20(2):178-83.
- Bettis DI, Morshedi RG, Chaya C, et al. Trabeculectomy with mitomycin c or ahmed valve implantation in eyes with uveitic glaucoma. *J Glaucoma*. 2015;24(8):591-9.
- Moore DB, Stinnett S, Jaffe GJ, et al. improved surgical success of combined glaucoma tube shunt and retisert® implantation in uveitic eyes: a retrospective study. *Ophthalmol Ther*. 2015;4(2):103-13.
- Malone PE, Herndon LW, Muir KW, et al. Combined fluocinolone acetonide intravitreal insertion and glaucoma drainage device placement for chronic uveitis and glaucoma. *Am J Ophthalmol*. 2010;149(5):800-6.e1.

CHOROIDAL RUPTURE

Signs and Symptoms

Choroidal rupture is a possible consequence following blunt trauma directly to the eye.¹⁻⁷ Patients developing choroidal rupture are often younger males who are involved in activities such as ball sports that expose them to high-speed impact to the eye or adnexa. While it seems that men are more likely to experience blunt ocular trauma, one report of patients experiencing blunt orbital trauma indicated that choroidal rupture occurred more often in women.⁷ Common causes of choroidal rupture include impact injuries from paintballs, bottle corks, elastic bands, airbags and sports equipment, among numerous others.⁸⁻¹²

Choroidal ruptures may be single or multiple and can affect any part of the posterior segment.^{2,13,14} They are not typically seen acutely due to choroidal, retinal or vitreous hemorrhages after the traumatic injury.^{3,15} However, if

the trauma was many years antecedent, hemorrhage will only be present if choroidal neovascularization has developed and is bleeding.^{16,17}

Visual acuity and visual field may be unaffected, depending upon the location of the choroidal rupture and degree of collateral damage that occurred at the time of trauma. Unfortunately, choroidal ruptures often herald more significant damage throughout the eye, with poor visual results.⁷ Patients may have variably reduced acuity if the rupture occurred within the posterior pole. Acuity may be drastically affected in cases with subfoveal involvement.^{10-12,14,15}

Ophthalmoscopically, a posteriorly located curvo-linear (crescent-shaped) disruption is located parallel to the ora serrata. Often, the rupture will have the concave aspect toward the disc. Many ruptures are concentric with the optic nerve and vertically oriented, consistent with a break in Bruch's membrane.² Typically, significant reactive retinal pigment epithelium (RPE) hyperplasia is present, giving the rupture a pigmented appearance. Sclera is variably seen beneath, depending upon the degree of damage and exposure of the underlying tissue.

Pathophysiology

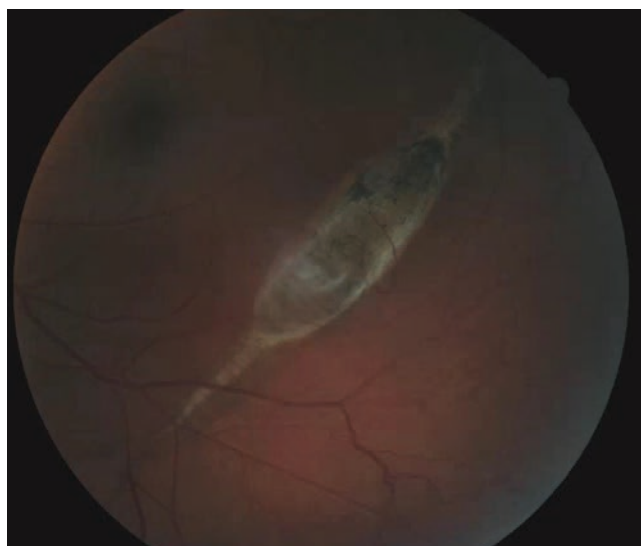Direct or indirect injury can precipitate a choroidal rupture. Direct ruptures are usually located anteriorly, at the exposed part of the eye and parallel to the ora serrata.¹⁸ More common are indirect ruptures occurring in the posterior pole, which are usually concentric to the optic nerve.¹⁸ As the globe is compressed along an anterior-posterior vector, the globe expands laterally, often resulting in a break in Bruch's membrane. In most cases, the sclera maintains the globe's integrity, limiting the damage to the resultant choroidal rupture and the collateral injuries sustained as a result

of the trauma. Unfortunately, in some cases the sclera tears, producing a ruptured globe.^{4,6,7}

Hemorrhage and edema may be present initially, but will resolve over time. Typically, reactive retinal and choroidal pigment epithelial hyperplasia will give the rupture a heavily pigmented appearance. Often, the overlying retina will be undisturbed in choroidal rupture. However, if the RPE is disturbed and becomes hyperplastic, overlying photoreceptor dysfunction will ensue.

Two distinct tomographic patterns of choroidal ruptures have been identified on spectral-domain optical coherence tomography (SD-OCT). The first type involves a forward protrusion of the retinal pigment epithelium-choriocapillaris (RPE-CC) layer with an acutely angled pyramid or dome shape. This was associated with either a small loss of continuity of the RPE layer or elevated RPE-CC projection accompanied by a significant quantity of subretinal hemorrhage. The second type involves a larger area of disruption of the RPE-CC layer, photoreceptor inner segment/outer segment junction and external limiting membrane, with a posterior-directed, concave contour depression at that area, with downward sliding of tissues into the defect.¹⁹

Due to the subsequent disruption of Bruch's membrane in choroidal rupture, the possibility exists for development of choroidal neovascular mem-



Choroidal rupture is a possible consequence following blunt trauma directly to the eye.

branes.^{13,14,16,17-20} This may be a late development, which can occur years after the precipitating trauma.^{18,21} Several factors have been seen to be predictive of the development of choroidal neovascular membranes in choroidal rupture; namely, proximity of the rupture to the center of the fovea, length of the rupture, older age and macular choroidal rupture.^{13,14} Hence, patients with these factors should be monitored closely.

Management

No intervention is needed in the acute phase of choroidal rupture, as long as the sclera is intact and no rupture of the globe is present. Any acute management is directed toward concomitant traumatic uveitis, hyphema, retinal detachment or breaks, and issues pertaining to elevated intraocular pressure should they be present. Patients with choroidal ruptures should be educated about their condition and counseled to consider full-time protective eyewear (protective frame with polycarbonate lenses). The patient must be monitored funduscopically for the development of choroidal neovascularization.

The use of home monitoring with an Amsler grid may be recommended. Patients with significant blunt ocular trauma should also be monitored for angle-recession glaucoma.

Various therapeutic modalities have been used to treat choroidal neovascularization occurring from choroidal rupture. Thermal laser photocoagulation has been a mainstay for these membranes.^{14,18} Photodynamic therapy (PDT) has been used with success.²⁰⁻²² PDT often results in reduction of membrane leakage and can completely eliminate the membrane with few adverse effects. Surgical removal of the neovascular membranes has also been reported.¹⁷ Subsequent submacular hemorrhage has been managed with vitrectomy, subretinal injection of tissue plasminogen activator and pneumatic displacement of blood with intravitreal air tamponade.^{23,24}

Recently, intravitreal injection of anti-vascular endothelial growth factors (anti-VEGF), such as bevacizumab and ranibizumab, has shown impressive results in managing choroidal neovascularization and subretinal fluid associated with choroidal rupture. These agents are seen to be first-line therapy should choroidal neovascularization develop at any time from choroidal rupture.²⁵⁻²⁹

Patients who develop choroidal neovascularization outside of the macula are typically monitored without treatment, as these membranes will involute over time. However, any hemorrhage threatening the macula should be treated.

While choroidal rupture involving the macula tends to have a poor visual prognosis, cases of patients with foveal choroidal ruptures regaining central vision over a protracted recovery period have been reported.³⁰ Incidents of early enlargement of choroidal rupture with subsequent loss of vision by expansion to the foveal region have also been documented.³¹

Clinical Pearls

- As the retina overlying a choroidal rupture may be unaffected, patients may retain excellent visual function and present asymptotically years after the trauma.
 - Choroidal neovascularization can occur years after the initial trauma.
 - Choroidal neovascular membranes resulting from choroidal rupture may spontaneously involute. For this reason, close observation may be a management option if no imminent threat to vision is present.
 - Subretinal hemorrhage from choroidal neovascularization is the most common cause of late vision loss.
 - Gonioscopy should also be performed at some point to rule out angle damage and an increased risk for developing late traumatic glaucoma.
 - Small peripheral choroidal ruptures can be confused with lattice retinal degeneration of the retina. Lattice lesions will typically be located well anterior to the equator, while choroidal ruptures are more posterior in the fundus.

1. Kuhn F, Morris R, Witherspoon CD, et al. Epidemiology of blinding trauma in the United States Eye Injury Registry. *Ophthalmic Epidemiol.* 2006;13(3):209-16.
2. Wyszynski RE, Grossniklaus HE, Frank KE. Indirect choroidal rupture secondary to blunt ocular trauma. A review of eight eyes. *Retina.* 1988;8(4):237-43.
3. Shakin JL, Yannuzzi LA. Posterior segment manifestations of orbital trauma. *Adv Ophthalmic Plast Reconstr Surg.* 1987;6:115-35.
4. Williams DF, Mieler WF, Williams GA. Posterior segment manifestations of ocular trauma. *Retina.* 1990;10 Suppl 1:S35-44.
5. Viestenz A, Kuchle M. Blunt ocular trauma. Part II. Blunt posterior segment trauma. *Ophthalmologe.* 2005;102(1):89-99.
6. Viestenz A, Kuchle M. Retrospective analysis of 417 cases of contusion and rupture of the globe with frequent avoidable causes of trauma: the Erlangen Ocular Contusion-Registry (EOCR) 1985 - 1995. *Klin Monatsbl Augenheilkd.* 2001;218(10):662-9.
7. Viestenz A. Rupture of the choroid after eyeball contusion--an analysis based on the Erlangen Ocular Contusion Registry (EOCR). *Klin Monatsbl Augenheilkd.* 2004;221(8):713-9.
8. Viestenz A, Kuchle M. Ocular contusion caused by elastic cords: a retrospective analysis using the Erlangen Ocular Contusion Registry. *Clin Experiment Ophthalmol.* 2002;30(4):266-9.
9. Viestenz A, Kuchle M. eye contusions caused by a bottle cap. a retrospective study based on the erlangen ocular contusion register (eocr). *Ophthalmologe.* 2002;99(2):105-8.

10. Morris DS. Ocular blunt trauma: loss of sight from an ice hockey injury. *Br J Sports Med.* 2006;40(3):e5.
11. Farr AK, Fekrat S. Eye injuries associated with paintball guns. *Int Ophthalmol.* 1998-1999;22(3):169-73.
12. Kim JM, Kim KO, Kim YD, et al. A case of air-bag associated severe ocular injury. *Korean J Ophthalmol.* 2004;18(1):84-8.
13. Secrétan M, Sickenberg M, Zografos L, et al. Morphometric characteristics of traumatic choroidal ruptures associated with neovascularization. *Retina.* 1998;18(1):62-6.
14. Ament CS, Zacks DN, Lane AM, et al. Predictors of visual outcome and choroidal neovascular membrane formation after traumatic choroidal rupture. *Arch Ophthalmol.* 2006;124(7):957-66.
15. Yeung L, Chen TL, Kuo YH, et al. Severe vitreous hemorrhage associated with closed-globe injury. *Graefes Arch Clin Exp Ophthalmol.* 2006;244(1):52-7.
16. Abri A, Binder S, Pavelka M, et al. Choroidal neovascularization in a child with traumatic choroidal rupture: clinical and ultrastructural findings. *Clin Experiment Ophthalmol.* 2006;34(5):460-3.
17. Gross JG, King LP, de Juan E, et al. Subfoveal neovascular membrane removal in patients with traumatic choroidal rupture. *Ophthalmology.* 1996;103(4):579-85.
18. O'Connor J. Choroidal rupture. *Optom Clin.* 1993;3(2):81-9.
19. Nair U, Soman M, Ganekal S, et al. Morphological patterns of indirect choroidal rupture on spectral domain optical coherence tomography. *Clin Ophthalmol.* 2013;7:1503-9.
20. Harissi-Dagher M, Sebag M, Gauthier D, et al. Photodynamic therapy in young patients with choroidal neovascularization following traumatic choroidal rupture. *Am J Ophthalmol.* 2005;139(4):726-8.
21. Mennel S, Hausmann N, Meyer CH, et al. Photodynamic therapy and indocyanine green guided feeder vessel photocoagulation of choroidal neovascularization secondary to choroid rupture after blunt trauma. *Graefes Arch Clin Exp Ophthalmol.* 2005;243(1):68-71.
22. Mehta HB, Shanmugam MP. Photodynamic therapy of a posttraumatic choroidal neovascular membrane. *Indian J Ophthalmol.* 2005;53(2):131-2.
23. Goldman DR, Vora RA, Reichel E. Traumatic choroidal rupture with submacular hemorrhage treated with pneumatic displacement. *Retina.* 2014;34(6):1258-60.
24. Doi S, Kimura S, Morizane Y, et al. Successful displacement of a traumatic submacular hemorrhage in a 13-year-old boy treated by vitrectomy, subretinal injection of tissue plasminogen activator and intravitreal air tamponade: a case report. *BMC Ophthalmol.* 2015;15:94.
25. Kim M, Kim JH, Seo Y, et al. Intravitreal bevacizumab for traumatic choroidal rupture. *Optom Vis Sci.* 2015;92(10):e363-7.
26. De Benedetto U, Battaglia Parodi M, Knutsson KA, et al. Intravitreal bevacizumab for extrafoveal choroidal neovascularization after ocular trauma. *J Ocul Pharmacol Ther.* 2012;28(5):550-2.
27. Artunay O, Rasiar R, Yuzbasoglu E, et al. Intravitreal bevacizumab injection in patients with choroidal neovascularization due to choroid rupture after blunt-head trauma. *Int Ophthalmol.* 2009;29(4):289-91.
28. Valdeperas X, Bonilla R, Romano MR, et al. Use of intravitreal bevacizumab for the treatment of choroidal neovascularization secondary to choroidal rupture. *Arch Soc Esp Oftalmol.* 2011;86(11):380-3.
29. Janknecht P. Treatment of traumatic choroidal neovascularization with ranibizumab. *Ophthalmologe.* 2011;108(1):57-9.
30. Raman SV, Desai UR, Anderson S, et al. Visual prognosis in patients with traumatic choroidal rupture. *Can J Ophthalmol.* 2004;39(3):260-6.
31. Moon K, Kim KS, Kim YC. A case of expansion of traumatic choroidal rupture with delayed-developed outer retinal changes. *Case Rep Ophthalmol.* 2013;4(2):70-5.



Classic beta blocker adjunctive therapy for the right patient at the right time³

The concomitant use of two topical beta-adrenergic blocking agents is not recommended^{4,5}

Indications and Usage

ISTALOL® (timolol maleate ophthalmic solution) is a non-selective beta-adrenergic receptor blocking agent indicated in the treatment of elevated intraocular pressure in patients with ocular hypertension or open-angle glaucoma.

Preservative-free TIMOPTIC® (timolol maleate ophthalmic solution) in OCUDOSE® (dispenser) is indicated in the treatment of elevated intraocular pressure in patients with ocular hypertension or open-angle glaucoma. It may be used when a patient is sensitive to the preservative in TIMOPTIC (timolol maleate ophthalmic solution), benzalkonium chloride, or when use of a preservative-free topical medication is advisable.

Important Safety Information for Istalol® and Timoptic® in Ocudose®

- Both ISTALOL® (timolol maleate ophthalmic solution) and TIMOPTIC® (timolol maleate ophthalmic solution) in OCUDOSE® (dispenser) are contraindicated in patients with: bronchial asthma; a history of bronchial asthma; severe chronic obstructive pulmonary disease; sinus bradycardia; second or third degree atrioventricular block; overt cardiac failure; cardiogenic shock; hypersensitivity to any component of the product.
- **The same adverse reactions found with systemic administration of beta-adrenergic blocking agents may occur with topical administration. Severe respiratory reactions and cardiac reaction, including death due to bronchospasm in patients with asthma, and rarely death in association with cardiac failure, have been reported following systemic or ophthalmic administration of timolol maleate.**
- Patients with a history of atopy or severe anaphylactic reactions to a variety of allergens may be unresponsive to the usual doses of epinephrine used to treat anaphylactic reactions.
- Timolol has been reported rarely to increase muscle weakness in some patients with myasthenia gravis or myasthenic symptoms.
- Beta-adrenergic blocking agents may mask signs and symptoms of acute hypoglycemia or certain clinical signs of hyperthyroidism. Patients subject to spontaneous hypoglycemia, or diabetic patients receiving either insulin or oral hypoglycemic agents, or patients suspected of developing thyrotoxicosis, should be managed carefully, with caution.
- In patients undergoing elective surgery, some authorities recommend gradual withdrawal of beta adrenergic receptor blocking agents because these agents impair the ability of the heart to respond to beta-adrenergically mediated reflex stimuli.
- The most frequently reported adverse reactions have been burning and stinging upon instillation. This was seen in 38% of patients treated with ISTALOL and in approximately one in eight patients treated with TIMOPTIC in OCUDOSE. Additional reactions reported with ISTALOL at a frequency of 4 to 10% include: blurred vision, cataract, conjunctival injection, headache, hypertension, infection, itching and decreased visual acuity.

Please see Brief Summary of Prescribing Information for ISTALOL and TIMOPTIC in OCUDOSE on the following pages.

For the patients who need incremental IOP reduction in a preservative free form⁶



For the patients who need incremental IOP reduction in a once a day form⁶

Istalol[®]
(timolol maleate
ophthalmic solution) 0.5%

References: 1. Alm A, Stjernschantz J. Effects on Intraocular Pressure and Side Effects of 0.005% Latanoprost Applied Once Daily, Evening or Morning. *Ophthalmology*. 1995;102:1743-1752. 2. Brubaker R. Flow of Aqueous Humor in Humans. *IOVS*. 1991;32(13):3145-3166. 3. Obstbaum S, Cioffi GA, Kriegstein GK, et al. Gold Standard Medical Therapy for Glaucoma: Defining the Criteria Identifying Measures for an Evidence-Based Analysis. *Clin Ther*. 2004;26(12):2102-2119. 4. Istalol [package insert]. Bridgewater, NJ: Bausch & Lomb Incorporated; 2013. 5. Timoptic in Ocudose [package insert]. Lawrenceville, NJ: Aton Pharma; 2009. 6. Stewart W, Day DG, Sharpe ED. Efficacy and Safety of Timolol Solution Once Daily vs Timolol Gel Added to Latanoprost. *Am J Ophthalmol*. 1999;128(6):692-696.

Timoptic and Ocudose are trademarks of Valeant Pharmaceuticals International, Inc. or its affiliates. Bausch + Lomb and Istalol are trademarks of Bausch & Lomb Incorporated or its affiliates.

BAUSCH + LOMB

©Bausch & Lomb Incorporated.

US/TOP/14/0017(1)

BRIEF SUMMARY OF PRESCRIBING INFORMATION

This Brief Summary does not include all the information needed to use TIMOPTIC® 0.25% AND 0.5% (timolol maleate ophthalmic solution) in OCUDOSE® (DISPENSER) safely and effectively. See full prescribing information for TIMOPTIC in OCUDOSE.

PRESERVATIVE-FREE STERILE OPHTHALMIC SOLUTION in a Sterile Ophthalmic Unit Dose Dispenser

TIMOPTIC® 0.25% AND 0.5% (TIMOLOL MALEATE OPHTHALMIC SOLUTION) in OCUDOSE® (DISPENSER)

INDICATIONS AND USAGE

Preservative-free TIMOPTIC in OCUDOSE is indicated in the treatment of elevated intraocular pressure in patients with ocular hypertension or open-angle glaucoma.

Preservative-free TIMOPTIC in OCUDOSE may be used when a patient is sensitive to the preservative in TIMOPTIC (timolol maleate ophthalmic solution), benzalkonium chloride, or when use of a preservative-free topical medication is advisable.

CONTRAINDICATIONS

Preservative-free TIMOPTIC in OCUDOSE is contraindicated in patients with (1) bronchial asthma; (2) a history of bronchial asthma; (3) severe chronic obstructive pulmonary disease (see WARNINGS); (4) sinus bradycardia; (5) second or third degree atrioventricular block; (6) overt cardiac failure (see WARNINGS); (7) cardiogenic shock; or (8) hypersensitivity to any component of this product.

WARNINGS

As with many topically applied ophthalmic drugs, this drug is absorbed systemically.

The same adverse reactions found with systemic administration of beta-adrenergic blocking agents may occur with topical administration. For example, severe respiratory reactions and cardiac reactions, including death due to bronchospasm in patients with asthma, and rarely death in association with cardiac failure, have been reported following systemic or ophthalmic administration of timolol maleate (see CONTRAINDICATIONS).

Cardiac Failure: Sympathetic stimulation may be essential for support of the circulation in individuals with diminished myocardial contractility, and its inhibition by beta-adrenergic receptor blockade may precipitate more severe failure.

In Patients Without a History of Cardiac Failure continued depression of the myocardium with beta-blocking agents over a period of time can, in some cases, lead to cardiac failure. At the first sign or symptom of cardiac failure, Preservative-free TIMOPTIC in OCUDOSE should be discontinued.

Obstructive Pulmonary Disease: Patients with chronic obstructive pulmonary disease (e.g., chronic bronchitis, emphysema) of mild or moderate severity, bronchospastic disease, or a history of bronchospastic disease (other than bronchial asthma or a history of bronchial asthma, in which TIMOPTIC in OCUDOSE is contraindicated [see CONTRAINDICATIONS]) should, in general, not receive beta-blockers, including Preservative-free TIMOPTIC in OCUDOSE.

Major Surgery: The necessity or desirability of withdrawal of beta-adrenergic blocking agents prior to major surgery is controversial. Beta-adrenergic receptor blockade impairs the ability of the heart to respond to beta-adrenergically mediated reflex stimuli. This may augment the risk of general anesthesia in surgical procedures. Some patients receiving beta-adrenergic receptor blocking agents have experienced protracted severe hypotension during anesthesia. Difficulty in restarting and maintaining the heartbeat has also been reported. For these reasons, in patients undergoing elective surgery, some authorities recommend gradual withdrawal of beta-adrenergic receptor blocking agents.

If necessary during surgery, the effects of beta-adrenergic blocking agents may be reversed by sufficient doses of adrenergic agonists.

Diabetes Mellitus: Beta-adrenergic blocking agents should be administered with caution in patients subject to spontaneous hypoglycemia or to diabetic patients (especially those with labile diabetes) who are receiving insulin or oral hypoglycemic agents. Beta-adrenergic receptor blocking agents may mask the signs and symptoms of acute hypoglycemia.

Thyrotoxicosis: Beta-adrenergic blocking agents may mask certain clinical signs (e.g., tachycardia) of hyperthyroidism. Patients suspected of developing thyrotoxicosis should be managed carefully to avoid abrupt withdrawal of beta-adrenergic blocking agents that might precipitate a thyroid storm.

PRECAUTIONS

General: Because of potential effects of beta-adrenergic blocking agents on blood pressure and pulse, these agents should be used with caution in patients with cerebrovascular insufficiency. If signs or symptoms suggesting reduced cerebral blood flow develop following initiation of therapy with Preservative-free TIMOPTIC in OCUDOSE, alternative therapy should be considered.

Choroidal detachment after filtration procedures has been reported with the administration of aqueous suppressant therapy (e.g., timolol).

Angle-closure glaucoma: In patients with angle-closure glaucoma, the immediate objective of treatment is to reopen the angle. This requires constricting the pupil. Timolol maleate has little or no effect on the pupil. TIMOPTIC in OCUDOSE should not be used alone in the treatment of angle-closure glaucoma.

Anaphylaxis: While taking beta-blockers, patients with a history of atopy or a history of severe anaphylactic reactions to a variety of allergens may be more reactive to repeated accidental, diagnostic, or therapeutic challenge with such allergens. Such patients may be unresponsive to the usual doses of epinephrine used to treat anaphylactic reactions.

Muscle Weakness: Beta-adrenergic blockade has been reported to potentiate muscle weakness consistent with certain myasthenic symptoms (e.g., diplopia, ptosis, and generalized weakness). Timolol has been reported rarely to increase muscle weakness in some patients with myasthenia gravis or myasthenic symptoms.

Information for Patients: Patients should be instructed about the use of Preservative-free TIMOPTIC in OCUDOSE.

Since sterility cannot be maintained after the individual unit is opened, patients should be instructed to use the product immediately after opening, and to discard the individual unit and any remaining contents immediately after use.

* TIMOPTIC and OCUDOSE are trademarks of Valeant Pharmaceuticals International, Inc. or its affiliates. © 2014 Valeant Pharmaceuticals International, Inc. or its affiliates. All rights reserved.

Patients with bronchial asthma, a history of bronchial asthma, severe chronic obstructive pulmonary disease, sinus bradycardia, second or third degree atrioventricular block, or cardiac failure should be advised not to take this product. (See CONTRAINDICATIONS.)

Drug Interactions: Although TIMOPTIC (timolol maleate ophthalmic solution) used alone has little or no effect on pupil size, mydriasis resulting from concomitant therapy with TIMOPTIC (timolol maleate ophthalmic solution) and epinephrine has been reported occasionally.

Beta-adrenergic blocking agents: Patients who are receiving a beta-adrenergic blocking agent orally and Preservative-free TIMOPTIC in OCUDOSE should be observed for potential additive effects of beta-blockade, both systemic and on intraocular pressure. The concomitant use of two topical beta-adrenergic blocking agents is not recommended.

Calcium antagonists: Caution should be used in the coadministration of beta-adrenergic blocking agents, such as Preservative-free TIMOPTIC in OCUDOSE, and oral or intravenous calcium antagonists, because of possible atrioventricular conduction disturbances, left ventricular failure, and hypotension. In patients with impaired cardiac function, coadministration should be avoided.

Catecholamine-depleting drugs: Close observation of the patient is recommended when a beta blocker is administered to patients receiving catecholamine-depleting drugs such as reserpine, because of possible additive effects and the production of hypotension and/or marked bradycardia, which may result in vertigo, syncope, or postural hypotension.

Digitalis and calcium antagonists: The concomitant use of beta-adrenergic blocking agents with digitalis and calcium antagonists may have additive effects in prolonging atrioventricular conduction time.

CYP2D6 inhibitors: Potentiated systemic beta-blockade (e.g., decreased heart rate, depression) has been reported during combined treatment with CYP2D6 inhibitors (e.g., quinidine, SSRIs) and timolol.

Clonidine: Oral beta-adrenergic blocking agents may exacerbate the rebound hypertension which can follow the withdrawal of clonidine. There have been no reports of exacerbation of rebound hypertension with ophthalmic timolol maleate.

Injectable epinephrine: (See PRECAUTIONS, General, Anaphylaxis)

Carcinogenesis, Mutagenesis, Impairment of Fertility: In a two-year oral study of timolol maleate administered orally to rats, there was a statistically significant increase in the incidence of adrenal pheochromocytomas in male rats administered 300 mg/kg/day (approximately 42,000 times the systemic exposure following the maximum recommended human ophthalmic dose). Similar differences were not observed in rats administered oral doses equivalent to approximately 14,000 times the maximum recommended human ophthalmic dose.

In a lifetime oral study in mice, there were statistically significant increases in the incidence of benign and malignant pulmonary tumors, benign uterine polyps and mammary adenocarcinomas in female mice at 500 mg/kg/day (approximately 71,000 times the systemic exposure following the maximum recommended human ophthalmic dose), but not at 5 or 50 mg/kg/day (approximately 700 or 7,000 times, respectively), the systemic exposure following the maximum recommended human ophthalmic dose. In a subsequent study in female mice, in which post-mortem examinations were limited to the uterus and the lungs, a statistically significant increase in the incidence of pulmonary tumors was again observed at 500 mg/kg/day.

The increased occurrence of mammary adenocarcinomas was associated with elevations in serum prolactin which occurred in female mice administered oral timolol at 500 mg/kg/day, but not at doses of 5 or 50 mg/kg/day. An increased incidence of mammary adenocarcinomas in rodents has been associated with administration of several other therapeutic agents that elevate serum prolactin, but no correlation between serum prolactin levels and mammary tumors has been established in humans. Furthermore, in adult human female subjects who received oral dosages of up to 60 mg of timolol maleate (the maximum recommended human oral dosage), there were no clinically meaningful changes in serum prolactin.

Timolol maleate was devoid of mutagenic potential when tested *in vivo* (mouse) in the micronucleus test and cytogenetic assay (doses up to 800 mg/kg) and *in vitro* in a neoplastic cell transformation assay (up to 100 mcg/mL). In Ames tests the highest concentrations of timolol employed, 5,000 or 10,000 mcg/plate, were associated with statistically significant elevations of revertants observed with tester strain TA100 (in seven replicate assays), but not in the remaining three strains. In the assays with tester strain TA100, no consistent dose response relationship was observed, and the ratio of test to control revertants did not reach 2. A ratio of 2 is usually considered the criterion for a positive Ames test.

Reproduction and fertility studies in rats demonstrated no adverse effect on male or female fertility at doses up to 21,000 times the systemic exposure following the maximum recommended human ophthalmic dose.

Pregnancy: Teratogenic Effects—Pregnancy Category C. Teratogenicity studies with timolol in mice, rats and rabbits at oral doses up to 50 mg/kg/day (7,000 times the systemic exposure following the maximum recommended human ophthalmic dose) demonstrated no evidence of fetal malformations. Although delayed fetal ossification was observed at this dose in rats, there were no adverse effects on postnatal development of offspring. Doses of 1000 mg/kg/day (142,000 times the systemic exposure following the maximum recommended human ophthalmic dose) were maternotoxic in mice and resulted in an increased number of fetal resorptions. Increased fetal resorptions were also seen in rabbits at doses of 14,000 times the systemic exposure following the maximum recommended human ophthalmic dose, in this case without apparent maternotoxicity.

There are no adequate and well-controlled studies in pregnant women. Preservative-free TIMOPTIC in OCUDOSE should be used during pregnancy only if the potential benefit justifies the potential risk to the fetus.

Nursing Mothers: Timolol maleate has been detected in human milk following oral and ophthalmic drug administration. Because of the potential for serious adverse reactions from timolol in nursing infants, a decision should be made whether to discontinue nursing or to discontinue the drug, taking into account the importance of the drug to the mother.

Pediatric Use: Safety and effectiveness in pediatric patients have not been established.

Geriatric Use: No overall differences in safety or effectiveness have been observed between elderly and younger patients.

ADVERSE REACTIONS

The most frequently reported adverse experiences have been burning and stinging upon instillation (approximately one in eight patients).

The following additional adverse experiences have been reported less frequently with ocular administration of this or other timolol maleate formulations:
BODY AS A WHOLE: Headache, asthenia/fatigue, and chest pain.
CARDIOVASCULAR: Bradycardia, arrhythmia, hypotension, hypertension, syncope, heart

block, cerebral vascular accident, cerebral ischemia, cardiac failure, worsening of angina pectoris, palpitation, cardiac arrest, pulmonary edema, edema, claudication, Raynaud's phenomenon, and cold hands and feet.

DIGESTIVE: Nausea, diarrhea, dyspepsia, anorexia, and dry mouth.

IMMUNOLOGIC: Systemic lupus erythematosus.

NERVOUS SYSTEM/PSYCHIATRIC: Dizziness, increase in signs and symptoms of myasthenia gravis, paresthesia, somnolence, insomnia, nightmares, behavioral changes and psychic disturbances including depression, confusion, hallucinations, anxiety, disorientation, nervousness, and memory loss.

SKIN: Alopecia and psoriasisiform rash or exacerbation of psoriasis.

HYPERSENSITIVITY: Signs and symptoms of systemic allergic reactions including anaphylaxis, angioedema, urticaria, and localized and generalized rash.

RESPIRATORY: Bronchospasm (predominantly in patients with pre-existing bronchospastic disease), respiratory failure, dyspnea, nasal congestion, cough and upper respiratory infections.

ENDOCRINE: Masked symptoms of hypoglycemia in diabetic patients (see WARNINGS).
SPECIAL SENSES: Signs and symptoms of ocular irritation including conjunctivitis, blepharitis, keratitis, ocular pain, discharge (e.g., crusting), foreign body sensation, itching and tearing, and dry eyes; ptosis; decreased corneal sensitivity; cystoid macular edema; visual disturbances including refractive changes and diplopia; pseudophthalmos; choroidal detachment following filtration surgery (see PRECAUTIONS, General); and tinnitus.

UROGENITAL: Retroperitoneal fibrosis, decreased libido, impotence, and Peyronie's disease.

The following additional adverse effects have been reported in clinical experience with ORAL timolol maleate or other ORAL beta blocking agents, and may be considered potential effects of ophthalmic timolol maleate: **Allergic:** Erythematous rash, fever combined with aching and sore throat, laryngospasm with respiratory distress; **Body as a Whole:** Extremity pain, decreased exercise tolerance, weight loss; **Cardiovascular:** Worsening of arterial insufficiency, vasodilatation; **Digestive:** Gastrointestinal pain, hepatomegaly, vomiting, mesenteric arterial thrombosis, ischemic colitis; **Hematologic:** Nonthrombocytopenic purpura; thrombocytopenic purpura; agranulocytosis; **Endocrine:** Hyperglycemia, hypoglycemia; **Skin:** Pruritus, skin irritation, increased pigmentation, sweating; **Musculoskeletal:** Arthralgia; **Nervous System/Psychiatric:** Vertigo, local weakness, diminished concentration, reversible mental depression progressing to catatonia, an acute reversible syndrome characterized by disorientation for time and place, emotional lability, slightly clouded sensorium, and decreased performance on neuropsychometrics; **Respiratory:** Rales, bronchial obstruction; **Urogenital:** Urination difficulties.

OVERDOSAGE

There have been reports of inadvertent overdosage with Ophthalmic Solution TIMOPTIC (timolol maleate ophthalmic solution) resulting in systemic effects similar to those seen with systemic beta-adrenergic blocking agents such as dizziness, headache, shortness of breath, bradycardia, bronchospasm, and cardiac arrest (see also ADVERSE REACTIONS).

Overdosage has been reported with Tablets BLOCADREN® (timolol maleate tablets). A 30 year old female ingested 650 mg of BLOCADREN (maximum recommended oral daily dose is 60 mg) and experienced second and third degree heart block. She recovered without treatment but approximately two months later developed irregular heartbeat, hypertension, dizziness, tinnitus, faintness, increased pulse rate, and borderline first degree heart block.

An *in vitro* hemodialysis study, using ¹⁴C timolol added to human plasma or whole blood, showed that timolol was readily dialyzed from these fluids; however, a study of patients with renal failure showed that timolol did not dialyze readily.

DOSAGE AND ADMINISTRATION

Preservative-free TIMOPTIC in OCUDOSE is a sterile solution that does not contain a preservative. The solution from one individual unit is to be used immediately after opening for administration to one or both eyes. Since sterility cannot be guaranteed after the individual unit is opened, the remaining contents should be discarded immediately after administration.

Preservative-free TIMOPTIC in OCUDOSE is available in concentrations of 0.25 and 0.5 percent. The usual starting dose is one drop of 0.25 percent Preservative-free TIMOPTIC in OCUDOSE in the affected eye(s) administered twice a day. Apply enough gentle pressure on the individual container to obtain a single drop of solution. If the clinical response is not adequate, the dosage may be changed to one drop of 0.5 percent solution in the affected eye(s) administered twice a day.

Since in some patients the pressure-lowering response to Preservative-free TIMOPTIC in OCUDOSE may require a few weeks to stabilize, evaluation should include a determination of intraocular pressure after approximately 4 weeks of treatment with Preservative-free TIMOPTIC in OCUDOSE.

If the intraocular pressure is maintained at satisfactory levels, the dosage schedule may be changed to one drop once a day in the affected eye(s). Because of diurnal variations in intraocular pressure, satisfactory response to the once-a-day dose is best determined by measuring the intraocular pressure at different times during the day.

Dosages above one drop of 0.5 percent TIMOPTIC (timolol maleate ophthalmic solution) twice a day generally have not been shown to produce further reduction in intraocular pressure. If the patient's intraocular pressure is still not at a satisfactory level on this regimen, concomitant therapy with other agent(s) for lowering intraocular pressure can be instituted taking into consideration that the preparation(s) used concomitantly may contain one or more preservatives. The concomitant use of two topical beta-adrenergic blocking agents is not recommended. (See PRECAUTIONS, Drug Interactions, Beta-adrenergic blocking agents)

Distributed by:

Bausch + Lomb, a division of
Valeant Pharmaceuticals North America LLC
Bridgewater, NJ 08807 USA

Manufactured by:
Laboratoire Unither
ZI de la Guérie
F-50211 Coutances Cedex
France

Rev. 05/14
Based on 65N0T8557/4 9390301
US/TOP/14/0018(1)

BRIEF SUMMARY OF PRESCRIBING INFORMATION

This Brief Summary does not include all the information needed to use ISTALOL® (timolol maleate ophthalmic solution) 0.5% safely and effectively. See full prescribing information for ISTALOL.

Istalol® (timolol maleate ophthalmic solution) 0.5%

Initial U.S. Approval: 1978

STERILE

INDICATIONS AND USAGE

Istalol (timolol maleate ophthalmic solution) 0.5% is a non-selective beta-adrenergic receptor blocking agent indicated in the treatment of elevated intraocular pressure (IOP) in patients with ocular hypertension or open-angle glaucoma.

CONTRAINDICATIONS

4.1 Asthma, COPD: Istalol is contraindicated in patients with bronchial asthma; a history of bronchial asthma; severe chronic obstructive pulmonary disease (see **WARNINGS AND PRECAUTIONS, 5.1, 5.3**).

4.2 Sinus Bradycardia, AV Block, Cardiac Failure, Cardiogenic Shock: Istalol is contraindicated in patients with sinus bradycardia; second or third degree atrioventricular block; overt cardiac failure (see **WARNINGS AND PRECAUTIONS, 5.2**); cardiogenic shock.

4.3 Hypersensitivity Reactions: Istalol is contraindicated in patients who have exhibited a hypersensitivity reaction to any component of this product in the past.

WARNINGS AND PRECAUTIONS

5.1 Potentiation of Respiratory Reactions Including Asthma: Istalol contains timolol maleate; and although administered topically, it can be absorbed systemically. Therefore, the same adverse reactions found with systemic administration of beta-adrenergic blocking agents may occur with topical administration. For example, severe respiratory reactions and cardiac reactions including death due to bronchospasm in patients with asthma, and rarely death in association with cardiac failure, have been reported following systemic or ophthalmic administration of timolol maleate (see **CONTRAINDICATIONS, 4.1**).

5.2 Cardiac Failure: Sympathetic stimulation may be essential for support of the circulation in individuals with diminished myocardial contractility, and its inhibition of beta-adrenergic receptor blockade may precipitate more severe failure. In patients without a history of cardiac failure, continued depression of the myocardium with beta-blocking agents over a period of time can, in some cases, lead to cardiac failure. At the first sign or symptom of cardiac failure, Istalol should be discontinued (see also **CONTRAINDICATIONS, 4.2**).

5.3 Obstructive Pulmonary Disease: Patients with chronic obstructive pulmonary disease (e.g., chronic bronchitis, emphysema) of mild or moderate severity, bronchospastic disease, or a history of bronchospastic disease [other than bronchial asthma or a history of bronchial asthma in which Istalol is contraindicated (see **CONTRAINDICATIONS, 4.2**)] should, in general, not receive beta-blocking agents, including Istalol.

5.4 Increased Reactivity to Allergens: While taking beta-blockers, patients with a history of atopy or a history of severe anaphylactic reactions to a variety of allergens may be more reactive to repeated accidental, diagnostic, or therapeutic challenge with such allergens. Such patients may be unresponsive to the usual doses of epinephrine used to treat anaphylactic reactions.

5.5 Potentiation of Muscle Weakness: Beta-adrenergic blockade has been reported to potentiate muscle weakness consistent with certain myasthenic symptoms (e.g., diplopia, ptosis, and generalized weakness). Timolol has been reported rarely to increase muscle weakness in some patients with myasthenia gravis or myasthenic symptoms.

5.6 Masking of Hypoglycemic Symptoms in Patients with Diabetes Mellitus: Beta-adrenergic blocking agents should be administered with caution in patients subject to spontaneous hypoglycemia or to diabetic patients (especially those with labile diabetes) who are receiving insulin or oral hypoglycemic agents. Beta-adrenergic receptor blocking agents may mask the signs and symptoms of acute hypoglycemia.

5.7 Masking of Thyrotoxicosis: Beta-adrenergic blocking agents may mask certain clinical signs (e.g., tachycardia) of hyperthyroidism. Patients suspected of developing thyrotoxicosis should be managed carefully to avoid abrupt withdrawal of beta-adrenergic blocking agents that might precipitate a thyroid storm.

5.8 Contamination of Topical Ophthalmic Products After Use: There have been reports of bacterial keratitis associated with the use of multiple-dose containers of topical ophthalmic products. These containers had been inadvertently contaminated by patients who, in most cases, had a concurrent corneal disease or a disruption of the ocular epithelial surface (see **PATIENT COUNSELING INFORMATION, 17**).

5.9 Impairment of Beta-adrenergically Mediated Reflexes During Surgery: The necessity or desirability of withdrawal of beta-adrenergic blocking agents prior to major surgery is controversial. Beta-adrenergic receptor blockade impairs the ability of the heart to respond to beta-adrenergically mediated reflex stimuli. This may augment the risk of general anesthesia in surgical procedures. Some patients receiving beta-adrenergic receptor blocking agents have experienced protracted severe hypotension during anesthesia. Difficulty in restarting and maintaining the heartbeat has also been reported. For these reasons, in patients undergoing elective surgery, some authorities recommend gradual withdrawal of beta-adrenergic receptor blocking agents. If necessary during surgery, the effects of beta-adrenergic blocking agents may be reversed by sufficient doses of adrenergic agonists.

5.10 Angle-Closure Glaucoma: In patients with angle-closure glaucoma, the immediate objective of treatment is to reopen the angle. This may require constricting the pupil. Timolol maleate has little or no effect on the pupil. Istalol should not be used alone in the treatment of angle-closure glaucoma.

5.11 Cerebrovascular Insufficiency: Because of potential effects of beta-adrenergic blocking agents on blood pressure and pulse, these agents should be used with caution in patients with cerebrovascular insufficiency. If signs or

symptoms suggesting reduced cerebral blood flow develop following initiation of therapy with Istalol, alternative therapy should be considered.

5.12 Choroidal Detachment: Choroidal detachment after filtration procedures has been reported with the administration of aqueous suppressant therapy (e.g. timolol).

ADVERSE REACTIONS

6.1 Clinical Trials Experience: Because clinical trials are conducted under widely varying conditions, adverse reaction rates observed in the clinical trials of a drug cannot be directly compared to rates in the clinical trials of another drug and may not reflect the rates observed in practice.

The most frequently reported adverse reactions have been burning and stinging upon instillation in 38% of patients treated with Istalol. Additional reactions reported with Istalol at a frequency of 4 to 10% include: blurred vision, cataract, conjunctival injection, headache, hypertension, infection, itching and decreased visual acuity. The following additional adverse reactions have been reported less frequently with ocular administration of this or other timolol maleate formulations.

Timolol (Ocular Administration): *Body as a whole:* Asthenia/fatigue and chest pain; *Cardiovascular:* Bradycardia, arrhythmia, hypotension, syncope, heart block, cerebral vascular accident, cerebral ischemia, cardiac failure, worsening of angina pectoris, palpitation, cardiac arrest, pulmonary edema, edema, claudication, Raynaud's phenomenon and cold hands and feet; *Digestive:* Nausea, diarrhea, dyspepsia, anorexia, and dry mouth; *Immunologic:* Systemic lupus erythematosus; *Nervous System/Psychiatric:* Dizziness, increase in signs and symptoms of myasthenia gravis, paresthesia, somnolence, insomnia, nightmares, behavioral changes and psychic disturbances including depression, confusion, hallucinations, anxiety, disorientation, nervousness and memory loss; *Skin:* Alopecia and psoriasisiform rash or exacerbation of psoriasis; *Hypersensitivity:* Signs and symptoms of systemic allergic reactions, including angioedema, urticaria, and localized and generalized rash; *Respiratory:* Bronchospasm (predominantly in patients with pre-existing bronchospastic disease), respiratory failure, dyspnea, nasal congestion, cough and upper respiratory infections; *Endocrine:* Masked symptoms of hypoglycemia in diabetic patients (see **WARNINGS AND PRECAUTIONS, 5.6**); *Special Senses:* Signs and symptoms of ocular irritation including conjunctivitis, blepharitis, keratitis, ocular pain, discharge (e.g., crusting), foreign body sensation, itching and tearing, and dry eyes; ptosis, decreased corneal sensitivity; cystoid macular edema; visual disturbances including refractive changes and diplopia; pseudophthalmos; choroidal detachment following filtration surgery (see **WARNINGS AND PRECAUTIONS, 5.12**); *Urogenital:* Retroperitoneal fibrosis, decreased libido, impotence, and Peyronie's disease.

6.2 Postmarketing Experience

Oral Timolol/Oral Beta-blockers: The following additional adverse effects have been reported in clinical experience with ORAL timolol maleate or other ORAL beta-blocking agents may be considered potential effects of ophthalmic timolol maleate: *Allergic:* Erythematous rash, fever combined with aching and sore throat, laryngospasm with respiratory distress; *Body as a Whole:* Extremity pain, decreased exercise tolerance, weight loss; *Cardiovascular:* Worsening of arterial insufficiency, vasodilatation; *Digestive:* Gastrointestinal pain, hepatomegaly, vomiting, mesenteric arterial thrombosis, ischemic colitis; *Hematologic:* Nonthrombocytopenic purpura; thrombocytopenic purpura, agranulocytosis; *Endocrine:* Hyperglycemia, hypoglycemia; *Skin:* Pruritus, skin irritation, increased pigmentation, sweating; *Musculoskeletal:* Arthralgia; *Nervous System/Psychiatric:* Vertigo, local weakness, diminished concentration, reversible mental depression progressing to catatonia, an acute reversible syndrome characterized by disorientation for time and place, emotional lability, slightly clouded sensorium and decreased performance on neuropsychometrics; *Respiratory:* Rales, bronchial obstruction; *Urogenital:* Urination difficulties.

DRUG INTERACTIONS

7.1 Beta-Adrenergic Blocking Agents: Patients who are receiving a beta-adrenergic blocking agent orally and Istalol® should be observed for potential additive effects of beta-blockade, both systemic and on intraocular pressure. The concomitant use of two topical beta-adrenergic blocking agents is not recommended.

7.2 Calcium Antagonists: Caution should be used in the co-administration of beta-adrenergic blocking agents, such as Istalol, and oral or intravenous calcium antagonists because of possible atrioventricular conduction disturbances, left ventricular failure, and hypotension. In patients with impaired cardiac function, co-administration should be avoided.

7.3 Catecholamine-Depleting Drugs: Close observation of the patient is recommended when a beta blocker is administered to patients receiving catecholamine-depleting drugs such as reserpine, because of possible additive effects and the production of hypotension and/or marked bradycardia, which may result in vertigo, syncope, or postural hypotension.

7.4 Digitalis and Calcium Antagonists: The concomitant use of beta-adrenergic blocking agents with digitalis and calcium antagonists may have additive effects in prolonging atrioventricular conduction time.

7.5 CYP2D6 Inhibitors: Potentiated systemic beta-blockade (e.g., decreased heart rate) has been reported during combined treatment with CYP2D6 inhibitors (e.g., quinidine) and timolol.

7.6 Clonidine: Oral beta-adrenergic blocking agents may exacerbate the rebound hypertension which can follow the withdrawal of clonidine. There have been no reports of exacerbation of rebound hypertension with ophthalmic timolol maleate.

USE IN SPECIFIC POPULATIONS

8.1 Pregnancy

Teratogenic Effects: Pregnancy Category C: Teratogenicity studies have been performed in animals. Teratogenicity studies with timolol in mice, rats, and rabbits at oral doses up to 50 mg/kg/day (7,000 times the systemic exposure following the maximum recommended human ophthalmic dose) demonstrated no evidence of fetal malformations. Although delayed fetal ossification was observed at this dose

in rats, there were no adverse effects on postnatal development of offspring. Doses of 1000 mg/kg/day (142,000 times the systemic exposure following the maximum recommended human ophthalmic dose) were maternotoxic in mice and resulted in an increased number of fetal resorptions. Increased fetal resorptions were also seen in rabbits at doses of 14,000 times the systemic exposure following the maximum recommended human ophthalmic dose, in this case without apparent maternotoxicity. There are no adequate and well-controlled studies in pregnant women. Istalol should be used during pregnancy only if the potential benefit justifies the potential risk to the fetus.

8.3 Nursing Mothers: Timolol has been detected in human milk following oral and ophthalmic drug administration. Because of the potential for serious adverse reactions from Istalol in nursing infants, a decision should be made whether to discontinue nursing or to discontinue the drug, taking into account the importance of the drug to the mother.

8.4 Pediatric Use: Safety and effectiveness in pediatric patients have not been established.

8.5 Geriatric Use: No overall differences in safety or effectiveness have been observed between elderly and younger patients.

OVERDOSAGE

There have been reports of inadvertent overdosage with Istalol resulting in systemic effects similar to those seen with systemic beta-adrenergic blocking agents such as dizziness, headache, shortness of breath, bradycardia, bronchospasm, and cardiac arrest. An *in vitro* hemodialysis study, using ¹⁴C timolol added to human plasma or whole blood, showed that timolol was readily dialyzed from these fluids; however, a study of patients with renal failure showed that timolol did not dialyze readily.

NONCLINICAL TOXICOLOGY

13.1 Carcinogenesis, Mutagenesis, Impairment of Fertility: In a two-year study of timolol maleate administered orally to rats, there was a statistically significant increase in the incidence of adrenal pheochromocytomas in male rats administered 300 mg/kg/day (approximately 42,000 times the systemic exposure following the maximum recommended human ophthalmic dose). Similar differences were not observed in rats administered oral doses equivalent to approximately 14,000 times the maximum recommended human ophthalmic dose. In a lifetime oral study in mice, there were statistically significant increases in the incidence of benign and malignant pulmonary tumors, benign uterine polyps and mammary adenocarcinomas in female mice at 500 mg/kg/day (approximately 71,000 times the systemic exposure following the maximum recommended human ophthalmic dose), but not at 5 or 50 mg/kg/day (approximately 700 or 7,000, respectively, times the systemic exposure following the maximum recommended human ophthalmic dose). In a subsequent study in female mice, in which post-mortem examinations were limited to the uterus and the lungs, a statistically significant increase in the incidence of pulmonary tumors was again observed at 500 mg/kg/day. The increased occurrence of mammary adenocarcinomas was associated with elevations in serum prolactin which occurred in female mice administered oral timolol at 500 mg/kg/day, but not at doses of 5 or 50 mg/kg/day. An increased incidence of mammary adenocarcinomas in rodents has been associated with administration of several other therapeutic agents that elevate serum prolactin, but no correlation between serum prolactin levels and mammary tumors has been established in humans. Furthermore, in adult human female subjects who received oral dosages of up to 60 mg of timolol maleate (the maximum recommended human oral dosage), there were no clinically meaningful changes in serum prolactin. Timolol maleate was devoid of mutagenic potential when tested *in vivo* (mouse) in the micronucleus test and cytogenetic assay (doses up to 800 mg/kg and *in vitro* in a neoplastic cell transformation assay (up to 100 mcg/mL). In Ames tests the highest concentrations of timolol employed, 5,000 or 10,000 mcg/plate, were associated with statistically significant elevations of revertants observed with tester strain TA100 (in seven replicate assays), but not in the remaining three strains. In the assays with tester strain TA100, no consistent dose response relationship was observed, and the ratio of test to control revertants did not reach 2. A ratio of 2 is usually considered the criterion for a positive Ames test. Reproduction and fertility studies in rats demonstrated no adverse effect on male or female fertility at doses up to 21,000 times the systemic exposure following the maximum recommended human ophthalmic dose.

PATIENT COUNSELING INFORMATION

Patients with bronchial asthma, a history of bronchial asthma, severe chronic obstructive pulmonary disease, sinus bradycardia, second or third degree atrioventricular block, or cardiac failure should be advised not to take this product. (see **CONTRAINDICATIONS, 4.1, 4.2**) Patients should also be instructed that ocular solutions, if handled improperly or if the tip of the dispensing container contacts the eye or surrounding structures, can become contaminated by common bacteria known to cause ocular infections. Serious damage to the eye and subsequent loss of vision may result from using contaminated solutions. (see **WARNINGS AND PRECAUTIONS 5.8**) Patients should also be advised that if they have ocular surgery or develop an intercurrent ocular condition (e.g., trauma or infection), they should immediately seek their physician's advice concerning the continued use of the present multidose container. If more than one topical ophthalmic drug is being used, the drugs should be administered at least five minutes apart. Patients should be advised that Istalol® contains benzalkonium chloride which may be absorbed by soft contact lenses. Contact lenses should be removed prior to administration of the solution. Lenses may be reinserted 15 minutes following Istalol® administration.

Rx Only

Manufactured by:
Bausch & Lomb Incorporated
Tampa, FL 33637

Under License from:
SENUJ Pharmaceutical Co., Ltd
Osaka, Japan 541-0046

®/TM are trademarks of Bausch & Lomb Incorporated or its affiliates.
© Bausch & Lomb Incorporated

Based on 9401500

US/IST14/0007 Issued 06/2013

ANGIOID STREAKS

Signs and Symptoms

Angioid streaks are acquired irregular breaks in Bruch's membrane (BM), appearing as meandering, dark brown-reddish radial dehiscences emanating from the optic disc.¹⁻¹² They extend from a peripapillary ring as jagged, radiating lines coursing from the region of the disc in all directions.¹⁻⁷ Angioid streaks almost always occur bilaterally and are typically confined to the posterior polar region. The pigmentation or color of angioid streaks depends on the pigmentation of the fundus, retinal pigment epithelium (RPE) and choroid. In heavily pigmented individuals, the streaks will be dark brown-red in color; in lightly pigmented individuals, the streaks will have a more reddish hue.

Angioid streaks are often associated with "peau d'orange" (the dimpled peel of the orange), the characteristic appearance of RPE mottling often found in the temporal mid-periphery. Though associated with angioid streaks, RPE mottling can be found with or without them.

Angioid streaks produce no symptoms unless the fovea is involved. In fact, most of the time they are discovered serendipitously.¹² If the macular area is disrupted, the patient may only notice visual distortion or metamorphopsia, without any frank loss of acuity. A more substantial incursion will cause worse visual function. Since angioid streaks are either an idiopathic finding or are associated with systemic or other ocular issues, their epidemiology is linked to those conditions with no other specific predilection or incidence.³⁻¹¹

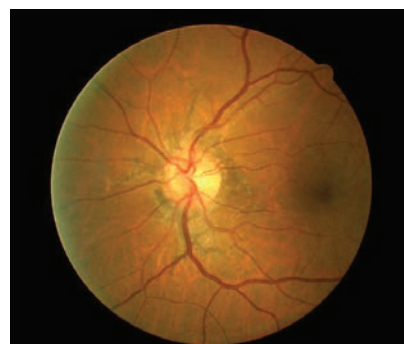The key complication connected to angioid streaks is their propensity to provoke choroidal neovascularization (CNV).¹⁻¹² The risk for developing CNV from angioid streaks is high—more than 70% over a patient's lifetime.¹² CNV arising from angioid streaks has the potential to cause catastrophic visual

loss through serous and/or hemorrhagic detachment of the macular RPE and/or neurosensory retina with subsequent disciform scarring or through development of pre-retinal or vitreous hemorrhage.¹⁻¹² Angioid streaks slowly enlarge in both length and width over time.^{2,4,12} As they grow and as the patient ages, the risk of CNV increases.^{2,4,12} Patients with angioid streaks are more prone to CNV formation than the normal population following blunt trauma.¹³ The systemic and ocular conditions most frequently associated with angioid streaks include pseudoxanthoma elasticum, Ehlers-Danlos syndrome, Paget's disease of bone (and acromegaly) and sickle cell hemoglobinopathies. Idiopathic cases exist as well, with no systemic association or optic disc drusen.¹⁻¹²

Pathophysiology

The underlying common pathology in angioid streaks is altered calcium sequestration or deposition leading to increased Bruch's membrane brittleness.^{3,4,12-14} Angioid streaks represent actual Bruch's membrane "cracking" with atrophic degeneration of the membrane and overlying retinal pigmented epithelium.^{3,4,12-14} Investigators have postulated that the streaks assume their shape and distribution secondary to intrinsic tractional forces along with the extrinsic forces exerted on the eye by the extraocular muscles.⁴ The brittleness of the Bruch's membrane is what makes the patient more prone to CNV formation following blunt injury.¹³

Each of the systemic conditions associated with angioid streaks seems to uniquely contribute to the calcification of Bruch's membrane. In idiopathic cases, the process is incompletely understood. In Paget's disease of the bone, osseous deformities lead to binding of calcium and elastic fibers in the Bruch's membrane.^{4,12} In pseudoxanthoma elasticum, calcium deposition in Bruch's membrane precipitates degeneration of its elastic



Angioid streaks extend from a peripapillary ring as jagged lines radiating out in all directions.

fibers.^{4,12} The appearance of angioid streaks in sickle-cell hemoglobinopathies has long been attributed to increased levels of serum iron. However, other anemias with increased iron levels are not associated with angioid streaks.¹² The histochemical connection between homozygotic sickle-cell anemia and angioid streaks was discovered when patients with sickle cell anemia and angioid streaks were found to have calcification of Bruch's membrane.^{4,12,14}

Researchers looking for a common signaling pathway have examined the role of osteoprotegerin and its relationship to calcification of Bruch's membrane.^{10,16} Osteoprotegerin is a key regulator in bone metabolism.¹⁵ It has also been found to have an effect in the vascular system.¹⁴ Studies suggest that osteoprotegerin is a critical arterial calcification inhibitor that is released by endothelial cells as part of a protective mechanism for their survival in certain pathological conditions, such as diabetes mellitus, chronic kidney disease and other metabolic disorders.¹⁵ Recent research has examined osteoprotegerin and its role in vascular calcification pathologies. The chemokine may have a multifactorial role or serve as a biomarker in numerous vascular diseases.¹⁵

Any time the RPE or subretinal structures are damaged, cytokines and chemo-attractants are released. When the tipping point is reached and vascular

endothelial growth factor along with other vaso-stimulating factors outnumber protective growth-inhibiting factors, CNV begins.^{1-7,11-14}

Management

The discovery of angioid streaks should immediately provoke a more complete history with the goal of possibly uncovering one of the systemically associated diseases. Correspondence to the primary care physician should include the fundoscopic discovery along with a short list of the commonly associated systemic diseases. A team approach can prevent redundant testing and ensure that an efficient laboratory workup is ordered. No treatment exists for angioid streaks themselves. Fundus photodocumentation, patient education (on the need to report sudden visual changes), home Amsler grid monitoring and biannual dilated fundus examination to rule out formation of CNV should be completed. No preventative therapy for CNV is available.

Until the advent of intravitreal anti-vascular endothelial growth factor injections (anti-VEGF), CNV from angioid streaks generally carried a poor prognosis, with a propensity for recurrence, causing poor functional outcomes whether it was treated with laser photocoagulation, transpupillary thermo-therapy, photodynamic therapy (PDT) or surgical removal.^{1-7,11-14} Anti-VEGF treatment has resulted in visual and anatomic outcomes far outpacing the other available options.^{1-7,11-18} Today, patients can expect visual stabilization in most cases, with visual improvement in many, particularly if treatment is begun early in the course of the disease. PDT in combination with anti-VEGF injections has also been used with success.^{1-7,11-18}

Clinical Pearls

- Angioid streaks are jagged cracks in the Bruch's membrane that radiate in all directions from the optic disc.

- The systemic associations of angioid streaks can be remembered by the mnemonic "PEPST": pseudoxanthoma elasticum, Ehlers-Danlos syndrome, Paget's disease of bone, sickle cell hemoglobinopathies and idiopathic.

- Angioid streaks are often discovered accidentally; they are a sign, not a diagnosis. They only cause symptoms if they radiate through the fovea or produce macular CNV.

- No treatment exists for angioid streaks, only for CNV. Patients should be counseled to report changes in vision immediately and should be monitored for CNV with dilated examinations biannually.

- A home Amsler grid should be dispensed for intermittent ongoing patient self-reevaluation.

1. Esen E, Sizmaz S, Demircan N. Intravitreal aflibercept for management of subfoveal choroidal neovascularization secondary to angioid streaks. *Indian J Ophthalmol*. 2015;63(7):616-8.

2. Matonti F, Conrath J. Angioid streaks. *J Fr Ophthalmol*. 2012;35(10):838-45.

3. Al-Rashaed S, Arevalo JF. Long-term follow-up of choroidal neovascularization secondary to angioid streaks: case series and literature review. *Clin Ophthalmol*. 2012;6(7):1029-34.

4. Clarkson JG, Altman RD. Angioid streaks. *Surv Ophthalmol*. 1982;26(5):235-46.

5. Gurwood AS, Mastrangelo DL. Understanding angioid streaks. *J Am Optom Assoc*. 1997;68(5):309-24.

6. Johnson BW, Oshinski L. Diagnosis and management of angioid streaks. *J Am Optom Assoc*. 1988;59(9):704-11.

7. Janotka H, Hess J, Wlodarczyk J. Angioid streaks. Pathogenesis and the clinical picture. *Klin Oczna*. 1995;97(9-10):299-302.

8. Finger RP, Charbel Issa P, Ladewig MS, et al. Pseudoxanthoma elasticum: genetics, clinical manifestations and therapeutic approaches. *Surv Ophthalmol*. 2009;54(2):272-85.

9. Bhoiwala DL, Dunaief JL. Retinal abnormalities in β -thalassemia major. *Surv Ophthalmol*. 2016;61(1):33-50.

10. Kerr NM, Cassinelli HR, DiMeglio LA, et al. Ocular manifestations of juvenile Paget disease. *Arch Ophthalmol*. 2010;128(6):698-703.

11. Gliem M, Finger RP, Fimmers R, et al. Treatment of choroidal neovascularization due to angioid streaks: a comprehensive review. *Retina*. 2013;33(7):1300-14.

12. Georgalas I, Papaconstantinou D, Koutsandrea C, et al. Angioid streaks, clinical course, complications, and current therapeutic management. *Ther Clin Risk Manag*. 2009;5(1):81-9.

13. Kubota M, Hayashi T, Arai K, et al. Choroidal neovascularization after blunt ocular trauma in angioid streaks. *Clin Ophthalmol*. 2013;7(7):1347-51.

14. Jampol LM, Acheson R, Eagle RC Jr., et al. *Arch Ophthalmol*. 1987; 105(1):93-8.

15. Makarović S, Makarović Z, Steiner R, et al. Osteoprotegerin and vascular calcification: clinical and prognostic relevance. *Coll Antropol*. 2015;39(2):461-8.

16. Rosina C, Romano M, Cigada M, et al. Intravitreal bevacizumab for choroidal neovascularization secondary to angioid streaks: a long-term follow-up study. *Eur J Ophthalmol*. 2015;25(1):47-50.

17. Battaglia Parodi M, Iacono P, La Spina C, et al. Intravitreal bevacizumab for nonsubfoveal choroidal neovascularization associated with angioid streaks. *Am J Ophthalmol*. 2014;157(2):374-7.

18. El Matri L, Kort F, Bouraoui R, et al. Intravitreal bevacizumab for the treatment of choroidal neovascularization secondary to angioid streaks: one year of follow-up. *Acta Ophthalmol*. 2011;89(7):641-6.

RETINOPATHY OF PREMATURITY

Signs and Symptoms

Retinopathy of prematurity (ROP) is a potentially blinding complication of prematurely born infants (30 weeks gestational age or younger) and small infants of low birth weight (1,500 grams [3 pounds, 3 ounces] or smaller; the threshold weight varies with sources).¹⁻¹⁵ It has been estimated that 50,000 children worldwide are blinded by the sequelae of ROP each year.⁹ A spectrum of ophthalmic findings exists in ROP from minimal—which do not affect vision—to bilateral tractional retinal detachment with total blindness.⁴

ROP progresses in two phases. The first begins with delayed retinal vascular growth after premature birth and evolves with partial regression of the existing retinal vessels.² The second is induced by hypoxia resulting in pathological retinal vessel growth.¹⁻¹¹ The major risk factors for ROP are prolonged exposure to supplemental oxygen therapy, shortened gestation period and low birth weight.^{1-4,8,15} There is no racial or gender predilection, although infants of African-descent with ROP seem to progress through the stages at a slower rate, and males of all races seem to progress faster.^{7,12-15}

ROP is the result of a staged process that exaggerates the effects of retinal maldevelopment.¹⁻¹¹ The stages of the process progress sequentially in describing the severity of disease. Stages 1 and 2 represent early ROP. Stage 3 describes the vascular phase in which neovascularization occurs. Stages 4 and 5 represent

the fibrovascular phase, with the formation of traction and retinal detachment.¹ In adults, inactive disease may manifest as a dragged optic disc, retinal vessels from peripheral traction and an ectopic macula.

The International Classification of ROP (ICROP) committee provided the standards for clinical assessment based on severity (stage) and anatomic location (zone).^{7,10,11}

Stage 1 disease is defined by the appearance of a retinal demarcation line at the junction of the vascularized retina posteriorly (towards the posterior pole) and nonvascularized retina anteriorly. Visible peripheral retinal vessels may begin to appear tortuous.

Stage 2 ROP occurs when the demarcation line thickens into a ridge containing tufts of malformed vessels. The vitreous may also become hazy. “Plus disease” is defined by engorgement of posterior pole retinal vessels induced by increasingly progressive peripheral retinal vascular stasis. Plus disease is a sign the process is rapidly progressing and is connoted by adding a “+” after the staging (i.e., Stage 2+).

Stage 3 disease is defined by fibrovascular proliferation with or without vitreous hemorrhage and increased retinal traction.

Stage 4 ROP is characterized by tractional retinal detachment (RD).

Stage 5 disease is defined by total RD. The advancement of internal fibrosis creates the appearance of leukocoria and is called retrolental fibroplasia. As vascular stasis increases, the iris vasculature may become tortuous.^{7,10,11}

The second component of nomenclature is the anatomic location defined by a zone. Zone I is defined by a circle within the posterior pole that is created by placing its center in the middle of the optic disc and extending its radius to a length that is twice the distance from the center of the disc to the center of the fovea. Zone II is a circle with the same

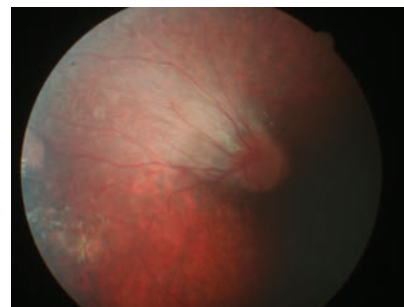
center as Zone I. It extends nasally to the ora serrata. Zone III is the residual temporal crescent of retina anterior to Zone II. The proper nomenclature of ROP includes both the stage and zone. “Threshold ROP” requires intervention. It is defined as Stage 3+ disease (fibrovascular proliferation with or without vitreous hemorrhage and increased retinal traction with engorgement of posterior pole retinal vessels) in Zone I or II occupying at least five contiguous clock hours or eight non-contiguous clock hours of retina. In this situation, there is greater than 50% chance for RD.^{7,10-14} The early treatment of high-risk ROP (ETROP) study defined “pre-threshold” disease and determined that treating these cases before they reached “threshold” parameters provided a significant anatomic and functional benefit.¹²⁻¹⁴ “Pre-threshold” ROP was defined as any ROP in Zone I that was less than threshold disease; or in Zone II, Stage 2 with plus disease; or Zone II, Stage 3 disease without plus disease; or zone II, Stage 3 with plus disease but fewer than five contiguous or eight cumulative clock hours.¹⁴

Researchers have been able to determine that genetic makeup may protect some infants. The opposite is also true; unfavorable genetic markers, such as those that code for a lighter pigmented retinal pigment epithelium (RPE) increase susceptibility.¹⁵

Pathophysiology

The underlying cause for ROP is prematurity and low birth weight.¹⁻¹⁶ Both factors lead to retinal vascular underdevelopment. The human retinal vasculature is not complete until the normal gestational period is reached.⁷ Prematurely born infants have incomplete vascular coverage of the retina.¹⁻¹¹ Medical technology has increased the survival rate of smaller, younger babies, allowing ROP to continue as a significant problem.¹⁻¹⁶

Retinal and choroidal angiogenesis along with tractional retinal detach-



Retinopathy of prematurity exhibiting the classic dragged disc can be seen in this case.

ment are the major causes of vision loss.^{15,19} Retinal angiogenesis occurs after the withdrawal of supplemental oxygen therapy creates relative retinal hypoxia.^{1,2,4-7-15,19,20} The stimulus causes upregulation of growth factors, integrins and proteinases.^{1,2,4-7-15,19} This results in endothelial cell proliferation and migration.^{15,19-20} When the tight balance between angiogenic factors and endogenous angiogenesis inhibitors—which helps to keep the angiogenic process under control—is upset, neovascularization, vascular fibrosis, retinal traction and retinal detachment can occur.^{2,7,15,19} Endothelial cell proliferation and reduced retinal vascular flow contribute to formation of the “plus” variation, which signals an aggressive process and likelihood of neovascular consequences.^{1,2,4-7-15,19,20}

Supplemental oxygen for premature and low birth weight infants contributes to ROP through the dysregulation of vascular endothelial growth factor (VEGF).^{2,7,15,19-21} The supplemental oxygen in early phase ROP (Phase 1 ROP) leads to hyperoxia. This stimulus leads to suppression of VEGF, which inhibits normal vessel growth.²¹ The poor vessel growth leads to retinal anoxia.²¹ When the supplemental oxygen therapy is discontinued, elevated levels of VEGF and aggravated retinal hypoxia in Phase 2 ROP precipitate pathological vessel proliferation.^{1,2,4-7-15,19-21}

Insulin-like growth factor 1 (IGF-1) is also a factor in ROP.^{2,15} IGF-1 in premature babies seems to have a direct

correlation with the severity of clinical ROP.^{2,15} IGF-1 acts as a permissive factor by allowing maximal VEGF stimulation of vessel growth.² Lack of IGF-1 in preterm infants prevents normal retinal vascular growth in Phase 1 of ROP.² As infants mature, rising levels of IGF-1 in Phase 2 ROP stimulates pathological neovascularization.^{1,2,7,15,19-21} Equally contributory is the condensation of vitreous, which exerts tractional forces onto the retina.⁷

New data suggests that exposure to perinatal infection/inflammation is also associated with an increased risk for ROP.¹⁶ This effect is secondary to direct exposure to circulating products of infection and/or inflammation. Inflammation and/or oxidative stress may have the potential to modify the risk of oxygen-associated ROP.¹⁶ Prenatal, perinatal and postnatal systemic inflammation may contribute to a “pre-phase” ROP sensitizing of the retina, setting the stage for Phase 1 and Phase 2 ROP pathogenesis.¹⁶

Some investigators have speculated that intense lighting may contribute to the worsening of ROP disease.^{7,17,18} Recent data seems to conclusively show that decreasing ambient light exposure in neonatal intensive care units for at-risk infants has no benefit in reducing its incidence or course of ROP.^{17,18}

Management

The diagnosis of ROP is made through bedside dilated binocular indirect ophthalmoscopy (BIO). Screening should be completed in all premature infants with less than 30 weeks gestation and infants with low birth weight (<1,500 grams).^{3,7,8} If the retinas are clearly vascularized, only one examination is required. If they are not, another examination should be completed at 33 weeks postnatally.⁷ Infants with ROP should be referred to retinal specialists to rule out the need for weekly monitoring; infants with plus disease and advanced

stage disease or increased zone disease demand closer scrutiny. Infants with mild forms of ROP can be watched at two-week intervals, insuring that their fundi mature.^{3,7}

Vascularization of the preterm peripheral retina is a finite process; once the peripheral inner retinal vessels develop, the disease process stops.²² Any infant reaching “threshold ROP” should have treatment within 72 hours.^{7,10-14} ROptool (Clarity Medical Systems) is a semi-automated computer program that analyzes input images from a computer connected to a special BIO (RetCam, Keeler Instruments).²³ It objectively assesses the fundi for pre-plus and plus disease by measuring retinal vascular tortuosity and vessel width from fundus photographs, assisting and improving decision making.²³

Surgical treatment for ROP in the absence of RD is designed to regress and prevent neovascularization.^{22,24-27} While cryotherapy may have been the earliest treatment investigated for improving outcomes, it is rarely employed today. The modern approach uses combinations of anti-VEGF injections and scatter laser photocoagulation (photoablation).^{22,24-27} Laser photocoagulation works by destroying retina, thereby significantly decreasing VEGF expression.²⁷ It also simultaneously creates a chorioretinal atrophic pathway for the diffusion of choroidal oxygen into the retina.²⁷ Laser destructive procedures have the deleterious side effect of reducing visual field. In response to this, anti-VEGF injections have been used with success.^{1-15,22,24-27}

ROP is less likely than choroidal neovascularization from age-related macular degeneration, or retinal neovascularization from proliferative diabetic retinopathy, to necessitate repeated injections.²³ In many instances the disease undergoes spontaneous involution after 44 weeks of age or after one treatment.²³ Other advantages of injections include ease of administration and their abil-

ity to be performed in very sick infants, thereby avoiding the general anesthesia that would be required for the delivery of binocular indirect endo laser photocoagulation.²²

General guidelines for treatment not withstanding pre- and threshold disease were established by the Multicenter Cryotherapy for Retinopathy of Prematurity (CRYO-ROP) trial, and include, but are not limited to; Zone I, any stage ROP with plus disease; Zone I, Stage 3 ROP with or without plus disease; and Zone II, Stage 2 or 3 ROP with plus disease. Cases with retinal detachment are treated with vitrectomy or scleral buckling; vitrectomy is preferred whenever possible.^{26,27}

Clinical Pearls

- It has been estimated that 50,000 children worldwide are blinded by the sequelae of ROP each year.
- The critical risk factors associated with ROP are prematurity, prolonged exposure to supplemental oxygen and low birth weight.
- Vascularization of an infant’s peripheral retina is a finite process; once the peripheral retinal vessels develop, the ROP disease process stops.
- The general pathophysiology of ROP is intuitive; prematurity causes incomplete retinal vascularity, and supplemental oxygen given to premature infants creates relative retinal hyperoxia. The metabolic result suppresses retinal vessel growth, and removal of the supplemental oxygen in the setting of poor retinal vessel development leaves the retina in a comparative hypoxic state provoking vessel proliferation, tortuosity (plus disease), neovascularization, vitreoretinal traction, vitreous hemorrhage and, ultimately, retinal detachment.
- Treatment of high-risk, pre-threshold disease reduces the risk of RD by 50%. Early treatment of ROP reduces poor outcomes and increases function significantly over the patient’s lifetime.

- Treatment is accomplished by combinations of laser ablation and anti-VEGF injections. Retinal detachments are repaired with vitrectomy and scleral buckling.

- Other causes of leukocoria include Coats' disease, persistent fetal vascular syndrome (formerly known as persistent hyperplastic primary vitreous), tumor, cataract, chorioretinal infection (toxoplasmosis, toxocariasis) and congenital retinoschisis.

- In mild ROP, the condition may actually be first diagnosed in adults with characteristic dragged disc, ectopic macula and mild acuity reduction.

1. Hartnett ME. Pathophysiology and mechanisms of severe retinopathy of prematurity. *Ophthalmology*. 2015;122(1):200-10.
2. Chen J, Smith LE. Retinopathy of prematurity. *Angiogenesis*. 2007;10(2):133-40.
3. Fierson WM, Capone A Jr. Telemedicine for evaluation of retinopathy of prematurity. *Pediatrics*. 2015;135(1):e238-54.
4. Casteels I, Cassiman C, Van Calster J, et al. Educational paper: Retinopathy of prematurity. *Eur J Pediatr*. 2012;171(6):887-93.
5. Jordan CO. Retinopathy of prematurity. *Pediatr Clin North Am*. 2014;61(3):567-77.
6. Isaza G, Arora S, Bal M, et al. Incidence of retinopathy of prematurity and risk factors among premature infants at a neonatal intensive care unit in Canada. *J Pediatr Ophthalmol Strabismus*. 2013;50(1):27-32.
7. Reochia FM, Capone A. Retinopathy of prematurity. In: Yanoff M, Duker JS. *Ophthalmology*. Mosby-Elsevier, St. Louis, MO. 2009:870-76.
8. Stahl A, Göpel W. screening and treatment in retinopathy of prematurity. *Dtsch Arztebl Int*. 2015;112(43):730-5.
9. Saugstad OD. Oxygen and retinopathy of prematurity. *J Perinatol*. 2006;26(5) Suppl 1:S46-50;S63-4.
10. ICROP Committee. An international classification of retinopathy of prematurity. Prepared by an international committee. *Br J Ophthalmol*. 1984; 68(10): 690-697.
11. ICROP Committee. An international classification of retinopathy of prematurity. the committee for the classification of retinopathy of prematurity. *Arch Ophthalmol*. 1984;102(8):1130-4.
12. Kivlin JD, Biglan AW, Gordon RA. Early retinal vessel development and iris vessel dilatation as factors in retinopathy of prematurity. Cryotherapy for Retinopathy of Prematurity (CRYO-ROP) Cooperative Group. *Arch Ophthalmol*. 1996;114(2):150-4.
13. Early Treatment For Retinopathy Of Prematurity Cooperative Group. Revised indications for the treatment of retinopathy of prematurity: results of the early treatment for retinopathy of prematurity randomized trial. *Arch Ophthalmol*. 2003;121(12):1684-94.
14. Good WW; Early Treatment for Retinopathy of Prematurity Cooperative Group. Final results of the Early Treatment for Retinopathy of Prematurity (ETROP) randomized trial. *Trans Am Ophthalmol Soc*. 2004;102(12):233-48.
15. Cavallaro G, Filippi L, Bagnoli P, et al. The pathophysiology of retinopathy of prematurity: an update of previous and recent knowledge. *Acta Ophthalmol*. 2014;92(1):2-20.
16. Lee J, Dammann O. Perinatal infection, inflammation, and retinopathy of prematurity. *Semin Fetal Neonatal Med*. 2012;17(1):26-9.

17. Johannes C, Dow K. Does reducing light exposure decrease the incidence of retinopathy of prematurity in premature infants? *Paediatr Child Health*. 2013;18(6):298-300.
18. Jorge EC, Jorge EN, El Dib RP. Early light reduction for preventing retinopathy of prematurity in very low birth weight infants. *Cochrane Database Syst Rev*. 2013;8(8):CD000122.
19. Das A, McGuire PG. Retinal and choroidal angiogenesis: pathophysiology and strategies for inhibition. *Prog Retin Eye Res*. 2003;22(6):721-48.
20. Guaiquil VH, Hewing NJ, Chiang MF, et al. A murine model for retinopathy of prematurity identifies endothelial cell proliferation as a potential mechanism for plus disease. *Invest Ophthalmol Vis Sci*. 2013;54(8):5294-302.
21. Scott A, Pownier MB, Fruttiger M. Quantification of vascular tortuosity as an early outcome measure in oxygen induced retinopathy (OIR). *Exp Eye Res*. 2014;120(3):55-60.
22. Mota A, Carneiro A, Breda J, et al. Combination of intravitreal ranibizumab and laser photocoagulation for aggressive posterior retinopathy of prematurity. *Case Rep Ophthalmol*. 2012;3(1):136-41.
23. Cabrera MT, Freedman SF, Hartnett ME, et al. Real-time, computer-assisted quantification of plus disease in retinopathy of prematurity at the bedside. *Ophthalmic Surg Lasers Imaging Retina*. 2014;45(6):542-8.
24. Arámbulo O, Dib G, Iturralde J, et al. Intravitreal ranibizumab as a primary or a combined treatment for severe retinopathy of prematurity. *Clin Ophthalmol*. 2015;9(10):2027-32.
25. Drenser KA, Trese MT, Capone A Jr. Aggressive posterior retinopathy of prematurity. *Retina*. 2010;30(4 Suppl):S37-40.
26. Hubbard GB 3rd. Surgical management of retinopathy of prematurity. *Curr Opin Ophthalmol*. 2008;19(5):384-90.
27. CRYO-ROP Committee. Multicenter trial of cryotherapy for retinopathy of prematurity. Preliminary results. Cryotherapy for Retinopathy of Prematurity Cooperative Group. *Arch Ophthalmol*. 1988;106(4):471-9.

SOLAR RETINOPATHY

Signs and Symptoms

Solar retinopathy, photo-maculopathy, eclipse retinopathy and foveomacular retinitis are all synonymous terms connoting retinal (specifically foveal) damage resulting from direct or indirect sun gazing, possibly during a solar eclipse or even on a normal day.¹⁻⁸ The thermal effect of a bright operating microscope light, prolonged exposure to direct and indirect ophthalmoscope light, exposure to tanning bed lights without protective goggles, unprotected arc welding, prolonged direct exposure to a laser pointer and solar viewing through an incorrectly prepared telescope can also produce retinal damage similar to that of a solar exposure.^{3,9-16}

Solar retinopathy can present variably; it can be unilateral or bilateral, with asymmetric manifestations based on length of observation time, the

dominant eye, "eye switching" or the amount of squint during the observation time.^{3,6} Damage can be skewed by oculo-anatomic dissimilarities between the eyes, such as media clarity, an intra-ocular lens, and an irregular, dilated or miotic pupil.^{3,6,15} Other reasons for this unusual exposure are: sun gazing as part of a religious ritual or for holistic healing, accidental exposure from unprotected sunbathing, taking photosensitizing medications such as tetracycline, mental illness or a chemically altered state (e.g., drugs, alcohol).^{2,3,9} Temperature, ozone and latitude can influence solar injuries.^{6,17}

Many patients with solar retinopathy will initially deny sun gazing, making the diagnosis challenging.^{6,8} While no gender or racial predilections exist, young people are the most susceptible, secondary to the clarity of their media and a lack of knowledge and experience.³ The general incidence of solar retinopathy is low.¹⁻¹¹

Signs and symptoms of solar retinopathy often develop a few hours after exposure, similar to the appearance of a hematoma following blunt trauma.^{3,16} Patients present with some form of visual impairment—usually reduced visual acuity from 20/40 to 20/80, which may improve after some recovery time.¹⁻¹⁶ As the injury evolves, the acuity may drop to levels of 20/200 or worse with observable metamorphopsia (facial and traditional Amsler grid), glare, central or paracentral scotoma, and migraine headache or eye ache.^{2-7,14,16}

Like the symptoms, physical signs of injury require time to develop. Hours after exposure, the macula may still appear normal upon ophthalmoscopic examination and photodocumentation.²⁻⁷ After 24 hours, the foveal reflex is often lost.^{2-7,12} The retina may or may not exhibit edema, but the macular RPE often demonstrates a round (shape of the sun or whatever was being viewed), mottled, gray thickening.^{2-7,12,16} Early

changes tend to fade, leaving a small, yellow cystic lesion in the fovea with clumped RPE pigmentation.^{2-7,12-16}

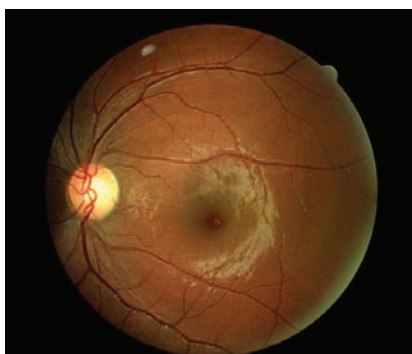
After 14 days, the lesion develops into a lamellar or juxtafoveolar defect with well-demarcated, reddish, irregular edges.

While this lesion can improve over time in cases of mild injury, it generally does not.^{6,12} This lamellar defect is pathognomonic of solar retinopathy.^{6,11-14}

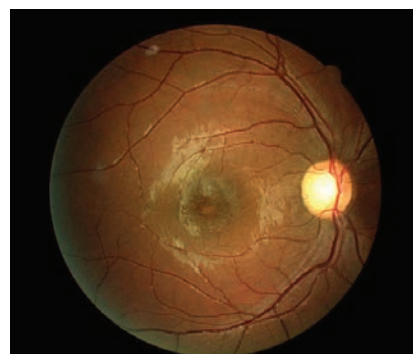Pathophysiology

Optical coherence tomography (OCT) and fundus autofluorescence photography (FAF), a noninvasive technique based on the properties of autofluorescent retinal fluorophores (such as lipofuscin) located in the RPE, can provide key data toward accurate diagnosis.^{1,6,12-15} Studies examining the findings of OCT-based platforms used for imaging the foveal alterations in solar retinopathy have identified fragmentation of the inner hyperreflective layer, and fusion of the inner and outer hyperreflective layers without spaces, as well as interruption of the inner-hyperreflective layer and a lack of reflectivity of the underlying layer.³ Juxtafoveal microcystic cavities in the outer retina, interruption of the external limiting membrane, and inner and outer segment junctions with disorganized material in the vitelliform space have also been identified in solar retinopathy.^{6,11-15} FAF imaging of solar retinopathy demonstrates hypoautofluorescence surrounded by a relatively hyperautofluorescent ring.⁶ Reduced content of lipofuscin in the RPE has been described in cases of light-induced loss of photoreceptors.⁶

Light can damage the external ocular structures and retina by way of any combination of mechanical, thermal or photochemical means.¹⁻¹⁶ Photochemical (i.e., actinic) damage typically occurs following prolonged low irradiance exposure lasting between 10 seconds and 90 seconds.¹⁶ The ocular optical system converges light rays onto the macula; prolonged exposure to any bright light



Solar retinopathy with foveal cysts.



will eventually generate a photic injury.^{3,6,16} Sustained direct solar observation for longer than 90 seconds, even through a constricted pupil, can raise retinal temperatures upwards of 22 degrees Celsius, far above the threshold for photocoagulation.^{16,18}

Solar radiation, i.e., energy generated by the emission of electrons or alpha particles, is absorbed by the RPE.^{6,16} This energy induces toxicity, which in turn reduces the lipofuscin content of the RPE cells and decreases phagocytosis of photoreceptor outer segments.⁶ This physiology may explain the FAF findings of the hyperautofluorescent ring with reduced central autofluorescence.⁶ Damage to the photoreceptors induces a lack of normal outer segment processing, which can lead to an elevated accumulation of outer segments in the outer retina and subretinal space visible upon SD-OCT.^{1,13-15} Bisretinoid N-retinylidene-N-retinylethanolamine (A2E) also accumulates in the outer retina and is visible as the yellow autofluorescent lesion soon after injury.⁶

Another pathophysiological aspect of solar retinopathy is light-induced damage of the apical melanosomes of the RPE by highly reactive free radicals created by blue-light wavelengths.⁶ Susceptibility to this damage varies between individuals. As previously mentioned, young people are more vulnerable, but their capacity for regeneration is greater as well.³

Management

Solar retinopathy has a dubious prognosis; in the mildest exposures, visual acuity and field may return close to pre-exposure levels within three to seven months so long as re-injury or repeat exposures are discontinued.¹⁻¹⁷ In cases with extended exposure and greater acuity reduction, the prognosis is poor. No treatment is available for cases that develop persistent lamellar defects associated with lost acuity, continued metamorphopsia or scotomata. Current standard of care is education toward prevention (i.e., don't sun gaze; wear appropriate eye wear when sunbathing, tanning or welding; and only observe an eclipse or the sun through appropriate astronomical filters or devices), home monitoring with an Amsler grid to ensure stability, and office monitoring for the formation of additional retinal complications such as solar-induced drusenoid changes and the rare formation of choroidal neovascularization (CNV).¹⁻²⁰

Clinical Pearls

- Solar retinopathy can occur from gazing at the sun, whether during periods of bright sunshine or when the bright intensity is obscured by a lunar eclipse.
- Solar retinopathy can also result from prolonged exposure to the bright lights of ophthalmic instruments, unprotected exposure to tanning bed lighting,

and solar astronomic viewing without proper protective ocular devices.

- Embarrassment over religious beliefs, state of mind, lack of common sense or lack of preparedness may cause patients to deny sun gazing.
- The granular gray macular coloration and circular, red, edgeless lesion mimicking a retinal hole (foveal lamellar lesion) are classic findings of solar retinopathy.

1. Jain A, Desai RU, Charalel RA, et al. Solar retinopathy: comparison of optical coherence tomography (OCT) and fluorescein angiography (FA). *Retina*. 2009;29(9):1340-5.
2. Khatib N, Kryazer B, Lifshitz T, et al. Acute eclipse retinopathy: a small case series. *J Optom*. 2014;7(4):225-8.
3. Stock RA, Savaris SL, de Lima Filho EC, et al. Solar retinopathy without abnormal exposure: case report. *Arq Bras Oftalmol*. 2013;76(2):118-20.
4. Stokkermans TJ, Dunbar MT. Solar retinopathy in a hospital-based primary care clinic. *J Am Optom Assoc*. 1998;69(10):625-36.
5. Atmaca LS, Idil A, Can D. Early and late visual prognosis in solar retinopathy. *Graefes Arch Clin Exp Ophthalmol*. 1995;233(12):801-4.
6. Bruè C, Mariotti C, De Franco E, et al. Solar retinopathy: a multimodal analysis. *Case Rep Ophthalmol Med*. 2013;2013(2):906920.
7. Yannuzzi LA, Fisher YL, Slakter JS, et al. Solar retinopathy. A photobiologic and geophysical analysis. *Retina*. 1989;9(1):28-43.
8. Rai N, Thuladar L, Brandt F, et al. Solar retinopathy: a study from Nepal and from Germany. *Documenta Ophthalmologica*. 1998;95(2):99-108.
9. Vojniković B, Njirić S. Solar spectral lines ("solar halo")-healing or harmful for the retina? *Coll Antropol*. 2010;34(4) Suppl 2:127-9.
10. Youssef PN, Sheibani N, Albert DM. Retinal light toxicity. *Eye (Lond)*. 2011;25(1):1-14.
11. Volkov W, Kharitonova NN, Mal'tsev DS. Tanning lamp radiation-induced photochemical retinal damage. *Vestn Oftalmol*. 2014;130(1):63-72.
12. Moran S, O'Donoghue E. Solar retinopathy secondary to sungazing. *BMJ Case Rep*. 2013;2013(1):pii:bcr2012008402.
13. Kung YH, Wu TT, Sheu SJ. Subtle solar retinopathy detected by fourier-domain optical coherence tomography. *J Chin Med Assoc*. 2010;73(7):396-8.
14. Chen KC, Jung JJ, Aizman A. High definition spectral domain optical coherence tomography findings in three patients with solar retinopathy and review of the literature. *Open Ophthalmol J*. 2012;6(6):29-35.
15. Li KH, Chen SN, Hwang JF, et al. Unusual optical coherence tomography and fundus autofluorescence findings of eclipse retinopathy. *Indian J Ophthalmol*. 2012;60(6):561-3.
16. Bauml CR. Light toxicity and laser burns. In: Yanoff M, Duker JS. *Ophthalmology*. Mosby-Elsevier, St. Louis, MO. 2009:1018-23.
17. Vojniković B, Toth I. Daily variation of UV-A and UV-B solar radiation on the Adriatic Sea. *Coll Antropol*. 2011;35(9) Suppl 2:3-5.
18. White TJ, Mainster MA, Wilson PW, Tips JH. Chororetinal temperature increases from solar observation. *Bull Math Biophys*. 1971;33(1):1-17.
19. Gastro-Correia J, Coutinho MF, Maria J, et al. Solar radiation and choroidal neovascularization. An epidemiologic study. *Ophthalmology*. 1988;2(2):177-9.

20. Alexander LJ. Age-related macular degeneration: the current understanding of the status of clinicopathology, diagnosis and management. *J Am Optom Assoc*. 1993;64(12):822-37.

IDIOPATHIC MACULAR TELANGIECTASIA

Signs and Symptoms

Idiopathic macular telangiectasia (IMT), formerly known as idiopathic juxtafoveal retinal telangiectasia (IJRT), is a retinal vascular malformation.¹⁻¹⁹ Clinical and angiographic features along with the method for classification were first described by Gass and Oyakawa in 1982.^{1,2} The lesions were further reclassified by Gass and Blodi in 1993.¹⁻³ Yannuzzi and associates described their features visible with optical coherence tomography (OCT), contributing to the original classification by Gass and revisited the method of classification, ultimately restaging the entity.³ IMT remains the current terminology used.¹⁻¹¹

The symptoms associated with all forms of IMT are variable, painless disturbances in vision.¹⁻¹⁵ When lesions do not affect the macula and do not occur on the visual axis, signs are present with an absence of symptoms. When the lesions enlarge, exude, bleed or induce the formation of choroidal neovascularization (CNV) in or around the fovea, symptoms can range from metamorphopsia and reduced acuity to relative and absolute scotomata (depending on the lesion size, the edema produced and presence or absence of intraretinal exudation) or even hemorrhage and macular hole formation.¹⁻¹⁵ As the condition progresses, CNV and scarring processes may produce macular atrophy and lamellar or full-thickness macular holes, worsening signs and symptoms accordingly.⁷

IMT is observable as a grayish discoloration of the affected retinal region, with loss of retinal transparency.^{7,15} Additionally, perifoveal hemorrhage or exudation is possible. The affected area is often temporally adjacent to the fovea.⁷

In the earliest stages of all subtypes, telangiectatic vessels will be absent or barely evident on clinical examination and OCT imaging. Fluorescein angiography (FA) or optical coherence tomography angiography (OCTA) is often necessary to elucidate the abnormally developing juxtafoveal capillary network.¹⁻¹¹

Multiple golden-crystalline, refractile neurosensory retinal deposits may form adjacent to where the vascular anomaly is developing. Diagnosis can be challenging at this stage, since talc and tamoxifen are also capable of producing crystalline retinopathy.⁵ Intraretinal, round, yellow spot lesions measuring between 100µm and 300µm in diameter, similar to those seen in the adult form of vitelliform foveomacular dystrophy or Best's disease, occur in up to 5% of cases of IMT.⁷ Ectatic capillaries, blunted venules, retinal pigment plaques, foveal atrophy and neovascular complexes are all characteristics of the three subtypes and stages.¹⁵ Leakage of telangiectatic macular capillaries is a characteristic finding on fluorescein angiography (FA), and neurosensory atrophy may be detectable upon OCT imaging.

The new technology of confocal blue reflectance (CBR) imaging may permit early diagnosis.⁸ CBR is a fast, safe, non-invasive imaging modality that captures the fundus reflectance after illuminating it with a confocal blue light of 488nm emitted by a scanning laser ophthalmoscope.⁸ This wavelength accentuates the visibility of blood vessels and enhances the contrast of certain structures on the surface of the retina, rendering them easier to see compared to white-light-illuminated images. It is particularly adept at uncovering deficiencies of the Müller cells in IMT cases.⁸ Optical pigment densitometry may also provide useful, characteristic, stage-dependent data demonstrating retinal capillary proliferation and penetration into the retinal pigment epithelium (RPE) with depleted macular pigment density (MPD).^{10,15}

Lamellar macular holes may develop as the result of focal atrophy of the foveolar retina.^{7,8} These holes are characterized by a distinct, often-circular margin in the setting of central retinal thinning that does not extend beyond the edges of the capillary-free zone.^{1-3,7,8,12,13} Full-thickness macular holes have been reported as sequelae of IMT-2 (described below).^{7,14} A macular hole should be suspected when visual acuity is poor and a central scotoma or metamorphopsia is reported/detected. It can be identified by ophthalmoscopic observation and supported by the Watzke-Allen test.

Pathophysiology

IMT pathophysiology is incompletely understood.¹⁻¹¹ IMT is categorized into types (IMT-1 and IMT-2), with each type subcategorized by various stages connoting characteristics.¹⁻¹¹ Each subtype and stage takes into account the entity's frequency, affected gender, age of onset, laterality and retinal findings.^{3,11}

IMT-1 consists of aneurysmal telangiectasia characterized by predominantly unilateral capillary, venular and arteriolar aneurysms and telangiectatic abnormalities in the juxtafoveal region (1-199 μ m).^{1-3,10} IMT-1a is the second most common form of the disease.¹¹ It can occur congenitally or be acquired between the second and fifth decades of life.¹¹ It occurs predominantly in males (90%) and is marked by unilateral macular telangiectasia with visible aneurysms.¹¹ Symptoms are pursuant to the volume of macular edema and exudation.¹¹ IMT-1a demonstrates visible exudation with minimal capillary occlusion. IMT-1b presents with similar findings, is more rare and typically presents in the fourth to sixth decade of life.¹¹ Recently, a new variant was reported and tentatively classified as IMT-1c, characterized by unilateral macular telangiectasia with visible aneurysms and macular edema complicated by neovascularization similar to that seen in IMT-3 disease.¹¹

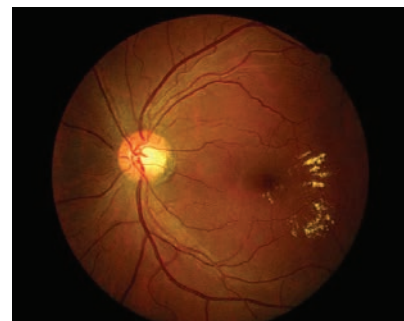IMT-2a is the most commonly seen form of the disease.¹¹ It is acquired (no genetic link known), bilateral and affects males and females equally in the third to fifth decades with macular telangiectasia that tend to induce formation of intraretinal and/or occult (poorly defined on FA) subretinal neovascularization.^{1-3,11} IMT-2b is recognized for its presentation in younger subjects with a family history of IMT, and demonstrates a greater incidence of capillary occlusions on FA.^{1-3,11}

IMT-3 is rare, bilateral and associated with vascular occlusions.^{1-3,11} IMT-3a presents predominantly in women between the third and fifth decades, is acquired and is noted to exude minimally.¹¹ IMT-3b may have a congenital vector (still under investigation), has no gender predilection and is associated with central nervous system vasculopathies.¹¹

While the IMT-2 subtypes have worse sequelae and prognoses with more dubious outcomes even in the setting of attempted treatment, they are an exceedingly rare form of the disease; estimated prevalence ranges from 1/1,000 to 5/100,000 people.^{19,20}

Evidence of genetic transmittance exists, but investigations are ongoing.¹¹ Other retinal diseases, such as Coats' disease, can cause the formation of retinal telangiectasia, but IMT is unique, as its presentation is limited to the parafoveal area without any specific inciting cause.¹⁻¹¹ Some investigators have hypothesized that the condition is in fact a variant of Coats' disease.¹⁻³

Defective Müller cells, which play a role in the storage and metabolism of macular pigment, are theorized to play a role in the formation of highly reflective intraretinal crystalline deposits.^{7,8} Deposit formation neither correlates with disease severity nor predicts its course.⁷ Stellate intraretinal pigmented black plaques composed of hyperplastic RPE cells may develop, creating intraretinal



Macular telangiectasia and its resultant circinate exudative leakage can be seen.

architecture that promotes development of the clinicopathologic feature known as right-angled vessels.^{1-3,7,8} Other investigators have documented histopathological abnormalities in retinal vessels, including vascular ectasia as well as pericyte and endothelial cell degeneration.¹⁹

CNV develops as a consequence of intraretinal injury.¹⁻¹⁷ Upregulated chemokines and cytokines provoked by the disease's course (crystalline deposition, pigment plaque formation, exaggerated exudation, vessel and neuronal degeneration, and intraretinal and subretinal bleeding) induce CNV growth.^{17,19} Subretinal hemorrhage, cystoid macular edema, lipid hard exudates, disciform scarring and retinochoroidal anastomosis all produce rapid significant vision loss with some form of permanent visual disability.^{3,7,8,15,17} Unlike choroidal neovascularization in age-related macular degeneration (AMD), CNV in IMT is not usually accompanied by an RPE detachment.⁷ Further, the size of IMT CNV compared to the CNV produced in AMD is small.⁷

At the heart of IMT pathophysiology is macular retinal pigment alteration and Müller cell depletion.^{7,8} Müller cells also help provide nutrition to the surrounding retinal neurons by maintaining the integrity of the blood-retinal barrier in the outer plexiform layer.^{7,8} Müller cells span the entire retinal thickness. They allow efficient light transmission with minimal reflection.

Research has shown no evidence of increased lipofuscin accumulation in the RPE.⁷ Immunohistochemical analysis of the IMT process has demonstrated loss of the perifoveal Müller cells.^{7,8} Müller cell depletion in IMT has been documented through OCT and CBR imaging.⁸

Müller cells serve as a retinal reservoir for xanthophyll.⁸ Any pathological process that involves the cells will affect macular pigment. Since the range of blue light at approximately the 460nm spectrum is absorbed maximally by macular pigments, decreased absorption or increased reflection of blue light is detectable when pigment in the foveal and parafoveal area is depleted.^{7,8} This is the basis of CBR imaging and explains why CBR imaging is effective at detecting early injury in the IMT process.⁸

OCT hyporeflective zones represent cavitory spaces secondary to Müller cell loss rather than fluid-filled cystic spaces.^{1-3,7,8} Pathological involvement of Müller cells decreases light transmission and creates increased retinal reflectance. Disruption of Müller cells coupled with the presence of macular or perifoveal edema and exudation released from compromised retinal telangiectatic vessels contribute to lost function.^{7,8} The pathophysiology also seems to confirm that IMT-2 is as much a neurodegenerative disease, as it is a vascular one.^{1-3,7,8} It is unclear why some IMT-2 lesions develop CNV and others do not.¹⁻¹⁶

Management

In nonproliferative cases where vision is unaffected, initial photodocumentation with subsequent in-home Amsler grid monitoring and biannual dilated funduscopy is acceptable. Focal laser photocoagulation, photodynamic therapy, steroid injection and anti-VEGF injections have all been attempted in nonproliferative cases where acuity is reduced secondary to refractory macular edema, yielding mixed results.^{1-4,6,7,15,17,18} Currently, laser

photocoagulation is the most popular intervention, with a solid reputation for reducing vascular leakage and a reasonable record of success in IMT-1 cases.¹⁷ The disadvantage and risk of laser photocoagulation is that, while it may regress retinal swelling, it may concurrently produce retinal scar formation that permanently reduces function.¹⁷

The exact role of VEGF in IMT-1 pathogenesis remains unclear. Interventions with anti-VEGF agents have been inconsistent.¹⁷ Given the risks of photocoagulation, investigations to uncover the best treatment are underway. Aflibercept (Regeneron Pharmaceuticals), a recombinant fusion protein with high affinity for binding many related growth factors, such as placental growth factors 1 and 2, VEGF-A and VEGF-B, has shown promise.¹⁷ Intravitreal steroid injections have also been attempted with mixed success in cases not responding to the laser or anti-VEGF treatment.¹⁸

Currently, no proven effective treatment or prevention strategy exists for visually significant IMT-2 lesions.^{1-4,6,7,15,17-20} Multiple case reports have documented the clinical benefits of anti-VEGF inhibition; given the pathophysiology of IMT-2 disease, the strategy seems intuitive. Macular holes produced by IMT processes cannot be treated; they are the result of atrophic, as opposed to tractional, processes not amenable to vitrectomy with tamponade.

Clinical Pearls

- The predominant cause of lost function in nonproliferative IMT cases is macular edema.
- The predominant cause of catastrophic lost function is CNV.
- IMT is categorized into types (IMT-1 and IMT-2), with each type subcategorized by various stages connoting characteristics. Each subtype and stage takes into account the entity's frequency, affected gender, age of onset,

laterality and retinal findings.

- In nonproliferative cases where vision is unaffected, photodocumentation with both in-home Amsler grid and biannual dilated monitoring is acceptable. Focal laser photocoagulation, photodynamic therapy and anti-VEGF injections have all been attempted in nonproliferative cases where acuity is reduced secondary to refractory macular edema with mixed results.

- No proven guidelines exist for the prevention or treatment of CNV from IMT-2 lesions. Given their pathophysiology, anti-VEGF injections are being investigated.

- OCT classically shows a superficial retinal, fluid-filled cyst with an intact overlying internal limiting membrane, described as a *retinal drape*.

1. Nakhwa CP, Sindal MD. Idiopathic macular telangiectasia type 1 with ruptured retinal arterial macroaneurysm post intravitreal bevacizumab. Middle East Afr J Ophthalmol. 2015;22(3):396-8.

2. Gass JD, Blodi BA. Idiopathic juxtafoveal retinal telangiectasis. Update of classification and follow-up study. Ophthalmology. 1993;100(10):1536-46.

3. Yannuzzi LA, Bardal AM, Freund KB, et al. Idiopathic macular telangiectasia. Arch Ophthalmol. 2006;124(4):450-60.

4. Veloso CE, Vianna RN, Pelayes DE, et al. Intravitreal bevacizumab for type 2 idiopathic macular telangiectasia. Ophthalmic Res. 2013;49(4):205-8.

5. Rijal RK, Nakhwa C, Sindal MD. Crystalline deposits in the macula - tamoxifen maculopathy or macular telangiectasia? Nepal J Ophthalmol. 2014;6(2):227-9.

6. De Bats F, Denis P, Kodjikian L. Idiopathic macular telangiectasia: clinical appearance, imaging and treatment. J Fr Ophthalmol. 2013;36(2):164-71.

7. Wu L. Multimodality imaging in macular telangiectasia 2: A clue to its pathogenesis. Indian J Ophthalmol. 2015;63(5):394-8.

8. Powner MB, Gillies MC, Tretiaeh M, et al. Perifoveal müller cell depletion in a case of macular telangiectasia type 2. Ophthalmology. 2010;117(12):2407-16.

9. Charbel Issa P, Heeren TF, Krüger E, et al. Morphological characteristics in macular telangiectasia type 2. Ophthalmologie. 2014;111(9):819-28.

10. Chin EK, Kim DY, Hunter AA 3rd, et al. Staging of macular telangiectasia: power-Doppler optical coherence tomography and macular pigment optical density. Invest Ophthalmol Vis Sci. 2013;54(7):4459-70.

11. Tilleul J, Querques G, Capuano V, et al. Type 1 idiopathic macular telangiectasia associated with type 3 neovascularization. Case Rep Ophthalmol. 2014;5(3):352-6.

12. Gass JD, Oyakawa RT. Idiopathic juxtafoveal retinal telangiectasis. Arch Ophthalmol. 1982;100(5):769-80.

13. Patel B, Duvall J, Tullio AB. Lamellar macular hole associated with idiopathic juxtafoveal telangiectasia. Br J Ophthalmol. 1988;72(7):550-1.

14. Shukla D. Evolution and management of macular hole secondary to type 2 idiopathic macular telangiectasia. Eye (Lond). 2011;25(4):532-3.

15. Charbel Issa P, Kupitz EH, Heeren TF, et al. Treatment for macular telangiectasia type 2. *Dev Ophthalmol*. 2016;55(10):189-95.
16. Zhang Q, Wang RK, Chen CL, et al. Swept source optical coherence tomography angiography of neovascular macular telangiectasia type 2. *Retina*. 2015;35(11):2285-99.
17. Shibebe O, Vaze A, Gillies M, et al. Macular oedema in idiopathic macular telangiectasia type 1 responsive to aflibercept but not bevacizumab. *Case Rep Ophthalmol Med*. 2014;2014(10):219792.
18. Loutfi M, Papathomas T, Kamal A. Macular oedema related to idiopathic macular telangiectasia type 1 treated with dexamethasone intravitreal implant (ozurdex). *Case Rep Ophthalmol Med*. 2014;2014(6):231913.
19. Toy BC, Koo E, Cukras C, et al. Treatment of nonneovascular idiopathic macular telangiectasia type 2 with intravitreal ranibizumab: results of a phase II clinical trial. *Retina*. 2012;32(5):996-1006.
20. Klein R, Blodi BA, Meurer SM, et al. The prevalence of macular telangiectasia type 2 in the Beaver Dam eye study. *Am J Ophthalmol*. 2010;150(1):55-62.

RETINAL ARTERY OCCLUSION

Signs and Symptoms

Acute retinal artery occlusions (RAO) are visually debilitating events.^{1,2} Categorized as branch (BRAO), central (CRAO), cilioretinal or ophthalmic, depending on the location of the blockage, they are not the result of a single disease but develop from several systemic abnormalities.^{2,3} As such, there is no definitive epidemiology for RAO. Instead, the epidemiology varies with systemic diseases and risk factors that cause the blockages, such as heart disease, cardiovascular disease, smoking, obesity, and other chronic or episodic contributors (bacterial endocarditis, tumors, leukemia, corticosteroid injection, polyarteritis nodosa, syphilis, blunt trauma, radiation exposure, optic nerve drusen, amniotic fluid embolism, cocaine abuse).^{3,4} The majority of patients with RAO are older adults.³

Patients present with sudden painless monocular vision loss, either of central acuity, visual field or both.¹⁻⁴ In many cases, the loss is noticed upon waking. When a branch retinal artery is involved or a cilioretinal artery is present in CRAO, patients are more likely to complain of shadows in their visual field or notice that parts of it are missing. Some patients may report that they had been experiencing episodes of transient visual

loss before the current episode.³⁻⁵ While the etiology of retinal artery obstruction is primarily embolic, plaques are not always visible.²

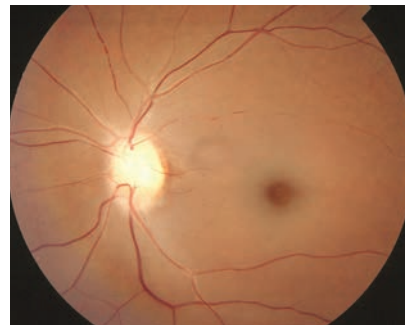
As artery occlusions develop, the funduscopic appearance will vary. As blood flow is impeded, retinal function becomes compromised immediately, though initially the retina may appear unaffected and normal.¹⁻⁵ However, as the ischemia evolves, retinal arteries may be visibly narrowed. The retina will then appear pale with swelling.¹⁻⁵ Nerve fiber layer hemorrhages may be present in the parapapillary area.³ The classic macular “cherry red spot” seen in CRAO occurs due the absence of foveal photoreceptors and thinner anatomy in the macular region.³ Here, the intact choroidal circulation is highlighted by the surrounding retinal pallor, allowing it to stand out.¹⁻¹¹

Following the acute injury, the retinal appearance resolves over the course of weeks. Unfortunately, function rarely returns, although there have been isolated reports of visual function improving over time, with or without treatment.^{1-4,6,7}

Pathophysiology

Emboli from various sources travel through the vascular system, becoming lodged inside a retinal vessel, partially or completely obstructing the flow of blood to distal tissues.^{2,4} Calcific emboli are most likely to cause retinal artery occlusion and are often cardiac in origin. Multiple reports in the literature cite etiologies related to malfunctioning clotting factors in blood, such as antiphospholipid disease, factor VIII abnormality along with protein S and C alteration as an underlying source.⁷⁻⁹ Amniotic fluid embolism has also been recorded as an uncommon source of retinal emboli.¹⁰

As the oxygen-sensitive retinal elements become oxygen deprived, they quickly begin to fail, creating symptoms of variable visual phenomena or complete painless vision loss.¹⁻⁷ Retinal tissue is



The classic macular “cherry red spot” seen in central retinal artery occlusion occurs due the absence of foveal photoreceptors and thinner anatomy in the macular region.

extremely sensitive to oxidative stress.¹² The inner layers of the retina succumb to ischemia, with intracellular edema and necrosis present within 70 minutes of the event.³

When partial or complete retinal arterial occlusion occurs, tissue ischemia begins. Retinal ischemia initiates the process of vascular endothelial growth factor (VEGF) release with subsequent neovascularization in the anterior and posterior segments.¹¹ Interestingly, neovascular complications from retinal artery occlusion are infrequent when compared to other retinal vascular diseases, such as retinal vein occlusion and diabetes, because artery occlusion causes the retinal tissue to infarct and die rather than oxygen starve. Thus, there is very little release of angiogenic factors.

Hypertension is clearly a major risk factor for the development of microvasculopathy in general.¹³ As such, it increases the risk for retinal vascular events such as retinal vein occlusion, RAO and ischemic optic neuropathy.¹³ Sickle cell disease has also been noted as an etiology of RAO.¹⁴ While most cases are the result of cardiac, carotid, vascular, hemodynamic or autoimmune diseases, rare instances occur in which retinal artery occlusions manifest in healthy individuals with no attributable systemic etiology found.^{7,15} Additionally, some cases of central retinal artery occlusion

are caused not by emboli but rather by thrombus and vascular lumen necrosis from giant cell arteritis (GCA). This condition must be considered as a possible cause of retinal artery occlusion in elderly patients in order to prevent fellow eye vision loss.^{2,3}

Management

Retinal artery occlusion management needs to follow the same principles of treatment as any other vascular end-organ ischemic disease, which is to attempt to reperfuse ischemic tissue as quickly as possible and to institute secondary prevention early on. Thus, the key to any visual recovery in any RAO is timely intervention. Anecdotally, the potential for achieving any restoration of vision is greatest when the blockage is dislodged within 100 minutes of the onset of the first symptoms.^{3,16} While frequently unsuccessful, emergent treatments are designed to increase retinal perfusion by reestablishing retinal blood flow.^{1-4,16}

The traditional mechanism of increasing intraocular pressure by aggressive digital palpation with sudden release is designed to stimulate retinal autoregulatory mechanisms. Here, as the retinal tissues sense the general hypoxia created by the digitally applied force, the retinal vasculature dilates to increase blood flow. When intraocular pressure drops and aqueous is forced from the eye, resistance to incoming blood decreases. The hope is that the emboli will be dislodged and move further down the retinal arterial system, permitting reperfusion to the critical central retinal tissue.³ Other strategies for dislodging the embolus include decreasing the resistance to ocular blood flow by reducing intraocular pressure via topical and oral medication, or paracentesis. An alternate strategy involves stimulating retinal vascular dilation by increasing blood carbon dioxide levels, either by breathing into a paper bag, inhaling a Carbogen mixture (95%

oxygen, 5% carbon dioxide) or taking sublingual nitroglycerine.³

Unfortunately, heroic measures rarely impact the final outcome. Hyperbaric oxygen therapy has shown anecdotal success at restoring vision in several case reports and series.¹⁷⁻²⁰ Visual prognosis for this therapy is dependent upon the time lag from the onset of symptoms to the beginning of hyperbaric oxygenation treatment, and the time lag until retinal reperfusion begins. Hyperbaric oxygenation treatment can compensate for retinal ischemia, but the lack of glucose and accumulation of toxic metabolites is not addressed.¹⁷⁻²⁰ Currently, a large number of nonresponders combined with a lack of controlled clinical trials makes hyperbaric oxygen therapy a speculative treatment at this time. Also, hyperbaric chambers are not readily available in many areas, and the treatment is often not covered by insurance.

A technique using an Nd:YAG laser to photodisrupt emboli within the central retinal artery and branch retinal arteries may help achieve rapid reperfusion of the retina.⁴ Transluminal Nd:YAG embolysis (TYL) or embolectomy (TYE) has been reported as a potential procedure capable of quick deployment in cases of retinal nonperfusion secondary to embolic blockage.⁴ In one study following TYL, Snellen visual acuity improved by an average of 4.7 lines in 17 of 19 patients (89%), and 11 patients (58%) gained greater than four lines.⁴ Vitreous hemorrhage and subhyaloid hemorrhage are potential complications.⁴

Patients with artery occlusion must receive a complete systemic workup to uncover the underlying cause.^{4,15} Evaluation should include a complete blood count with differential and platelets, an erythrocyte sedimentation rate (ESR), C-reactive protein (CRP), lipid panel, carotid artery evaluation using transcranial Doppler, prothrombin time, activated partial thromboplastin time, protein S, protein C, antiphospholipid

antibody testing, antinuclear antibody and lupus anticoagulant testing, echocardiogram and transesophageal echocardiogram.^{8,9,15,21-24} Previously undiagnosed vascular risk factors have been found in 78% of all CRAO patients. Systemic arterial hypertension is the most commonly associated risk factor, while the most meaningful risk factor was ipsilateral carotid artery stenosis leading to endarterectomy. In elderly patients with systemic symptoms suggestive of GCA, obtaining ESR and CRP is emergently required.^{25,26}

Intra-arterial thrombolysis (IAT) represents an aggressive approach to treating retinal arterial occlusions with the potential to produce superior visual outcomes compared with conventional treatments.²⁷⁻²⁹ While the strategy of using intravenous and intra-arterial thrombolytic agents such as urokinase has existed and been investigated for more than 20 years, insufficient evidence is available to support routine use of the treatment.²⁷⁻³⁰ More recently, intravenous recombinant tissue plasminogen activator has shown some success in restoring visual function.^{31,32} A lack of controlled clinical trials also make this a speculative treatment. The studies demonstrate best efficacy requires intervention in less than six hours from arterial occlusion.

Most importantly, there has been a paradigm shift in the evaluation and management of patients with acute RAO. American Heart Association/American Stroke Association (AHA/ASA) guidelines recommend that all patients with suspected retinal ischemia should undergo immediate brain imaging. In the period immediately following acute RAO, there is an increased risk of coronary and cerebral infarction.^{33,34} It has been well documented that silent brain infarction on diffusion-weighted magnetic resonance imaging (DW-MRI) is a frequent finding in patients with BRAO and CRAO.³⁵⁻⁴⁰ Acute ischemic stroke has been detected

in approximately 25% of RAO patients, with nearly 40% *not* exhibiting any neurologic symptoms or signs consistent with stroke.³⁶ These silent brain infarctions bear a high risk of future stroke.

Patients with BRAO and CRAO should undergo prompt neuroimaging and evaluation, preferably upon hospital admission to a stroke unit. Current recommendations advise to emergently refer RAO patients to a specialized stroke facility for immediate DW-MRI and evaluation.³⁹ Many of these patients will be admitted on the spot for a comprehensive stroke assessment and management.

Clinical Pearls

- Cilioretinal arteries take their blood supply from the choroid, often emerging from the temporal optic nerve and aiding in the supply of retinal tissues in the vicinity of the macula. In the event that a CRAO occurs in the presence of a cilioretinal artery, these vessels can partially preserve function over the area of their distribution so long as the occlusion also does not effect the choroidal circulation.
- Patients with the primary antiphospholipid antibody syndrome may develop RAO as well as exhibit episodes of ocular or systemic transient ischemic attack (TIA), anterior ischemic optic neuropathy, cilioretinal artery occlusion, CRAO and ophthalmic artery occlusion. Ocular TIA, retinal vascular thrombosis and optic neuropathy are considered the ocular hallmark signs of Hughes' syndrome. Testing for autoimmune factors and antiphospholipid antibody syndrome is especially important in younger patients with retinal artery occlusion.
- Heroic measures to restore retinal perfusion typically fail in the majority of these cases because patients delay seeking treatment.
- Patients with RAO need to immediately undergo DW-MRI to ascertain if there is any concurrent cerebrovascular infarction or risk for debilitating stroke.

These patients need rapid referral and admission to a stroke unit. Eye care practitioners should not attempt to obtain this imaging. Acute RAO should no longer be thought of solely as an ocular condition. These patients should be considered to be having a stroke.

- Identify a local facility with a stroke unit. When a patient presents with any form of RAO, time for intervention and investigation is critical.
- Never forget the possibility of GCA as a potential cause of CRAO in elderly patients.

- Pokhrel PK, Loftus SA. Ocular emergencies. *Am Fam Physician*. 2007; 76(6):829-36.
- Hayreh SS. Prevalent misconceptions about acute retinal vascular occlusive disorders. *Prog Retin Eye Res*. 2005; 24(4):493-519.
- Duker JS. Retinal arterial obstruction. In: Yanoff M, Duker JS. *Ophthalmology* 2nd Ed. St Louis, MO, Mosby 2004: 854-61.
- Opremac E, Rehmar AJ, Ridenour CD et al. Restoration of retinal blood flow via transluminal Nd:YAG embolysis/embolectomy (TYL/E) for central and branch retinal artery occlusion. *Retina*. 2008; 28(2):226-35.
- Schmidt D, Hetzel A, Geibel-Zehender A et al. Systemic diseases in non-inflammatory branch and central retinal artery occlusion--an overview of 416 patients. *Eur J Med Res*. 2007; 12(12):595-603.
- Sowka JW, Vollmer LA, Au M. Atypical retinal vaso-occlusion with structural and functional resolution. *Optom Vis Sci*. 2015;92(1):e6-11.
- Chung YR, Kim JB, Lee K et al. Retinal artery occlusion in a healthy pregnant patient. *Korean J Ophthalmol*. 2008; 22(1):70-1.
- Greven CM, Weaver RG, Owen J et al. Protein S deficiency and bilateral branch retinal artery occlusion. *Ophthalmology*. 1991; 98(1):33-4.
- Nelson ME, Talbot JF, Preston FE. Recurrent multiple-branch retinal arteriole occlusions in a patient with protein C deficiency. *Graefes Arch Clin Exp Ophthalmol*. 1989;227(5):443-7.
- Kim IT, Choi JB. Occlusions of branch retinal arterioles following amniotic fluid embolism. *Ophthalmologica*. 2000; 214(4):305-8.
- Konareva-Kostianeva M. Neovascular glaucoma. *Folia Med (Plovdiv)*. 2005;47(2):5-11.
- Kergoat H, Hérard ME, Lemay M. RGC sensitivity to mild systemic hypoxia. *Invest Ophthalmol Vis Sci*. 2006; 47(12):5423-7.
- Wong TY, Mitchell P. The eye in hypertension. *Lancet*. 2007; 369(9559):425-35.
- Liem RI, Calamaras DM, Chhabra MS, et al. Sudden-onset blindness in sickle cell disease due to retinal artery occlusion. *Pediatr Blood Cancer*. 2008; 50(3):624-7.
- Winterkorn JM, Mack P, Eggenberger E. Transient visual loss in a 60-year-old man. *Surv Ophthalmol*. 2008; 53(3):301-5.
- Hayreh SS, Zimmerman MB, Kimura A, et al. Central retinal artery occlusion. Retinal survival time. *Exp Eye Res*. 2004; 78(3):723-36.
- Menzel-Severing J, Siekmann U, Weinberger A, et al. Early hyperbaric oxygen treatment for nonarteritic central retinal artery obstruction. *Am J Ophthalmol*. 2012;153(3):454-9.
- Weinberger AW, Siekmann UP, Wolf S, et al. Treatment of Acute Central Retinal Artery Occlusion (CRAO) by Hyperbaric Oxygenation Therapy (HBO)--Pilot study with 21 patients. *Klin Monbl Augenheilkd*. 2002;219(10):728-34.
- Cope A, Eggert JV, O'Brien E. Retinal artery occlusion: visual outcome after treatment with hyperbaric oxygen. *Diving Hyperb Med*. 2011;41(3):135-8.
- Demir M, Kara O, Yildiz A, et al. Efficacy of hyperbaric oxygen therapy in a young woman with idiopathic branch retinal artery occlusion. *Diving Hyperb Med*. 2013;43(3):164-5.
- Suvajac G, Stojanovich L, Milenkovich S. Ocular manifestations in antiphospholipid syndrome. *Autoimmun Rev*. 2007; 6(6):409-14.
- Coroi M, Bontas E, Defranceschi M et al. Ocular manifestations of antiphospholipid (Hughes') syndrome--minor features? *Oftalmologia*. 2007; 51(3):16-22.
- Coroi M, Bontas E, Visan R, et al. Ocular migraine and antiphospholipid antibodies--where we stand? *Oftalmologia*. 2007;51(3):8-15.
- Schmidt D, Hetzel A, Geibel-Zehender A. Retinal arterial occlusion due to embolism of suspected cardiac tumors -- report on two patients and review of the topic. *Eur J Med Res*. 2005; 10(7):296-304.
- Callizo J, Feltgen N, Pantenburg S, et al. Cardiovascular Risk Factors in Central Retinal Artery Occlusion: Results of a Prospective and Standardized Medical Examination. *Ophthalmology* 2015;122(9):1881-8.
- Coisy S, Leruez S, Ebran JM, et al. Systemic conditions associated with central and branch retinal artery occlusions. *J Fr Ophtalmol*. 2013;36(9):748-57.
- Noble J, Weizblit N, Baerlocher MO, et al. Intra-arterial thrombolysis for central retinal artery occlusion: a systematic review. *Br J Ophthalmol*. 2008; 92(5):588-93.
- Bioussé V, Calvetti O, Bruce BB, et al. Thrombolysis for central retinal artery occlusion. *J Neuroophthalmol*. 2007; 27(3):215-30.
- Weber J, Remonda L, Mattle HP, et al. Selective intra-arterial fibrinolysis of acute central retinal artery occlusion. *Stroke*. 1998; 29(10):2076-9.
- Vallée JN, Paques M, Aymard A, et al. Combined central retinal arterial and venous obstruction: emergency ophthalmic arterial fibrinolysis. *Radiology*. 2002; 223(2):351-9.
- Nowak RJ, Amin H, Robeson K, et al. Acute central retinal artery occlusion treated with intravenous recombinant tissue plasminogen activator. *J Stroke Cerebrovasc Dis*. 2012;21(8):913.e5-8.
- Chen CS, Lee AW, Campbell B, et al. Efficacy of intravenous tissue-type plasminogen activator in central retinal artery occlusion: report from a randomized, controlled trial. *Stroke*. 2011;42(8):2229-34.
- Chang YS, Chu CC, Weng SF, et al. The risk of acute coronary syndrome after retinal artery occlusion: a population-based cohort study. *Br J Ophthalmol*. 2015;99(2):227-31.
- Park SJ, Choi NK, Yang BR, et al. Risk and risk periods for stroke and acute myocardial infarction in patients with central retinal artery occlusion. *Ophthalmology*. 2015;122(11):2336-2343.e2.
- Lauda F, Neugebauer H, Reiber L, et al. Acute silent brain infarction in monocular visual loss of ischemic origin. *Cerebrovasc Dis*. 2015;40(3-4):151-6.
- Lee J, Kim SW, Lee SC, et al. Co-occurrence of acute retinal artery occlusion and acute ischemic stroke: diffusion-weighted magnetic resonance imaging study. *Am J Ophthalmol*. 2014;157(6):1231-8.
- Moss HE. Retinal vascular changes are a marker for cerebral vascular diseases. *Curr Neurol Neurosci Rep*. 2015;15(7):40.
- Cohen S. Co-occurrence of acute retinal artery occlusion and acute ischemic stroke: diffusion-weighted magnetic resonance imaging study. *Am J Ophthalmol*. 2014;158(4):850.
- Bioussé V. Acute retinal arterial ischemia: an emergency often ignored. *Am J Ophthalmol*. 2014;157(6):1119-21.
- Helenius J, Arsvava EM, Goldstein JN, et al. Concurrent acute brain infarcts in patients with monocular visual loss. *Ann Neurol*. 2012;72(2):286-93.



LACRISERT[®]

(hydroxypropyl cellulose ophthalmic insert)

BAUSCH + LOMB

Lacrisert is a trademark of Valeant Pharmaceuticals International, Inc. or its affiliates.
Bausch + Lomb is a trademark of Bausch & Lomb Incorporated or its affiliates.

©2014 Bausch & Lomb Incorporated

US/LAC/14/0008b

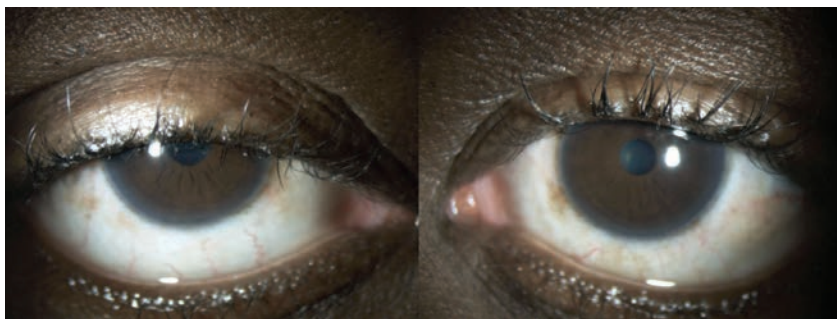
OCULAR MYASTHENIA GRAVIS

Signs and Symptoms

Ocular myasthenia gravis (OMG) is a subset of general myasthenia gravis (GMG) with muscular dysfunction affecting only the levator and extraocular muscles. OMG has a slight male preponderance. There is a bimodal onset for women, peaking around 30 and 60 years, while men have a skewed unimodal age distribution peaking at age 70.¹ GMG affects adults in 90% of cases, with the remaining 10% being children and adolescents.² The incidence of GMG is 72:1,000,000.¹ Non-Caucasian patients are typically diagnosed up to two decades earlier than Caucasians.¹

Patients with OMG will present complaining of new onset ptosis, diplopia or both. Ocular signs and symptoms include intermittent pupil sparing ophthalmoparesis, including oculomotor, trochlear and abducens palsy; ptosis of the eyelid and the pathognomonic Cogan's lid twitch (overshooting of the affected eyelid on upgaze with a final ptotic resting position after prolonged fixation in downgaze). In addition to cranial nerve palsies, presence of isolated inferior oblique, superior rectus and medial rectus underaction as well as a pseudo-internuclear ophthalmoplegia is possible.¹⁻⁶ The ptosis and diplopia may be transient, fluctuating or progressive throughout the day, and may improve with rest.^{2,7}

In patients with pure OMG, there will be no accompanying weakness of any other non-ocular skeletal muscles as seen in GMG. Approximately 53% of patients with OMG present with concurrent GMG, and 44% with OMG will progress to generalized disease within one to two years, most within one year.⁸ Ocular myasthenia gravis is bothersome due to ptosis and diplopia, which causes dysfunction of



Patients with ocular myasthenia gravis often present complaining of new-onset ptosis (as is depicted here), diplopia or both.

daily activities, but GMG is potentially life-threatening. Myasthenic crisis is the catastrophic failure of the skeletal muscles involved in respiration.⁹ Patients in myasthenic crisis develop acute respiratory failure and require prompt airway protection in the form of ventilation support.⁹

Pathophysiology

Both OMG and GMG are considered to arise from an autoimmune, antibody-mediated disorder of neuromuscular synaptic transmission as well as a paraneoplastic syndrome associated with tumors of the thymus gland or thymic hyperplasia. Approximately 10% to 15% of OMG/GMG patients have thymomas, and 30% of thymoma patients have GMG.² Thymomas involve tumorous infiltration of the gland by nonmalignant or malignant cells.¹⁰

In nerve signal propagation, acetylcholine is released from the presynaptic nerve terminal to bind with receptors on the postsynaptic nerve terminal. After the nerve impulse has propagated, the enzyme acetylcholinesterase then degrades the acetylcholine so that it can be repackaged by the presynaptic nerve terminal into new vesicles of acetylcholine for the next nerve impulse conduction.

OMG and GMG result from an antibody-mediated, T cell-dependent immunologic attack on the endplate

region of the postsynaptic membrane. Maverick antibodies occupy the postsynaptic nerve terminal, preventing acetylcholine from reaching the intended target. As the receptors, which receive the neurotransmitter acetylcholine, are degraded, the signal intended to invoke a muscle movement cannot be propagated or maintained. Thus, acetylcholine is blocked from reaching the post-synaptic receptors. Subsequently, acetylcholinesterase degrades acetylcholine, and the component parts are sequestered back into the presynaptic membrane to formulate new acetylcholine for the next action potential. This produces muscle weakness as well as rapid fatiguing and loss of stamina.

Management

Several clinical tests for suspected OMG can be performed in the office:

- A sleep test can be employed with the patient resting with eyes closed for a period of 20 minutes. As the acetylcholine builds up in the presynaptic membranes, pre-existing weaknesses will immediately improve for a short time.
- In a fatigue test, a patient with ptosis is asked to look up. As the patient fatigues, the eyelids drift down and ptosis worsens.
- Additionally, the patient can be asked to squeeze the eyes closed. If the individual lacks strength or fatigues quickly, it will become apparent as the

eyes begin to open despite the attempt to forcefully close them. This phenomenon is known as Osher's "peek sign."

- Finally, for patients with ptosis or ophthalmoplegia, the ice pack test can be employed. Here, a bag of crushed ice covered in a towel is placed over the affected closed eye for two minutes. Lowering the temperature slows the action of acetylcholinesterase, allowing acetylcholine a longer duration in the synaptic cleft and a greater opportunity to interact with post-synaptic receptors. This produces a subsequent improvement in function. Immediate improvement in ptosis is highly suspicious for OMG.

Ocular myasthenia gravis is diagnosed upon clinical suspicion, aided by the tests described above and confirmed with at least one of the following: edrophonium challenge, single-fiber electromyography or positivity of acetylcholine receptor antibodies. However, seronegativity to acetylcholine receptor antibodies occurs in approximately 30% of patients with OMG.¹¹ These patients are instead seropositive for antibodies against the muscle-specific kinase (anti-MuSK-positive).¹² Thus, in some patients with OMG, the diagnosis may be made based using a preponderance of evidence from clinical tests. Three types of acetylcholine receptor antibodies may be involved: binding, blocking and modulating. They cause acetylcholine receptor loss by three mechanisms: blocking of acetylcholine binding, accelerated receptor degradation (antigenic modulation) and lysis of postsynaptic membrane induced by complement. In order to enhance sensitivity, all three should be evaluated.¹³

MG has been associated with other autoimmune diseases, so once diagnosis has been confirmed, additional laboratory work should include a computed tomography (CT) scan of the chest, antinuclear antibody (ANA) testing, a rheumatoid factor (RF) test and a thy-

roid panel (T3, T4, TSH). Reports of an association between OMG/GMG and thyroid ophthalmopathy, another autoimmune disease, have been documented. As such, the overlap of presenting signs and symptoms warrants testing for both OMG and thyroid ophthalmopathy, especially when cases of ophthalmoparesis and ptosis are not totally consistent with one disease or the other.^{14,15}

Initial treatment for symptomatic OMG is anticholinesterase medications. Pyridostigmin bromide is the most commonly used oral anticholinesterase to treat OMG and GMG. It is well tolerated at low doses, with minimal cholinergic side effects. Adverse effects are gastrointestinal disturbance, diarrhea, cramping, hypersalivation, sweating and, rarely, bradycardia and arterioventricular block. Oral ambenonium chloride can be used if gastrointestinal side effects with pyridostigmin are intolerable.² Many patients can achieve relief with these medications.^{7,16}

Immunosuppression is well accepted as part of OMG and GMG management.^{1,2,5,17-19} Glucocorticosteroids and azathioprine are first-line immunosuppressive therapy for OMG and GMG, with cyclosporine, methotrexate and mycophenolate mofetil serving as second-line therapies. Corticosteroids such as prednisone appear not only to inhibit the antibody response but also to increase acetylcholine receptor synthesis and augment the organization of the postsynaptic membrane.⁵

The second purpose of immunosuppression with prednisone, beyond improving function, is to reduce conversion of pure OMG to GMG. Controversies have arisen over a lack of randomized, controlled clinical trials, and varying reports as to the degree of reduced conversion achieved. However, it is well accepted that immunosuppression for patients with OMG reduces

the conversion to GMG.^{5,6,17-19} It seems advantageous to use oral prednisone especially in the first year as well as the second year to reduce the risk of conversion to GMG. However, the benefits must be balanced against the adverse effects of long-term immunosuppression, including the possibility of developing diabetes, osteoporosis or a malignancy. While the features of OMG may only mildly affect quality of life and may be tolerable to patients, the systemic implications are profound, and immunosuppression may be disease altering. As such, once diagnosed or strongly suspected, patients with OMG should be in the hands of a neurologist or neuromuscular specialist specifically skilled in management.

As OMG and GMG can be a paraneoplastic syndrome in concert with thymoma, thymectomy is considered part of the therapeutic armamentarium. Multiple observational studies have shown that thymectomy can potentially hasten stabilization of the disease, reduce the need for corticosteroids and, in some patients, lead to complete remission.²⁰ However, no clinical trials have compared the efficacy of thymectomy to standard immunosuppressant therapy to indicate which therapy is more efficacious. The guidelines for patients without thymoma are even less clear.²

In patients where visually debilitating ptosis following anticholinesterase and immunosuppressive therapy is maintained, surgical correction can be attempted. The frontalis sling with a frontalis orbicularis oculi muscle flap has good cosmetic results, with functional outcomes that improve quality of life.²¹

Clinical Pearls

- Most cases of OMG will progress to GMG within two years, and many within just one year after onset. However, some patients will convert

beyond two years. Patients shouldn't be misled into believing that they will have a good prognosis if they haven't converted to GMG after two years.

- Ocular myasthenia gravis never affects the pupil. If ptosis and ophthalmoplegia are present, and the pupil is affected, MG is not the cause.

- Ocular myasthenia gravis can mimic cranial nerve III, IV and VI palsy as well as internuclear ophthalmoplegia, thyroid eye disease, and isolated recti or oblique muscle paresis.

- As OMG can be seronegative for acetylcholine receptor antibodies and may be false-negative on edrophonium challenge, the diagnosis may hinge on clinical supporting tests such as rest and ice pack.

- The ice pack test works exceptionally well with ptosis as the presenting weakness, but is less effective and diagnostic when ophthalmoparesis is the presenting sign.

- The late, great Lawrence Gray, OD, used to remind us of the rest-fatigability-forced closure-and-ice pack testing for OMG by saying, "Sleep 'em, tease 'em, squeeze 'em and freeze 'em."

1. Peragallo JH, Bitrian E, Kupersmith MJ, et al. Relationship between age, gender, and race in patients presenting with myasthenia gravis with only ocular manifestations. *J Neuroophthalmol*. 2016;36(1):29-32.

2. Melzer N, Ruck T, Fuhr P, et al. Clinical features, pathogenesis, and treatment of myasthenia gravis: a supplement to the guidelines of the german neurological society. *J Neurol*. 2016 Feb 17. [Epub ahead of print].

3. Ortiz S, Borchert M. Long-term outcomes of pediatric ocular myasthenia gravis. *Ophthalmology*. 2008;115(7):1245-8.

4. Juel VC, Massey JM. Myasthenia gravis. *Orphanet J Rare Dis*. 2007;2(1):44.

5. Kupersmith MJ, Latkany R, Homel P. Development of generalized disease at 2 years in patients with ocular myasthenia gravis. *Arch Neurol*. 2003;60(2):243-8.

6. Kusner LL, Puwanant A, Kaminski HJ. Ocular myasthenia: diagnosis, treatment, and pathogenesis. *Neurologist*. 2006;12(5):231-9.

7. Mittal MK, Barohn RJ, Pasnoor M, et al. Ocular myasthenia gravis in an academic neuro-ophthalmology clinic: clinical features and therapeutic response. *J Clin Neuromuscul Dis*. 2011;13(1):46-52.

8. Kupersmith MJ. Ocular myasthenia gravis: treatment successes and failures in patients with long-term follow-up. *J Neurol*. 2009;256(8):1314-20.

9. Szczekliki W, Jankowski M, Wegrzyn W, et al. Acute respiratory failure in patients with Guillain-Barré syndrome and myasthenic crisis treated with plasmapheresis in the intensive care unit. *Pol Arch Med Wewn*. 2008;118(4):239-42.

10. Kumar R. Myasthenia gravis and thymic neoplasms: A brief review. *World J Clin Cases*. 2015;3(12):980-3.

11. Peeler CE, De Lott LB, Nagia L, et al. Clinical utility of acetylcholine receptor antibody testing in ocular myasthenia gravis. *JAMA Neurol*. 2015;72(10):1170-4.

12. Chan KH, Lachance DH, Harper CM, et al. Frequency of seronegativity in adult-acquired generalized myasthenia gravis. *Muscle Nerve*. 2007; 36(5):651-8.

13. Eymard B. Antibodies in myasthenia gravis. *Rev Neurol (Paris)*. 2009;165(2):137-43.

14. Ji H, Yang J, Zhu H, et al. Clinical analysis of thyroid associated ophthalmopathy with myasthenia Graves in 12 patients. *Zhonghua Yan Ke Za Zhi*. 2015;51(8):581-5.

15. Chen CS, Lee AW, Miller NR, et al. Double vision in a patient with thyroid disease: what's the big deal? *Surv Ophthalmol*. 2007;52(4):434-9.

16. Kraithat P, Hansapinyo L, Patikulsila P. Treatment outcomes and predictive factors in pediatric ocular myasthenia gravis. *J Med Assoc Thai*. 2015;98(9):883-8.

17. Wong SH, Plant GT, Cornblath W. Does treatment of ocular myasthenia gravis with early immunosuppressive therapy prevent secondarily generalization and should it be offered to all such patients? *J Neuroophthalmol*. 2016;36(1):98-102.

18. Nagia L, Lemos J, Abusamra K, et al. Prognosis of ocular myasthenia gravis: retrospective multicenter analysis. *Ophthalmology*. 2015;122(7):1517-21.

19. Benatar M, McDermott MP, Sanders DB, et al. Muscle Study Group (MSG). Efficacy of prednisone for the treatment of ocular myasthenia (EPITOME): A randomized, controlled trial. *Muscle Nerve*. 2016;53(3):363-9.

20. de Perrot M, McRae K. Evidence for thymectomy in myasthenia gravis: getting stronger? *J Thorac Cardiovasc Surg*. 2016 Jan 9. pii: S0022-5223(16)00015-5. doi: 10.1016/j.jtcvs.2016.01.006. [Epub ahead of print].

21. Lai CS, Lai YW, Huang SH, et al. Surgical correction of the intractable blepharoptosis in patients with ocular myasthenia gravis. *Ann Plast Surg*. 2016;76 Suppl 1:S55-9.

CRANIAL NERVE III PALSY

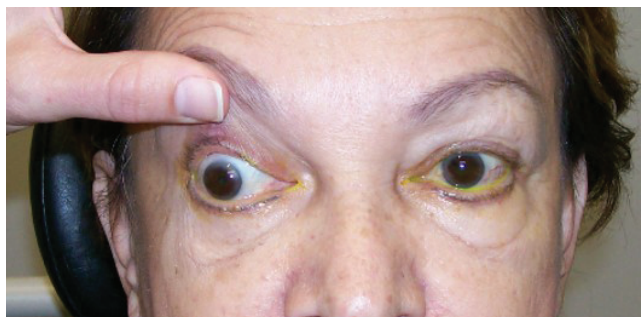Signs and Symptoms

A patient with acute cranial nerve (CN) III palsy will usually present with sudden-onset unilateral ptosis (or rarely, a bilateral ptosis if the damage occurs to the third nerve nucleus) and ophthalmoplegia. Eye or head pain may be present, depending upon the cause.¹⁻⁴ The patient often complains of double vision, though in some cases the diplopia may be masked by the ptosis, which obscures the vision in the affected eye.

If the lid is manually elevated, the diplopia can be elicited. Visual acuity is typically unaffected unless the provoking lesion occurs in the superior orbital fissure, causing simultaneous cranial nerve II involvement.

CN III palsy produces a noncomitant deviation. Limitation of elevation, depression and/or adduction is possible, as well as an underaction of the superior, inferior, medial recti muscles and inferior oblique muscle.¹⁻³ The underaction of these muscles may be complete or incomplete.⁵⁻⁷ This leads to the diagnostic pattern of a CN III palsy, which is a reversing hyper-deviation from up to downgazes, and an exo-deviation, which increases across from the vertically limited eye.

Complete CN III palsy will present with an eye that is down and out; however, partial CN III palsy may not have this posture. Total involvement of the levator palpebrae superioris and all extraocular muscles subserved by CN III is termed a complete CN III palsy. Patients with some degree of involvement (but not total paralysis) of the extraocular and levator muscles are said to have an incomplete CN III palsy or partial CN III palsy.³ In any case of CN III palsy, the pupil may be dilated and minimally reactive to light (pupillary involvement), totally reactive and normal (pupillary non-involvement) or may be sluggishly responsive (partial pupillary involvement).^{3,4,7-10}



Complete pupil sparing cranial nerve III palsy due to ischemic vascular disease.

Various neurological signs may present concomitantly with the development of CN III palsy. Patients may additionally have contralateral intention tremor, ataxia or contralateral hemiplegia, depending upon the cause and brainstem location of damage to CN III.³

Patients developing acute CN III palsy tend to be older; the condition is uncommon in children, though it does occur.⁷ Concurrent diabetes and/or hypertension in older patients is common.^{3,6,7,11} Occasionally, head trauma is to blame for CN III palsy development.¹²

Pathophysiology

The third cranial nerve arises in the dorsal mesencephalon with distinct paired subnuclei that give rise to fibers that pass through the brainstem, subarachnoid space, cavernous sinus and orbit to ultimately innervate the levator palpebrae superioris, superior rectus, inferior rectus, medial rectus and inferior oblique muscles. All subnuclei innervate ipsilateral structures, with the exception of the superior rectus (also innervating the contralateral eye) and the levator palpebrae superioris, which has a single subnucleus innervating both eyelid muscles.^{3,13} In concert with the third cranial nerve nucleus is the Edinger-Westphal nucleus, which controls the pupil sphincter and ciliary body muscles. Pre-synaptic, parasympathetic pupillary fibers course on the outside of CN III.

Third nerve palsy results from damage to the oculomotor nerve anywhere along its route: the nucleus in the dorsal mesencephalon, fascicles in the brainstem parenchyma, the nerve root in the subarachnoid space, the cavernous sinus or the posterior orbit.^{3,13} Damage to the third nerve nucleus is rare and results in an ipsilateral third nerve palsy with contralateral superior rectus underaction and bilateral ptosis. Damage to the third nerve fascicles

emerging from the CN III subnuclear complex and passing through the parenchyma of the mesencephalon can result in an ipsilateral third nerve palsy with contralateral hemiparesis (Weber's syndrome), contralateral intention tremor (Benedikt's syndrome), contralateral ataxia (Claude's syndrome) or ipsilateral cerebellar ataxia (Nothnagel's syndrome). Vascular infarct, metastatic disease and demyelination are the common causes of brainstem involvement.^{7,13}

Once the CN III fascicles emerge from the brainstem, they form the nerve proper and travel a course through the subarachnoid space parallel to the posterior communicating arteries. Damage to the third nerve within the subarachnoid space produces isolated third nerve palsy. The main concern in an isolated CN III palsy occurring within the subarachnoid space is compression of the nerve by an expanding aneurysm of the posterior communicating artery or other adjacent vessel such as the internal carotid, basilar, anterior communicating or temporal arteries, though to a lesser extent than from the posterior communicating artery.^{8,9,14-16} Up to 30% of isolated CN III palsies occurring secondary to damage within the subarachnoid area are due to aneurysms.^{7,11} Vasculopathic infarct, often associated with concurrent diabetes or hypertension, accounts for 35% of cases of isolated CN III palsy.¹¹

Aneurysmal compression is marked by head or retro-orbital pain and anisocoria greater in bright illumination. There may be ipsilateral pupil dilation as the expanding aneurysm compresses the pupillomotor fibers surrounding CN III as well as pain-sensitive dura and other such structures. Additionally, oozing blood will irritate meningeal tissue. In many of these cases, the palsy will be incomplete.

Approximately one-third of patients with CN III palsy from vascular infarct

manifest a small degree of anisocoria of typically less than 1mm. In contradistinction, aneurysmal compression typically causes more than 2mm of anisocoria.¹¹ Additionally, patients developing CN III palsy from aneurysmal compression may initially not present with anisocoria or pupil involvement.^{5,8-10} These patients typically present initially with an incomplete palsy that evolves and develops pupil dilation over several days.^{3,7, 11}

Damage to the third nerve in the cavernous sinus, superior orbital fissure or posterior orbit is less likely to present as an isolated palsy due to the confluence of other structures within these areas. Cavernous sinus involvement will also include possible concurrent pareses of cranial nerve IV, VI, V1 and V2, as well as an ipsilateral Horner's syndrome. The most common causes of damage in these areas include metastatic disease, inflammation, herpes zoster, carotid artery aneurysm, pituitary adenoma, pituitary apoplexy and sphenoid wing meningioma.^{2,3,7}

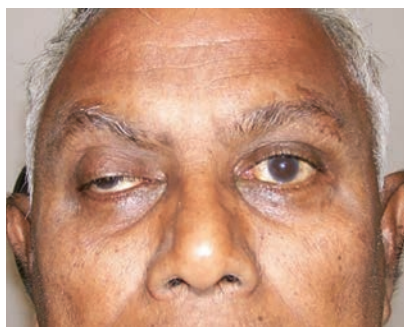Management

Management of third nerve palsy in the adult depends upon the associated findings and etiology. In complicated third nerve palsies where other neural structures are involved with additional symptoms and findings, the patient should undergo magnetic resonance imaging (MRI) of the brain to assist in ascertaining the etiology. The scan should be directed to the anatomical location as dictated by the associated findings described above.³

In cases of isolated, complete third nerve palsies that have no pupillary involvement, where the patient is over 50 years of age, the main cause is predominantly ischemic vascular infarct. Giant cell arteritis is also a potential etiology, mimicking a vasculopathic, pupil-sparing CN III palsy.¹⁷ Indicated testing includes MRI and magnetic

resonance angiography (MRA) or CT angiography (CTA), erythrocyte sedimentation rate, C-reactive protein, blood pressure measurement, complete blood count with differential and blood glucose testing. Close pupil observation is required, as pupil involvement may be delayed by five to seven days. This is especially true for patients with incomplete CN III palsy with pupil sparing as they are more likely to have an incipient aneurysm developing.⁵ In ischemic vascular CN III palsy, the pupil will not evolve, aberrant regeneration will not occur and the palsy will spontaneously improve or resolve over three to six months.^{3,11,18} If the palsy shows no improvement over six to eight weeks or aberrant regeneration develops, repeat neuroimaging and further evaluation is required to rule out the presence of a mass.³

Children under age 14 rarely have aneurysms, and the majority of third nerve palsies in this age group are traumatic or congenital.⁷ If the patient is under 50 and has a non-pupillary-involved, isolated third nerve palsy, neuroimaging or intracranial angiography is indicated since ischemic vasculopathy is less likely to occur in this age group than is aneurysm. If the adult patient of any age presents with complete or incomplete isolated third nerve palsy with pupillary involvement, this should be considered a medical emergency and the patient should undergo immediate neuroimaging and intracranial angiography. In these cases, the cause is likely an aneurysm at the junction of the internal carotid and posterior communicating arteries or another adjacent artery. The patient may die from subarachnoid hemorrhage and brainstem herniation through the foramen magnum if the aneurysm ruptures. Incomplete palsies should be considered to be a developing aneurysm even if the pupil is uninvolved, and management should be urgent in these cases.



Incomplete cranial nerve III palsy resulting from an intracranial aneurysm.

There has been controversy regarding the need for neuroimaging of isolated, pupil-sparing CN III palsy in elderly patients with vascular risk factors presumed to have an ischemic etiology. It has been recommended that such cases do not warrant additional evaluation. Murchison et al. noted in a prospective analysis that the diagnostic yield of neuroimaging isolated cranial neuropathies was extremely low and did not justify the expense, as the clinical management was not altered in a single case of 93 patients discovered to have a non-vascular cause.¹⁹ However, Tamhankar and associates looked at 109 patients age 50 or older with acute isolated ocular motor nerve palsy from a presumed microvascular cause and subjected them all to MRI imaging and serologic studies, and found a cause other than vascular ischemia in nearly 17%.²⁰ The alternate etiologies included midbrain infarction, neoplasms, inflammation, pituitary apoplexy and GCA. However, when excluding patients with GCA and CN III palsy, the likelihood of an alternate non-microvascular cause of isolated CN IV and VI palsy was less than 5% combined, suggesting that extensive workup for these patients may be unnecessary and best reserved for patients with CN III palsy.²⁰

In cases of CN III palsy caused by subarachnoid aneurysm, immediate neurosurgical intervention is necessary. Common treatment involves direct

clipping of the aneurysm or endovascular embolization with detachable coils.^{16,21-28} Both procedures show similar levels of success in preservation of life as well as partial or complete recovery of CN III function. However, some studies suggest that microsurgical clipping of aneurysms is more likely to result in complete nerve function recovery and may be preferable in cases of ruptured aneurysms.^{26,28} Partial CN III palsies are more likely to have a complete return to function following surgical treatment than complete palsies.

Even following successful treatment, a significant number of patients will have limited return of CN III function. In these instances, medial transposition of the lateral rectus muscle provides a good surgical option. A modification of this procedure involves splitting of the lateral rectus into two halves followed by transposing the superior half from below the superior oblique and superior rectus, and inferior half from below the inferior oblique and inferior rectus to attach them at the superior and inferior edge of the medial rectus insertion, respectively. This gives excellent horizontal and vertical alignment in primary gaze—though, of course, limited mobility remains.²⁹⁻³¹ The vertical component makes these procedures difficult, with a significant number of patients needing two or more surgeries.

Clinical Pearls

- Isolated third nerve palsy due to ischemic vasculopathy will spontaneously resolve and recover over a period of three to six months. If the palsy fails to resolve in this timeframe, neuro-ophthalmologic studies or neuro-ophthalmologic consultation must be undertaken once again (this should have occurred at the initial presentation) in order to search for the true etiology.

- Worsening of CN III palsy through the first two weeks suggests ischemic vascular insult is not the cause.

- Painless, complete CN III palsy in an adult over age 50 without pupil involvement is uncommonly caused by an aneurysm.

- Patients manifesting an incomplete, painful CN III palsy must be suspected of having a developing aneurysm.

- Myasthenia gravis has the ability to mimic virtually any cranial neuropathy, including isolated non-pupillary-involved third nerve palsies. Myasthenia gravis must remain a possible diagnosis when encountering a third nerve palsy, especially when the course is variable or atypical.

- Pain will accompany aneurysmal compression. In ischemic vascular CN III palsies, pain is frequent (but may be absent) and is typically less severe, though this is not necessarily diagnostic.

- Consider GCA as a cause of CN III palsy in the elderly.

- Ischemic vascular CN III palsy does not progress to develop aberrant regeneration. Features of aberrant regeneration of CN III include pupillary light-near dissociation, elevation of the upper lid on downgaze, and elevation of the upper eyelid on adduction.

- CN III palsy from suspected aneurysm is one of the few true medical emergencies seen in eye care. These patients must be sent to the hospital immediately for neurosurgical consult.

- Patient anatomy plays a significant diagnostic role. If the artery runs very close to CN III, then a small aneurysm may cause compression and the lesion can be missed on noninvasive imaging. Conversely, if the artery and the nerve are further apart, it may require the aneurysm to be relatively large in order to cause compression.

1. Satyarthee GD, Mahapatra AK. Unusual neuro-ophthalmic presentation of anterior communicating artery aneurysm with third nerve paresis. *J Clin Neurosci*. 2004;11(7):776-8.

2. Bahmani Kashkouli M, Khalatbari MR, Yahyavi ST, et al. Pituitary apoplexy presenting as acute painful isolated unilateral third cranial nerve palsy. *Arch Iran Med*. 2008;11(4):466-8.

3. Yanovitch T, Buckley E. Diagnosis and management of third nerve palsy. *Curr Opin Ophthalmol*. 2007;18(5):373-8.

4. Delengocky T, Bui CM. Complete ophthalmoplegia with pupillary involvement as an initial clinical presentation of herpes zoster ophthalmicus. *J Am Osteopath Assoc*. 2008;108(10):615-21.

5. Takahashi M, Kase M, Suzuki Y, et al. Incomplete oculomotor palsy with pupil sparing caused by compression of the oculomotor nerve by a posterior communicating posterior cerebral aneurysm. *Jpn J Ophthalmol*. 2007;51(6):470-3.

6. Capó H, Warren F, Kupersmith MJ. Evolution of oculomotor nerve palsies. *J Clin Neuroophthalmol*. 1992;12(1):21-5.

7. Richards BW, Jones FR Jr, Young BR. Causes and prognosis in 4,278 cases of paralysis of the oculomotor, trochlear, and abducens cranial nerves. *Am J Ophthalmol*. 1992;113(5):489-96.

8. Kasoff I, Kelly DL Jr. Pupillary sparing in oculomotor palsy from internal carotid aneurysm. Case report. *J Neurosurg*. 1975;42(6):713-7.

9. Kissel JT, Burde RM, Klingele TG, et al. Pupil-sparing oculomotor palsies with internal carotid-posterior communicating artery aneurysms. *Ann Neurol*. 1983;13(2):149-54.

10. Saito R, Sugawara T, Mikawa S, et al. Pupil-sparing oculomotor nerve paresis as an early symptom of unruptured internal carotid-posterior communicating artery aneurysms: three case reports. *Neurol Med Chir (Tokyo)*. 2008;48(7):304-6.

11. Akagi T, Miyamoto K, Kashii S, et al. Cause and prognosis of neurologically isolated third, fourth, or sixth cranial nerve dysfunction in cases of oculomotor palsy. *Jpn J Ophthalmol*. 2008;52(1):32-5.

12. Takeuchi S, Takasato Y, Masaoka H, et al. *Brain Nerve*. 2008;60(5):555-8.

13. Adams ME, Linn J, Yousry I. Pathology of the ocular motor nerves III, IV, and VI. *Neuroimaging Clin N Am*. 2008;18(2):261-82.

14. White JB, Layton KF, Cloft HJ. Isolated third nerve palsy associated with a ruptured anterior communicating artery aneurysm. *Neurocrit Care*. 2007;7(3):260-2.

15. Aiba T, Fukuda M. Unilateral oculomotor nerve paresis associated with anterior communicating artery aneurysm rupture—two case reports. *Neurol Med Chir (Tokyo)*. 2003;43(10):484-7.

16. Asakura K, Tasaki T, Okada K. A case of unruptured anterior temporal artery aneurysm showing pupil-sparing oculomotor palsy. *No Shinkei Geka*. 1986;14(6):777-82.

17. Thurtell MJ, Longmuir RA. Third nerve palsy as the initial manifestation of giant cell arteritis. *J Neuroophthalmol*. 2014;34(3):243-5.

18. Kung NH, Van Stavern GP. Isolated ocular motor nerve palsies. *Semin Neurol*. 2015;35(5):539-48.

19. Murchison AP, Gilbert ME, Savino PJ. Neuroimaging and acute ocular motor mononeuropathies: a prospective study. *Arch Ophthalmol*. 2011;129(3):301-5.

20. Tamhankar MA, Biousse V, Ying GS, et al. Isolated third, fourth, and sixth cranial nerve palsies from presumed microvascular versus other causes: a prospective study. *Ophthalmology*. 2013;120(11):2264-9.

21. Ahn JY, Han IB, Yoon PH, et al. Clipping vs coiling of posterior communicating artery aneurysms with third nerve palsy. *Neurology*. 2006;66(1):121-3.

22. Sheehan MJ, Dunne R, Thornton J, et al. Endovascular repair of posterior communicating artery aneurysms, associated with oculomotor nerve palsy: A review of nerve recovery. *Interv Neuroradiol*. 2015;21(3):312-6.

23. Patel K, Guilfoyle MR, Bulters DO, et al. Recovery of oculomotor nerve palsy secondary to posterior communicating artery aneurysms. *Br J Neurosurg*. 2014;28(4):483-7.

24. Briguì M, Chauvet D, Clarençon F, et al. Recovery from oculomotor nerve palsy due to posterior communicating artery aneurysms: results after clipping versus coiling in a single-center series. *Acta Neurochir (Wien)*. 2014;156(5):879-84.

25. Chalouhi N, Theofanis T, Jabbour P, et al. Endovascular treatment of posterior communicating artery aneurysms with oculomotor nerve palsy: clinical outcomes and predictors of nerve recovery. *AJNR Am J Neuroradiol*. 2013;34(4):828-32.

26. Gaberel T, Borha A, di Palma C, Emery E. Clipping versus coiling in the management of posterior communicating artery aneurysms with third nerve palsy: a systematic review and meta-analysis. *World Neurosurg*. 2015 Sep 25. [Epub ahead of print].

27. Mino M, Yoshida M, Morita T, Tominaga T. Outcomes of oculomotor nerve palsy caused by internal carotid artery aneurysm: comparison between microsurgical clipping and endovascular coiling. *Neurol Med Chir (Tokyo)*. 2015;55(12):885-90.

28. McCracken DJ, Lovasik BP, McCracken CE, et al. Resolution of oculomotor nerve palsy secondary to posterior communicating artery aneurysms: comparison of clipping and coiling. *neurosurgery*. 2015;77(6):931-9.

29. Saxena R, Sharma M, Singh D, et al. Medial transposition of split lateral rectus augmented with fixation sutures in cases of complete third nerve palsy. *Br J Ophthalmol*. 2016 Jan 12. [Epub ahead of print].

30. Gokyigit B, Akar S, Satana B, et al. Medial transposition of a split lateral rectus muscle for complete oculomotor nerve palsy. *J AAPOS*. 2013;17(4):402-10.

31. Shah AS, Prabhu SP, Sadiq MA, et al. Adjustable nasal transposition of split lateral rectus muscle for third nerve palsy. *JAMA Ophthalmol*. 2014;132(8):963-9.

CRANIAL NERVE IV PALSY

Signs and Symptoms

A patient with cranial nerve (CN) IV palsy (also known as superior oblique palsy, trochlear palsy and fourth nerve palsy) will typically present with complaints of vertical or diagonal diplopia, which often becomes worse as the patient tries to read. The patient may experience an inability to look down and in. A component of horizontal diplopia is possible as a lateral phoria becomes manifest due to the vertical dissociation.¹⁻⁴ The chin is often tucked downwards (moved into the field of the dysfunctional muscle) as well. The patient may note greater diplopia or visual discomfort when head tilting toward the side of the palsy. Commonly, the patient develops a compensatory head tilt opposite to the affected superior oblique muscle.

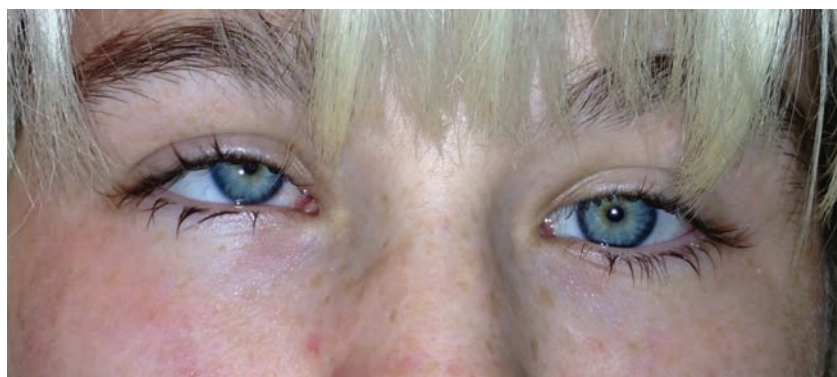Visual acuity is unaffected, and concurrent pain is rare. Ocular motility testing with the alternate cover test will typically reveal a hyperphoric or hyper-tropic deviation that will increase in contralateral gaze, reduce in ipsilateral gaze, increase on ipsilateral head tilt

and decrease on contralateral head tilt. In bilateral cranial nerve IV palsy, the patient will manifest a small hyperdeviation in primary gaze, which increases in lateral gazes, with the hyper eye being opposite of the direction of gaze. A right hyper in left gaze, reversing to a left hyper in right gaze, will likely also be present. The hyperdeviation increases on ipsilateral head tilt, manifesting as a right hyper on right head tilt and a left hyper on left head tilt.⁵⁻⁸

A large percentage of CN IV palsies are congenital, but may not become symptomatic until later in life. With acute onset in older adults may be concurrent hypertension and/or diabetes. However, vasculopathic CN IV palsies are less frequent than vasculopathic CN VI or CN III palsies.⁹⁻¹¹ Isolated, acquired cases often include a history of head trauma immediately preceding development of the CN IV palsy. The trauma need not be major, as relatively minor injuries can precipitate CN IV palsy.^{2,3,12-14} In cases of longstanding decompensated CN IV palsy, the inciting trauma may have been many years antecedent.

Pathophysiology

The fourth cranial nerve nucleus is located in the dorsal mesencephalon. Nerve fibers decussate and exit the brain stem dorsally into the subarachnoid space. It is at this decussation in the anterior medullary velum that a bilateral CN IV palsy can occur. The nerve then courses forward to enter the cavernous sinus, superior orbital fissure and orbit to innervate the superior oblique muscle. Damage to the fourth nerve nucleus or its fascicles within the midbrain prior to the decussation produces contralateral fourth nerve palsy. Depending on the cause of the CN IV palsy in the midbrain, as well as the surrounding anatomic structures involved, evidence of a contralateral Horner syndrome may be present. If



Right hyper deviation caused by traumatic cranial nerve IV palsy.

the damage also includes a more superior region of the midbrain, features of dorsal midbrain syndrome may be observed, including light-near dissociated pupils, convergence retraction nystagmus and up-gaze palsy. The main causes of damage to the fourth nerve in this area are hemorrhage, infarction, trauma, tumor, hydrocephalus and demyelination.^{9,14}

The fourth nerve is especially prone to trauma as it exits the brain stem and courses through the subarachnoid space. In contrast to third nerve palsies with an etiology in subarachnoid space, fourth nerve palsies are rarely due to aneurysmal compression. The most common causes of damage to the fourth nerve in this region are trauma and ischemic vasculopathy.³

Due to the large number of other neural structures that accompany the fourth nerve as it travels through the cavernous sinus and superior orbital fissure, it is unlikely that patients will exhibit isolated fourth nerve palsy when damage occurs there. Common causes of damage to the fourth nerve in these areas are herpes zoster, inflammation of the cavernous sinus or posterior orbit, as well as meningioma, metastatic disease, pituitary adenoma and carotid cavernous fistula.¹⁵ CN IV palsy with ipsilateral Horner syndrome localizes to the cavernous sinus. Trauma to the head or orbit can cause damage to the

trochlear tendon with resultant superior oblique muscle dysfunction.

Trauma and vascular disease are considered the main causes of acquired CN IV palsy.^{14,15} However, numerous reports of other potential, but less common, causes of isolated CN IV palsy exist, including multiple sclerosis, polycythemia vera, cat-scratch disease and, infrequently, metastatic disease.¹⁵⁻²¹

Management

If the CN IV palsy is not congenital and not associated with recent trauma, a history of past trauma should be investigated. Sometimes, fourth nerve palsy presents suddenly as an acquired case, but may actually result from decompensation of a longstanding or congenital palsy. A patient with a decompensated, longstanding palsy will often present with a compensatory head tilt away from the palsied eye. Investigating old photographs can confirm the presence of a habitual head posture. Further, patients with decompensated, longstanding fourth nerve palsies will have an exaggerated vertical fusional ability.

Longstanding fourth nerve palsies typically have a benign course and require no additional work-up or further management. In cases that are unclear, neuroimaging may assist diagnosis. Magnetic resonance imaging can demonstrate superior oblique atrophy

and an absent trochlear nerve, aiding in diagnosis of congenital palsy presenting with sudden vertical diplopia occurring later in life due to delayed decompensation.^{22,23}

In the case of complicated fourth nerve palsies, i.e., those that present with other concurrent neurological dysfunction, the patient should undergo neuroradiological studies dictated by the accompanying signs and symptoms. If the patient is elderly and has a fourth nerve palsy of recent origin, an ischemic vascular evaluation should be undertaken to search for diabetes and hypertension. CN IV palsies caused by vascular infarct usually spontaneously resolves over a period of up to 10 months with no further management beyond periodic observation and either occlusion or press-on prism required.^{2,3,24} In elderly patients, giant cell arteritis should also be considered, and appropriate history and testing should be ordered.

In the case of isolated fourth nerve palsies caused by recent trauma, the patient should undergo neuroradiological studies of the head to dismiss the possibility of a concurrent subarachnoid hemorrhage. During the post-traumatic diplopic phase, temporary prisms or occlusion may resolve symptoms. A single injection of botulinum toxin A into the ipsilateral inferior oblique muscle can rapidly and safely resolve symptomatic diplopia while waiting for spontaneous recovery.^{25,26}

In cases of decompensated or otherwise unresolving fourth nerve palsy, conservative management with prism is very effective and should likely be pursued first. Even large vertical deviations can benefit from prismatic correction with relief or resolution of diplopia and compensatory head tilt.^{27,28} In cases where prism or other conservative methods fail, strabismus surgery is a viable option, after waiting with no indication of spontaneous resolution. Superior oblique tuck combined with

inferior oblique recession or combined resection and anterior transposition of the inferior oblique muscle have been seen as effective methods of eliminating diplopia and head tilt secondary to chronic CN IV palsies.^{29,30}

Clinical Pearls

- Cases of true vertical diplopia are most commonly caused by CN IV palsy.
- If the presenting motility of a patient is a hyperdeviation in one eye that increases on opposite gaze and ipsilateral head tilt, the cause is nearly always going to be CN IV palsy.
- Although the Parks-Bielschowsky three-step test is the cornerstone of cyclovertical strabismus diagnosis, it is not completely sensitive to diagnosing CN IV palsy. The complete three-step test fails to detect 30% of cases of CN IV palsy. Often, only two of three steps are positive in CN IV palsy. Thus, you do not need a complete three-step test to make the diagnosis.^{31,32}
- Myasthenia gravis and thyroid eye disease can mimic CN IV palsy and must always be considered.
- Bilateral CN IV palsy localizes damage to the anterior medullary velum, where both CN IV decussate at the level of the isthmus pons. Although the CN IV nucleus is in the midbrain, CN IV cross a bit lower.
- In children, nearly all cases of isolated fourth nerve palsy are either congenital or traumatic in nature. In adults, nearly all isolated, acquired fourth nerve palsies can be ascribed to trauma or vascular disease. Rarely is tumor or aneurysm a cause. The majority of fourth nerve palsies follow a benign course.
- When encountering isolated fourth nerve palsy, the clinician should delay prescribing permanent prisms for at least three months and surgery for 12 months in order to allow for the palsy to recover. Otherwise, glasses with per-

manent prism correction or premature surgery can induce vertical diplopia, should the palsy recover.

1. Staubach F, Lagrèze WA. Oculomotor, trochlear, and abducens nerve palsies. *Ophthalmologie*. 2007;104(8):733-46.
2. Akagi T, Miyamoto K, Kashii S, et al. Cause and prognosis of neurologically isolated third, fourth, or sixth cranial nerve dysfunction in cases of oculomotor palsy. *Jpn J Ophthalmol*. 2008;52(1):32-5.
3. Hoya K, Kirino T. Traumatic trochlear nerve palsy following minor occipital impact—four case reports. *Neurol Med Chir (Tokyo)*. 2000;40(7):358-60.
4. von Noorden GK, Murray E, Wong SY. Superior oblique paralysis. A review of 270 cases. *Arch Ophthalmol*. 1986;104(12):1771-6.
5. Baumeister E. Contribution to the diagnosis of trochlear paresis (first description of Bielschowsky head-tilt test). 1874. *Strabismus*. 2003;11(2):129-30.
6. Simonsz HJ, Crone RA, van der Meer J, et al. Bielschowsky head-tilt test—II. Ocular counterrolling and Bielschowsky head-tilt test in 23 cases of superior oblique palsy. *Vision Res*. 1985;25(12):1977-82.
7. Gräf M, Krzizok T, Kaufmann H. Head-tilt test in unilateral and symmetric bilateral acquired trochlear nerve palsy. *Klin Monatsbl Augenheilkd*. 2005;222(2):142-9.
8. Straumann D, Bockisch CJ, Weber KP. Dynamic aspects of trochlear nerve palsy. *Prog Brain Res*. 2008;171:53-8.
9. Park UC, Kim SJ, Hwang JM, et al. Clinical features and natural history of acquired third, fourth, and sixth cranial nerve palsy. *Eye*. 2008;22(5):691-6.
10. Trigler L, Siatkowski RM, Oster AS, et al. Retinopathy in patients with diabetic ophthalmoplegia. *Ophthalmology*. 2003;110(8):1545-50.
11. Acaroglu G, Akinci A, Zilelioglu O. Retinopathy in patients with diabetic ophthalmoplegia. *Ophthalmologica*. 2008;222(4):225-8.
12. Dhalilwal A, West AL, Trobe JD, et al. Third, fourth, and sixth cranial nerve palsies following closed head injury. *J Neuroophthalmol*. 2006;26(1):4-10.
13. Ishizaki E, Kurokawa Y. A case of solitary and unilateral trochlear nerve palsy due to a blunt head impact. *Rinsho Shinkeigaku*. 2003;43(9):571-3.
14. de Camargo GB, Hida WT, Goldchmit M, et al. [Paralytic strabismus: review of 24 years at "Santa Casa de São Paulo"]. *Arq Bras Oftalmol*. 2007;70(4):585-7.
15. Richards BW, Jones FR Jr, Younger BR. Causes and prognosis in 4,278 cases of paralysis of the oculomotor, trochlear, and abducens cranial nerves. *Am J Ophthalmol*. 1992;113(5):489-96.
16. Tsuda H, Ito T, Yoshioka M, et al. Isolated trochlear nerve palsy in herpes zoster ophthalmicus. *Intern Med*. 2007;46(8):535-6.
17. Mielke C, Alexander MS, Anand N, et al. Isolated bilateral trochlear nerve palsy as the first clinical sign of a metastatic [correction of metastatic] bronchial carcinoma. *Am J Ophthalmol*. 2001;132(4):593-4.
18. Lavin PJ, Donahue SP, Jacobson DM, et al. Isolated trochlear nerve palsy in patients with multiple sclerosis. *Neurology*. 2000;55(2):321-2.
19. Jacobson DM, Moster ML, Eggenberger ER, et al. Isolated trochlear nerve palsy in patients with multiple sclerosis. *Neurology*. 1999;53(4):877-9.
20. Jones MM, Clement CI, Rowe DB. Isolated trochlear nerve palsy as a presenting feature of primary polycythemia rubra vera. *Clin Experiment Ophthalmol*. 2004;32(3):339-40.
21. Müller D, Neubauer BA, Waltz S, et al. Neuroborreliosis and isolated trochlear palsy. *Eur J Paediatr Neurol*. 1998;2(5):275-6.

22. Lee S, Kim SH, Yang HK, et al. Imaging demonstration of trochlear nerve agenesis in superior oblique palsy emerging during the later life. *Clin Neurol Neurosurg*. 2015;139:269-71.

23. Yang HK, Kim JH, Hwang JM. Congenital superior oblique palsy and trochlear nerve absence: a clinical and radiological study. *Ophthalmology*. 2012;119(1):170-7.

24. Khaier A, Dawson E, Lee J. Clinical course and characteristics of acute presentation of fourth nerve paresis. *J Pediatr Ophthalmol Strabismus*. 2012;49(6):366-9.

25. Bagheri A, Eshaghi M. Botulinum toxin injection of the inferior oblique muscle for the treatment of superior oblique muscle palsy. *J AAPOS*. 2006;10(5):385-8.

26. Talebnejad MR, Tahamtan M, Nowroozzadeh MH. Botulinum toxin injection for treatment of acute traumatic superior oblique muscle palsy. *J Ophthalmic Vis Res*. 2015;10(3):263-7.

27. Tokarz-Sawirska E, Lachowicz E. Conservative management of posttraumatic diplopia. *Klin Oczna*. 2015;117(1):14-9.

28. Tamhankar MA, Ying GS, Volpe NJ. Success of prisms in the management of diplopia due to fourth nerve palsy. *J Neuroophthalmol*. 2011;31(3):206-9.

29. Farvardin M, Bagheri M, Pakdel S. Combined resection and anterior transposition of the inferior oblique muscle for treatment of large primary position hypertropia caused by unilateral superior oblique muscle palsy. *J AAPOS*. 2013;17(4):378-80.

30. Engel JM. Treatment and diagnosis of congenital fourth nerve palsies: an update. *Curr Opin Ophthalmol*. 2015;26(5):353-6.

31. Manchandia AM, Demer JL. Sensitivity of the three-step test in diagnosis of superior oblique palsy. *J AAPOS*. 2014;18(6):567-71.

32. Kono R, Okanobu H, Ohtsuki H, et al. Absence of relationship between oblique muscle size and bielschowsky head tilt phenomenon in clinically diagnosed superior oblique palsy. *Invest Ophthalmol Vis Sci*. 2009;50(1):175-9.

CRANIAL NERVE VI PALSY

Signs and Symptoms

A patient with cranial nerve (CN) VI palsy will present with horizontal, uncrossed diplopia that worsens at distance in the direction ipsilateral to the involved eye. The patient will have an abduction deficit in the involved eye and a noncomitant esodeviation.^{1,2} Isolated CN VI palsy is not associated with visual acuity loss, visual field loss or other neurologic findings. Some degree of head or retro-orbital pain may be present, dependent upon the cause. The palsy may be acute, chronic or evolving over time.

Three distinct demographic groups are known to develop CN VI palsy. Most patients developing acute CN VI palsy are older (i.e., over age 50). This group often has a concurrent history of hypertension and/or diabetes,

with peak incidence occurring in the seventh decade.³⁻⁶ Children are also prone to develop CN VI palsy. The cause may range from benign conditions, such as viral illness or trauma, to malignancy.⁷⁻¹¹ The third group consists of young adults ages 20 to 50. This group is more likely to have neurologically complicated CN VI palsies involving other cranial nerves.^{12,13} In contrast to older adults, vascular disease such as diabetes and hypertension is uncommon in this age group with more serious conditions such as central nervous system (CNS) mass lesions and multiple sclerosis typically being found instead.¹³⁻¹⁵

As various cancers have been associated with CN VI palsy, patients may present with a pre-existing history of malignant disease. However, CN VI palsy also might be the premonitory sign of cancer in some individuals. Carcinoma in particular has been associated with the development of CN VI palsy, either through direct invasion from the nasopharynx or metastasis to anatomic regions along the course of CN VI from the prostate or other sites.¹⁶⁻²¹ Other less common associations with CN VI palsy include herpes zoster, temporal arteritis, Lyme disease, sarcoidosis, pituitary tumor, aneurysm, cavernous sinus fistula and syndrome, inflammation, raised intracranial pressure from trauma or pseudotumor, and ophthalmoplegic migraine.²²⁻²⁸ There have been reports of CN VI palsy developing after intravitreal injections of anti-VEGF ranibizumab and bevacizumab, though the mechanism of nerve paralysis is unknown.^{29,30}

Pathophysiology

CN VI arises in the pons in close association with the facial nerve (CN VII), paramedian pontine reticular formation (PPRF), medial longitudinal fasciculus (MLF) and descending corticospinal fibers. Due to this arrangement,

damage to the sixth nerve within the brain stem often produces a sixth nerve palsy along with a facial nerve palsy. Damage to the CN VI nucleus or the PPRF results in an ipsilateral gaze palsy. Simultaneous involvement of the MLF causes a superimposed internuclear ophthalmoplegia.

A non-nuclear pontine CN VI palsy may also be associated with contralateral hemiparesis, with or without a CN VII palsy (Raymond's syndrome vs. Millard-Gubler syndrome). These additional findings identify the location of damage to be the pons, where ischemic infarct, tumors and demyelination are common causes.^{3,4}

CN VI travels through the subarachnoid space, ascends the clivus and enters the cavernous sinus. In this subarachnoid space, CN VI can be damaged by metastatic lesions to the bony clivus. In addition, the sixth nerve may be compressed by the petroclivoid ligament in Dorello's canal due to increased intracranial pressure from any cause. This can induce a unilateral or bilateral sixth nerve palsy (which is often intermittent) and papilledema.¹³ As the sixth nerve passes over the petrous apex of the temporal bone, damage here can result in a sixth nerve palsy, facial pain and hearing loss. This occurs as a result of the spread of infection from the middle ear or mastoids (Gradenigo's syndrome).^{16,21}

Within the cavernous sinus, the sixth nerve is joined by the oculosympathetic nerves, as well as CN III, IV, V1 and V2. Damage here can yield a sixth nerve palsy and Horner's syndrome, loss of sensation in the forehead and cheek region, as well as possibly concurrent CN III and IV palsy.^{19,20,31} The etiology may be aneurysm, meningioma, pituitary adenoma, inflammation or cavernous sinus fistula.³²⁻³⁵ CN VI palsy combined with ipsilateral Horner's syndrome is highly localizing to the cavernous sinus; this is known

as Parkinson's syndrome.^{36,37} The sixth nerve is also vulnerable to ischemic infarct from diabetes and hypertension. This remains a prime cause of isolated sixth nerve palsy in older patients.

While CN VI can be affected in many areas through its course from the pons to the orbit, a significant number of cases will have no conclusive etiology, despite extensive medical evaluation.^{2-4,6,13} As many as one-third of CN VI palsies will remain idiopathic.⁶

Management

The first step in managing patients involves determining if the cause of the abduction deficit is, in fact, truly a CN VI palsy. Other causes of abduction deficit include myasthenia gravis and thyroid orbitopathy. The most important consideration in managing patients with true acute onset CN VI palsy involves identifying the causative factor in an efficient, cost-effective manner. Doing so involves understanding common causes for each patient profile and palsy. In one large, population-based study, the four most common causes of CN VI palsy were: (1) idiopathic, (2) hypertension alone, (3) coexistent diabetes and hypertension, and (4) trauma.⁶

Details regarding presentation and medical history must be obtained, as well as a neurologic examination upon discovery. Each case of CN VI palsy should be classified as traumatic or non-traumatic, with non-traumatic cases subdivided as neurologically isolated or non-neurologically isolated.⁶ Additionally, patients should be ascribed to one of three groups: children, young adults or older adults.⁶

A non-neurologically isolated sixth nerve palsy involving any of the above-mentioned neurological signs indicates a prompt need for MRI of the suspect area. Non-neurologically isolated CN VI palsies are commonly caused by cerebrovascular accidents involving the

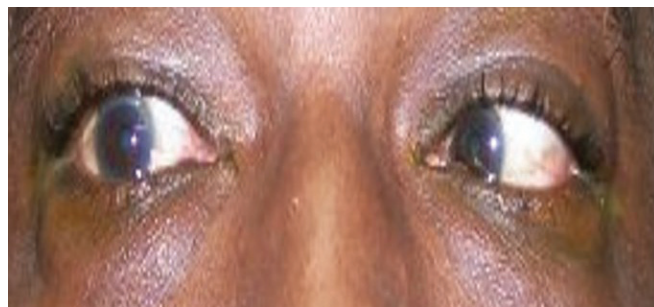pons, aneurysm (typically within the cavernous sinus) or neoplasm.⁶ While neurologically complicated CN VI palsy is likely caused by a serious condition, such as

neoplasm, isolated CN VI palsy actually has a very low risk (2% in one series) of being caused by a neoplasm.⁶

In children, CN VI palsy can occur from a presumed viral cause or idiopathic intracranial hypertension. These cases have an excellent prognosis.^{9,10} However, nearly half of all CN VI palsies in children are due to neoplastic disease, notably pontine glioma.^{8,11,38,39} Thus, pediatric neurologic consultation and evaluation is urgent in this group, and the cause of the palsy shouldn't be presumed to be benign.¹¹

In younger adults, CN VI palsy is likely to be caused by serious underlying disease. In this group, central nervous system (CNS) mass lesions and multiple sclerosis account for 33% and 24% of CN VI palsies, respectively.¹³ Idiopathic CN VI palsies account for 13% of cases, and vascular disease only 4%.¹³ It should be noted that CN VI palsy caused by CNS mass lesions in young adults typically produces other cranial neuropathies (non-isolated). Neuroimaging is mandatory in this group.

In adults over the age of 50 with an isolated sixth nerve palsy, a workup for ischemic vascular diseases such as diabetes and hypertension should be undertaken, as this is a common cause.^{2-6,40} If the patient is over the age of 60 years, then an erythrocyte sedimentation rate (ESR) and C-reactive protein should be ordered to rule out giant cell arteritis.⁴⁰ In cases of isolated CN VI palsy in older adults with a his-



A patient presents with right cranial nerve VI palsy.

tory of diabetes or hypertension, neuroimaging and other extensive evaluation can be initially deferred, unless the palsy progresses, fails to improve after three months or other neurologic complications develop.

Ischemic vascular palsies typically progress over several days and may be no better at one week's time, but progressive worsening over two weeks warrants neuroimaging, as this is not a feature of a vasculopathic cause.⁶ Thus, cases of potentially sinister origin can usually be suspected within two weeks of observation and then acted upon. A recent report has shown that in isolated CN VI palsy in patients with no vasculopathic risk factors or positive laboratory or clinical findings, neuroimaging can serve as a useful diagnostic tool to identify the exact cause, with a yield of nearly 50%.⁴¹

Spontaneous recovery of CN VI palsy is common, especially if the etiology is either idiopathic, traumatic or microvascular.^{3,4,6,13,42} Resolution of CN VI palsy is typically complete within three to six months, although some cases may take longer. CN VI palsies associated with CNS mass lesions tend to have a worse prognosis for spontaneous recovery.^{6,13} In cases where complete recovery does not occur, alternate patching or Fresnel prism correction may alleviate diplopia and visual discomfort. More aggressive therapy in non-remitting cases includes medial rectus injection with botulinum

toxin.⁴³⁻⁴⁶ Finally, there are several rectus muscle transposition surgeries that can alleviate diplopia and reduce esotropia in primary position with improvement in abduction.⁴⁷⁻⁴⁹

Clinical Pearls

- The etiology of isolated CN VI palsy in the adult is undetermined in a significant number of cases, despite full diagnostic evaluation.

- While vasculogenic CN VI palsies can be expected to progress over several days, they will not worsen over a period of two or more weeks. Such a clinical course suggests alternate etiologies.

- Myasthenia gravis may mimic a sixth nerve palsy and should always be considered in the differential diagnosis, especially if the palsy takes on a variable course with exacerbations and remissions.

- A patient with horizontal diplopia and lateral rectus underaction can only be said to have an abduction deficit. Forced duction testing must be done. A positive forced duction test indicates a restrictive ophthalmopathy while a negative result indicates a CN VI palsy or ocular myasthenia.

- The risk of acute isolated CN VI palsy in an older adult being caused by a neoplasm is low.

- Acute CN VI palsies in children are often harbingers of serious disease, such as cancer, and must be promptly investigated.

- Non-neurologically isolated CN VI palsies are often associated with CNS mass lesions and should be promptly evaluated.

- Acute CN VI palsy in a young adult is not commonly caused by microvascular infarct, but rather by more serious disease such as multiple sclerosis and CNS mass lesions and should be promptly investigated.

2. Staubach F, Lagrèze WA. Oculomotor, trochlear, and abducens nerve palsies. *Ophthalmologie*. 2007;104(8):733-46.

3. Richards BW, Jones FR Jr, Younge BR. Causes and prognosis in 4,278 cases of paralysis of the oculomotor, trochlear, and abducens cranial nerves. *Am J Ophthalmol*. 1992;113(5):489-96.

4. Rush JA, Younge BR. Paralysis of cranial nerves III, IV, and VI. Cause and prognosis in 1,000 cases. *Arch Ophthalmol*. 1981;99(1):76-9.

5. Acaroglu G, Akinci A, Zilelioglu O. Retinopathy in patients with diabetic ophthalmoplegia. *Ophthalmologica*. 2008;222(4):225-8.

6. Patel SV, Mutyalu S, Leske DA, et al. Incidence, associations, and evaluation of sixth nerve palsy using a population-based method. *Ophthalmology*. 2004;111(2):369-75.

7. Janssen K, Wojciechowski M, Poot S, et al. Isolated abducens nerve palsy after closed head trauma: a pediatric case report. *Pediatr Emerg Care*. 2008;24(9):621-3.

8. Broniscer A, Laningham FH, Sanders RP, et al. Young age may predict a better outcome for children with diffuse pontine glioma. *Cancer*. 2008;111(3):566-72.

9. Cohen HA, Nussinovitch M, Ashkenazi A, et al. Benign abducens nerve palsy of childhood. *Pediatr Neurol*. 1993;9(5):394-5.

10. Vallée L, Guilbert F, Lemaître JF, et al. Benign paralysis of the 6th cranial nerve in children. *Ann Pediatr (Paris)*. 1990;37(5):303-5.

11. Lee MS, Galetta SL, Volpe NJ, et al. Sixth nerve palsies in children. *Pediatr Neurol*. 1999;20(1):49-52.

12. Brinar VV, Habek M, Ozretić D, et al. Isolated non-traumatic abducens nerve palsy. *Acta Neurol Belg*. 2007;107(4):126-30.

13. Peters GB 3rd, Bakri SJ, Krohel GB. Cause and prognosis of nontraumatic sixth nerve palsies in young adults. *Ophthalmology*. 2002;109(10):1925-8.

14. Barr D, Kupersmith MJ, Turbin R, et al. Isolated sixth nerve palsy: an uncommon presenting sign of multiple sclerosis. *J Neurol*. 2000;247(9):701-4.

15. Mitchell JP, Beer J, Yancy A, et al. Lateral rectus muscle palsy, facial numbness and ataxia as the initial manifestation of multiple sclerosis. *J Natl Med Assoc*. 2008;100(5):572-4.

16. Marchese-Ragona R, Maria Ferraro S, Marioni G, et al. Abducent nerve paralysis: first clinical sign of clivus metastasis from tonsillar carcinoma. *Acta Otolaryngol*. 2008;128(6):713-6.

17. Malloy KA. Prostate cancer metastasis to clivus causing cranial nerve VI palsy. *Optometry*. 2007;78(2):55-62.

18. O'Boyle JE, Gardner TA, Oliva A, et al. Sixth nerve palsy as the initial presenting sign of metastatic prostate cancer. A case report and review of the literature. *J Clin Neuroophthalmol*. 1992;12(3):149-53.

19. Hirao M, Oku H, Sugawara J, et al. Three cases of abducens nerve palsy accompanied by Horner syndrome. *Nippon Ganka Gakkai Zasshi*. 2006;110(7):520-4.

20. Tsuda H, Ishikawa H, Asayama K, et al. Abducens nerve palsy and Horner syndrome due to metastatic tumor in the cavernous sinus. *Intern Med*. 2005;44(6):644-6.

21. İlhan O, Sener EC, Ozyar E. Outcome of abducens nerve paralysis in patients with nasopharyngeal carcinoma. *Eur J Ophthalmol*. 2002;12(1):55-9.

22. Arai M, Katsumata R. Temporal arteritis presenting with headache and abducens nerve palsy. Report of a case. *Rinsho Shinkeigaku*. 2007;47(7):444-6.

23. Berit P. Isolated and combined pareses of cranial nerves III, IV and VI. A retrospective study of 412 patients. *J Neurol Sci*. 1991;103(1):10-5.

24. Kim SH, Lee KC, Kim SH. Cranial nerve palsies accompanying pituitary tumour. *J Clin Neurosci*. 2007;14(12):1158-62.

25. Nagasawa H, Iseki C, Wada M, et al. Abducens nerve palsy as the first manifestation of cavernous sinus sarcoïdosis. *Rinsho Shinkeigaku*. 2005;45(1):38-40.

26. Iwao K, Kobayashi H, Okinami S. Case of herpes zoster ophthalmicus with abducent palsy: the cause and magnetic resonance imaging findings. *Nippon Ganka Gakkai Zasshi*. 2006;110(3):193-8.

27. Kindstrand E. Lyme borreliosis and cranial neuropathy. *J Neurol*. 1995;242(10):658-63.

28. Vasconcelos LP, Stancio FG, Leal JC, et al. Ophthalmoplegic migraine: a case with recurrent palsy of the abducens nerve. *Headache*. 2008;48(6):961-4.

29. Caglar C, Kocamis SI, Durmus M. Isolated sixth nerve palsy after intravitreal ranibizumab injection. *Cutan Ocul Toxicol*. 2015;4:1-3.

30. Cakmak HB, Toklu Y, Yorgun MA, Simsek S. Isolated sixth nerve palsy after intravitreal bevacizumab injection. *Strabismus*. 2010;18(1):18-20.

31. Tsuda H, Ishikawa H, Kishiro M, et al. Abducens nerve palsy and postganglionic Horner syndrome with or without severe headache. *Intern Med*. 2006;45(14):851-5.

32. Kupersmith MJ, Stiebel-Kalish H, Huna-Baron R, et al. Cavernous carotid aneurysms rarely cause subarachnoid hemorrhage or major neurologic morbidity. *J Stroke Cerebrovasc Dis*. 2002;11(1):9-14.

33. Wu HC, Ro LS, Chen CJ, et al. Isolated ocular motor nerve palsy in dural carotid-cavernous sinus fistula. *Eur J Neurol*. 2006;13(11):1221-5.

34. Lee KY, Kim SM, Kim DI. Isolated bilateral abducens nerve palsy due to carotid cavernous dural arteriovenous fistula. *Yonsei Med J*. 1998;39(3):283-6.

35. Ogawa G, Tanabe H, Kanzaki M, et al. Two cases of idiopathic carotid-cavernous fistula with headache and ophthalmoplegia. *Rinsho Shinkeigaku*. 2007;47(8):516-8.

36. Kal A, Ercan ZE, Duman E, Arpaci E. Abducens nerve palsy and ipsilateral horner syndrome in a patient with carotid-cavernous fistula. *J Craniofac Surg*. 2015;26(7):e653-5.

37. Ebner RN, Ayerza DR, Aghetoni F. Sixth nerve palsy + ipsilateral horner's syndrome = parkinson's syndrome. *Saudi J Ophthalmol*. 2015;29(1):63-6.

38. Merino P, Gómez de Liaño P, Villalobo JM, et al. Etiology and treatment of pediatric sixth nerve palsy. *J AAPOS*. 2010;14(6):502-5.

39. Teksam O, Keser AG, Konuskan B, et al. Acute abducent nerve paralysis in the pediatric emergency department: analysis of 14 patients. *Pediatr Emerg Care*. 2015 Mar 24. [Epub ahead of print]

40. Kung NH, Van Stavem GP. Isolated ocular motor nerve palsies. *Semin Neurol*. 2015;35(5):539-48.

41. Nair AG, Ambika S, Noronha VO, Gandhi RA. The diagnostic yield of neuroimaging in sixth nerve palsy--sankara nethralaya abducens palsy study (SNAPS): Report 1. *Indian J Ophthalmol*. 2014;62(10):1008-12.

42. Holmes JM, Droste PJ, Beck RW. The natural history of acute traumatic sixth nerve palsy or paresis. *J AAPOS*. 1998;2(5):265-8.

43. Kao LY, Chao AN. Subtenon injection of botulinum toxin for treatment of traumatic sixth nerve palsy. *J Pediatr Ophthalmol Strabismus*. 2003;40(1):27-30.

44. Holmes JM, Leske DA, Christiansen SP. Initial treatment outcomes in chronic sixth nerve palsy. *J AAPOS*. 2001;5(6):370-6.

45. Gómez De Liaño Sánchez P, Villarejo Díaz-Maroto I, Gómez De Liaño Sánchez R, et al. Treatment of sixth nerve palsy of traumatic or tumor etiology using botulinum toxin. *Arch Soc Esp Oftalmol*. 2000;75(7):471-6.

46. Bagheri A, Babsharif B, Abrishami M, et al. Outcomes of surgical and non-surgical treatment for sixth nerve palsy. *J Ophthalmic Vis Res*. 2010;5(1):32-7.

47. Muraki S, Nishida Y, Ohji M. Surgical results of a muscle transposition procedure for abducens palsy without tenotomy and muscle splitting. *Am J Ophthalmol*. 2013;156(4):819-24.

48. Gunton KB. Vertical rectus transpositions in sixth nerve palsies. *Curr Opin Ophthalmol*. 2015;26(5):366-70.

49. del Pilar González M, Kraft SP. Outcomes of three different vertical rectus muscle transposition procedures for complete abducens nerve palsy. *J AAPOS*. 2015;19(2):150-6.

1. Goodwin D. Differential diagnosis and management of acquired sixth cranial nerve palsy. *Optometry*. 2006;77(11):534-9.

Up to
18 CE
Credits*

REVIEW OF OPTOMETRY®
EDUCATIONAL MEETINGS OF CLINICAL EXCELLENCE



SAVE THE DATE!
June 8-11, 2017

DISNEY'S YACHT AND BEACH CLUB

The Yacht Club is one of the most conveniently located resorts on Disney's property! It's within walking distance of Epcot, Disney's Boardwalk, the Swan, and the Dolphin hotels. It is also just a short boat ride away from the Disney's Hollywood Studios. There is a very good reason why Disney's Yacht Club remains one of the most popular resorts in Orlando.

Other 2017 NT&T Meetings!

- San Diego
- Philadelphia
- Nashville

log on to...

www.reviewofoptometry.com/events
to stay informed!



*Approval pending



Photos Courtesy of Disney Group Marketing

BRIEF SUMMARY OF PRESCRIBING INFORMATION

This Brief Summary does not include all the information needed to prescribe Lotemax Gel safely and effectively. See full prescribing information for Lotemax Gel.

Lotemax (loteprednol etabonate ophthalmic gel) 0.5%

Rx only

Initial Rx Approval: 1998

INDICATIONS AND USAGE

LOTEMAX is a corticosteroid indicated for the treatment of post-operative inflammation and pain following ocular surgery.

DOSAGE AND ADMINISTRATION

Invert closed bottle and shake once to fill tip before instilling drops.

Apply one to two drops of LOTEMAX into the conjunctival sac of the affected eye four times daily beginning the day after surgery and continuing throughout the first 2 weeks of the post-operative period.

CONTRAINDICATIONS

LOTEMAX, as with other ophthalmic corticosteroids, is contraindicated in most viral diseases of the cornea and conjunctiva including epithelial herpes simplex keratitis (dendritic keratitis), vaccinia, and varicella, and also in mycobacterial infection of the eye and fungal diseases of ocular structures.

WARNINGS AND PRECAUTIONS

Intraocular Pressure (IOP) Increase

Prolonged use of corticosteroids may result in glaucoma with damage to the optic nerve, defects in visual acuity and fields of vision. Steroids should be used with caution in the presence of glaucoma. If this product is used for 10 days or longer, intraocular pressure should be monitored.

Cataracts

Use of corticosteroids may result in posterior subcapsular cataract formation.

Delayed Healing

The use of steroids after cataract surgery may delay healing and increase the incidence of bleb formation. In those diseases causing thinning of the cornea or sclera, perforations have been known to occur with the use of topical steroids. The initial prescription and renewal of the medication order should be made by a physician only after examination of the patient with the aid of magnification such as slit lamp biomicroscopy and, where appropriate, fluorescein staining.

Bacterial Infections

Prolonged use of corticosteroids may suppress the host response and thus increase the hazard of secondary ocular infections. In acute purulent conditions of the eye, steroids may mask infection or enhance existing infection.

Viral Infections

Employment of a corticosteroid medication in the treatment of patients with a history of herpes simplex requires great caution. Use of ocular steroids may prolong the course and may exacerbate the severity of many viral infections of the eye (including herpes simplex).

Fungal Infections

Fungal infections of the cornea are particularly prone to develop coincidentally with long-term local steroid application. Fungus invasion must be considered in any persistent corneal ulceration where a steroid has been used or is in use. Fungal cultures should be taken when appropriate.

Contact Lens Wear

Patients should not wear contact lenses during their course of therapy with LOTEMAX.

ADVERSE REACTIONS

Adverse reactions associated with ophthalmic steroids include elevated intraocular pressure, which may be associated with infrequent optic nerve damage, visual acuity and field defects, posterior subcapsular cataract formation, delayed wound healing and secondary ocular infection from pathogens including herpes simplex, and perforation of the globe where there is thinning of the cornea or sclera.

The most common adverse drug reactions reported were anterior chamber inflammation (5%), eye pain (2%), and foreign body sensation (2%).

USE IN SPECIFIC POPULATIONS

Pregnancy

Teratogenic Effects: Pregnancy Category C.

Loteprednol etabonate has been shown to be embryotoxic (delayed

ossification) and teratogenic (increased incidence of meningocele, abnormal left common carotid artery, and limb flexures) when administered orally to rabbits during organogenesis at a dose of 3 mg/kg/day (35 times the maximum daily clinical dose), a dose which caused no maternal toxicity. The no-observed-effect-level (NOEL) for these effects was 0.5 mg/kg/day (6 times the maximum daily clinical dose). Oral treatment of rats during organogenesis resulted in teratogenicity (absent innominate artery at ≥ 5 mg/kg/day doses, and cleft palate and umbilical hernia at ≥ 50 mg/kg/day) and embryotoxicity (increased post-implantation losses at 100 mg/kg/day and decreased fetal body weight and skeletal ossification with ≥ 50 mg/kg/day). Treatment of rats with 0.5 mg/kg/day (6 times the maximum clinical dose) during organogenesis did not result in any reproductive toxicity. Loteprednol etabonate was maternally toxic (significantly reduced body weight gain during treatment) when administered to pregnant rats during organogenesis at doses of ≥ 5 mg/kg/day.

Oral exposure of female rats to 50 mg/kg/day of loteprednol etabonate from the start of the fetal period through the end of lactation, a maternally toxic treatment regimen (significantly decreased body weight gain), gave rise to decreased growth and survival, and retarded development in the offspring during lactation; the NOEL for these effects was 5 mg/kg/day. Loteprednol etabonate had no effect on the duration of gestation or parturition when administered orally to pregnant rats at doses up to 50 mg/kg/day during the fetal period.

There are no adequate and well controlled studies in pregnant women.

LOTEMAX should be used during pregnancy only if the potential benefit justifies the potential risk to the fetus.

Nursing Mothers

It is not known whether topical ophthalmic administration of corticosteroids could result in sufficient systemic absorption to produce detectable quantities in human milk. Systemic steroids appear in human milk and could suppress growth, interfere with endogenous corticosteroid production, or cause other untoward effects. Caution should be exercised when LOTEMAX is administered to a nursing woman.

Pediatric Use

Safety and effectiveness in pediatric patients have not been established.

Geriatric Use

No overall differences in safety and effectiveness have been observed between elderly and younger patients.

NONCLINICAL TOXICOLOGY

Carcinogenesis, Mutagenesis, Impairment Of Fertility

Long-term animal studies have not been conducted to evaluate the carcinogenic potential of loteprednol etabonate. Loteprednol etabonate was not genotoxic *in vitro* in the Ames test, the mouse lymphoma tk assay, or in a chromosome aberration test in human lymphocytes, or *in vivo* in the single dose mouse micronucleus assay. Treatment of male and female rats with up to 50 mg/kg/day and 25 mg/kg/day of loteprednol etabonate, respectively, (600 and 300 times the maximum clinical dose, respectively) prior to and during mating did not impair fertility in either gender.

PATIENT COUNSELING INFORMATION

Administration

Invert closed bottle and shake once to fill tip before instilling drops.

Risk of Contamination

Patients should be advised not to allow the dropper tip to touch any surface, as this may contaminate the gel.

Contact Lens Wear

Patients should be advised not to wear contact lenses when using LOTEMAX.

Risk of Secondary Infection

If pain develops, redness, itching or inflammation becomes aggravated, the patient should be advised to consult a physician.

Bausch & Lomb Incorporated

Tampa, Florida 33637 USA

US Patent No. 5,800,807

©Bausch & Lomb Incorporated

®/™ are trademarks of Bausch & Lomb Incorporated or its affiliates.

US/LGX/15/0042

Based on 9269100-9269200

Revised: 9/2012



Down, Boy.

Help Tame Postoperative Ocular Inflammation
and Pain With **LOTEMAX[®] GEL**

Indication

LOTEMAX[®] GEL (loteprednol etabonate ophthalmic gel) 0.5% is indicated for the treatment of post-operative inflammation and pain following ocular surgery.

Important Safety Information about LOTE[®]MAX[®] GEL

- LOTE[®]MAX[®] GEL is contraindicated in most viral diseases of the cornea and conjunctiva including epithelial herpes simplex keratitis (dendritic keratitis), vaccinia, and varicella, and also in mycobacterial infection of the eye and fungal diseases of ocular structures.
- Prolonged use of corticosteroids may result in glaucoma with damage to the optic nerve, defects in visual acuity and fields of vision. If this product is used for 10 days or longer, IOP should be monitored.
- Use of corticosteroids may result in posterior subcapsular cataract formation.
- Use of steroids after cataract surgery may delay healing and increase the incidence of bleb formation and occurrence of perforations in those with diseases causing corneal and scleral thinning. The initial prescription and renewal of the medication order should be made by a physician only after examination of the patient with the aid of magnification, and where appropriate, fluorescein staining.
- Prolonged use of corticosteroids may suppress the host response and thus increase the hazard of secondary ocular infection. In acute purulent conditions, steroids may mask infection or enhance existing infection.
- Use of a corticosteroid medication in the treatment of patients with a history of herpes simplex requires great caution. Use of ocular steroids may prolong the course and exacerbate the severity of many viral infections of the eye (including herpes simplex).
- Fungal infections of the cornea are particularly prone to develop coincidentally with long-term local steroid application. Fungus invasion must be considered in any persistent corneal ulceration where a steroid has been used or is in use.
- Patients should not wear contact lenses when using LOTE[®]MAX[®] GEL.
- The most common ocular adverse drug reactions reported were anterior chamber inflammation (5%), eye pain (2%) and foreign body sensation (2%).

Please see brief summary of Prescribing Information on adjacent page.

®/™ are trademarks of Bausch & Lomb Incorporated or its affiliates. © 2015 Bausch & Lomb Incorporated. All rights reserved. Printed in USA. US/LGX/15/0041(1)

BAUSCH + LOMB

 **LOTEMAX[®] GEL**
loteprednol etabonate
ophthalmic gel 0.5%