

# REVIEW<sup>®</sup> *of* OPTOMETRY

May 15, 2023 • reviewofoptometry.com

Leadership in clinical care

**Pediatric Exams  
Made Easy**

*How to make a big impact  
on our smaller patients.*

**PAGE 34**

24TH ANNUAL  
DRY EYE REPORT

## How CONTACT LENSES Contribute to DRY EYE

# PRESERVATIVE-FREE POWERHOUSE

— SYMPTOM RELIEF FOR DRY EYES —



No two patients' eyes are the same. That's why REFRESH<sup>®</sup> provides a portfolio of products expertly formulated around your patients' specific needs.

RECOMMEND THE LEADER IN PRESERVATIVE-FREE\*

**Refresh<sup>®</sup>**  
Lubricant Eye Drops

[refreshbrand.com/doc](http://refreshbrand.com/doc)

\*REFRESH<sup>®</sup> Family of Products, Ipsos Healthcare, 2021 REFRESH<sup>®</sup> ECP Recommendation Survey  
© 2023 AbbVie. All rights reserved. All trademarks are the property of their respective owners.

**Allergan**  
an AbbVie company

US-RFS-230035 03/23



When Psych Issues Manifest in Your Patient, p. 42 • Would You Miss This Retinal Detachment?, p. 31

# REVIEW<sup>®</sup> *of* OPTOMETRY

May 15, 2023 • reviewofoptometry.com

Leadership in clinical care

## Pediatric Exams Made Easy

*How to make a big impact  
on our smaller patients.*

**PAGE 34**

24TH ANNUAL  
DRY EYE REPORT

## How CONTACT LENSES Contribute to DRY EYE

*Learn about their impact on the  
fragile tear film, which patients  
are at greatest risk and  
the options available  
to alleviate symptoms.*

**Page 54**

Assessing Eyelid Health  
in Dry Eye Patients


**Page 48**

Keeping an Eye Out  
For Lacrimal Gland  
Abnormalities

**Page 62**

— EARN 2 CE  
CREDITS

REVIEW OF OPTOMETRY • VOL. 160, NO. 5 • MAY 15, 2023 • Pediatric Exams Made Easy • Handling Mental Health Issues in Patients • Eyelids and Dry Eye • Contact Lenses and Dry Eye • Diagnosing Lacrimal Gland Disorders



# let's open our eyes to preservative freedom

## innovation is our purpose



Our priority is to continue growing as a leader in the field of preservative-free eye products. Thea Pharma, Inc. intends to provide the next generation with answers to unmet eye care needs by sharing knowledge across the eye care industry.



**Théa**  
let's open our eyes

---

**We strive to deliver uncompromising care that allows eye care professionals in the US to envision preservative freedom as the future of ophthalmic treatment**

**DISCOVER HOW AT  
[THEAPHARMAINC.COM/PRESERVATIVE-FREE/](http://THEAPHARMAINC.COM/PRESERVATIVE-FREE/)**





## Washington Scope Bill Awaiting Governor's Signature

*SSB 5389 would authorize optometrists in the state to perform several advanced procedures—excluding lasers—and expand prescribing rights.*

To wrap up an eventful run this legislative session, Washington's Substitute Senate Bill 5389—proposing to add various practice rights and procedures to optometry's scope—recently passed both the Senate (46-2) and the House (81-15) with strong bipartisan support. The document landed on Governor Jay Inslee's desk on April 21 and was expected to be signed into law within 20 days.

"For the first time in two decades, the bill will update Washington's scope of practice to more fully reflect the education and training of optometrists and move the state more in line with what is increasingly becoming the standard of care in optometry," says Michael Sirott, OD, president of the Optometric Physicians of Washington (OPW).

The bill has been altered rather significantly since its introduction in January. The original version proposed that optometrists be allowed to perform laser procedures—included in the practice scope of 10 states and counting. But, after multiple negotiations to assuage the concerns voiced by the

opposition, the current and final version of the bill excludes lasers, as well as suturing. The final document would still grant optometrists the authority to perform numerous advanced procedures and prescribe more pharmaceutical agents. Some of the expanded privileges proposed in SSB 5389 include:

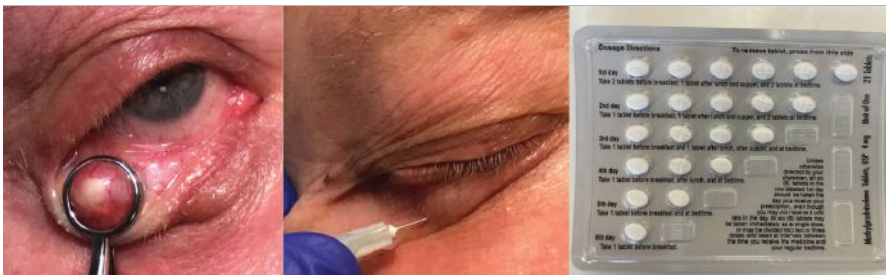- Incision and excision of chalazion
- Injections (subconjunctival, subcutaneous and intramuscular (epinephrine))
- Eyelid surgery (excluding cosmetic surgery or those requiring the use of general anesthesia)
- Use of topical and injectable anesthesia
- Prescribing of oral steroids

The legislation also grants authority to the Washington Board of Optometry regarding the rulemaking necessary to implement the physician training and certification outlined in the new law, which is something Dr. Sirott says the OPW pushed for throughout the session to remain in the bill. Once the document is signed, it's expected to take the Board about two years to implement the new law's provisions.

So, what will optometrists have to do to perform the added procedures once SSB 5389 is signed and the Board's rulemaking process is complete? Dr. Sirott says that the legislation "creates a licensing endorsement structure that will clearly demonstrate which optometrists are endorsed by the Board of Optometry to perform advanced procedures. It spells out specific pathways for ODs to earn the endorsement, including completion of required training in an accredited optometry school or through robust, accredited continuing education courses, similar to the CE requirements that physicians meet when learning new procedures," he explains.

Other training requirements outlined in the bill to perform the advanced procedures include live patient experience during clinical training, as well as successful completion of a nationally standardized examination, such as the National Board of Examiners in Optometry procedure examination.

Speaking on the bill's negotiated amendments, including the exclusion of laser procedures, Dr. Sirott remarks that "the road to legislation always has a few curves along the way. We accepted some compromises to align the bill more closely with the findings and recommendations of the Department of Health's 'sunrise review' of the bill," he notes. "Our opponents battled every step of the way, including proposing some 'poison pill' amendments with the intention of making the bill something the OPW couldn't accept. Fortunately, we were able to work with legislators to remove those problematic



**A bill that was awaiting Washington Gov. Jay Inslee's signature at press time would authorize the state's optometrists to perform several non-laser procedures, such as lesion removal and injections, as well as expand their prescribing authority to include oral steroids and topical or injectable anesthesia.**

provisions and keep the bill something we could strongly support.”

The OPW credits the progress of the bill thus far to its numerous supporters and advocates, especially the organization’s members. “It took a lot of work to get to this point,” Dr. Sirott reiterates. “We had a core group of volunteers who put in untold hours working on the substance of the bill and coordinating advocacy efforts. We organized a series of meetings and demonstrations with legislators in preparation for this session. As the bill moved through Olympia, we had a number of calls to action for our members to contact their legislators or support the bill during committee hearings, and they responded.”

Dr. Sirott shares numerous arguments cited by the bill’s proponents during hearings that helped communicate its safety and importance:

- The bill aligned closely with the Department of Health recommendations, which concluded that

“ODs are taught these procedures in school, are prepared to safely provide this care to patients and are already doing so in other states, including our neighbors in Oregon,” said Dr. Sirott.

- The bill would help patients receive more timely care by removing the need to wait months for an appointment with an ophthalmologist who accepts their insurance (especially Medicaid).
  - A study commissioned by the OPW found “patients most likely to benefit from expanded access to care were rural residents, the elderly and low-income families relying on the state’s Medicaid system,” notes Dr. Sirott.
  - The bill would reduce patient costs by eliminating duplicate office visits and exams and reducing the time and expense of travel.
- “Some of the most powerful testimony came in the form of personal

stories from optometrists holding dual licensure in multiple states who could perform the procedures elsewhere but not in Washington,” says Dr. Sirott.

Thanks to the strong advocacy efforts of the OPW and ODs across the state, in just a few weeks, the expanded practice rights may be signed into law.

“While this was an important victory for optometry in Washington, we didn’t get everything we wanted in the bill, such as laser procedures, so we’ll be developing plans for when and how to reapproach the Legislature on that issue in the future,” says Dr. Sirott.

With numerous states fighting for optometric laser authority and four that have succeeded since 2021, evidence continues to mount on the safety and qualification of ODs performing laser procedures. The OPW plans to work with the Department of Health over the next few years to prepare for the legislative battle for laser privileges. ◀

## Autoimmune Disease Associated with Thinner Cornea, Dry Eye

Previous studies have shown that patients with dry eye disease (DED) display thinner superior corneal epithelium compared with controls. Researchers recently tested their hypothesis that presence of autoantibodies is associated with superior epithelial thinning. They also assessed the link between corneal epithelial thickness and clinical findings, as well as the utility of including corneal epithelial thickness as a diagnostic tool for DED patients. They presented their results during ARVO 2023 in New Orleans.

This study included 208 patients from the DED clinic at University of Illinois Chicago who had bloodwork results for autoantibodies associated with DED-related autoimmune diseases. Superior corneal epithelial thickness, Schirmer’s 1 test and corneal higher-order aberrations (HOAs) were obtained when available.

Patients with antibody-positive bloodwork had thinner superior corneal epithelial thickness (47.41µm vs. 49.73µm) compared to those with antibody-negative bloodwork (n=181 eyes).

The top two most useful indicators that a patient will have antibody-positive bloodwork are a Schirmer’s <15mm and an epithelial thickness <45µm. Eyes with epithelial thickness <45µm and Schirmer’s <10mm have significantly greater corneal HOAs (1.85 vs. 0.1) compared with eyes with thickness ≥45µm and/or Schirmer’s ≥10mm. If a patient’s eye had both superior corneal epithelial thickness <45µm and Schirmer’s test results <10mm, the probability that they had auto-antibody-positive bloodwork was 81.2%.

“Presence of autoimmune disease must be considered in patients who have superior epithelial thinning and reduced tear production because these patients are five-times more likely to have antibody-positive bloodwork and

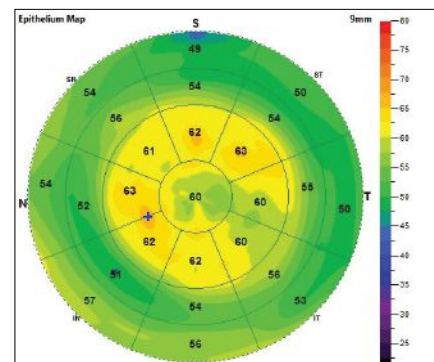


Photo: Justin Cole, OD, and Jarett Mazzarella, OD

**If a patient’s eye has both superior corneal epithelial thickness <45µm and Schirmer’s test results <10mm, they are five-times more likely to have antibody-positive bloodwork and associated visual compromise.**

associated visual compromise, as demonstrated by high corneal HOAs,” the researchers concluded in their abstract.

*Original abstract content © Association for Research in Vision and Ophthalmology 2023.* ◀

Bernal A, Yang Y, Surenkhuu B, et al. Corneal epithelial thickness in dry eye disease (DED) patients: association with autoimmunity. ARVO 2023 annual meeting.

# Irregular Sleep Schedule Associated with Myopia

Researchers noted a higher prevalence of the condition among schoolchildren who get less than seven hours of shut-eye per day.

Sleep plays a crucial role in mental and physical health, especially during the developmental period. Perhaps unsurprisingly, several studies have suggested that irregular sleep-wake patterns in children may contribute to increased refractive error. Additionally, research has demonstrated a link between myopia and shorter sleep duration. To delve further into this potential correlation, researchers in China recently conducted a cross-sectional study on school-aged children and adolescents. Their findings confirmed that there likely is an association between irregular sleep-wake schedules and myopia risk.

A total of 30,188 students were recruited. Each filled out a questionnaire on sleep-wake schedules, and presence of myopia was determined based on the age that children first reported using myopia-correction glasses or contact lenses. The researchers then performed multivariate logistic regression to examine the relationship between sleep-wake schedule and risk of self-reported myopia. An additional analysis stratified students by school grade.

The overall prevalence of myopia in the cohort was 49.8%. Primary, junior high and senior high school students had respective prevalence rates of 25.6%, 62.4% and 75.7%. The researchers observed a higher myopia prevalence among students with irregular vs. regular sleep-wake times. They noted that the following factors appeared to be associated with an increased odds ratio (OR) of self-reported myopia:

- nighttime sleep duration of less than seven hours/day (OR=1.27)
- no daytime nap (OR=1.10)
- irregular weekday bedtime (OR=1.11)
- irregular weekday wake time (OR=1.21)
- weekend bedtime delayed more than one hour/day (OR=1.20)



Photo: Annie Spratt on Unsplash

**Sleep-wake patterns in children could play a role in myopia, a recent study showed.**

- weekend wake time delayed more than one hour/day (OR=1.11)
- irregular sleep-wake time on weekdays (OR=1.13)
- social jetlag (defined as the discrepancy in sleep time between weekdays and weekends) greater than one hour/day (OR=1.08)

These associations remained significant after adjusting for age, sex, grade, parental education level, family income, parental myopia and academic record and workload.

In the analysis stratified by school grade, the following were associated with self-reported myopia in primary school students: nighttime sleep duration <less than seven hours/day, no daytime naps and irregular sleep-wake time on weekdays.

The researchers proposed some possible explanations for the observed associations in their recent paper on the study, published in *BMC Ophthalmology*.

“During the day, the indoor environment is relatively dark. However, at night, artificial lighting not only increases the intensity of light above natural nighttime but also reduces the duration of darkness, which puts humans out of sync with natural circadian rhythms,” they explained in their paper. “An observational study showed that using objective indicators in children could observe significant diurnal changes in

multiple eye and systemic parameters within 24 hours, and the rhythms of the eye axis and choroidal thickness were approximately opposite.”

Additionally, the researchers cited a similar study performed on animals, which found that “exposure to mid-night light altered the rhythm of the ocular axis and choroidal thickness, which may be associated with the occurrence of refractive error in the eyes,” they wrote.

Encouraging parents of younger patients to enforce a healthy sleep schedule could potentially reduce a child’s risk of developing myopia or help prevent the impact of insufficient sleep on refractive error. But what exactly is a “healthy” sleep schedule for children? The researchers noted that a child’s sleep schedule should ideally have the following:

- sufficient duration (the American Academy of Sleep Medicine recommends nine to 12 hours/day for children aged six to 12 years and eight to 10 hours/day for those aged 13 to 18 years)
- proper and regular timing
- good quality

Additionally, sleep disorders and other obstacles to a healthy sleep schedule should be addressed whenever possible.

“Investigating and understanding irregular sleep-wake schedules in modern society could be an effective approach to understanding and preventing myopia,” the researchers concluded in their paper. “Longitudinal cohort studies or randomized controlled trials that use objective sleep measures of community-based sleep education intervention should be conducted to further clarify myopia’s etiology.” ◀

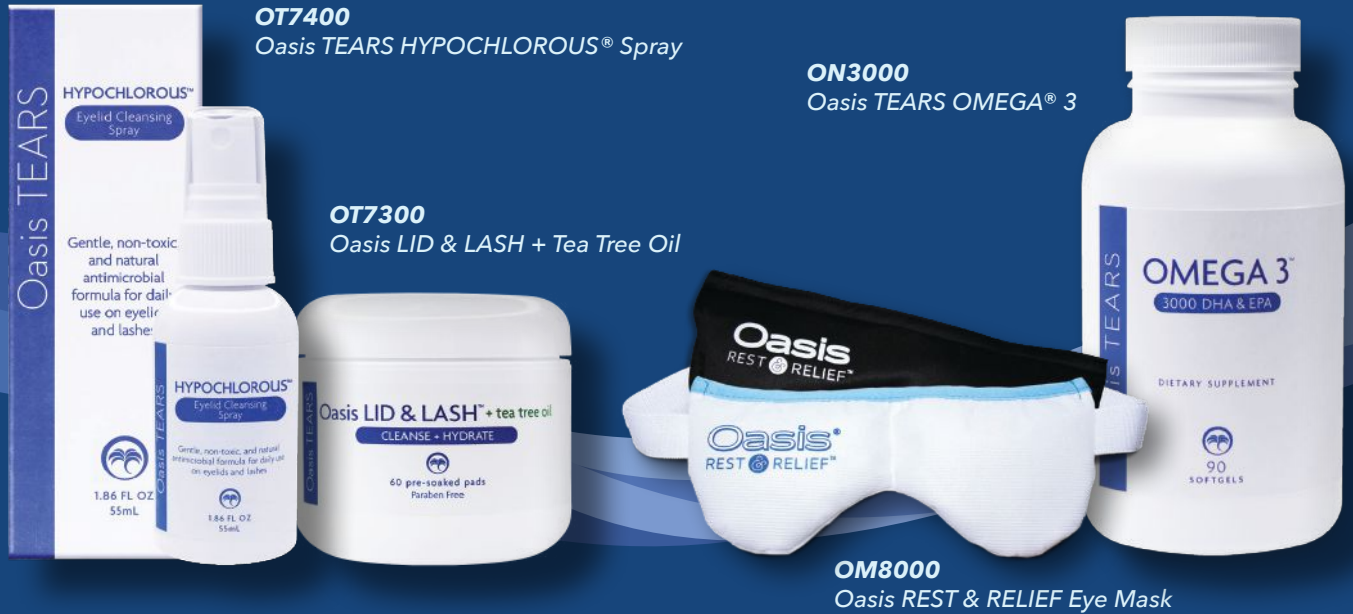Xu S, Zong Z, Zhu Y, et al. Association between sleep-wake schedules and myopia among Chinese school-aged children and adolescents: a cross-sectional study. *BMC Ophthalmol.* 2023;23:135.





# TOO MUCH SCREEN TIME

Introduce a **Lid Hygiene Regimen** for Your Patients



**OT7400**  
*Oasis TEARS HYPOCHLOROUS® Spray*

**ON3000**  
*Oasis TEARS OMEGA® 3*

**OT7300**  
*Oasis LID & LASH + Tea Tree Oil*

**OM8000**  
*Oasis REST & RELIEF Eye Mask*

SCRUB & CLEANSE

ENCOURAGE FLOW



**Receive A Lid Hygiene Kit**  
**Schedule A Lid Hygiene Workshop**

Call (844) 820-8940

Email [customerservice@oasismedical.com](mailto:customerservice@oasismedical.com)

Visit [www.oasismedical.com](http://www.oasismedical.com)

# Oily Skin Increases Risk of Dry Eye

*Study shows the tear film may be disrupted by fatty acids and low pH from adjacent non-ocular lipids, which can lead to irritation and pain.*

It's been proposed that meibomian lipids on the lid margin form a barrier that prevents skin lipids from entering the eye and disrupting tear film stability. What happens, then, when meibomian gland dysfunction upsets this balance by reducing eyelid lipid release? In a presentation at ARVO 2023 in New Orleans, optometrist Jim Kokkinakis from Sydney described his recent investigation of the interaction. Using three volunteer subjects, Dr. Kokkinakis found that applying facial lipid samples to the ocular surface caused tear film disruption, pain, fluorescein staining of the corneal surface and meibomian gland activity. According to the author, this is the first study showing the effects of skin lipid contamination of the ocular surface.

First, the side of the nose of each participant was swabbed to collect lipids found on the skin. Next, the corneal surface, eyelid margin, eyelash base or lacrimal lake were touched with either a cleaned (control) or loaded thread. Acetic acid was used as the control for low pH. Effects on the tear film were visualized using fluorescein or TearView, a new

device that shows tear film formation and stability in real time.

Both TearView and fluorescein assessment showed that minimal amounts of skin lipid applied to the cornea, eyelid margin or lacrimal lake spread and destroyed the tear film's integrity, which was not restored for several blinks. The contamination of the eye with the skin lipid sample also caused pain and staining of the corneal surface. TearView showed that introducing the skin lipid triggered meibomian lipid secretion that displaced the substance, presumably giving protection. In the control subjects, acetic acid—emulating skin pH—destroyed the tear film but did not spread from the site of touch. It caused corneal staining, and the tear film recovered with one blink. Neutral control lipids did not cause any discomfort and did not destroy the tear film but smeared across the tear film during blinking. In contrast, free fatty acids had similar effects to the skin swab substance.

Tear film disruption is most likely due to fatty acids and low pH, which supports the proposed barrier function of meibum on the eyelid margin, the author explained. "This barrier

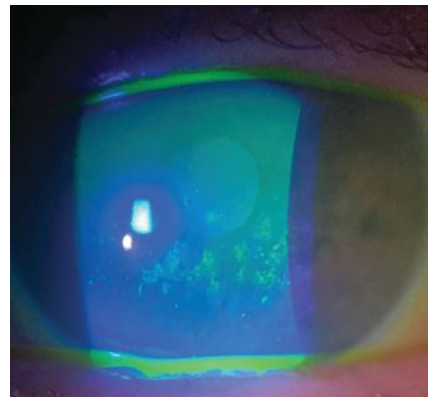


Photo: Pam Theriot, OD

**The tear film may be disrupted by skin oils, which can lead to a faulty tear film and dry, irritated eyes.**

would be compromised by diminished meibomian lipid secretion or excess of skin lipid secretion, which would overwhelm the lid margin barrier. Therefore, skin lipid contamination of the ocular surface might be a common factor for the cause of dry eye in various types of blepharitis, ocular rosacea and meibomian gland dysfunction," Dr. Kokkinakis concluded in his abstract.

*Original abstract content © Association for Research in Vision and Ophthalmology 2023.* ◀

Kokkinakis J. In vivo evidence that skin lipids may be a cause of dry eye in humans. ARVO 2023 annual meeting.

## IN BRIEF

■ **Lattice Degeneration Top Risk Factor for RRD, Retinal Tear After Cataract Surgery.** A recent study in *Ophthalmology Science* evaluated the incidence of two rare post-cataract surgery complications, rhegmatogenous retinal detachment (RRD) and retinal tear, using data from the IRIS registry. **The researchers identified certain demographics, ocular comorbidities and intraoperative factors that increased the likelihood of these events, including male gender, younger age, lattice degeneration, hypermature cataract, posterior**

**vitreous detachment and high myopia.** The retrospective cohort study included 3,177,195 eyes of 1,983,712 patients who were at least 40 years old and underwent cataract surgery. Within one year post-op, 0.21% of the cohort developed RRD—equating to one in 500 cataract surgeries—and 0.17% developed retinal tear without RRD. **"Prior studies (before modern-day small-incision cataract surgery) have reported the one-year incidence of RRD after cataract surgery to range from 0.6% to 1.7%, representing a more than 30-fold increased risk of RRD**

**when compared with rates in the general population of 0.007% to 0.018%,"** the researchers wrote in their paper. **"However, more recent studies [including the present study] demonstrate that this incidence rate may be declining."** When the research team performed multivariable logistic regression on the data, they found that the following factors increased the risk of RRD and retinal tear, respectively: male sex (OR: 3.15 and 1.79), younger age compared with patients over 70 (OR: 8.61 and 2.74), peaking at age 40 to 50 for RRD (OR: 7.74 to 9.58) and age 50 to 60 for retinal tear

(OR: 2.52 to 2.98). The researchers wrote that **"approximately 1.44% of patients with lattice degeneration—the most significant RRD risk factor observed—developed the complication within a year post-op."** As for retinal tear, lattice degeneration also conferred the highest odds (OR: 43.86). Based on these data, **the researchers recommend careful monitoring for these patients after cataract surgery, especially for young males.** Morano MJ, Khan MA, Zhang Q, et al. Incidence and risk factors for retinal detachment and retinal tear after cataract surgery: IRIS Registry Analysis. *Ophthalmol Sci.* April 2023. [Epub ahead of print].

# Hypertension During Pregnancy Increases Refractive Errors in Offspring

All forms of ametropia showed higher incidence in a large study. Potential mechanisms include elevated antiangiogenic factors and increased oxidative stress.

A nationwide study based in Denmark recently found that refractive conditions are more prevalent during childhood and adolescence. The researchers explained their findings were a result of growing evidence in support of adverse prenatal or intrauterine environments contributing to high refractive error development. They specifically looked at maternal hypertensive disorder of pregnancy (HDP), since the condition's association remains unknown.

Individuals born in Denmark from 1978 to 2018 were included (n=2,537,421) and followed from birth to refractive error diagnosis, 18th birthday, death, emigration or the last day of 2018, whichever happened first. Considered exposures were maternal HDP (preeclampsia and eclampsia) and hypertension. Outcomes were first occurrences of high ametropia of any kind in offspring.

Of the 104,952 mothers with HDP, 0.9% of offspring developed high refractive error; among children of 2,432,469 mothers without HDP, the rate was 0.6%. The cumulative incidence of high refractive error was higher in the exposed cohort at 18 years old, and offspring of mothers with HDP had a 39% increased risk of overall high refractive error. Elevated risks included concomitant hypermetropia, myopia

and astigmatism. High risk persisted in offspring 12 years or younger. Highest risk was observed, through both timing of diagnosis and severity of preeclampsia, in offspring prenatally exposed to preeclampsia that was early-onset and severe.

The *JAMA Network Open* authors explained a few possibilities of the observed associations. One may be because women with HDP exhibit changed serum level of circulation antiangiogenic factors. The increased factor of tyrosine kinase and decreased placental growth factor may persistently influence ocular microvasculature structure and ocular blood flow, leading to altered retinal development and morphologic changes.

Another way this association may occur is through HDP causing excessive oxidative stress and inflammation, affecting various organ systems through differing pathophysiological mechanism activation. In turn, oxidative stress may damage the retina and affect refractive development by resultant short- and long-term refractive errors.

The authors also mention maternal HDP and its subtypes are potentially associated with other visual conditions like retinopathy of prematurity, narrower retinal arteriolar and venular caliber, thinner macular ganglion cell-inner



Photo: Freestocks/Unsplash

**Pregnant women with gestational diabetes or preeclampsia may be more likely to produce children prone to hyperopia, myopia or astigmatism.**

plexiform layer and others, suggesting HDP has negative effects on visual development more generally.

Lastly, the connection was made between HDP and diabetes, as both consist of the most common cardiometabolic disorders occurring in pregnancy. The authors pointed to similar disease risk in both conditions for overall high refractive error, suggesting a shared pathological process of both in refractive development of offspring.

Looking at clinical implications, the researchers noted that “these findings suggest that early screening of ophthalmic refractive errors should be recommended for offspring prenatally exposed to maternal HDP, especially those of mothers with severe and early-onset preeclampsia.” ◀

Li M, Huang C, Yang W, et al. Evaluation of hypertensive disorder of pregnancy and high refractive error in offspring during childhood and adolescence. *JAMA Netw Open*. 2023;6(4):e238694.

## IN BRIEF

**DREAM Study Researchers Again Challenge Omega-3 Efficacy in DED Treatment.** While the original DREAM study only followed patients for 12 months, researchers—again led by study chair Penny Asbell, MD—recently obtained an additional year of data from moderate-to-severe DED patients who had been initially randomized to receive omega-3 pills the first year. During the second year, participants were re-randomized

to either continue with omega-3 or switch to placebo. The team evaluated progression of DED symptoms and signs over two years and presented their findings at ARVO 2023.

The data showed that **at three months, DED patients taking omega-3 showed significant improvements in OSDI and Brief Ocular Discomfort Index scores and less use of artificial tears or gel; however, after this period (an additional six to 24 months), DED symptoms remained stable.** The only metric

that showed a significant change in treated patients over two years was conjunctival staining score.

The researchers explained that the significant improvement in subjective DED symptoms in the first three months of omega-3 treatment could be chalked up to a placebo effect. They noted that **“future clinical trials of DED should consider the short-term placebo effect of treatments on DED symptoms.”**

The results of this randomized follow-up study on the DREAM

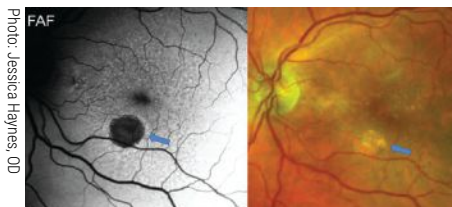
cohort suggest that omega-3 supplementation and observation promote comparable treatment outcomes over two years in DED patients. Additionally, the researchers concluded in their abstract that **“these results do not support progression of DED over the two years of observation.”**

*Original abstract content © Association for Research in Vision and Ophthalmology 2023.*

Daniel Lee D, Yu Y, Bunya VV, et al. Two-year progression of dry eye disease in the dry eye assessment and management (DREAM) study. ARVO 2023 annual meeting.

# Study Finds One in Four GA Patients Convert to Wet AMD Within Three Years

**O**ne study presented at ARVO 2023 in New Orleans helps characterize the extent of disease burden associated with geographic atrophy (GA). Specifically, the authors' intention was to see how VA changes and conversion to neovascular AMD affect GA patients. Although GA due to AMD is a common vision loss cause, the authors noted there aren't many large clinical studies assessing the relationship.



**GA can cause meaningful disease burden by VA, conversion to nAMD and CST measures.**

The retrospective study included patients diagnosed with dry AMD with advanced atrophy. Patients must have not been diagnosed with nAMD prior to GA diagnosis in at least one eye. A follow-up of at least three years ensued.

Average age was 79 years. Of the 18,712 GA eyes, 25% were diagnosed with nAMD on average 24.7 months later. Conversion rates by year were as follows (percentage of GA eyes):

- within year one: 8.8%
- within year two: 5.9%
- within year three: 4.6%
- beyond year three: 6.3%

The 75% who didn't develop nAMD (11,125 eyes) and still had valid VA readings throughout follow-up possessed average VA measures of 59.5 letters at baseline and a 3.1 letter loss at one year. Loss of 6.4 letters at year two

was observed in 9,725 GA eyes, and 8,870 saw a 10.1 letter loss at year three.

Eyes with baseline VA below 20/40 to 20/100 lost more letters than others. Even further, eyes with GA but good VA at baseline ended up losing more letters than those with worse VA.

The authors conclude that "those GA eyes with modest VA impairment at baseline may be at the greatest risk of further vision loss, likely from progression to subfoveal GA. Eyes with GA are also at meaningful risk of nAMD." This information may help clinicians when looking at these patients.

*Original abstract content © Association for Research in Vision and Ophthalmology 2023.* ◀

Ciulla TA, Boucher N, Aggarwal N, Harris A. Geographic atrophy is associated with meaningful disease burden: visual acuity changes and conversion to neovascular AMD over 3 years in 18,712 patient eyes. ARVO 2023 annual meeting.

# Blood Thinners Worsen Submacular Hem. Secondary to AMD

**F**or patients with AMD, the development of extensive submacular hemorrhage can be vision-threatening despite the beneficial effects of surgical intervention. The findings of a new study presented at ARVO 2023 in New Orleans suggest taking extra caution when monitoring patients on blood thinners, as the data showed these drugs can significantly increase the size and severity of submacular hemorrhage.

"Systemic blood-thinning drugs, which are commonly prescribed in the same age group [as AMD], are known to increase the overall risk of severe hemorrhage in many parts of the body," the team of German researchers wrote in their abstract. To investigate the potential association of submacular hemorrhage severity with various types of blood thinners, the group reviewed the medical records of 175 patients who underwent surgery for submacular hemor-

rhage between 2019 and 2022 (mean age: 83). The average hemorrhage size was 33.62mm<sup>2</sup>, and the average BCVA was 1.58logMAR at presentation and 1.47logMAR one year post-op.

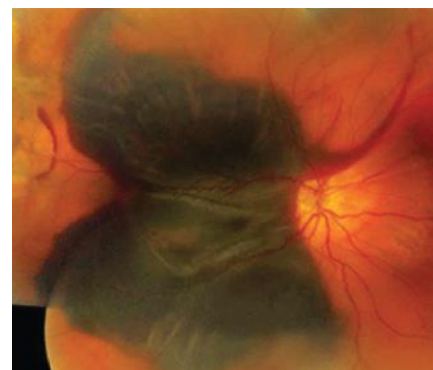
Nearly three-quarters of patients were on blood thinners (73.4%). The researchers reported that "the size of submacular hemorrhage was larger in patients on blood-thinning medication (36.03mm<sup>2</sup> vs. 21.73mm<sup>2</sup>) and their post-op BCVA was worse" after one year, at 1.63logMAR vs. 1.32logMAR for unmedicated subjects. They also observed a difference in outcomes depending on blood thinner type. Compared with direct oral anticoagulants, patients with vitamin K antagonists (e.g., warfarin) had larger hemorrhage size and worse BCVA outcomes.

These study results provide convincing evidence of the potential increased severity of hemorrhage in patients with AMD on blood thinners. Therefore,

the researchers concluded, "the indication for their intake should be critically evaluated."

*Original abstract content © Association for Research in Vision and Ophthalmology 2023.* ◀

Liegl RG, Weber C, Bertelsmann M, et al. Blood thinners in patients with submacular hemorrhage secondary to neovascular AMD. ARVO 2023 annual meeting.



**Close monitoring for signs of submacular hemorrhage may be warranted for AMD patients taking blood-thinning medication.**

# Atropine\* PF

## Now Available in **503B!**


0.01%, 0.025%, and 0.05%

SCAN TO ORDER



# 100%

**PRESERVATIVE-FREE.**  
**BORIC ACID-FREE.**



## Still the same medication, but with no preservatives.

- ✓ Preservative-Free (no BAK)
- ✓ \$39 per bottle / \$390 per box of 10
- ✓ Patent-pending formulation
- ✓ 240 days expiration dating\*\*

## All three concentrations are also available to prescribe from our **503A Patient Specific Pharmacy.**

Start prescribing to your patients today by scanning the QR code below. At [atropine.com](https://atropine.com), you'll find EMR instructions, the MaxRX Prescriber Portal™ link, and our fax order form.



**atropine.com**

powered by  
**imprimis<sup>®</sup>**  
A HARROW COMPANY



\*For professional use only. ImprimisRx specializes in customizing medications to meet unique patient and practitioner needs. No compounded medication is reviewed by the FDA for safety and efficacy. ImprimisRx does not compound essential copies of commercially available products. These ingredients carry risks. Visit [imprimisrx.com/productinformation](https://imprimisrx.com/productinformation) for full product details.

\*\*Stability studies conducted at controlled room temperature storage for up to 240 days. BUD in 503A is 180 days.

ImprimisRx and MaxRX Prescriber Portal are trademarks of Harrow IP, LLC. ©2023 ImprimisRx. All Rights Reserved. OT-00018\_Rev2 04/23

# PVD Follow-up in Six Weeks or Less is Crucial

*Be vigilant for delayed retinal break or detachment during this period in all patients. High-risk eyes should be seen sooner and more frequently.*

After a patient's initial diagnosis of posterior vitreous detachment (PVD), reevaluation in the short-term is critical to identify and address any visual consequences, but guidelines regarding the timing of the second exam are unclear. In a recent analysis of data from the IRIS registry, researchers found that follow-up examination after initial PVD within six weeks or less is necessary to diagnose retinal complications.

Patients coded to have a PVD from 2013 to 2018 along with CPT coding of extended ophthalmoscopy were included. Ocular baseline characteristics included visual acuity, lens status, presence or absence of vitreous hemorrhage, myopia, lattice degeneration and subspecialty training of the treating physician.

A total of 434,046 eyes met inclusion/exclusion criteria and 10,518 eyes (2.42%) presented with a delayed retinal break or detachment after initial PVD. The median time to retinal break and detachment after initial PVD was 42 days and 51 days, respectively.

In PVD eyes with at least one ocular risk factor among vitreous hemorrhage, lattice degeneration, fellow eye retinal break or detachment, and myopia, the median time to retinal break or detach-

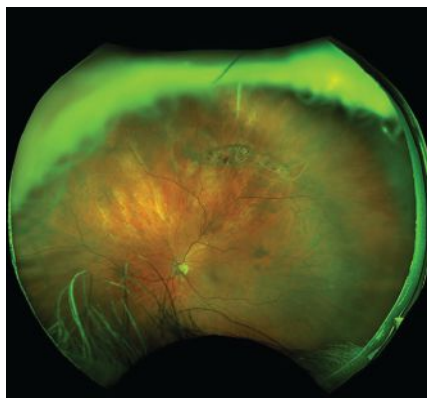


Photo: Anna Bedwell, OD

**A double horseshoe tear in an area of lattice from a PVD. The tear was not present at the first visit but instead found at the one-month follow-up.**

ment was shortened to 34 and 39 days, respectively. In eyes documented only with vitreous hemorrhage, the median time to retinal break was just 14 days.

"We noted a significant difference in timing to delayed retinal detachment in non-retina specialists (median=57 days) vs. retina specialists (median=46 days)," the authors pointed out in their paper for *Ophthalmology Retina*. "No significant difference, however, was found in timing of delayed retinal break in this subset (median=38 days)."

If PVD is not managed appropriately, potentially devastating consequences can occur. Thus, the timing of a follow-up exam after the initial visit is crucial

to detect delayed retinal pathology. The authors recommend at least one repeat exam within the first six weeks in all patients, and sooner and more frequent exams within one month for eyes with higher risk features.

Anna Bedwell, OD, of Indiana University School of Optometry—an active member of the Optometric Retina Society and editor of its newsletter— noted that she agrees with the findings of this study and highlighted two important components for monitoring acute PVD that the study emphasizes: follow-up timing and risk assessment.

"In the past few years, I've adjusted my follow-up timeline based on risk factors," she explained. "I follow-up on all acute PVDs with a four- to six-week follow-up. For those with risk factors, particularly lattice degeneration, high myopia, history of retinal break in the fellow eye or vitreous hemorrhage at presentation, I recommend a second follow-up another four to six weeks later. This study reinforces that idea. Even though the incidence of a delayed retinal break is low, a missed retinal break can have significant visual consequences." ◀

Vangipuram G, Li C, Liu L, et al. Timing of delayed retinal pathology in patients presenting with acute posterior vitreous detachment in the IRIS Registry. *Ophthalmol Retina*. April 10, 2023. [Epub ahead of print].

## IN BRIEF

### ■ Intermittent Exotropia More Common in Early-Onset Myopia.

New research presented at ARVO 2023 found the most common type of strabismus to develop in young myopes to be intermittent exotropia. The team of investigators from Sydney also observed that the age of myopia onset played a significant role in the development of intermittent exotropia, reporting a higher incidence rate in children with early-onset myopia.

The Sydney Myopia Study included 876 schoolchildren aged

six to 12 and 1,211 children aged 12 to 17 who were followed for five to six years. SE myopia  $\leq 0.5D$  and hyperopia  $\geq 3.0D$  were identified using cycloplegic autorefraction.

In the younger cohort, the incidence rate of strabismus was 8.0/1000 children/year, and in the older cohort, the incidence was 16.3/1000 children/year. The researchers observed significant changes in the type of strabismus present in the two cohorts over the follow-up period. "Of children without strabismus at baseline, intermittent exotropia was the most common type to develop, with 1.9%

of the younger cohort and 2.2% of the older cohort developing an intermittent exotropia by follow-up," they reported in their abstract.

One in four myopic children (25%) in the younger cohort developed strabismus vs. 1.9% of emmetropic and 4.3% of hyperopic children. "In children with early-onset myopia, all incident strabismus was intermittent exotropia type," the investigators pointed out, adding that this equates to an incidence rate of 45.5/1000 children/year for intermittent exotropia in those with early-onset myopia. In the older cohort, however, this

wasn't the case; only 4.2% of later-onset myopes aged 12 to 17 years old developed strabismus, and the incidence rate of intermittent exotropia was 6.6/1000 children/year.

The team concluded that there's a significant relationship between refraction and strabismus, "with the age of myopia onset being an influential factor in the development of intermittent exotropia."

Original abstract content © Association for Research in Vision and Ophthalmology 2023.

Adinanto F, French A, Rose KA. Increased incidence of intermittent exotropia in children with early onset myopia. ARVO 2023 annual meeting.

# Why Modern ERG Is Re-Defining Diabetes Management



**Timothy Earley, OD**  
Medina Vision & Laser Centre



**Steve Ferrucci, OD, FAAO**  
Sepulveda Veterans Administration



**Julie Rodman, OD, MSc, FAAO**  
The Eyecare Institute - Broward

## Detecting and managing diabetic retinopathy (DR) has always centered on structural testing, including dilated fundus examination and, in many cases, OCT. How does ERG further enhance clinical decision-making?

**Dr. Rodman:** Early detection of retinal abnormalities is a critical step in preventing vision loss. Importantly, functional loss may precede identifiable structural damage when using an objective test like ERG. Also, it's important to recognize that, because DR is a neurovascular disease, retinal function doesn't always align with structure, which is why functional and structural tests should be used in tandem.

**Dr. Earley:** DR is a chronic, progressive disease, which means we can detect it before it becomes advanced disease. This is best achieved using both structural and functional testing. ERG tips us off to functional changes that may impact a patient's vision — typically in advance of structural changes. This is an important feature of ERG testing—it allows us to detect functional stress so that we can anticipate structural damage. In studies comparing the ability of ERG and structural imaging to evaluate sight-threatening DR, ERG outperformed traditional imaging at predicting which patients would likely need subsequent medical intervention.<sup>1,2</sup>

**Dr. Ferrucci:** Beyond diagnosis, ERG also helps us make referral decisions. Traditionally, we base referral on disease severity and presence or absence of DME as identified using structural tests. But careful consideration of functional abnormalities is important too. Functional tests can offer clear guidance, provided an objective measure like ERG is used. In fact, functional loss alone (provided it's measured objectively) may be sufficient reason to increase exam frequency or make a referral.

## There are other functional measures that can be used in DR management. What makes ERG stand out?

**Dr. Earley:** First, measuring visual acuity alone is not an appropriate functional measure when managing diabetic eye disease. On the other hand, ERG offers a direct reading of retinal health by measuring the functioning of the retina.

**Dr. Rodman:** Having an awareness of the functional health of a diabetes patient is so helpful. ERG measures both retina cell stress and, in some units, pupil light response as well. This powerful combination provides a superior progression risk assessment.

**Dr. Ferrucci:** Functional tools like ERG can provide clear answers and allow us to confidently make clinical decisions. Newer devices are also non-invasive and entirely objective. The RETeval device even provides a simple score that indicates whether or not a diabetes patient is in trouble.

## How is the RETeval device different compared to other ERG technologies?

**Dr. Ferrucci:** The RETeval device by LKC Technologies is the only FDA-cleared, portable, battery-operated, non-mydratric ERG testing instrument on the market in the US. It has skin rather than corneal electrodes, adjusts for pupil size in real time, and doesn't require dilation.

**Dr. Rodman:** The RETeval is unique in that it offers a DR Assessment Protocol that provides a superior risk assessment for progression. As diabetic patients worsen into moderate and severe nonproliferative disease, it may become challenging to determine the best time to refer to a retinal specialist. With the RETeval DR Assessment, you simply check the score. A score of 23.5 or higher indicates an 11-fold risk of requiring intervention within 3 years.<sup>1</sup>

**Dr. Earley:** In an assessment of RETeval's ability to evaluate diabetic retinopathy, the advantages included earlier detection of retinal dysfunction, lower investment costs, and less required subjective photo-reading knowledge compared to traditionally-used imaging techniques. In short, the test allows for earlier detection of retinal dysfunction at a lower cost and with less knowledge than is required with traditional imaging.<sup>3</sup>

## Many optometric practices are struggling with staffing shortages that make adding more tests challenging. Is implementing the RETeval device practical in offices that are already stretched thin?

**Dr. Rodman:** Grading diabetic retinopathy is not easy or fast, but the ERG component is the exception. This is one part of the exam that's simple and can easily be delegated.

**Dr. Earley:** A technician can perform a RETeval exam in both eyes within minutes,<sup>3</sup> and patients don't get frustrated because it's completely objective. It's also great for the doctor because the device provides immediate results.

**Dr. Ferrucci:** By adding the DR Score to the chart, I have an excellent baseline for future visits, which saves time while providing straightforward documentation that all the pieces of the clinical and coding puzzle fit together appropriately.

<sup>1</sup>Brigell, M.G., et al. (2020). *Translational Vision Science & Technology*, 9(9), 40-40.

<sup>2</sup>Al-Otaibi, H., et al. (2017). *Translational Vision Science & Technology*, 6(3), 3-3.

<sup>3</sup>Zeng, Y., et al. (2019). *British Journal of Ophthalmology*, 103, 1747-1752.

Sponsored by



# FEATURES

REVIEW OF OPTOMETRY • Vol. 160, No. 5 • May 15, 2023

## 24TH ANNUAL DRY EYE REPORT

### 48 Assessing Eyelid Health in Dry Eye Patients

We dive into the role abnormalities and meibomian gland dysfunction play in development and progression.

*By Katherine Sanford, OD*

### 54 How Contact Lenses Contribute to Dry Eye

Learn about their impact on the fragile structure of the tear film, which patients are at greatest risk and the options available to alleviate symptoms.

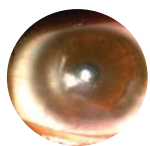*By Melanie Frogozo, OD*

### 62 Keeping an Eye Out for Lacrimal Gland Abnormalities

Understanding how these issues present and their potential implications is critical for prompt treatment and positive patient outcomes.

*By Ashley Kay Maglione, OD  
and Kelly Malloy, OD*

— EARN 2 CE CREDITS



### 34 Pediatric Exams Made Easy

Make a big impact with our smaller patients and take the time to address their visual needs.

*By Daniel Press, OD, and Kelly Cohen, OD*



### 42 When Psych Issues Manifest in Your Patient

How to properly handle mental health conditions, such as depression, abuse and post-traumatic stress disorder, that may arise during an exam.

*By Dennis Pardo, OD*



IVERIC  
BIO



# REFRAME THE FUTURE OF GEOGRAPHIC ATROPHY

The future of geographic atrophy (GA) is evolving right before our eyes—now is the time to rethink our approach to care.

Together, we can optimize imaging modalities to detect earlier, improve GA management, and offer new hope to patients.

SEE **GA** DIFFERENTLY

In partnership with the eye care community, Iveric Bio is providing resources to help you and your patients prepare for the future of GA.



To learn more, scan here or visit [seeGAdifferently.com/reframe](https://seeGAdifferently.com/reframe)

# DEPARTMENTS

REVIEW OF OPTOMETRY • MAY 15, 2023



VISIT US ON SOCIAL MEDIA

Facebook: revoptom

Twitter: revoptom

Instagram: revoptom

LinkedIn: company/review-of-optometry

4

## NEWS REVIEW

Clinical, legislative and practice updates.

18

## OUTLOOK

### It Don't Come Easy

Dry eye patients who want to reduce their symptoms need to take at least some action of their own instead of expecting you to solve it all.

**Jack Persico, Editor-in-Chief**

20

## THROUGH MY EYES

### Innovations, Part Two

These products are making an impact in eyecare.

**Paul M. Karpecki, OD**

22

## CHAIRSIDE

### Put Your Foot Down

Arguably the most important organ, your feet deserve all the care in the world.

**Montgomery Vickers, OD**

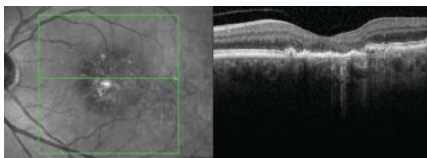
24

## CLINICAL QUANDARIES

### Give It a Shot

A new treatment for early dry AMD can slow lesion progression.

**Paul C. Ajamian, OD**



26

## THE ESSENTIALS

### Vascular Variations

Brush up on the fundamental differences between arteries, veins and capillaries.

**Bisant A. Labib, OD**

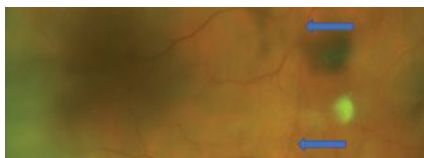
31

## YOU BE THE JUDGE

### Lurking in the Shadows

Would you refer for supplemental testing under these circumstances?

**Jerome Sherman, OD, and Sherry Bass, OD**



72

## OCULAR SURFACE REVIEW

### Drink Up

Hydrating the whole body—not just the eyes—is key to improving the ocular surface.

**Paul M. Karpecki, OD**

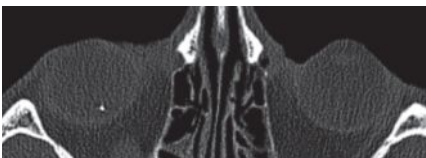76

## URGENT CARE

### Tiny Red Flag, Big Issue

An external injury nearly disguised an intraocular foreign body.

**Alison Bozung, OD**



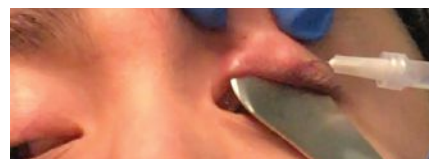78

## ADVANCED PROCEDURES

### Lose that Lump

Intralesional injection can help patients who want a less invasive option for treating their chalazion.

**Blair Lonsberry, OD, MS, MEd**



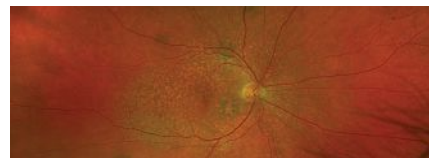
82

## RETINA QUIZ

### Spot the Problem

A photoshoot gone wrong led to this patient's condition.

**Rami Aboumourad, OD, and Joshua Black, OD**



86

## SURGICAL MINUTE

### More MIGS on the Way

Two new implants are bound to make a significant impact for your glaucoma patients.

**Derek N. Cunningham, OD, and Walter O. Whitley, OD, MBA**

90

## DIAGNOSTIC QUIZ

### Seeing Both Side of It

Is this patient's ocular asymmetry a cause for concern? What is the appropriate course of action?

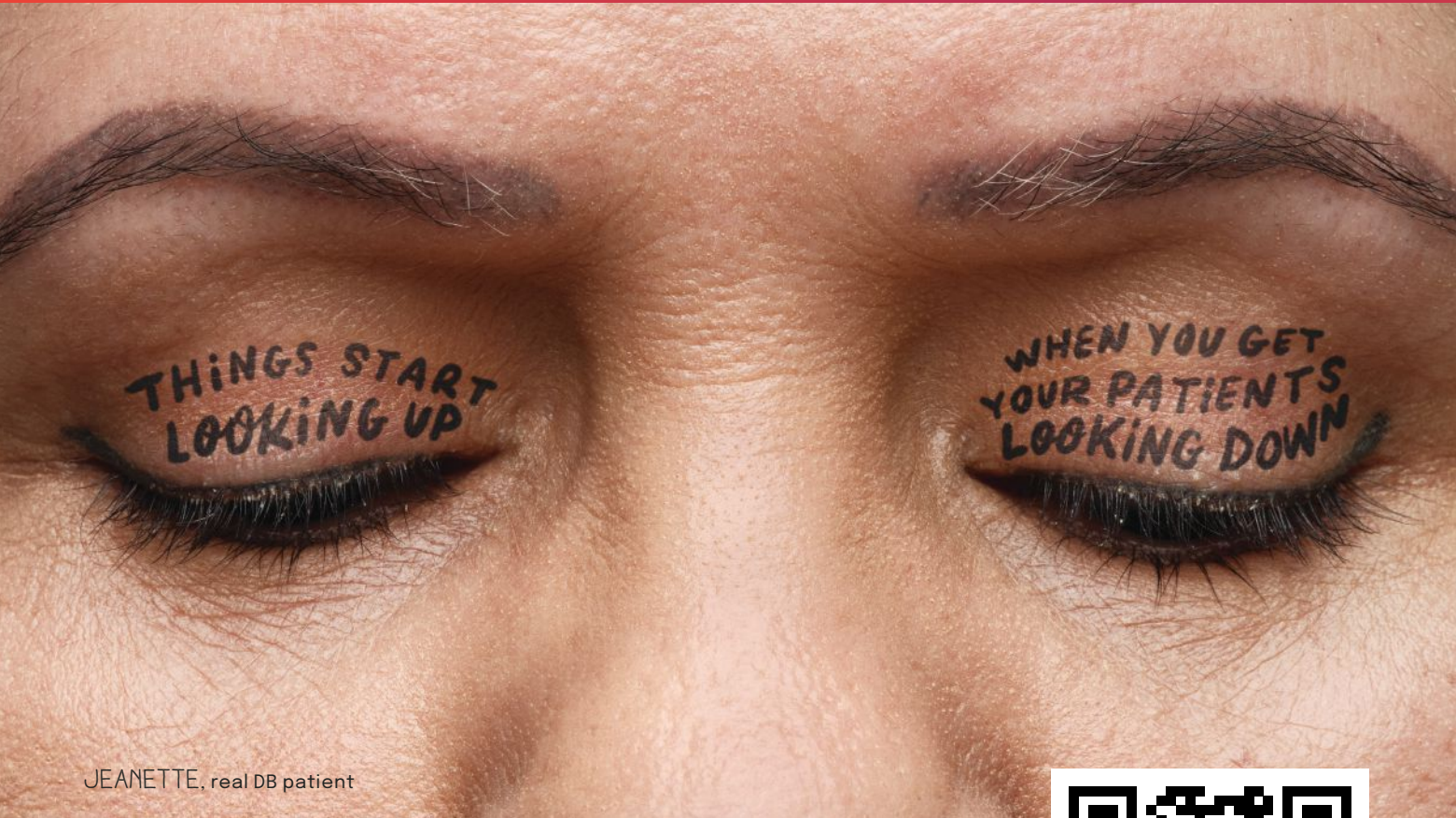**Andrew S. Gurwood, OD**

REVIEW OF OPTOMETRY (ISSN 0147-7633) IS PUBLISHED MONTHLY, 12 TIMES A YEAR BY JOBSON MEDICAL INFORMATION LLC, 395 HUDSON STREET, 3RD FLOOR FLOOR, NEW YORK, NY 10014. PERIODICALS POSTAGE PAID AT NEW YORK, NY AND ADDITIONAL MAILING OFFICES. POSTMASTER: SEND ADDRESS CHANGES TO REVIEW OF OPTOMETRY, PO BOX 81, CONGERS, NY 10920-0081. SUBSCRIPTION PRICES: US: ONE YEAR \$56; TWO YEARS \$97, CANADA: ONE YEAR \$88, TWO YEARS \$160, INT'L: ONE YEAR \$209, TWO YEARS \$299. FOR SUBSCRIPTION INFORMATION CALL TOLL-FREE (877) 529-1746 (USA); OUTSIDE USA, CALL (845) 267-3065. OR EMAIL US AT REVOPOTOMETRY@CAMBEYWEST.COM. PUBLICATIONS MAIL AGREEMENT NO: 40612608. CANADA RETURNS TO BE SENT TO BLEUCHIP INTERNATIONAL, P.O. BOX 25542, LONDON, ON N6C 6B2.

# Keep an eye out for the root cause of blepharitis.

*Demodex* mites are the cause of chronic inflammation and associated with two-thirds of blepharitis cases.<sup>1,2</sup>

*Demodex* blepharitis (DB) is an important part of eyelid health.<sup>3,4</sup>



JEANETTE, real DB patient

SEE THE SIGNS OF DB FOR YOURSELF

LOOK *at the* LIDS.COM



@LookAtTheLids



 TARSUS

**References:** **1.** Gao YY, Di Pascuale MA, Li W, et al. High prevalence of *Demodex* in eyelashes with cylindrical dandruff. *Invest Ophthalmol Vis Sci.* 2005;46(9):3089-3094. **2.** Trattler W, Karpecki P, Rapoport Y, et al. The prevalence of *Demodex* blepharitis in US eye care clinic patients as determined by collarettes: a pathognomonic sign. *Clin Ophthalmol.* 2022;16:1153-1164. **3.** Aumond S, Bitton E. The eyelash follicle features and anomalies: a review. *J Optom.* 2018;11(4):211-222. **4.** Fromstein SR, Harthan JS, Patel J, Opitz DL. *Demodex* blepharitis: clinical perspectives. *Clin Optom (Auckl).* 2018;10:57-63.

EDITOR-IN-CHIEF

**JACK PERSICO**  
(610) 492-1006 • jpersico@jobson.com

SENIOR EDITOR

**JULIE SHANNON**  
(610) 492-1005 • jshannon@jobson.com

SENIOR ASSOCIATE EDITOR

**CATHERINE MANTHORP**  
(610) 492-1043 • cmanthorp@jobson.com

SENIOR ASSOCIATE EDITOR

**MARK DE LEON**  
(610) 492-1021 • mdeleon@jobson.com

ASSOCIATE EDITOR

**LEANNE SPIEGLE**  
(610) 492-1026 • lspiegle@jobson.com

ASSOCIATE EDITOR

**RACHEL RITA**  
(610) 492-1000 • rrita@jobson.com

SENIOR SPECIAL PROJECTS MANAGER

**JILL GALLAGHER**  
(610) 492-1037 • jgallagher@jobson.com

SENIOR ART DIRECTOR

**JARED ARAUJO**  
jaraujo@jobson.com

GRAPHIC DESIGNER

**LYNNE O'CONNOR**  
lyoconnor@jobson.com

DIRECTOR OF CE ADMINISTRATION

**REGINA COMBS**  
(212) 274-7160 • rcombs@jobson.com

**Clinical Editors**

Chief Clinical Editor • Paul M. Karpecki, OD

Associate Clinical Editors

Joseph P. Shovlin, OD, Christine W. Sindt, OD

Clinical & Education Conference Advisor

Paul M. Karpecki, OD

Case Reports Coordinator • Andrew S. Gurwood, OD

**Columnists**

*Advanced Procedures* – Nate Lighthizer, OD

*Chairside* – Montgomery Vickers, OD

*Clinical Quandaries* – Paul C. Ajamian, OD

*Cornea and Contact Lens Q+A* – Joseph P. Shovlin, OD

*Diagnostic Quiz* – Andrew S. Gurwood, OD

*The Essentials* – Bisant A. Labib, OD

*Focus on Refraction* – Marc Taub, OD, Pamela Schnell, OD

*Glaucoma Grand Rounds* – James L. Fanelli, OD

*Ocular Surface Review* – Paul M. Karpecki, OD

*Retina Quiz* – Mark T. Dunbar, OD

*Surgical Minute* – Derek Cunningham, OD, Walter Whitley, OD

*Therapeutic Review* – Jessica Steen, OD

*Through My Eyes* – Paul M. Karpecki, OD

*Urgent Care* – Alison Bozung, OD

*You Be The Judge* – Jerome Sherman, OD, Sherry Bass, OD

**Editorial Offices**

19 Campus Blvd., Suite 101 • Newtown Square, PA 19073

Jobson Medical Information/WebMD

395 Hudson Street, 3rd Floor, New York, NY 10014

Subscription inquiries: (877) 529-1746

Continuing Education inquiries: (800) 825-4696

Printed in USA



BY JACK PERSICO  
EDITOR-IN-CHIEF  
**OUTLOOK**

## It Don't Come Easy

*Dry eye patients who want to reduce their symptoms need to take at least some action of their own instead of expecting you to solve it all.*

**W**e've just started to access a treasure trove of new insights into dry eye's modifiable risk factors now that the Tear Film and Ocular Surface Society has shared the key findings from its forthcoming report, "A Lifestyle Epidemic: Ocular Surface Disease." A walk-through of the conclusions by the TFOS Lifestyle Workshop, released in early May, begins to show the overwhelming scope of the problem.

It's no wonder dry eye is so pervasive: so are its catalysts. Influences as diverse as make-up wear, medication use, digital screens, dietary choices, environmental exposure and the rise of COVID are just a few that get called out by TFOS for attention and, when possible, remediation.

You can find our summary of the initial TFOS release of highlights on our website. We'll delve even more deeply into this prodigious work after publication of all eight subcommittee reports in *The Ocular Surface* journal.

Like the society's last tentpole release, the 2017 TFOS DEWS II report, this new one is anticipated to have far-reaching implications on the practice of eye care aimed at the betterment of ocular surface health.

If you'll allow me to boil down hundreds of pages of sophisticated analysis and a three-year collaborative effort by many of the top minds in eye care into a single phrase, the lesson of the report is: "It don't come easy." (That's right, a Ringo Starr song from 1971. Just go with it, I'm old.)

There's a tendency for the public to sometimes view the fulfillment of their medical needs through the same lens as consumer goods and services,

where innovations are continuously simplifying and enriching our lives. In an era when we have instant access to so many solutions to our needs and desires, it can be hard to make the mental adjustment to a mindset of taking personal responsibility for our health and wellbeing. In too many ways, we've become allergic to effort.

Against those headwinds, optometrists are going to struggle to communicate the TFOS Lifestyle Report's implications to their patients—because it puts the onus on *their* shoulders. Some of the biggest dry eye catalysts in a patient's day-to-day life are unavoidable, like digital device use and the environmental surroundings in which they live and work. It would be unrealistic to expect most people to decrease screen use, for instance, or suddenly move to a less harsh climate.

So, as you process the latest TFOS recommendations, look first for the low-hanging fruit. Recommend simple modifications to sleep and dietary habits instead of wholesale changes, teach a make-up regimen that allows personal expression but isn't oblivious to the vulnerability of the eyes, have conversations about optimizing screen viewing instead of giving a lecture about reducing device use outright, encourage efforts to create better (or, hey, *any*) diligence toward proper contact lens hygiene, and so on. If people start seeing results, they'll be motivated to try some of the harder lifestyle changes that can make a substantive difference.

Sustainable ocular surface health may not come easy, but patients can get there if they're willing to listen—to you and to Ringo. ■

START WITH OCULAR SURFACE PROTECTION  
**ON THE PATH TO  
RESTORATION**



**ACELLFX**   
Acellular Amniotic Membrane

Amniotic membrane image not to scale, enhanced to show detail.

AcellFX is a human amniotic membrane that provides a protective environment for repair of the cornea and conjunctiva,\* allowing re-cellularization to occur and the ocular surface to return to a healthier state<sup>1-3</sup>

Find out more about the amniotic membrane made specifically for eye care professionals at **AcellFX.com**

**CPT CODE 65778:**  
**Placement of amniotic membrane on the ocular surface without sutures**



**References:** 1. Walkden A. Amniotic membrane transplantation in ophthalmology: an updated perspective. *Clin Ophthalmol.* 2020;14:2057-2072. 2. Craig JP, Nichols KK, Akpek EK, et al. TFOS DEWS II definition and classification report. *Ocul Surf.* 2017;15(3):276-283. 3. Jones L, Downie LE, Korb D, et al. TFOS DEWS II management and therapy report. *Ocul Surf.* 2017;15(3):575-628.

\*There are no specific FDA indications for the product.

This information does not guarantee payment and is not legal advice.

It is the provider's responsibility to check for proper coding and billing.

Before use, please refer to Information for Use (IFU) package insert.



BY PAUL M. KARPECKI, OD  
CHIEF CLINICAL EDITOR

## THROUGH MY EYES

# Innovations, Part Two

*These products are making an impact in the eyecare world.*

Last month I talked about the new eyecare products available today, but there were too many to list in one column. Here, I'll discuss the rest of the lesser-known but just as important treatments that help improve outcomes and disease diagnosis for conditions such as dry eye and glaucoma, as well as augmented reality technology that's helping patients improve their vision. Let's dive into part two of these impressive innovations.

## Quad and Triple Simple Drops

One of the first patients I saw in my current clinic was a friend's grandfather who had advanced glaucoma. He was on three different drops and presented with pressures of 30mm Hg and 31mm Hg. He used his drops at the wrong times; for example, he was taking PGA in the morning. After performing SLT, I ordered the Quad and Triple preservative-free drops from Imprimis. The Quad, dosed QHS, contains timolol, brimonidine, dorzolamide and latanoprost, and the Triple, dosed in the morning, contains timolol, brimonidine and dorzolamide.

This patient's pressure currently runs between 11mm Hg and 13mm Hg, and with only two bottles he has no issue remembering which drop to use when.

## Low-level Laser Therapy (LLLT)

This intervention directly treats the meibomian glands, triggering an endogenous heating of the eyelids through cell adenosine triphosphate production that is maintained for over

24 minutes. For that reason, LLLT works extremely well on hordeola, chalazia and meibomian gland dysfunction. When combined with intense pulsed light, it can have a greater effect on the telangiectatic vessels, evaporative dry eye and even blepharitis.



**Eyedaptic's glasses enhance vision for those with low vision diseases such as AMD and diabetic retinopathy.**

## Eyedaptic

These augmented reality glasses have been shown to improve functional vision in patients with macular scarring from conditions such as advanced age-related macular degeneration and Stargardt's disease. The technology involves enhancing the image to take advantage of the healthy retinal tissue and is adaptive to the user's vision, habits and environment. Patients quickly adapt, gaining numerous lines of vision and the ability to recognize faces, significantly increase reading speed, functionality and quality of life.

## Vital Tears

For years, obtaining serum tears for patients with aqueous-deficient dry eye, keratoconjunctivitis sicca, neurotrophic keratopathy and limbal stem cell deficiency was fraught with

hassles sorting out fulfillment issues with apothecaries, tissue banks and compounding pharmacies. It never seemed authenticated until Vital Tears emerged. Simply prescribe the concentration (most conditions require 20% serum) and the company takes it from there. Phlebotomists meet patients at their home or place of work and create the drops for patients to administer on a regular basis. It's seamless, sterile and effective.

## iTear100

This FDA-approved device from Olympic Ophthalmics uses focused oscillatory energy to activate the external nasal nerve from the outside of the nose. The result of placing the iTear100 on the outside crease of the nose for 30 seconds on each side is basal tear production from the meibomian glands, goblet cells and lacrimal glands. The energy level, frequency and tip design were optimized through extensive clinical trials to maximize stimulation of the external nasal nerve safely and comfortably.

## Form Fit Hydrogel Canalicular Plug/Absorbable Lacrimal Plug

The form fit canalicular plug for dry eye from Oasis Medical is made of a soft hydrogel material and inserted in the punctae. Once it makes contact with tears, it slowly increases in size by three times. The plug can easily be flushed out if necessary, but is designed to remain in place.

If you require a dissolvable plug, the soft plug extended duration can be placed in the punctae and remain for approximately 180 days. Be sure to purchase extended duration plug forceps (Bruder Healthcare), which secure the plug without damaging it for easy implantation. ■

### About Dr. Karpecki


**Dr. Karpecki** is the director of Cornea and External Disease for Kentucky Eye Institute, associate professor at the Kentucky College of Optometry and medical director for the Dry Eye Institutes of Kentucky and Indiana. He is the Chief Clinical Editor for *Review of Optometry* and chair of the New Technologies & Treatments conferences. A fixture in optometric clinical education, he consults for a wide array of ophthalmic companies, including ones discussed in this article. Dr. Karpecki's full disclosure list can be found in the online version of this article at [www.reviewofoptometry.com](http://www.reviewofoptometry.com).

# Your Complete Resource.

MERCHANDISING · SPACE PLANNING · DESIGN · SEATING · LIGHTING · OPTICAL ART · & MORE



DRY EYE + MED SPA



ARCHITECTURE · SPACE PLANNING · FRAME DISPLAYS · DISPENSING FURNITURE

EXAM LANES · LIGHTING · SEATING · OPTICAL ART · & MORE



START TODAY!

**EYEDESIGNS**  
CUSTOM INTERIORS + FURNITURE *group*  
800-346-8890 · www.eyedesigns.com



# Put Your Foot Down

*Arguably the most important organ, your feet deserve all the care in the world if they're going to carry you around it.*

**O**ne biological organ may be more important than any other if you want to have a long and happy career in optometry. This topic is never ever covered in optometry school. This topic is never ever covered in optometric CE. This topic has never even been covered in the most wonderful publication in the history of our profession. That's right... this one!

The organ in question is, obviously, your feet.

Feet are very, very important to optometry. We spend a lot of time standing and walking. Our feet take a beating. The patient's feet take a beating, too, as we drag them from room to room puffing the dreaded air at them and flashing bright lights. Which is better, foot number one or foot number two? Both hurt.

Growing up in the beautiful hills of West Virginia—how majestic and how grand—my brothers and I got a new pair of sneakers, which we called tennis shoes, although we never played tennis, every time basketball season rolled around: high-top Chuck Taylors or green-soled Bob Cousy's. At Christmas, we cracked open the Sears catalogue and ordered comfy, rubber-soled chukka boots. For church, we were allowed fake leather dress shoes. Summer flip flops were next.

No wonder our feet are all jacked up now.

When I got married in 1980, Renee somehow convinced me my feet were important and started me on the road of buying good quality footwear. I

could not believe that a pair of shoes could cost more than \$10 or \$15. Really? That's crazy! No, it's not.

Optometrists are on our feet all day, and we ignore them at our own peril. Here are my Top Three Optometric Foot Tips:

1. Wear good shoes that cost more than \$10 or \$15. I have loved switching to scrubs, with thanks to COVID, allowing me to feel free to wear the most comfy and supportive shoes that (my wife's) money can buy. This also meant I bought too many shoes that turned out not to be that comfy or supportive after all. Darn it.

Oh, well, that's why they invented eBay, a.k.a. my retirement plan.

2. Get pedicures. This is a secret that those with XX chromosomes have kept to themselves for years as those with XY chromosomes suffered. I try to get a pedicure as often as I want to, which means as often as my wife permits. As a long-distance runner (given up with pleasure 45 years ago) up and down the mountains of West Virginia, my feet (knees, back, etc.) are a mess, and an

occasional pedicure gives me a great excuse to throw money at something that maybe helps. Kinda like a pizza and beer kinda helps.

3. Lose a couple of pounds. If you are having more problems than your patients nuzzling up to the slit lamp, take it as a sign.

Now that I have freely delivered to you the above-mentioned incredible foot advice, let's discuss the real reason I write about this important subject.


Simple. My feet hurt. As a young fellow, I was a serious long-distance runner. Well, truthfully, that's what I tell people. In fact, my definition of "serious long-distance runner" includes my three- to seven-mile slow jogs every day up and down the mountains and hollows (pronounced "hollers") of West Virginia from the age of 15 to around 34. Why did I stop then? Well, my wife kindly reminded me that we had children to raise, and I was never home... working all day and running well into the evening.

My current impressive girth is a proud symbol of my becoming a better husband and parent.

So basically, I jacked my feet up every day for nearly 20 years. Mobility, like vision, is often taken for granted.

I am doing all I can to help my feet survive.

I don't jog five miles now, but we all sure do wander hundreds of steps per day in the office, don't we? I don't plan to let plantar fasciitis be the reason I finally retire someday. I would rather it be something cool like "The Beatles need me." ■



**About Dr. Vickers**

**Dr. Vickers** received his optometry degree from the Pennsylvania College of Optometry in 1979 and was clinical director at Vision Associates in St. Albans, WV, for 36 years. He is now in private practice in Dallas, where he continues to practice full-scope optometry. He has no financial interests to disclose.



From the makers of the #1-prescribed dry eye brand in Europe\*

## Covering the spectrum of

# Dry Eye Relief

iVIZIA® lubricant eye drops deliver a unique combination of lasting relief and ocular surface protection in a preservative-free formulation.

- Advanced formulation for patients with dry eye offers a combination of povidone (active), hyaluronic acid (HA), and trehalose
- HA and trehalose increased tear film thickness for up to 240 minutes
- Proprietary, multi-dose preservative-free (MDPF) bottle and preservative-free formulation
- Safe for use with contact lenses†



**Recommend iVIZIA and request samples by visiting [iVIZIA.com/ECP](https://www.ivizia.com/ECP).**

Scan here.

\*Prescription market data, Sept. 2021 – S01K without cyclosporine.

†To limit blurriness when using contact lenses, remove contacts, apply drops, then insert contacts.

Copyright ©2023 Théa | Similasan | All Rights Reserved. | 0141-AP-02 01.2023

Made by  
**Théa**  
let's open our eyes

Distributed by  
**Similasan**  
EVIDENCE-BASED EYE CARE



EDITED BY PAUL C. AJAMIAN, OD

## CLINICAL QUANDARIES

# Give It a Shot

*A new treatment for early dry AMD can slow lesion progression. This elevates the role of the OD in disease detection.*

**Q** I have a patient with early geographic atrophy (GA) of the retinal pigment epithelium (RPE) that I have followed for years and told her there is no treatment. I am hearing that a new medication has been approved, and would like to know when to refer and what to expect when comanaging?

**A** On February 17, Syfovre (pegcetacoplan), manufactured by Apellis Pharmaceuticals, was approved for treating GA, an advanced form of dry AMD. This is a progressive condition, but clinical trials found an intravitreal dose of Syfovre could slow the growth of GA lesions by an average of 20% when taken monthly, and 17.5% when taken every other month.<sup>1</sup> The approval was based on positive results from the Phase III OAKS and DERBY studies at 24 months.<sup>2</sup>

“The key to reaping the benefits of this medication is early use,” says Tanuj P. Banker, MD, a vitreoretinal surgeon at Center For Sight in Sarasota, FL. Once the drug became available, he performed the first injection in Southwest Florida. “For patients with GA who qualify for treatment, it

is our goal to start treatment as soon as possible, as there has not been a treatment option available for those suffering from this form of macular degeneration,” Dr. Banker adds.

Patients will benefit most with long-term use of the medication. They will need injection treatments every 25 to 60 days, but Dr. Banker assures that the procedure uses multiple rounds of topical anesthetic and only lasts a few seconds. The patient may experience mild pressure during the injection; however, there is typically no significant discomfort.

### Positive Effects

Apellis has warned that Syfovre could cause episodes of ocular inflammation elevated pressure, endophthalmitis, retinal detachment or development of wet AMD. In particular, there is a 12% chance of progression to wet AMD on a monthly injection schedule and a 7% chance with a bimonthly treatment plan.<sup>3</sup>

Dr. Banker’s patients have tolerated Syfovre very well thus far. His practice is currently using the medication only in patients with Medicare with a secondary insurance. However, he believes coverage will expand in the coming months to take care of those who are commercially insured.

### Tackling GA Together: Comanagement is Critical

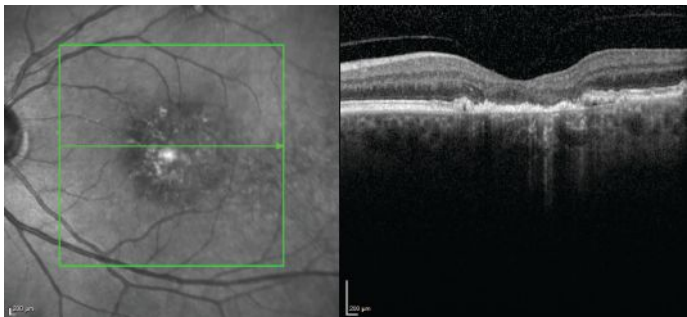
As retina specialists start using Syfovre in hopes of mitigating the retinal cell loss and visual impairment that often develops with dry AMD, they will heavily rely upon optometrists to educate and refer the proper patients. Dr. Banker believes that recognizing the early stages of the disease is critical before advanced atrophy sets in and that optometrists could closely monitor patients taking Syfovre throughout their treatment regimen.

“As you are following these patients, remember that GA correlates poorly with VA. In the study the average VA was 20/63, but treating patients with good vision provides the most potential long-term benefits,” Dr. Banker explains. “Other retina specialists are less conservative and inject patients with much better vision.”

He also recommends OCT and fundus autofluorescence (FAF) as excellent tools for detecting GA.

“On OCT, I tell my referring physicians to look specifically for (1) diffuse loss of RPE and photoreceptors, (2) loss of the external limiting membrane and (3) increased choroidal transmission,” he says. “On FAF, look for depigmented hypoautofluorescent areas.”

In addition to OCT, Dr. Banker finds red-free photography very helpful for high-risk markers to identify potential intermediate AMD patients who are at risk. ■



**Diffuse loss of photoreceptors and RPE can be useful to detect GA.**

1. What is Syfovre? Syfovre. [syfovre.com/about-syfovre/what-is-syfovre](https://www.syfovre.com/about-syfovre/what-is-syfovre). Accessed March 26, 2023.

2. FDA approves Syfovre (pegcetacoplan injection) as first and only treatment for geographic atrophy (GA), a leading cause of blindness [press release]. Apellis. [investors.apellis.com/news-releases/news-release-details/fda-approves-syfovre-tm-pegcetacoplan-injection-first-and-only](https://investors.apellis.com/news-releases/news-release-details/fda-approves-syfovre-tm-pegcetacoplan-injection-first-and-only). February 17, 2023. Accessed March 26, 2023.

3. Side effects. Syfovre. [syfovre.com/about-syfovre/side-effects](https://www.syfovre.com/about-syfovre/side-effects). Accessed March 26, 2023.

About  
Dr. Ajamian

Dr. Ajamian is board certified by the American Board of Optometry and serves as Center Director of Omni Eye Services of Atlanta. He is vice president of the Georgia State Board of Optometry and general CE chairman of SECO International. He has no financial interests to disclose.

# icare

For better perception



## iCare DRsplus

# A higher standard in retinal imaging



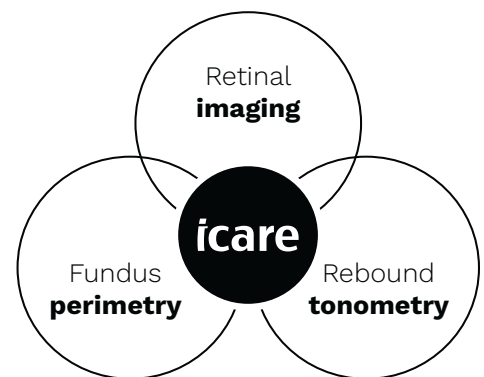
Confocal Technology allows scanning through media opacities resulting in high resolution images through pupils as small as 2.5 mm



TrueColor using white LED light providing detail rich retinal images



Fully automated operation resulting in fast acquisition time and enhanced patient comfort



**Get to know iCare for  
imaging and perimetry.**



Discover the next level of eye care  
with our full line of devices.

Scan or visit [www.icare-world.com/USA](http://www.icare-world.com/USA)





BY BISANT A. LABIB, OD

## THE ESSENTIALS

# Vascular Variations

*Brush up on the fundamental differences between arteries, veins and capillaries and how each feeds the eye.*

**T**he body's peripheral vascular network is composed of arteries, veins and capillaries, each of which exhibit unique characteristics contributing to their function. The eye, like every other organ in the body, contains both an arterial and a venous system in order to adequately deliver oxygen and nutrients to and from ocular structures and eliminate waste. Regardless of which organ is discussed, all blood vessels throughout the body possess similar anatomical properties. Identifying their distinguishing anatomical features makes us one step closer to under-

standing the various ocular pathologies that arise as a result of systemic vascular disorders.<sup>1,2</sup>

### Complementary Function

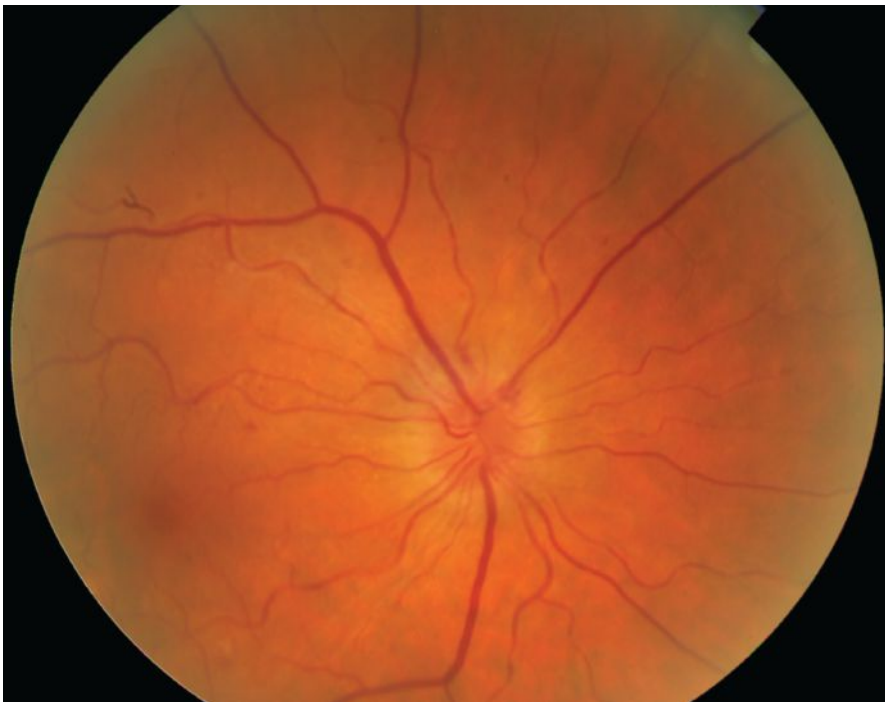Arteries, or arterioles, are responsible for transporting blood to the eye for nourishment. This occurs through the internal carotid artery, which extends from the heart and branches into the ophthalmic artery. The ophthalmic artery further subdivides into the internal carotid artery, the long and short posterior ciliary arteries and the anterior ciliary arteries. This arterial network supplies the various anterior

and posterior ocular structures with oxygen and nutrients. Veins perform the opposite function, in that they return blood from a given structure back to the heart. Venous outflow is mediated by the central retinal vein and vortex veins, which are branches of the superior and inferior ophthalmic veins. They ultimately drain through structures such as the cavernous sinus, pterygoid venous plexus and facial vein.<sup>3</sup> These anatomical connections explain why ocular diseases spread throughout different compartments of the head and neck.

An illustration of arterial function is the case of retinal artery occlusion, where blood is prevented from perfusing the retina due to an obstruction of an artery. As such, the area in which the occluded artery is responsible for perfusing appears whitened and ischemic, due to lack of blood flow. In contrast, if a retinal vein occlusion occurs, blood is prohibited from leaving the retina, and severe hemorrhages form in the area of distribution of the affected vein.

### Divergent Purposes

While arteries and veins share some structural similarities, they also have notable anatomical differences that affect their functions. One of the most significant differences is the thickness and elasticity of their walls. Arteries have thicker, more muscular walls that allow them to withstand the high pressure of blood flow from the heart. Veins, however, have thinner walls with less muscle and are not designed to withstand high pressure. Instead, they have valves that prevent blood from flowing backward. This makes veins particularly sensitive to hematological factors such as hypercoagulability or vasculitides, which are often underlying factors in



**Hypertensive retinopathy causing constriction of retinal arterioles in response to elevated systemic blood pressure and autoregulation.**

About  
Dr. Labib

**Dr. Labib** graduated from Pennsylvania College of Optometry, where she now works as an associate professor. She completed her residency in primary care/ocular disease and is a fellow of the American Academy of Optometry and a diplomate in the Comprehensive Eye Care section. She has no financial interests to disclose.

# The Review News Feed

Continuously updated.  
Clinically focused.

**TABLE 1. BRIEF OVERVIEW OF THE STRUCTURE AND FUNCTION OF BLOOD VESSEL TYPES**

Vessels	Structure	Function
Arteries/arterioles	Thick, muscular walls with smaller lumina to accommodate high blood flow	<ul style="list-style-type: none"> <li>Deliver oxygen and nutrients to tissues</li> <li>Respond to sympathetic stimulation</li> </ul>
Veins	Thinner walls with valves to prevent blood backflow and larger lumen	<ul style="list-style-type: none"> <li>Drain blood back to heart</li> <li>Respond more to parasympathetic stimulation</li> </ul>
Capillaries	Thin, single layer of endothelial cells	<ul style="list-style-type: none"> <li>Transport oxygen and nutrients to cells</li> <li>Remove waste</li> </ul>

retinal vein occlusions.<sup>4,5</sup>

Another major difference between arteries and veins is their size. Arteries have smaller lumina than veins, which means that blood flows through them more quickly. This is because arteries are designed to transport oxygenated blood away from the heart to the rest of the body at high pressure. In contrast, veins have larger lumina and slower blood flow, as they are designed to return deoxygenated blood from the body back to the heart. When observing retinal vasculature, for example, a normal ratio between arteries and veins is 2:3; this ratio is often reduced in systemic disease processes that affect vessel attenuation.<sup>5</sup>

Arteries and veins also respond differently to neurotransmitters and hormones. Arteries are more responsive to sympathetic nervous system stimulation, which can cause them to constrict and increase blood pressure. Veins are more responsive to parasympathetic nervous system stimulation, which can cause them to dilate and decrease blood pressure. This distinction is due to the differences in their smooth muscle cell composition. These features are clinically relevant in that arteries are more susceptible to elevations in blood pressure, causing them to initially constrict in response and manifest as the arteriolar narrowing that is often observed in any stage of hypertensive retinopathy.<sup>4,7</sup>

In addition to arterioles and veins, there are choriocapillaris and capillaries located in the retina. Due to the high metabolic demands of retinal

cells, these tiny blood vessels provide additional oxygen and nutrients. The choriocapillaris supplies the outer retinal layers in particular, whereas the retinal capillaries supply the inner portion. These capillaries are also responsible for removing waste products from the retina and transporting them into the bloodstream for elimination from the body. The structure of a capillary is a thin, single layer of endothelial cells, allowing diffusion of nutrients. Capillary function is implicated in many disease processes that lead to nonperfusion or growth of neovascularization.<sup>2,6</sup>

Arteries, veins and capillaries have a number of anatomical differences that affect their function. These include differences in wall thickness, structure, oxygenation status and responsiveness to neurotransmitters and hormones. Understanding these differences is important for understanding how blood circulates through the eye and how it is susceptible to systemic vascular diseases. ■

- Mercadante AA, Raja A. Anatomy, arteries. In: StatPearls [Internet]. Treasure Island (FL): StatPearls Publishing. 2023. Updated March 6, 2023.
- Tucker WD, Arora Y, Mahajan K. Anatomy, blood vessels. In: StatPearls [Internet]. Treasure Island (FL): StatPearls Publishing. 2022. Updated August 8, 2022.
- Kiel JW. The ocular circulation. San Rafael (CA): Morgan & Claypool Life Sciences. 2010.
- Tortora GJ, Derrickson BH. Principles of anatomy and physiology. John Wiley & Sons. 2017.
- Boron WF, Boulpaep EL. Medical physiology. Elsevier Saunders. 2016.
- Hall JE, Hall, ME. Textbook of medical physiology. Elsevier Saunders. 2015.
- Widmaier EP, Raff H, Strang KT. Vander's human physiology: the mechanisms of body function. McGraw-Hill. 2014.

April 26, 2023  
**Study Finds One in Four GA Patients Convert to Wet AMD Within Three Years**  
In addition, better baseline visual acuity was indicative of more lines of eventual vision loss.

With 15 news stories published every week,

April 25, 2023  
**Heart Attack, Glaucoma Share Modifiable Risk Factors**  
The prevalence of myocardial infarction was higher among patients with ocular conditions.

all on matters of clinical relevance to optometric practice,

April 24, 2023  
**Oily Skin Increases Risk of Dry Eye**  
Study shows the tear film may be disrupted by fatty acids and low pH from adjacent non-ocular lipids, which can lead to irritation.

there's no better place to stay informed about the latest research

April 21, 2023  
**Hypertension During Pregnancy Increases Refractive Errors in Offspring**  
All forms of ametropia showed higher incidence in large study. Potential mechanisms include elevated antiangiogenic factors and increased oxidative stress.

that can improve the care you provide to your patients.

FIND OUT FIRST AT  
[reviewofoptometry.com/news](http://reviewofoptometry.com/news)  
Stories post every weekday.

Washington Scope Bill Awaiting Governor's Signature  
SSS 5389 would authorize ODs to perform several advanced procedures—excluding lasers—and expand prescribing rights.  
April 26, 2023

Autoimmune Disease Associated with Thinning Corneas, Dry Eye  
Researchers believe that conditions of this type should be considered in patients who have superior epithelial thinning and reduced tear production.  
April 26, 2023

Study Finds One in Four GA Patients Convert to Wet AMD Within Three Years  
In addition, better baseline visual acuity was indicative of more lines of eventual vision loss.  
April 26, 2023

Survey Confirms Myopia Management is on the Rise  
Simple refractive error correction without intervention remains most common, but mitigation efforts are increasingly popular. Still holding back some practitioners are product availability and cost.  
April 25, 2023

Heart Attack, Glaucoma Share Modifiable Risk Factors  
The prevalence of myocardial infarction was higher among patients with vascular conditions.  
April 25, 2023

Use of Several Systemic Meds Associated with Worse DED  
Aspirin, steroids and vitamin D3 increased disease severity, while diuretic use decreased meibomian gland abnormality.  
April 25, 2023

Myopia, Glaucoma Combo Leads to Greater VF Loss  
Even more worrisome, patients with both conditions experience more paracentral scotomas than others.  
April 24, 2023

Blood Thinners Worsen Submacular Hemorrhage Secondary to AMD  
Vitamin K antagonists have a more detrimental impact than oral anticoagulants, study shows.  
April 24, 2023

Oily Skin Increases Risk of Dry Eye  
Study shows the tear film may be disrupted by fatty acids and low pH from adjacent non-ocular lipids, which can lead to irritation and pain.  
April 24, 2023

Corneal Tomography Increasingly Unreliable in Advanced Keratoconus  
The thinner the cornea, the worse the repeatability of the scans. These findings may impact clinicians' assessment of CKL candidacy.  
April 21, 2023

Obesity, High Alcohol Intake, Skipping Meals Increases Glaucoma Risk  
Moderation in each of these lifestyle factors, including exercise, is recommended.  
April 21, 2023

Hypertension During Pregnancy Increases Refractive Errors in Offspring  
All forms of ametropia showed higher incidence in a large study. Potential mechanisms include elevated antiangiogenic factors and increased oxidative stress.  
April 21, 2023

Corneal Development Influenced by Birth Weight  
Adults born smaller than average at term had steeper corneas.  
April 20, 2023

PVD Follow-up Within Six Weeks or Less is Crucial, Study Finds  
Be vigilant for delayed retinal break or detachment during this period in all patients. High-risk eyes should be seen sooner and more frequently.

When Selecting a Prescription  
Dry Eye Treatment

**DON'T**

**MAKE  
HER  
WAIT.**



Not an actual patient.

### **Indication**

Xiidra® (lifitegrast ophthalmic solution) 5% is indicated for the treatment of signs and symptoms of dry eye disease (DED).

### **Important Safety Information**

- Xiidra is contraindicated in patients with known hypersensitivity to lifitegrast or to any of the other ingredients.
- In clinical trials, the most common adverse reactions reported in 5-25% of patients were instillation site irritation, dysgeusia and reduced visual acuity. Other adverse reactions reported in 1% to 5% of the patients were blurred vision, conjunctival hyperemia, eye irritation, headache, increased lacrimation, eye discharge, eye discomfort, eye pruritus and sinusitis.
- To avoid the potential for eye injury or contamination of the solution, patients should not touch the tip of the single-use container to their eye or to any surface.



**Novartis Pharmaceuticals Corporation**  
East Hanover, New Jersey 07936-1080



**CHOOSE XIIDRA**  
Because lasting symptom  
relief can start as early as  
**2 WEEKS<sup>1\*</sup>**



Access to Xiidra is  
better than ever<sup>2</sup>

\*Xiidra reduced symptoms of eye dryness at 2 weeks (based on Eye Dryness Score compared to vehicle) in 2 out of 4 studies, with improvements observed at 6 and 12 weeks in all 4 studies.<sup>1†</sup>

### Important Safety Information (cont)

- Contact lenses should be removed prior to the administration of Xiidra and may be reinserted 15 minutes following administration.
- Safety and efficacy in pediatric patients below the age of 17 years have not been established.

**Please see Brief Summary of Important Product Information on adjacent page.**

#### <sup>†</sup>Pivotal trial data

The safety and efficacy of Xiidra were assessed in four 12-week, randomized, multicenter, double-masked, vehicle-controlled studies (N=2133). Patients were dosed twice daily. **Use of artificial tears was not allowed during the studies.** The study end points included assessment of signs (based on Inferior fluorescein Corneal Staining Score [ICSS] on a scale of 0-4) and symptoms (based on patient-reported Eye Dryness Score [EDS] on a visual analogue scale of 0-100).<sup>1</sup>

Effects on symptoms of dry eye disease: A larger reduction in EDS favoring Xiidra was observed in all studies at day 42 and day 84. Xiidra reduced symptoms of eye dryness at 2 weeks (based on EDS) compared to vehicle in 2 out of 4 clinical trials.<sup>1</sup>

Effects on signs of dry eye disease: At day 84, a larger reduction in ICSS favoring Xiidra was observed in 3 of the 4 studies.<sup>1</sup>

**References:** **1.** Xiidra [package insert]. East Hanover, NJ: Novartis Pharmaceuticals Corp. **2.** Data on file. DRF Fingertip Formulary<sup>®</sup> Novartis Pharmaceuticals Corp; July 2022.

**XIIDRA, the XIIDRA logo and ii are registered trademarks of Novartis AG.**

## **Xiidra® (lifitegrast ophthalmic solution), for topical ophthalmic use**

**Initial U.S. Approval: 2016**

**BRIEF SUMMARY: Please see package insert for full prescribing information.**

### **1 INDICATIONS AND USAGE**

Xiidra® (lifitegrast ophthalmic solution) 5% is indicated for the treatment of the signs and symptoms of dry eye disease (DED).

### **4 CONTRAINDICATIONS**

Xiidra is contraindicated in patients with known hypersensitivity to lifitegrast or to any of the other ingredients in the formulation [see *Adverse Reactions (6.2)*].

### **6 ADVERSE REACTIONS**

The following serious adverse reactions are described elsewhere in the labeling:

- Hypersensitivity [see *Contraindications (4)*]

#### **6.1 Clinical Trials Experience**

Because clinical trials are conducted under widely varying conditions, adverse reaction rates observed in clinical trials of a drug cannot be directly compared to rates in the clinical trials of another drug and may not reflect the rates observed in practice.

In five clinical trials of DED conducted with lifitegrast ophthalmic solution, 1401 patients received at least one dose of lifitegrast (1287 of which received lifitegrast 5%). The majority of patients (84%) had less than or equal to 3 months of treatment exposure. One hundred-seventy patients were exposed to lifitegrast for approximately 12 months. The majority of the treated patients were female (77%). The most common adverse reactions reported in 5%-25% of patients were instillation-site irritation, dysgeusia, and reduced visual acuity.

Other adverse reactions reported in 1%-5% of the patients were blurred vision, conjunctival hyperemia, eye irritation, headache, increased lacrimation, eye discharge, eye discomfort, eye pruritus, and sinusitis.

#### **6.2 Postmarketing Experience**

The following adverse reactions have been identified during post-approval use of Xiidra. Because these reactions are reported voluntarily from a population of uncertain size, it is not always possible to reliably estimate their frequency or establish a causal relationship to drug exposure.

Rare serious cases of hypersensitivity, including anaphylactic reaction, bronchospasm, respiratory distress, pharyngeal edema, swollen tongue, urticaria, allergic conjunctivitis, dyspnea, angioedema, and allergic dermatitis have been reported. Eye swelling and rash have also been reported [see *Contraindications (4)*].

### **8 USE IN SPECIFIC POPULATIONS**

#### **8.1 Pregnancy**

##### Risk Summary

There are no available data on Xiidra use in pregnant women to inform any drug-associated risks. Intravenous (IV) administration of lifitegrast to pregnant rats, from pre-mating through gestation day 17, did not produce

teratogenicity at clinically relevant systemic exposures. Intravenous administration of lifitegrast to pregnant rabbits during organogenesis produced an increased incidence of omphalocele at the lowest dose tested, 3 mg/kg/day (400-fold the human plasma exposure at the recommended human ophthalmic dose [RHOD], based on the area under the curve [AUC] level). Since human systemic exposure to lifitegrast following ocular administration of Xiidra at the RHOD is low, the applicability of animal findings to the risk of Xiidra use in humans during pregnancy is unclear [see *Clinical Pharmacology (12.3) in the full prescribing information*].

##### Data

##### Animal Data

Lifitegrast administered daily by IV injection to rats, from pre-mating through gestation day 17, caused an increase in mean pre-implantation loss and an increased incidence of several minor skeletal anomalies at 30 mg/kg/day, representing 5,400-fold the human plasma exposure at the RHOD of Xiidra, based on AUC. No teratogenicity was observed in the rat at 10 mg/kg/day (460-fold the human plasma exposure at the RHOD, based on AUC). In the rabbit, an increased incidence of omphalocele was observed at the lowest dose tested, 3 mg/kg/day (400-fold the human plasma exposure at the RHOD, based on AUC), when administered by IV injection daily from gestation days 7 through 19. A fetal no observed adverse effect level (NOAEL) was not identified in the rabbit.

#### **8.2 Lactation**

##### Risk Summary

There are no data on the presence of lifitegrast in human milk, the effects on the breastfed infant, or the effects on milk production. However, systemic exposure to lifitegrast from ocular administration is low [see *Clinical Pharmacology (12.3) in the full prescribing information*]. The developmental and health benefits of breastfeeding should be considered, along with the mother's clinical need for Xiidra and any potential adverse effects on the breastfed child from Xiidra.

#### **8.4 Pediatric Use**

Safety and efficacy in pediatric patients below the age of 17 years have not been established.

#### **8.5 Geriatric Use**

No overall differences in safety or effectiveness have been observed between elderly and younger adult patients.

Distributed by:  
Novartis Pharmaceuticals Corporation  
One Health Plaza  
East Hanover, NJ 07936  
T2020-87





BY JEROME SHERMAN, OD, AND SHERRY BASS, OD

**YOU BE THE JUDGE**

# Lurking in the Shadows

*Would you refer for supplemental testing under these circumstances?*

**A** 45-year-old male with his own construction business presented for a visit complaining of blurry vision when reading. He was examined and corrected to 20/20 with a pair of reading glasses. He had been followed in the practice for over 14 years and was status-post LASIK, although he still wore contact lenses for best correction. The patient did not want to be dilated so Optos photos were taken. The practitioner noted posterior vitreous detachment (PVD) in both eyes, but no other retinal abnormalities.

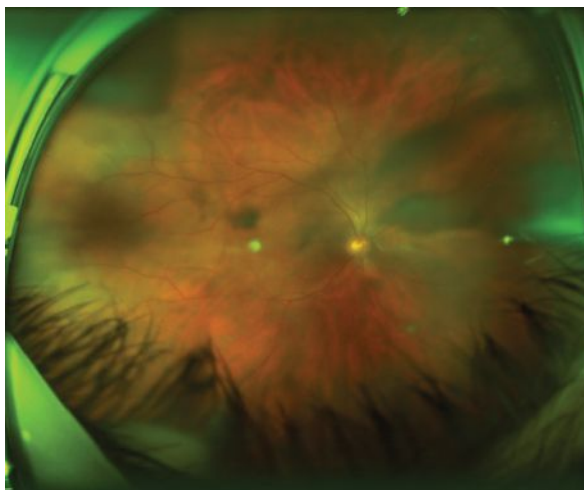
For the next year, the patient was followed for three visits related to contact lenses and dry eye secondary to the LASIK. At each visit the patient deferred dilation. Six months after his last follow-up, he presented with a different complaint. The practitioner wrote “patient started seeing a shadow in the left side of the right eye [...] it is there when looking to the right, not as much looking straight or to the left.” The practitioner noted “no flashes, history of floaters.”

## Testing

The practitioner noted uncorrected visual acuities of 20/40 in each eye but not corrected acuities. No anterior segment abnormalities were noted. Biomicroscopy was performed

but the practitioner did not note the presence or absence of pigmented cells in the vitreous, the so-called “Schafer’s sign,” which can indicate the possible presence of a retinal tear. The patient was dilated with 1.0% tropicamide and 2.5% phenylephrine. The dilated fundus examination was performed, and the practitioner noted “new and large vitreal strands OD.”

Because of the specificity of the patient’s new complaint about the shadow being more obvious when he looked to the right, the practitioner was more suspicious of a problem in the temporal retina of the right eye (nasal field). Several Optos photographs were taken using steering with emphasis on the temporal retina (*Figure 1*).



**Fig. 1.** Optos photo of the right eye, with two cortical spokes nasally and a wide one superior temporal.

## Diagnosis

The patient was diagnosed with a shadow “due to new vitreal strands and a new PVD.” The practitioner wrote “reviewed retinal detachment, the signs and symptoms today...” No return appointment was scheduled.

## Follow-Up

The patient returned one month later with a complaint that he woke up with reduced vision in the right eye only that morning and that he had had flashes and floaters, which had started two days before. Visual acuity in the right eye was hand motion. Examination revealed a large retinal detachment (*Figure 2*). The patient was immediately referred to a retina specialist, who diagnosed a superior-temporal tear and a large bullous macula-off retinal detachment. The detachment was repaired one day later. One month later, the visual acuity had improved to 20/80, and the patient reported that the vision was still distorted. Two months later, the

patient reported that images appeared “bent” in the center of vision in his right eye when performing daily tasks.

The patient was noted to have developed a 2+ nuclear and posterior subcapsular cataract (secondary to the vitrectomy performed during the retinal repair) and a new epiretinal membrane with macular edema. A membrane peel was recommended, as was cataract extraction.

Five months later, the best-corrected visual acuity remained 20/60 in the right eye. The patient initiated a

**About Drs. Sherman and Bass**

**Dr. Sherman** is a Distinguished Teaching Professor at the SUNY State College of Optometry and editor-in-chief of *Retina Revealed* at [www.retinarevealed.com](http://www.retinarevealed.com). During his 52 years at SUNY, Dr. Sherman has published about 750 various manuscripts. He has also served as an expert witness in 400 malpractice cases, approximately equally split between plaintiff and defendant. Dr. Sherman has received support for *Retina Revealed* from Carl Zeiss Meditec, MacuHealth and Konan. **Dr. Bass** is a Distinguished Teaching Professor at the SUNY College of Optometry and is an attending in the Retina Clinic of the University Eye Center. She has served as an expert witness in a significant number of malpractice cases, the majority in support of the defendant. She serves as a consultant for ProQR Therapeutics.

malpractice lawsuit against the practitioner for failure to diagnose the retinal detachment when he initially complained of the shadow and for failure to refer him to a retina specialist for prompt treatment.

The patient claimed that the failure to detect the detachment on the day he was experiencing the shadow delayed treatment, resulting in a macula-off retinal detachment and two surgeries, which resulted in irreversible reduction of vision in the right eye with distortions in his vision that he claimed made it difficult to perform his construction work.

### You Be the Judge

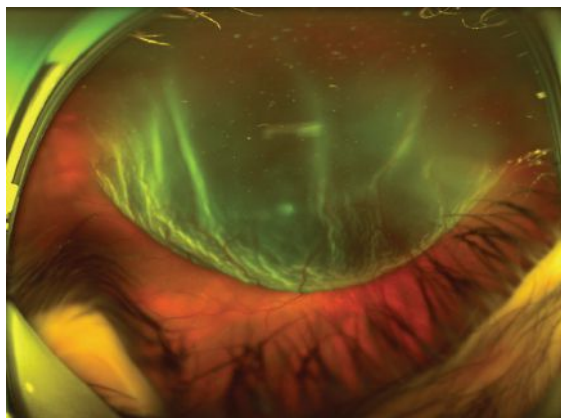
Was there a retinal detachment when the patient initially complained of a shadow? The practitioner did not see a detachment but took photos. Do you see a retinal detachment in *Figure 1*?

If the practitioner did not see a detachment, should the patient have been referred to a retina specialist for supplementary testing procedures, such as scleral depression, three-mirror contact lens examination and/or B-scan ultrasonography? Should the practitioner have made a follow-up appointment after the initial examination?

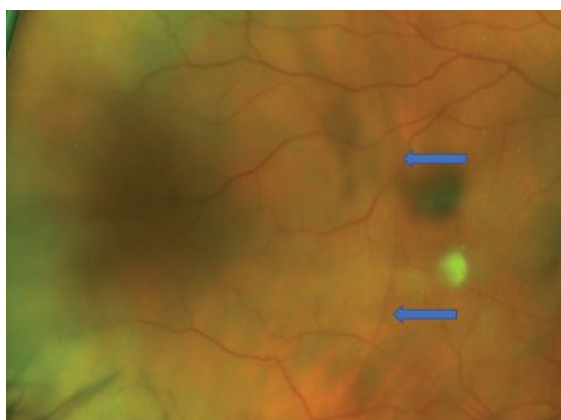
### Our Opinion

This case is unusual because, unbeknownst to both of us, we were each asked to opine for opposite sides. One of us (JS) opined that the practitioner performed a standard-of-care examination and that, based on the photos, a detachment was not evident. In addition, the superior-temporal detachment that ultimately occurred was not evident in the earlier photographs. The other one of us (SB) opined that, on careful examination, a possible shallow retinal detachment was visible in the temporal retina of the right eye in the photographs (*Figure 3*).

Although the average practitioner may not have appreciated the possible shallow retinal detachment on the photograph, standard of care would have dictated that the practitioner refer the patient for supplemental testing and examination, especially considering the patient's chief complaint of a shadow that was more visible when he looked to the right. He did not complain of a floater or say



**Fig. 2.** The retinal specialist described a superior-temporal macula-off retinal detachment.



**Fig. 3.** Magnified view of the temporal retina OD one month prior to large retinal detachment. It reveals a circular border, possibly denoting a shallow retinal detachment (blue arrows).

that the shadow moved across his vision.

### Litigation Outcome

The case was settled for an undisclosed amount.

### Discussion

In the “Clinical Practice Guidelines of the American Optometric Association for the Care of the Patient with Retinal Detachment and Peripheral Vitreoretinal Disease,” it is stated that supplemental testing may be indicated to rule out a tear and/or detachment.<sup>1</sup> The practitioner did not perform any supplemental testing, and the average practitioner under like circumstances would likely not have performed supplemental procedures since many ODs are not able to perform a three-mirror contact lens exam and scleral depression proficiently and most do not have access to B-scan ultrasonography.

The practitioner in their deposition admitted to referring retina patients occasionally to a retina specialist, hence this patient could have been referred for supplemental testing. History is also an important consideration.

In a recent retrospective cohort study of 8,305 patients with acute-onset PVD, results revealed that variables that are associated with greater risk of retinal tear and rhegmatogenous retinal detachment following acute-onset PVD included blurred vision, male sex, age younger than 60, prior keratorefractive surgery and prior cataract surgery.<sup>2</sup>

The patient in this case had prior LASIK and was a 45-year-old male. Symptoms of sudden onset of floaters, flashes and/or a field defect (or shadow) in the periphery that does not move should make the practitioner more suspicious of retinal detachment. In this case, the patient presented with the complaint of a shadow that appeared

NOTE: This article is one of a series based on actual lawsuits in which the author served as an expert witness or rendered an expert opinion. These cases are factual, but some details have been altered to preserve confidentiality. The article represents the authors' opinion of acceptable standards of care and does not give legal or medical advice. Laws, standards and the outcome of cases can vary from place to place. Others' opinions may differ; we welcome yours.

more obvious in certain fields of gaze and did not move.

The important lesson to be learned here is that any patient complaining of a shadow that is different from a floater should be referred for additional testing to rule out a tear or retinal detachment. Widefield photography is not a substitute for a thorough dilated fundus examination, and it is unfortunate this patient deferred dilation for a number of visits. Widefield photography is an adjunctive procedure that can indicate the presence of a tear and/or retinal detachment.

In this case, the dilated fundus examination performed by the practitioner did not reveal a tear or a detachment, but the photos they took, one of us (SB) believes, tell a different story.

In contrast, JS argued in his deposition that “a like practitioner under like circumstances” would not have noticed the very subtle curvilinear line in the Optos image that may not be an RD but rather a retinoschisis not requiring treatment (*Figure 3*). Furthermore, the detachment was in the far superotemporal quadrant a full month later and arguably had nothing to do with the curvilinear line in the posterior pole, which may or may not be a shallow RD. Even if the patient were referred, the superior-temporal tear that resulted in the bullous RD may not have been present a month earlier.

SB argued that a tear was likely evident at the initial visit, causing the shallow retinal detachment, and that a second, more superior tear could have developed later. If the patient were referred for supplemental testing, such as B-scan ultrasonography, a shallow retinal detachment could have been differentiated from a retinoschisis. JS further argued that there is no proof that the curvilinear line was a shallow RD, and, in the US, there is only one retina specialist per 100,000 population and referrals should be reserved for patients who are believed to require advanced intervention and not for every floater, flash or shadow. SB opined that the practitioner, in their deposition, claimed that a retina specialist was available and patients were referred all the time when needed, but the practitioner did not believe it was needed.

Both of us agreed that the shallow possible retinal detachment would likely not have been appreciated by the average practitioner, but we differ on the follow-up and the need for a referral.

The bottom line in this case is that the patient suffered a macula-off retinal detachment one month later in the same eye that might have been prevented had the practitioner referred the patient to a retina specialist sooner rather than later even if the practitioner did not detect a detachment.

But, you be the judge: did the clinician meet the standard of care practiced by “like practitioners under like circumstances?” We welcome your opinion as well. ■

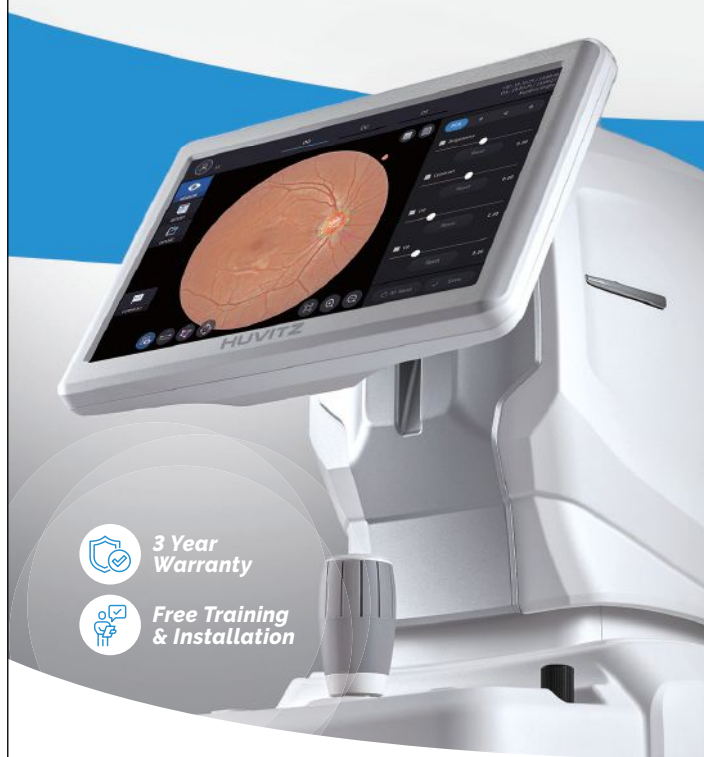1. Optometric clinical practice guideline: care of the patient with retinal detachment and peripheral vitreoretinal disease. American Optometric Association. [www.aoa.org/aoa/documents/practice%20management/clinical%20guidelines/consensusbased%20guidelines/care%20of%20patient%20with%20retinal%20detachment%20and%20peripheral%20vitreoretinal%20disease.pdf](http://www.aoa.org/aoa/documents/practice%20management/clinical%20guidelines/consensusbased%20guidelines/care%20of%20patient%20with%20retinal%20detachment%20and%20peripheral%20vitreoretinal%20disease.pdf). Accessed March 27, 2023.

2. Seider MI, Conell C, Melles RB. Complications of acute posterior vitreous detachment. *Ophthalmology*. 2022;129(1):67-72.

# High quality, automatic digital retinal imaging.

Experience the  
**HFC-1 Non-Mydriatic Fundus Camera.**

- Quick and stable auto tracking and auto shooting
- Adjust fixation target position
- Enhanced Visualization Technology captures fine pathological variation
- Full color digital image acquisition



**COBURN TECHNOLOGIES** 

1-800-COBURN-1  
See our full line of products at [coburntechnologies.com](http://coburntechnologies.com)

**OPTOMETRY'S MEETING**  
visit booth #405

# PEDIATRIC EXAMS MADE EASY

Make a big impact with our smaller patients and take the time to address their visual needs.



BY DANIEL PRESS, OD,  
AND KELLY COHEN, OD  
PARK RIDGE, IL

Many people have seen a video of a young child seeing their parents' faces clearly after putting on glasses for the first time. That first look of surprise is often followed with a smile that could melt your heart. That specific opportunity is few and far between, but there are still many other rewarding aspects of serving our pediatric patients. An eye examination of your adult patients should differ from the eye examination of your pediatric patients. Visual skills and ability are developed during childhood, and the eye examination should mirror the developmental ability of the child. Remember that the chronologic age of a child may not equal their developmental ability. As children grow, so do their visual skills and demands.

The eye examination of a toddler should be distinguished from the visual assessment of a primary school-aged child. Visual skills are built upon the foundation of healthy eyes and adequate visual acuity

(VA), which is where we should start with our infant examinations (*Figure 1*). The first eye examination should take place between six and 12 months of age. If there are no concerns, then the second eye examination should take place at three years of age and then at five years of age and on an annual basis thereafter. This article will discuss how to conduct an easy pediatric exam and relay findings with parents.

## Not Just Small Adults

Keep in mind that the visual demands of a child are different from those for adults. Children learn through tactile and motor activities for the first few years of life. Those activities rely more heavily on visual perception and visual motor integration than the ability to see letters on an acuity chart.<sup>1</sup>

When performing eye exams in pediatric patients, it is crucial to evaluate for any presence of disease. With that said, the most common ocular morbidities in childhood are refractive error and strabismus.<sup>2,3</sup> This article will emphasize the vast majority of childhood findings and not disease itself.

Let's consider visual considerations through childhood:

**Infancy to age three.** In early life, children learn through tactile exploration. Most of their visual demands will be within a few feet from their face. Motor development is the foundation for vision development, which then guides increasingly complex motor skills. Adequate binocular vision, accommodation and accurate eye movements are important for children to reach their potential with motor skills and spatial awareness. Refractive findings are relevant when they are amblyogenic or when presenting with a strabismus; otherwise, allow emmetropization to occur and watch patients carefully with borderline refractive findings (*Table 1*).<sup>4</sup> In this age group, it is recommended to attempt to measure VA as a later step in the examination. A sample can be found in "Suggested Exam Flow for the Infant/Toddler."

**Ages three to six.** Much learning should still occur through tactile and motor stimulation, but children in this age group are starting to use their vision and perceptual skills for more reading-based learning purposes.<sup>1</sup> As

### About the authors

Dr. Press practices at Park Ridge Vision and is board-certified in vision development and therapy. He is a fellow of the College of Optometrists in Vision Development and is an advisory board member for Review of Myopia Management. Dr. Press is a paid consultant for Johnson & Johnson Vision. Dr. Cohen practices at Park Ridge Vision. She is a fellow of the American Academy of Optometry, as well as a member of the Illinois Optometric Association, the American Optometric Association and the College of Optometrists in Vision Development. She has no financial disclosures.

**TABLE 1. GUIDELINES FOR PRESCRIBING IN INFANTS/YOUNG CHILDREN**

*Adapted from the American Academy of Ophthalmology<sup>4</sup>*

Condition	Age younger than one	Age one to two	Age two to three	Age three to four
<b>Isometropia</b>				
Myopia	5.00D or more	4.00D or more	3.00D or more	2.50D or more
Hyperopia (no deviation)	6.00D or more	5.00D or more	4.50D or more	3.50D or more
Hyperopia with esotropia	2.00D or more	2.00D or more	1.50D or more	1.50D or more
Astigmatism	3.00D or more	2.50D or more	2.00D or more	1.50D or more
<b>Anisometropia (without strabismus)</b>				
Myopia	4.00D or more	3.00D or more	3.00D or more	2.50D or more
Hyperopia	2.50D or more	2.00D or more	1.50D or more	1.50D or more
Astigmatism	2.50D or more	2.00D or more	2.00D or more	1.50D or more

*Note: These values were generated by consensus and are based solely on professional experience and clinical impressions because there are no scientifically rigorous published data for guidance.*

children enter the classroom, adequate distance and near VA are necessary to meet the expected classroom environmental demands. Assess near vision and binocular status to ensure the child has the visual skills to learn to read in such a pivotal time of their development.

**Ages seven to 14+.** At this point in education, children move from the “learning to read” phase into the “reading to learn” phase. Efficient visual skills aid in the development of reading ability and are an important piece of development for further educational progress. In this age group, subjective findings are typically much easier to collect and best-corrected VA can be more accurately measured. This is often when binocular dysfunctions present with symptoms as the visual demands increase to a level that requires sustained visual efficiency.

### Ask the Right Questions

Most parents are unaware of the link between vision and performance/learning. Their understanding of an eye examination is to determine the need for glasses/contact lenses to aid VA. Many are surprised to hear that there is much more to a com-

prehensive vision examination that evaluates a child’s ability to meet the demands of the classroom. It is our job to probe the parent and child for clues that may warrant an extended visual evaluation.

Here are sample history questions to ask the child’s parent/caregiver:

- **Was the child born full-term?** If not, what was the length of gestation and how much did they weigh

at birth? Children born prematurely with lower birth weight are at an increased risk of developmental delay including visual delays.<sup>5</sup>

- **Did they reach all developmental milestones on time?** Visual problems are more common in children with delayed developmental milestones.<sup>5</sup>

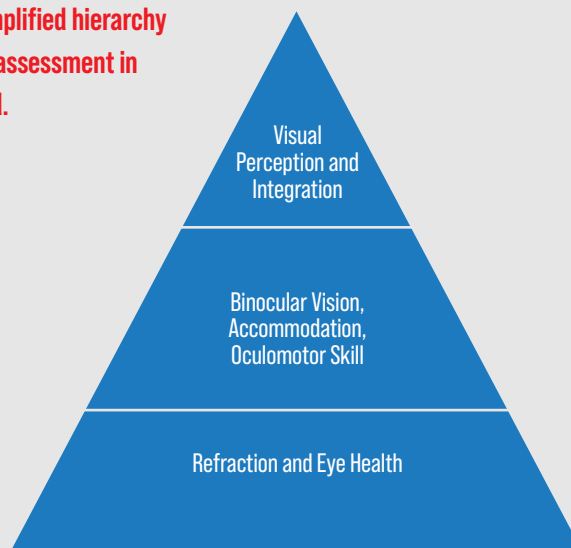
Here are sample performance questions to ask the parent of a school-aged child:

- **Is your child reading at an appropriate age level?** Vision may impact reading skills, and if this question is answered in the affirmative, then consider additional visual testing beyond a routine eye examination.<sup>6</sup>

- **Does your child struggle with reading but excel in other subjects?** Vision problems such as convergence insufficiency, accommodative dysfunction and oculomotor dysfunction tend to cause a struggle in subjects that incorporate a higher reading demand compared with other subjects.

- **Do you feel as though your child is reaching their full potential?** A gap in potential may indicate a visual processing disorder. “A high verbal IQ combined with a performance IQ that is 20 points lower should signal the need for an optometric evaluation,” says Linda Kreger Silverman, PhD.<sup>7</sup>

**Fig. 1. Simplified hierarchy of visual assessment in childhood.**



**Suggested Exam Flow for the Infant/Toddler**

1. Retinoscopy—distance/near.
2. Direct ophthalmoscopy.
3. Binocular status.
4. Pupils.
5. Extraocular muscles, near point of convergence.
6. Stereopsis—Stereo E or PASS.
7. IOP—iCare tonometry.
8. VA—fixation, resistance to occlusions, optokinetic nystagmus, Teller acuity cards.
9. Dilated fundus examination.
10. Cycloplegic retinoscopy.

• **Does your child avoid reading-related tasks?** Visual symptoms may not be present if the child simply avoids extended near point tasks such as reading.

• **Is there a concern or diagnosis of attention deficit hyperactivity disorder?** Attention disorders are more common in children with visual dysfunction.<sup>8</sup>

Here are sample questions to ask the school-aged child:

• **What is your favorite subject in school? What is your least favorite subject?** Children who dislike subjects heavy in reading are more likely to have vision problems compared with students who favor subjects heavy in reading.

• **Do you ever see the words moving on a page when you are trying to read?**

• **Do you ever see two of things when you're looking at them?**

• **Do your eyes or head hurt after looking at something?**

If the history questions suggest that a child has a vision problem, then it is helpful to quantify the symptoms. The Convergence Insufficiency Symptom Survey (CISS) is a 15-item questionnaire that has a 96% sensitivity and 88% specificity at identifying children with convergence insufficiency when using >16 as a cutoff score (Table 2).<sup>9</sup> The CISS also identifies children with disorders other than convergence insufficiency

**TABLE 2. CONVERGENCE INSUFFICIENCY SYMPTOM SURVEY**

Possible Subjective Symptoms	Frequency				
	Never (0)	Infrequently/ not very (1)	Sometimes (2)	Fairly often (3)	Always (4)
1. Do your eyes feel tired when reading or doing close work?					
2. Do your eyes feel uncomfortable when reading or doing close work?					
3. Do you have headaches when reading or doing close work?					
4. Do you feel sleepy when reading or doing close work?					
5. Do you lose concentration when reading or doing close work?					
6. Do you have trouble remembering what you have read?					
7. Do you have double vision when reading or doing close work?					
8. Do you see the words move, jump, swim or appear to float on the page when reading or doing close work?					
9. Do you feel like you read slowly?					
10. Do your eyes ever hurt when reading or doing close work?					
11. Do your eyes ever feel sore when reading or doing close work?					
12. Do you feel a "pulling" feeling around your eyes when reading or doing close work?					
13. Do you notice the words blurring or coming in and out of focus?					
14. Do you lose your place while reading or doing close work?					
15. Do you have to re-read the same line of words when reading?					
Total Score _____	_____x0	_____x1	_____x2	_____x3	_____x4

*Total score of 16 or higher is suggestive of convergence insufficiency*

that interfere with comfortable near visual function.<sup>10</sup>

If a child has an identifiable complaint, ask for the familiar features regarding the symptom such as onset, location, duration, character, aggravating and associated factors, relieving factors, timing and severity of symptoms. If there are asthenopia

complaints in the frontal region of the head that occur more frequently in the afternoon compared with first waking, suspect a vision problem until ruled out by extensive visual testing. If you do not have any findings to explain the child's complaints during the time of the eye examination, then perform additional visual



**Manan Shah, MD**

Eye MD, Bethlehem, GA

After using several different brands of punctal plugs in my practice, **I've found Lacriversa plugs to be the best** in regards to **ease of placement, sizing, retention, efficacy, and patient comfort.**

Furthermore, customer service at Lacriversa has been excellent.”



**Vera180™**

Synthetic absorbable plug provides extended temporary occlusion lasting up to 6 months.



VeraPlug™  
**FlexFit™**

Designed with a flexible outer nose for simple sizing, excellent retention and greater patient comfort.

A FRESH PERSPECTIVE™

[lacriversa.com](http://lacriversa.com) (855) 857-0518

2500 Sandersville Rd · Lexington KY 40511 USA



evaluation or refer to a colleague who does ([locate.covd.org](https://locate.covd.org)). That testing should include a complete binocular and accommodative evaluation and may include a cycloplegic refraction. In the past, the timing of symptoms during the academic week compared with the weekend would be a meaningful history question to differentiate symptoms emanating from a vision problem. With the ubiquitous nature of near point screen use, we are not so quick to dismiss a vision problem when symptoms are equal on school days compared with non-school days.

### Clinical Testing

An excellent starting point for determining what testing is appropriate for pediatric patients can be found in the American

Optometric Association’s evidence-based clinical practice guideline, “Comprehensive Pediatric Eye and Vision Examination.”<sup>10</sup> However, each child brings a unique combination of language development, cognitive function, comfort level and attention in the exam room that may make standardized testing challenging. Keep your testing options open and flexible based on the individual in order to gather enough data to inform your clinical decisions. A helpful strategy is to start with the known testing standard for each exam element and modify accordingly if the child cannot accurately perform or sit for the test.

**Refraction.** For children who may have difficulty with subjective responses, rely on your retinoscope. A computer/laptop in the exam room is very helpful with obtaining retinoscopy findings. Videos of interest are easily accessible through a web search and help to hold a child’s visual atten-



Fig. 2. Near fixation targets.

tion. If you plan on prescribing lenses, it is recommended to trial frame the retinoscopy findings and check VA. In the case of a child who has difficulty with subjective responses, rely on the observable responses to the lenses including the quality of the retinoscopy reflex and any improvement in fixation/visual attention. Due to active accommodation and poor fix-

ation, non-cycloplegic autorefractor measurements are often unreliable. Cycloplegic autorefraction is more reliable than non-cycloplegic findings. It is not recommended to prescribe solely based on autorefractor findings. Whether performed under cycloplegia or not, the results do not elucidate how a child is functioning in their habitual state including the impact of their binocular vision and accommodation.

**Binocular/accommodative/oculomotor.** It is important to have engaging fixation targets for young children. Spinning light wands are an effective fixation target to assess extraocular muscle movement. Light up animal keychains have proven to be effective at drawing a child’s visual attention. Younger children should be engaged in a target of interest while using your thumb to perform the cover test. For the uncooperative

child, binocular status can be estimated via the Hirshberg reflex. Older children should be instructed to look at a 20/30 size VA target (or two lines above best VA) for binocular and accommodative evaluation (*Figure 2*). Minimum recommended testing and expected findings during a “routine” eye examination for the school age child can be found in *Table 3*.

TABLE 3. RECOMMENDED MINIMUM TESTING OF BINOCULAR VISION AND ACCOMMODATION FOR THE SCHOOL-AGED CHILD

Test	Expected Finding
Cover test distance and near	0 to 6pd exophoria
Near point of convergence 20/30 accommodative target	<6cm
Accommodative lag: fused cross cylinder	+0.50D
Negative relative accommodation	±2.50D
Positive relative accommodation	-2.50D




# THE POWER OF COLOR TOPOGRAPHY

With the high-resolution color camera & magnification changer of the OCULUS Keratograph® 5M, the future of corneal topography & dry eye diagnosis for your practice is crystal clear.

Enjoy more efficient diagnoses, improved patient compliance and more successful dry eye management today.

 **OCULUS**<sup>®</sup>  
[www.oculususa.com](http://www.oculususa.com)



**Stereoacuity.**

Stereopsis is an important indicator in the development of normal binocular vision. For preschool-aged children, the Preschool Assessment of Stereopsis with a Smile (PASS) test is recommended for random dot stereoacuity testing. At later ages, perform the Randot stereoacuity test, which offers both global targets which require bifoveal fixation and local stereoacuity measurements.



**Fig. 3. A blue LED owl keychain can be useful for corneal assessment.**



**Anterior segment.** For broad assessment in the young child, a 20D lens can be used as a magnifier with a light source, such as a penlight. This can help identify any ocular disease associated with the lids, lashes and conjunctiva, as well as allow gross assessment of the cornea, iris and lens. If fluorescein evaluation of the cornea is warranted, a useful tool is an owl light up keychain that incorporates blue LED lights (*Figure 3*).

**Posterior segment.** Most disease of this area in pediatric patients is found in the posterior pole. If a peripheral evaluation is difficult based on the patient's attention and fixation, getting a clear look at the optic nerve and macula can suffice. A direct ophthalmoscope can be used with a 20D lens to get a full view of the posterior pole. Using the lens as you would for indirect ophthalmoscopy, focus the direct ophthalmoscope to the lens by dialing in approximately +3 and tromboning the lens until it's full of light. With enough practice, this can be done on undilated pupils as well.

**VA.** Measuring acuity in preschool aged children can be accomplished using HOTV or LEA symbols. If a child has a hard time recognizing a shape or is shy in the exam room, a matching chart can be given. VA does not only test for the threshold of eyesight. Performing these tests requires visual skills including fixation, attention and discrimination. In younger children, we typically reach the threshold of visual perception before reaching the threshold of VA. Therefore, it is not uncommon nor an indication of any deficit when the child does not see 20/20 VA.

Qualitatively, pay attention to whether the child is resistant to occlusion of one eye. If a child gets upset or quiet with occlusion or if they actively try to duck away

from occlusion, it may be an indicator that the uncovered eye has reduced acuity. While this is not a standard measurement of VA, it is an important clinical finding that should be noted in the patient's chart. If the VA cannot be measured but the patient has an amblyogenic factor, this simple observation may guide your treatment plan.

**Make a Diagnosis**

The most common visual diagnoses outside of ametropia are amblyopia and non-strabismic binocular vision problems. There have been exciting new developments in amblyopia treatment of late. Amblyopia is found in 3% of pediatric patients and carries with it a significant public health concern. Amblyopia is a neurodevelopmental disorder in which binocular visual development is disrupted. While this often manifests with monocular findings, such as reduced VA, oculomotor abnormalities and reduced accommodative function in the delayed eye, amblyopia is a binocular vision problem at its core.

Restoring binocular function is emerging as an alternative to the centuries-old treatment of monocular patching. Monocular patching has poor compliance, reported at 40% along with a 25% recurrence of amblyopia once patching is discontinued.<sup>11</sup> Patching does not address the neurologic basis of the disease. The modernized approach to anisometropic amblyopia management is to minimize binocular competition to maximize overall visual performance.<sup>12</sup>

The Sanet-Vergara treatment protocol recommends prescribing the combination of refractive powers that provides the best binocular response through Worth 4 Dot and stereopsis testing at distance and near. This often means reducing the refractive power of the amblyogenic eye to allow better sensory fusion and, thus, treats the amblyopia through the binocular system. If occlusion therapy is necessary, translucent occlusion with Bangerter filters may be used. This will facilitate binocular integration and allows for adjustments in the degree of occlusion as the condition improves.<sup>13</sup> The standard of care in the treatment of amblyopia will likely shift from monocular patching to binocular treatment in the near future.

Non-strabismic binocular vision problems include disorders of vergence and accommodation. The most common of these diagnoses is convergence insufficiency (CI).<sup>14</sup> The textbook definition of CI includes exophoria at near greater than distance, receded near point of convergence (NPC) and reduced positive fusional vergence (PFV). There are patients who “do not read the textbook” and present with CI without all of the classically expected findings. Patients may have esophoria at near and CI as they have a receded near point of convergence.<sup>15</sup>

The patient with CI may be able to pass the NPC test on the first attempt only to show a receded NPC on

repeat testing. The patient with CI may have a normal NPC but reduced PFV findings. It may be difficult to properly diagnose CI within the time constraints of an annual eye examination. Therefore, it is crucial to ask about the common signs and symptoms of binocular and accommodative dysfunction during the examination, and if present, schedule or refer the patient for further visual testing.

## Takeaways

Providing comprehensive pediatric vision care is an excellent way to build a practice and is rewarding for both the patient and doctor. Diagnosing road blocks in vision development including ametropia, binocular vision dysfunction, accommodative dysfunction, oculomotor dysfunction, amblyopia and strabismus is an important step for children to receive full-scope care. Treatment may include lenses, prisms and/or optometric vision therapy. Successful treatment of the vision problem, whether in your practice or referred to a colleague, helps the child reach their full potential and creates a lifetime of gratitude for the diagnosing doctor. We are grateful to be in a position to make such a positive impact on the lives of children. ■

1. Oberer N, Gashaj V, Roebbers CM. Executive functions, visual-motor coordination, physical fitness and academic achievement: Longitudinal relations in typically developing children. *Hum Mov Sci.* 2018;58:69-79.
2. Kelkar J, Kelkar A, Thakur P, Jain HH, Kelkar S. The epidemiology and disease pattern of pediatric ocular morbidities in Western India: The National Institute of Ophthalmology Amblyopia StUdy in Indian Paediatric EyeS (NIMBUS) study report 1. *Indian J Ophthalmol* 2023;71(3):941-5.
3. Vitale S, Cotch MF, Sperduto RD. Prevalence of visual impairment in the United States. *JAMA.* 2006;295(18):2158-63.
4. Braverman RS. Types of amblyopia. *American Academy of Ophthalmology.* [www.aao.org/education/disease-review/types-of-amblyopia](http://www.aao.org/education/disease-review/types-of-amblyopia). October 21, 2015. Accessed April 15, 2023.
5. Soleimani F, Zaheri F, Abdi F. Long-term neurodevelopmental outcomes after preterm birth. *Iran Red Crescent Med J.* 2014;16(6):e17965.
6. Quaid P, Simpson T. Association between reading speed, cycloplegic refractive error and oculomotor function in reading disabled children vs. controls. *Graefes Arch Clin Exp Ophthalmol.* 2013;251(1):169-87.
7. Kay K, ed. *Uniquely Gifted: Identifying and Meeting the Needs of Twice Exceptional Learners.* Avocus Publishing; 2000:153-65.
8. Granet DB, Gomi CF, Ventura R, Miller-Scholte A. The relationship between convergence insufficiency and ADHD. *Strabismus.* 2005;13(4):163-8.
9. Borsting EJ, Rouse MW, Mitchell GL, et al.; Convergence Insufficiency Treatment Trial Group. Validity and reliability of the revised convergence insufficiency symptom survey in children aged nine to 18 years. *Optom Vis Sci.* 2003;80(12):832-8.
10. Horan LA, Ticho BH, Khammar AJ, et al. Is the Convergence Insufficiency Symptom Survey Specific for convergence insufficiency? a prospective, randomized study. *Am Orthopt J.* 2015;65:99-103
11. American Optometric Association. Evidence-based clinical practice guideline: comprehensive pediatric eye and vision examination. *Optometric Clinical Practice.* 2020. [www.aao.org/AOA/Documents/Practice%20Management/Clinical%20Guidelines/EBO%20Guidelines/Comprehensive%20Pediatric%20Eye%20and%20Vision%20Exam.pdf](http://www.aao.org/AOA/Documents/Practice%20Management/Clinical%20Guidelines/EBO%20Guidelines/Comprehensive%20Pediatric%20Eye%20and%20Vision%20Exam.pdf). Accessed April 15, 2023.
12. Wynnanski-Jaffe T, Kushner BJ, Moshkovitz A, et al; CureSight Pivotal Trial Group. An eye-tracking-based dichoptic home treatment for amblyopia: a multicenter randomized clinical trial. *Ophthalmology.* 2023;130(3):274-85.
13. Giménez PV, Sanet R, Press L, et al. Management of anisometropic amblyopia: a retrospective study. *Vis Dev Rehabil.* 2023;9(1):32-40.
14. Scheiman M, Kulp MT, Cotter SA, et al. Interventions for convergence insufficiency: a network meta-analysis. *Cochrane Database Syst Rev.* 2020;12(12):CD006768.
15. Rafiq Ghadban, Jennifer M. Martinez, Nancy N. Diehl, Brian G. Mohney, The incidence and clinical characteristics of adult-onset convergence insufficiency. *Ophthalmology.* 2015;122(5):1056-9.



**REGISTRATION OPEN!**  
**EARLY BIRD PRICING: \$225\***



**SEPTEMBER 22–24, 2023**  
**THE WESTIN PHILADELPHIA**  
**PHILADELPHIA, PENNSYLVANIA**

**EARN UP TO 21 CE CREDITS\***

[www.reviewedu.com/nttphiladelphia](http://www.reviewedu.com/nttphiladelphia)



**NOVEMBER 10–12, 2023**  
**GRAND HYATT NASHVILLE**  
**NASHVILLE, TENNESSEE**

**EARN UP TO 21 CE CREDITS\***

[www.reviewedu.com/nttnashville](http://www.reviewedu.com/nttnashville)



For more information and to register, scan the QR code or visit:  
[www.reviewedu.com/ntt2023](http://www.reviewedu.com/ntt2023)



\*Approval pending

\* See websites for details

# WHEN PSYCH ISSUES MANIFEST IN YOUR PATIENT

How to properly handle mental health conditions, such as depression, abuse and post-traumatic stress disorder, that may arise during an exam.



BY DENNIS PARDO, OD  
STRATFORD, CT

It is estimated that more than one in five adults 18 and older in the United States live with a mental illness—nearly 57.8 million, representing 22.8% of all adults—and this increases to nearly 50% for adolescents.<sup>1</sup> Given these staggering statistics, ODs will see psychological issues in the exam chair often, and points to why our role of screening and participation in full-scope care is critical for our patients.

We are not trained psychotherapists, but as primary care physicians (PCPs) for the eye, how do we navigate these issues that manifest in our patients during an exam? As an OD turned psychotherapist, I'm going to help answer this question and provide suggestions to address and defuse psychological issues when they happen.

## Intake Forms

We have medical conditions and the medications that go along with them on our intake forms. It is important that we have a place on the form to

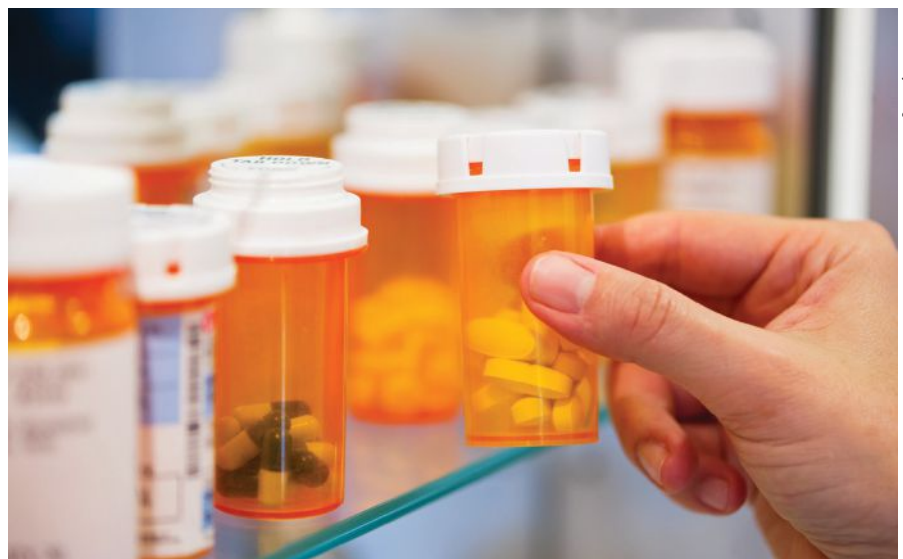

Photo: Getty Images

**Be aware of certain psychotropic medications that can cause ocular side effects.**

write down psychological conditions and the psychotropic medications our patients are taking. As ODs, this gives us a useful snapshot of the mental health conditions our patients have, which can help us anticipate some of the issues that may come up during the exam.

Taking it a step further, we could also have patients fill out short mental health screening tools—GAD-7 for anxiety and PHQ-9 for depres-

sion, as examples—both of which many PCPs use now.

To illustrate this, let's talk about bipolar disorder and one medication our patients may be taking for this condition, lithium. If you have a new patient who lists attention-deficit/hyperactivity disorder (ADHD) on the intake form and takes lithium, what should you be on the lookout for? This medication may cause eye irritation and dry eye during the first

About  
the author

**Dr. Pardo** has over 20 years of optometric experience in clinical practice, teaching, lecturing and medical affairs. He currently runs a private mental health practice, as well as conducts lectures and workshops on a variety of mental health topics. He has no financial interests to disclose.

few weeks of treatment. A contributing factor is that lithium can increase sodium concentration in the tear film. Knowing this can prompt you to check tear film osmolarity and treat the underlying irritation while the patient is adjusting to lithium.<sup>2</sup>

There are other ocular side effects of psychotropic medications, and optometrists should follow patients individuals placed on agents such as this and antidepressants diligently. A standardized approach for monitoring ocular toxicities from these medications and others would be helpful.<sup>2</sup>

### Basic Awareness

So, you have a mental health section on your intake form—now what? Start to recognize the importance of encountering and caring for patients with mental health conditions, the medications that go with them and their ocular side effects. These include:

- Anxiety disorders/depression.
- Phobias.
- Post-traumatic stress disorder (PTSD).
- ADHD.
- Schizophrenia.
- Substance-related and addictive disorders.
- Obsessive-compulsive disorders.
- Abuse in children, the elderly and those with a disability.

While this is not an exhaustive list, basic knowledge of these major conditions will set you up well to navigate psychological issues that may come up. Let's take a look at each of the mental health conditions above and how they may manifest in your exam chair:

#### *Anxiety disorders/depression.*

Research shows that patients with retinitis pigmentosa, keratoconus, Sjögren's syndrome and glaucoma have higher levels of anxiety and/or depression than age-matched controls.<sup>3-6</sup> How does knowing this help us as optometrists? Let's say you have a patient with keratoconus and you are the third OD they have seen because not one has provided a rea-

son for their fluctuating vision loss. They appear nervous, sad and frustrated, and their responses are very short. Knowing that patients with keratoconus can have higher levels of anxiety and depression allows you to anticipate how they might present ahead of time and tailor how you interact with them as a result.

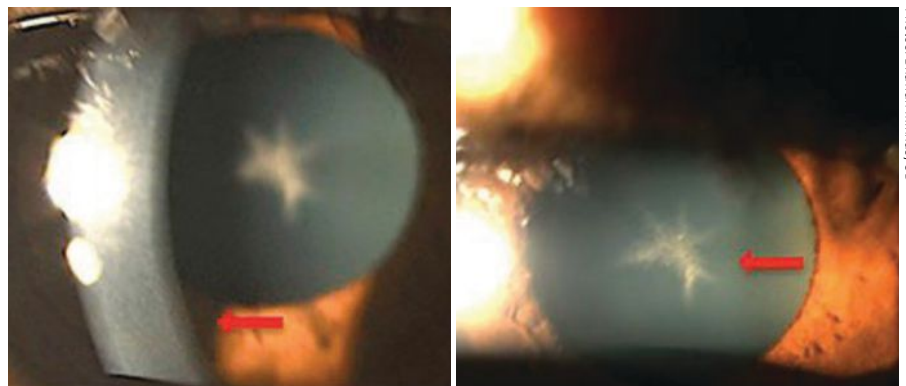Ask more open-ended questions to get them talking more and validate their frustration so they feel heard. Allay their anxiety by answering any questions they have and let them know you will do your best to help them, rather than just jumping into the exam. Yes, this is basic rapport building, but taking a bit more time and care in engaging can go a long way in reducing their anxiety, helping them feel more comfortable with you.

As a psychotherapist at a university counseling center, I had a keratoconus patient referred to me for anxiety and depression by an OD who worked at the same clinic. It turns out the client had suicidal ideation, until they were referred by that OD for corneal crosslinking. Prior to that, the patient had seen several optometrists and ophthalmologists who were not able to help and the patient was severely depressed because they felt unheard and hopeless that their vision would never improve. The OD in this case not only made the

right referral for corneal crosslinking, but may have saved this patient's life by referring for therapy.

**Phobias.** As an optometrist, I had a new patient who told me he had a phobia of being dilated, which I had never heard of at the time. He explained that when doctors tried to dilate him, he'd get extremely anxious and fearful. I asked him if he was willing to try it again—taking it slow—and he agreed. I told him I would start with a drop of an artificial tear to see how that felt before instilling the first dilation drop; this made him feel comfortable with me. The patient then started to feel anxious and I reassured him that it was just an artificial tear with no medication in it, and he calmed down.

I asked if he was comfortable with me instilling the first dilation drop, and he agreed. The patient started to get anxious again and we did a grounded breathing exercise together, directing him to feel his body supported by the chair and I would be here to help him if he needed it, reassuring him that this is a safe place and reminding him to focus on his breath. With this exercise, he was able to ride through his anxiety and felt more comfortable doing the second drop. We did the same exercise after administering the second drop and successfully completed the dilated fundus exam.



**A 54-year-old Black female with pertinent history of clozapine 100mg PO daily use for schizophrenia. No previous history of typical antipsychotic medication use. Her best-corrected visual acuity is 20/20 OU. Note the fine golden-brown dust-like deposits on the corneal endothelium, greatest inferiorly and anterior subcapsular opacity in a stellate pattern in both eyes. No pigmentary retinopathy was noted.**

Photos: Bhawan Mirhas, OD

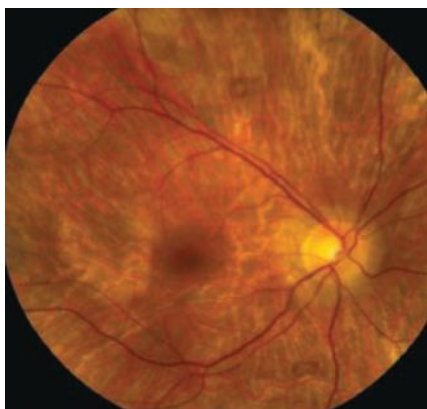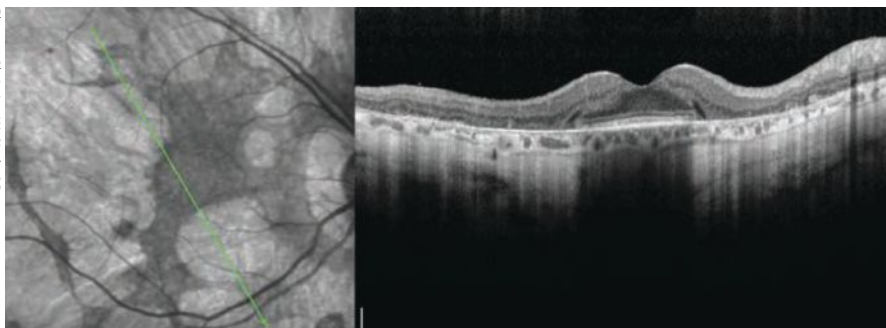
Using the artificial tear first established that it was not the medication causing the anxiety, but the sensation of the drop hitting his eye. Pairing that with a grounded breathing exercise helped him get through it and the following year we had no issues dilating him. Emergency room physicians and nurses use grounded breathing frequently with their anxious patients and it can be used in the OD office successfully as well.

**PTSD.** When working with a patient who has PTSD, it's important to be aware that certain procedures and/or sudden movements can be triggers for symptoms, such as Goldmann tonometry and the bright lights of the BIO. The tonometer coming towards them and the bright lights of the BIO can cause a startle response such as jumping up or shaking, common among those with PTSD. Knowing this ahead of time, make sure to adequately explain what they will experience beforehand, answer any questions about the procedure and let them know you can stop if they need you to, so that the startle response can be minimized or not occur at all. Effective communication between doctor and patient here is critical.

**Schizophrenia.** A hallmark symptom is visual hallucinations. If you have a patient with a history of schizophrenia, knowing this can help with discerning ocular symptoms from mental symptoms.

As a psychotherapist, I had a patient diagnosed with schizophrenia who reported seeing things regularly in his periphery. Is this an ocular condition or a mental health-related visual hallucination? It could be one or the other, or both, so I referred him to an OD for a dilated fundus exam to have a baseline of retinal health assessed. The patient might be frustrated, angry or feel unheard if their PCP just assumes these symptoms are psychological, which could lead to dire consequences if it is an ocular condition that goes undiagnosed. Be the clinician that listens to

Photos: Christine W. Sindi, OD



**Clinical signs and symptoms of thioridazine toxicity include decreased visual acuity, visual field defects and retinal pigment epithelial disturbances. There is selective uptake of thioridazine in pigmented uveal tissue and the retinal pigment epithelium, which results in toxicity.**

the exam, look for marks on the body that may be suspicious of self-injurious behaviors. Again, we may be the first to notice this, especially if it is new behavior.

Do not confront or embarrass the patient by accusing them of self-injurious behaviors. Communicate carefully that you noticed these marks and ask the patient if they are aware of them and how they may have come about. It could be from numerous things—a fall, accident or abuse, or maybe they will let you know they are self-inflicted. If it is not obvious how they came about, recommend referral to a therapist. If it is abuse, we are mandated reporters, which I discuss next.

**Suspected abuse.** Optometrists, like other healthcare providers, are mandated reporters. I was fortunate that in my optometric career I only had to report once, but it was very challenging. When we suspect abuse in the exam room, how do we deal with it? Communication with both the patient and parent/caregiver if they are a minor, must be calm, clear and straightforward. It needs to be explained that we are mandated to report suspected abuse, as parents/caregivers often try to stop you from or talk you out of reporting. We do not want to accuse the parents/caregivers, but rather emphasize that we

them and rules out an ocular etiology to this symptom.

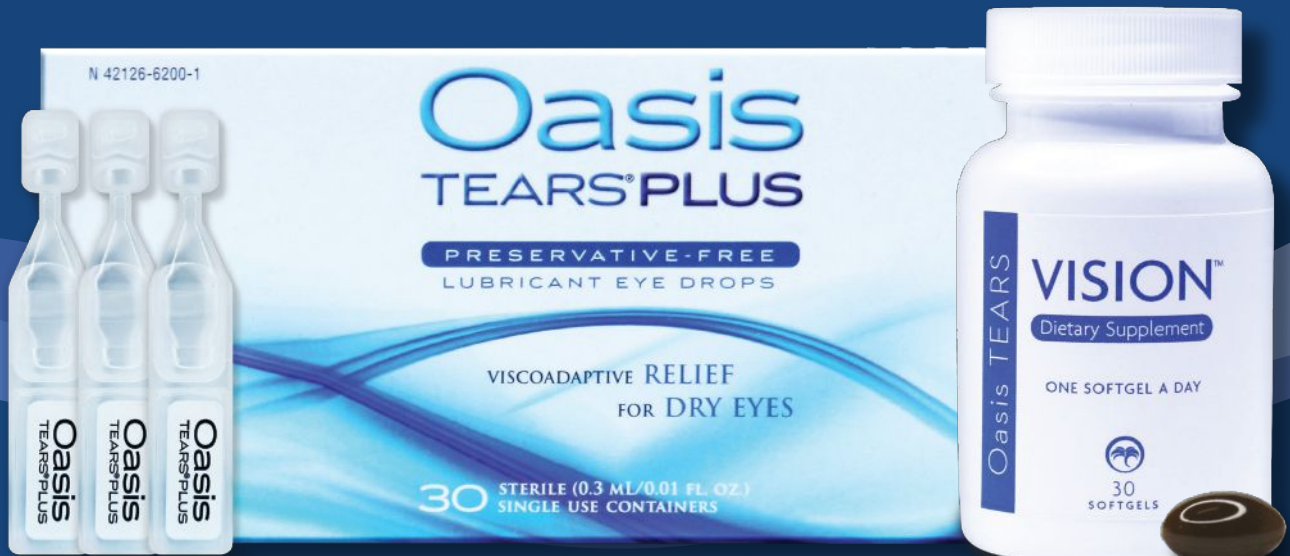**Obsessive-compulsive disorders.** Some of your patients will come to you undiagnosed with a mental health condition. An example of this can be trichotillomania, which is an obsessive-compulsive disorder. We may be the first to notice this, especially in the early stages. How do we deal with this during an exam? Don't jump right into labeling! Ask the patient if they have noticed their eyelashes are missing or if something happened to their eyebrows to explain why they are thinner. Give them an opportunity to explain why they think this is happening and to hopefully explain that they are plucking. Only after that should you discuss what trichotillomania is and refer them to a therapist for treatment.

**Self-harm.** Evaluate the whole patient, not just their eyes. With rates of depression increasing since the pandemic, incidences of self-harm have also increased. Self-injurious behaviors may include cutting, scratching, burning and bruising. When we greet a patient and during



# TOO MUCH SCREEN TIME

Bring **Comprehensive Dry Eye Relief** to your Patients



**OT6200**  
Oasis TEARS® PLUS Preservative Free

**ON3010**  
Oasis TEARS VISION Supplements

## QUALITY TEARS



### Schedule the OTC for Dry Eye: An Implementation Workshop

Call (844) 820-8940

Email [customerservice@oasismedical.com](mailto:customerservice@oasismedical.com)

Visit [www.oasismedical.com](http://www.oasismedical.com)

are mandated if we suspect abuse is a possible explanation of what we are concerned about.

The American Optometric Association Standards of Professional Conduct states: optometrists have the responsibility to identify signs of abuse and neglect in children, dependent adults and elders and to report suspected cases to the appropriate agencies, consistent with state law. Mandated reporting laws vary by state, so it is critical for us to know what our reporting responsibilities are in the state we practice in. This information can be found on the websites specific to your state’s department of children and families, elder protective services and disabled persons protection commission.

“**Knowing that patients with keratoconus can have higher levels of anxiety and depression allows you to anticipate how they might present ahead of time and tailor how you interact with them as a result.**”

### Handling Argumentative Patients

As previously stated, the COVID-19 pandemic caused an increase in many mental health conditions. Mask mandates in doctor’s offices, vaccinations, boosters, social isolation and fear of getting COVID-19 were and still are just a few of the things that increase anxiety, depression and fear. When people are more anxious, depressed and fearful, it often translates to anger and abrasiveness, and we have become the target of our patient’s misdirected anger and frustration. As ODs, we are not alone in this; PCPs, ophthalmologists, dentists, nurse practitioners and physician assistants are also experiencing similar situations.

TABLE 1. OCULAR COMPLICATIONS OF PSYCHIATRIC MEDICATIONS<sup>8</sup>

Ocular Complication	Medication
Refractive error	Topamax
Increased intraocular pressure	Topamax, antidepressants (TCAs/SSRIs/SNRIs)
Accommodative interference	Topamax, antidepressants (TCAs/SSRIs)
Ocular motor disturbances	Anticonvulsants, Topamax, anxiolytics, lithium
Oculogyric crisis	Typical antipsychotics, atypical antipsychotics, Topamax, anticonvulsants
Tear film changes	Lithium, antidepressants
Corneal or lenticular opacities	Typical antipsychotics, rarely atypical antipsychotics
Pigmentary retinopathy	Typical antipsychotics, rarely anticonvulsants and anxiolytics

How do we deal with this? First, remind yourself to not take it personally. Misdirected means just that; it is not really meant for us, but we get the heat sometimes. Second, we need to defuse the situation. One suggestion is a mindfulness exercise I learned in my training as a therapist, called the Greeting Exercise, which can be very helpful to the OD experiencing more anger from patients.<sup>7</sup>

Before greeting each patient, take a few slow breaths to allow for a transition between patients. Visualize the next patient as a human being who may be anxious about seeing you, concerned about what is going on with their eyes or fearful or vulnerable. Say to yourself, this person is coming to me because I have the unique ability to help them with their eyesight and I am grateful for that. Then, greet the patient. It may sound hokey, but give it a try. You’ll most likely find that it can be extremely helpful to take a minute to transition to the next patient and set yourself up to deal with any anger the patient may exhibit. It’s a preventive approach to deal with this trend we are all experiencing as ODs.

### Referral Network

All ODs should have a few mental health professionals they can refer

patients to. Just like referring patients to PCPs and ophthalmologists, it’s important to have mental health professionals in our community we feel comfortable referring patients to. There is an opportunity for cross-referral if you establish a relationship with mental health professionals in your community. By referring your patients to a therapist, they will thank you by referring additional patients back to you.

### Takeaways

Combining effective communication, intent listening, proper screening, grounded breathing exercises and mindfulness will not only help calm the patient, but ensure a more successful visit to your office. ■

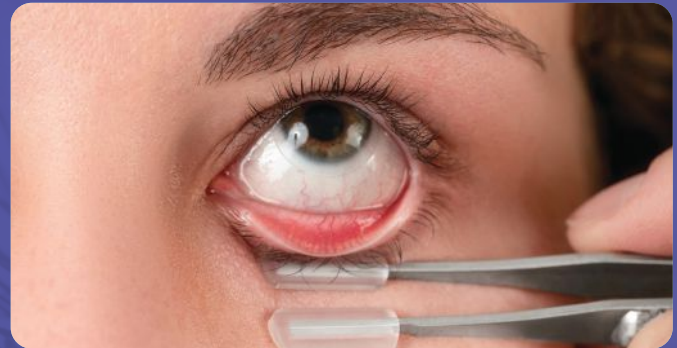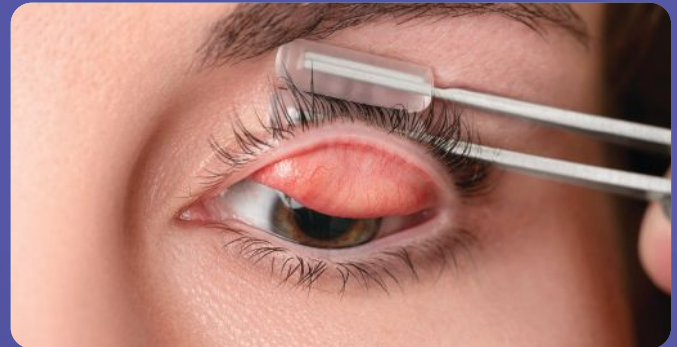1. NIMH. Mental Illness. [www.nimh.nih.gov/health/statistics/mental-illness](http://www.nimh.nih.gov/health/statistics/mental-illness). Accessed April 24, 2023.
2. Minhas B. The Mind’s Eye: Ocular Complications of Psychotropic Medications. *Rev Optom*. January 15, 2016.
3. Kim S, Shin DW, An AR, et al. Mental health of people with retinitis pigmentosa. *Optom Vis Sci*. 2013;90(5):488-93.
4. Moschos MM, Gouliopoulos NS, Kalogeropoulos C, et al. Psychological aspects and depression in patients with symptomatic keratoconus. *J Ophthalmol*. 2018;7314308.
5. Valtýsdóttir ST, Guðbjörnsson B, Lindqvist U, et al. Anxiety and depression in patients with primary Sjögren’s syndrome. *J Rheumatol*. 2000;27(1):165-9.
6. Mabuchi F, Yoshimura K, Kashiwagi K, et al. High prevalence of anxiety and depression in patients with primary open-angle glaucoma. *J Glaucoma*. 2008;17(7):552-7.
7. Germer C, Siegel RD, Fulton PR. *Mindfulness and psychotherapy*, 2nd ed. (Eds.) The Guilford Press. 2013.
8. Richa S, Yazbek JC. Ocular adverse effects of common psychotropic agents. *CNS Drugs*. 2010;24(6):501-26.



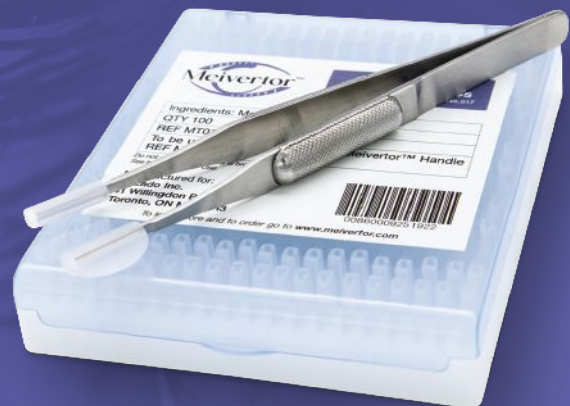

US Patent 11,446,017

# The **ONLY** **SINGLE-HANDED** **UPPER** and lower eyelid **EVERSION TOOL**



- Optimize the functionality of your meibographer
- Empower your technician to take the images you need – flipping a lid has never been easier
- Whenever you evert an upper eyelid – AND need a free hand – use your Meivertor



For more information and to purchase go to [meivertor.com](http://meivertor.com)

# ASSESSING EYELID HEALTH IN DRY EYE PATIENTS

We dive into the role abnormalities and meibomian gland dysfunction play in development and progression.

BY KATHERINE SANFORD, OD  
MEMPHIS

In 2017, the Tear Film and Ocular Surface Society released the findings of the Dry Eye Workshop II. The goal was to update the definition of dry eye established by the original Dry Eye Workshop in 2007 and re-evaluate the pathophysiology, diagnosis and management of dry eye spectrum conditions.<sup>1</sup> The report focused on the multifactorial nature of dry eye and evaluated the complex interconnections between the tear film, lacrimal glands, meibomian glands, cornea, conjunctiva and eyelids and alterations of these structures that lead to homeostasis disruption and symptomatic disease.<sup>2</sup>

This article will focus on two of these connections—eyelid abnormalities and meibomian gland dysfunction (MGD)—and discuss how to recognize these conditions, along with the role they play in the development of dry eye.

## Eyelid Malpositions

Entropion and ectropion refer to eyelid malpositions that commonly

affect the population, particularly geriatric patients. *Entropion* is an inward rotation of the eyelid margin which often results in misdirection of lashes and with time, the eyelid margin can become abnormally keratinized. *Ectropion* is the contrasting disorder in which the lid margin rotates outward. These most often affect the bottom lids but can impact the upper eyelids as well. The general etiologies for eyelid malpositions are:

- involuntional
- cicatricial (inflammation, infection or trauma)
- spastic (orbicularis spasm)
- neurogenic (CN 5 palsy)<sup>3</sup>

Regardless of the cause, poor lid closure and incomplete blinks result in exposure of the cornea, inadequate distribution of the tear film and chronic irritation of the ocular surface, which have significant effects on patients' quality of life. The result can be a myriad of symptoms, including blurred vision, epiphora, pain and foreign body sensation. Dry eye was the most common reason that patients sought treatment for their lids.<sup>4,5</sup>

When evaluating the lids, additional techniques can help determine

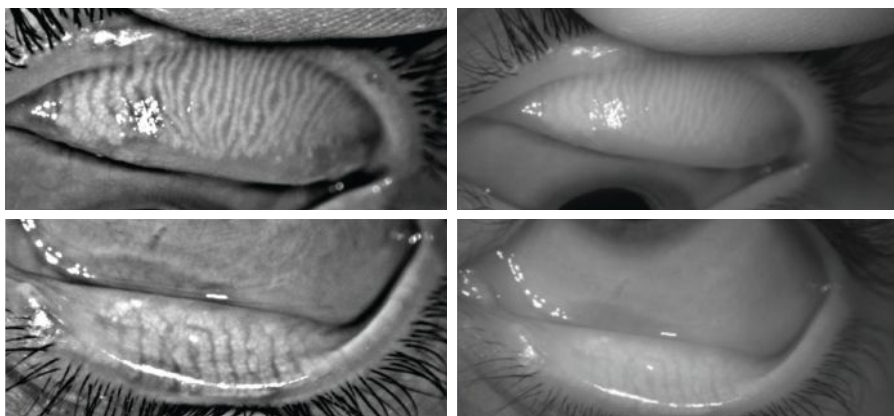
severity and causation of the malpositions. For ectropion, perform a snap back test by pulling downward on the lower lid and upward on the upper lid and evaluate the speed at which the lid snaps back into its normal position. Anything other than a brisk return to normal position is considered abnormal and severity can be assessed by the speed and whether lid blink is necessary to resume normal positioning. Presence and degree of eversion of the puncta away from the ocular surface also is indicative of severity.

For entropion, perform a digital eversion test by manually rotating the lid margin outward to its normal position. Involuntional entropion can be manually everted but cicatricial cannot due to the scarring and shortening of lid tissues.<sup>4</sup> Another common diagnostic test is the pinch test where the central eyelid is pulled away from the globe. This test is considered positive for horizontal laxity if the lid can be pulled more than 8mm away from the globe.<sup>6</sup>

Yang et al. demonstrated alterations to the meibomian glands from marginal entropion. Keratinization of the lid margin commonly occurs with

About  
the author

Dr. Sanford is an attending optometrist at the Memphis VA Medical Center. She has no financial interests to disclose.



**Meibography images from the Oculus keratograph showing normal meibomian gland number and morphology within the upper and lower lids.**

entropion due to chronic mechanical irritation of the lid tissues with blink. This keratinization gradually dislocates the meibomian gland orifices. Chronic contact between the meibomian gland orifices and the ocular surface causes shedding of conjunctival cells which obstructs the ducts. Dammed meibomian secretions over time cause inflammatory cell infiltration, dilatation of the ducts and finally, atrophy.

Entropic lids were found to have higher meibomian gland loss and thinner lipid layer thickness (LLT) than normal lids.<sup>7</sup> The more extensive the entropion, the greater was the degree of meibomian gland loss, but LLT did not decrease accordingly, possibly due to compensatory upregulation of production of lipids in the remaining glands. Patients were followed post entropion repair and were found to have an unchanged meibomian gland loss, but an increased LLT, supporting the notion that entropion is involved in the cause and/or worsening of MGD. Decreased LLT has been shown to closely correlate with signs and symptoms and ocular comfort improves when LLT is increased.<sup>8,9</sup>

While Yang et al. proposed that entropion causes or exacerbates MGD, Siah described the opposite scenario, in which entropion is a result of MGD. Rather than a distinct clinical entity, entropion is a spectrum of conditions that begins with minor

meibomian gland distortions and progresses to full-blown entropion of the lid.

Meibomian gland inversion (MGI) is the lowest severity on the spectrum and begins with tarsal contraction due to the subclinical inflammation involved with MGD. The contraction/curling causes intermittent inversion of the gland orifices, particularly with blinking, and patients experience discomfort despite an absence of obvious entropion. Orifices of the glands gradually fill with epithelium and thick meibum fills the ducts. As the condition progresses, inward rotation of the lid increases and lid ptosis, trichiasis and entropion can occur with time.

MGI can be observed with a careful slit lamp exam, noting that the meibomian gland orifices of the up-

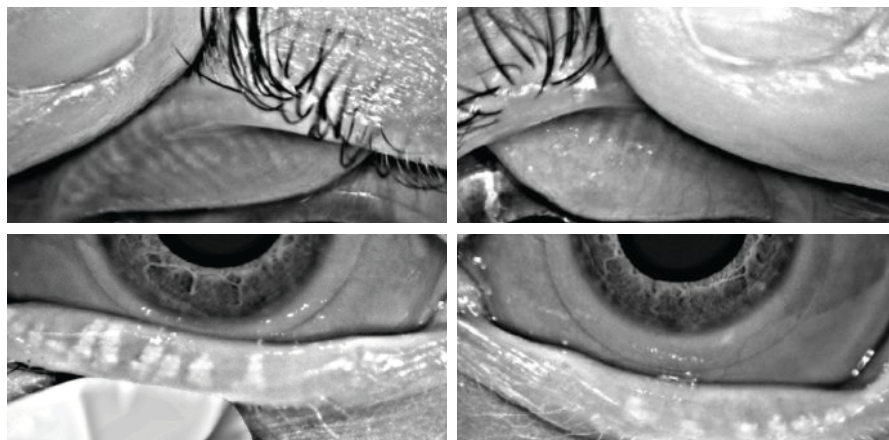
per lid are not visible in up gaze but can be brought into view with slight manipulation of the lid with a cotton tipped applicator. Patients often note improvement of symptoms with repositioning and following minor surgical corrections for MGI.<sup>10</sup>

## **Surgical Procedures**

These are often necessary to address gross lid malpositions and can greatly improve symptoms of dry eye and ocular irritation that patients experience. In other instances, however, surgery may be the cause of, rather than the treatment for, patients' dry eye.

Dry eye is a relatively minor complication of blepharoplasty, but it can significantly impact patients' quality of life and surgical satisfaction. Upper eyelid ectropion and lagophthalmos are the more common of the blepharoplasty complications. Excessive pulling or excessive removal of upper eyelid skin can cause the lid margin to evert away from the ocular surface, and dry eye ensues due to ductal hyperkeratinization and lipid deficiency.<sup>3,11,12</sup> Pre-referral assessment for blepharoplasty should include Schirmer testing, tear break-up time (TBUT) testing and monitoring for proptosis or exophthalmos, which increase the risk of developing dry eye postoperatively.

The decision to perform blepharoplasty on an existing dry



**Meibography images from a long-term contact lens wearer, demonstrating mild attenuation of the meibomian glands within the upper lid and marked gland atrophy within the lower lid.**

eye patient should not be taken lightly and ODs should educate dry eye patients carefully and refer thoughtfully.

### Lax Eyelid Conditions

This is a broad term which describes a class of conditions characterized by lid laxity with no predilection for age, sex or body mass index. Floppy eyelid syndrome (FES) is the most recognizable of the lax eyelid conditions, with easily everted upper eyelids and reactive papillary conjunctivitis of the upper tarsal conjunctiva that primarily occurs in obese men. The most significant systemic association with FES is obstructive sleep apnea (OSA), with some studies showing OSA is present in up to 100% of FES patients. Not all OSA patients will present with FES (4.5% to 18% prevalence amongst OSA patients) but the prevalence and severity of FES has been shown to mirror the severity of OSA.<sup>13</sup>

Uncertainty remains as to the exact mechanism of FES development, but theories include direct pressure on the lids due to these patients often sleeping prone or on their sides to minimize snoring, as well as intermittent systemic hypoxia during apnea.<sup>14</sup> Connective tissues within the lid are damaged over time and result in laxity, reduced goblet cell counts and gel-forming mucins, MGD and dry eye symptoms.<sup>15,16</sup> FES patients will demonstrate MGI and posterior migration of the gland orifices which negatively affects the tear film and causes chronic irritation with blink.<sup>17</sup>

Dry eye will additionally be worsened by eversion of lids during sleep, allowing greater tear evaporation. Symptoms will be worse in the morning upon waking and laterality can vary depending on prone, supine or side sleeping due to mechanical eversion of the lids against the pillow during sleep. Slit lamp evaluation of the upper lids will clearly identify

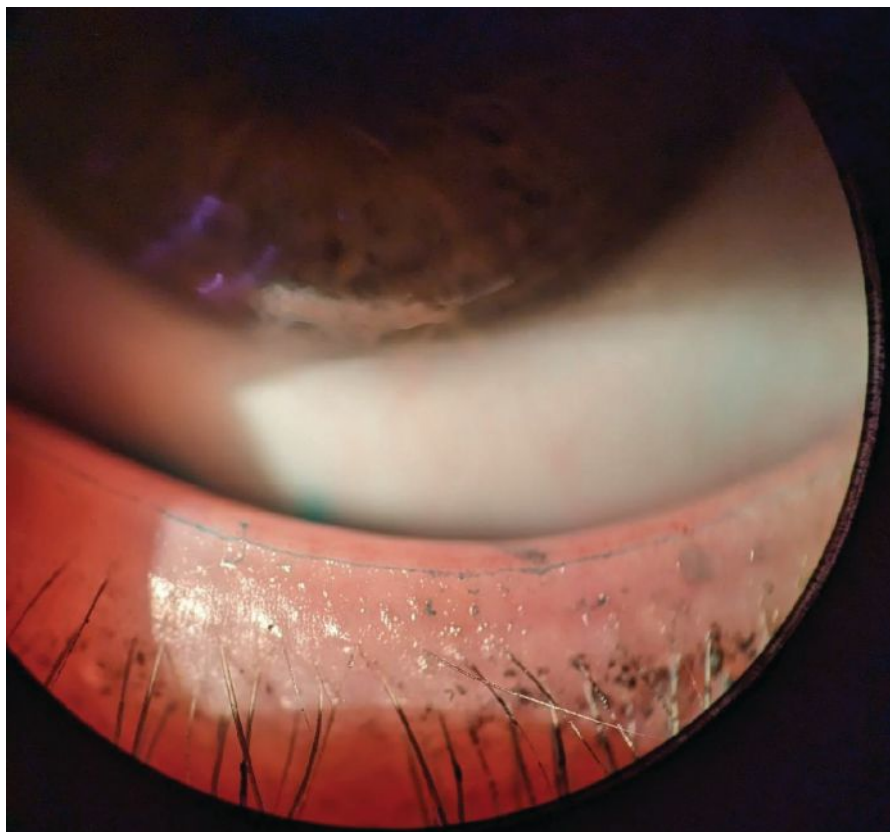
these patients in that the upper lids will distract easily from the globe when pulled superiorly and laterally. Distraction of greater than 5mm of the upper lid is considered a diagnostically positive test. Conjunctival changes will be visible upon evaluation of the superior conjunctiva and a possible lash ptosis.<sup>15</sup>

A history of OSA may be elicited in undiagnosed patients by asking about daytime somnolence, loud snoring or nocturnal gasping or choking.<sup>18</sup> While continuous positive airway pressure (CPAP) therapy is the gold standard treatment for OSA, it has been shown to have mixed results related to FES. Many patients reported no significant improvement to dry eye symptoms and intermittently experienced heightened instances of ocular irritation due to air leakage from poorly sealed CPAP masks. A smaller number of patients experienced improvement of symptoms and demonstrated increased TBUT values likely related to the supine sleeping position necessitated by CPAP mask wear and diminished mechanical trauma.<sup>19</sup> For this reason, evaluation of symptomatic FES patients should always include a careful history regarding CPAP use, mask type, proper mask fitting and episodic leakage of air.

### Sleep-related Issues

On average, a third of a person's life is spent asleep; therefore, it stands to reason the significant impact sleep-related issues can have on ocular health. Eye closure in sleep is involuntary and requires coordinated action from the ocular muscle groups, namely relaxation of the levator palpebrae and active contraction of the orbicularis oculi.<sup>18,20</sup> Any disruption of this coordination can negatively affect the eye's ability to achieve full closure during sleep.

Inadequate lid seal (ILS) is the general term for incomplete eyelid closure during sleep and is a common phenomenon. Causes include thyroid eye disease, facial palsies, trauma and cosmetic procedures, but



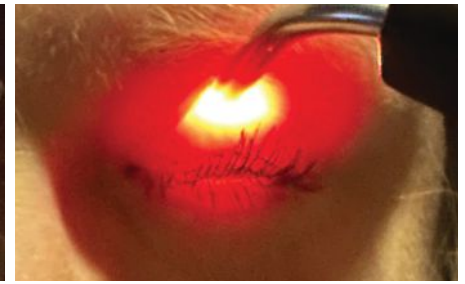
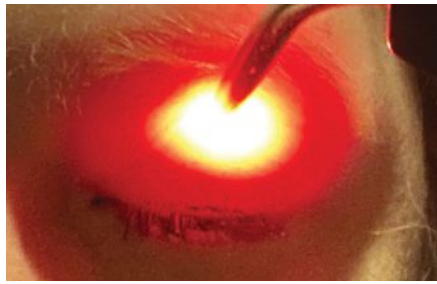
Slit lamp image of lissamine green staining of Marx's Line on the lower lid, marking the mucocutaneous junction of the eyelid.

can also be found in patients with 'normal' lid anatomy and function. The most common factor in these patients without lid closure issues is alcohol intoxication the night before due to sympathetic muscle activity to Müller's muscle and altered eye movements. Use of hypnotics such as Ambien, Lunesta or Sonata were also found to be contributory.<sup>18,20,21</sup>

Physiologically, tear production has a circadian rhythm and is diminished during sleep, leaving the eye in a relatively dry state, and protection from desiccation is typically provided by lid closure.<sup>22</sup> Coupled with hypoxia due to closed lids and tear composition changes resulting in a subclinical inflammatory state, the ocular surface is at significant risk during sleep.<sup>18</sup> This can greatly exacerbate existing dry eye disease, treatment for which can be difficult if the ILS is not addressed.

Korb et al. demonstrated that while 80% of asymptomatic patients have normal lid closure with no signs of compromised lid seal, 61% of symptomatic dry eye patients have some degree of compromise. This leads to nocturnal evaporative stress and correlates closely with the presence of moderate to severe symptoms of dry eye.<sup>23</sup> These patients will typically have symptoms most severe upon waking, similar to FES.

While some patients present with a history of observing incomplete lid closure during sleep, others have to be evaluated in-office using the snap back test described earlier and the Korb-Blackie light test. To perform this test, the patient is placed in a semi-reclined exam chair in a fully darkened room and asked to close their eyes as if they were falling asleep. While the lids are closed, a transilluminator is placed directly against the outside of the closed upper eyelid with only enough pressure to ensure contact and avoid pulling of the lid. The practitioner then observes the presence or absence of light emanating from between the lashes of the closed lids.



**Korb-Blackie lid test to monitor for incomplete lid seal. Left image demonstrates artificially induced positive finding (visible light between lashes) when excessive pressure is applied to lid. Right image demonstrates proper testing procedure with no visible light between lashes.**

Any visible light from between the lashes in the central, nasal or temporal regions of the lids is considered a positive finding for compromised lid seal. Severity can then be assessed by noting the amount of light present (0 = no light visible, 1 = minimal light, 2 = moderate light, 3 = severe light).<sup>24</sup>

### **MGD: Cause and Consequence**

Numerous references to the part MGD plays in dry eye and lid-related conditions have been made thus far, but now let us take a more direct look at MGD itself. In 2011, the International Workshop on Meibomian Gland Dysfunction published the results of an exhaustive literature and research review related to MGD and provided a summary of the definition, physiology and management.<sup>29</sup> According to the group, "MGD is a chronic, diffuse abnormality of the meibomian glands, commonly characterized by terminal duct obstruction and/or qualitative/quantitative changes in the glandular secretion. This may result in alteration of the tear film, symptoms of eye irritation, clinically apparent inflammation and ocular surface disease."<sup>30</sup>

The meibomian glands excrete lipids onto the ocular surface that form the outermost layer of the tear film overlying the aqueous and mucin layers.<sup>31,32</sup> Meibum is a complex mix of various lipids including fats, free fatty acids and cholesterol, and serves several purposes.<sup>33</sup> Meibum provides a smooth optical surface, reduces tear film evaporation, enhances tear

film stability and spreading, forms a hydrophobic barrier to prevent tear film loss, prevents contamination of the tear film by sebum and seals the lid margins during sleep.<sup>34,12</sup>

**Dysfunction.** MGD can be classified into high delivery and low delivery states. High delivery or hypersecretory MGD is seen in seborrheic dermatitis, atopic disease and acne rosacea and plays a small role in overall incidence. Low delivery gland hyposecretion is seen with contact lens wear and meibomian gland atrophy. Low delivery gland obstruction is associated with retinoid use, systemic hormonal treatments and age, and is by far the most common category.<sup>31,35</sup> 65% of all dry eye patients demonstrate obstructive MGD.<sup>35</sup> Regardless of classification, however, the net result is lipid abnormalities within the tear film leading to evaporative dry eye.<sup>34</sup>

**Obstruction.** Meibomian gland obstruction happens when the ductal epithelium becomes hyperkeratinized and meibum viscosity increases within the duct. With time, the obstruction leads to dilatation of the gland, gland atrophy and reduced secretions. With insufficient lipids on the ocular surface, evaporation and osmolarity increase, causing an unstable tear film and increased bacterial growth on the lid margin.<sup>30</sup> Biofilm comprised of an over proliferation of normal *Staphylococcal* bacteria accumulates around the lash follicle and then progresses to the meibomian and

accessory lacrimal glands of Wolfring and Krause due to decreased flushing of tears and diminished antibacterial proteins in the tear film. Bacteria increase enzyme activity within the ocular system and change the viscosity of meibum. This leads to further stasis and inflammation within the gland.<sup>31</sup> Eventually, inflammation disrupts the structural integrity of connective tissues and glands within the lid.

At this point in the cycle, biofilm may recede as the ocular surface environment is so altered it is no longer conducive to bacterial growth.<sup>36</sup>

**Evaluation.** While evaluation tools such as symptom questionnaires, TBUT and Schirmer testing provide evidence of generic dry eye, additional, more focused evaluation of the glands is required to identify MGD. Lids should be viewed carefully under the slit lamp to look for MGI, gland migration and capping. Marx's line, which occurs at the mucocutaneous junction of the eyelid, is usually visualized on the conjunctival side of the meibomian orifices when fluorescent dye is applied to the lid margin. It represents the barrier line between the lipids from the meibomian glands and the aqueous tear film and is found to shift outward to the cutaneous side of the orifices with MGD.<sup>12</sup>

Expressibility and quality of the secretions should be assessed through diagnostic expression of the glands with a cotton tipped application or digital pressure. Minimal pressure should be necessary to express a normally functioning meibomian gland and the resulting secretions should be clear and free-flowing.

Meibography and meiboscopy will demonstrate the number and morphology of the glands. Meiboscopy can be performed in-office simply by holding a transilluminator against the cutaneous side of the lid while everting the lids in a darkened exam room. The light will provide a

limited view of the glands revealing any atrophy, dilatation or tortuosity. Meibographers such as the Keratograph 5M (Oculus) and LipiView II (Johnson & Johnson) capture detailed non-contact images of the meibomian glands and can be performed easily by skilled technicians.

## Takeaways

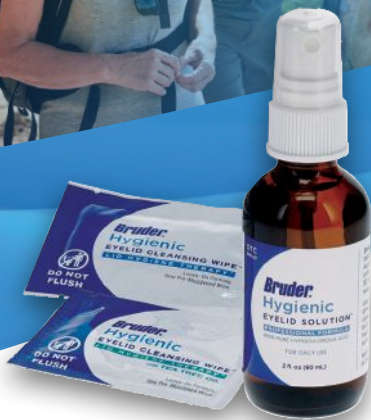Proper identification of the type of dry eye a patient has is the critical first step in determining an appropriate treatment plan. It's important to screen carefully for eyelid abnormalities and MGD in all dry eye patients, keeping in mind that multiple categories and causes can occur simultaneously, and address each component separately to maximize the patient's comfort and vision. ■

1. The definition and classification of dry eye disease: report of the Definition and Classification Subcommittee of the International Dry Eye Workshop (2007). *Ocul Surf.* 2007;5(2):75-92.
2. Craig JP, Nichols KK, Akpek EK, et al. TFOS DEWS II Definition and Classification Report. *Ocul Surf.* 2017;15(3):276-83.
3. Cho IC, Kim BJ, You HJ, Tark WH. Surgical correction of upper eyelid ectropion presenting dry eye symptoms. *Aesthet Surg J.* 2021;41(1):NP1-9.
4. Hakim F, Phelps PO. Entropion and ectropion. *Dis Mon.* 2020;66(10):101039.
5. Doan S, Zagórski Z, Palmares J, et al. Eyelid disorders in ophthalmology practice: results from a large international epidemiological study in eleven countries. *Ophthalmol Ther.* 2020;9(3):597-608.
6. Marcet MM, Phelps PO, Lai JS. Involutional entropion: risk factors and surgical remedies. *Curr Opin Ophthalmol.* 2015;26(5):416-1.
7. Yang MK, Sa HS, Kim N, et al. Quantitative analysis of morphological and functional alterations of the meibomian glands in eyes with marginal entropion. *PLoS One.* 2022;17(4):e0267118.
8. Blackie CA, Solomon JD, Scaffidi RC, et al. The relationship between dry eye symptoms and lipid layer thickness. *Cornea.* 2009;28(7):789-94.
9. Finis D, Pischel N, Schrader S, Geerling G. Evaluation of lipid layer thickness measurement of the tear film as a diagnostic tool for meibomian gland dysfunction. *Cornea.* 2013;32(12):1549-53.
10. Siah WF, Boboridis K, Tan P, et al. Meibomian gland inversion: under-recognized entity. *Acta Ophthalmol.* 2019;97(8):e1116-e1122.
11. Pacella SJ, Codner MA. Minor complications after blepharoplasty: dry eyes, chemosis, granulomas, ptosis, and scleral show. *Plastic and Reconstructive Surgery.* 2010;125(2):709-18.
12. Yamaguchi M, Kutsuna M, Uno T, et al. Marx line: fluorescein staining line on the inner lid as indicator of meibomian gland function. *Am J Ophthalmol.* 2006;141(4):669-75.
13. Sward M, Kirk C, Kumar S, et al. Lax eyelid syndrome (LES), obstructive sleep apnea (OSA) and ocular surface inflammation. *Ocul Surf.* 2018;16(3):331-6.
14. Mastrotta KM. Impact of floppy eyelid syndrome in ocular surface and dry eye disease. *Optom Vis Sci.* 2008;85(9):814-6.
15. Salinas R, Puig M, Fry CL, et al. Floppy eyelid syndrome: a comprehensive review. *Ocul Surf.* 2020;18(1):31-9.
16. Barbosa FL, Xiao Y, Bian F, et al. Goblet cells contribute to ocular surface immune tolerance-implications for dry eye disease. *Int J Mol Sci.* 2017;18(5):978.
17. Yvon C, Hunt S, Malhotra R. The importance of identifying meibomian gland inversion in patients with floppy eyelid syndrome. *Ophthalmic Plast Reconstr Surg.* 2023;39(2):156-61.
18. McNab AA. The eye and sleep. *Clin Exp Ophthalmol.* 2005;33(2):117-25.
19. Kadyan A, Asghar J, Dowson L, Sandramouli S. Ocular findings in sleep apnoea patients using continuous positive airway pressure. *Eye (Lond).* 2010;24(5):843-50.
20. Takahashi A, Negishi K, Ayaki M, et al. Nocturnal lagophthalmos and sleep quality in patients with dry eye disease. *Life (Basel).* 2020;10(7):105.
21. Greenlund IM, Cunningham HA, Tikkanen AL, et al. Morning sympathetic activity after evening binge alcohol consumption. *Am J Physiol Heart Circ Physiol.* 2021;320(1):H305-15.
22. Kawashima M, Uchino M, Yokoi N, et al. The association of sleep quality with dry eye disease: the Osaka study. *Clin Ophthalmol.* 2016;10:1015-21.
23. Korb D, Blackie C, Nau A. Prevalence of compromised lid seal in symptomatic refractory dry eye patients and asymptomatic patients. *Invest Ophthalmol Vis Sci.* 2017;58:2696.
24. Blackie CA, Korb DR. A novel lid seal evaluation: the Korb-Blackie light test. *Eye Contact Lens.* 2015;41(2):98-100.
25. Alevi D, Perry HD, Wedel A, et al. Effect of sleep position on the ocular surface. *Cornea.* 2017;36(5):567-71.
26. Gauba V, Curtis ZJ. Sleep position and the ocular surface in a high airflow environment. *Saudi J Ophthalmol.* 2014;28(1):66-8.
27. Ayaki M, Kawashima M, Negishi K, Tsubota K. High prevalence of sleep and mood disorders in dry eye patients: survey of 1,000 eye clinic visitors. *Neuropsychiatr Dis Treat.* 2015;11:889-94.
28. Ayaki M, Tsubota K, Kawashima M, et al. Sleep disorders are a prevalent and serious comorbidity in dry eye. *Invest Ophthalmol Vis Sci.* 2018;59(14):DES143-50.
29. Nichols KK. The international workshop on meibomian gland dysfunction: introduction. *Invest Ophthalmol Vis Sci.* 2011;52(4):1917-21.
30. Nichols KK, Foulks GN, Bron AJ, et al. The international workshop on meibomian gland dysfunction: executive summary. *Invest Ophthalmol Vis Sci.* 2011;52(4):1922-9.
31. Baudouin C, Messmer EM, Aragona P, et al. Revisiting the vicious circle of dry eye disease: a focus on the pathophysiology of meibomian gland dysfunction. *Br J Ophthalmol.* 2016;100(3):300-6.
32. Arita R, Morishige N, Koh S, et al. Increased tear fluid production as a compensatory response to meibomian gland loss: a multicenter cross-sectional study. *Ophthalmology.* 2015;122(5):925-33.
33. Butovich IA. The meibomian puzzle: combining pieces together. *Prog Retin Eye Res.* 2009;28(6):483-98.
34. Nelson JD, Shimazaki J, Benitez-del-Castillo JM, et al. The international workshop on meibomian gland dysfunction: report of the definition and classification subcommittee. *Invest Ophthalmol Vis Sci.* 2011;52(4):1930-7.
35. Knop E, Knop N, Millar T, et al. The international workshop on meibomian gland dysfunction: report of the subcommittee on anatomy, physiology, and pathophysiology of the meibomian gland. *Invest Ophthalmol Vis Sci.* 2011;52(4):1938-78.
36. Rynerson JM, Perry HD. DEBS—a unification theory for dry eye and blepharitis. *Clin Ophthalmol.* 2016;10:2455-67.

# OPEN YOUR EYES™ to Bruder®

a Hilco Vision Company

## HYGIENE | HEAT | HYDRATION



**Open your eyes to Bruder.** You know us for our #1 doctor-recommended moist heat eye compress. But did you know we also offer a comprehensive line of science-based products for lid hygiene and hydration?

**Healthy eyes start with three dry eye essentials: Hygiene, Heat and Hydration.** Proper lid hygiene, with Bruder Hygienic Eyelid Cleansing Wipes and Solution (HOCl), helps to relieve dry eye symptoms, supports the tear film and reduces bacteria. Moist heat applied to closed eyes, using a Bruder Mask, supports production of tears and unclogging of the meibomian glands, releasing natural oils that balance the tear film. Hyper-hydrating with our new specially formulated drink mix, Dry Eye Drink by Bruder, helps fight dehydration that has been associated with dry eye and other ocular diseases.

Ready to provide relief? Stock up now on Bruder dry eye essentials.  
Contact us at [eye@bruder.com](mailto:eye@bruder.com) or 888-827-8337 | [bruder.com/pro](https://bruder.com/pro)



# HOW CONTACT LENSES CONTRIBUTE TO DRY EYE

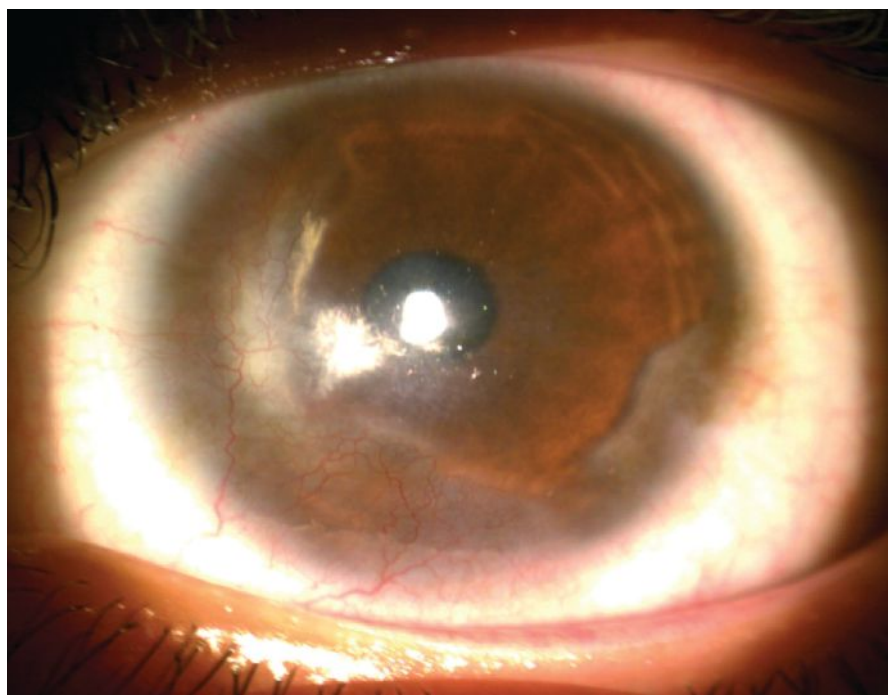
Learn about their impact on the fragile structure of the tear film, which patients are at greatest risk and the options available to alleviate symptoms.



BY MELANIE FROGOZO, OD  
SAN ANTONIO, TX

**P**receding the cornea, the tear film is the first surface of the eye that refracts light.<sup>1</sup> Altogether, the production, distribution and clearance of the tear film create a highly organized system that maintains ocular surface health.<sup>2</sup> Disruption of this process may lead to dry eye disease (DED), causing tear film instability, increased evaporation, inflammation and blurred and fluctuating vision.<sup>3</sup>

The tear film is composed of an aqueous-mucin layer that contains fluid and soluble factors produced by the lacrimal glands and mucin secreted from goblet cells. Lipid is secreted by the meibomian glands and covers the aqueous-mucin layer. The tear film organization of proteins and glycoproteins functions to maintain a stable, lubricated and smooth optical surface over the cornea. Additionally, the tears contain factors that promote wound healing, suppress inflammation, scavenge free radicals and



**Fig. 1. Limbal stem cell deficiency can develop from DED-related chronic inflammation to the limbus.**

defend against infection.<sup>2</sup>

On the eye, contact lenses divide the tear film into a pre-lens and a post-lens component. Identifying current patient tear film and ocular

health status allows for proper prescription of lens modality, associated care solutions and topical medications to maintain eye health.

In this article, I'll review the tear

#### About the author

**Dr. Frogozo** is the owner of Alamo Eye Care in San Antonio, Texas, where she directs the Contact Lens Institute. She is also a fellow of the American Academy of Optometry and the Scleral Lens Education Society, an advisory board member of the Gas Permeable Lens Institute, a committee member of the Contact Lens and Cornea Section of the American Optometric Association, an associate member of the International Society of Contact Lens Specialists and a member of the Texas Optometric Association. She has no financial disclosures.



film components, risk factors for DED and considerations for managing dry eye in contact lens wearers. Additionally, I'll discuss therapeutic lenses currently available for healing severe DED caused by ocular surface disease, as well as touch on some future dry eye-related contact lens technologies in the pipeline.

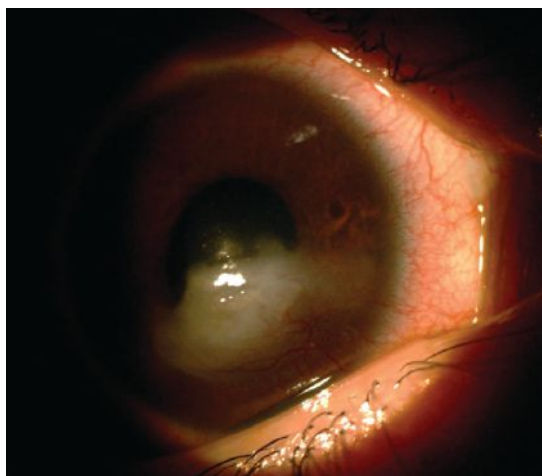
## Regulation of Tear Production

The lacrimal functional unit controls the production, delivery and clearance of tears.<sup>3</sup> The components of this unit include the tear-secreting glands (main and accessory lacrimal glands, meibomian glands, conjunctival goblet cells), the surface epithelium, eyelids, lacrimal drainage system, the glandular and mucosal immune system and its connecting innervation.<sup>2</sup>

The neural component of the lacrimal functional unit is a reflexive loop starting at the corneal nerves with afferent movement to the central nervous system. This afferent pathway, along with emotional brain centers, connect to secretory and motor efferent nerves that drive tear production and blinking. The efferent pathways end at the accessory lacrimal glands, conjunctival goblet cells and the meibomian glands.

This intricate reflexive loop indicates that secretion of the tear film is tightly controlled to maintain normal homeostasis.<sup>2</sup> Damage to the innervation of the lacrimal functional unit, either from surgery or chronic disease, results in decreased tear secretion and surface epithelial barrier disruption. Insult and denervation of the cornea can cause neuropathic pain, including altered tear composition and inflammation.<sup>3</sup>

One discovered ocular surface nociceptor, TRPM8, has been characterized as the "cold receptor," as it is stimulated by cooling of the corneal surface between blinks. This cold receptor is thought to have responsibility in driving normal tear flow.<sup>4</sup> Interestingly, a new topical ophthalmic medication for evaporative DED



**Fig. 2. Exposure keratitis can cause severe dryness and desiccation in the cornea, causing scarring.**

is currently being investigated by the FDA that may also act on the TRPM8 receptors.<sup>5</sup> Perfluorohexyloctane ( $F_6H_8$ ) is a semi-fluorinated alkane liquid that has been used in ocular surgery as a vitreous substitute.<sup>6</sup> In former animal studies,  $F_6H_8$  produced corneal surface temperature changes in tear-deficient guinea pigs.<sup>7</sup> It has been suggested that in addition to preventing evaporation,  $F_6H_8$  may facilitate heat exchange between corneal tissue and the environment, thus reducing corneal temperature and activating TRPM8 cold-thermosensitive channels. In turn, the increased activity of corneal cold nerves may lead to an increase in tear production and blink rate.<sup>8</sup>

A randomized Chinese clinical trial published this past March showed that topical  $F_6H_8$  was safe and effective at reducing DED-related symptoms. Additionally, in this population, the drop was well-tolerated and increased tear film break-up time and lipid layer thickness.<sup>5</sup>

Currently,  $F_6H_8$  is commercially available in Europe for the treatment of evaporative DED. In the US, a formulation of  $F_6H_8$  manufactured and commercialized by Bausch + Lomb had its New Drug Application accepted by the FDA in September 2022. This ophthalmic topical medication has a PDUFA action date of June 28, 2023.

## Tear Film Components

To better understand the ways in which dry eye and contact lens wear intersect, let's review the functions of the primary tear film components, including mucins, lipids and the aqueous-mucin tear layer.

**Mucins.** Tear mucus is composed of water and mucin glycoproteins that serve to maintain barrier function, hydration and wettability of the hydrophobic surface epithelial cell membranes. Also, the tear mucus provides a matrix for lacrimal

secreted factors and minimizes friction from blinking. The cornea and conjunctival epithelial cells produce membrane-associated mucins that are major components of the wettable glycocalyx.<sup>9</sup> In addition, the goblet cells secrete a gel mucus that moves over the ocular surface, which also contributes to tear stability by binding water.<sup>10</sup>

Goblet cell loss occurs in systemic inflammatory diseases, such as Sjögren's syndrome, Stevens-Johnson syndrome and graft-vs.-host disease.<sup>11</sup> Eyes with significant goblet cell loss due to Stevens-Johnson syndrome or Sjögren's syndrome are at risk for developing sight-threatening corneal ulceration and opacification.<sup>12</sup>

**Lipids.** The surface lipid layer of the tear film is primarily derived from the meibomian glands and serves as the interface between the aqueous layer and the air. The lipid layer functions as a smooth optical surface and reduces surface tension of the tear film. Furthermore, the lipid layer prevents anterior migration of aqueous tears from the lid margin and retards evaporation.<sup>13</sup> During a blink, the lipid layer is first compressed towards the lower lid, then spreads upward as the lid opens. Altered spreading and thinning of the lipid layer in those with meibomian gland disease contributes to tear film instability.<sup>14</sup>

**Other tear film components.** The aqueous-mucin tear layer contains numerous proteins, including growth and supportive factors. Some of these have a homeostatic function (*e.g.*, suppress inflammation and maintain innervation), while others participate primarily in epithelial and/or stromal wound healing.<sup>15</sup> For example, anti-infective molecules, including lysozyme, lactoferrin and lipocalin, have been found in the normal tear film.<sup>16,17</sup> The basic antibacterial mechanism of these factors involves their ability to bind free iron necessary for bacterial growth.<sup>18</sup> Also, there are several antioxidants, including ascorbic acid and cysteine, that scavenge and protect the ocular surface against damage from free radicals.<sup>19</sup>

### Demographic and Lifestyle Risk Factors

DED is associated with several demographic and lifestyle factors. Patients of female sex and individuals with reduced sleep duration are at risk of aqueous-deficient DED. Additionally, increased screen exposure is risk factor for evaporative dry eye. Advancing age and elevated psychological stress may also be associated with both aqueous-deficient and evaporative DED.<sup>20</sup>

Being female is an independent risk factor for the development of aqueous-deficient dry eye disease. This association has been hypothesized to be mediated by hormone regulatory actions of the hypothalamic-pituitary axis, sex-specific steroids and the thyroid gland. Additionally, the complex interactions between the immune system, autonomic pathways and the lacrimal functional unit may play a role in this predisposition in female patients.<sup>20</sup>

Inadequate sleep is associated with increased risk of aqueous-deficient DED. Although the mechanism is not well understood, there is a positive association between DED and sleep disorders, decreased sleep duration and sleep quality. Poor sleep duration and quality reduce produc-

tion of androgens and decreases parasympathetic tone. These preceding events lead to the downregulation of tear secretion from the lacrimal glands. Moreover, sleep deprivation may alter the circadian patterns of the hypothalamic-pituitary-adrenal axis and renin-angiotensin-aldosterone system, leading to excessive diuresis, natriuresis and dehydration, which might also impact aqueous tear production.<sup>20</sup>



**Poor sleep duration and quality reduce production of androgens and decreases parasympathetic tone. These preceding events lead to the downregulation of tear secretion from the lacrimal glands.**



Increased digital device screen exposure was identified to be a risk factor for the development of evaporative dry eye. Device use may suppress spontaneous and reflex blinking during tasks involving significant levels of cognition and visual processing. The decrease in blink rate and completeness diminishes the delivery of meibum to the ocular surface, thereby increasing the risk of evaporative DED.<sup>20</sup>

Advancing age is associated with increased risk of aqueous-deficient and evaporative DED. Dry eye is an age-related degenerative condition that progresses with lifetime cumulative exposure to a diverse range of physiological and environmental factors, as well as hormonal changes, which can all lead to ocular surface inflammation and neurosensory abnormalities. Additionally, mental health disorders, such as anxiety and depression, increase psychological stress. This mechanism may exacerbate pre-existing ocular surface homeostatic disturbances through the modulation of immune, hormonal and neurosensory systems.<sup>20</sup>

### Tear Film and Contact Lenses

The tear film is a critical component of the eyes optical system. The tears and the anterior surface of the cornea account for approximately 80% of the eye's refractive power.<sup>21</sup> Deterioration in corneal surface smoothness causes reduced contrast sensitivity and increased optical aberrations that degrade retina image quality.<sup>22</sup> As already mentioned, destabilization of the tear film due to external or local factors upsets the delicate homeostatic balance at the ocular surface and gives rise to DED. When a contact lens is placed on eye, it divides the tear film. This alteration of the pre-corneal tear film may be a risk factor for DED.<sup>23</sup>

Contact lens use was reported as a risk factor for dry eye in several large epidemiological studies on DED.<sup>23,24</sup> The interaction of contact lenses with the tear film results in an increased rate of evaporation, reduced tear thickness and volume, delayed spreading of the lipid layer, reduced pH, increased tear ferning, increased osmolarity of the pre-lens tear film and increased friction between the lens and surface epithelium, all of which can cause uncomfortable DED symptoms.<sup>25</sup> Additionally, several lens-induced ocular changes have been associated with the etiology of contact lens-related dry eye, including decreased goblet cell density and alterations in mucin produced by goblet cells.<sup>26,27</sup> Also, changes to meibomian gland function increasing the number of plugged and expressible orifices as well as gland dropout have both been associated with lens wear.<sup>28</sup>

Ocular discomfort due to dryness has been identified in a number of studies as a primary reason for the discontinuation of contact lenses.<sup>29</sup> Inflammation is a core mechanism of DED, its damage to the ocular surface and the sensation of discomfort. Several inflammatory markers, including interleukins, were increased in tears those with contact lens-related dry eye. These results support a growing evidence



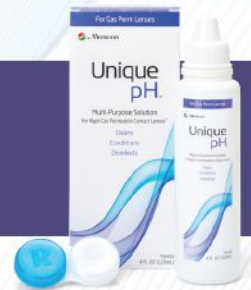# Unique never felt so good.

Unique pH™ is a highly effective multipurpose solution for gas permeable contact lenses that cleans, conditions, and disinfects in one bottle.

Unique pH™ conditions lenses by adjusting to the eye's natural tear pH to enhance the wettability and comfort of gas permeable contact lenses on insertion. The formula is designed to provide a soothing effect during lens wear.

Complimentary starter kits available!

**ORDER ONLINE**  [www.meniconwebstore.com](http://www.meniconwebstore.com)



that suggests a potential role of inflammation in contact lens-related dry eye.<sup>30</sup>

### Lens-Related DED Treatments

Options for managing this type of dry eye include daily disposable lenses, topical artificial tears, hydroxypropyl cellulose ophthalmic inserts, omega-3 and omega-6 fatty acids, punctal plugs and azithromycin.<sup>31-36</sup> In addition, studies have shown that both topical lifitegrast and cyclosporine ophthalmic solution may be safe and effective therapeutic interventions for managing patients with contact lens-related dry eye.<sup>34,37</sup>

Let's dive into a few therapeutic options for contact lens wearers experiencing dry eye, followed by a sneak peek at some prospective management options in the pipeline.

#### Medical lenses for severe dry eye.

Individuals with severe DED from ocular surface diseases such as limbal stem cell deficiency (*Figure 1*), neurotrophic keratitis, exposure keratitis (*Figure 2*) and persistent epithelial defects (*Figure 3*) can benefit from therapeutic scleral lenses. The unique design of a scleral lens vaults the cornea while landing on the sclera conjunctival shape. A fluid

reservoir filled typically with non-preserved sterile saline constantly hydrates the cornea, thus facilitating its healing process and preventing further desiccation of the ocular surface.<sup>38</sup>

Topical medications, such as antibiotics, can be added into the vault of the lens before insertion to aid surface therapy.<sup>39</sup> Further promoting healing, the large-diameter lens protects the ocular surface from shearing forces of the eyelids. Also, the gas permeable lens design corrects irregular astigmatism from corneal abnormalities.<sup>38</sup>

**Lens care considerations.** Contact lens care systems have important implications for lens-wearing comfort.<sup>40</sup> In addition to providing exceptional disinfection and cleaning, the fundamental features of hydrogen peroxide (H<sub>2</sub>O<sub>2</sub>) lens care systems can also help promote lens wear comfort. One difference between H<sub>2</sub>O<sub>2</sub> and multipurpose solutions is that the former systems are preservative-free. For lens wearers with sensitivity to preservatives, including some patients with dry eye or contact lens-associated dryness symptoms, H<sub>2</sub>O<sub>2</sub> will help avoid discomfort associated with preservative sensitivity.<sup>41</sup>

In a small randomized study of symptomatic lens wearers, the use of a one-step H<sub>2</sub>O<sub>2</sub> system resulted in significantly greater lens wettability than the use of polyhexamethylene biguanide-containing multipurpose solutions.<sup>42</sup> Also, an analysis of multiple lens and lens care system combinations found that participants using a one-step H<sub>2</sub>O<sub>2</sub> system had significantly greater subjective comfort ratings than multipurpose solution users upon lens insertion.<sup>43</sup>

Surface wetting agents can improve the comfort of contact lenses in those experiencing dry symptoms. Recently, a novel covalently bonded polyethylene glycol (PEG)-based lens surface treatment was designed to improve lens wettability, deposit resistance and tear break-up time to enhance contact lens comfort. A double-masked crossover study found that PEG surface-treated scleral lenses provided improved comfort and reduced both DED symptoms and ocular surface compromise compared with untreated participants with DED. Additionally, PEG-based surface treatment improved contact lens comfort in soft and gas-permeable contact lens wearers.<sup>44</sup>

#### Future contact lens technologies.

Topical ophthalmic medications are part of a mainstay treatment for those with contact lens-related dry eye and ocular surface disease. Topical medications are rapidly removed by the nasolacrimal duct and clearance of the tear film, as well as by conjunctival blood and lymphatic flow.<sup>45</sup> In fact, only 1% to 5% of the administered topical medication is absorbed by the tissue.<sup>46</sup> To counter low bioavailability, frequent instillation of medication is needed, which impacts patient compliance.

Instead of topical medications, drug-eluting contact lenses may be an alternative treatment for eye conditions such as DED. Drug delivery with therapeutic lenses increases the time of the medication in front of the cornea, therefore, increasing bioavailability to approximately 50%.<sup>47</sup>

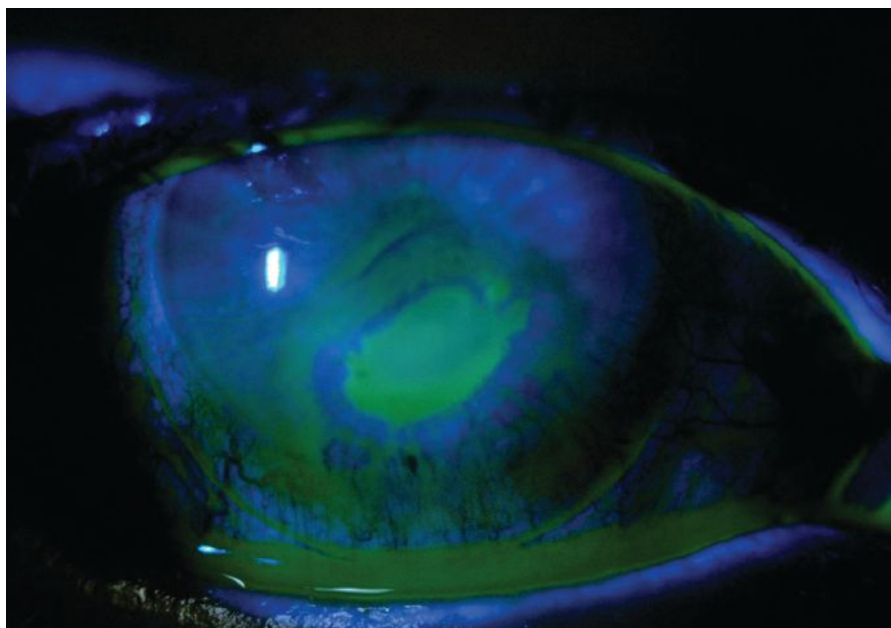


Fig. 3. Persistent epithelial defects can occur from loss of corneal innervation from dry eye.

For the treatment of all stages  
of neurotrophic keratitis (NK)



## NOT JUST ANY SOLUTION A RESOLUTION

### Complete and long-lasting resolution of NK for most patients\*<sup>1-4</sup>

- Up to 72% of patients achieved complete corneal healing in clinical trials\*<sup>1-3</sup>
- 80% of these patients remained healed at 1 year (REPARO trial)\*<sup>4</sup>

\* Resolution was evaluated in clinical trials as complete corneal healing, defined as the absence of staining in the lesion area and no persistent staining in the rest of the cornea after 8 weeks of treatment and as <0.5-mm lesion staining at 48-week follow-up.<sup>1,3</sup>

† Key study findings were after 8 weeks of treatment, 6 times daily. REPARO (Study NGF0212): 52 European patients with neurotrophic keratitis (NK) in 1 eye per group; 72% of patients completely healed; vehicle response rate 33.3%.

Study NGF0214: 24 US patients with NK in 1 or both eyes per group; 65.2% completely healed; vehicle response rate 16.7%.<sup>2,3</sup>

### Important Safety Information WARNINGS AND PRECAUTIONS

#### Use with Contact Lens

Contact lenses should be removed before applying OXERVATE because the presence of a contact lens (either therapeutic or corrective) could theoretically limit the distribution of cenergermin-bkbj onto the area of the corneal lesion. Lenses may be reinserted 15 minutes after administration.

#### Eye Discomfort

OXERVATE may cause mild to moderate eye discomfort such as eye pain during treatment. The patient should be advised to contact their doctor if a more serious eye reaction occurs.

#### ADVERSE REACTIONS

In clinical trials, the most common adverse reaction was eye pain following instillation which was reported in approximately 16% of patients. Other adverse reactions occurring in 1% to 10% of OXERVATE patients and more frequently than in the vehicle-treated patients included corneal deposits, foreign body sensation, ocular hyperemia, ocular inflammation and tearing.

#### USE IN SPECIFIC POPULATIONS

##### Pregnancy

There are no data from the use of OXERVATE in pregnant women to inform any drug associated risks.

#### Lactation

The developmental and health benefits of breastfeeding should be considered, along with the mother's clinical need for OXERVATE, and any potential adverse effects on the breastfed infant from OXERVATE.

#### Pediatric Use

The safety and effectiveness of OXERVATE have been established in the pediatric population. Use of OXERVATE in pediatric patients 2 years of age and older is supported by evidence from adequate and well-controlled trials of OXERVATE in adults with additional safety data in children.

#### INDICATION

OXERVATE® (cenergermin-bkbj) ophthalmic solution 0.002% (20 mcg/mL) is indicated for the treatment of neurotrophic keratitis.

#### DOSAGE AND ADMINISTRATION

Instill one drop of OXERVATE in the affected eye(s), 6 times a day at 2-hour intervals for eight weeks.

**To report ADVERSE REACTIONS, contact Dompé U.S. Inc. at 1-833-366-7387 or FDA at 1-800-FDA-1088 or [www.fda.gov/medwatch](http://www.fda.gov/medwatch).**

**Please see the Brief Summary of full Prescribing Information for OXERVATE on the following page.**

**References:** 1. OXERVATE® (cenergermin-bkbj) ophthalmic solution 0.002% (20 mcg/mL) [US package insert], Boston, MA; Dompé U.S. Inc.; 2019. 2. Bonini S, et al. *Ophthalmology*. 2018;125:1332-1343. 3. Pflugfelder SC, et al. *Ophthalmology*. 2020;127:14-26. 4. Data on File. Clinical Study Report (NGF0212). Dompé U.S. Inc., 2016.

oxervate®   
(cenergermin-bkbj ophthalmic  
solution) 0.002% (20 mcg/mL)



## Brief Summary of full Prescribing Information

Consult the full Prescribing Information for complete product information, available at [www.oxervate.com/prescribing-information](http://www.oxervate.com/prescribing-information).

### INDICATIONS AND USAGE

OXERVATE® (cenegermin-bkjb) ophthalmic solution 0.002% is indicated for the treatment of neurotrophic keratitis.

### DOSAGE AND ADMINISTRATION

#### General Dosing Information

Contact lenses should be removed before applying OXERVATE and may be reinserted 15 minutes after administration.

If a dose is missed, treatment should be continued as normal, at the next scheduled administration.

If more than one topical ophthalmic product is being used, administer the eye drops at least 15 minutes apart to avoid diluting products. Administer OXERVATE 15 minutes prior to using any eye ointment, gel or other viscous eye drops.

#### Recommended Dosage and Dose Administration

Instill one drop of OXERVATE in the affected eye(s), 6 times a day at 2-hour intervals for eight weeks.

### WARNINGS AND PRECAUTIONS

#### Use with Contact Lens

Contact lenses should be removed before applying OXERVATE because the presence of a contact lens (either therapeutic or corrective) could theoretically limit the distribution of cenegermin-bkjb onto the area of the corneal lesion. Lenses may be reinserted 15 minutes after administration.

#### Eye Discomfort

OXERVATE may cause mild to moderate eye discomfort such as eye pain during treatment. The patient should be advised to contact their doctor if a more serious eye reaction occurs.

### ADVERSE REACTIONS

#### Clinical Studies Experience

Because clinical studies are conducted under widely varying conditions, adverse reaction rates observed in the clinical studies of a drug cannot be directly compared to rates in the clinical studies of another drug and may not reflect the rates observed in practice.

In two clinical trials of patients with neurotrophic keratitis, a total of 101 patients received cenegermin-bkjb eye drops at 20 mcg/mL at a frequency of 6 times daily in the affected eye(s) for a duration of 8 weeks. The mean age of the population was 61 to 65 years of age (18 to 95). The majority of the treated patients were female (61%). The most common adverse reaction was eye pain following instillation which was reported in approximately 16% of patients. Other adverse reactions occurring in 1-10% of OXERVATE patients and more frequently than in the vehicle-treated patients included corneal deposits, foreign body sensation, ocular hyperemia, ocular inflammation and tearing.

### USE IN SPECIFIC POPULATIONS

#### Pregnancy

##### Risk Summary

There are no data from the use of OXERVATE in pregnant women to inform any drug associated risks.

Administration of cenegermin-bkjb to pregnant rats or rabbits during the period of organogenesis did not produce adverse fetal effects at clinically relevant doses. In a pre- and postnatal development study, administration of cenegermin-bkjb to pregnant rats throughout gestation and lactation did not produce adverse effects in offspring at clinically relevant doses.

#### Lactation

##### Risk Summary

There are no data on the presence of OXERVATE in human milk, the effects on breastfed infant, or the effects on milk production. The developmental and health benefits of breastfeeding should be considered, along with the mother's clinical need for OXERVATE, and any potential adverse effects on the breastfed infant from OXERVATE.

#### Pediatric Use

The safety and effectiveness of OXERVATE have been established in the pediatric population. Use of OXERVATE in this population is supported by evidence from adequate and well-controlled trials of OXERVATE in adults with additional safety data in pediatric patients from 2 years of age and older.

#### Geriatric Use

Of the total number of subjects in clinical studies of OXERVATE, 43.5 % were 65 years old and over. No overall differences in safety or effectiveness were observed between elderly and younger adult patients.

### NONCLINICAL TOXICOLOGY

#### Carcinogenesis, Mutagenesis, Impairment of Fertility

##### Carcinogenesis and Mutagenesis

Animal studies have not been conducted to determine the carcinogenic and mutagenic potential of cenegermin-bkjb.

##### Impairment of fertility

Daily subcutaneous administration of cenegermin-bkjb to male and female rats for at least 14 days prior to mating, and at least 18 days post-coitum had no effect on fertility parameters in male or female rats at doses up to 267 mcg/kg/day (1709 times the MRHOD).

In general toxicology studies, subcutaneous and ocular administration of cenegermin-bkjb in females was associated with ovarian findings including persistent estrus, ovarian follicular cysts, atrophy/reduction of corpora lutea, and changes in ovarian weight at doses greater than or equal to 19 mcg/kg/day (119 times the MRHOD).



Additionally, this modality of drug delivery may encourage treatment compliance due to the elimination of multiple drops throughout the day. Drug-eluting soft lenses loaded with cyclosporine and dexamethasone have been investigated for DED and corneal inflammation, respectively.<sup>48,49</sup>

“**The ocular surface is a privileged but delicate environment. Disruptions in the homeostasis of the ocular surface can impact visual perception, induce pain states and generally degrade quality of life.**”

## Takeaways

The ocular surface is a privileged but delicate environment. Disruptions in the homeostasis of the ocular surface can impact visual perception, induce pain states and generally degrade quality of life.

A stable tear film is critical to maintaining a healthy ocular surface. This surprisingly complex emulsion is susceptible to disruption from a variety of insults, including idiopathic disease, injury, surgery, infection and contact lenses. DED commonly results from altered tear film functioning and can be exacerbated by or even caused by contact lenses. At the same time, considered use of contact lenses can also ameliorate the signs and symptoms of dry eye.

Looking ahead, foreseeable advances in contact lens technology may improve the ability of contact lenses to heal the ocular surface and also to prevent dry eye's development. ■

1. Tutt R, Bradley A, Begley C, Thibos LN. Optical and visual impact of tear break-up in human eyes. *Invest Ophthalmol Vis Sci.* 2000;41(13):4117-23.
2. Pflugfelder SC, Stern ME. Biological functions of tear film. *Exp Eye Res.* 2020;197:108115.
3. Rosenthal P, Borsook D. Ocular neuropathic pain. *Br J Ophthalmol.* 2016;100(1):128-34.

4. Parra A, Madrid R, Echevarria D, et al. Ocular surface wetness is regulated by TRPM8-dependent cold thermoreceptors of the cornea. *Nat Med.* 2010;16(12):1396-99.
5. Tian L, Gao Z, Zhu L, et al. perfluorohexyloctane eye drops for dry eye disease associated with meibomian gland dysfunction in chinese patients: a randomized clinical trial. *JAMA Ophthalmol.* 2023;141(4):385-92.
6. Zeana D, Becker J, Kuckelkorn R, Kirchhof B. Perfluorohexyloctane as a long-term vitreous tamponade in the experimental animal. *Experimental perfluorohexyloctane substitution.* *Int Ophthalmol.* 1999;23(1):17-24.
7. Acosta MC, Luna C, Quirce S, Gallar J. Infrared thermography of the ocular surface of tear-deficient eyes treated with perfluorohexyloctane. *Invest Ophthalmol Vis Science.* 2017;58:465.
8. Delicado-Miralles M, Velasco E, Díaz-Tahoces A, et al. Deciphering the action of perfluorohexyloctane eye drops to reduce ocular discomfort and pain. *Front Med (Lausanne).* 2021;8:709712.
9. Gipson IK, Spurr-Michaud S, Tisdale A, Menon BB. Comparison of the transmembrane mucins MUC1 and MUC16 in epithelial barrier function. *PLoS One.* 2014;9(6):e100393.
10. Gipson IK, Argüeso P. Role of mucins in the function of the corneal and conjunctival epithelia. *Int Rev Cytol.* 2003;231:1-49.
11. Wang Y, Ogawa Y, Dogru M, et al. Baseline profiles of ocular surface and tear dynamics after allogeneic hematopoietic stem cell transplantation in patients with or without chronic GVHD-related dry eye. *Bone Marrow Transplant.* 2010;45(6):1077-83.
12. Bagga B, Motukupally SR, Mohamed A. Microbial keratitis in Stevens-Johnson syndrome: Clinical and microbiological profile. *Ocul Surf.* 2018;16(4):454-7.
13. Georgiev GA, Eftimov P, Yokoi N. Structure-function relationship of tear film lipid layer: A contemporary perspective. *Exp Eye Res.* 2017;163:17-28.
14. Braun RJ, King-Smith PE, Begley CG, Li L, Gewecke NR. Dynamics and function of the tear film in relation to the blink cycle. *Prog Retin Eye Res.* 2015;45:132-64.
15. Klenkler B, Sheardown H, Jones L. Growth factors in the tear film: role in tissue maintenance, wound healing, and ocular pathology. *Ocul Surf.* 2007;5(3):228-39.
16. Wiesner J, Vilcinskas A. Antimicrobial peptides: the ancient arm of the human immune system. *Virulence.* 2010;1(5):440-64.
17. Dartt DA. Tear lipocalin: structure and function. *Ocul Surf.* 2011;9(3):126-38.
18. Flanagan JL, Willcox MD. Role of lactoferrin in the tear film. *Biochimie.* 2009;91(1):35-43.
19. Ohashi Y, Dogru M, Tsubota K. Laboratory findings in tear fluid analysis. *Clin Chim Acta.* 2006;369(1):17-28.
20. Wolffsohn JS, Wang MTM, Vidal-Rohr M, et al. Demographic and lifestyle risk factors of dry eye disease subtypes: a cross-sectional study. *Ocul Surf.* 2021;21:58-63.
21. Rolando M, Zierhut M. The ocular surface and tear film and their dysfunction in dry eye disease. *Surv Ophthalmol.* 2001;45 Suppl 2:S203-10.
22. Rieger G. The importance of the precorneal tear film for the quality of optical imaging. *Br J Ophthalmol.* 1992;76(3):157-58.
23. Gomes JAP, Azar DT, Baudouin C, et al. TFOS DEWS II iatrogenic report. *Ocul Surf.* 2017;15(3):511-38.
24. Doughty MJ, Fonn D, Richter D, et al. A patient questionnaire approach to estimating the prevalence of dry eye symptoms in patients presenting to optometric practices across Canada. *Optom Vis Sci.* 1997;74(8):624-31.
25. Craig JP, Willcox MD, Argüeso P, et al. The TFOS International Workshop on Contact Lens Discomfort: report of the contact lens interactions with the tear film subcommittee. *Invest Ophthalmol Vis Sci.* 2013;54(11):TFOS123-56.
26. Colorado LH, Alzahrani Y, Prithard N, Efron N. time course of changes in goblet cell density in symptomatic and asymptomatic contact lens wearers [published correction appears in *Invest Ophthalmol Vis Sci.* 2016;57(8):3891]. *Invest Ophthalmol Vis Sci.* 2016;57(6):2888-94.
27. Berry M, Pult H, Purslow C, Murphy PJ. Mucins and ocular signs in symptomatic and asymptomatic contact lens wear. *Optom Vis Sci.* 2008;85(10):E930-8.
28. Alghamdi WM, Markouli M, Holden BA, Papas EB. Impact of duration of contact lens wear on the structure and function of the meibomian glands. *Ophthalmic Physiol Opt.* 2016;36(2):120-31.
29. Richdale K, Sinnott LT, Skadahl E, Nichols JJ. Frequency of and factors associated with contact lens dissatisfaction and discontinuation. *Cornea.* 2007;26(2):168-74.
30. Ramamoorthy P, Khanal S, J Nichols J. Inflammatory proteins associated with contact lens-related dry eye. *Cont Lens Anterior Eye.* 2022;45(3):101442.
31. Lazon de la Jara P, Papas E, Diec J, Naduvilath T, Willcox MD, Holden BA. Effect of lens care systems on the clinical performance of a contact lens. *Optom Vis Sci.* 2013;90(4):344-50.
32. Sindt CW, Longmuir RA. Contact lens strategies for the patient with dry eye. *Ocul Surf.* 2007;5(4):294-307.
33. Luchs JI, Nelinson DS, Macy JI; LAC-07-01 Study Group. Efficacy of hydroxypropyl cellulose ophthalmic inserts (LAC-RISERT) in subsets of patients with dry eye syndrome: findings from a patient registry. *Cornea.* 2010;29(12):1417-27.
34. Wang L, Chen X, Hao J, Yang L. Proper balance of omega-3 and omega-6 fatty acid supplements with topical cyclosporine attenuated contact lens-related dry eye syndrome. *Inflammopharmacology.* 2016;24(6):389-96.
35. Li M, Wang J, Shen M, et al. Effect of punctal occlusion on tear menisci in symptomatic contact lens wearers. *Cornea.* 2012;31(9):1014-22.
36. Nichols JJ, Bickle KM, Zink RC, Schiewe MD, Haque RM, Nichols KK. Safety and efficacy of topical azithromycin ophthalmic solution 1.0% in the treatment of contact lens-related dry eye. *Eye Contact Lens.* 2012;38(2):73-79.
37. Gonzalez AL. Safety and efficacy of lifitegrast 5% ophthalmic solution in contact lens discomfort. *Clin Ophthalmol.* 2018;12:2079-85.
38. Harthan JS, Shorter E. Therapeutic uses of scleral contact lenses for ocular surface disease: patient selection and special considerations. *Clin Optom (Auckl).* 2018;10:65-74.
39. He X, Donaldson KE, Perez VL, Sotomayor P. Case series: overnight wear of scleral lens for persistent epithelial defects. *Optom Vis Sci.* 2018;95(1):70-5.
40. Jones L, Brennan NA, González-Méjome J, et al. The TFOS International Workshop on Contact Lens Discomfort: report of the contact lens materials, design, and care subcommittee. *Invest Ophthalmol Vis Sci.* 2013;54(11):TFOS37-70.
41. Carnt N, Stapleton F. Silicone hydrogel lens-solution interaction and inflammation. *Eye Contact Lens.* 2013;39(1):37-41.
42. Guillon M, Maissa C, Wong S, Patel T, Garofalo R. Effect of lens care system on silicone hydrogel contact lens wettability. *Cont Lens Anterior Eye.* 2015;38(6):435-41.
43. Diec J, Papas E, Naduvilath T, Xu P, Holden BA, Lazon de la Jara P. Combined effect of comfort and adverse events on contact lens performance. *Optom Vis Sci.* 2013;90(7):674-81.
44. Mickles CV, Harthan JS, Barnett M. Assessment of a novel lens surface treatment for scleral lens wearers with dry eye. *Eye Contact Lens.* 2021;47(5):308-13.
45. Janagam DR, Wu L, Lowe TL. Nanoparticles for drug delivery to the anterior segment of the eye. *Adv Drug Deliv Rev.* 2017;122:31-64.
46. Novack GD. Ophthalmic drug delivery: development and regulatory considerations. *Clin Pharmacol Ther.* 2009;85(5):539-43.
47. Bengani L, Chauhan A. Are contact lenses the solution for effective ophthalmic drug delivery? *Future Med Chem.* 2012;4(17):2141-3.
48. Kim J, Mondal H, Jin R, et al. Cellulose acetate phthalate-based pH-responsive cyclosporine a-loaded contact lenses for the treatment of dry eye. *Int J Mol Sci.* 2023;24(3):2361.
49. Bengani LC, Kobashi H, Ross AE, et al. Steroid-eluting contact lenses for corneal and intraocular inflammation. *Acta Biomater.* 2020;116:149-61.

Earn 2 CE Credits  
(COPE APPROVED)

# KEEPING AN EYE OUT FOR LACRIMAL GLAND ABNORMALITIES

Understanding how these issues present and their potential implications is critical for prompt treatment and positive patient outcomes.



BY ASHLEY KAY MAGLIONE, OD,  
AND KELLY MALLOY, OD  
PHILADELPHIA

The anatomical structure and function of the lacrimal gland makes it susceptible to certain systemic diseases. Lacrimal gland structural change and/or gland dysfunction may be the presenting sign of an underlying systemic disease. Eyecare providers may be the first to see signs of an undiagnosed systemic disease manifesting as a lacrimal gland abnormality; therefore, it is critical that they have a clear understanding of the issues that can impact this structure.<sup>1-3</sup>

## Review of Anatomy

To help doctors identify patients with lacrimal gland abnormalities, first the normal anatomy and function will be reviewed. The lacrimal glands are paired structures located

superior temporally in each orbit. The lacrimal glands lie just under the frontal bones—which form the orbital roof—within a depression known as the lacrimal fossa. Anatomically, each lacrimal gland is divided by the tendon of the levator palpebrae superioris, making them appear as a bi-lobed structure with a larger orbital portion and smaller palpebral portion.<sup>4</sup>

On occasions when our patients with lacrimal gland disease complain of pain, it is the ophthalmic branch of the trigeminal nerve (CN V) that is responsible for the afferent, or sensory, perception. Conversely, efferent innervation to the lacrimal gland arises from the autonomic nervous system.

Specifically, preganglionic parasympathetic fibers travel with the greater superficial petrosal nerve, a branch of the facial nerve (CN VII), and then synapse in the pterygopalatine ganglion in the sphenopalatine fossa.

Concurrently, postganglionic sympathetic neurons from the superior cervical ganglion also course through the pterygopalatine ganglion and before reaching the lacrimal gland, travel with the aforementioned parasympathetic neurons via the ophthalmic and maxillary divisions of the trigeminal nerve.<sup>4</sup>

The autonomic innervation allows for the lacrimal gland to achieve its primary function: basal production of the aqueous components of the tear film. Therefore, pathology affecting the lacrimal gland, or its innervation, may give rise to aqueous-deficient dry eye disease. The etiologies of aqueous deficiency are often described in terms of two broad categories: Sjögren's syndrome (SS)-related dry eye vs. non-Sjögren's conditions.<sup>5</sup> In SS patients, lymphocytes primarily infiltrate the salivary and lacrimal glands, thus producing classic symptoms of dry mouth (xerostomia)

### About the authors


**Dr. Maglione** graduated from the Pennsylvania College of Optometry at Salus University. She completed a two-year advanced residency program at the Eye Institute in neuro-ophthalmic disease. She continues to work in the neuro-ophthalmic disease service at the Eye Institute and teaches didactically in neuroanatomy and neuro-ophthalmic disease courses at Salus University. She has no financial disclosures. **Dr. Malloy** is a professor at Salus University, where she specializes in neuro-ophthalmic disease. She is the Chief of the Neuro-Ophthalmic Disease Specialty Clinical Service at the Eye Institute and Co-Director of the Neuro-Ophthalmic Disease residency program at Salus University. She is a Diplomate in this specialty at the American Academy of Optometry. She is a speaker and on the advisory board for Osmotica Pharmaceuticals and RVL Pharmaceuticals.



and dry eye (keratoconjunctivitis sicca).

If a patient has symptoms suspicious for SS, consider ordering serology for the diagnostic serum antibody markers Ro/SS-A and La/SS-B.<sup>6</sup> Examples of non-Sjögren's conditions that can result in abnormal lacrimal gland aqueous production range from hormonal changes to decreased corneal sensation to autoimmune diseases to secondary effects from pharmacologic drugs.<sup>7</sup>

It is important to recognize that the lacrimal gland has a secondary, but arguably equally important, function. The lacrimal gland further contributes to the tears with an ocular immune response by secreting IgA and IgG antibodies via mucosa-associated lymphoid tissue (MALT). The presence of MALT within the lacrimal gland makes it susceptible to additional systemic conditions, including those that involve immune-mediated responses within lymphoid tissues.<sup>4</sup> When the lacrimal gland is affected by these various systemic conditions, associated structural changes may be recognized by the patient and the provider.



**Fig. 1. Diffuse sodium fluorescein staining indicative of corneal dryness OS of a patient with a history of chronic inflammatory dacryoadenitis secondary to GPA.**

However, anatomical changes may also be subtle. Therefore, an observant eyecare provider should always “keep an eye out” for lacrimal gland abnormalities.

The use of a case-based approach with the following examples allows us to review lacrimal findings, associated ocular complaints and presentations and differential diagnoses that an eyecare provider may need to consider when encountering an abnormal shape or size variation of a patient's lacrimal gland(s). Further,

we discuss examination tools and management options that a clinician can use to help make cases of lacrimal gland disease less daunting, while also improving patient outcomes.

### Case Study 1

A 32-year-old woman presented with complaints of ocular dryness and blurry vision. She reported a history of left eyelid swelling that had prompted her to seek eye care, initially with a different provider. The patient had been diagnosed with a chalazion, and treatment was initiated with warm compresses and ophthalmic ointment containing tobramycin and dexamethasone.

She did not note any improvement, thus surgical excision of the chalazion was then performed. Postoperatively, her swelling continued to worsen, prompting her to seek emergent care. The emergency department proceeded with a frontal orbitotomy and lacrimal gland biopsy to look for involvement of deeper ocular structures; however, results were considered to be consistent with a history of left chalazion.

#### Keeping an Eye Out for Lacrimal Gland Abnormalities

Jointly provided by the Postgraduate Institute for Medicine (PIM) and the Review Education Group

**Release Date:** May 15, 2023

**Expiration Date:** May 15, 2026

**Estimated Time to Complete Activity:** two hours

**Target Audience:** This activity is intended for optometrists engaged in lacrimal gland abnormality management.

**Educational Objectives:** After completing this activity, participants should be better able to:

- Recognize the anatomy of a healthy lacrimal gland.
- Identify lacrimal gland abnormalities and their potential impact.
- Distinguish between various differential diagnoses.
- Manage patients with lacrimal gland abnormalities.

**Faculty:** Ashley Kay Maglione, OD, and Kelly Malloy, OD

**Disclosure of Conflicts of Interest:** PIM requires faculty, planners and others in control of educational content to disclose all their financial relationships with ineligible companies. All identified conflicts of interest are thoroughly vetted and mitigated according to PIM policy. PIM is committed to providing its learners with high-quality, accredited CE activities and related materials that promote improvements or quality in health care and not a specific proprietary business interest of an ineligible company.

Those involved reported the following relevant financial relationships with ineligible entities related to the educational content of this CE activity: *Faculty* – Dr. Maglione has

no financial disclosures. Dr. Malloy is a speaker and on the advisory board for Osmotica Pharmaceuticals and RVL Pharmaceuticals. *Planners and Editorial Staff* - PIM has nothing to disclose. The Review Education Group has nothing to disclose.

**Accreditation Statement:** In support of improving patient care, this activity has been planned and implemented by PIM and the Review Education Group. PIM is jointly accredited by the Accreditation Council for Continuing Medical Education, the Accreditation Council for Pharmacy Education and the American Nurses Credentialing Center to provide CE for the healthcare team. PIM is accredited by COPE to provide CE to optometrists.

**Credit Statement:** This course is COPE-approved for two hours of CE credit. Activity #126026 and course ID 84405-SD. Check with your local state licensing board to see if this counts toward your CE requirement for relicensure.

**Disclosure of Unlabeled Use:** This educational activity may contain discussion of published and/or investigational uses of agents that are not indicated by the FDA. The planners of this activity do not recommend the use of any agent outside of the labeled indications. The opinions expressed in the educational activity are those of the faculty and do not necessarily represent the views of the planners. Refer to the official prescribing information for each product for discussion of approved indications, contraindications and warnings.

**Disclaimer:** Participants have an implied responsibility to use the newly acquired information to enhance patient outcomes and their own professional development. The information presented in this activity is not meant to serve as a guideline for patient management. Any procedures, medications or other courses of diagnosis or treatment discussed or suggested in this activity should not be used by clinicians without evaluation of their patient's condition(s) and possible contraindications and/or dangers in use, review of any applicable manufacturer's product information and comparison with recommendations of other authorities.



TABLE 1. CHARACTERISTICS OF DACRYOADENITIS

Dacryoadenitis Onset	Likely Etiology	Associated Pain
Acute	Infectious	Yes
Chronic	Inflammatory	Often no

Shortly after her lacrimal gland biopsy, the patient, who is now pregnant, developed neurologic symptoms of right-sided weakness and slurring of speech. She was again hospitalized and underwent magnetic resonance imaging (MRI) of the brain with contrast, which revealed pachymeningitis, or inflammation of the outermost layer of the meninges, the dura. She was immediately started on dexamethasone and empiric antibiotics, which improved her neurologic and ocular symptoms rapidly.

She was monitored until neurologic symptoms returned about one month later, and she returned to emergency medicine for a third time. While hospitalized, MRI revealed exacerbated pachymeningitis, but the patient denied further treatment of this condition and left against medical advice.

Ten days later, and now postpartum, she developed progressive neurologic and recurrent ocular symptoms, including swelling in the superior temporal aspect of her left orbit. Because the swelling was in the anatomical location of the lacrimal gland, differentials for lacrimal gland enlargement were considered. As the cause of her lacrimal gland abnormality was likely associated with her systemic symptoms, it was hoped it could potentially facilitate both an ocular and systemic diagnosis.

**Discussion.** As our patient had been diagnosed with intracranial inflammation (pachymeningitis), it was deemed reasonable to consider that her lacrimal gland swelling may also be due to related inflammation. Enlargement and swelling of the lacrimal gland due to an inflammatory process is known as dacryoadenitis. This condition can occur in all age groups but is most common in

children and young adults. Patients with dacryoadenitis usually present with a characteristic S-shaped swollen eyelid with a secondary ptosis related to the lacrimal gland swelling.<sup>8</sup> Hyperemia, often localized to the superior lateral conjunctiva, may be present. There may be associated ductional limitations, such as reduced supraduction and adduction, due to mass effect (*i.e.*, physical limitation of movement due to the lesion occupying space).<sup>1</sup>

Dacryoadenitis may be classified in a variety of ways, including by the nature/timing of the presentation—acute or chronic—and/or may be further classified by etiologies including infectious or inflammatory pathology (*Table 1*). When dacryoadenitis is chronic, the underlying etiology is often inflammatory, and the patient may not have associated acute pain symptoms. In contrast, acute dacryoadenitis is often infectious in nature and usually painful.<sup>8</sup> Due to the context of our patient's presentation being painless and chronic over a nine-month pregnancy, there was suspicion of an underlying inflammatory etiology.

There are numerous inflammatory systemic conditions that have been associated with dacryoadenitis (*Table 2*).<sup>9</sup> Dacryoadenitis can be a presenting sign in undiagnosed systemic diseases. In fact, the lacrimal gland may be predisposed to inflammation in patients due to the presence

of MALT. For instance, a systemic disease associated with lacrimal gland inflammation is sarcoidosis—where orbital findings of dacryoadenitis are seen in up to half of patients who were previously undiagnosed.<sup>1,10</sup>

In patients with dacryoadenitis, a systemic workup into underlying potential etiologies should be completed, especially in cases that are chronic and/or have signs and symptoms beyond the orbit, such as in the presented case.

Providers may evaluate for undiagnosed systemic disease in part by looking for serum markers, such as those listed in *Table 2*. For example, elevated serum angiotensin-converting enzyme (ACE) or lysozyme may point to a diagnosis of sarcoidosis. However, these blood tests may not be specific to one condition and may have false negative or positive results.

Therefore, if suspicion is still high for a specific etiology based on clinical symptoms, despite a negative serum panel, additional testing should be considered on a case-by-case basis. For instance, if a patient with chronic dacryoadenitis also has complaints consistent with sarcoidosis, such as cough or shortness of breath, a computerized tomography (CT) scan of the chest would be indicated even if ACE levels are normal.<sup>11</sup>

Additionally, when considering differential causes of dacryoadenitis, a diagnosis may be narrowed, or even definitively made, through biopsy of affected tissue and histopathologic analysis.<sup>1,9</sup> In the presented case, an additional biopsy was pursued. Since previous orbital biopsies were unrevealing, a dural biopsy was performed and provided the likely diagnosis of granulomatosis with polyangiitis (GPA).

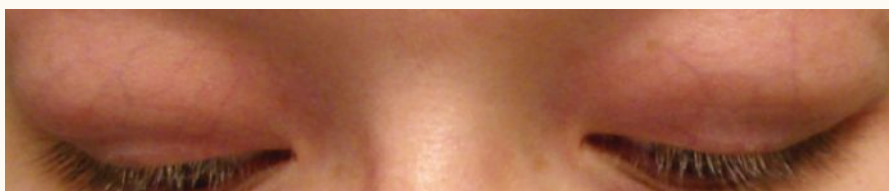


Fig. 2. Young woman with bilateral swelling in the lacrimal glands.

**Confounding factors.** GPA is an autoimmune vasculitis that classically involves the upper respiratory tract, lungs and kidneys. Orbital involvement occurs in about half of patients with GPA; while isolated involvement of the lacrimal gland is rare in GPA, it may be the presenting sign of the disease as was demonstrated in our patient's presentation.<sup>2,12</sup> In patients with GPA, anti-neutrophil cytoplasmic antibodies react with neutrophil enzyme proteinase 3. Activated neutrophils transmigrate the walls of blood vessels and are then joined by monocytes, resulting in granulomatous inflammation and damage.<sup>13</sup>

With consideration to the lacrimal gland/eyelid biopsy of our patient's orbital swelling, it was initially thought to be consistent with her history of chalazion; findings of granulomatous inflammation are characteristics of each pathology.<sup>14,15</sup> Despite potential overlap in histopathologic analysis of tissue, when the findings are integrated with the patient's history, symptoms and performed serologic analysis, diagnostic confidence can be increased.

**Treatment.** Treatment of dacryoadenitis, unilateral in this case, is usually aimed at managing the underlying etiology. For inflammatory causes, management often involves systemic steroids.<sup>1,9</sup> The patient with newly diagnosed GPA was initially treated with pulse IV steroids and then started on rituximab, a monoclonal antibody. There are now numerous monoclonal antibody medications available which are used to treat various autoimmune diseases. Management should be guided and risks assessed.

It is important to evaluate patients with lacrimal gland inflammation for possible underlying systemic diseases, not only from a purely diagnostic standpoint but also to help guide appropriate long-term treatment. For our patient, subsequent neuroimaging demonstrated improved pachymeningitis and resolution of dacryoadenitis; however, this patient

**TABLE 2. CONDITIONS ASSOCIATED WITH DACRYOADENITIS<sup>2,3,10,16-21</sup>**

Systemic Condition	Disease Characteristics	Lacrimal Gland Involvement	Serum Markers
SS	Autoimmune inflammatory disorder commonly causing dry eye and mouth	Most lacrimal gland involvement is without dacryoadenitis, but rarely can occur	Ro/SS-A and La/SS-B
Sarcoidosis	Non-caseating granulomatous inflammatory disorder	Most frequently involved orbital tissue is the lacrimal gland	Various serology including serum lysozyme, elevated levels of ACE
Crohn's Disease	Inflammatory condition that classically affects the gastrointestinal tract	While rare, when lacrimal glands are involved, the presentation is often bilateral	Anti-saccharomyces cerevisiae antibody (ASCA)
GPA	Vasculitis that affects small to medium vessels, often in the upper respiratory tract and kidneys	Isolated involvement of the lacrimal gland rare but may be the presenting sign	Proteinase 3-anti-neutrophil cytoplasmic antibody (cANCA)
IgG4-Related Disease	Chronic disease that causes tumor-like swelling	Dacryoadenitis with inflammation of parotid/salivary gland referred to as Lymphoepithelial Sialadenitis part of the disease spectrum	Elevated levels of IgG4
Eosinophilic Granulomatosis with Polyangiitis	Granulomatous inflammatory disorder that affects small- and medium-sized vessels	Lacrimal involvement typically not isolated, and other orbital structures are often involved	Myeloperoxidase anti-neutrophil cytoplasmic antibody (pANCA)
Idiopathic Orbital Inflammatory Pseudotumor (IOIP)	Diffuse, tumor-like enlargement of the lacrimal gland in the absence of systemic disease	Characteristically unilateral, acute and painful	Diagnosis of exclusion, a panel including the above serum markers should generally be unrevealing

presented to the clinic following her diagnosis and treatment with complaints of residual dry eye and blurred vision.

**Follow-up.** On examination, testing demonstrated best-corrected visual acuity of 20/20 OD and 20/30 OS. The patient exhibited a left ptosis, with interpalpebral fissures measuring 9mm OD and 5mm OS, likely due to her history of surgical incisions in the superior left orbit following biopsy. Additionally, she had restricted ocular motility in the left eye, which may be from residual mass effect. On slit lamp examination, the left cornea

demonstrated diffuse corneal staining consistent with her blur complaint and reduced acuity OS (*Figure 1*). Visual field, OCT and dilated posterior segment examination showed no optic neuropathy or persistent intraocular inflammation.

While the patient's clinical swelling associated with dacryoadenitis was resolved, it is suspected that the chronic nature of the previous inflammation to the gland may have resulted in reduced primary function of the lacrimal gland, causing secondary aqueous-deficient dry eye disease OS. She was started on

**TABLE 3. ADDITIONAL TESTING TO CONSIDER AS NEEDED IN CASES OF PERSISTENT LACRIMAL GLAND ENLARGEMENT (NON-RESPONSIVE TO TREATMENT)**

Serum Laboratory Testing	Imaging	Lacrimal Gland Biopsy
<ul style="list-style-type: none"> <li>- Inflammatory etiologies as noted in Table 2</li> <li>- Infectious etiologies, including tuberculosis</li> </ul>	<ul style="list-style-type: none"> <li>- Dedicated orbital MRI study, preferably w/w/o contrast</li> <li>- Consider MRI of brain to rule out intracranial mass or other abnormal enhancement</li> <li>- In some cases, chest CT may be needed if sarcoidosis or tuberculosis is suspected</li> </ul>	<ul style="list-style-type: none"> <li>- If signs/symptoms do not respond to treatment or resolve by three months</li> <li>- Indicated in cases of suspected idiopathic orbital inflammatory pseudotumor, as it is a diagnosis of exclusion</li> </ul>

judicious preservative-free artificial tears and commercially available topical cyclosporine because of its anti-inflammatory properties. A scleral lens fit was also recommended to potentially assist in her dry eye management and further improve visual clarity.

This case demonstrated that dacryoadenitis can be a presenting sign in an undiagnosed systemic disease. Awareness of a variety of inflammatory systemic conditions that can be associated with dacryoadenitis may expedite diagnosis, guide appropriate treatment and improve both ocular and systemic outcomes.

### Case Study 2

A 21-year-old woman presented with a chief complaint of bilateral swelling in the superior-temporal orbit, consistent with the lacrimal gland region (Figure 2). Medical history was remarkable for a relatively recent diagnosis of Epstein-Barr Virus (EBV) shortly prior to the onset of her ocular symptoms. Examination was largely unremarkable aside from the swelling in the superior eyelid region and mildly reduced abduction ability bilaterally, likely related to physical restriction due to mass effect from the enlarged lacrimal glands.

As with the first case presented, the complaint of swelling in the region of the lacrimal gland again raised the differential of dacryoadenitis. In contrast to the prior case, this patient had a more acute onset of swelling

and denied any concurrent systemic inflammatory symptoms or diagnoses. A recent viral (EBV) diagnosis raised the suspicion that her dacryoadenitis was infectious in etiology. In fact, infectious dacryoadenitis is most often viral in nature.

Previously, measles and mumps were commonly reported causative viruses of dacryoadenitis, but now, the most common viral etiology of dacryoadenitis is indeed EBV. Adenovirus, influenza, herpes simplex, herpes zoster and SARS-CoV-2 have also been implicated pathogens resulting in dacryoadenitis.<sup>21-23</sup>

Bacterial dacryoadenitis more often occurs in patients with a history of trauma or conjunctival infection. The most likely pathogen is *Staphylococcus aureus*, but others include *Streptococcus pneumoniae* and gram-negative rods.<sup>8,9</sup> Infection with *Mycobacterium tuberculosis* can result in an atypically chronic infectious dacryoadenitis.<sup>8,24</sup>

**Treatment.** Following diagnosis of infectious dacryoadenitis, bilateral in this case, treatment is tailored to the causative pathogen. As such, antibiotics are considered in bacterial cases. If the suspected etiology for dacryoadenitis is believed to be of viral etiology, the condition is usually self-limiting.

Regarding the presented patient, further testing or treatment was not warranted given her recent history of confirmed EBV—as long as the dacryoadenitis resolves in an expected

time with expected improvement. However, if infectious dacryoadenitis does not respond to appropriate treatment or is persistent, further workup such as blood work, imaging and possible biopsy may be indicated to rule out more sinister causes of lacrimal gland enlargement (Table 3).

### Case Study 3

A 69-year-old man presented with a complaint of right eye redness for 10 days without associated pain, as well as a three-day history of horizontal diplopia in right gaze. All aspects of his afferent visual system evaluation remained normal. However, he exhibited a right-sided ptosis with palpebral apertures of 5mm OD and 8mm OS.

In addition, he had reduced levator function of the right eye at 15mm, with the left eye having 20mm of levator function. He exhibited reduced abduction and supraduction OD. There was an associated esodeviation, greater in right gaze, for which he was symptomatic, and a left hyperdeviation in upgaze, for which he was asymptomatic, partly because of his right-sided ptosis. The culmination of the clinical ocular findings could raise suspicion of a condition such as myasthenia gravis. However, the associated ocular redness was not consistent with such a diagnosis.

The conjunctival hyperemia was moderate and located temporally with greatest conjunctival injection toward the posterior globe (Figure 3). Additional in-office testing helped establish a differential diagnosis for the patient’s complaints and clinical presentation. Exophthalmometry was a valuable key measure in the case, with results of the measurements demonstrating a 4mm proptosis of the right eye (25mm OD, 21mm OS).

External examination of the patient showed a fullness of the right upper eyelid, concentrated temporally and not with the typical jelly-roll pattern often seen with thyroid eye disease. There appeared to be associated right lacrimal gland enlargement.

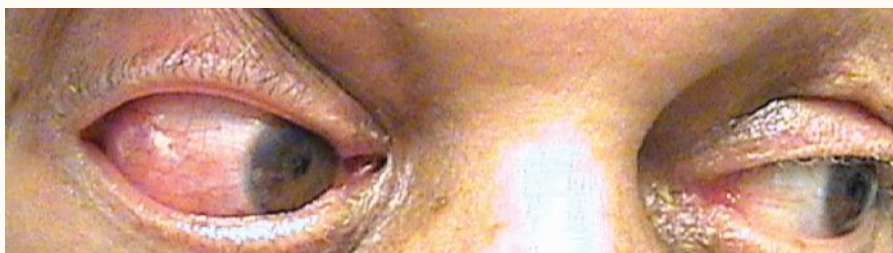Intraocular pressure, blood pressure and dilated fundus examination were all unremarkable.

Unlike the previous two cases, this patient had no history of concurrent systemic inflammation or preceding infection. However, a thorough history did uncover a remote history of non-Hodgkin's lymphoma (NHL) affecting his right leg/groin region eight years prior. He underwent surgery for the lymphoma at that time and had no known recurrence, despite oncologic surveillance.

Uncovering a history of lymphoma in a patient presenting with proptosis is very important because lymphoma, like all other cancers, can possibly recur either at the same site or a more remote location. Although not always the case, lymphoma is more common in people with immune system diseases or in those taking immunosuppressant drugs.<sup>25</sup> Some infections have been associated with an increased risk of lymphoma, including EBV and *Helicobacter pylori* infection.<sup>26,27</sup>

The first sign of lymphoma is often the appearance of enlarged lymph nodes, more likely to arise in the upper portion of the body. Cervical lymphadenopathy is the most frequent head and neck presentation of NHL.<sup>25</sup> The lymph nodes become enlarged due to a buildup of abnormal lymphocytes that do not die when they normally would. These abnormal lymphocytes instead build up, causing swelling of not only the lymph nodes but also potentially the spleen and the liver in later-stage disease.<sup>25</sup>

There are many different types of lymphoma, but they are divided into two main categories: HL and NHL. The main difference between these two types is the presence or absence of a Reed-Sternberg cell, which is a large, abnormal lymphocyte that may contain more than one nucleus. These multi-nucleated Reed-Sternberg cells are present in HL but not typically found in the many variants of NHL.<sup>28</sup>



**Fig. 3. Conjunctival hyperemia in a man with double vision and proptosis.**

Lymphomas can be further classified into the type of lymphocytes that have become malignant, either B lymphocytes (B-cells) or T lymphocytes (T-cells). Whereas HL occurs due to malignantly transformed B-cells, NHL can be associated with either malignantly transformed B-cells or T-cells.<sup>25</sup>

Diffuse large B-cell lymphoma is the most common subtype of NHL, accounting for 30% to 40% of new NHL diagnoses.<sup>29</sup> The overwhelming majority of orbital lymphomas are of B-cell origin.<sup>30</sup> One type of B-cell NHL is a MALT lymphoma, which tends to affect elderly patients. Due to the lacrimal gland secreting IgA and IgG antibodies via MALT as mentioned above, this is an important consideration when the lacrimal gland is enlarged.<sup>25,28,30</sup>

Orbital lymphoma, or ocular adnexal lymphoma, is a localized form of systemic lymphoma affecting the orbit, lacrimal gland, eyelids and conjunctiva. Conjunctival involvement can present as a salmon or flesh-colored mass on the conjunctiva.<sup>31</sup> Lymphoid orbital tumors comprise 10% to 15% of all orbital tumors and are the most prevalent orbital malignancy affecting older adults.<sup>32,33</sup>

Although this patient's clinical presentation could lead to several differential diagnoses, the addition of the history of past lymphoma causes orbital lymphoma to rise to the top of the differential diagnosis list. In this case, due to the history of lymphoma, the first step of the workup was to obtain neuroimaging to assess for cancer risk; an orbital MRI with contrast is preferred if not contraindicated.

Our patient had no contraindications and proceeded with the imaging. The results revealed enlargement and enhancement of the lacrimal gland (*Figure 4*). The structural abnormality extended temporally and superiorly behind the globe into the orbit, also encompassing the medial rectus and superior rectus muscles.

Subsequent biopsy confirmed B-cell NHL. Because the disease was localized to the orbit, systemic chemotherapy was not indicated, and the patient underwent orbital radiation.<sup>34</sup> Treatment options now also include biologics such as CD20 monoclonal antibodies, which can destroy B-cells.<sup>35</sup>

While the presence of MALT within the lacrimal gland increases the risk for lymphoma, it is important to recognize that not all lacrimal swelling is a tumor and that not all lacrimal gland tumors are lymphomas. In fact, lymphomas are not responsible for the majority of lacrimal gland tumors. Of greater frequency, and the most common malignant histology of the lacrimal gland, are adenoid cystic carcinomas.<sup>36</sup> These primary cancers are of epithelial origin and often present with pain related to perineural growth of the cancer.<sup>37</sup>

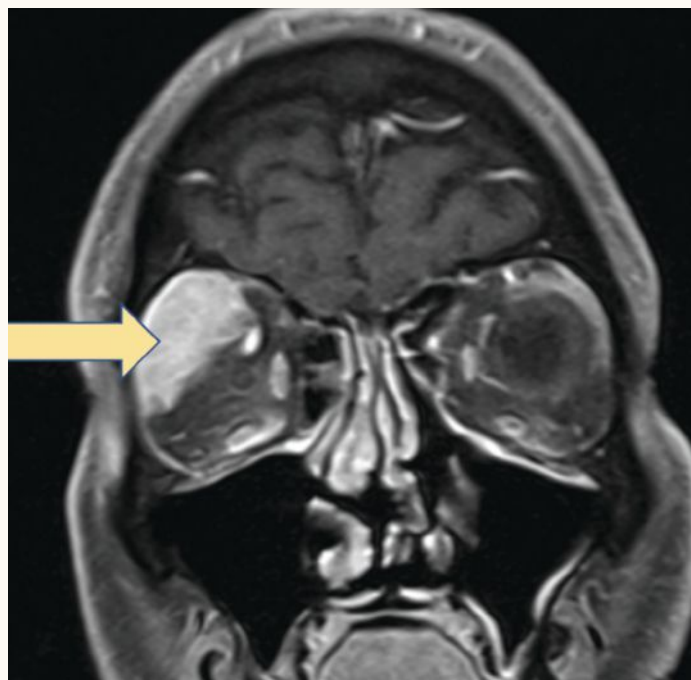Adenoid cystic carcinomas have a poor prognosis, with only a 20% survival rate at 10 years.<sup>37</sup> Another important consideration in the differential diagnosis of lacrimal gland tumors is those caused by metastasis from a distant primary cancer. Metastatic tumors of the lacrimal glands are most frequently caused by breast cancer metastases but can certainly be associated with other primary cancers as well.<sup>38,39</sup>

This case serves as a reminder to always ask your patients about a personal history of cancer. A patient's history of cancer is an important consideration regardless of the previous area/tissue involved, how remote the condition was or how long the individual has been in remission. It is a good practice assessment to take baseline exophthalmometry readings not only on patients with a history of thyroid disease but also on all patients with a medical history related to cancer so that you can monitor for interval change.

In this particular patient, asking about a previous cancer diagnosis helped to hone in on the correct diagnosis and get him the fastest possible treatment, which in turn can potentially improve the prognosis.

### Takeaways

Abnormal lacrimal gland structure, changes to the anatomy and/or variations of function can be suggestive of, and possibly the initial manifestation of, systemic disease. Eyecare providers need to be aware of systemic conditions that can affect the lacrimal gland so that prompt and relevant workup and management can be initiated. Appropriate diagnostic workup, treatment, management and referral of patients with lacrimal gland dysfunction can improve both long-term ocular and systemic prognosis. ■



**Fig. 4. MRI with contrast demonstrating biopsy-proven B-cell NHL involving the lacrimal gland.**

1. Singh S, Selva D. Non-infectious Dacryoadenitis. *Surv Ophthalmol.* 2022;67(2):353-68.
2. Hibino M, Kondo T. Dacryoadenitis with Ptosis and Diplopia as the Initial Presentation of Granulomatosis with Polyangiitis. *Intern Med.* 2017;56(19):2649-53.
3. Caçola RL, Alves Morais S, Carvalho R, et al. Bilateral dacryoadenitis as initial presentation of a locally aggressive and unresponsive limited form of orbital granulomatosis with polyangiitis. *BMJ Case Reports.* 2016;2016.bcr2015214099.
4. Machiele R, Lopez MJ, Czyn CN. Anatomy, Head and Neck, Eye Lacrimal Gland. In: *StatPearls.* 2022: Treasure Island (FL).

5. The definition and classification of dry eye disease: report of the Definition and Classification Subcommittee of the International Dry Eye WorkShop (2007). *Ocul Surf.* 2007;5(2):75-92.
6. Mavragani CP, Moutsopoulos HM. Sjögren's syndrome. *Annu Rev Pathol.* 2014;9:273-85.
7. Huang R, Su C, Fang L, et al. Dry eye syndrome: comprehensive etiologies and recent clinical trials. *Int Ophthalmol.* 2022;42(10):3253-72.
8. Patel R, Patel BC. Dacryoadenitis. In: *StatPearls.* 2022, StatPearls Publishing 2022, StatPearls Publishing LLC.: Treasure Island (FL).
9. Mombaerts I. The many facets of dacryoadenitis. *Curr Opin Ophthalmol.* 2015;26(5):399-407.
10. Pasadhika S, Rosenbaum JT. Ocular Sarcoidosis. *Clin Chest Med.* 2015;36(4):669-83.
11. Heinle R, Chang C. Diagnostic criteria for sarcoidosis. *Autoimmun Revs.* 2014;13(4-5):383-7.
12. Sfiniadaki E, Tsiara I, Theodosiadis P, et al. Ocular Manifestations of Granulomatosis with Polyangiitis: A Review of the Literature. *Ophthalmol Ther.* 2019;8(2):227-34.
13. Zheng Y, Zhang Y, Cai M, et al. Central Nervous System Involvement in ANCA-Associated Vasculitis: What Neurologists Need to Know. *Front Neurol.* 2018;9:1166.
14. Jordan GA, Beier K. Chalazion. In: *StatPearls [Internet].* 2021, StatPearls Publishing.
15. Leivo T, Koskenmies S, Uusitalo M, et al. IgG4-related disease mimicking chalazion in the upper eyelid with skin manifestations on the trunk. *Inter Ophthalmol.* 2015;35(4):595-7.
16. Moriyama M, Tanaka A, Maehara T, et al. T helper subsets in Sjögren's syndrome and IgG4-related dacryoadenitis and sialoadenitis: a critical review. *J Autoimmun.* 2014;51:81-8.
17. Jakobiec FA, Rashid A, Lane KA, et al. Granulomatous dacryoadenitis in regional enteritis (Crohn disease). *Am J Ophthalmol.* 2014;158(4):838-844.e1.
18. Linskens RK, Mallant-Hent RC, Groothuisink ZMA, et al. Evaluation of serological markers to differentiate between ulcerative colitis and Crohn's disease: pANCA, ASCA and agglutinating antibodies to anaerobic coccoid rods. *Eur J Gastroenterol Hepatol.* 2002;14(9):1013-18.

19. Akella SS, Schlachter DM, Black EH, et al. Ophthalmic Eosinophilic Granulomatosis With Polyangiitis (Churg–Strauss Syndrome): A Systematic Review of the Literature. *Ophthalmic Plast Reconstr Surg.* 2019;35(1):7-16.
20. Mombaerts I, Bilyk JR, Rose GE, et al. Consensus on Diagnostic Criteria of Idiopathic Orbital Inflammation Using a Modified Delphi Approach. *JAMA Ophthalmol.* 2017;135(7):769-76.
21. Martínez Díaz M, Piqueras SC, Marchite CB, et al. Acute dacryoadenitis in a patient with SARS-CoV-2 infection. *Orbit.* 2022;41(3):374-7.
22. Obata H, Yamagami S, Saito S, et al. A case of acute dacryoadenitis associated with herpes zoster ophthalmicus. *Jpn J Ophthalmol.* 2003;47(1):107-9.
23. Rhem MN, Wilhelmus KR, Jones DB. Epstein-Barr virus dacryoadenitis. *Am J Ophthalmol.* 2000;129(3):372-5.
24. Madge SN, Prabhakaran VC, Shome D, et al. Orbital tuberculosis: a review of the literature. *Orbit.* 2008;27(4):267-77.
25. Singh R, Shaik S, Negi BS, et al. Non-Hodgkin's lymphoma: A review. *J Family Med Prim Care.* 2020;9(4):1834-40.
26. Ross AM, Leahy CI, Neylon F, et al. Epstein-Barr Virus and the Pathogenesis of Diffuse Large B-Cell Lymphoma. *Life (Basel).* 2023;13(2):521.

27. Lai Y, Shi H, Wang Z, et al. Incidence trends and disparities in *Helicobacter pylori* related malignancy among US adults, 2000-2019. *Front Public Health.* 2022;10:1056157.
28. Yadav G, Singh A, Jain M, et al. Reed Sternberg-Like Cells in Non-Hodgkin Lymphoma: A Diagnostic Challenge. *Discoveries (Craiova).* 2022;10(3):e155.
29. Chen Y, Xu J, Meng J, et al. Establishment and evaluation of a nomogram for predicting the survival outcomes of patients with diffuse large B-cell lymphoma based on International Prognostic Index scores and clinical indicators. *Ann Transl Med.* 2023;11(2):71.
30. Olsen TG, Heegaard S. Orbital lymphoma. *Surv Ophthalmol.* 2019;64(1):45-66.
31. McGrath LA, Ryan DA, Warriar SK, et al. Conjunctival Lymphoma. *Eye.* 2023;37(5):837-48.
32. Vogele D, Sollmann N, Beck A, et al. Orbital Tumors-Clinical, Radiologic and Histopathologic Correlation. *Diagnosics (Basel).* 2022;12(10):2376.
33. Chen YQ, Yue ZF, Chen SN, et al. Primary diffuse large B-cell lymphoma of orbit: A population-based analysis. *Front Med (Lausanne).* 2022;9:990538.
34. Pereira-Da Silva MV, Di Nicola ML, Altomare F, et al. Radiation therapy for primary orbital and ocular adnexal lymphoma. *Clin Transl Radiat Oncol.* 2022;38:15-20.
35. Constantinides M, Fayd'herbe De Maudave A, Potier-Cartereau M, et al. Direct Cell Death Induced by CD20 Monoclonal Antibodies on B Cell Lymphoma Cells Revealed by New Protocols of Analysis. *Cancers (Basel).* 2023;15(4):1109.
36. Andreoli MT, Aakalu V, Setabutr P. Epidemiological Trends in Malignant Lacrimal Gland Tumors. *Otolaryngol Head Neck Surg.* 2015;152(2):279-83.
37. Benali K, Benmessouad H, Aarab J, et al. Lacrimal gland adenoid cystic carcinoma: report of an unusual case with literature review. *Radiat Oncol J.* 2021;39(2):152-8.
38. Nickelsen MN, VON Holstein S, Hansen AB, et al. Breast carcinoma metastasis to the lacrimal gland: Two case reports. *Oncol Lett.* 2015;10(2):1031-5.
39. Chen H, Li J, Wang L, et al. Hepatocellular carcinoma metastasis to the lacrimal gland: A case report. *Oncol Lett.* 2014;8(2):911-3.

## OPTOMETRIC STUDY CENTER QUIZ

To obtain CE credit through the Optometric Study Center, complete the test form on the following page and return it with the \$35 fee to: Jobson Healthcare Information, Attn.: CE Processing, 395 Hudson Street, 3rd Floor New York, New York 10014. To be eligible, please return the card within three years of publication. You can also access the test form and submit your answers and payment via credit card online at [revieweducationgroup.com](http://revieweducationgroup.com). You must achieve a score of 70 or higher to receive credit. Allow four weeks for processing. For each Optometric Study Center course you pass, you earn two hours of credit. Please check with your state licensing board to see if this approval counts toward your CE requirement for relicensure.

**1. Sympathetic and parasympathetic neurons destined for the lacrimal gland travel in the orbit with branches of which cranial nerve?**

- a. Trigeminal nerve (CN V).
- b. Optic nerve (CN II).
- c. Abducens nerve (CN VI).
- d. Oculomotor nerve (CN III).

**2. Which of the following are serum antibody markers for SS?**

- a. Ro/SS-A and La/SS-B.
- b. ACE.
- c. cANCA.
- d. IgG4.

**3. Which of the following may be associated with dacryoadenitis?**

- a. S-shaped swollen eyelid.
- b. Hyperemia of the superior temporal conjunctiva.
- c. Ductional limitations.
- d. All of the above.

**4. Which of the following would likely be associated with acute, painful dacryoadenitis?**

- a. Crohn's disease.
- b. Viral infection.
- c. Sarcoidosis
- d. Eosinophilic GPA.

**5. Which of the following is the most common cause of viral dacryoadenitis?**

- a. SARS-CoV-2.
- b. Adenovirus.
- c. EBV.
- d. Herpes simplex.

**6. Which of the following is the most common cause of bacterial dacryoadenitis?**

- a. *Staphylococcus aureus*.
- b. *Streptococcus pneumoniae*.
- c. *Mycobacterium tuberculosis*.
- d. *Staphylococcus epidermidis*.

**7. Chronic infectious dacryoadenitis is usually caused by which of the following bacteria?**

- a. *Staphylococcus aureus*.
- b. *Streptococcus pneumoniae*.
- c. *Mycobacterium tuberculosis*.
- d. *Staphylococcus epidermidis*.

**8. Which of the following are serum antibody markers for eosinophilic GPA?**

- a. Ro/SS-A and La/SS-B.
- b. ASCA.
- c. cANCA.
- d. pANCA.

**9. In a patient with dacryoadenitis, a chest CT may be helpful in the diagnosis of which suspected condition?**

- a. IgG4-related disease.
- b. Crohn's disease.
- c. GPA.
- d. Sarcoidosis.

**10. Elevated cANCA may be associated with which of the following systemic conditions?**

- a. IgG4-related disease.
- b. Crohn's disease.
- c. GPA.
- d. Sarcoidosis.

**11. Lymphoma is more likely to occur in which of the following individuals?**

- a. Immunocompromised individuals.
- b. Those taking immunosuppressant drugs.
- c. Those with a history of EBV infection.
- d. All of the above .

**12. The first sign of lymphoma is usually which?**

- a. Enlarged lymph nodes in the upper portion of the body.
- b. Enlarged lymph nodes in the lower portion of the body.
- c. Enlarged spleen.
- d. Enlarged liver.

**13. The most common subtype of NHL is which?**

- a. MALT lymphoma.
- b. Diffuse large B-cell lymphoma.
- c. T-cell lymphoma.
- d. None of the above.

**14. What percentage of orbital tumors are lymphoid?**

- a. 10% to 15%.
- b. 20% to 35%.
- c. 40% to 55%.
- d. 70% to 85%.

**15. What is the most common malignant tumor of the lacrimal gland?**

- a. B-cell lymphoma.
- b. T-cell lymphoma.
- c. Adenoid cystic carcinoma.
- d. Plasmacytoma.

**16. Lacrimal gland metastatic tumors are most likely to originate from which primary cancer?**

- a. Breast.
- b. Colon.
- c. Brain.
- d. Prostate.

**17. In patients with sarcoidosis, the most frequently involved orbital tissue is which?**

- a. Orbital fat.
- b. Extraocular muscles.
- c. Lacrimal gland.
- d. Conjunctiva.

**18. In patients with dacryoadenitis and inflammation of the parotid gland, which of the following serum tests is most likely indicated?**

- a. ACE.
- b. ASCA.
- c. IgG4.
- d. cANCA.

**19. Which of the following conditions is a diagnosis of exclusion?**

- a. SS.
- b. GPA.
- c. IOIP.
- d. NHL

**20. Which of the following treatment modalities may be used in B-cell lymphoma localized to the orbit?**

- a. Chemotherapy.
- b. Orbital radiation.
- c. Whole body radiation.
- d. Plasmapheresis.

### Examination Answer Sheet

#### Keeping an Eye Out for Lacrimal Gland Abnormalities

Valid for credit through May 15, 2026

**Online:** This exam can be taken online at [revieweducationgroup.com](http://revieweducationgroup.com). Upon passing the exam, you can view your results immediately and download a real-time CE certificate. You can also view your test history at any time from the website.

**Directions:** Select one answer for each question in the exam and completely darken the appropriate circle. A minimum score of 70% is required to earn credit.

**Mail to:** Jobson Healthcare Information, LLC, Attn.: CE Processing, 395 Hudson Street, 3rd Floor New York, New York 10014.

**Payment:** Remit \$35 with this exam. Make check payable to Jobson Healthcare Information, LLC.

**Credit:** This course is COPE-approved for two hours of CE credit. Course ID 84405-SD.

**Processing:** There is a four-week processing time for this exam.

Jointly provided by PIM and the Review Education Group.

**Answers to CE exam:**

1. (A) (B) (C) (D)
2. (A) (B) (C) (D)
3. (A) (B) (C) (D)
4. (A) (B) (C) (D)
5. (A) (B) (C) (D)
6. (A) (B) (C) (D)
7. (A) (B) (C) (D)
8. (A) (B) (C) (D)
9. (A) (B) (C) (D)
10. (A) (B) (C) (D)
11. (A) (B) (C) (D)
12. (A) (B) (C) (D)
13. (A) (B) (C) (D)
14. (A) (B) (C) (D)
15. (A) (B) (C) (D)
16. (A) (B) (C) (D)
17. (A) (B) (C) (D)
18. (A) (B) (C) (D)
19. (A) (B) (C) (D)
20. (A) (B) (C) (D)

**Post-activity evaluation questions:**

Rate how well the activity supported your achievement of these learning objectives. 1=Poor, 2=Fair, 3=Neutral, 4=Good, 5=Excellent

21. Recognize the anatomy of a healthy lacrimal gland. (1) (2) (3) (4) (5)
22. Identify lacrimal gland abnormalities and their potential impact. (1) (2) (3) (4) (5)
23. Distinguish between various differential diagnoses. (1) (2) (3) (4) (5)
24. Manage patients with lacrimal gland abnormalities. (1) (2) (3) (4) (5)
25. Based upon your participation in this activity, do you intend to change your practice behavior? (Choose only one of the following options.)
  - (A) I do plan to implement changes in my practice based on the information presented.
  - (B) My current practice has been reinforced by the information presented.
  - (C) I need more information before I will change my practice.
26. Thinking about how your participation in this activity will influence your patient care, how many of your patients are likely to benefit? (please use a number):
27. If you plan to change your practice behavior, what type of changes do you plan to implement? (Check all that apply.)
 

(A) Apply latest guidelines	(D) Change in current practice for referral	(G) More active monitoring and counseling
(B) Change in diagnostic methods	(E) Change in vision correction offerings	(H) Other, please specify: _____
(C) Choice of management approach	(F) Change in differential diagnosis	
28. How confident are you that you will be able to make your intended changes?
  - (A) Very confident
  - (B) Somewhat confident
  - (C) Unsure
  - (D) Not confident
29. Which of the following do you anticipate will be the primary barrier to implementing these changes?
 

(A) Formulary restrictions	(D) Insurance/financial issues	(G) Patient adherence/compliance
(B) Time constraints	(E) Lack of interprofessional team support	(H) Other, please specify: _____
(C) System constraints	(F) Treatment related adverse events	
30. Additional comments on this course: \_\_\_\_\_

Please retain a copy for your records. Please print clearly.

First Name

Last Name

E-Mail

The following is your:  Home Address  Business Address

Business Name

Address

City  State

ZIP

Telephone #  -  -

Fax #  -  -

OE Tracker Number

**Rate the quality of the material provided:**  
 1=Strongly disagree, 2=Somewhat disagree,  
 3=Neutral, 4=Somewhat agree, 5=Strongly agree

31. The content was evidence-based. (1) (2) (3) (4) (5)

32. The content was balanced and free of bias. (1) (2) (3) (4) (5)

33. The presentation was clear and effective. (1) (2) (3) (4) (5)

By submitting this answer sheet, I certify that I have read the lesson in its entirety and completed the self-assessment exam personally based on the material presented. I have not obtained the answers to this exam by any fraudulent or improper means.

Signature \_\_\_\_\_ Date \_\_\_\_\_ Lesson 123858 RO-OSC-0523



*Review of Optometry*<sup>®</sup>  
presents a collaboration between



For the first time, New Technologies and Treatments in Eye Care and the Intrepid Eye Society's Innovations and Implementations in Practice will be held as a combined meeting. As always, our renowned faculty will bring you the latest advancements in dry eye, ocular surface disease, myopia, retina, glaucoma, and contact lenses on top of other urgent issues for practitioners.

**AUGUST 25–27, 2023**

MARRIOTT SAVANNAH RIVERFRONT | SAVANNAH, GEORGIA

 **IN-PERSON EVENT**

**CONFERENCE CO-CHAIRS**



**John D. Gelles, OD, FAAO, FIAOMC, FCLSA, FSLs, FBCLA**  
Clinical Assistant Professor  
Department of Ophthalmology  
Rutgers New Jersey  
Medical School  
Newark, New Jersey



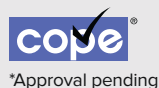**Paul M. Karpecki, OD, FAAO**  
Director of Cornea Services  
Kentucky Eye Institute  
Medical Director  
KEPLR Vision  
Lexington, Kentucky



**Nathan Lighthizer, OD, FAAO**  
Director of Continuing Education  
Associate Professor  
Associate Dean NSU Oklahoma  
College of Optometry  
Tulsa, Oklahoma

**EARLY BIRD  
SPECIAL PRICING**  
**\$225**  
increases June 9

Earn up to 21 COPE credits\*



For more information and to register visit:  
[www.reviewedu.com/ntt\\_ies](http://www.reviewedu.com/ntt_ies)





BY PAUL M. KARPECKI, OD  
CHIEF CLINICAL EDITOR

## OCULAR SURFACE REVIEW

# Drink Up

*Hydrating the whole body—not just the eyes—is key to improving the ocular surface.*

**D**ry eye can be caused or exacerbated by many things, not the least of which is dehydration. Indeed, we have long been aware of the multifactorial nature of dry eye disease (DED), yet we have paid comparatively less attention to specifically how and why whole body hydration is an important consideration in dry eye etiology and management, something that is backed by research and can be a meaningful therapeutic strategy.<sup>1-3</sup>

Here, we will review the scientific literature on the effects and measurement of hydration and recommend practical strategies that can help patients improve whole body hydration in a manner that is specifically designed to optimize ocular surface health.

### Ocular Structures and Systems

The effects of whole body hydration on the eyes are staggering, although not surprising since water is a major constituent of the eye.<sup>4</sup> In fact, the tear film, aqueous and vitreous are over 98% water.<sup>5</sup> A systematic

#### Biometric Measurement Alternations That Respond to Hydration Status:<sup>3</sup>

- Tear film osmolarity<sup>6</sup>
- Central corneal thickness<sup>7</sup>
- Intraocular pressure<sup>8-10</sup>
- Anterior chamber depth<sup>11</sup>
- Axial length<sup>12</sup>
- Color Doppler imaging<sup>13</sup>
- Spectral-domain OCT<sup>14</sup>

review shows that hydration affects the ocular physiology, morphology, ocular pathophysiologic processes and disease states found in both the front and back of the eye, including dry eye, cataracts, refractive changes, glaucoma and retinal vascular disease.<sup>3</sup>

### Hydration Challenges

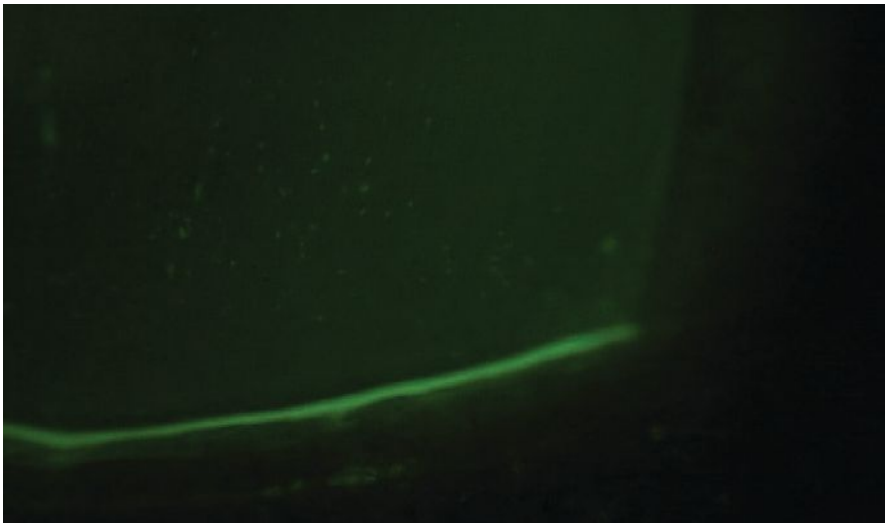
Despite apparent challenges associated with patients' ability or willingness to improve whole body hydration, optometrists should do their part to at least convey the relevance of hydration on ocular well-being. Ideally, our conversations should extend beyond cliché reminders to drink more water and include specific directions on how to meet eye health hydration standards.

Hydration isn't as simple as drinking lots of water. Electrolytes also play an important role in reaching and maintaining healthy hydration levels—so much so that in the Women's Health Study, which included over 50,000 participants, researchers concluded that recommending increased water intake is not justifiable, as water by itself has not been proven to decrease risk of DED.<sup>14</sup>

Recognizing that drinking a lot of water can be a burden, many patients have turned to sport drinks and other high-electrolyte beverages. While these can help overcome dehydration quicker, many are unsuitable for regular use due to high sugar content. Also, none of these beverages are specifically formulated with ingredients shown to benefit ocular structures in particular.

### Dry Eye Drink

Recognizing the need for something eyecare providers could confidently

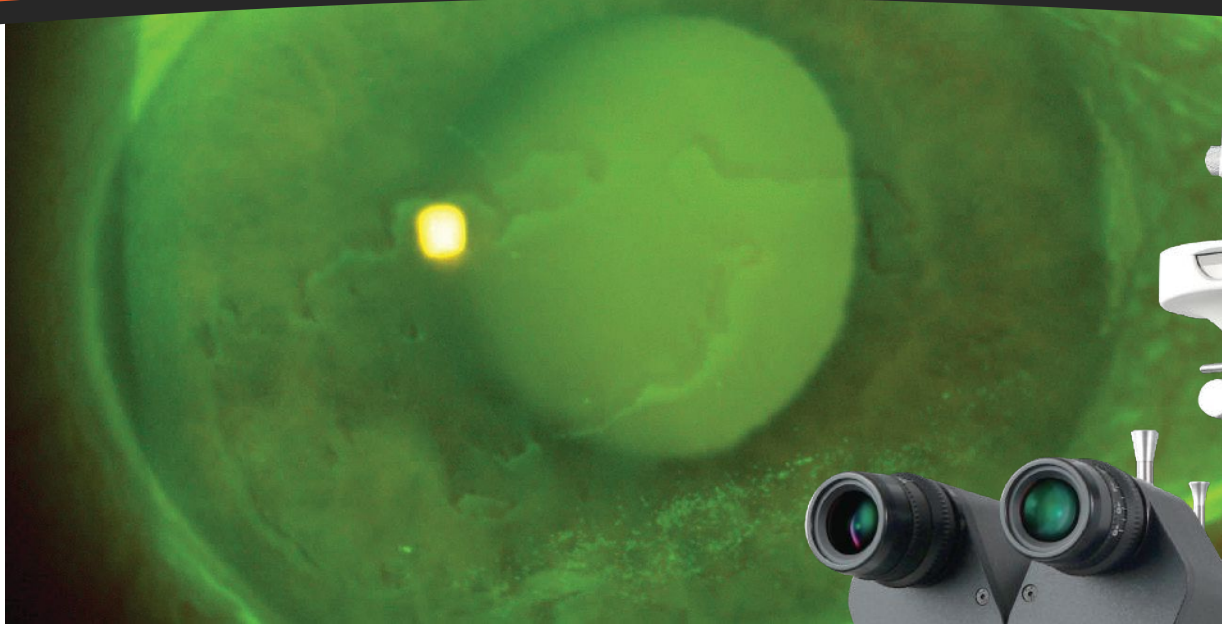


Minimal tear meniscus height, pictured here, is indicative of aqueous-deficient dry eye.

#### About Dr. Karpecki

**Dr. Karpecki** is director of Cornea and External Disease at Kentucky Eye Institute and an associate professor at the Kentucky College of Optometry. He is the Chief Clinical Editor for *Review of Optometry* and chair of the New Technologies & Treatments conferences. A fixture in optometric clinical education, he consults for a wide array of ophthalmic companies, including ones discussed in this article. Dr. Karpecki's full disclosure list can be found in the online version of this article at [www.reviewofoptometry.com](http://www.reviewofoptometry.com).

# The Anterior Segment Virtuoso



Nothing performs better in the anterior chamber than the Firefly® Imaging System. Using wavelengths similar to natural light, it delineates eye anatomy with an optical resolution of 200 lp/mm.

The standard Firefly comes fully loaded with video capture, automatic exposure, artificial intelligence, meibography, and a Wratten yellow filter. Optional Dry Eye Diagnostic module.

See Firefly's online image gallery, and we're sure you'll applaud the performance. Visit [eyefficient.com](http://eyefficient.com)

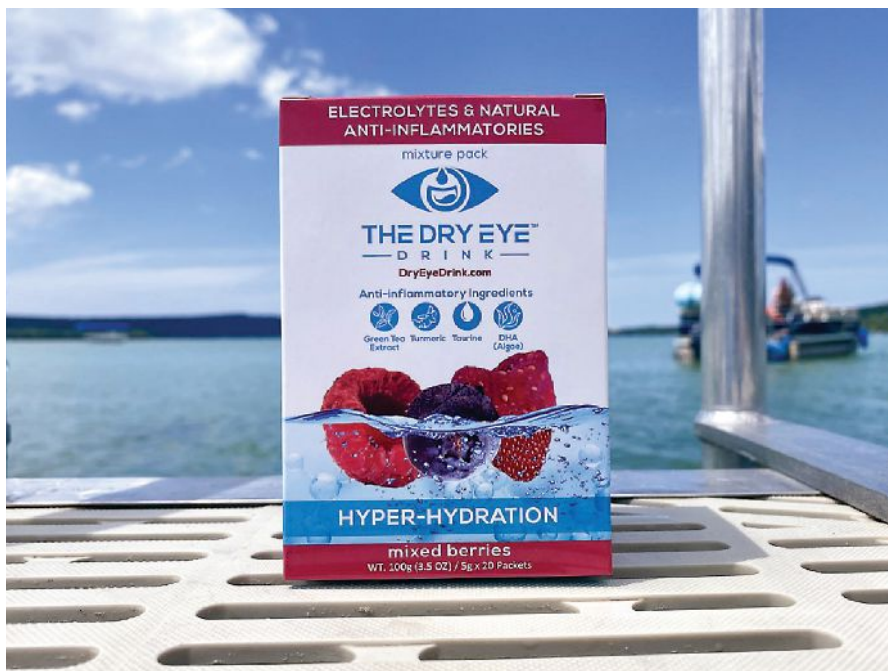

FIREFLY'S ONLINE GALLERY



EYEFFICIENT<sup>SM</sup>

© 2023 EYEFFICIENT, ALL RIGHTS RESERVED



**Dry Eye Drink is a combination of turmeric, DHA, taurine, green tea and natural electrolytes, which helps decrease inflammation.**

recommend to a broad base of patients—many of whom enjoy flavored beverages, yet may not be likely to adhere to drinking large quantities of water—a new product was developed, known as the Dry Eye Drink. This specifically formulated powdered drink pack is meant to be added to water and consumed twice per day to help hyperhydrate patients without the deleterious effects of sugar.

“**Ideally, our conversations should extend beyond cliché reminders to drink more water and include specific directions on how to meet eye health hydration standards.**”

After testing 43 formulations, the final version was developed with other vitamins that have been shown to benefit the ocular surface, such as vitamins A, B3, B6, B12 and C.

The Dry Eye Drink also includes turmeric, DHA, taurine and green tea, as well as natural electrolytes and omega-3s, which help decrease inflammation.

The product has shown clinical benefits and new versions were recently developed. Patient feedback indicated that for caffeine-sensitive individuals, the original daytime formula can cause restlessness when taken immediately before bed, which led to a “PM” version that replaced the B vitamins and green tea extract with melatonin, chamomile extract and Valerian root extract. In other words, it was designed to not only aid dry eye, but also sleep issues. Lack of adequate sleep has been associated with DED, and DED has been shown to affect sleep quality.<sup>15,16</sup>

Anecdotally, one of the primary causes of treatment-resistant DED is inadequate lid seal, which may also play a key role in poor sleep quality.

As we learn more about the role hydration plays in dry eye, whole body hydration—specifically the Dry Eye Drink—may help more patients in their journey to better ocular surface health. ■

### Hydration Terms<sup>3</sup>

- **Dehydration:** loss of total body water.
- **Rehydration:** gain of total body water.
- **Hypohydration:** generalized body water deficit beyond the normal range.
- **Hyperhydration:** generalized body water excess beyond the normal range.

*Special thanks to Josh Davidson, OD, for his contributions to this column.*

1. Lemp MA. Advances in understanding and managing dry eye disease. *Am J Ophthalmol.* 2008;146(3):350-6.
2. Walsh NP, Fortes MB, Raymond-Barker P, et al. Is whole-body hydration an important consideration in dry eye? *Invest Ophthalmol Vis Sci.* 2012;53(10):6622-7.
3. Sherwin JC, Kokavec J, Thornton SN. Hydration, fluid regulation and the eye: in health and disease. *Clin Exp Ophthalmol.* 2015;43(8):749-64.
4. Fischbarg J. Water channels and their roles in some ocular tissues. *Mol Aspects Med.* 2012;33(5-6):638-41.
5. Bishop PN. Molecular composition of the vitreous and aging changes. *Encyclopedia of the Eye.* 2010:37-43.
6. Fortes MB, Diment BC, Di Felice U, et al. Tear fluid osmolality as a potential marker of hydration status. *Med Sci Sports Exerc.* 2011;43(8):1590-7.
7. Sabetti L, Renzetti A, D'Alessandri L, Balestrazzi E. Eventual error caused by dehydration with pachometry. *Ophthalmologica.* 2001;215(2):97-101.
8. Hunt A, Feigl B, Stewart I. The intraocular pressure response to dehydration: a pilot study. *Eur J Appl Physiol.* 2012;112(5):1963-6.
9. Read SA, Collins MJ. Water drinking influences eye length and IOP in young healthy subjects. *Exp Eye Res.* 2010;91(2):180-5.
10. Susanna R Jr, Vessani RM, Sakata L, et al. The relation between intraocular pressure peak in the water drinking test and visual field progression in glaucoma. *Br J Ophthalmol.* 2005;89(10):1298-301.
11. Nowroozzadeh MH, Mirhosseini A, Meshkibaf MH, Roshannejad J. Effect of Ramadan fasting in tropical summer months on ocular refractive and biometric characteristics. *Clin Exp Optom.* 2012;95(2):173-6.
12. Inan UU, Yuçel A, Ermis SS, Öztürk F. The effect of dehydration and fasting on ocular blood flow. *J Glaucoma.* 2002;11(5):411-5.
13. Balk LJ, Sonder JM, Strijbis EM et al. The physiological variation of the retinal nerve fiber layer thickness and macular volume in humans as assessed by spectral domain-optical coherence tomography. *Invest Ophthalmol Vis Sci.* 2012;53(3):1251-7.
14. Nguyen L, Magno MS, Utheim TP, et al. The relationship between habitual water intake and dry eye disease. *Acta Ophthalmologica.* 2023;101(1):65-73.
15. Li A, Zhang X, Guo Y, et al. The association between dry eye and sleep disorders: the evidence and possible mechanisms. *Nat Sci Sleep.* 2022;14:2203-12.
16. Magno MS, Utheim TP, Snieder H, et al. The relationship between dry eye and sleep quality. *Ocul Surf.* 2021;20:13-9.

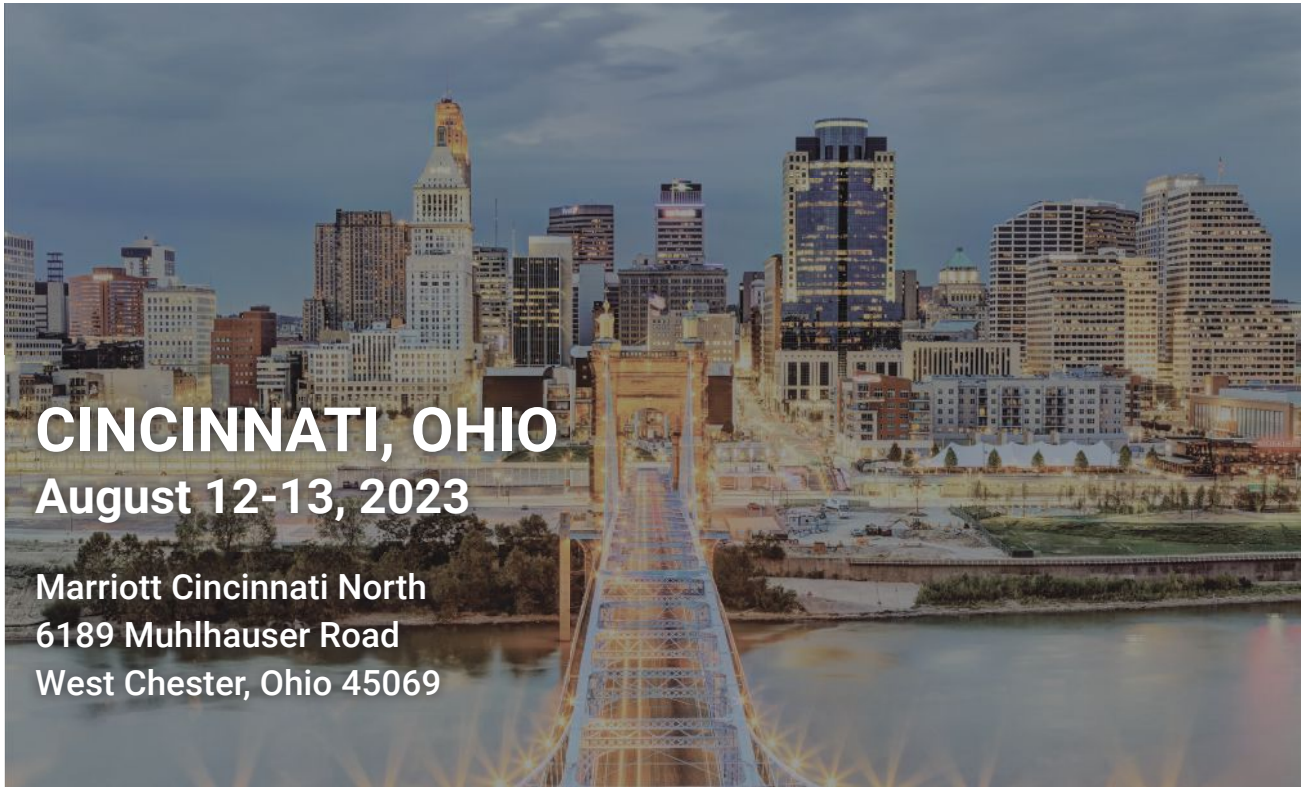MidWest  
Optometric  
Society



# MEDICAL OPTOMETRY IS OUR FUTURE

Glaucoma, Dry Eye, Cornea, Retina, Neuro, New Optometric Procedures

16 hours COPE accredited Optometric CE  
All 5 hours Kentucky ETP - Florida CE Broker



## CINCINNATI, OHIO August 12-13, 2023

Marriott Cincinnati North  
6189 Muhlhauser Road  
West Chester, Ohio 45069



**ELLIOT M. KIRSTEIN**  
OD, FAAO

**PINAKIN DAVEY**  
OD, PhD, FAAO

**TANIA PATEL**  
OD



**TODD A. ZELCZAK**  
OD, FAAO

**HAROON CHAUDHRY**  
MD

**HOWELL FINDLAY**  
OD

[www.mwoptsociety.com](http://www.mwoptsociety.com)  
513.448.0060



**THE OHIO STATE UNIVERSITY**  
COLLEGE OF OPTOMETRY

CO – SPONSORED BY THE OHIO STATE  
UNIVERSITY COLLEGE OF OPTOMETRY



# Tiny Red Flag, Big Issue

*An external injury nearly disguised an intraocular foreign body.*

**A** 34-year-old male presented to the ophthalmic emergency department with acute loss of vision in his right eye. He had been using a circular saw to cut a piece of wood at work and, although he endorsed wearing sunglasses at the time, he felt something hit his right eye. He proceeded to rinse the eye with water to remove any particulate matter.

On presentation, his visual acuity was 20/60 OD and 20/25 OS. Intraocular pressures (IOPs) were 17mm Hg OD and 15mm Hg OS. The pupils were noted to react briskly and equally to light without afferent pupillary defect. Extraocular motility testing was normal.

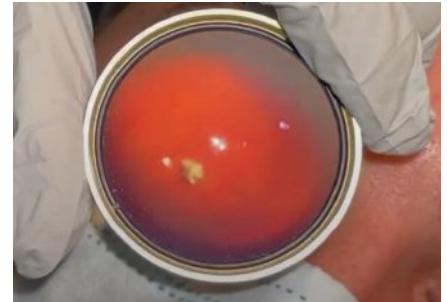On examination, the left eye was unremarkable. There was a small subconjunctival hemorrhage present nasally in the right eye, and within this area of hemorrhage, a very small 1mm conjunctival laceration was identified. Gentle exploration of the conjunctival laceration with a sterile cotton-tipped applicator and topical anesthetic did not reveal any foreign material nor provoke a positive Seidel sign. The cornea was clear aside from an old scar, but there were significant pigmented cells

in the anterior chamber. The vitreous appeared quiet without hemorrhage or white blood cells. With further fundus examination via indirect ophthalmoscopy, a small shiny foreign body was seen in the interior vitreous chamber just overlying the retina. There was no retinal tear or detachment appreciable.

Given that the foreign body was likely metallic and the patient did not know the date of his last tetanus vaccination, a TDAP (tetanus, diphtheria and pertussis) vaccine was administered in the emergency department. Upon further discussion, the patient reported he had last eaten about two hours prior to presentation, and therefore surgery to remove the foreign body would need to occur the following day. Throughout the evening and night, the patient instilled topical antibiotic drops to the right eye. Intravitreal antibiotics were considered but held due to the relative lack of intraocular inflammation at the time of his visit.

## Verdict

Our patient was diagnosed with an open globe injury with intraocular foreign body (IOFB) of the right eye.

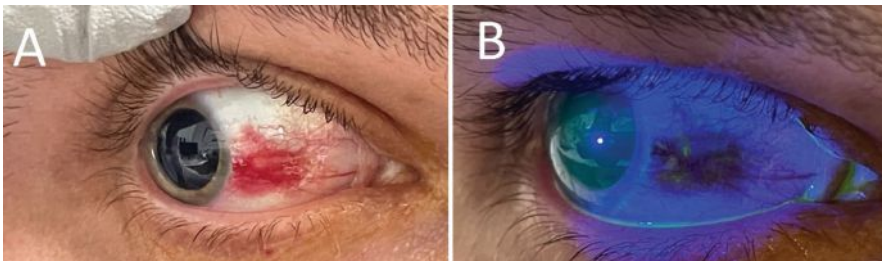

**An intraocular metallic shard was seen on binocular indirect ophthalmoscopy OD.**

At the time of his evaluation in the emergency department, the full thickness combined conjunctival and scleral wound was Seidel-negative and had already self-sealed. It is not uncommon for small, sharp projectile objects to create self-sealing wounds, making them hard to identify clinically.

Eyes with IOFBs are considered to have open-globe injuries due to the penetration of the eye wall. Of all open-globe injuries, it is estimated that anywhere between 18% to 41% have an IOFB present, most of which are in the posterior segment.<sup>1</sup> Over 90% of patients who present with an IOFB are young men 29 to 38 years of age, as they are particularly at risk for these injuries due to the kind of workplace environments they commonly dominate. The top causes of IOFBs include hammering, power tool use and weapon-related injuries.<sup>2,3</sup> The most commonly encountered IOFB material is metal, followed by organic or vegetative materials, stone, plastic and glass.<sup>1,3</sup> Since metallic IOFBs are commonly seen, it is important to recall the complications that can develop from iron (siderosis bulbi) and copper (chalcosis bulbi) degradation inside the eye, including retinal toxicity, severe intraocular inflammation, glaucoma, optic neuropathy and cataract formation.<sup>4</sup>

The visual outcome in patients with IOFBs varies widely and is related to



**(A) Right eye under white light, revealing a focal subconjunctival hemorrhage in an otherwise quiet-appearing eye. (B) After sodium fluorescein application, there was a tiny conjunctival defect appreciable in the area of hemorrhage.**

About  
**Dr. Bozung**

**Dr. Bozung** works in the Ophthalmic Emergency Department of the Bascom Palmer Eye Institute (BPEI) in Miami and serves as the clinical site director of the Optometric Student Externship Program as well as the associate director of the Optometric Residence Program at BPEI. She has no financial interests to disclose.

a number of different factors, including the initial visual acuity, presence of afferent pupillary defect, presence of intraocular hemorrhage, existence of retinal detachment, development of endophthalmitis and location and size of both the IOFB and entrance wound.<sup>3</sup>

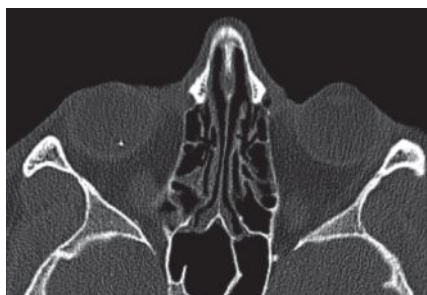## Discussion

When assessing a patient for any potential globe injury, obtaining a detailed history of the injury is critical. Doctors should inquire about the setting where the injury occurred (*e.g.*, home, work), what the patient was doing when the accident occurred and whether or not the patient was wearing any protective eyewear. It is also helpful to ask whether the patient attempted any interventions themselves and when they last ate or drank something.

Standard measures are taken for patients with ophthalmic trauma, including visual acuity, extraocular motilities, pupillary testing and IOP. In some cases—for example, an obviously open-globe or injury involving extraocular muscles—it may be prudent to avoid checking IOP or assessing ocular motility. Attention should be focused on the adnexa, assessing for any signs of lid laceration or orbital trauma.

Then, evaluation of the anterior and posterior segment is completed to the fullest extent possible. In some cases, a view of the posterior segment may be precluded by hemorrhage or cataract formation, so careful ultrasonography should be considered.

At times, especially when clinical exam alone cannot identify or exclude suspected IOFB, additional imaging may be useful. Typically, this would include plain film X-ray, computed tomography (CT) or magnetic resonance imaging (MRI). Of these, the CT orbit without contrast is the most commonly used and recommended study.<sup>3</sup> This is likely for a couple of reasons. First, plain film X-ray (radiography) may not capture or identify IOFBs that are very small or not considered radio-opaque.<sup>5</sup> Next, MRIs are contraindicated in any patient who is suspected to have trau-



**CT of the orbits with 1mm cuts was performed to rule out foreign material that missed on exam. A small, hyperdense body can be seen within the right globe.**

ma with metallic material, as the metal can become superheated and be mobilized by the magnetic field. This could lead to significant intraocular or intraorbital damage. Interestingly, in one rabbit model, researchers found that the size threshold required to demonstrate movement of a ferromagnetic IOFB when exposed to the MRI's magnetic field is about 3x1x1mm.<sup>6</sup> This and another case report series suggest that tiny metallic foreign bodies (<0.5mm) may not actually be mobilized during an MRI scan; however, this type of imaging is still not recommended due to the potential risks.<sup>7</sup> Lastly, MRI is generally more time-consuming and expensive to obtain when compared with a CT scan.

Unfortunately, CT imaging has its limitations as well, as not all IOFB materials can be captured easily. Standard CT scan cuts of 3mm are generally too spaced out to capture small foreign bodies, so 1mm cuts should be specified. Additionally, common materials that are not easily visualized with CT scans include wood and some plastics, so caution should be exercised when ruling out these types of IOFBs.<sup>8,9</sup>

## Outcome

The morning following presentation, our patient underwent surgery to remove the IOFB. A vitrectomy was performed, and the metallic shard was gently removed via a 2mm sclerotomy site that had been created with a blade. In cases such as this, a clean and controlled wound made intraoperatively by the surgeon is often ideal

compared with the entry site of the IOFB. The eye then underwent an air-fluid exchange and was filled with 20% SF<sub>6</sub> gas. Attention was focused on the initial wound to ensure it was still well-sealed. Finally, the sclerotomy sites and conjunctival tissues were closed. At the conclusion of the case, intravitreal vancomycin, ceftazidime and voriconazole were administered.

The patient presented for a one-day postoperative visit, at which point his vision was hand motion in the surgical eye, and the pressure was 18mm Hg. The retina was attached, and the patient was given strict return precautions with restrictions including wearing a protective hard shield over the surgical eye at all times, avoiding heavy lifting or bending and keeping water out of the eye.

By his three-week postoperative follow-up, the patient's vision had improved to 20/200 with a residual gas bubble, and IOP remained stable. OCT of the retina was completed and confirmed normal macular anatomy, suggesting a good visual prognosis. At this time, the patient, who lived in a different state, was anxious to return home and was advised to do so by driving (rather than flying) due to the retained intraocular gas bubble. He was given recommendations to continue follow-up care locally. ■

1. Loporchio, D., et al., Intraocular foreign bodies: A review. *Surv Ophthalmol*, 2016. 61(5): p. 582-96.

2. Greven, C.M., et al., Intraocular foreign bodies: management, prognostic factors, and visual outcomes. *Ophthalmology*, 2000. 107(3): p. 608-12.

3. Jung, H.C., et al., Intraocular Foreign Body: Diagnostic Protocols and Treatment Strategies in Ocular Trauma Patients. *J Clin Med*, 2021. 10(9).

4. Casini, G., et al., Ocular siderosis: a misdiagnosed cause of visual loss due to ferrous intraocular foreign bodies—epidemiology, pathogenesis, clinical signs, imaging and available treatment options. *Doc Ophthalmol*, 2021. 142(2): p. 133-152.

5. Saeed, A., et al., Plain X-ray and computed tomography of the orbit in cases and suspected cases of intraocular foreign body. *Eye (Lond)*, 2008. 22(11): p. 1373-7.

6. Williams, S., et al., Ferrous intraocular foreign bodies and magnetic resonance imaging. *Am J Ophthalmol*, 1988. 105(4): p. 398-401.

7. Zhang, Y., et al., Tiny ferromagnetic intraocular foreign bodies detected by magnetic resonance imaging: a report of two cases. *J Magn Reson Imaging*, 2009. 29(3): p. 704-7.

8. Rong, A.J., et al., Multimodal imaging features of intraocular foreign bodies. *Semin Ophthalmol*, 2019. 34(7-8): p. 518-532.

9. Modjtahedi, B.S., et al., Imaging characteristics of intraocular foreign bodies: a comparative study of plain film X-ray, computed tomography, ultrasound, and magnetic resonance imaging. *Retina*, 2015. 35(1): p. 95-104.



BY NATE LIGHTHIZER, OD

## ADVANCED PROCEDURES

# Lose that Lump

*Intralesional injection can help patients who want a less invasive option for treating their chalazion.*

BY BLAIR LONSBERRY, OD, MS, MED  
FOREST GROVE, OR

**A**s optometry continues to lobby for expanded scope of practice, a lot of attention is focused on the use of lasers. An area equally important for most optometrists to incorporate into their practice is the injection of corticosteroids into chalazia. The procedure is straightforward and provides a non-surgical option to management. Surgical incision and curettage of a chalazion has a high success rate (upwards of 92% after a single procedure) but is also an invasive technique requiring the injection of an anesthetic, clamping of the lesion, incision and subsequent curettage.<sup>1</sup>

An alternative that is very attractive to many patients is an injection of triamcinolone acetonide into the

lesion. Several studies have demonstrated the success of intralesional steroid injections for chalazia with a success rate in some studies over 90%, depending on the concentration of the steroid injected and number of injections.<sup>2</sup>

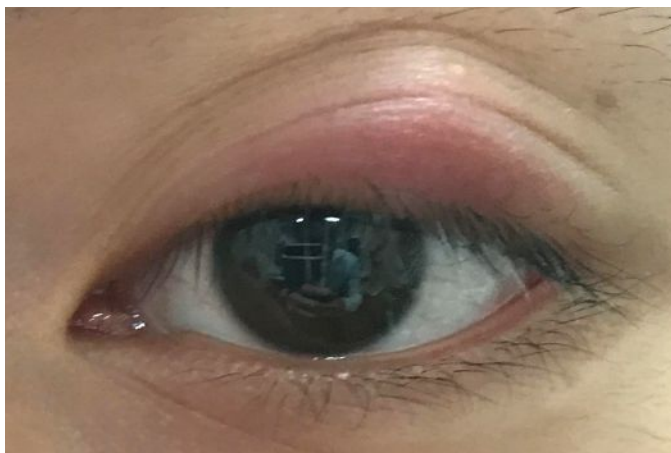### Background and Mechanism

The use of depot steroid of triamcinolone acetonide has been widely used in many ophthalmic diseases and procedures such as intralesional injections of granulomas and treatment of periocular scars. It has anti-inflammatory, anti-VEGF and antifibrotic properties.<sup>3</sup> Chalazia are composed of corticosteroid-sensitive inflammatory cells. These inflammatory cells cause exudation, which can compress the lymphatic vessels and lead to an alteration in lymphatic vessels that results in granuloma formulation in the

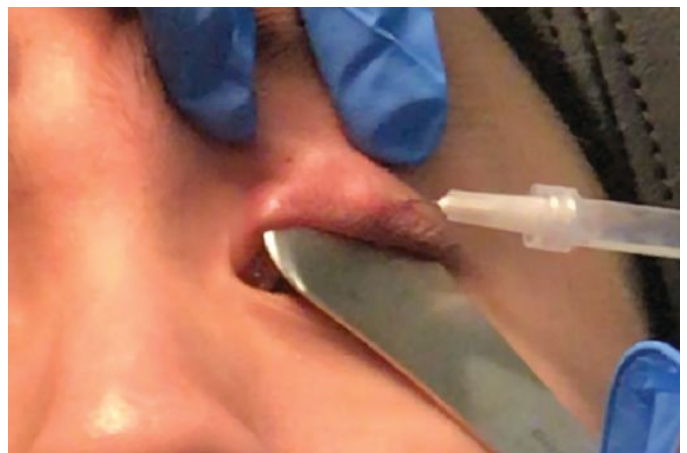lids. The presumed action of depot corticosteroid is suppressing additional release of inflammatory cells and reducing exudation of plasma fluids. The inhibition of further production of inflammatory cells and reduction of plasma fluid exudation can lessen the compressive effect and facilitate the lymphatic absorption of the chalazion's contents.<sup>4</sup>

Triamcinolone acetonide is the typical corticosteroid used in intralesional injections. A single dose of intralesional injection of higher concentration of triamcinolone acetonide at 40mg/mL is more effective than at 10mg/mL; however, there is also an increased chance of potential complications.<sup>5</sup> There are two main routes of injection—transcutaneous or transconjunctival—with or without topical or injected anesthesia.

Transcutaneous injection tends to be the most popular as there is less pain for the patient and is often the easiest and most efficient. The transconjunctival route is preferred for those patients with whom there is a larger concern for skin depigmentation at the injection site.<sup>1</sup> The



**Fig. 1.** Chalazion of the left upper lid that has been present for one month.



**Fig. 2.** Injection of triamcinolone acetonide into and around the chalazion showing proper angle of the needle.

About  
Dr. Lighthizer

Dr. Lighthizer is the associate dean, director of continuing education and chief of specialty care clinics at the NSU Oklahoma College of Optometry. He is a founding member and immediate past president of the Intrepid Eye Society. Dr. Lighthizer's full disclosure list can be found in the online version of this article at [www.reviewofoptometry.com](http://www.reviewofoptometry.com).



# Which Slit Lamp Camera do I choose?

**Platinum** (workhorse). . .

**Gold** (budget friendly). . .

**Diamond** (maximum clarity & resolution)

**Time to Call *TelScreen!***  
**502.515.1806**



We deliver everything you need for quick & comprehensive patient education.

**EyeRes**<sup>TM</sup>  
Digital Imaging Systems  
by **TelScreen**



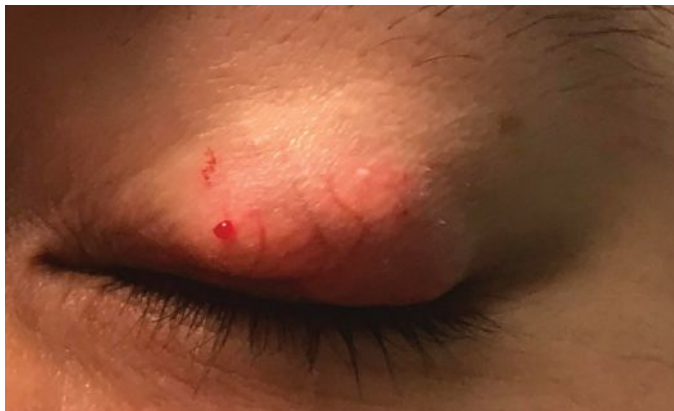[www.TelScreen.com](http://www.TelScreen.com)



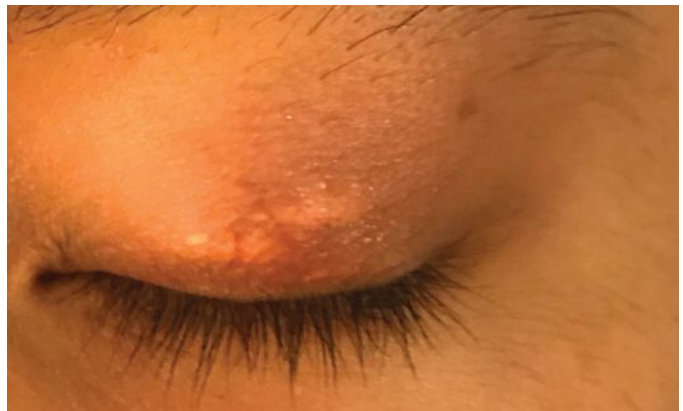@telscreen



@telscreen



**Fig. 3.** Patient has received an injection of triamcinolone 40mg/mL from both the temporal and nasal aspect of the chalazion.



**Fig. 4.** Skin deposits of steroid after the injection. Let the patient know this will happen and is not skin depigmentation.

most common adverse reaction to this treatment is skin depigmentation (particularly in darkly pigmented patients), but using a transconjunctival approach to injection reduces this risk. Triamcinolone acetonide is commonly used for many skin lesions, and skin hypopigmentation has been reported in 1.3% to 6% of cases.<sup>6</sup>

The advantages of intralesional injection of this steroid are many: it is a simple outpatient procedure typically with little to no bleeding, anesthesia injection is not required, multiple chalazia can be treated at a time, there is no post-procedure scarring and it is useful in children and anxious patients. Potential complications that have been reported after injection of a chalazion include hypopigmentation or depigmentation of lid skin, yellow or white deposits in the lid skin, subconjunctival eyelid fat atrophy, steroid-induced glaucoma, subcapsular cataract and second injection. Reported complications from the injection process include possible corneal perforation with traumatic cataract by injection needle, as well as microembolism of retinal and choroidal vasculature that can lead to infarction.<sup>5</sup>

### Procedural Technique

The equipment needed typically includes:

- Topical anesthetic drops (*i.e.*, proparacaine).
- Alcohol pads for cleaning the top of the medication bottle and for the patient's lid.

- A 1cc or 3cc syringe.
- An 18-gauge needle for medication draw up.
- A 25- to 27-gauge needle for the injection.
  - 10mg/mL or 40mg/mL triamcinolone acetonide (the two of us exclusively use 40mg/mL).
  - Gauze for any potential bleeding and putting pressure on lid after injection.
  - A sharps container.
  - A betadine swabstick for additional disinfection of the lid (optional).
  - A Jaeger plate for protection of the globe during the injection (optional).

Prior to the procedure, educate the patient about the options available to them, which include leaving the lesion alone (as this is a cosmetic reason for treatment), intense pulsed light therapy, intralesional injection or incision and curettage. Make them aware about possible complications.

Skin depigmentation is likely the most concerning side effect of the injection. I have not seen any depigmentation in Asian or Latinx patients. A patient of African American descent, darkly pigmented skin or one that is concerned about skin depigmentation is often recommended a transconjunctival injection or other potential treatment options. Have the patient fill out and sign a patient consent form that describes the procedure in layman's terms and potential side effects and have both the patient and the practitioner sign it.

*Figure 1* depicts a patient with a chalazion of the left upper lid that has been there for approximately one month. The patient agreed to proceed with a 0.3cc triamcinolone acetonide 40mg/mL injection. A drop of anesthetic was instilled into each eye, and the left upper lid was cleaned with an alcohol wipe. The patient was reclined in the exam chair so that we could approach them from behind to perform the injection. Most injections are done at an angle, but the approach with a chalazion injection is completely parallel to skin (*Figure 2*). If the lesion is approached at an angle, it is more likely for the needle to go through the lid and possibly hit the globe. There is the option to use a Jaeger plate, which is applied under the lid to protect the globe; however, the plate stretches the skin and can make localization of the chalazion more challenging.

At first impression, you think you would want to inject directly into the chalazion; however, it is difficult to inject into a solid lesion. It is better to start your injection into the skin in front of the lesion and then push the needle forward until it pierces the lesion. As you begin to inject the steroid, you will notice that it is challenging to push it out of the needle; that is because you are in a solid lesion. Don't push harder and end up moving the needle forward through the lesion. As you continue to try and push steroid out of the

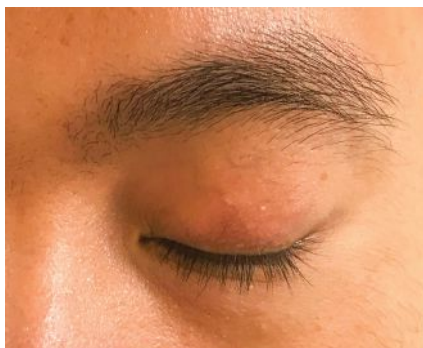needle, you are going to slowly pull out of the lesion, and you will see the skin puff up, indicating that you are injecting steroid into the skin that surrounds the lesion. If the lesion is larger, you can inject the other side of the lesion in the same way by approaching it completely parallel to the skin and piercing the skin outside of the lesion first. *Figure 3* shows the lid after the injection of steroid from both the temporal and nasal side.

### Post-Procedure and Follow-Up

Tell the patient to leave the lesion alone for several days, *i.e.*, to not push or massage the area. It is important to try and not force the steroid away from the lesion. The steroid is in suspension, and the liquid aspect of the steroid gets absorbed rapidly, leaving behind a depot or deposit of steroid. *Figure 4* depicts the deposits of steroid in the injection site. These deposits are not skin depigmentation and may last from four to six weeks after the injection. After three to four days, the patient can begin their warm compresses and gentle lid massage again.

Follow-up with the patient typically in two weeks to see how they are progressing. If at two weeks, the lesion looks reduced and there are still steroid deposits in the skin, the patient is told to continue the warm compresses and lid massage and to return if the lesion doesn't completely resolve. *Figure 5* shows the patient four weeks after their steroid injection with complete resolution of the chalazion.

Conversely, if at the initial two- to three-week follow-up the lesion does not look like it has reduced and there are no steroid deposits, give the patient the option of another injection. Alternatively, they can continue to do the warm compresses and massage and return in another two weeks for an injection if there is no further resolution. Keep educating patients on how to prevent further development of chalazia with good lid hygiene practices.



**Fig. 5. Resolution of the chalazion four to five weeks post-injection.**

Be sure to document all aspects of the procedure and patient education in both the assessment and plan area, as well as in the narrative of the procedure order (CPT 11900: injection, intralesional; up to and including seven lesions). You will also need to document the amount and concentration of triamcinolone injected, the lot number and the expiration date.

Incorporating steroid injections into your practice is a relatively straightforward process with limited specialized equipment and will provide a much-needed treatment option for your patients. The first injection is the scariest! However, after that one you will feel comfortable that this is a procedure that optometrists can readily offer our patients. ■

1. Aycinena AR, Achiron A, Paul M, Burgansky-Eliash Z. Incision and curettage vs. steroid injection for the treatment of chalazia: a meta-analysis. *Ophthalmic Plast Reconstr Surg.* 2016;32(3):220-4.
2. Mohan K, Dhir SP, Munjal VP, Jain IS. The use of intralesional steroids in the treatment of chalazion. *Ann Ophthalmol.* 1986;18(4):158-60.
3. Bartlett JD, Jaanus SD. *Clinical Ocular Pharmacology.* 5th ed. Butterworth-Heinemann/Elsevier, 2008.
4. Agliano M, Lorenzoni P, Volpi N, et al. Lymphatic vessels in human eyelids: an immunohistological study in dermatochalasia and chalazion. *Lymphology.* 2008;41(1):29-39.
5. Lee JW, Yau GS, Wong MY, Yuen CY. A comparison of intralesional triamcinolone acetonide injection for primary chalazion in children and adults. *ScientificWorldJournal.* 2014;2014:413729.
6. Martins N, Polido-Pereira J, Caneira M, Fonseca JE. Treatment of persistent cutaneous atrophy after corticosteroid injection with fat graft. *Reumatol Clin (Engl Ed).* 2019;15(6):e122-4.

### ABOUT THE AUTHOR

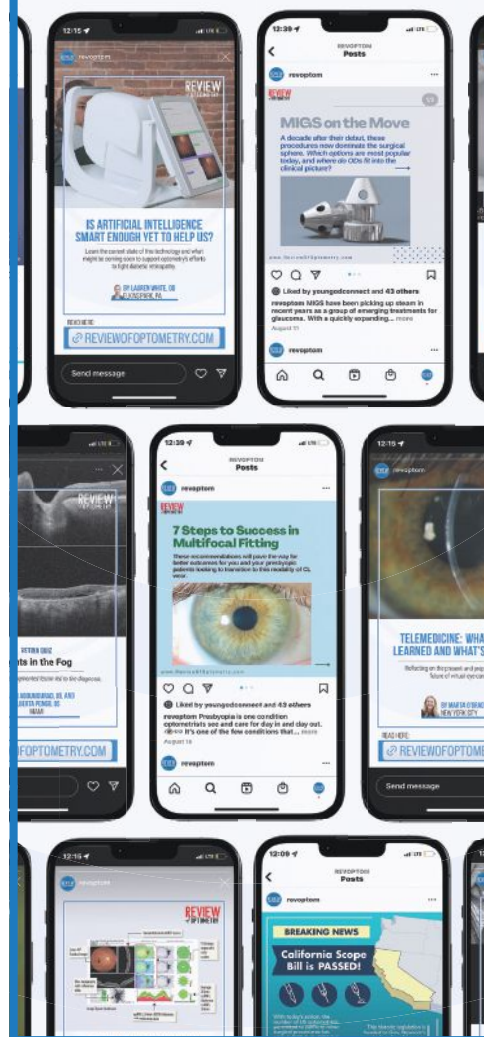


**Dr. Lonsberry** is a professor of optometry at Pacific University College of Optometry.

# A NEW WAY TO EXPERIENCE REVIEW OF OPTOMETRY

Follow us on Instagram for striking clinical images, news headlines, issue previews and great content from the magazine—all formatted for mobile.

 @REVOPTOM





# Spot the Problem

*What do these distinctive lesions represent?*

BY RAMI ABOUMOURAD, OD, AND JOSHUA BLACK, OD  
MIAMI

**A** 78-year-old Caucasian male was referred to our institute for evaluation. Past medical history was extensive, with a family history of cancer, which notably included the patient's lung cancer diagnosis; he underwent resection one year prior with subsequent chemotherapy infusions every 21 days. Past ocular history included cataract surgery in both eyes over a decade ago. He was a cigarette smoker for many years and denied any history of illicit drug use.

Best-corrected visual acuity was 20/25 OD and OS. Confrontation visual fields were full to finger counting, extraocular motilities were full and pupils were equal in size without an afferent pupillary defect OU. IOP was 14mm Hg OD and 13mm Hg OS. Anterior segment exam revealed multiple pigmented iris lesions OU and posterior chamber intraocular lenses with clear posterior capsules OU. Fundus imaging is shown below.

## Take the Retina Quiz

1. Upon review of the images, all of the below are true except:

- a. There are bilateral multifocal melanocytic lesions.
- b. FAF displays diffusely stippled hypo- and hyperautofluorescence throughout the posterior pole OU.
- c. OCT of the right eye demonstrates a thickened and homogeneously hyperreflective choroidal lesion in the nasal macula.
- d. All of the above are true.

2. What is the most likely diagnosis?

- a. Bilateral diffuse uveal melanocytic proliferation.
- b. Choroidal metastases.
- c. Uveal melanoma.
- d. Uveal effusion syndrome.

3. Which of the following is NOT associated with vision loss in this condition?

- a. Rapid development of cataracts.
- b. Exudative retinal detachment.
- c. Infiltrative optic neuropathy.
- d. All of the above are associated with vision loss.

4. What is the most appropriate management for this patient?

- a. Close observation.
- b. High-dose oral corticosteroids.
- c. Intravitreal injection of an anti-VEGF agent.
- d. Rapid initiation of plasmapheresis.

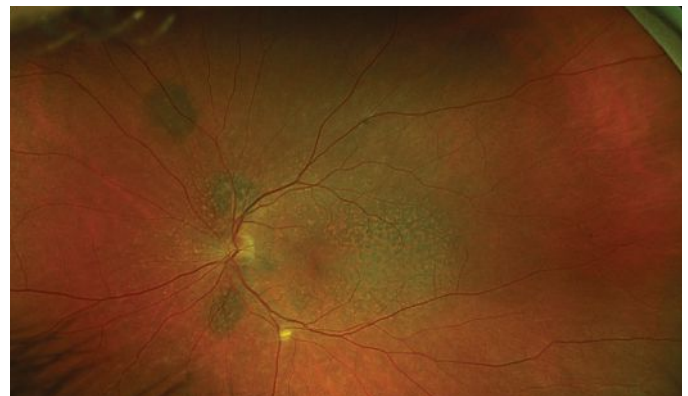
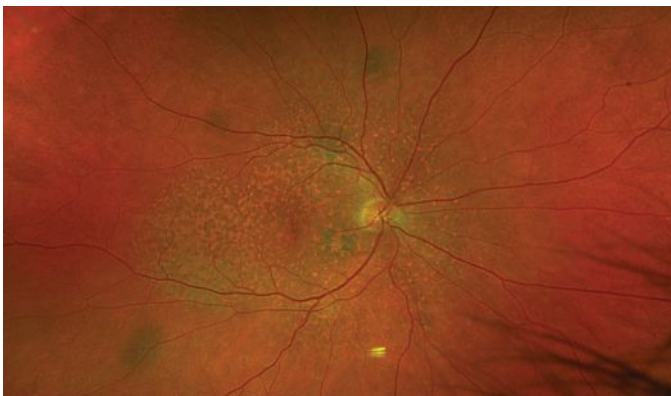
5. Which of the following is true?

- a. Breast cancer is the most common malignancy associated with this condition.
- b. Diplopia is a common associated finding due to extraocular muscle infiltration.
- c. The overall prognosis is poor and average survival is 19 months from the time of visual symptom onset.
- d. All of the above.

*For answers to the quiz, see page 90.*

## Diagnosis

Fundus exam revealed diffuse multifocal reddish-orange patches creating a mottled reticular appearance of the posterior fundus with multiple scattered uveal melanocytic lesions OU. OCT showed irregular retinal pigment epithelial aggregations without subretinal fluid, as well as thickening and hyperreflectivity of the choroid corresponding with the melanocytic lesions. FAF revealed a characteristic



**Fig. 1.** Optos ultrawide fundus photograph of the right eye.

**Fig. 2.** Optos ultrawide fundus photograph of the left eye.

### About Dr. Dunbar

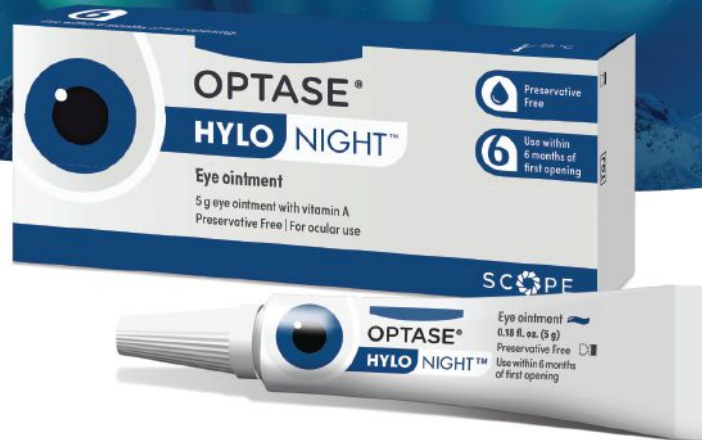**Dr. Dunbar** is the director of optometric services and optometry residency supervisor at the Bascom Palmer Eye Institute at the University of Miami. He is a founding member of the Optometric Glaucoma Society and the Optometric Retina Society. Dr. Dunbar is a consultant for Carl Zeiss Meditec, Allergan, Regeneron and Genentech.

**NEW**

Marketed as VitA-POS and HYLO Night in Europe.  
Now available in the US.

# OPTASE® HYLO NIGHT™

THE DRY EYE OINTMENT WITH A DIFFERENCE



Preservative  
FREE



Sterile for  
6 Months



Well  
Tolerated



300  
Applications



6 Hours  
Comfort & Relief

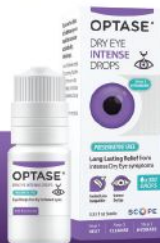

Contains  
Vitamin A\*

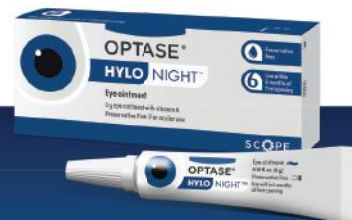## OPTASE® HYLO NIGHT™ & DRY EYE INTENSE DROPS

Bring comfort and relief to your patients **day and night**

OPTASE® DRY EYE INTENSE DROPS



OPTASE® HYLO NIGHT™



24hr Dry Eye Management

\*Vitamin A (Retinol Palmitate) is an inactive ingredient in OPTASE® HYLO NIGHT™

For more information visit [optase.com](http://optase.com)

**SCOPE**

SCOPEUS036

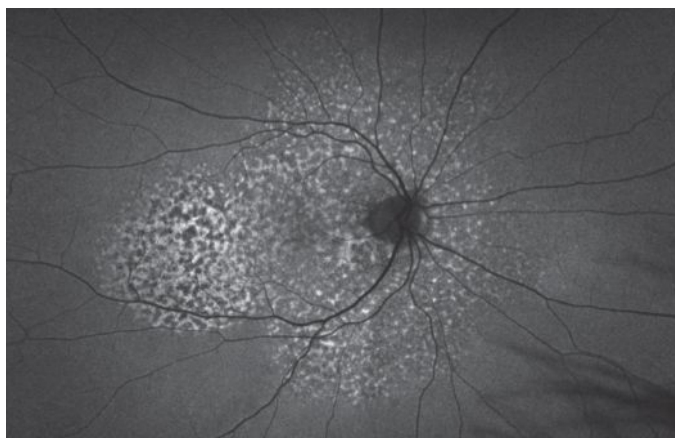


Fig. 3. Optos FAF of the right eye.

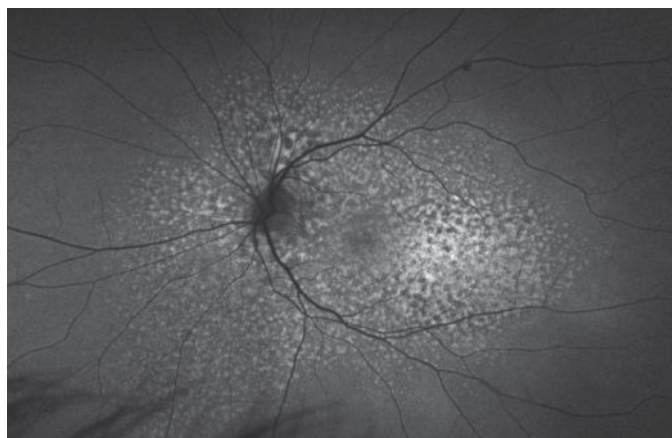


Fig. 4. Optos FAF of the left eye.

“leopard spot” pattern consisting of diffuse areas of stippled hypo- and hyperautofluorescence. Angiography and echography were also obtained but not included due to space constraints. Fluorescein angiography displayed a distinct appearance of patchy early hypo- and hyperfluorescence corresponding to the findings on FAF, and indocyanine green angiography confirmed that the foci of melanocytic lesions were choroidal with discrete areas of hypocyanescence. This constellation of findings is consistent with the presentation of bilateral diffuse uveal melanocytic proliferation (BDUMP).

### Discussion

BDUMP is a rare paraneoplastic syndrome in which melanocytic tumors arise in the uveal tract in patients with systemic carcinomas.<sup>1,2</sup> The clinical presentation was first described in 1966 in a patient with bilateral acquired uveal melanocytic lesions in the setting of pancreatic carcinoma.<sup>3</sup> There have been less than 100 cases reported in literature, and, on average, about four documented cases annually as of 2017.<sup>4,6</sup> Histopathology and cytology have confirmed the benignity of these lesions.<sup>5-7</sup> Ophthalmic manifestations may precede or follow the diagnosis of systemic carcinoma.<sup>7</sup>

While the exact pathophysiology of BDUMP is poorly understood due to its rarity, it is proposed that

a serum borne tumor-produced factor—cultured melanocyte elongation and proliferation (CMEP)—leads to melanocyte proliferation and, thus, acquired melanocytic lesions of the uveal tract.<sup>5,8</sup> It is unclear if both the systemic carcinoma of uveal proliferations are secondary to a common stimulus, if the CMEP is released by the systemic carcinoma or is there is another process involved.<sup>5-7</sup> While BDUMP can be seen in association with any systemic malignancy, lung cancers are the most common in men, and reproductive tract cancers are the most common in women.<sup>9</sup>

These melanocytic lesions may infiltrate the iris, ciliary body and choroid, resulting in a breach in the blood-aqueous barrier and/or blood-retinal barrier via either direct or indirect mechanisms.<sup>7</sup> Additionally, infiltration of the anterior uveal tract may induce metabolic dysfunction and secondary rapid cataract formation.<sup>5-7</sup> In 1990, five cardinal ocular signs were proposed:<sup>1</sup>

- (1) Multiple round or oval subtle red patches at the level of the RPE in the posterior fundus.
- (2) Multifocal areas of early hyperfluorescence corresponding with these patches.
- (3) Development of multiple, slightly elevated, pigmented and non-pigmented uveal melanocytic tumors, as well as evidence of diffuse thickening of the uveal tract.
- (4) Exudative retinal detachment.
- (5) Rapid progression of cataracts.

Vision loss primarily occurs by rapid cataract progression or loss of retinal function. Loss of retinal function may take place by either chronic exudative retinal detachment and its sequelae or by presumed toxic or immune-mediated destruction to the retina and retinal pigment epithelium (RPE).<sup>5,7</sup> Histopathology has revealed that the characteristic fundus appearance of reddish-orange patches is related to RPE depigmentation overlying diffuse uveal infiltration of hypopigmented melanocytic proliferations.<sup>6,7</sup>

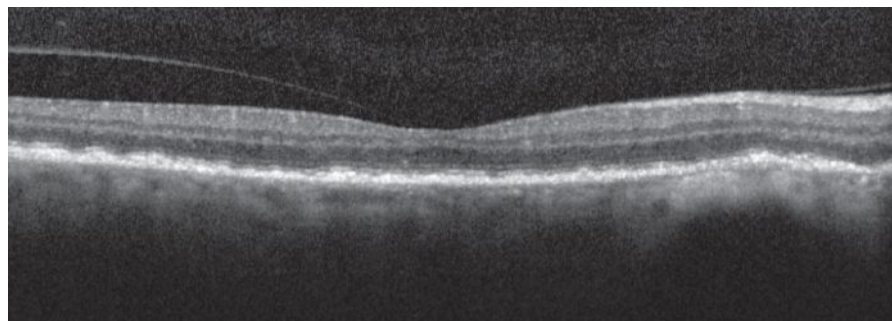


Fig. 5. Heidelberg macular OCT of the right eye.

This results in the reticular pattern that we refer to as leopard spots.<sup>6,7</sup>

## Observation

In the absence of exudative retinal detachment, these patients are closely observed, with an emphasis often placed on addressing the primary malignancy.<sup>5,7-9</sup> The serum-borne nature of CMEP factor suggests there may be a role for plasmapheresis, which has been shown effective in some cases.<sup>5,7-10</sup> Furthermore, local/systemic corticosteroids and various forms of radiation/brachytherapy have been attempted without success.<sup>5,7-9</sup>

While data is scarce due to the rarity of the condition, the prognosis for patients with BDUMP is poor, as the average time to mortality after onset of visual symptoms is 19 months. Survival beyond seven years is rare; nearly all patients ultimately died from dissemination of the primary malignancy.<sup>1,5</sup>

This patient's presentation of numerous bilateral melanocytic lesions of the anterior and posterior uveal tracts suggested that they were acquired. Furthermore, he had never been told of any "freckles" or pigmented lesions in the past. He was managed with close observation given the absence of exudative retinal detachment in both eyes. Concern for rapid cataract progression was not applicable given his pseudophakic status.

In summary, the discovery of bilateral acquired uveal melanocytic lesions should prompt investigation for a systemic malignant neoplasm if not already known to the patient. ■

1. Gass JD, Gieser RG, Wilkinson CP, et al. Bilateral diffuse uveal melanocytic proliferation in patients with occult carcinoma. *Arch Ophthalmol*. 1990;108(4):527-33.
2. Saito W, Kase S, Yoshida K, et al. Bilateral diffuse uveal melanocytic proliferation in a patient with cancer-associated retinopathy. *Am J Ophthalmol*. 2005;140(5):942-5.
3. Macherer R. [On the pathogenesis of the flat malignant melanoma]. *Klin Monbl Augenheilkd*. 1966;148(5):641-52.

4. Barr CC, Zimmerman LE, Curtin VT, Font RL. Bilateral diffuse melanocytic uveal tumors associated with systemic malignant neoplasms. A recently recognized syndrome. *Arch Ophthalmol*. 1982;100(2):249-55.
5. Klemp K, Kiilgaard JF, Heegaard S, et al. Bilateral diffuse uveal melanocytic proliferation: Case report and literature review. *Acta Ophthalmol*. 2017;95(5):439-45.
6. Ryan SJ, Davis JL, Flynn HW, et al. *Retina*. Fifth ed. Saunders/Elsevier; 2013.
7. Agarwal A, Gass JDM. *Gass' Atlas of Macular Diseases*. Fifth ed. Elsevier; 2011.
8. Miles SL, Niles RM, Pittock S, et al. A factor found in the IgG fraction of serum of patients with paraneoplastic bilateral diffuse uveal melanocytic proliferation causes proliferation of cultured human melanocytes. *Retina*. 2012;32(9):1959-66.
9. Moreno TA, Patel SN. Comprehensive review of treatments for bilateral diffuse uveal melanocytic proliferation: a focus on plasmapheresis. *Int Ophthalmol Clin*. 2017;57(1):177-94.
10. Kiryakoza LC, Diaz JD, Priluck J, et al. A case of bilateral diffuse uveal melanocytic proliferation in the setting of urothelial carcinoma of the ureter: a failed response to plasmapheresis. *Ophthalmic Surg Lasers Imaging Retina*. 2022;53(6):350-3.

## ABOUT THE AUTHORS



**Drs. Aboumourad and Black** currently practice at Bascom Palmer Eye Institute in Miami. Neither has any financial disclosures.

## ADVERTISER INDEX

This advertiser index is published as a convenience and not as part of the advertising contract. Every care will be taken to index correctly. No allowance will be made for errors due to spelling, incorrect page number, or failure to insert.

Alcon .....	COVER 4
.....	<a href="http://www.Alcon.com">www.Alcon.com</a>
Allergan.....	COVER TIP
.....	<a href="http://www.allergan.com">www.allergan.com</a>
Bruder Healthcare Company .....	53
.....	(888) 827-8337
.....	<a href="mailto:eyes@bruder.com">eyes@bruder.com</a>
.....	<a href="http://www.bruder.com">www.bruder.com</a>
Coburn Technologies .....	33
.....	(800) COBURN-1
.....	<a href="http://www.coburntechnologies.com">www.coburntechnologies.com</a>
CooperVision .....	COVER 3
.....	<a href="http://mindsight.com">mindsight.com</a>
Dompe.....	59-60
.....	<a href="http://www.oxervate.com/HCP">www.oxervate.com/HCP</a>
Eye Designs .....	21
.....	(800) 346-8890
.....	<a href="http://www.eyedesigns.com">www.eyedesigns.com</a>

Eyefficient.....	73
.....	800-417-8136
.....	<a href="http://www.eyefficient.com">www.eyefficient.com</a>
Icare USA .....	25
.....	(888) 422-7313
.....	<a href="mailto:infoUSA@icare-world.com">infoUSA@icare-world.com</a>
.....	<a href="http://www.icare-world.com/USA">www.icare-world.com/USA</a>
Imprimis Pharmaceuticals, Inc. ....	11
.....	<a href="http://www.simpledrops.com">www.simpledrops.com</a>
Iveric Bio .....	15
.....	<a href="http://www.IvericBio.com">www.IvericBio.com</a>
Lacrivera .....	37
.....	855-857-0518
.....	<a href="http://www.lacrivera.com">www.lacrivera.com</a>
LKC.....	13
.....	<a href="http://www.lkc.com">www.lkc.com</a>
Meivertor .....	47
.....	<a href="http://Meivertor.com">Meivertor.com</a>
Menicon .....	57
.....	(800) 636-4266
.....	<a href="http://www.meniconamerica.com">www.meniconamerica.com</a>
Novartis Pharmaceuticals.....	28-30
.....	<a href="http://www.novartis.com">www.novartis.com</a>

Oasis Medical .....	7
.....	(844) 820-8940
.....	<a href="mailto:customerservice@oasismedical.com">customerservice@oasismedical.com</a>
.....	<a href="http://www.oasismedical.com">www.oasismedical.com</a>
Oasis Medical .....	45
.....	(844) 820-8940
.....	<a href="mailto:customerservice@oasismedical.com">customerservice@oasismedical.com</a>
.....	<a href="http://www.oasismedical.com">www.oasismedical.com</a>
Oculus, Inc.....	39
.....	(888) 519-5375
.....	<a href="mailto:ads@oculususa.com">ads@oculususa.com</a>
.....	<a href="http://www.pentacam.com">www.pentacam.com</a>
Scope Eyecare .....	83
.....	<a href="http://www.scopeeyecare.com">www.scopeeyecare.com</a>
Tarsus .....	17
.....	<a href="http://www.tarsusrx.com">www.tarsusrx.com</a>
TelScreen .....	79
.....	<a href="http://www.TelScreen.com">www.TelScreen.com</a>
Thea Pharma .....	19
.....	<a href="http://www.acelfx.com">www.acelfx.com</a>
Thea Pharma .....	23
.....	<a href="http://www.ivizia.com/ecp">www.ivizia.com/ecp</a>
Thea Pharma .....	COVER 2-3
.....	<a href="http://www.theapharmainc.com">www.theapharmainc.com</a>



BY DEREK N. CUNNINGHAM, OD, AND  
WALTER O. WHITLEY, OD, MBA

## SURGICAL MINUTE

# More MIGS on the Way

*Two new implants are bound to make a significant impact for your glaucoma patients.*

**M**inimally invasive glaucoma surgeries (MIGS) have been revolutionary in the treatment of glaucoma. Although drops have traditionally been the mainstay of care, many eyecare providers are seeking other procedural and surgical options to lower and control intraocular pressure (IOP). Essentially, these alternate treatment options are termed “interventional glaucoma,” which is a mindset on how we can proactively approach glaucoma treatment while minimizing compliance issues and side effects and improve patients’ quality of life. From selective laser trabeculoplasty to intracameral injections and MIGS, these treatments all play a larger role in glaucoma management.

One of these treatments is stenting the canal, which improves aqueous outflow through the trabecular outflow pathway and has proven to be safe and effective. We will discuss two of the latest stent additions to keep on your radar—iStent Infinite (Glaukos) and iDose TR (Glaukos).

## iStent Infinite

Granted clearance by the FDA last year, this device is the first standalone implantable device for patients with primary open-angle glaucoma where previous medical and surgical treatments have failed. These patients are

For a video of the procedure, read this article online at [www.reviewofoptometry.com](http://www.reviewofoptometry.com).

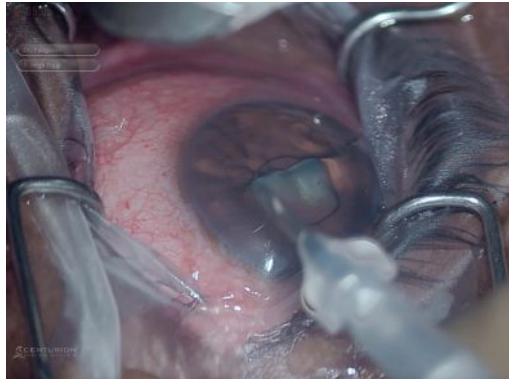

Photo: Akshay Yadegari, MD

**iStent Infinite and iDose TR have proven to be safe and effective MIGS procedures to lower IOP and improve aqueous outflow.**

those who have had previous glaucoma filtering surgeries or cilioablativ procedures without success.

So, what’s the difference with iStent Infinite? Instead of using two heparin-coated titanium stents, like the iStent inject W (Glaukos), iStent Infinite includes three stents preloaded into an auto-injector system. Stents are inserted along approximately six clock hours around Schlemm’s canal and are designed to lower IOP by restoring the natural physiological outflow of aqueous humor.

In a recent study, 76.1% of patients met the responder endpoint of >20% mean diurnal IOP reduction at 12 months. For patients on the same or fewer medication(s) as baseline, 53% achieved ≥30% mean diurnal IOP reduction without surgical interventions/other events. There were no explants, infections or device-related interventions or hypotony.<sup>1</sup>

## iDose TR

This stent has been in development for many years and its New Drug Application (NDA) was recently submitted to the FDA. The iDose TR, also from Glaukos, is an intraocular implant designed to continuously deliver travoprost from within the anterior chamber for extended periods of time. The device is designed such that it can be removed and replaced with a new iDose TR, potentially offering a long-term dropless alternative to a regimen of daily topical therapy.<sup>2</sup>

The NDA submission includes data from two Phase III pivotal trials, which both successfully achieved the prespecified primary efficacy endpoints through three months and demonstrated tolerability and safety through 12 months. The application also includes data from the iDose TR exchange trial, which included a second administration of the implant and removal of the original iDose TR, with the second administration demonstrating a favorable safety profile over 12 months.<sup>2</sup>

We have all seen patients who continuously progress no matter our pharmaceutical or surgical treatments and there is a need for effective MIGS procedures, such as stents. These new stents are a bridge between first-line therapies, potentially a pivotal moment in glaucoma care. Postoperative care is expected to be similar to current MIGS procedures; it is important to discuss this with your comanaging surgeon. ■

1. Sarkisian SR Jr, Grover DS, Gallardo MJ, et al. iStent Infinite Study Group. Effectiveness and safety of iStent Infinite trabecular micro-bypass for uncontrolled glaucoma. *J Glaucoma*. 2023;32(1):9-18.

2. Glaukos submits new drug application to U.S. FDA for iDose TR. [www.investors.glaukos.com/investors/news/news-details/2023/Glaukos-Submits-New-Drug-Application-to-U.S.-FDA-for-iDose-TR/default.aspx](http://www.investors.glaukos.com/investors/news/news-details/2023/Glaukos-Submits-New-Drug-Application-to-U.S.-FDA-for-iDose-TR/default.aspx). February 27, 2023. Accessed March 20, 2023.

About Drs.  
Cunningham and Whitley

Dr. Cunningham is the director of optometry at Dell Laser Consultants in Austin, TX. He has no financial interests to disclose. Dr. Whitley is the director of professional relations and residency program supervisor at Virginia Eye Consultants in Norfolk, VA. He is a consultant for Alcon.





# Find qualified opticians fast

Finding a qualified optician for your practice can be difficult. That's why private practices and large employers alike trust Eyes On Eyecare® for specialized job posting and recruiting services.

## SOURCE OPTICAL TALENT MORE EFFICIENTLY WITH OUR:

✓ Large talent pool of licensed opticians—including active and passive job seekers

✓ Cross-promotions in Vision Monday, 20/20 Magazine, and other leading eyecare publications

✓ Expert recruiting team with years of expertise sourcing for specialized optical and staff positions

*"I had such a wonderful experience using Eyes On Eyecare. It was so easy to post a job and they walk you through the entire process. I recommend them to everyone I know."*

*- Ashley Wojcik*

*I was able to attract good quality candidates to fill my openings.*

*- Paul Naftali, OD*

Learn more at [eyesoneyecare.com/hire-now](https://eyesoneyecare.com/hire-now)



PROUD PARTNER OF JOBSON OPTICAL GROUP

Contact Lenses

**INDUSTRY LEADING SERVICE | LOWEST PRICES | SAME DAY SHIPPING\***

**JOHNSON & JOHNSON**

Acuvue 1 Day Oasys (90 Pack)  
Acuvue Oasys (12 Pack)  
Acuvue Vita (6 Pack)

AS LOW AS  
\$69.95  
\$48.95  
\$36.95

**COOPERVISION**

Biofinity (6 Pack)  
Biofinity Toric (6 Pack)  
Biofinity Energy (6 Pack)

AS LOW AS  
\$29.50  
\$40.50  
\$31.95

**BAUSCH & LOMB**

Biotrue (90 Pack)  
Ultra (6 Pack)  
Ultra Presbyopia (6 Pack)

AS LOW AS  
\$41.95  
\$29.95  
\$51.95



**National-Lens.com**

Call for our current price list  
or visit our website to register  
**866.923.5600**

\*Some restrictions apply, contact us for details

**Practice For Sale**

**Practice Consultants**

Practice Sales • Appraisals • Consulting  
[www.PracticeConsultants.com](http://www.PracticeConsultants.com)

**PRACTICES FOR SALE  
NATIONWIDE**

Visit us on the Web or call us to learn more about our company and the practices we have available.  
info@PracticeConsultants.com  
**925-820-6758**

[www.PracticeConsultants.com](http://www.PracticeConsultants.com)

**Practice For Rent**

**Optometry Practice  
for Rent**

Pasadena, Texas  
(outside of Houston)

Mainly Medicaid, Spanish Speaking  
Approximately 1560 sq. feet

**Call 281-435-3078**  
Leave a message

**Do you have  
CE Programs?**

**CONTACT US TODAY  
FOR CLASSIFIED  
ADVERTISING**

**Toll free:  
888-498-1460**

**E-mail:  
sales@kerhgroup.com**

**REVIEW  
of OPTOMETRY**

Do you have  
Products and  
Services for sale?

**CLASSIFIED  
ADVERTISING WORKS**

- JOB OPENINGS
- CME PROGRAMS
- PRODUCTS
- AND MORE...

Contact us today for  
classified advertising:  
Toll free: **888-498-1460**  
E-mail: [sales@kerhgroup.com](mailto:sales@kerhgroup.com)



Targeting Optometrists?

**CLASSIFIED ADVERTISING WORKS**

- JOB OPENINGS
- CME PROGRAMS
- PRODUCTS & SERVICES
- AND MORE...

Contact us today for classified advertising:  
Toll free: **888-498-1460**  
E-mail: [sales@kerhgroup.com](mailto:sales@kerhgroup.com)

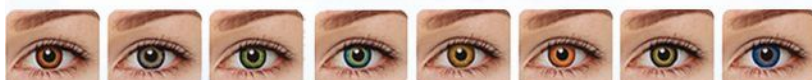Contact Lenses

# Impressions

Color Contact Lens

*Unleash your true color!*

Impressions colored contacts blend naturally with your patients eyes to create a beautiful look.  
Available in nine dazzling opaque colors.



\* Brown \* Grey \* Green \* Turquoise \* Hazel \* Honey \* Pure Hazel \* True Sapphire  
\* Available in RX PL to -8.00

Impressions are fun, hip, fashionable, comparable to other color contact lenses and very competitively priced to help your bottom line.  
- Free Trial Kit and P.O.P. Materials with Purchase -

SOLD EXCLUSIVELY BY:



866.923.5600  
National-Lens.com



## REVIEW of OPTOMETRY

### Targeting Optometrists?

#### CLASSIFIED ADVERTISING WORKS

- JOB OPENINGS • CME PROGRAMS
- PRODUCTS & SERVICES • AND MORE...

Contact us today for classified advertising:

Toll free: **888-498-1460**

E-mail: [sales@kerhgroup.com](mailto:sales@kerhgroup.com)





# Seeing Both Sides of It

*Is this patient's ocular asymmetry a cause for concern? If so, what is the appropriate course of action?*

**A** 47-year-old female presented to the office emergently with a chief complaint of right-side facial pain of two weeks' duration. She explained she was diagnosed with a sinus infection by her medical doctor and started on an oral antibiotic but was not improving. She had

no previous medical or ocular history. She was taking only the oral antibiotic prescribed by the doctor and denied allergies of any kind.

### Clinical Findings

Her best-corrected entering visual acuities were 20/20 OD and 20/20

OS at distance and near. Her extra-ocular motilities were normal and her confrontation fields were full OU. The pertinent external and pupillary observations are demonstrated in the photographs below.

There was no afferent defect present. Her biomicroscopic examination was normal and Goldmann applanation tonometry was measured at 17mm Hg in both eyes. Dilated fundus examination revealed no significant posterior pole or peripheral retina findings: the nerves were distinct with cup-to-disc ratios of 0.3/0.35 OD and OS.

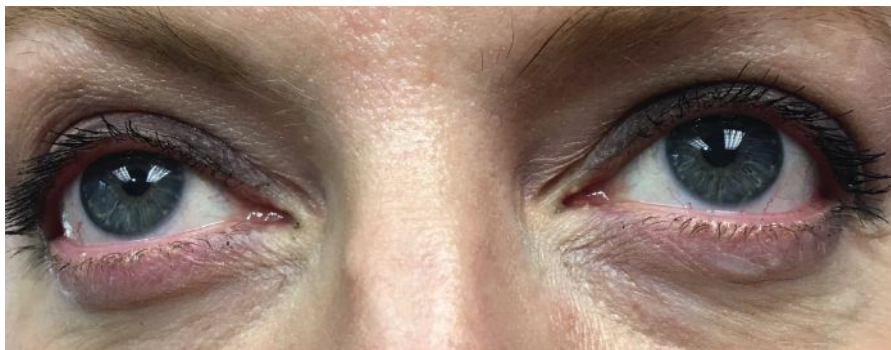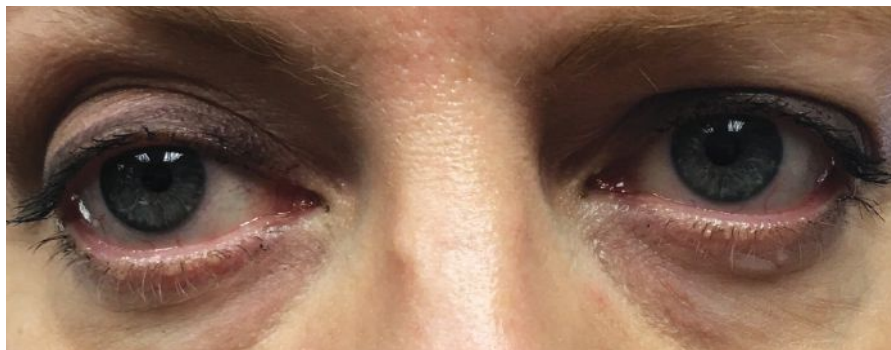### For More Information

Additional studies included measuring the pupils in both bright and dim illumination to confirm a pathologic anisocoria. Inspecting old photographs was completed to ensure that the ptotic eyelid position on the suspected side was new. A diluted topical adrenergic drop instillation test was completed to provoke suspected denervation hypersensitivity on the suspected side and observe its effect on the ptotic eyelid.

### Your Diagnosis

What would be your diagnosis in this case? What is the likely prognosis? Which interventions, if any, would you recommend? To find out, please read the online version of this article at [www.reviewofoptometry.com](http://www.reviewofoptometry.com). ■

*Dr. Gurwood thanks Nick Karbach, OD, for his contributions to this case.*



**How might this presentation connect with the symptom of facial pain on the right side?**

#### About Dr. Gurwood

Dr. Gurwood is a professor of clinical sciences at The Eye Institute of the Pennsylvania College of Optometry at Salus University. He is a co-chief of Primary Care Suite 3. He is attending medical staff in the department of ophthalmology at Albert Einstein Medical Center, Philadelphia. He has no financial interests to disclose.

## Retina Quiz Answers (from page 82)—Q1: d, Q2: a, Q3: c, Q4: a, Q5: c

### NEXT MONTH IN THE MAG

In June, we present our annual retina issue. Topics include:

- Dig into Dry AMD: Tools, Tips and Treatments You Should Know
- Follow This Retinal Referral Timeline

- Should You Worry When You See Choroidal Folds?
- Vitreous Disorders: Benign or Bothersome?
- What Dietary Changes Can—and Can't—Do for Retinal Disorders
- Low Vision: What to Do When Impairment Affects Quality of Life



# ALWAYS ON.

**MyDay Energys® TAKE LENS COMFORT ALL THE WAY TO EXTRAORDINARY.**

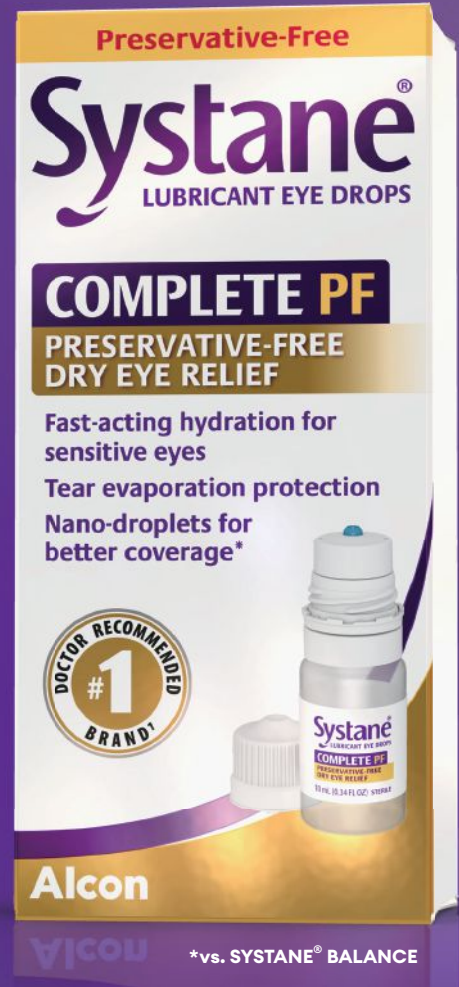Phones, tablets and laptops; wherever you are, even the middle of nowhere. We're all on, all the time. Finally, there's a 1-day lens with the technology and comfort to take them all on. MyDay Energys® daily disposable contact lenses are the first 1-day lens powered by DigitalBoost™ and Aquaform® Technology. They're designed to help with tiredness and dryness symptoms from digital eye strain. Extraordinary comfort—always on.



LEARN MORE



**1 drop.  
8 hours  
dry eye relief.<sup>2</sup>**



- Preservative-free formula ideal for sensitive eyes<sup>3</sup>
- One simple choice for all major types of dry eye<sup>2</sup>
- Multi-dose bottle replaces 120 unit-dose vials<sup>4\*\*</sup>

**Recommend SYSTANE® COMPLETE PF  
TO MAKE EVERY LOOK COUNT**

\*\*Calculation based on comparison of SYSTANE® COMPLETE PF vs. SYSTANE® HYDRATION UD; 1 drop per eye per dose.

**References:** **1.** Based on IQVIA ProVoice Survey of Eye Care Professionals 12 months ending December 31, 2021. **2.** Silverstein S, Yeu E, Tauber J, et al. Symptom Relief Following a Single Dose of Propylene Glycol-Hydroxypropyl Guar Nanoemulsion in Patients with Dry Eye Disease: A phase IV, Multicenter Trial. *Clin Ophthalmol.* 2020;14:3167-3177. **3.** Craig JP, Nelson JD, Azar DT, et al. TFOS DEWS II report executive summary. *Ocul Surf.* 2017;15:802-812. **4.** Alcon data on file, 2021.

©2022 Alcon Inc. US-SYX-2200084