

Mediastinal emphysema associated with functional endoscopic sinus surgery. A case report*

M.A. Sohail¹, K. Kishore¹, H. Stammberger², J.A. Jebeles², W. Luxenberger²

¹ Department of Ear, Nose and Throat, Al-Nahda Hospital, Sultanate of Oman

² University Ear, Nose and Throat Hospital, Graz, Austria

SUMMARY

A case of mediastinal emphysema after functional endoscopic sinus surgery (FESS) is presented. Mediastinal emphysema is a rare and previously unreported complication after FESS. The possible aetiologies are discussed.

Key words: mediastinal emphysema, sinus surgery, complications, FESS

INTRODUCTION

Functional endoscopic sinus surgery (FESS) using the technique of Messerklinger and Stammberger, has been proven a safe and successful technique in the management of sinusitis (Stammberger and Posawetz, 1990). Reported complications include - but are not limited - to CSF leaks, internal carotid artery injury, persistent infection, optic nerve injury with blindness, orbital emphysema, cerebrovascular accident, and extraocular muscle paralysis (Maniglia, 1989; Stammberger and Posawetz, 1990). Despite these complications, the overall complication rate is low in the hands of an experienced surgeon (Stammberger and Posawetz, 1990).

To our knowledge no one has previously reported mediastinal emphysema associated with FESS. Mediastinal emphysema has been reported after adenotonsillectomy, orbital floor fracture, laryngotracheal complex injury whether surgical or non-surgical, dental extraction, and pneumo-encephalography (Munsell, 1967; Habal et al., 1972; Sandler et al., 1975; Jakse, 1985). Proposed mechanisms for the development of mediastinal emphysema include disruption of the continuity of the aerodigestive tract, rupture of a pulmonary alveolus or bleb with subsequent dissection toward the hilum and mediastinum, and even occurrence secondary to a spontaneous pneumothorax (English, 1991). Due to the many possible aetiologies of post-operative mediastinal emphysema, it is often difficult to determine which mechanism is responsible for its occurrence in a particular patient.

CASE REPORT

A 40-year-old male patient presented with a 10-year history of recurrent bronchitis, persistent nasal discharge, headache and post-nasal

drip. Pre-operative evaluation was remarkable for the following findings: nasal endoscopic examination revealed oedema and purulent secretions in the middle meatus bilaterally, chest X-ray showed mildly increased vascular markings, and the CT of the paranasal sinuses showed bilateral opacification of the maxillary and anterior ethmoidal sinuses with the left side also showing involvement of the posterior ethmoidal cells (Figure 1).

FESS was performed under general anaesthesia using the Messerklinger and Stammberger approach. No complications were encountered and it was believed that both the lamina papyracea and orbital periosteum had been left intact. Several hours post-operatively the patient developed emphysema of the left cheek, which continued to expand and eventually involved the left orbit, neck and anterior chest wall. Post-operative chest X-rays revealed emphysema of the mediastinum (Figure 1). No evidence of an infectious process was noted and the patient was treated conservatively. On post-operative day 2, the emphysema began to resolve clinically. On post-operative day 5, there was no further clinical evidence of persisting emphysema and the patient was discharged.

Post-operative follow-up after two weeks including radiographic evaluation confirmed complete resolution of the mediastinal emphysema (Figure 2). The paranasal sinus cavities healed appropriately and the patient is free of his pre-operative symptoms.

DISCUSSION

Mediastinal emphysema often results from alveolar rupture during the course of acute or chronic pulmonary disease; however, a diverse group of non-respiratory entities (such as surgical trauma, non-surgical trauma, anaesthetic complications, and infection) have been implicated in the aetiology of mediastinal

* Received for publication January 17, 1994; accepted August 1, 1994

emphysema. Surgical emphysema of the eyelid, intra-orbital tissues, and soft tissues of the cheek have been reported after FESS as a result of violating orbital integrity. Extensive emphysema as seen in this particular patient with involvement of the

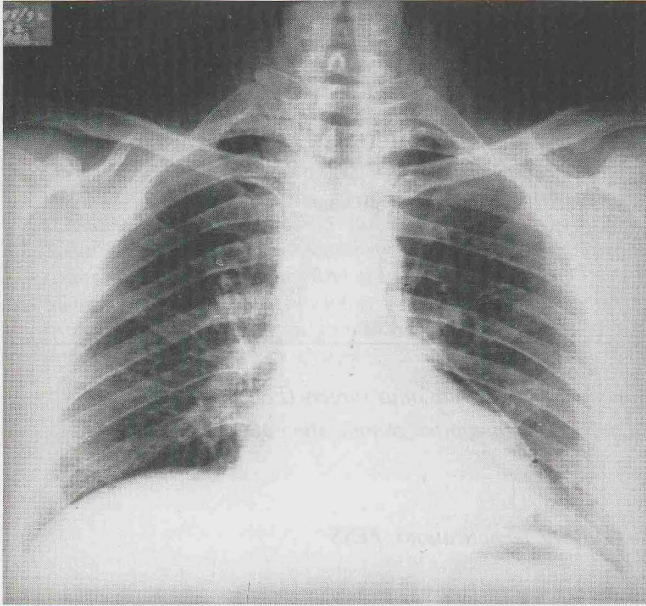


Figure 1. Post-operative chest X-ray showing mediastinal emphysema.

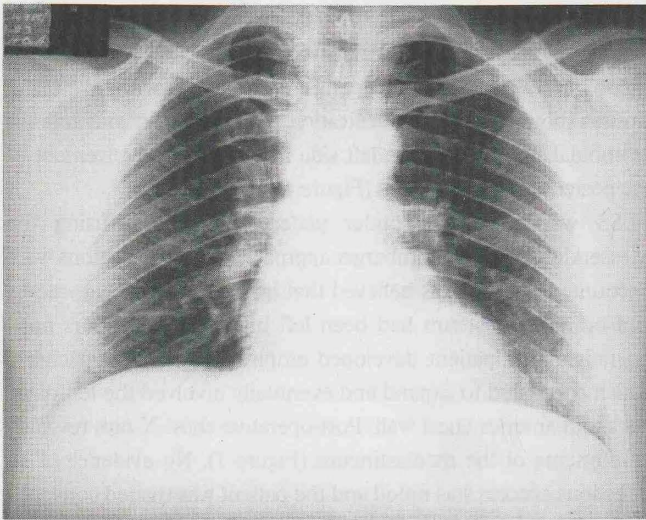


Figure 2. Chest X-ray two weeks post-operatively showing spontaneous resolution of the mediastinal emphysema.

cheek, neck, chest wall, and mediastinum has to our knowledge not been reported.

The aetiology of the mediastinal emphysema in this case is quite perplexing. It is unclear whether the emphysema is caused by the FESS itself or is due to other pathology. Possible aetiologies include a ruptured alveolus as the patient had a history of recurrent chest infections, although the pre-operative chest X-ray was not impressive. Unfortunately, a pre-operative CT

scan of the thorax had not been performed. This could have provided some insight into the aetiology of the mediastinal emphysema. It is unlikely that an unnoticed insult to the orbit occurred, since repeated post-operative endoscopic examinations of the paranasal sinuses confirmed a visually intact lamina papyracea; however, a microscopical hole could not be ruled out.

No clinical evidence of infection secondary to gas-forming bacteria was seen. A likely explanation for the post-operative emphysema is a complication of the general anaesthetic. Traumatic injury to the laryngotracheal complex during intubation may have occurred. This laryngotracheal complex injury could have led to emphysema in the neck, which subsequently dissected superiorly to the cheek and inferiorly into the chest wall and mediastinum. On future follow-up visits, a CT scan of the thorax will be performed to evaluate for other pathologic entities which may have been the causative factor for the mediastinal emphysema.

CONCLUSION

FESS has rapidly become the most frequently-used surgical approach for the management of sinusitis failing medical therapy. Although the total number of complications secondary to surgical procedures on the paranasal sinuses may have increased, the incidence of complications has actually decreased. Various complications associated with FESS have been reported; however, mediastinal emphysema is a rare and, to our knowledge, previously unreported associated complication. The many possible aetiologies for the development of mediastinal emphysema make the precise aetiology difficult to determine, and the possibility that the emphysema is not directly related to the FESS must be considered.

REFERENCES

1. English (1991) *Otolaryngology*, Volume 3. J. Stuart Freeman, pp. 27-52.
2. Habal MB, Beart R, Murray JE (1972) Mediastinal emphysema secondary to fracture of orbital floor. *Am J Surg* 123: 606.
3. Jakse R (1985) Leitsymptom Emphysem. *Laryngol Rhinol Otol* 64: 275-282.
4. Maniglia AJ (1989) Fatal and major complications secondary to nasal and sinus surgery. *Laryngoscope* 99: 276-283.
5. Munsell WP (1967) Pneumomediastinum: A report of 28 cases and review of literature. *JAMA* 202: 689.
6. Sandler CM, Libshitz HI, Marks G (1975) Pneumoperitonium, pneumomediastinum and pneumopericardium following dental extraction. *Radiology* 115: 539.
7. Stammberger H, Posawetz W (1990) Functional endoscopic sinus surgery. Concept, indications and results of the Messerklinger technique. *Eur Arch Otorhinolaryngol* 247: 63-76.

Prof. H. Stammberger
Universitäts-HNO-Klinik
Auenbruggerplatz 20
A-8036 Graz
Austria