

Expert Opinions

Primary Empty Sella

Sandhya Mehla, MBBS ; Abigail L. Chua, DO; Brian Grosberg, MD; Randolph W. Evans, MD

Primary empty sella (PES) syndrome is a misnomer as it is not a syndrome but a radiological finding with possible endocrine abnormalities. No specific headache type has been shown to be caused by PES. Endocrine screening may be considered for asymptomatic persons with PES.

Key words: primary empty sella, headache, endocrine screening

(*Headache* 2020;0:1-4)

The term, “empty sella,” was first introduced by Busch in 1951 to describe “a peculiar anatomical condition, observed in 40 of 788 human cadavers, particularly females, characterized by a sella turcica with a diaphragma sellae incomplete or that forms only a small peripheral rim, with a pituitary gland not absent, but flattened in such a manner as to form a thin layer of tissue at the bottom of the sella turcica”.¹ In 1968, Kaufman postulated that “... empty sella is a distinct anatomical and radiographic entity, function of an incompleteness of diaphragm sellae and of the cerebrospinal fluid (CSF) pressure, normal or elevated”²

CASE HISTORY

This is a 54-year old female with a 2 year history of mild migraine headaches without aura relieved by acetaminophen. She recently developed benign

From the Hartford Healthcare Headache Center, University of Connecticut School of Medicine, West Hartford, CT, USA (S. Mehla, A.L. Chua, and B. Grosberg); Department of Neurology, Baylor College of Medicine, Houston, TX, USA (R.W. Evans).

Address all correspondence to S. Mehla, Hartford Healthcare Headache Center, Ayer Neuroscience Institute, University of Connecticut School of Medicine, Norwich, CT, USA, email:sandhya.mehla@hhchealth.org

positional vertigo and saw another physician who obtained an MRI of the brain showing an empty sella. Past medical history was otherwise negative. On examination, her body mass index was 34. Neurological examination was normal. The optic discs had sharp margins and superior venous pulsations were present.

QUESTIONS

What is primary empty sella (PES), its prevalence, and risk factors? How often and what type of headaches are associated? Are visual field defects associated? Is pituitary function abnormal in PES? Should asymptomatic patients undergo testing, if so, which tests? Do the tests need to be repeated and, if so, specifically how often?

EXPERT OPINION

What is Empty Sella?.—“Empty sella” is an anatomical and radiological finding in which the subarachnoid space herniates into the sella turcica with the flattening of the pituitary gland to varying degrees.^{3,4} Based on the extent of this herniation, empty sella can be partial or complete. A diagnosis of partial empty sella is made when less than 50% of the sella is filled with CSF and the pituitary gland thickness ranges from

Accepted for publication September 14, 2020.

Conflict of Interest: None

3 to 7 mm, with 7 mm being the lower limit of normal thickness. A diagnosis of complete empty sella is made when more than 50% of sella is filled with CSF and the pituitary gland thickness is less than or equal to 2 mm.^{3,5}

Empty sella syndrome may occur as a primary disorder, which is not a syndrome but a radiological and anatomical finding. Causes of secondary empty sella include the following: a cerebral tumor or hydrocephalus; idiopathic intracranial hypertension; surgery for a pituitary tumor; Sheehan's syndrome; a sequela of craniocerebral trauma or cerebral radiotherapy, and lymphocytic hypophysitis.³

An MRI of the brain can also be useful in differentiating between primary and secondary empty sella syndrome. In PES, the thin rim of pituitary is normal pituitary tissue which should enhance normally on T1-weighted images with contrast, whereas in secondary empty sella, as atrophy or shrinkage of the pituitary is usually the etiology, it does not enhance because of scarring. Very rarely empty sella can be associated with an ectopic microadenoma located in the intersphenoidal septum. An MRI of the pituitary gland with and without gadolinium should be performed in patients where there is suspicion of a pituitary adenoma in the compressed pituitary tissues.

Epidemiology.—The incidence of PES is about 5.5%-12% at autopsy.^{1,2} Neuroimaging studies report the incidence of PES to be 12%.⁶ Male to female ratio is reported as 5:1.³ The peak incidence occurs between 30 and 40 years of age and is less frequently seen in children than in adults. In clinical practice, the incidence range of PES has been noted from 8% to 35% according to various large case series.^{3,6,7}

Female gender, multiple pregnancies, obesity and sleep apnea, and arterial hypertension are the common risk factors for the development of PES.⁸ In a series of 203 patients, about 73% of patients were overweight and 15% were obese. The rate of obesity was even higher in women.³ In a series of 175 patients, multiple pregnancies were reported in 58.3%, obesity and sleep apnea in 49.5%, and arterial hypertension in 27.3%.⁹

Pathophysiology.—The pathophysiology of PES is poorly understood but sellar, upper sellar, and pituitary factors may contribute to the development (Fig. 1). Incomplete development of the diaphragm sella is noted in 20%-77% of cases with PES and in 20% of healthy people.⁷

Upper sellar factors via either CSF pulsatility or a stable or intermittent rise in CSF pressure can contribute to the development of PES. Alterations in intracranial pressure (ICP) and/or CSF dynamics were noted in 77% of cases, with a range of ICP between 14 and 26 mmHg.⁷

Obesity may contribute to the development of PES through a few possible mechanisms. Hypercapnia and obstructive sleep apnea in obese patients can cause a stable or intermittent rise in ICP.^{10,11} Central obesity causes increased intra-abdominal pressure which indirectly increases pleural and cardiac filling pressure. This can cause decreased venous return in the brain leading to increased venous pressure and increased ICP. Obesity also causes increased release of cortisol production via cytokines and a rise in the enzyme 11 β -HSD1. Cortisol can raise CSF pressure through increased CSF production and decreased CSF drainage.^{4,12} Thrombophilic states secondary to obesity might also cause raised ICP.¹³

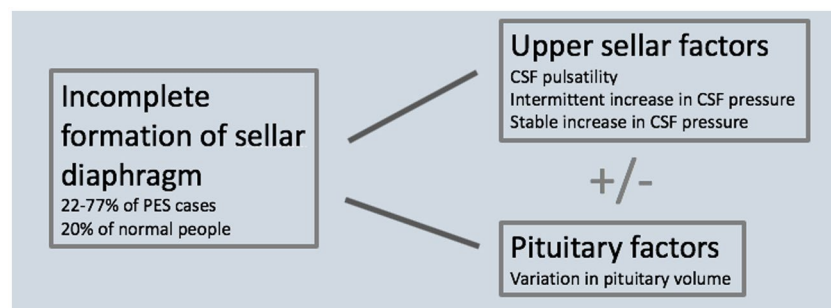


Fig. 1.—Factors which may result in primary empty sella.

Changes in the pituitary can result in PES. During pregnancy and lactation, the pituitary can even double in size. When the involution occurs, the extra space in the sella fills with CSF. Primary hormonal deficiency states such as primary hypothyroidism, primary hypoadrenalism, and primary hypogonadism can lead to pituitary hyperplasia followed by involution.⁴

Headache and Empty Sella.—Headache has been reported as a symptom in 80%-88% of patients with PES.⁴ However, it is not known if there is a specific headache due to PES as PES is most likely an incidental finding in people with primary headache having scans. There have been no studies comparing the headaches of those with PES to age and gender-matched control population.

Visual Disturbances.—Visual disturbances have been noted in 1.6-16% of patient with PES. In a series of 175 patients, 13.7% had some type of visual disturbance including the following: decreased visual acuity, an enlarged blind spot, quadrantanopia, hemianopia, or tunnel vision.⁹ Herniation of the visual system into the pituitary fossa has traditionally been thought to be the cause of visual defects but this can occur even in the absence of radiologic herniation of the visual system. It is hypothesized that this could result from traction on the infundibular stalk as in a case series of 2 patients where visual symptoms improved immediately after surgery to release pressure on the visual pathways.¹⁴ The onset of these defects is so insidious that a large proportion of patients does not complain of visual symptoms but are detected on ophthalmologic testing only.

Despite these reports, it is not certain how many patients with PES have visual disturbances. Gitelman's series,⁹ for example, included 2 with papilledema. Griffiths et al opine that PES and visual failure may be a chance association.¹⁵

Hypopituitarism.—In a pooled analysis, the prevalence of hypopituitarism was 52%.¹⁶ The prevalence of isolated pituitary insufficiency was 21% and multiple pituitary axis dysfunction was 30%.

Hormonal irregularities are mainly found with hormones secreted from the anterior pituitary gland which is predominantly compressed. Somatotrophic and gonadotrophic axes are affected more than others so decreased growth hormone and decreased gonadotropins are the common findings.¹⁸ Increased prolactin secretion is seen

from the anterior pituitary in PES cases in up to 10% secondary to the decreased release of dopamine from the pituitary stalk which also gets compressed early on when the herniation of subarachnoid space begins.^{4,17}

The most common symptoms secondary to hormonal irregularities in women are obesity in 52%, irregular menses in 40%, galactorrhea in 26%, and hypertrichosis in 18%. In men, sexual disturbance and gynecomastia are the most frequent symptoms.⁴

For asymptomatic patients, some authors suggest obtaining the following: morning cortisol concentration, free thyroxin, estradiol in women with irregular menses, testosterone in men, insulin-like growth factor, and prolactin.¹⁶ In asymptomatic persons with PES, Snyder opines that thyroxin and early morning cortisol could be measured but will likely be normal.¹⁹ If abnormalities are found or symptoms of possible hormonal disturbance develop, additional hormone diagnostic tests using stimulation are recommended.

REFERENCES

1. Busch W. Die Morphologie der Sella turcica und ihre Beziehungen zur Hypophyse. *Virchows Arch Path Anat.* 1951;320:437-458.
2. Kaufman B. The "empty" sella turcica – A manifestation of the intrasellar subarachnoid space. *Radiology.* 1968;90:931-941.
3. De Marinis L, Bonadonna S, Bianchi A, Maira G, Giustina A. Primary empty sella. *J Clin Endocrinol Metab.* 2005;90:5471-5477.
4. Chiloiro S, Giampietro A, Bianchi A, et al. Diagnosis of endocrine disease: Primary empty sella: A comprehensive review. *Eur J Endocrinol.* 2017;177:R275-R285.
5. Hodgson SF, Randall RV, Holman CB, MacCarty CS. Empty sella syndrome. Report of 10 cases. *Med Clin North Am.* 1972;56:897-907.
6. Foresti M, Guidali A, Susanna P. Primary empty sella. Incidence in 500 asymptomatic subjects examined with magnetic resonance. *Radiol Med.* 1991;81:803-807.
7. Maira G, Anile C, Mangiola A. Primary empty sella syndrome in a series of 142 patients. *J Neurosurg.* 2005;103:831-836.
8. Miljic D, Pekic S, Popovic V. Empty sella. In Feingold KR, Anawalt B, Boyce A, et al., ed. *Endotext.* South Dartmouth, MA: MDText.com, Inc.; 2000. Available at: <https://www.ncbi.nlm.nih.gov/books/NBK532084/>. Accessed October 2,2020.

9. Guitelman M, Basavilbaso NG, Vitale M, et al. Primary empty sella (PES): A review of 175 cases. *Pituitary*. 2013;16:270-274.
10. Newton DA, Bone I. Papilloedema and optic atrophy in chronic hypercapnia. *Br J Dis Chest*. 1979;73:399-404.
11. Sugita Y, Iijima S, Teshima Y, et al. Marked episodic elevation of cerebrospinal fluid pressure during nocturnal sleep in patients with sleep apnea hypersomnia syndrome. *Electroencephalogr Clin Neurophysiol*. 1985;60:214-219.
12. Sinclair AJ, Ball AK, Burdon MA, et al. Exploring the pathogenesis of IIH: An inflammatory perspective. *J Neuroimmunol*. 2008;201-202:212-220.
13. Dunkley S, Johnston I. Thrombophilia as a common predisposing factor in pseudotumor cerebri. *Blood*. 2004;103:1972-1973.
14. Guinto G, del Valle R, Nishimura E, Mercado M, Nettel B, Salazar F. Primary empty sella syndrome: The role of visual system herniation. *Surg Neurol*. 2002;58:42-47.
15. Griffiths PG, Dayan M, Coulthard A. Primary empty sella: cause of visual failure or chance association? *Eye (Lond)*. 1998;12(Pt 6):905-906.
16. Auer MK, Stieg MR, Crispin A, Sievers C, Stalla GK, Kopczak A. Primary empty sella syndrome and the prevalence of hormonal dysregulation. *Dtsch Arztebl Int*. 2018;115:99-105.
17. Melmed S, Casanueva FF, Hoffman AR, et al. Diagnosis and treatment of hyperprolactinemia: An Endocrine Society clinical practice guideline. *J Clin Endocrinol Metab*. 2011;96:273-288.
18. Petersenn S, Quabbe HJ, Schöfl C, Stalla GK, Werder K, Buchfelder M. The rational use of pituitary stimulation tests. *Dtsch Arztebl Int*. 2010;107:437-443.
19. Snyder PJ. Causes of hypopituitarism. In: Post TW, ed. *UpToDate*. Waltham, MA: UpToDate Inc. Available at: <https://www.uptodate.com>. Accessed September 11, 2020.