

Crush Injuries and Compartment Syndrome

Crush Injuries (CI) and Compartment Syndrome (CS) are two very serious complications from mechanisms such as trauma, extended compression from body weight, overexertion causing rhabdomyolysis, orthopedic procedures, and many other causes. CI and CS can be difficult to recognize because there may initially be very few, if any, signs and symptoms. However, recognition and early intervention are crucial because CI and CS can be a life and limb-threatening emergency.

Pathophysiology

- Crush Injury (CI) – Results from prolonged, continuous pressure on large muscles resulting in muscle disintegration.
- Compartment Syndrome (CS) – Any condition in which a structure has been constricted within a space. This is a deep tissue injury that causes swelling and bleeding. The skin only stretches so far before the pressure is redirected inwards to internal structures leading to tissue necrosis and metabolic acidosis.
- Rhabdomyolysis – Destruction of skeletal muscle tissue accompanied by the release of muscle cell contents into the bloodstream that results in hypovolemia, hyperkalemia, and acute renal failure.
- Ventricular fibrillation is the most common dysrhythmia associated with sudden cardiac death in CI/CS. A lack of calcium and an increase in potassium levels begin to widen the QRS complex until it blends with the T-wave, causing a sine wave ECG. At this point, ventricular fibrillation and asystole are imminent.

(continued on next page)



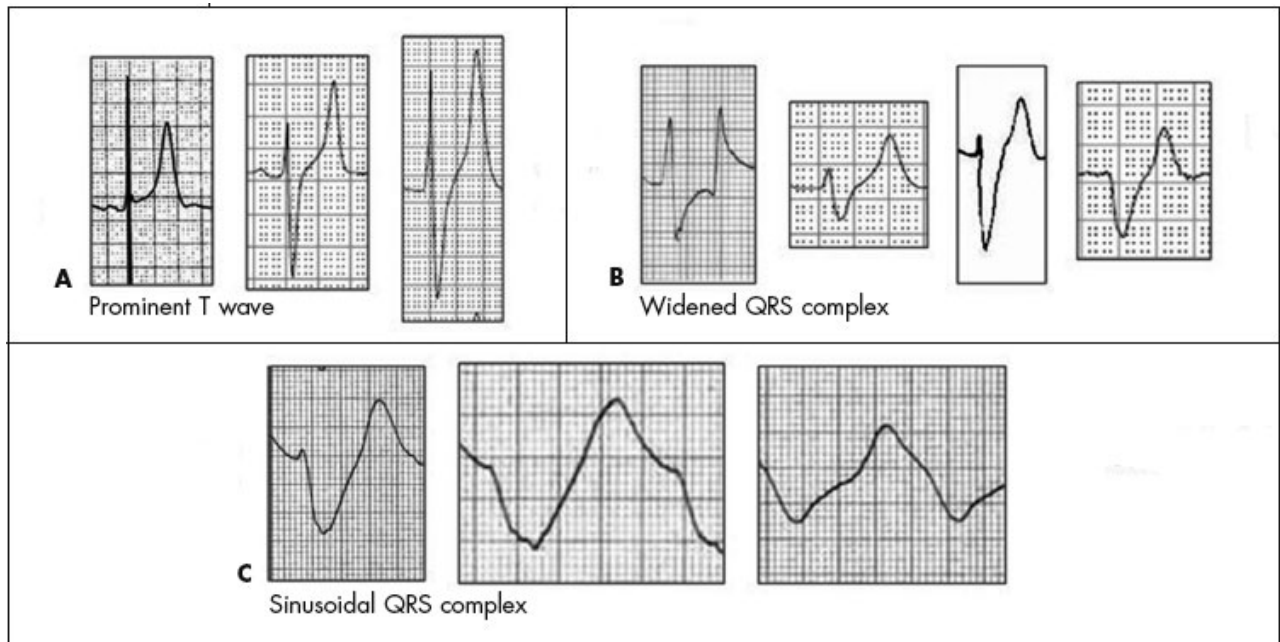
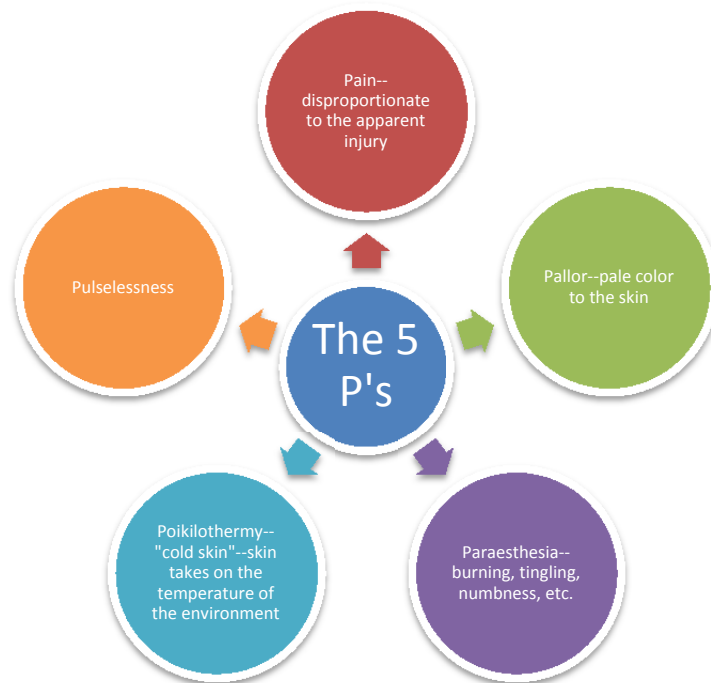

Figure 4 – The classic ECG findings of hyperkalemia are shown here: prominent T waves that are tall, narrow, and symmetric (A); QRS-complex widening (B); and widened QRS complex with sine-wave configuration, consistent with sinoventricular rhythm (C).

www.consultantlive.com

It usually takes between four to six hours of pressure to cause damage, but in severe crush cases, as little as one hour or less of pressure can cause damage. It may also take up to approximately 48 hours after pressure is released for signs and symptoms to emerge.

- Assessment and Recognition
 - Initial presentation may have few, if any, physical signs and symptoms. Maintain a high level of suspicion for CI/CS with prolonged extrication, prolonged exposure to constant pressure (think of the stroke patient that can't move off of his arm), and extensive lower extremity/pelvic injuries.
 - Physical findings include a tense or tight feeling of the skin and the 5 "P's"

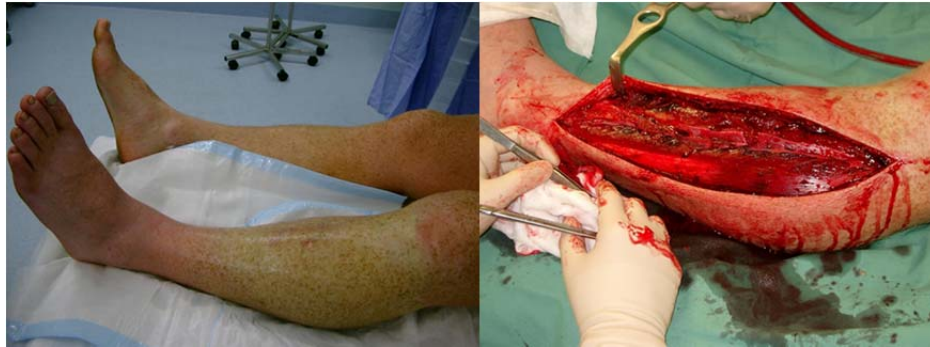

Management

- Begin treatment before signs and symptoms emerge if there is a high level of suspicion. The patient may already be in renal failure or metabolic acidosis.
- Basic Life Support (BLS) care
 - Control reperfusion – The pressure is released from the extremity, reperfusion begins, and toxins are released systemically. Have ALS support on scene to help mitigate the effects of the reperfusion toxin release. A venous tourniquet may be considered, but this is highly controversial and should only be used according to individual policies/procedures and medical control.
 - Maintain core body temperature.
 - Splint the limb at the level of the heart to limit edema and maintain perfusion.
 - Rapid transport to a trauma center is critical. Initiate ALS or air transport as soon as CI/CS is suspected, even prior to extrication.
- Advanced Life Support (ALS) care
 - Adequate hydration with normal saline to maintain a high kidney output.
 - Medicate for pain early and often, as needed.
 - Sodium bicarbonate can be used to help reverse existing metabolic acidosis, treat hyperkalemia, and keep the urine alkalotic (may help prevent renal tube obstruction).

(continued on the next page)

- Mannitol may help to promote diuresis to reduce urine acidity. Do not give Lasix because it acts in the wrong area of the kidney and actually increases urine acidity. Only use mannitol after adequate IV hydration has been established.
- Hospital treatment
 - Hyperbaric oxygen therapy may be considered for early cases.
 - An open fasciotomy allows tissues to swell without constricting blood flow.
 - Amputation may be a final step to prevent further tissue necrosis and infection.



A lower extremity showing signs of swelling and pallor with compartment syndrome and an open fasciotomy performed on a lower extremity. www.lifeinthefastlane.com

For more information, please visit the following websites:

- <http://www.emsworld.com/article/10321291/beyond-the-basics-crush-injuries-and-compartment-syndrome>
- <http://www.emsworld.com/article/12016910/compartment-syndrome-of-the-extremities>