

Porphyria cutanea tarda* *Porfíria cutânea tardia**

Fátima Mendonça Jorge Vieira¹ José Eduardo Costa Martins²

Abstract: *This is a review article of porphyria cutanea tarda addressing pathophysiology, clinical features, associated conditions, triggering factors, biochemistry, histopathology, electronic microscopy, immunofluorescence microscopy and treatment of the disease.*

Keywords: *Chloroquine; Fluorescent antibody technique; Porphyria cutanea tarda/complications; Porphyria cutanea tarda/pathology; Porphyria cutanea tarda/pathophysiology; Porphyria cutanea tarda/therapy; Precipitating factors*

Resumo: Trata-se de revisão sobre a porfíria cutânea tardia em que são abordados a fisiopatogenia, as características clínicas, as doenças associadas, os fatores desencadeantes, a bioquímica, a histopatologia, a microscopia eletrônica, a microscopia de imunofluorescência e o tratamento da doença.

Palavras-chave: Cloroquina; Fatores desencadeantes; Imunofluorescência; Porfíria cutânea tardia; Porfíria cutânea tardia/complicações; Porfíria cutânea tardia/fisiopatologia; Porfíria cutânea tardia/patologia; Porfíria cutânea tardia/terapia

INTRODUCTION

Porphyria cutanea tarda is caused by the partial deficiency of uroporphyrinogen-decarboxylase (Urod) activity, inherited or acquired, with resultant accumulation of uroporphyrin (URO) and 7-carboxyl porphyrinogen, mostly in the liver.¹ The word porphyria originates from the Greek word *porphura*, which means purple color, and was chosen because of the urine reddish to purplish staining of patients with porphyria.²

In 1911, Günther described “chronic hematorporphyria” including cases, which nowadays are recognized as porphyria cutanea tarda (PCT) and porphyria variegata (PV). In 1937, Waldenström renamed this group as “porphyria cutanea tarda”, not distinguishing from PV,³ but in 1957, he acknowledged the difference between the two disorders.⁴

PCT is universal and the most frequent porphyria. The disease usually appears in middle-age individuals, the majority of them over 40 years old.⁵ In the past, it was found mostly in men, but the current incidence in women,⁶ is increasing due to the intake of estrogens and to the increase in alcohol con-

sumption.⁷

The disclosure of low Urod activity in PCT promoted its subdivision:⁸

Sporadic porphyria cutanea tarda (Type I, symptomatic or acquired) – It encompasses 72% to 84% of cases,⁹⁻¹¹ and the enzyme deficiency is restricted to the liver, with normal erythrocyte Urod activity.¹² There is no family history. The specific enzyme defect is not caused by mutation in the Urod *locus*;¹ and the cDNA sequences of hepatic, extra-hepatic Urod, as well as the promoter region of the gene are normal.¹³

Familial porphyria cutanea tarda (Type II or inherited) – It comprises 16% to 28% of cases. Urod activity is reduced to half normal in all tissues (erythrocytes and liver) due to reduction in enzyme synthesis or stability.^{10,11,14,15} Differentiation between PCT types I and II cannot be solely based on erythrocyte Urod activity, which may be at the lower limit in PCT type II and below the normal interval in PCT type I.^{10,16} Thus, DNA testing is preferred for the identification

* Work done at Department of Dermatology, Hospital das Clínicas da Faculdade de Medicina da Universidade de São Paulo – USP - Sao Paulo, (SP), Brazil.
Conflict of interests: None

¹ Graduate student at the Department of Dermatology, Hospital das Clínicas da Faculdade de Medicina da Universidade de São Paulo – USP - Sao Paulo, (SP), Brazil.

² Associate professor at the Department of Dermatology, Hospital das Clínicas da Faculdade de Medicina da Universidade de São Paulo – USP - Sao Paulo, (SP), Brazil.

of familial cases.⁷ Mutations in the Urod gene discriminate familial from sporadic forms. Many Urod mutations (more than 40) in the 1p34 chromosome diminish enzyme stability or cause altered pre-RNA splicing.^{1,7,14,18} It is an autosomic dominant disorder with low clinical penetrance; less than 10% of affected subjects are symptomatic.¹⁵ As most individuals who inherit the enzyme defect do not manifest the disorder, it is suggested that additional genetic or non-genetic factors are needed for expressing the disease.¹⁴ The age at onset of the disease, severity of the symptoms, sex distribution, liver enzyme and iron profiles are not different between types I and II.⁷

Type III porphyria cutanea tarda – It is biochemically indistinguishable from type I (normal erythrocyte Urod), but it affects more than one family member.^{1,19} It occurs in a small number of patients (<5%). The promoter region and the coding DNA sequence of Urod are normal, suggesting that other loci are involved in its pathogenesis, and these may be genes affecting tissue iron.^{10,13} It is not proven that type III PCT is a distinct form of the disease or if it would be PCT type I with inherited contribution.¹¹

Toxic porphyria cutanea tarda – It occurs after the exposure to hexachlorobenzene (HCB) 20 and tetrachlorodibenzo-p-dioxin (TCDD), which diminish hepatic Urod activity.²¹

PATHOGENESIS

Biosynthesis of heme and inhibition of uroporphyrinogen-decarboxylase

The main sites of heme synthesis are the bone marrow (85%) and the liver.²² Heme biosynthesis is depicted in Figure 1.²³ Urod, the fifth enzyme of the heme biosynthesis chain, is a polypeptide of approximately 42kDa, coded by a single gene in 1p34 chromosome, with 10 exons distributed in 3kb.¹ It is a cytoplasmic enzyme and it catalyzes the sequential decarboxylation (oxidative) of four acetyl groups of uroporphyrinogen (Urogen), yielding 7-, 6-, 5- and 4-carboxyl porphyrinogen or coproporphyrinogen (Coprogen). In PCT there is an inversion in the action sequence of the enzymes Urod and Coprogen oxidase; the latter may initially cause decarboxylation of 5-carboxyl porphyrinogen, yielding dehydroisocoproporphyrinogen, which is decarboxylated by Urod, resulting in harderoporphyrinogen (Harderogen) that goes back to the heme biosynthesis chain or may be hydrated forming isocoproporphyrinogen (Isocopro), thus explaining its increase in the stools of PCT patients.²³

Individuals with PCT seem to be inheritantly

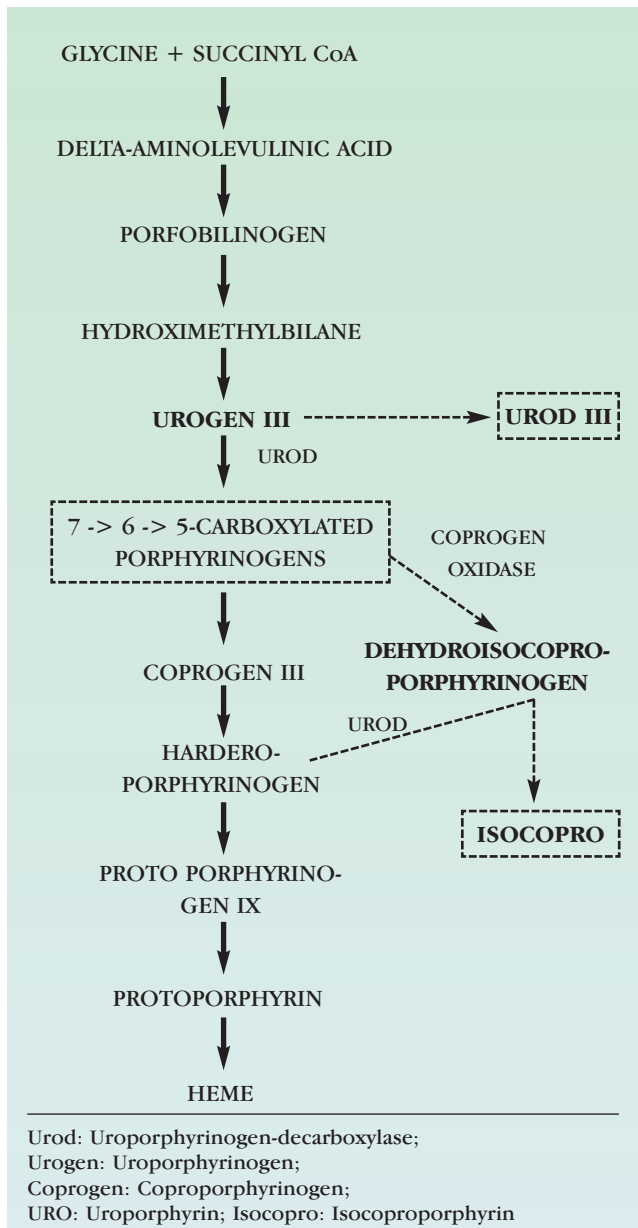


FIGURE 1: Heme porphyrin-heme biosynthesis chain and enzymes involved in the different porphyrias. Source: Bickers DR et al.²³

predisposed to present Urod deficiency in response to hepatic injury.⁹ PCT results in progressive inactivation of Urod (structurally normal) in the liver, by a specific process affecting the catalytic site, not affecting the main epitopes.²⁴ Liver Urod activity decreases to less than 25% of normal, which generates enough quantities of porphyrins to cause photosensitization.^{12,24,25} Although this process is described in sporadic PCT, it is also likely to occur in familial form.⁴

In 1998,¹¹ Elder reviewed which factors interfered in the inactivation mechanism of Urod in the hepatocytes, in experimental models, and observed

that three main factors accelerated inactivation: iron overload, cytochrome P450 induction and increased supplementation of delta-aminolevulinic acid (ALA).^{1,26} Iron acts by promoting the formation of oxygen reactive factors (ORF),²⁷ which act by oxidating Urogen, generating URO and non-porphyrin (non-characterized) oxidated products which cause Urod inactivation. Oxidation occurs by means of hydroxyl radicals.²⁵ Cyclic hydrocarbons induce cytochrome P450.²⁸ Human cytochrome is less active than that of rodents in catalizing Urogen oxidation.²⁹ ALA has an accelerating effect, likely due to the fact it acts as Urogen supplier, Urod substrate which is inhibited.³⁰

The interaction among inherited and acquired factors implicit in Urod inactivation are depicted in Figure 2 and it is based in a pathogenetic model suggested by Thunell and Harper.¹⁴ In normal conditions, just about all Urogen III is converted in Coprogen III. In the presence of iron, the oxidated proportion of URO and of non-porphyrin oxidation products is increased. Urod inactivation is self-supported. Iron acts as a switch which controls the generation and the inhibition of Urod, beginning a vicious cycle of its inactivation; its removal allows restoring Urod activity.¹¹ There are several genes that may induce PCT: mutations in the Urod locus and other likely loci would be genes involved in iron metabolism, in production of hepatic heme (ALA formation) and in induction of cytochrome P450; other susceptibility genes, besides those of hemochromatosis, have not been identified yet. Iron may be increased due to dietary ingestion, increased intestinal absorption (alcohol and estrogens) or because a chronic viral infection releases the iron bound to ferritin. Alcohol and cyclic hydrocarbons may also induce the ALA-synthetase gene, increasing Urogen, the precursor of Urod inhibitors.¹⁴ Some authors suggest that auto-antibodies may be involved in the inhibition of Urod catalytic activity in patients with hepatitis C.³¹

Pathophysiology of skin lesions

The photosensitization capacity of porphyrins was demonstrated by Meyer-Betz in 1912, when he self-injected hematoporphyrin.³² Porphyrin exposure to the spectrum of the Soret band (400 to 410nm) results in the emission of two fluorescence peaks in the region of 600 to 610nm and of 640 to 669nm.²³ The photosensitization mechanism is not well defined. The interaction among several factors is likely to be responsible for the pathogenesis of skin lesions, such as oxygen reactive factors, cells (mast cells and fibroblasts), soluble mediators (complement and eicosanoid systems) and matrix metalloproteinases.²³

Oxygen reactive factors (ORF) – Porphyrins

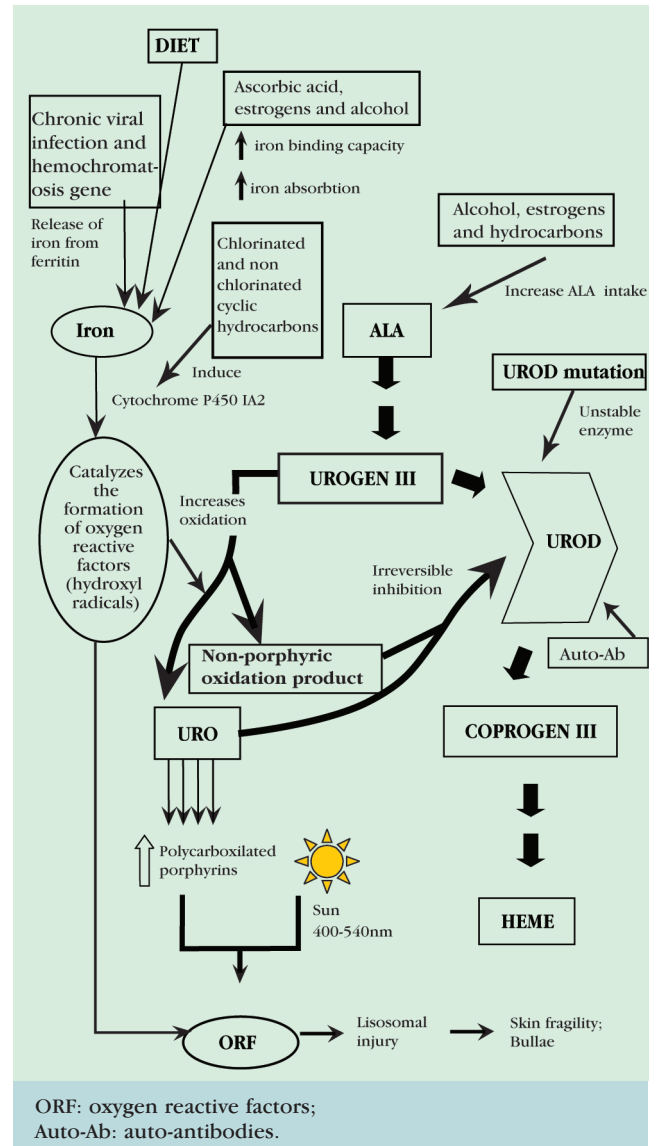


FIGURE 2: The inactivation mechanism of uroporphyrinogen-decarboxylase in hepatocytes and interaction between inherited and acquired factors in porphyria cutanea tarda (pathogenetic model)source: Thunell S et al.14

(URO and Copro) absorb light energy generating a porphyrin molecule in the excited singlet state, which converts spontaneously to the triplet state of lower energy level and longer average life, facilitating the reaction with biological substrates. Porphyrins in the triplet state transfer energy to oxygen (O₂) molecules, producing the ORF, such as the singlet oxygen (¹O₂), superoxide anion (O₂⁻), hydroxyl radicals (OH), hydrogen peroxide (H₂O₂) and lipid peroxides, which interact with cell membranes causing tissue injury and release of pro-inflammatory mediators. Singlet oxygen (¹O₂) is probably the main mediator of tissue injury.³³ This process is called photodynamic reaction. Several studies support the participation of

ORF in photosensitivity induced by porphyrins.^{34,35}

Physicochemical properties of porphyrins – Porphyrin distribution in tissues depends on its physicochemical properties. URO and Copro are hydrophilic and accumulate majorly in the lower epidermis and upper dermis; on the other hand, protoporphyrin (Proto) has greater affinity with lipid membranes (endothelial cell and lysosome membrane). This explains the clinical differences between erythropoietic protoporphyria (EPP) and PCT.⁴

Complement participation – Its participation in the genesis of the skin injury was suggested by immunofluorescence studies which identified complement (C') on vessels walls and on the dermal-epidermal junction (DEJ).³⁶⁻³⁸ In vitro irradiation of serum of PCT patients results in C' activation.³⁹ Porphyrin-induced photosensitization is suppressed in animals with C' depletion and congenitally C5 deficient.⁴⁰ Chemotaxis generation due to C5 is also seen after skin exposure to radiation at Soret band in PCT patients.³³ Light irradiated porphyrin presumably generates ORF, especially singlet oxygen, which in turn, activates C'.⁴¹

Fibroblast proliferation and fibrosis – Enhanced biosynthesis of collagen occurs after incubation of fibroblasts with URO, irrespective of light radiation.⁴² C' activation causes generation of anaphylotoxin (C5a),³³ releasing histamine from mast cells, which stimulate collagen production.⁴³ Fibrosis may also be secondary to vascular injury.³⁶

Eicosanoid metabolism – *In vitro* incubation of peritoneal macrophages of rats or of fibrosarcoma cells with hematoporphyrin derivatives, followed by radiation of 630nm, results in the generation of prostaglandin E₂ (PGE₂).⁴⁴ It is known that the PCT blister fluid contains PGE₂.⁴⁵

Matrix metalloproteinases (MMP) – *In vitro* photoexcited URO induces interstitial collagenases [MMP-1, MMP-2 (type IV collagenase) and MMP-3 (stromelysin-1)] in fibroblasts of human dermis, suggesting that the degradation of the dermis and basal membrane may be caused by such enzymes.⁴⁶

The cause of pigment changes and hypertrichosis was not elucidated yet.

TRIGGERING FACTORS

The factors that often contribute to the occurrence of PCT are alcohol, estrogens, iron, hepatitis C virus (HCV), human immunodeficiency virus (HIV), polychlorinated hydrocarbons and hemodialysis in patients with chronic renal failure (CRF). At least one of these factors is present in most patients, regardless of the PCT type.⁵

Alcohol – alcoholism has been acknowledged as an important triggering factor of PCT.⁴⁷ Since most of the

alcoholics do not develop PCT, it is clear that alcohol only acts in synergism with other factors in predisposed subjects.⁴⁸ This is possibly linked to the inheritance of mutations associated to hemochromatosis (Cys282Tyr).⁴⁹ The analysis of urinary porphyrin excretion and of hepatic porphyrin concentration in alcoholics with chronic liver disease suggests that the biochemical changes consistent with Urod deficiency are more frequent than the diagnosis of PCT.⁵⁰ Chronic alcoholism leads to suppression of erythropoiesis and increases dietary iron absorption.⁵¹ Alcohol induces cytochrome P450 isoenzyme causing the consumption of the hepatic heme and affecting ALA-synthetase expression, increasing Urogen generation and overloading Urod, inhibited or genetically altered, promoting the enzyme deficit manifestation.⁵²

Estrogens – The use of estrogens for contraception, post-menopause hormonal replacement or hormonal therapy in men with prostate cancer, may be associated to PCT.⁶ Estrogens are the single triggering factor in over 25% of women with PCT,⁵³ and its interruption is usually enough for remission, when used for a short time.⁵⁴ The mechanism by which they act for PCT expression is no yet established. Estrogens induce hepatic ALA-synthetase, but this does not explain the excretion pattern of porphyrins in PCT.⁵⁵ Estrogens may also act inhibiting Urod in the liver of patients with genetically reduced enzyme.⁵⁶

Hexachlorobenzene (HCB) – Used as a fungicide, caused an "epidemic" of toxic PCT in southeast Turkey in 1952. It was also used as a pesticide in wheat seeds, but due to famine, thousands of people, mostly children ate bread made with this wheat and presented toxic PCT.²⁰ Toxic porphyria may be caused by other chlorated hydrocarbons, such as polychlorinated biphenyl (PCB) and 2, 3, 7, 8-tetrachlorodibenzo-p-dioxin (TCDD), byproducts in the synthesis of herbicides.⁵⁷

Hemochromatosis and iron metabolism – Iron overload ranges from mild to moderate in most patients, and clinical hemochromatosis is uncommon.²² Some degree of hepatic siderosis is present in 80% of patients with PCT.^{5,48,58,59} PCT is frequent where alcoholism is due to iron-rich beer and wine, like in South Africa and Italy.³⁰ Cys282Tyr in the hemochromatosis gene was identified as a susceptibility factor for acquired or familial PCT.⁹ People homozygous for this mutation with hemochromatosis have up to 60-fold greater risk of having PCT53 and have earlier onset of skin lesions.¹⁸ In southern Europe, another mutation in the hemochromatosis gene which also may be associated to PCT is H63D.⁶⁰

Viral infections – The role of hepatotropic viruses in triggering PCT has been reported since 1992.⁶¹ The prevalence of anti-HCV antibodies ranges

from 8% to 90%, and it is related to its endemicity in the population,^{9,11,62} being higher in some regions of Europe (France,⁶³ Spain,⁶⁴ Italy^{31,61} e Poland⁶⁵) and in the United States.⁵³ There is no predominance of HCV genotype in porphyrias.⁶⁶ These patients have additional benefit from phlebotomy, because lowering iron improves hepatic inflammation and response to interferon treatment.⁶⁷ There must be a predisposition for Urod deficiency, because most patients with hepatitis C do not develop PCT.⁶⁸ As PCT may be the first indication of an HCV infection, it is important to be searched in all patients.⁶⁹ The hypotheses explaining the role of HCV in PCT encompass: (1) lower Urod activity secondary to hepatocyte injury;^{64,70} (2) changes in the cytochrome P450 oxidase-dependent system;⁷⁰ and (3) increased auto-immune response in the liver.³¹ Auto-antibodies would occur due to a mechanism of molecular mimicking⁷¹ and they act as inhibitors of the Urod catalytic activity.⁷² There is also slight increase in the prevalence of hepatitis B.⁷³

The association of HIV with PCT was first recognized in 1987,⁷⁴ and in the early records, PCT usually occurred in the late phases of the infection.⁷⁵ Currently, in most cases reported, the diagnosis of HIV is concomitant to that of PCT;⁷⁶ therefore, ordering HIV serology should be considered in all PCT patients. Other triggering factors are usually associated, such as alcohol, hepatitis B and hepatitis C. It is likely that the combination of these factors causes hepatic injury, and the HIV infection enhances the injury.⁷⁶

Hemodialysis – PCT may occur in patients with CRF treated by hemodialysis.^{77,78} Predisposition to PCT is likely due to preexistent reduction of hepatic Urod activity.⁷⁹ Iron overload in these patients also contributes to reducing Urod activity.⁸⁰

CLINICAL MANIFESTATIONS

Vesicles and bullae, followed by erosions and crusts occur mainly in sun and trauma exposed areas, such as face, back of hands (Figure 3) and feet.^{6,81} Just about all patients present skin fragility. Bullae are tense, not surrounded by inflammation, and their content is usually clear, occasionally hemorrhagic. Hypopigmented or hyperpigmented scars with millia occur mainly in the fingers and the back of hands.⁸² Another skin change is the diffuse hyperpigmentation of the face and of the photoexposed areas.^{6,69,81} Hyperpigmentation may be the first sign of the disease in women (Figure 4).⁸³ Hair is usually of lanugo type but may vary in thickness and color, occurring in the frontotemporal and upper malar regions.⁸¹ Sclerodermiform plaques occur in 1.6% to 18% of patients^{69,84} and usually appear after long duration of the disease.^{84,85} Plaques are white-yellowish, hardened and they occur in photoexposed or protected areas.⁴³

The association with scleroderma is rare.⁸⁶ Other cutaneous changes are cicatricial alopecia,⁶⁹ precocious aging with solar elastosis and comedones,^{81,82} and onycholysis.⁸¹ Non-cutaneous manifestations are peripheral neuropathy,⁸⁷ Van der Hoeve scleromalacia perforans,⁸⁸ palmar fibromatosis,⁸² deafness, insomnia, personality changes, conjunctivitis and epiphora.⁸⁹ Nausea, anorexia, diarrhea and constipation are other symptoms described.⁸²

ASSOCIATED CONDITIONS

Hepatic changes – Hepatic disease is unusual, despite hepatic enzyme changes and increased hepatic porphyrin, with precipitated uroporphyrinogen crystals inside hepatocytes.⁹⁰ The crystals are needle-shaped brownish cytoplasm inclusions, showing double refraction under polarized light and specific of PCT,⁹¹ but their contribution to the progression of the hepatic disease is controversial.⁵⁹ Cirrhosis occurs in less than 15% of patients, who have greater risk of developing hepatocellular carcinoma (HCC) than those with cirrhosis of other causes.^{59,92,93} The incidence of HCC in PCT ranges from 5% to 16%, and, in autopsies, from 40% to 50%, indicating that these tumors are asymptomatic and slow progressing.⁹⁴ The coexistence of factors, such as viral hepatitis, alcohol and iron overload may explain the occurrence of HCC in patients with PCT.⁹² The risk of HCC increases in men older than 50 years, with symptomatic PCT for 10 years or longer and with cirrhosis.^{93,94} The risk of HCC decreases with early effective treatment.⁹⁴ The patients should be monitored with ultra-sound and serum alpha-fetoprotein measurements for the early detection of HCC.⁹⁵ Surgery and the intratumoral injection of absolute ethanol, to cause tumor necrosis, are successful procedures in small tumors with no associated cirrhosis. Regardless of the treatment

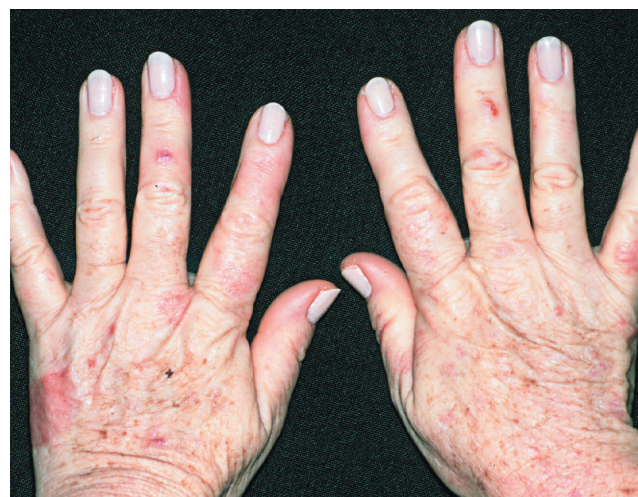

FIGURE 3: Porphyria cutanea tarda – Bullae and ulcerated lesions topped by crusts on the dorsum of hands

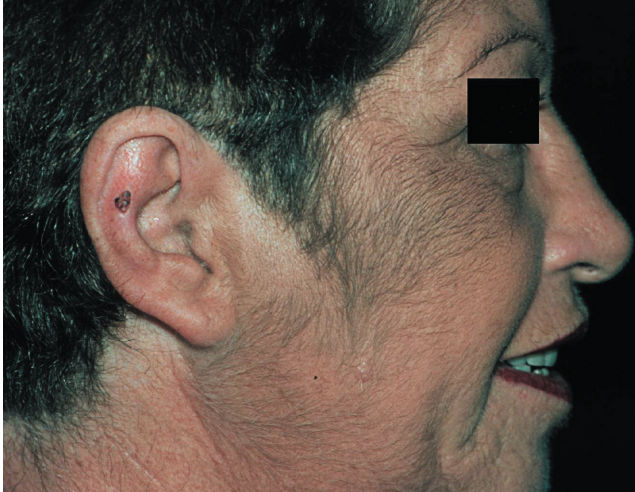

FIGURE 4: Porphyrria cutanea tarda – Female patient with hypertrichosis in the malar region

employed, metastases are frequent, even in small tumors, because of microscopic vascular invasion.¹⁴

Glucose intolerance – It is often mentioned in PCT, and in some reports the incidence of diabetes mellitus is greater than 40%, especially in men.⁶ In one study, 77% of participants had altered glucose tolerance test (GTT),⁴⁸ but in another research, the GTT of 20 PCT patients was compared with controls and no differences were found.⁹⁶ Some authors associate glucose intolerance to the presence of the hemochromatosis gene rather than to PCT.⁹⁷

Other associated conditions to PCT are systemic lupus erythematosus⁹⁸ or discoid lupus,⁹⁹ dermatomyositis,⁶ systemic sclerosis,⁸⁶ hematological disorders,¹⁰⁰ sideroblastic anemia,¹¹ thalassemia¹¹ and cytomegalovirus infection.⁸⁰

DIAGNOSIS AND LABORATORY FINDINGS

The diagnosis of PCT is made clinically, histopathologically and by the analysis of urinary, fecal and blood porphyrins.

Porphyrin analysis

The screening test, with the Wood lamp, is positive in urine (+ +) and in feces (+ +) and negative in blood (erythrocytes).¹⁰¹ If the screening test is positive or dubious, the quantitative test must be performed.

Urinary porphyrins may be quantified by the HPLC (High Performance Liquid Chromatography) method.¹⁰² The six porphyrin fractions are detected and identified with this test – uroporphyrin (URO), 7-, 6- and 5-carboxyl porphyrin, and coproporphyrin (Copro) – in 24-hour urine. In PCT, the characteristic pattern is the increased excretion of URO (50 times) and of 7-carboxyl porphyrin. 6- and 5-carboxyl porphyrins may also be increased. Copro is less

increased. than URO is.^{14,30} The URO/Copro ratio is usually greater than 3:1, while in physiological conditions this ratio is about 1:4.²³ The biochemical marker to assess response to treatment is the quantification of urinary porphyrins.⁶⁹

Fecal porphyrin of patients with PCT is increased and is primarily represented by Isocopro, 7-carboxyl porphyrin and, in lesser amounts, by URO and Copro. The 24-hour fecal protein excretion is greater than the total amount excreted in urine.²³

The main plasma porphyrin is uroporphyrin, which can be measured in a qualitative test, by plasma dilution in phosphate buffered saline and read in a spectrophotometer. It is further subjected to 410nm wave length, producing a characteristic emission peak between 618 and 620nm.¹⁰³

Other biochemical changes – Virtually all patients have increased serum iron, iron saturation, and ferritin.^{2,23} Approximately 50% of them have increased serum transaminases and γ -glutamyl-transpeptidase.⁴

HISTOPATHOLOGY

PCT displays histopathologically characteristic subepidermal bulla that distinguishes it from other porphyrias, suggesting that in PCT an additional unknown pathologic event occurs.^{36,37,104} In the base of the subepidermal bulla, dermal papillae extend to the internal bulla cavity (Figure 5). This phenomenon called festonamento is explained by the rigidity of the upper dermis induced by eosinophilic material in vessel walls.¹⁰⁴ Inflammatory infiltrate is mild or absent.¹⁰⁴ In sclerodermiform lesions, dermis sclerosis is caused by increased collagen I, similar to systemic scleroderma,^{36,84} and there is a significant number of mast cells in the inflammatory infiltrate.⁴³ Exposed skin often displays considerable solar elastosis.³⁶

With PAS (periodic acid Schiff) staining, hyaline material, PAS-positive and diastase-resistant is found in the upper dermis vessel walls and in the DEJ (Figure 6).^{37,105} Hyaline deposits are the response to repeated episodes of injury in vessel walls with content leakage.¹⁰⁶ Electron microscopy demonstrated that thickening is due to multiple layers of basal lamina, thin collagen fibers and filamentous and amorphous material.^{36,37,104} Histochemical studies demonstrated that the hyaline deposits contain tryptophan, originated in the blood, not found in the dermis¹⁰⁷ The structural changes in the DEJ are identical to those described in vessels.^{36,37}

Direct immunofluorescence (DIF) detects IgG, IgA, IgM, and C3 within the vessel walls and in DEJ (Figure 7).³⁸ Circulating auto-antibody against vascular, perivascular antigens and anti-basal membrane, or immunocomplexes, were not identified; therefore

it is unlikely that such deposits result from an immunological phenomenon.^{36,37} Several authors suggest that deposit occurs due to the entrapment of immunoglobulins and complement in the hyaline material.^{36,84} Since the DEJ deposits correspond to the vessel deposit, it is likely that they are leaking plasma components.^{36,37} The immunoglobulin deposits cannot be blamed for fragility because they also occur in EPP, in which there is no fragility.³⁶ It is believed that such difference is related to solubility of the involved porphyrins.³⁷

Some studies using electron microscopy and immunomapping (antigenic immunomapping of the dermal-epidermal junction) observed different bulla cleavage levels: basal keratinocytes,¹⁰⁸ lamina lucida,^{109,110} dense sublamina¹⁰⁵ and papillary dermis.³⁶

DIFFERENTIAL DIAGNOSIS

The differential diagnosis of PCT must be made with hereditary coproporphyrin, porphyria variegata, hepatoerythropoietic porphyria, late onset congenital erythropoietic porphyria (Günther disease), pseudoporphyria, acquired bullous epidermolysis and scleroderma.²³ All these disorders can be differentiated on clinical, histological grounds, immunofluorescence or by the study of porphyrins.

TREATMENT

After the identification and suppression of the triggering factor of the disease, especially alcohol and estrogens, there is gradual improvement.^{11,111}

Phlebotomy – Several reports stress the efficacy of this treatment,¹¹¹ which was introduced by Ippen, in 1961.¹¹² Phlebotomy is an outpatient procedure in which approximately 500ml (one unit) of

blood are removed weekly or at every two weeks, until hemoglobin reaches 10g/dl or serum iron reaches 50 to 60 µg/dl.²³ The goal of this treatment is to reduce the iron stores to a level lower than the normal limit.⁴ Ferritin does not assess the intensity of iron deposits,¹¹³ because it may be increased by infectious, inflammatory and malignant diseases.¹¹⁴ Low ferritin levels, on the other hand, always indicate low body iron stores,¹¹⁵ and, thus, phlebotomies must be interrupted when the lower reference limit is reached.¹¹⁶ Porphyrin excretion may remain low after the interruption of phlebotomies.²³ In 90% of patients treated with phlebotomy, the urinary excretion of URO reaches normal levels after five to 12 months.¹⁵⁰ The remission time is quite variable (four to 85 months).⁶ Relapse occurs at about 2.5 years after the end of the treatment, and in most cases, responds to a new treatment.¹¹⁷ Phlebotomy is the treatment of choice for patients with the hemochromatosis gene, because it prevents iron induced hepatic injury.¹¹⁸ It is contra-indicated in cases of anemia, cardiovascular disease, hepatic cirrhosis (blood loss increases the need for albumin synthesis) and HIV.²³

Antimalarials – Low dose chloroquine diphosphate (aminoquinolona) is utilized.¹¹⁷ Hydroxichloroquine is seldom utilized and was associated to early relapse.¹¹⁹ In 1957, chloroquine was first used to treat PCT, because of its action in some photodermatoses.^{120,121} chloroquine in antimalarial doses causes severe hepatotoxic reaction associated to intense uroporphynuria and photosensitization.¹²⁰ Low doses - 125mg^{117,122,123} or 250mg¹²⁴ - twice a week, were successfully used in several reports. Chloroquine administration is followed by increased

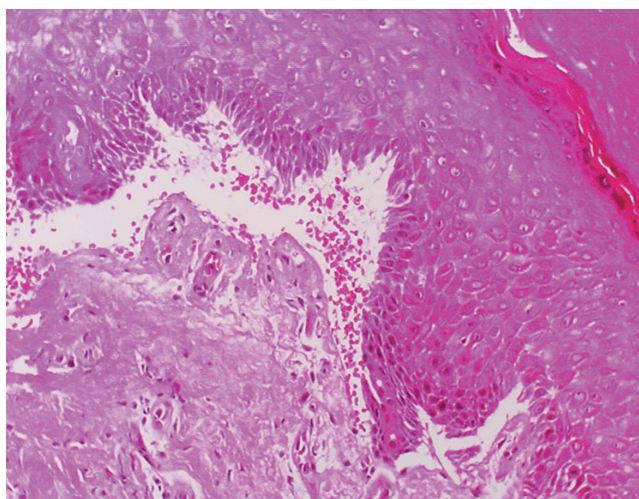


FIGURE 5: Porphyria cutanea tarda – Histopathology with hematoxylin-eosin stain showing subepidermal bulla with straight dermal papillae and no inflammatory infiltrate (40x).

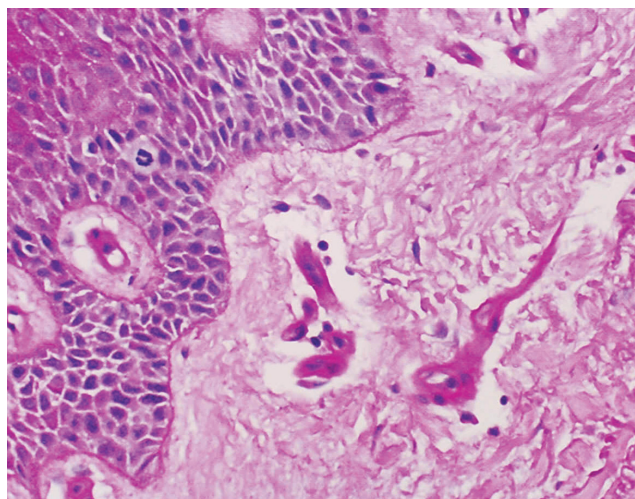


FIGURE 6: Porphyria cutanea tarda – Periodic acid Schiff staining depicting PAS-positive diastase-resistant hyaline material thickening the wall of dermal vessel and the dermal-epidermal junction (40x).

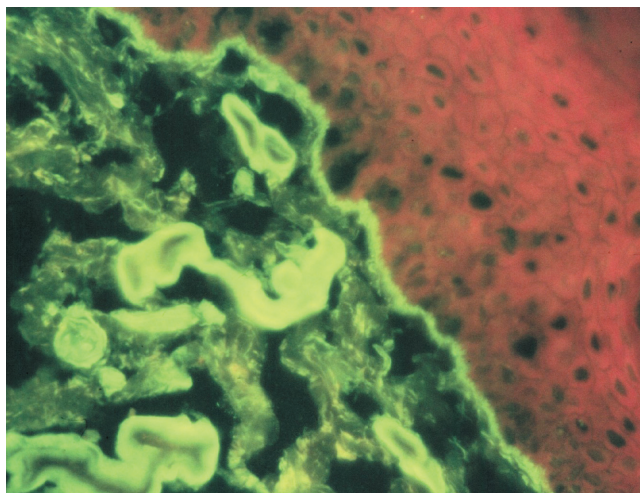


FIGURE 7: Porphyria cutanea tarda – Direct immunofluorescence of injured skin showing homogeneous, intense and continuous fluorescence in the dermal-epidermal junction and walls of vessels with anti-IgG

urine excretion of porphyrins¹²⁵ and slight increase in hepatic transaminases at the beginning of treatment.¹²⁴ Chloroquine does not worsen hepatic injury^{124,126} nor causes retinopathy, when used in low doses.¹²⁷ Bullae and cutaneous fragility improve in approximately⁶ months and the porphyrin excretion normalizes between six to 15 months.^{117,122,124,127} It is recommended that treatment must not be interrupted until biochemical remission (urine URO < 100µg/24h) is attained.¹²² The duration of the remission period varies from 17 to 24 months.^{122,127} Chloroquine is effective, however relapse occurs earlier than after phlebotomy.¹¹⁷ There are several hypotheses to explain the mechanism of action of chloroquine: (1) it chelates iron from hepatocytes,

which is later eliminated;¹²⁸ (2) it reduces ALA-synthetase activity;¹²⁹ (3) it forms a complex with uroporphyrin, which is excreted by the liver through the bile,¹³⁰ but the model utilized is not comparable to human PCT¹²⁹, and (4) it increases the excretion of porphyrins by means of exocytosis and has a porphyrinostatic effect, inhibiting porphyrin formation.¹²⁴ Phlebotomy associated to chloroquine is employed when there is inadequate response the either treatment alone.¹³¹

Interferon-alpha (IFN-α) – Its use in patients with HCV may improve the skin lesions and porphyrin excretion.^{132,133} The reduction in porphyrins may occur with no change in the HCV viral load.¹³³ It is suggested that it acts by inducing reduction of hepatic siderosis¹³² or by its immunomodulator effect, diminishing the inflammatory response to HCV, which would cause Urod inhibition.¹³⁵

Human recombinant erythropoietin – In chronic renal failure porphyrins have displayed high affinity with plasma proteins and thus are not dialyzable. Chloroquine cannot be utilized because the complexes it forms with porphyrin are not filtered either, and the associated anemia precludes phlebotomy indication. The use of human recombinant erythropoietin can reduce iron excess.^{134,135} When the patient does not respond to this treatment, low volume phlebotomy is used.¹³⁶ Renal transplantation may improve PCT.¹³⁷

Other possible treatments are the slow administration of subcutaneous deferoxamine (iron chelating agent),¹³⁸ cholestiramine¹³⁹ and oral thalidomide.¹⁴⁰

In the follow-up, the coexisting hepatic disease is supervised and, in order to prevent relapses, urinary porphyrins are measured, because porphyrinuria precedes dermatological manifestations. □

REFERENCES

- Elder GH, Roberts AG. Uroporphyrinogen decarboxylase. *J Bioenerg Biomembr.* 1995;27:207-14.
- Rich MW. Porphyria cutanea tarda. Don't forget to look at the urine. *Postgrad Med.* 1999;105:208-10, 213-4.
- Waldenström J. Studien über Porphyrie. *Acta Med scand.* 1937;82(Suppl):S84-90.
- Elder GH. The cutaneous porphyrias. In: Hawk JLM. *Photodermatology.* New York: Oxford University Press; 1999. p.171-97.
- Siersema PD, Rademakers LH, Cleton MI, ten Kate FJ, de Bruijn WC, Marx JJ, et al. The difference in liver pathology between sporadic and familial form of porphyria cutanea tarda: the role of iron. *J Hepatol.* 1995;23:259-67.
- Grossman ME, Bickers DR, Poh-Fitzpatrick MB, Deleo VA, Harber LC. Porphyria cutanea tarda: clinical features and laboratory findings in 40 patients. *Am J Med.* 1979;67:277-86.
- Bygum A, Christiansen L, Peterson NE, Horder M, Thomsen K, Brandrup F. Familial and sporadic porphyria cutanea tarda: clinical, biochemical and genetic features with emphasis on iron status. *Acta Derm Venereol.* 2003;83:115-20.
- Kushner JP, Barbuto AJ, Lee GR. An inherited enzymatic defect in porphyria cutanea tarda: decreased uroporphyrinogen decarboxylase activity. *J Clin Invest.* 1976;58:1089-97.
- Elder GH, Worwood M. Mutations in the hemochromatosis (HFE) gene, porphyria cutanea tarda and iron overload. *Hepatology.* 1998;27:289-91.
- Held JL, Sassa S, Attalah K, Harber LC. Erythrocyte uroporphyrinogen decarboxylase activity in porphyria cutanea tarda: a study of 40 consecutive patients. *J Invest Dermatol.* 1989;93:332-4.
- Elder GH. Porphyria cutanea tarda. *Semin Liver Dis.* 1998;18:67-75.
- Elder GH, Urquhart AJ, de Salamanca RE, Munoz JJ, Bonkovsky H. Immunoreactive uroporphyrinogen decarboxylase in the liver in porphyria cutanea tarda. *Lancet.* 1985;2:229-32.
- Garey JR, Franklin KF, Brown DA, Harrison LM, Metcalf KM, Kushner JP. Analysis of uroporphyrinogen decarboxylase complementary DNAs in sporadic porphyria cutanea tarda. *Gastroenterology.* 1993;105:165-9.
- Thunell S, Harper P. Porphyrias, porphyrin metabolism, porphyrias. III. Diagnosis, care and monitoring in porphyria cutanea tarda - suggestions for a handling programme. *Scand J Clin Lab Invest.* 2000;60:561-79.
- DeVerneuil H, Aitkne G, Nordmann Y. Familial and sporadic porphyria cutanea tarda: two different diseases. *Hum Genet.* 1978;44:145-51.
- Doss MO, Frank M, Braun-Falco O. Porphyria cutanea tarda: erythrocyte uroporphyrinogen decarboxylase activity in 471 consecutive patients. *Curr Probl Dermatol.* 1991;20:97-105.
- Sassa S, Kappas A. Molecular aspects of the inherited porphyrias. *J Intern Med.* 2000;247:169-78.
- Brady JJ, Jackson HA, Roberts AG, Morgan RR, Whatley SD, Rowlands GL, et al. Co-inheritance of mutations in the uroporphyrinogen decarboxylase and hemochromatosis genes accelerates the onset of porphyria cutanea tarda. *J Invest Dermatol.* 2000;115:868-74.
- D'Alessandro Gandolfo L, Griso D, Macri A, Biolcati G, Topi GC. Familial porphyria cutanea tarda with normal erythrocytic urodecarboxylase: an exception to the rule? *Dermatologica.* 1989;178:206-8.
- Cripps DJ, Peters HA, Gocmen A, Dogramici I. Porphyria turcica due to hexachlorobenzene - a 20 to 30 year follow-up study on 204 patients. *Br J Dermatol.* 1984;111:413-22.
- Pazderova-Vejlupková J, Nemcova M, Pícková J, Jirásek L, Lukás E. The development and prognosis of chronic intoxication by tetrachlorodibenzo-p-dioxin in men. *Arch Environ Health.* 1981;36:5-11.
- Kappas A, Sassa S, Galbraith RA, Nordmann Y. The porphyrias. In: Scriver CR, Beaudet AL, Sly WS, Valle D, editors. *The molecular and metabolic basis of inherited disease.* 7th ed. New York: Mc Graw-Hill; 1995. p.2103-59.
- Bickers DR, Pathak MA. The porphyrias. In: Fitzpatrick TB, Eisen AZ, Wolff K, Freedberg IM, Austen KF. *Dermatology in General medicine.* 4th ed. New York: McGraw-Hill; 1995. p.1854-93.
- Elder GH. Porphyria cutanea tarda: a multifactorial disease. In: Champion RH, Pye RJ, eds. *Recent advances in dermatology.* Edinburgh: Churchill Livingstone; 1990. p.55-70.
- De Matteis F. Role of iron in the hydrogen peroxide-dependent oxidation of hexahydroporphyrins (porphyrinogens): a possible mechanism for the exacerbation by iron of hepatic uroporphyrin. *Mol Pharmacol.* 1988;33:463-9.
- Constantin D, Francis JE, Akhtar A, Clothier B, Smith AG. Uroporphyrin induced by 5-aminolevulinic acid in Ahrd SWR mice. *Biochem Pharmacol.* 1996;52:1407-13.
- De Matteis F. Drug induced abnormalities of liver heme biosynthesis. In: Meeks RG, Harrison SD, Bull RJ. *Hepatotoxicology.* Boston: CRC press; 1991. p.437-79.
- Francis JE, Smith AG. Oxidation of uroporphyrinogens by hydroxyl radicals: evidence for nonporphyrin products as potential inhibitors of uroporphyrinogen decarboxylase. *Febs Lett.* 1988;233:311-4.
- Lambrech RW, Sinclair PR, Gorman N, Sinclair JF. Uroporphyrinogen oxidation catalyzed by reconstituted cytochrome P450IA2. *Arch Biochem Biophys.* 1992;294:504-10.
- Sweeney GD. Porphyria cutanea tarda, or the uroporphyrinogen decarboxylase deficiency diseases. *Clin Biochem.* 1986;19:3-14.
- Ferri C, Baicchi U, LaCivita L, Greco F, Longombardo G, Mazzoni A, et al. Hepatitis C virus-related autoimmunity in patients with porphyria cutanea tarda. *Eur J Clin Invest.* 1993;23:851-5.
- Meyer-Betz F. Untersuchungen über die biologische (photodynamische) Wirkung des Hämatoporphyrins und anderer Derivate des Blut und Gallenfarbstoffs. *Dtsch Arch Klin Med.* 1913;112:476-503.
- Lim HW, Poh-Fitzpatrick MB, Gigli I. Activation of the complement system in patients with porphyrias after irradiation in vivo. *J Clin Invest.* 1984;74:1961-5.
- Lim HW, Gigli I, Wasserman SI. Differential effects of protoporphyrin and uroporphyrin on murine mast cells. *J Invest Dermatol.* 1987;88:281-6.
- Athar M, Elmets CA, Bickers DR, Mukhtar H. A novel mechanism for the generation of superoxide anions in hematoporphyrin derivative-mediated cutaneous photosensitization. Activation of the xanthine oxidase pathway. *J Clin Invest.* 1989;83:1137-43.
- Wolff K, Hönigsmann H, Rauschmeier W, Schuler G,

- Pechlaner R. Microscopic and fine structural aspects of porphyrias. *Acta Derm Venereol (Stockh)*. 1982; 100 (Suppl):S17-28.
37. Epstein JH, Tuffanelli DL, Epstein WL. Cutaneous changes in the porphyrias: a microscopic study. *Arch Dermatol*. 1973;107:689-98.
 38. Cormane RH, Szabò E, Hoo TT. Histopathology of skin in acquired and hereditary porphyria cutanea tarda. *Br J Dermatol*. 1971;85:531-9.
 39. Torinuki W, Miura T, Tagami H. Activation of complement by 405-nm light in serum from porphyria cutanea tarda. *Arch Dermatol Res*. 1985;277:174-8.
 40. Lim HW, Gigli I. Role of complement in porphyrin-induced photosensitivity. *J Invest Dermatol*. 1981;76:4-9.
 41. Schnait FG, Wolff K, Konrad K. Erythropoietic protoporphyria-submicroscopic events during the acute photosensitivity flare. *Br J Dermatol*. 1975;92:545-57.
 42. Varigos G, Schiltz JR, Bickers DR. Uroporphyrin I stimulation of collagen biosynthesis in human skin fibroblasts. A unique dark effect of porphyrin. *J Clin Invest*. 1982;69:129-35.
 43. Torinuki W, Kudoh K, Tagami H. Increased mast cell numbers in the sclerotic skin of Porphyria cutanea tarda. *Dermatologica*. 1989;178:75-8.
 44. Henderson BW, Donovan JM. Release of prostaglandin E2 from cells by photodynamic treatment *in vitro*. *Cancer Res*. 1989;49:6896-900.
 45. Sandberg S, Romslo I, Hovding G, Bjorndal T. Porphyrin-induced photodamage as related to the subcellular localization of the porphyrins. *Acta Derm Venereol Suppl (Stockh)*. 1982;100:75-80.
 46. Herrmann G, Wlaschek M, Bolsen K, Prenzel K, Goerz G, Scharffetter-Kochanek K. Photosensitization of uroporphyrin augments the ultraviolet A-induced synthesis of matrix metalloproteinases in human dermal fibroblasts. *J Invest Dermatol*. 1996;107:398-403.
 47. Brunsting LA, Mason HL, Aldrich RA. Adult form of chronic porphyria with cutaneous manifestations. Report of seventeen additional cases. *J Am Med Assoc*. 1951;146:1207-12.
 48. Lundvall O, Weinfeld A, Lundin P. Iron storage in porphyria cutanea tarda. *Acta Med Scand*. 1970;188:37-53.
 49. Sampietro M, Fiorelli G, Fargion S. Iron overload in porphyria cutanea tarda. *Haematologica*. 1999;84:248-53.
 50. Doss M, Look D, Henning H, Nawrocki P, Schmidt A, Dolle W, et al. Hepatic porphyrins and urinary porphyrins and porphyrin precursors in liver cirrhosis. *Klin Wochenshr*. 1972;50:1025-32.
 51. Chapman RW, Morgan MY, Laulich M, Hoffbrand AV, Sherlock S. Hepatic iron stores and markers of iron overload in alcoholics and patients with hemochromatosis. *Dig Dis Sci*. 1982;27:909-16.
 52. Thunell S, Floderus Y, Henrichson A, Moore M, Meissner P, Sinclair J. Alcoholic beverages in acute porphyria. *J Stud Alcohol*. 1992;53:272-6.
 53. Bulaj ZJ, Phillips JD, Ajioka RS, Franklin MR, Griffen LM, Guinee DJ, et al. Hemochromatosis genes and other factors contributing to the pathogenesis of porphyria cutanea tarda. *Blood*. 2000;95:1565-71.
 54. Haberman HF, Rosenberg F, Menon IA. Porphyria cutanea tarda: comparison of cases precipitated by alcohol and estrogens. *Can Med Assoc J*. 1975;113:653-5.
 55. Levere RD. Stilbestrol-induced porphyria: increase in hepatic delta-aminolevulinic acid synthetase. *Blood*. 1966;28:569-72.
 56. Sixel-Dietrich F, Doss M. Hereditary uroporphyrinogen-decarboxylase deficiency predisposing porphyria cutanea tarda (chronic hepatic porphyria) in females after oral contraceptive medication. *Arch Dermatol Res*. 1985;278:13-6.
 57. Altomare G, Capella GL. Occupational porphyria cutanea tarda due to exposure to symmetrical triazine herbicides. *Eur J Dermatol*. 1995;5:66-8.
 58. Bruguera M. Liver involvement in porphyria. *Seminars Dermatol*. 1986;5:178-85.
 59. Cortés J, Oliva H, Paradinas FJ, Hernandez-Guío C. The pathology of the liver in porphyria cutanea tarda. *Histopathology*. 1980;4:471-85.
 60. Sampietro M, Pipeno A, Lupica L, Arosio C, Vergani A, Corbeta N, et al. High prevalence of the His63Asp HFE mutation in Italian patients with porphyria cutanea tarda. *Hepatology*. 1998;27:181-4.
 61. Fargion S, Piperno A, Cappellini MD, Sampietro M, Fracanzani AL, Romano R, et al. Hepatitis C virus and porphyria cutanea tarda: evidence of a strong association. *Hepatology*. 1992;16:1322-6.
 62. Quecedo L, Costa J, de Salamanca RE. The role of the hepatitis C virus in the liver disease of porphyria cutanea tarda. *Med Clin (Barc)*. 1996;106:321-4.
 63. Lacour JPH, Bodokh I, Castanet J, Bekri S, Ortonne JP. Porphyria cutanea tarda and antibodies to hepatitis C virus. *Br J Dermatol*. 1993;128:121-3.
 64. DeCastro M, Sánchez J, Herrera JF, Cháves A, Durán R, García-Buey L, et al. Hepatitis C virus antibodies and liver disease in patients with porphyria cutanea tarda. *Hepatology*. 1993;17:551-7.
 65. Dabrowska E, Jablonska-Kaszewska I, Falkiewicz B. High prevalence of hepatitis C virus infection in patients with porphyria cutanea tarda in Poland. *Clin Exp Dermatol*. 1998;23:95-6.
 66. Cribier B, Petiau P, Keller F, Schmitt C, Vetter D, Held E, et al. Porphyria cutanea tarda and hepatitis C viral infection. *Arch Dermatol*. 1995;131:801-4.
 67. Bonkovsky HL, Poh-Fitzpatrick M, Pimstone N, Obando J, Di Bisceglie A, Tattrie C, et al. Porphyria cutanea tarda, hepatitis C, and HFE gene mutations in North America. *Hepatology*. 1998;27:1661-9.
 68. Cribier B, Rey D, Uhl G, Le Coz C, Hirth C, Libbrecht E, et al. Abnormal urinary coproporphyrin levels in patients infected by hepatitis C virus with or without HIV. *Arch Dermatol*. 1996;132:1448-52.
 69. Sarkany RPE. The management of porphyria cutanea tarda. *Clin Exp Dermatol*. 2001;26:225-32.
 70. Herrero C, Vicente A, Bruguera M, Ercilla MG, Barrera JM, Vidal J, et al. Is hepatitis C infection a trigger of porphyria cutanea tarda? *Lancet*. 1993;341:788-9.
 71. Ma Y, Fracanzani AL, Sampietro M, Mattioli M, Cheeseman P, Williams R, et al. Autoantibodies to human cytosol: a marker of sporadic porphyria cutanea tarda. *Clin Exp Immunol*. 2001;126:47-53.
 72. Gregorio GV, Pensati P, Iorio R, Vegnente A, Mieli-Vergani G, Vergani D. Autoantibody prevalence in children with liver disease due to chronic hepatitis C virus (HCV) infection. *Clin Exp Immunol*. 1998;112:471-6.
 73. Navas S, Bosch P, Castillo I, Marriott E, Carreno V. Porphyria cutanea tarda and hepatitis C virus and B virus infection: a retrospective study. *Hepatology*. 1995;21:279-84.
 74. Wissel PS, Sordillo P, Anderson KE, Sassa S, Savillo RL, Kappas A. Porphyria cutanea tarda associated with the

- acquired immune deficiency syndrome. *Am J Hematol.* 1987;25:107-13.
75. Castanet J, Lacour JP, Bodokh I, Bekri S, Ortonne JP. Porphyria cutanea tarda in association with human immunodeficiency virus infection: is it related to hepatitis C virus infection? *Arch Dermatol.* 1994;130:664-5.
 76. Mansourati FF, Stone VE, Mayer KH. Porphyria cutanea tarda and HIV/AIDS: a review of pathogenesis, clinical manifestations and management. *Int J STD AIDS.* 1999;10:51-6.
 77. Stevens BR, Fleischer AB Jr, Piering F, Crosby DL. Porphyria cutanea tarda in the setting of renal failure: response to renal transplantation. *Arch Dermatol.* 1993;129:337-9.
 78. Garcia Parrilla J, Ortega R, Pena ML, Rodicio JL, Salamanca RE, Olmos A, et al. Porphyria cutanea tarda during maintenance haemodialysis. *Br Med J.* 1980;280:1358.
 79. Elder GH, Path MRC, Lee GB, Tovey JA. Decreased activity of hepatic uroporphyrinogen decarboxylase in sporadic porphyria cutanea tarda. *N Engl J Med.* 1978;299:274-8.
 80. Burnett JW, Lamon JM, Levin J. Haemophilia, hepatitis and porphyria. *Br J Dermatol.* 1977;97:453-5.
 81. Mascaro JM, Herrero C, Lecha M, Muniesa AM. Uroporphyrinogen-decarboxylase deficiencies: porphyria cutanea tarda and related conditions. *Semin Dermatol.* 1986;5:115-24.
 82. Mascaro JM. The Porphyrias: a brief overview based on 25 years of experience (1969-1994) by the department of dermatology of the hospital clinic and faculty of medicine of Barcelona, Spain. *J Dermatol.* 1995;22:823-8.
 83. Boffa MJ, Reed P, Weinkove C, Ead RD. Hypertrichosis as the presenting feature of porphyria cutanea tarda. *Clin Exp Dermatol.* 1995;20:62-4.
 84. Krajnc I, Vizjak A, Hvala A, Jurcic V, Rozman B. The significance of histologic analysis of skin lesions in porphyria cutanea tarda. Light microscopy, electron microscopy, immunohistochemical and immunofluorescence analysis. *Wien Klin Wochenschr.* 1998;110:651-4.
 85. Doyle JA, Friedman SJ. Porphyria and scleroderma: a clinical and laboratorial review of 12 patients. *Australas J Dermatol.* 1983;24:109-14.
 86. Sigal M, Nahum HD, Crickx B, Bilet S, Mourier-Massicot CH, Belaich S. Porphyria cutanea tarda and scleroderma – chance association or related disease: a case report. *Clin Exp Dermatol.* 1990;15:285-8.
 87. Enriquez de Salamanca R, Cocero E, Jimenez LC, Franco C, Valls MV. Electroneurophysiological abnormalities in porphyria cutanea tarda. *Clin Exp Dermatol.* 1985;10:438-43.
 88. Piñol-Aguadé J, Mascaro JM, Galy-Mascaro C, Apdevila JM. Sur quelques manifestations cutanées et oculaires peu connues des porphyries. *Ann Dermatol Syphiligr (Paris).* 1969;96:265-70.
 89. Mascaro JM. Porphyria cutanea tarda: clinical manifestations. *Curr Probl Dermatol.* 1991;20:79-90.
 90. Fakan F, Chlumska A. Demonstration of needle-shaped hepatic inclusions in porphyria cutanea tarda using the ferric ferricyanide reduction test. *Virchows Arch A Pathol Anat Histopathol.* 1987;411:365-8.
 91. James KA, Cortes JM, Paradinas FJ. Demonstration of cytoplasmic needle-like inclusions in hepatocytes with porphyria cutanea tarda. *J Clin Pathol.* 1980;33:899-900.
 92. Fracanzani AL, Taioli E, Sampietro M, Fatta E, Bertelli C, Fiorelli G, et al. Liver cancer risk is increased in patients with porphyria cutanea tarda in comparison to matched control patients with chronic liver disease. *J Hepatol.* 2001;35:498-503.
 93. Salata H, Cortes JM, Enriquez de Salamanca R, Oliva H, Castro A, Kusak E, et al. Porphyria cutanea tarda and hepatocellular carcinoma. Frequency of occurrence and related factors. *J Hepatol.* 1985;1:477-87.
 94. Lim HW, Mascaro JM. The porphyrias and hepatocellular carcinoma. *Dermatol Clin.* 1995;13:135-42.
 95. Siersema PD, ten Kate FJW, Mulder PGH, Wilson JHP. Hepatocellular carcinoma in porphyria cutanea tarda: frequency and factors related to its occurrence. *Liver.* 1992;12:56-61.
 96. Lisi P, Santeusano F, Lombardi G, Compagnucci P. Carbohydrate metabolism in porphyria cutanea tarda. *Dermatologica.* 1983;166:287-93.
 97. van Ginneken EE, Lutterman JA, Netten PM. *Diabetes mellitus* in connection with hereditary disease. *Ned Tijdschr Geneesk.* 1997;141:1230-4.
 98. Clemmensen O, Thomsen K. Porphyria cutanea tarda and systemic lupus erythematosus. *Arch Dermatol.* 1982;118:160-2.
 99. O'Reilly FM, O'Loughlin S, Murphy GM. Discoid lupus erythematosus and porphyria cutanea tarda. *J R Soc Med.* 1996;89:523-4.
 100. Guyotat D, Nicolas JF, Augey F, Fiere D, Thivolet J. Porphyria cutanea tarda after allogenic bone marrow transplantation for chronic myelogenous leukemia. *Am J Hematol.* 1990;34:69-70.
 101. Magnus IA. Dermatological photobiology. Clinical and experimental aspects. Appendix II - Clinical screening tests for excess porphyrins. London: Blackwell Scientific; 1976. p.253-5.
 102. Lim CK, Peters TJ. Urine and faecal porphyrin profiles by reversed-phase high-performance liquid chromatography in the porphyrias. *Clin Chim Acta.* 1984;139:55-63.
 103. Gibbs NK, Traynor N, Ferguson J. Biochemical diagnosis of the cutaneous porphyrias: five years experience of plasma spectrofluorimetry [abstract]. *Br J Dermatol.* 1995;133:18.
 104. Lever WF, Schaumberg-Lever G. *Histopatologia da pele.* 7 ed. São Paulo: Manole; 1991. p.419-22.
 105. Timonen K, Niemi KM, Mustajoki P. Skin morphology in porphyria cutanea tarda does not improve despite clinical remission. *Clin Exp Dermatol.* 1991;16:355-8.
 106. Hönigsmann H, Gschnaiat F, Konrad K, Stingl G, Wolff K. Mouse model for protoporphyria. III. Experimental production of chronic erythropoietic protoporphyria-like skin lesions. *J Invest Dermatol.* 1976;66:188-95.
 107. Ryan EA. Histochemistry of the skin in erythropoietic protoporphyria. *Br J Dermatol.* 1966;78:501-18.
 108. Perrot H, Schmitt D, Thivolet J, Leung J, Germain D. Étude ultrastructurale de la bulle dans les porphyries cutanées hépatiques. *Bull Soc Fr Derm Syph.* 1972;79:12-8.
 109. Dabski C, Beutner EH. Studies of laminin and type IV collagen in blisters of porphyria cutanea tarda and drug-induced pseudoporphyria. *J Am Acad Dermatol.* 1991;25:28-32.
 110. Klein GF, Hintner H, Schuler G, Fritsch P. Junctional blisters in acquired bullous disorders of the dermal-

- epidermal junction zone: role of the lamina lucida as the mechanical locus minoris resistentiae. *Br J Dermatol.* 1983;109:499-508.
111. Ramsay CA, Magnus IA, Turnbull A, Baker H. The treatment of porphyria cutanea tarda by venesection. *Q J Med.* 1974;43:1-24.
 112. Ippen H. Allgemeinsymptome der späten Hautporphyrie (Porphyria Cutanea Tarda) als Hinweise für deren Behandlung. *Dtsche Med Wochenschr.* 1961;86:127-33.
 113. Rocchi E, Gibertini P, Cassanelli M, Pietrangelo A, Borghi A, Ventura E. Serum ferritin in the assessment of liver iron overload and iron removal therapy in porphyria cutanea tarda. *J Lab Clin Méd.* 1986;107:36-42.
 114. Vautier G, Murray M, Olnyk JK. Hereditary haemochromatosis: detection and management. *Med J Aust.* 2001;175:418-21.
 115. Lipschitz DA, Cook JD, Finch CA. A clinical evaluation of serum ferritin as an index of iron stores. *N Engl J Med.* 1974;290:1213-6.
 116. Ratnaik S, Blake D, Campbell D, Cowen P, Varigos G. Plasma ferritin levels as a guide to the treatment of porphyria cutanea tarda by venesection. *Australas J Dermatol.* 1988;29:3-8.
 117. Malina L, Chlumsky J. A comparative study of the results of phlebotomy therapy and low-dose chloroquine treatment in porphyria cutanea tarda. *Acta Derm Venereol.* 1981;61:346-50.
 118. McCrossin I. Porphyria cutanea tarda in south-east New South Wales. *Austral J Dermatol.* 2002;43:285-8.
 119. Malkinson FD, Levitt L. Hydroxychloroquine treatment of porphyria cutanea tarda. *Arch Dermatol.* 1980;116:1147-50.
 120. Liu AC. Hepatotoxic reaction to chloroquine phosphate in a patient with previously unrecognized porphyria cutanea tarda. *West J Med.* 1995;162:548-51.
 121. London ID. Porphyria cutanea tarda: report of a case successfully treated with chloroquine. *Arch Dermatol.* 1957;75:801-3.
 122. Ashton RE, Hawk JLM, Magnus IA. Low-dose oral chloroquine in the treatment of porphyria cutanea tarda. *Br J Dermatol.* 1981;111:609-13.
 123. Kordac V, Papezová R, Semrádová M. Chloroquine in the treatment of porphyria cutanea tarda. *N Eng J Med.* 1977;296:949.
 124. Kordac V, Jirsa M, Kotal P, Kalab M, Cervinka J, Kotyk A, et al. Agents affecting porphyrin formation and secretion: implications for porphyria cutanea tarda treatment. *Semin Hematol.* 1989;26:16-23.
 125. Freeseemann A, Frank M, Sieg I, Doss MO. Treatment of porphyria cutanea tarda by the effect of chloroquine on the liver. *Skin Pharmacol.* 1995;8:156-61.
 126. Chlumska A, Chlumska J, Malina L. Liver changes in porphyria cutanea tarda patients treated with chloroquine. *Br J Dermatol.* 1980;102:261-6.
 127. Valls V, Ena J, Enriquez de Salamanca R. Low-dose oral chloroquine in patients with porphyria cutanea tarda and low-moderate iron overload. *J Dermatol Sci.* 1994;7:169-75.
 128. Taljaard JF, Shanley BC, Stewart-Wynne EG, Deppe WM, Joubert SM. Studies on low dose chloroquine therapy and the action of chloroquine in symptomatic porphyria. *Br J Dermatol.* 1972;87:261-9.
 129. Goerz G, Bolsen K, Merk H. Influence of chloroquine on the porphyrin metabolism. *Arch Dermatol Res.* 1985;277:114-7.
 130. Scholnick PL, Epstein JH, Marver HS. The molecular basis of the action of chloroquine in porphyria cutanea tarda. *J Invest Dermatol.* 1973;61:226-32.
 131. Seubert S, Seubert A, Stella AM, Guzman H, Batlle A. Ergebnisse bei der Behandlung der Porphyria cutanea tarda mit Aderlass und Resorcin. *Z Hautkr.* 1990;65:223-5.
 132. Okano J, Horie Y, Kawasaki H, Kondo M. Interferon treatment of porphyria cutanea tarda associated with chronic hepatitis type C. *Hepatogastroenterology.* 1997;44:525-8.
 133. Sheikh MY, Wright RA, Burruss JB. Dramatic resolution of skin lesions associated with porphyria cutanea tarda after interferon-alpha therapy in a case of chronic hepatitis C. *Dig Dis Sci.* 1998;43:529-33.
 134. Fontanellas A, Herrero JA, Coronel F, Santos JL, Morán JM, Barrientos A, et al. Effects of recombinant human erythropoietin on porphyrin metabolism in uremic patients on hemodialysis. *J Am Soc Nephrol.* 1996;7:774-9.
 135. Sarkell B, Patterson JW. Treatment of porphyria cutanea tarda of end stage renal disease with erythropoietin. *J Am Acad Dermatol.* 1993;29:499-500.
 136. Poux JM, Demontis R, Cadranet JF, Ghazali A, Fievet P, Nordmann Y. Porphyria cutanea tarda in a dialyzed patient with hepatitis C virus infection: dramatic efficacy of small repeated phlebotomies. *Am J Med.* 1997;103:163-4.
 137. Ewing S, Crosby DL. Renal transplantation for porphyria cutanea tarda. *N Engl J Med.* 1997;336:811.
 138. Rocchi E, Gibertini P, Cassanelli M, Pietrangelo A, Borghi A, Pantaleoni M, et al. Iron removal therapy in porphyria cutanea tarda: phlebotomy versus slow subcutaneous desferrioxamine infusion. *Br J Dermatol.* 1986;114:621-9.
 139. Stathers GM. Porphyrin-binding effect of cholestyramine. Results of in vitro and in vivo studies. *Lancet.* 1966;2:780-3.
 140. Monastirli A, Georgiou S, Bolsen K, Pasmazi E, Papapanagiotou A, Goerz G, et al. Treatment of porphyria cutanea tarda with oral thalidomide. *Skin Pharmacol Appl Skin Physiol.* 1999;12:305-11.
 141. Gross U, Hoffmann GF, Doss MO. Erythropoietic and hepatic porphyrias. *J Inherit Metab Dis.* 2000;23:641-61.

MAILING ADDRESS:

Fátima Mendonça Jorge Vieira
Rua Voluntários da Pátria, 4370 – Cj. 121
Santana
02402 600 São Paulo SP
E-mail: fmjvieira@hotmail.com
Tel.: 6281-8712

How to cite this article: Vieira FMJ, Martins JEC. Porfiria cutanea tardia. *An Bras Dermatol.* 2006;81(6):569-80.