

Morphometric Study of Supratrochlear Foramen of the Humerus Related with Clinical Implications in a Thai Population

Estudio Morfométrico del Foramen Supratroclear del Húmero
Relacionado con Implicaciones Clínicas en una Población Tailandesa

Sorrathorn Boonchan¹; Kamonlapob Boonrugsa¹; Thanapat Charumporn¹;
Pakorn Navic²; Phruksachat Singsowan² & Pasuk Mahakkanukrauh^{2,3,4}

BOONCHAN, S.; BOONRUGSA, K.; CHARUMPORN, T.; NAVIC, P.; SINGSUWAN, P. & MAHAKKANUKRAUH, P.
Morphometric study of supratrochlear foramen of the humerus related with clinical implications in a Thai population. *Int. J. Morphol.*,
40(4):1048-1053, 2022.

SUMMARY: Supratrochlear foramen (STF) is a perforation of bony wall that separates the olecranon fossa and the coronoid fossa. Its incidence varies among different races. The aim of this study was to investigate the prevalence and morphometry of supratrochlear foramen among Thai population. A total of 640 dry humeri from 320 skeletons, 160 paired humeri of each sex, and known age were collected to study the prevalence of STF. The prevalence is reported categorized by sex and the side of humerus to identify whether there is a correlation. STF is categorized by shape and their metrics measured with digital vernier calipers. The ratio of transverse diameter (TD) and distance from the medial epicondyle to the lateral epicondyle (DMLE) were calculated to represent the size of STF. From 640 humeri, 404 cases were translucent septum, 133 cases were opaque septum, and 103 cases were recorded as foramen. In this study, the majority of supratrochlear foramen were oval-shaped, followed by irregular-shaped and round-shaped foramen. The ratio between TD and DMLE was 0.09 ± 0.44 mm on the right and 0.08 ± 0.41 mm on the left which was not significantly different. The findings can be used to understand the variation and location of supratrochlear foramen to help radiologists and orthopedic surgeons to avoid misdiagnosis of cystic lesion at the distal humerus.

KEY WORDS: Humerus; Supratrochlear foramen; Septal aperture.

INTRODUCTION

Supratrochlear foramen, also known as the olecranon aperture, the septal aperture, or foramen olecrani, is a structure located at the distal epiphysis of the humerus which is defined as a perforation of the bony wall that separates the olecranon fossa and the coronoid fossa (Chagas *et al.*, 2016). Many factors, including mechanical and genetic, are thought to be responsible for the formation of this foramen. According to Glanville's mechanical theory, supratrochlear foramen can result from repetitive injury between the ulna and humerus during flexion and extension (Glanville, 1967). Another factor that may play a significant role in supratrochlear foramen formation is T-Box (TBX) genes which are important in the developmental process of limb

and heart in utero (Chapman *et al.*, 1996). This hypothesis is supported by Hirsh in 1927 which states that this foramen may be prearranged by the TBX gene, hence the septum will not be perforated until seven years old (Hirsh, 1927).

Various factors have been found to correlate with an increase in the incidence of the foramen. One of those factors is race. From Lucas Alver Sarmiento Pires's meta-analysis of studies performed in Africa had the highest prevalence of olecranon aperture of the humerus., While studies in Europe had the lowest prevalence, there is a variation of supratrochlear foramen on the humerus among ethnic groups (Pires *et al.*, 2019). As a consequence, further study of the

¹ Faculty of Medicine, Chiang Mai University, Chiang Mai, 50200, Thailand.

² Department of Anatomy, Faculty of Medicine, Chiang Mai University, Chiang Mai, 50200, Thailand.

³ Forensic Osteology Research Center, Faculty of Medicine, Chiang Mai University, Chiang Mai, 50200, Thailand.

⁴ Excellence center in Osteology Research and Training Center (ORTC), Chiang Mai University, Chiang Mai, 50200, Thailand.
FUNDING. This work was supported by Faculty of medicine, Chiang Mai University [Grant No. 024/2565].

variation of supratrochlear foramen among the Thai population would be useful. Moreover, sex also affects the prevalence of supratrochlear foramen. Many studies show a correlation between sex and the presence of supratrochlear foramen. According to Brauer *et al.* (2007) and Diwan *et al.* (2013), it is suggested that supratrochlear foramen more often occurs in females than males. Furthermore, the association between the prevalence of supratrochlear foramen and the side of arms has been noted. A number of studies suggest that supratrochlear foramen occurs more frequently on the left side. However, Nayak *et al.* (2009) found a greater prevalence of supratrochlear foramen on the right side.

The existence of this structure is related to mistakes in clinical practice. For instance, misinterpretation can occur during the diagnostic process by a radiologist as cystic or osteolytic lesions. It is also associated with an increased risk of iatrogenic fracture caused by the nailing procedure of an orthopedic surgeon. To prevent medical errors and improve medical management, it is important to understand the morphological and morphometrical variations of this foramen.

Understanding its variation and location will help radiologists and orthopedic surgeons to improve the diagnostic approach and management of pathologic conditions of the distal humerus. This study investigates the morphometry of supratrochlear foramen among a Thai population.

MATERIAL AND METHOD

The samples were humeri of known sex, ranging from 15 to 100 years of age. Bones with pathologies or trauma were excluded from this study. The sample included 640 dry humeri from 320 skeletons. Of these, 160 paired humeri belonged to males and 160 paired humeri belonged to females. Socio-demographic data including sex and age was collected. All skeletons were selected from the Forensic Osteology Research Center, Faculty of Medicine, Chiang Mai University. This study was approved by the Research Ethics Committee of the Faculty of Medicine at Chiang Mai University (CODE:ANA-2564-08048).

Morphologic Characteristics. The morphological parameters used in this study include the incidence and the morphology of supratrochlear foramen on the humerus. The morphology includes a degree of perforation and shape of the supratrochlear foramen.

Degree of Perforation. Degree of perforation was categorized by the presence of foramen and degree of opacity at the septum between the coronoid fossa and the olecranon

fossa that was noted by placing the humerus against a light. Humeri were then sorted into four subgroups, opaque septum, translucent septum, translucent septum with foramen, and foramen (Fig. 1).

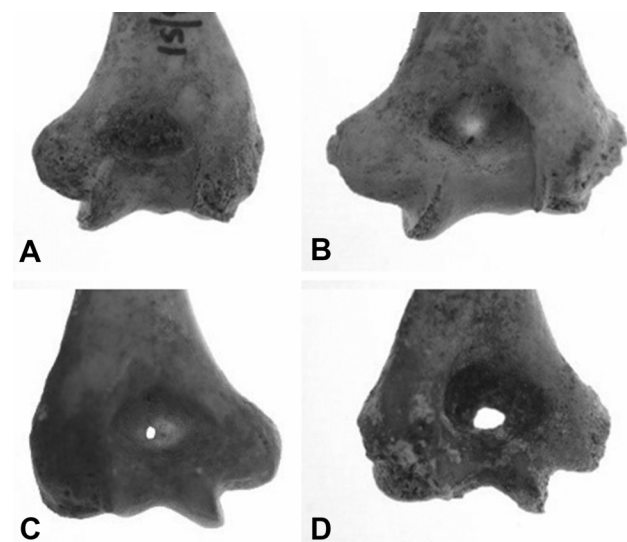


Fig. 1. Degree of perforation of supratrochlear foramen; A: opaque septum, B: translucent septum, C: translucent septum with foramen, D: foramen.

Shape of Supratrochlear Foramen. According to Shivaleela *et al.* (2016) and Mathew *et al.* (2016), supratrochlear foramen shapes can be visualized and classified into seven types, oval, triangular, rectangular, reniform, sieve, and round, as shown in Figure 2, while foramen that do not meet any described morphology were categorized as ‘irregular’.

Morphometric Data. Morphometric data includes the transverse diameter (TD) and the distance from the medial epicondyle to the lateral epicondyle (DMLE) which were measured with digital vernier calipers (Figs. 3 & 4). The ratio between TD and DMLE (TD to DMLE ratio) was calculated to represent the size of the supratrochlear foramen. These parameters were not considered for sieve and irregular shapes.

Statistical Analysis. For statistical analysis, data was divided into morphologic and morphometric data and analyzed using SPSS version 19. Morphological data, which included the degree of perforation and shape of STF (Supratrochlear Foramen), were analyzed to detect the difference between each sex and side using Chi-square test and Wilcoxon signed-rank test, respectively. Morphometric parameters were reported as mean \pm standard deviation. Independent sample t-test and Paired t-test were performed to establish whether there was any difference between each sex and each side, respectively. Value of $p < 0.05$ was considered statistically significant.

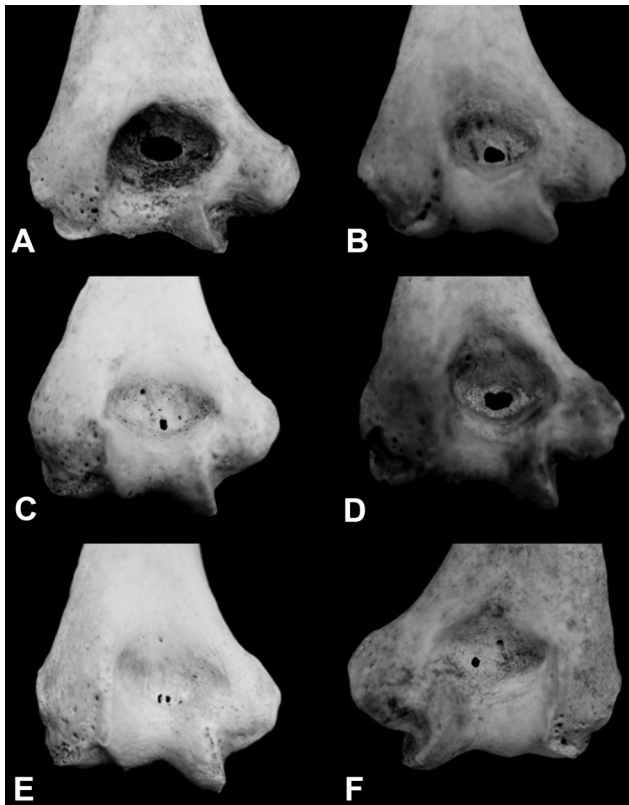


Fig. 2. Types of supratrochlear foramen; A: oval shape, B: triangular shape, C: rectangular shape; D: reniform shape; E: sieve shape; F: round shape

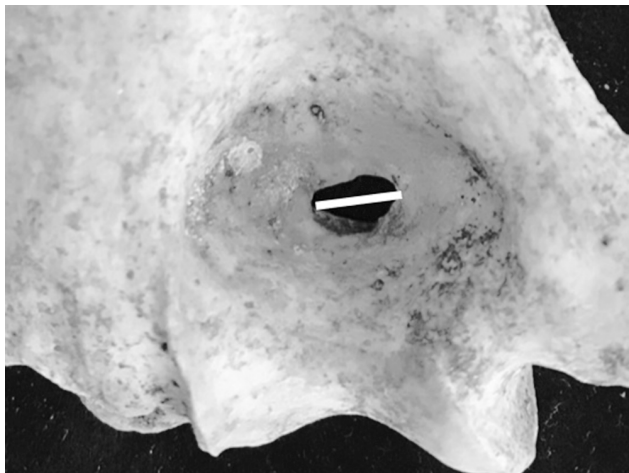


Fig. 3. Photograph showing measurement of maximum transverse diameter (TD).

RESULTS

Morphological Characteristics of STF. Among 320 cases of humeri, 82 cases (25.62 %) of STF were found. 61 cases (19.06 %) were reported as unilateral STF and the remaining 21 cases (6.56 %) were described as bilateral STF. In the 61

cases of unilateral STF, left-sided STF accounted for 14.06 % (45 cases) of the sample group, while right-sided STF was found in 16 cases (5.00 %).

Degree of Perforation of STF. Of the total 640 humeri, the majority was noted as an absence of foramen which can be categorized into humeri with translucent septum 404 cases (63.12 %) and humeri with opaque septum 133 cases (20.78 %). Foramen were observed in 103 humeri (16.10 %), with most identified as translucent septum (10.16 %). The remaining 5.94 % were humeri with foramen without a translucent septum. The difference in the prevalence of the degree of perforation between right and left sides was considered statistically significant (p -value = 0.00), but no statistically significant differences between sexes.

Shape of STF. From the data collected, the oval was the most commonly visualized shape, with the next most common shapes in descending order being irregular, round, reniform, and rectangular. Sieve and triangular shapes were equally the least common.

Morphometric Parameters of STF. In this study, TD was 5.08 ± 2.33 mm on the right side and 4.72 ± 2.27 mm on the left side. DMLE was 56.09 ± 4.10 mm on the right and 56.08 ± 4.08 mm on the left. The ratio between TD and DMLE was 0.09 ± 0.44 mm on the right and 0.08 ± 0.41 mm on the left. Out of these three parameters, only one was considered statistically different in males compared to females, which was the distance between the medial epicondyle and the lateral epicondyle (p -value = 0.000 in the right and 0.000 in the left). However, the difference of the left compared to the right was not significant.

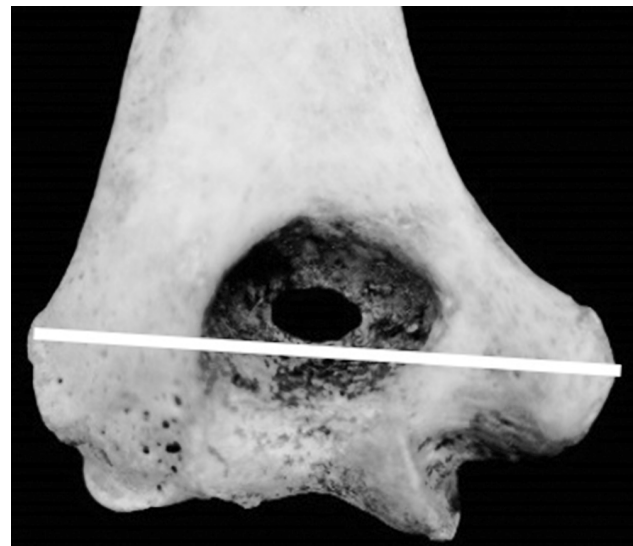


Fig. 4. Photograph showing measurement the distance from the medial epicondyle to the lateral epicondyle (DMLE).

DISCUSSION

According to Table I, previous studies suggest that STF is more commonly found among Native Americans, Africans, and Australians. However, European and

Americans have a lower tendency of STF. The prevalence of STF in Asians was in the same way except for Indians who are considered to have a different anthropological origin. This study was conducted with a Thai population and is consistent with existing studies conducted in Asia.

Table I. Prevalence of STF in each population.

Author	Population	Prevalence (%)
Present study	Thais	16.1
Shivaleela <i>et al.</i> (2016)	South Indians	26.7
Li <i>et al.</i> (2015)	Chinese (Jining)	10.3
Erdogmus <i>et al.</i> (2014)	Turkish	10.8
Nayak <i>et al.</i> (2009)	Indians	34.4
Glanville (1967)	Tellem	47
	Netherlands	6.1
Akabori (1934)	Japanese	18.1
	Korean	11
Hrdli_ka (1932)	Australians	46.5
	Germans	8.8
Hirsh (1927)	White Americans	4.7
	Arkansas-Indians	58

STF usually occurs more frequently in females than males. Both Erdogmus *et al.* (2014) and Paraskevas *et al.* (2010) report STF to be more common in females than males (Table II). In the present study, STF was found in 59 out of 320 female humeri (18 %) and 44 out of 320 male humeri (14 %) (Table II). This may be due to female bone structures. Brauer *et al.* (2007) stated that females have a greater degree of joint hypermobility than males. Furthermore, the inward curvature of the female elbow angle could cause the higher prevalence of STF in females.

Furthermore, STF has a higher frequency in the left hand than the right hand. From Table III, 8 out of 9 studies including the present study report a greater prevalence of STF on the left hand. This could be explained by the basis

Table II. Prevalence of unilateral and bilateral STFs compared between male and female.

Author	Male	Female	Total of Humeri
Present study	44 (14 %)	59 (18 %)	M=320; F = 320
Erdogmus <i>et al.</i> (2014)	6 (7.69 %)	12 (13.64 %)	M = 78; F = 88
Paraskevas <i>et al.</i> (2010)	14 (12.07 %)	24 (19.35 %)	M =116; F = 124

Note: M = Male; F = Female

Table III. Prevalence of STF compared between right side and left side.

Author	Right side	Left side	Total of Humeri
Present study	37 (11.56 %)	66 (20.62 %)	Paired humeri (Rt = 320; Lt = 320)
Shivaleela <i>et al.</i> (2016)	16 (22.22 %)	22 (31.42 %)	Unpaired humeri (Rt = 72; Lt = 70)
Chagas <i>et al.</i> (2016)	28 (19.31 %)	46 (24.86 %)	Unpaired humeri (Rt = 145; Lt = 185)
Mathew <i>et al.</i> (2016)	19 (16.67 %)	41 (31.53 %)	Unpaired humeri (Rt = 114; Lt = 130)
Li <i>et al.</i> (2015)	9 (6.56 %)	18 (14.4 %)	Unpaired humeri (Rt = 137; Lt = 125)
Erdogmus <i>et al.</i> (2014)	4 (4.82 %)	14 (16.87 %)	Paired humeri (Rt = 83; Lt = 83)
Paraskevas <i>et al.</i> (2010)	12 (10.00 %)	26 (21.67 %)	Paired humeri (Rt = 120; Lt =120)
Nayak <i>et al.</i> (2009)	73 (44.51 %)	59 (26.81 %)	Unpaired humeri (Rt = 164; Lt = 220)
Singhal & Rao (2007)	20 (25.64 %)	22 (30.56 %)	Unpaired humeri (Rt = 78; Lt = 72)

Note: Rt = Right; Lt = Left

of handedness. STF rarely occurs on the dominant right hand because it has more robust bones. Moreover, the range of joint motion and joint hypermobility which is greater on the left upper limb is also related to a higher prevalence of STF. However, Nayak *et al.* (2009) stated that there is more common on the right side than the left side.

In the present study, the majority of STF shapes were oval (43.70 %). Irregular (18.45 %) and round (16.50) were second and third most common shapes. A minority of STF were sieve and triangular shaped. According to Table IV, the most common shape found in every study were oval and round shapes, while a rectangular shape is the least common.

From previous studies, the size of the foramen was commonly measured by the vertical and transverse diameter, but this could be a cause of confounding bias according to the varied sizes of the humeri. The larger humeri tend to have a bigger STF. For this reason, the ratio between TD and DMLE was selected as a representative of size. From our study, the only parameter found to be distinct between sex is DMLE which can be explained by dissimilarity between sexes. However, statistical differences were not assumed in the ratio between TD and DMLE. This result is congruent with Li *et al.* (2015).

In conclusion, supratrochlear foramen is familiar to anatomists but not yet familiar to clinicians, as evidenced by it being mentioned little in clinical practice guidelines. Its existence is important for clinicians such as orthopedic surgeons and radiologists in many aspects. For instance, greater knowledge of supratrochlear foramen would reduce misdiagnosis of cystic lesion around the distal humerus by radiologists. Moreover, it could also aid orthopedic

surgeons when planning nailing fracture around the distal of the humerus.

BOONCHAN, S.; BOONRUGSA, K.; CHARUMPORN, T.; NAVIC, P.; SINGSUWAN, P. & MAHAKKANUKRAUH, P. Estudio morfométrico del foramen supratroclear del húmero relacionado con implicaciones clínicas en una población tailandesa. *Int. J. Morphol.*, 40(4):1048-1053, 2022.

RESUMEN: El foramen supratroclear (FST) es una perforación de la pared ósea que separa la fosa olecraneana y la fosa coronoides. Su incidencia varía entre las diferentes razas. El objetivo de este estudio fue investigar la prevalencia y la morfometría del foramen supratroclear entre la población tailandesa. Se recolectaron un total de 640 húmeros secos de 320 esqueletos, 160 húmeros emparejados de cada sexo y edad conocida para estudiar la prevalencia de FST. Se reportó la prevalencia categorizada por sexo y lado del húmero para identificar si existe correlación. FST se clasificó por forma y sus métricas se midieron con calibradores vernier digitales. Se calculó la relación del diámetro transversal (DT) y la distancia desde el epicóndilo medial al epicóndilo lateral (DEML) para representar el tamaño de STF. De 640 húmeros, 404 casos presentaban tabique translúcido, 133 casos tabique opaco y 103 casos se registraron como foramen. En este estudio, la mayoría de los forámenes supratroclears tenían forma ovalada, seguidos de los forámenes de forma irregular y redonda. La relación entre DT y DEML fue de $0,09 \pm 0,44$ mm en el lado derecho y de $0,08 \pm 0,41$ mm en el lado izquierdo, no existiendo diferencias estadísticamente significativas. Los resultados pueden ser útil para comprender la variación y la ubicación del foramen supratroclear y ayudar a los radiólogos y cirujanos ortopédicos a evitar un diagnóstico erróneo de lesión quística en el húmero distal.

PALABRAS CLAVE: Húmero; Foramen supratroclear; Abertura septal.

Table IV. Prevalence of STFs categorized by shape of STFs.

A author	Oval	Round	Reniform	Sieve	Triangular	Rectangular	Irregular	Number of Foramen
Present study	45 (43.70 %)	17 (16.50 %)	9 (8.74 %)	4 (3.88 %)	4 (3.88 %)	5 (4.85 %)	19 (18.45 %)	103 from 640
Satish & Suresh (2019)	7 (47 %)	5 (33 %)	-	0 (0 %)	3 (20 %)	-	-	15 from 78
De shmukh <i>et al.</i> (2018)	9 (45 %)	10 (50 %)	-	-	-	-	1 (5 %)	20 from 122
Shivaleela <i>et al.</i> (2016)	16 (42 %)	18 (47 %)	-	-	-	-	4 (11 %)	38 from 142
Matthew <i>et al.</i> (2016)	31 (52 %)	13 (21 %)	7 (12 %)	5 (8 %)	3 (5 %)	1 (2 %)	-	60 from 244
Savitha and Dakshayani (2016)	4 (29 %)	5 (36 %)	2 (14 %)	3 (21 %)	-	-	-	14 from 50
Li <i>et al.</i> (2015)	19 (70 %)	4 (15 %)	-	-	2 (7 %)	2 (7 %)	-	27 from 262
Arunkumar <i>et al.</i> (2015)	71 (93 %)	2 (2 %)	-	-	3 (4 %)	-	-	76 from 355
Erdogmus <i>et al.</i> (2014)	13 (72 %)	2 (11 %)	-	1 (6 %)	2 (11 %)	-	-	18 from 166
Diwan <i>et al.</i> (2013)	353 (83 %)	65 (15 %)	-	-	10 (2 %)	-	-	428 from 1776
Nayak <i>et al.</i> (2009)	123 (93 %)	7 (5 %)	-	-	2 (2 %)	-	-	132 from 384

REFERENCES

- Akabori, E. Septal apertures in the humerus in Japanese, Ainu and Koreans. *Am. J. Phys. Anthropol.*, 18(3):395-400, 1934.
- Arunkumar, K. R.; Manoranjitham, R.; Raviraj, K. & Dhanalakshmi, V. Morphological study of supratrochlear foramen of humerus and its clinical implications. *Int. J. Anat. Res.*, 3(3):1321-5, 2015.
- Brauer, C. A.; Lee, B. M.; Bae, D. S.; Waters, P. M. & Kocher, M. S. A systematic review of medial and lateral entry pinning versus lateral entry pinning for supracondylar fractures of the humerus. *J. Pediatr. Orthop.*, 27(2):181-6, 2007.
- Chagas, C. A. A.; Gutfiten-Schlesinger, G.; Leite, T. F.; Pires, L. A. & Silva, J. G. Anatomical and radiological aspects of the supratrochlear foramen in Brazilians. *J. Clin. Diagn. Res.*, 10(9):AC10-3, 2016.
- Chapman, D. L.; Garvey, N.; Hancock, S.; Alexiou, M.; Agulnik, S. I.; Gibson-Brown, J. J.; Cebra-Thomas, J.; Bollag, R. J.; Silver, L. M. & Papaioannou, V. E. Expression of the T-box family genes, Tbx1-Tbx5, during early mouse development. *Dev. Dyn.*, 206(4):379-90, 1996.
- Deshmukh, V. R.; Arathala, R. & Seth, S. The supratrochlear foramen of the humerus: formation and clinical implications. *Int. J. Sci. Res.*, 7(2):763-5, 2018.
- Diwan, R. K.; Rani, A.; Rani, A.; Chopra, J.; Srivastava, A. K.; Sharma, P. K.; Verma, R. K. & Pankaj, A. K. Incidence of supratrochlear foramen of humerus in North Indian Population. *Biomed. Res.*, 24(1):142-5, 2013.
- Erdogmus, S.; Guler, M.; Eroglu, S. & Duran, N. The importance of the supratrochlear foramen of the humerus in humans: An anatomical study. *Med. Sci. Monit.*, 20:2643-50, 2014.
- Glanville, E. V. Perforation of the coronoid-olecranon septum. Humero-ulnar relationships in Netherlands and African populations. *Am. J. Phys. Anthropol.*, 26(1):85-92, 1967.
- Hirsh, I. S. The supratrochlear foramen: clinical and anthropological considerations. *Am. J. Surg.*, 2(5):500-5, 1927.
- Hrdlic'ka, A. The humerus: septal apertures. *Anthropologie* (1923-1941), 10(1/4):31-96, 1932.
- Li, J.; Mao, Q.; Li, W. & Li, X. An anatomical study of the supratrochlear foramen of the Jining population. *Turk. J. Med. Sci.*, 45(6):1369-73, 2015.
- Mathew, A. J.; Gopidas, G. S. & Sukumaran, T. T. A study of the supratrochlear foramen of the humerus: Anatomical and clinical perspective. *J. Clin. Diagn. Res.*, 10(2):AC05-08, 2016.
- Nayak, S. R.; Das, S.; Krishnamurthy, A.; Prabhu, L. V. & Potu, B. K. Supratrochlear foramen of the humerus: an anatomico-radiological study with clinical implications. *Ups. J. Med. Sci.*, 114(2):90-4, 2009.
- Ndou, R. The significance of the supratrochlear aperture (STA) in elbow range of motion: an anatomical study. *Anat. Sci. Int.*, 93(1):88-97, 2018.
- Paraskevas, G. K.; Papaziogas, B.; Tzaveas, A.; Giaglis, G.; Kitsoulis, P. & Natsi, K. The supratrochlear foramen of the humerus and its relation to the medullary canal: a potential surgical application. *Med. Sci. Monit.*, 16(4):BR119-23, 2010.
- Pires, L. A. S.; Leite, T. F. O.; Fonseca Junior, A.; Babinski, M. A. & Chagas, C. A. A. The olecranon aperture of the humerus: a meta-analysis with anthropological and clinical discussion. *Homo*, 70(1):75-84, 2019.
- Satish, K. S. & Suresh, K. T. Supratrochlear foramen-anatomical variations and its clinical implications. *Int. J. Anat. Res.*, 7(3):6807-10, 2019.
- Savitha, V. & Dakshayani, K. R. Study of the supratrochlear foramen of the humerus. *Int. J. Anat. Res.*, 4(4):2979-83, 2016.
- Shivaleela, C.; Afroze, K. H. & Lakshmi Prabha, S. An osteological study of supratrochlear foramen of humerus of South Indian population with reference to anatomical and clinical implications. *Anat. Cell Biol.*, 49(4):249-53, 2016.
- Singhal, S. & Rao, V. Supratrochlear foramen of the humerus. *Anat. Sci. Int.*, 82(2):105-7, 2007.

Corresponding author:

Prof. Pasuk Mahakkanukrauh, MD

Excellence in Osteology Research and Training Center (ORTC)

Chiang Mai University

Chiang Mai, 50200

THAILAND

E-mail: pasuk034@gmail.com