

Case Report

Cholestatic Jaundice as a Paraneoplastic Manifestation of Prostate Cancer

Tomomi Kuramoto,¹ Hiroya Senzaki,¹ Hiroyuki Koike,¹ Kenji Yamagiwa,¹
Shinobu Tamura,² Tokuzou Fujimoto,³ and Takeshi Inagaki¹

¹ Department of Urology, Social Insurance Kinan Hospital, 46-70 Shinjou-chou, Tanabe-shi, Wakayama 646-8588, Japan

² Department of Hematology/Oncology, Social Insurance Kinan Hospital, 46-70 Shinjou-chou, Tanabe-shi, Wakayama 646-8588, Japan

³ Department of Internal Medicine, Social Insurance Kinan Hospital, 46-70 Shinjou-chou, Tanabe-shi, Wakayama 646-8588, Japan

Correspondence should be addressed to Tomomi Kuramoto; tkuramoto@kinan-hp.tanabe.wakayama.jp

Received 15 July 2013; Accepted 11 September 2013

Academic Editors: S.-S. Chen, G. L. Gravina, A. Greenstein, C. Liao, and F. Ramezanzadeh

Copyright © 2013 Tomomi Kuramoto et al. This is an open access article distributed under the Creative Commons Attribution License, which permits unrestricted use, distribution, and reproduction in any medium, provided the original work is properly cited.

Paraneoplastic syndrome associated with prostate cancer is extremely rare. We report a patient who presented with cholestatic jaundice without biliary duct obstruction, hepatic involvement, or infection. After a few detailed examinations, prostate cancer was diagnosed. After treatment with bicalutamide and leuprolide, the patient's symptoms and laboratory abnormalities were reversed. Cholestatic jaundice was regarded as a paraneoplastic manifestation in this patient. The patient remains symptom-free after 14-month followup. Paraneoplastic syndrome should be considered in case of cholestatic jaundice without biliary duct obstruction, hepatic involvement, or infection.

1. Introduction

Cholestatic jaundice as the initial symptom in patients with metastatic prostate cancer is extremely rare. Hepatic metastasis or biliary duct obstruction are cited as the causes of cholestatic jaundice in the literature [1, 2].

More rarely, patients with advanced prostate cancer present with cholestatic jaundice without any evidence of biliary duct obstruction or hepatic infiltration. Cholestatic jaundice is attributed to the remote effects of the tumor, known as paraneoplastic syndrome, particularly in patients with non-metastatic renal cell carcinoma (Stauffer's syndrome) [3].

However, prostate cancer presenting as cholestatic jaundice is extremely rare, and to our knowledge, only 4 cases of paraneoplastic cholestatic jaundice associated with prostate cancer have been reported in the literature [4–7].

We present a case of paraneoplastic cholestasis in prostate cancer and discuss the mechanism underlying the pathogenesis of this syndrome.

2. Case Report

A 75-year-old man was transported to our hospital by ambulance because of shock due to melena. Gastrointestinal

endoscopy revealed a hemorrhagic gastric ulcer, for which endoscopic hemostasis was performed; clinical examination revealed jaundice. Head and neck examinations revealed several small, soft, painless, and movable left cervical lymph nodes.

The liver and spleen were not palpable; however, a fist-sized mass was palpable around the umbilicus. Digital rectal examination revealed a walnut-sized prostate gland, and a stony hard mass was palpable behind the prostate.

Laboratory analysis revealed the following: hemoglobin, 8.7 g/dL; white blood cell count 4700/ μ L; thrombocyte count 16.9×10^4 / μ L; serum aspartate aminotransferase (AST) 45 U/L (normal range, 11–35 U/L); serum alanine aminotransferase (ALT) 42 U/L (normal range, 5–35 U/L); total bilirubin (t-bil) 17 mg/dL (normal range, 0.2–1.0 mg/dL); direct bilirubin (d-bil) 8.7 mg/dL (normal range, 0–0.4 mg/dL); and alkaline phosphatase (ALP) 44 U/L (normal range, 100–34 U/L). Urine analysis was positive for bilirubin but otherwise normal. Prostate-specific antigen (PSA) was 9862 ng/mL (normal range, 0–4 mg/mL). Abdominal computed tomography revealed para-aortic and pelvic lymph node enlargement but no abnormal findings in the liver, pancreas, spleen, or kidney (Figure 1). Magnetic resonance

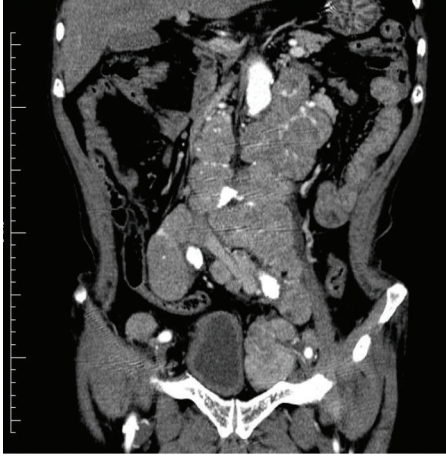

FIGURE 1: Abdominal computed tomography showing para-aortic and pelvic lymph node enlargement.

imaging revealed numerous enlarged lymph nodes in the pelvis. Bone scintigraphy revealed hot lesions on several ribs and the second lumbar vertebra. Prostate biopsy revealed adenocarcinoma (poorly differentiated, Gleason score 5 + 4). Antiandrogen treatment with bicalutamide (80 mg orally) was started, and after 14 days leuprolide was added (3.75 mg subcutaneously once a month) to the regimen. Twenty-eight days after the first subcutaneous injection of leuprolide, there was approximately 50% in the t-bil levels (from 17 to 10.5 mg/dL). After further 2.5 months, these levels returned to normal (Figure 3) following which AST, ALT, and ALP levels returned to normal 2 months later.

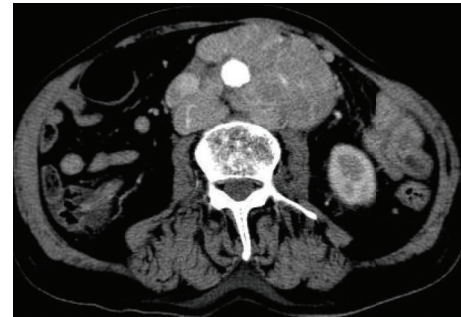
Hormonal therapy contributed to decrease in the size (by >40%) of para-aortic and pelvic lymph nodes (Figure 2). The patient achieved partial remission according to response evaluation criteria in solid tumors (RECIST) after a further 6 months.

Furthermore, 1 year after initiation of hormonal therapy, PSA levels decreased from 9862 to 13 ng/mL (Figure 3); the patient is presently in remission and continues to receive leuprolide (3.75 mg) subcutaneously once a month and bicalutamide (80 mg) orally daily.

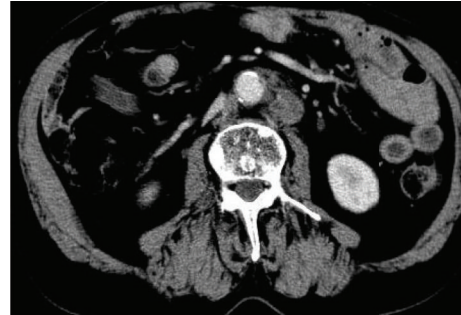
3. Discussion

Paraneoplastic syndrome is defined as a group of symptoms that may develop when substances released by certain cancer cells disrupt the normal functions of surrounding cells and tissues. Prostate cancer is the second most common urological malignancy associated with paraneoplastic syndrome after renal cell carcinoma [8].

Hong et al. reported many types of paraneoplastic phenomena associated with prostate cancer. They classified paraneoplastic syndrome into endocrine, hematological, dermatological, neurological, inflammatory, and other types according to clinical symptoms [9]. Among these, paraneoplastic cholestasis was uncommon, and the pathogenesis of paraneoplastic syndrome remains unknown. Blay et al. reported that interleukin-6 (IL-6) is involved in the physiopathology of paraneoplastic cholestasis in renal cell carcinoma (Stauffer's syndrome) [10].



(a)



(b)

FIGURE 2: Abdomen computed tomography scans during treatment. (a) Prior to hormonal therapy, showing para-aortic and pelvic lymph node enlargement. (b) Six months after initiation of hormonal therapy, lymph node size decreased to more than 40%.

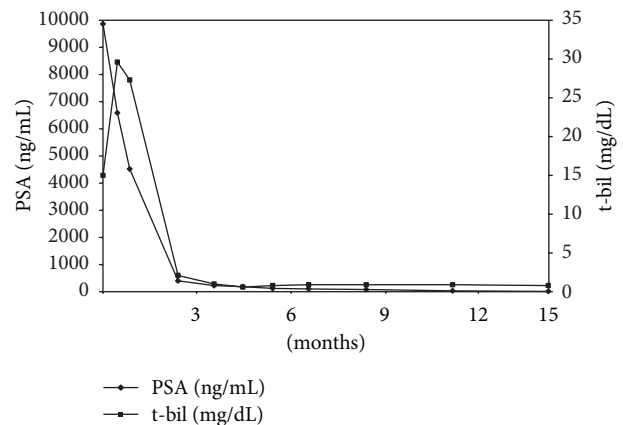


FIGURE 3: The patient's clinical course.

In our case, serum IL-6 levels decreased from 8.4 pg/mL (normal range, <4 pg/mL) before treatment to 2.8 pg/mL 4 months after treatment.

The literature includes 4 case reports cholestasis as a paraneoplastic manifestation associated with prostate cancer without metastatic hepatic infiltration, biliary duct obstruction, or evidence of an infectious etiology [4–7].

In our case, the patient had bone metastasis and enlarged lymph nodes at the time of diagnosis, and no biliary duct obstruction was observed because of lymph node involvement. The patient remains symptom-free and without biochemical relapse 1 year after initiation of antiandrogen treatment.

Because the jaundice evident at the start of treatment disappeared after effective hormonal treatment, we consider that this symptom was a paraneoplastic manifestation of the underlying prostate cancer.

In conclusion, paraneoplastic cholestasis should be considered in the absence of metastatic infiltration of the liver, metastatic extrahepatic biliary duct obstruction, or an infectious etiology in prostate cancer.

Conflict of Interest

The authors declare that they have no conflict of interests.

References

- [1] W. E. Bloch and N. L. Block, "Metastatic prostate cancer presenting as obstructive jaundice," *Urology*, vol. 40, no. 5, pp. 456–457, 1992.
- [2] A. Cole, D. Mendelblatt, J. Aguayo, A. Mathew, E. Martin, and D. L. Vesely, "Metastatic prostate cancer (with prostate-specific antigen of 9996) presenting as obstructive jaundice," *The American Journal of the Medical Sciences*, vol. 319, no. 2, pp. 118–122, 2000.
- [3] A. Tomadoni, C. Garcia, M. Márquez, J. C. Ayala, and F. Prado, "Stauffer's syndrome with jaundice, a paraneoplastic manifestation of renal cell carcinoma: a case report," *Archivos Espanoles de Urologia*, vol. 63, no. 2, pp. 154–156, 2010.
- [4] J. Moris de la Tassa, I. Claros Gonzalez, M. L. Garcia-Alcalde Fernandez, A. Antuna Egocheaga, and M. Arguelles Torano, "Cholestasis and prostatic carcinoma. Description of a case and review of paraneoplastic cholestasis," *Medical Clinica*, vol. 96, no. 1, pp. 22–25, 1991.
- [5] A. N. Reddy, S. J. Grosberg, and S. Wapnick, "Intermittent cholestatic jaundice and nonmetastatic prostatic carcinoma," *Archives of Internal Medicine*, vol. 137, no. 11, pp. 1616–1618, 1977.
- [6] A. Karakolios, C. Kasapis, T. Kallinikidis, P. Kalpidis, and N. Grigoriadis, "Cholestatic jaundice as a paraneoplastic manifestation of prostate adenocarcinoma," *Clinical Gastroenterology and Hepatology*, vol. 1, no. 6, pp. 480–483, 2003.
- [7] M. Koruk, M. Büyükberber, C. Savaş, and A. Kadayifçi, "Paraneoplastic cholestasis associated with prostate carcinoma," *The Turkish Journal of Gastroenterology*, vol. 15, no. 1, pp. 53–55, 2004.
- [8] E. Sacco, F. Pinto, F. Sasso et al., "Paraneoplastic syndromes in patients with urological malignancies," *Urologia Internationalis*, vol. 83, no. 1, pp. 1–11, 2009.
- [9] M. K. Hong, J. Kong, B. Namdarian et al., "Paraneoplastic syndromes in prostate cancer," *Nature Reviews Urology*, vol. 7, no. 12, pp. 681–692, 2010.
- [10] J. Y. Blay, J. F. Rossi, J. Wijdenes et al., "Role of interleukin-6 in the paraneoplastic inflammatory syndrome associated with renal-cell carcinoma," *International Journal of Cancer*, vol. 72, no. 3, pp. 424–430, 1997.