



Intermittent Hydrarthrosis, Rare, Unknown, Underdiagnosed and Forgotten: First report in Gambia

Asmell Ramos Cabrera¹, Mayelin Martinez², Rainier Paulino², Yamilet Hinojosa³, Kehinde O Oduntan⁴, Onyia Onyema⁵, Jennifer Shallop⁵

¹HOD Medicine AIUWA, Senior Internal Medicine Consultant EFSTH, Medicare Ltd., Gambia

²Consultant Physician, Medicare Ltd., Gambia

³Consultant Gynecologist, Medicare Ltd., Gambia

⁴General Surgeon, Medicare Ltd., Gambia

⁵General Physician, Medicare Ltd., Gambia

Correspondence

Asmell Ramos Cabrera

HOD Medicine AIUWA, Senior Internal Medicine Consultant EFSTH, Medicare Ltd., Gambia

E-mail: asmellramos@gmail.com

- Received Date: 26 Oct 2023
- Accepted Date: 02 Nov 2023
- Publication Date: 06 Nov 2023

Keywords

Intermittent hydrarthrosis, Asmell Ramos, Gambia, Rare diseases.

Copyright

© 2023 Authors. This is an open-access article distributed under the terms of the Creative Commons Attribution 4.0 International license.

Abstract

The first report of intermittent hydrarthrosis (IH) was made by Perrin in 1845; However, despite the simplicity of the symptoms and signs that characterize it, it is considered a rare disease, presumably its pathophysiology is autoinflammatory and of uncertain etiology. According to the number of reports published to date, the description of new cases remains extremely low. The chronicity and periodicity of the attacks of joint swelling, the tropism for the affected joint, almost always the knee, as well as the complete recovery without sequela after each attack, constitutes its characteristic hallmark. The simplicity of the clinical picture is at the same time the greatest obstacle to establishing the definitive diagnosis. Considering that there are no diagnostic criteria, it is necessary to exclude all conditions with a similar pattern, making the list large and complex. During the review of the literature, no references of publications of black patients were found, nor reports on the African continent. We decided to present the first case of intermittent hydrarthrosis in The Gambia and to date in the entire subregion.

Introduction

A 43-year-old patient previously healthy, five years ago, presented an episode of mild pain and swelling in the right knee (Figure 1). No history of trauma, injury, strenuous exercise, or recent infection. Laboratory studies were completely normal, as was the joint x-ray. However, despite the NSAIDs, therapy was not success as expected, over the course of a week gradually returned to normal, without anatomical or functional sequela.

Six months later, he was again affected by another episode, with the same clinical, humoral, and radiological pattern, as the previous one. The only difference, on that occasion, was the involvement of the left

ankle for the first and only time (Figure 2). Nevertheless, the right knee remained the affected joint for the remainder of the last five years.

The treatment in all episodes remains similar, as well as the response to it. Characterized by continued progressive improvement until returning to normal, and without functional or anatomical repercussions. This condition was perpetuated over five years, with identical regularity over every six months. The swelling, and inflammation in the right knee returned, making attacks habitual, a study of the synovial fluid was carried out, which showed and unspecific inflammatory process, but was not conclusive. Frustrated by the chronicity, recurrence, and regularity of the disease, he

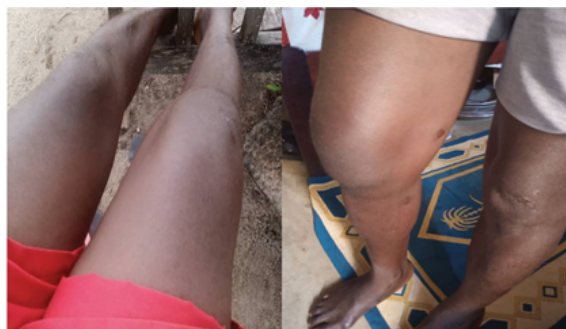

Figure 1. Swelling in the right knee.

Citation: Cabrera AR, Martinez M, Paulino R, et al. Intermittent Hydrarthrosis, Rare, Unknown, Underdiagnosed and Forgotten: First report in Gambia. *Med Clin Sci.* 2023;5(7):1-4

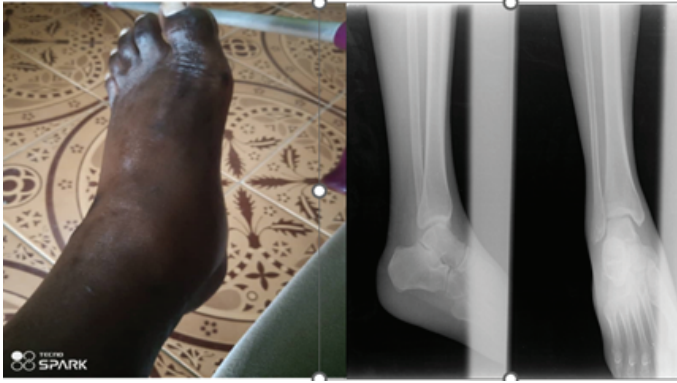

Figure 2. Swelling in the left ankle.

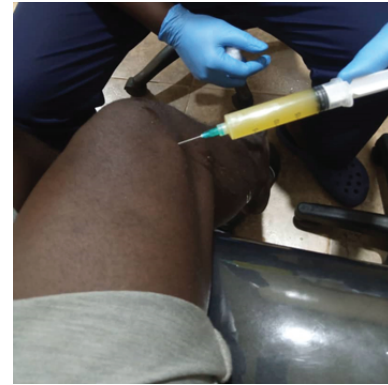

Figure 3. Macroscopy aspect synovial fluid

visited the internal medicine out clinic. During the interview, the patient denied any relevant medical history, apart from episodes of right knee swelling. There are no records of fever, diarrhea, constipation, skin changes or hair loss, nor are there reports of urethral discharge, lower back pain or pain in another joint, except for one episode of inflammation of the right ankle. In the general physical examination, he appears well, does not present any discomfort, walks with difficulty, and has functional limitations in the right knee due to increased joint volume. Despite the chronicity of the problem, he appears to be in good general health.

Examination of the right knee

It is observed to be enlarged and painful upon movement. No local temperature changes are seen, the patella fluctuates, with obvious signs of joint effusion. No peripheral or axial joints involved.

Vital signs

HR: 90 beats/min; BP 106/77mmhg; RR 22 cycles/min; O2 sat: 96%; Temp: 36.80 C.

Comment

Upon examination of the musculoskeletal system, no joint pain, stiffness, or deformity was evident. The rest of the physical examination was negative.

Investigations

FBC: Hb:13.5 g/l; WCC: 9.5x10 ⁹ ; Plt: 250.000 mcL	HbsAg: Negative
ESR: 80 mm/1hr; Rf: Male:<10 mm/1h	AcHb: Negative
CRP: 15 mg/L	HepC: Negative
BF (NEGATIVE)	VDRL/RPR: NEGATIVE
RHEUMATOID FACTOR: <8.00 IU/ml; Rf:<15.00	HIV: Negative
Anti-CCP: 3.5 U/ml	Liver enzymes: Normal
ANTI-NUCLEAR ANTIBODIES: 0.2; Rf: <0.9 Negative	Kidney function: Normal
Lipid profile: Normal	Lipid profile: Normal
Total proteins: 7g/dl; Rf: 5.5 to 9.0 g/dL	Total proteins: 7g/dl; Rf: 5.5 to 9.0 g/dL
Albumin: 4.5 g/dl; Rf: 3.5 to 5.5 g/dL	Albumin: 4.5 g/dl; Rf: 3.5 to 5.5 g/dL
Globulins: 2.5 g/dl; Rf:2.0 to 3.5 g/dL	ASO: Negative
Nasopharyngeal swab: Negative	

Synovial fluid study

- **Macroscopy:** 10 milliliters of synovial fluid of swallow yellow color and cloudy appearance (Figure 3)
- **Microscopy:** Densely cellular smears consisting of mix inflammatory cells and background debris.

Discussion

Intermittent hydrarthrosis is a rare rheumatologic disease, reported by Perrin in 1845 [1]. Characterized by recurrent self-remitting episodes of acute monoarticular arthritis, often with a fixed periodicity, typically affecting the knee or another large joint, typically develops an effusion over 72 hours, with only mild to moderate pain, and minimal signs of inflammation. It is also known as periodic synovitis, periodic benign synovitis, or periodic hydrarthrosis [2-4]. Initially, it was described in women and was associated with menstrual periods and allergic episodes of urticaria, allergic dermatitis, or angioedema; later it was found that men could also be involved, the pattern of joint involvement is similar in both sexes, although some publications suggest the condition is slightly more prevalent in females [5]. The incidence and prevalence of this condition is not known. A review in MalaCards, found in PubMed, only 146 Text-mined articles related to IH from 1930 to 2020 [6]. In subsequent years, reports have remained scarce (Figure 4), until the time of the review, no reports have been found in the black population, this is a question for which we have no explanation.

Although the knee is mainly impacted, sometimes other joints, mainly larger, can be attacked, such as the elbow or ankle. Fluid buildup in the joint can be extensive, causing discomfort and impairment of the movement. [7-10].

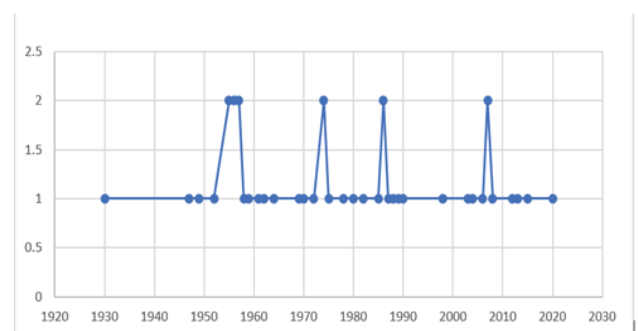


Figure 4. Number of publications of IH per decade

Table 1. Diseases associated with intermittent arthritis.

Diseases associated with intermittent arthritis.
<ul style="list-style-type: none"> • Microcrystal arthropathy (gout, calcium pyrophosphate, hydroxyapatite) • Reactive arthritis • Arthritis associated with inflammatory bowel disease (Crohn's disease and ulcerative colitis) • Palindromic rheumatism • Behcet's disease • Sarcoidosis • Recurrent polyarthritides • Whipple's disease • Familial Mediterranean fever • TRAPS • Hyper-IgD syndrome

The x-ray of the joint show's extension of the joint space and increased "blurred" shadows of the periarticular tissues. It is common to find a slight increase in inflammatory response markers. Biochemical blood test, as a rule, does not reveal any pathological changes. During the examination of the synovial fluid by joint puncture, a cytosis study was observed, with polynuclear cells increased by 50% or more. The clinical approach to the patient with IH requires establishing the differential diagnosis with diseases that cause intermittent arthritis (Table 1) Normally an acute episode of IH resolves independently, without leaving subsequent changes. There is no defined period between recurrence episodes, it is strictly individual, and each patient has their pattern, rhythm, and cycle. [11].

Crystal deposits (monosodium urate, calcium pyrophosphate or hydroxyapatite) usually present monoarticular and recurrent symptoms that affect small and large joints. However, they show a hyperacute inflammatory pattern, with local changes in color and temperature, being considerably painful. In chronic cases, the existence of extra-articular crystal deposits can be established [12]. Precipitating factors such as alcohol intake, red meat, or poor compliance, in addition to abandonment of treatment, are most likely associated with treatment with diuretics. In our case, none of the clinical, radiological and laboratory elements that define arthropathies due to crystal deposits are present.

Regarding arthropathies related to bowel inflammatory diseases, our patient had not suffered diarrhea, abdominal pain, or disorder in bowel habits [13,14]. There is also no evidence of extraintestinal manifestations such as erythema nodosum, pyoderma gangrenosum, uveitis or cholangitis. In some cases, arthritis precedes the appearance of intestinal symptoms, the diagnosis was considered unlikely, considering that he had been suffering from the disease for five years.

Reactive arthritis, usually affecting medium and large peripheral and axial joints. Typically, it is associated with previous gastrointestinal or urogenital infection, with asepsis of the synovial fluid. The most common manifestations are urethritis, conjunctivitis, and skin lesions. It is frequently oligoarticular, asymmetric, and asynchronous, predominantly in the lower limbs, and extends for several weeks to months. Familial cases associated with the presence of HLA B27 are reported [15].

The normal lipid profile, without xanthomas, nodules or

tophi, and the absence of Achilles tendon tenosynovitis, excludes the presence of type II hyperlipoproteinemia [16]. No oral or genital ulcers have been observed, fever has never been reported, nor has uveitis, serositis, or evidence of vasculitis been demonstrated. The completely normal pattern of humoral studies and the absence of family history allow us to consider the existence of TRAPS, Hyper-IgD syndrome, Behçet's disease and FMF as highly unlikely [11,17].

Palindromic rheumatism (PR) is considered a clinical variety of RA, with recurrent flares of arthritis, of short duration of 24 to 72 hours and spontaneous relief without sequela. It can be mono- or oligoarticular, causing pain, swelling and great joint limitation, sometimes making it difficult to establish the differential diagnosis with IH. However, there are peculiarities in PR, which are not present in IH, such as periarticular erythema, the nodules resemble those of rheumatoid arthritis, but unlike rheumatoid arthritis, they disappear after the flare. Synovial fluid has an inflammatory aspect with elevated inflammatory response. 30% of patients will develop RA or systemic lupus erythematosus within 6 years [18]. In our patient, rheumatoid factor, Anti-CCP and ANA were all negative. In addition, the distribution, onset, typicality of the crisis and absence of nodules with periarticular erythema, the lack of rhythmicity that characterizes IH excludes PR as a possible diagnosis.

Mayo Clinic in 1956, reported a series of forty-seven cases of IH, by Dr. Weiner, he established criteria for their selection [4]

1. **recurrence of joint symptoms at regular intervals**
2. **complete absence of signs and symptoms between attacks**
3. **absence of a specific local causal factor**
4. **absence of systemic reaction.**

In our case, after establishing the differential diagnosis, and being familiar with the peculiar pattern of joint involvement described above, for Weiner characterized by:

1. **Chronicity:** The patient has been ill for the last five years.
2. **Regularity and rhythmicity:** There have been outbreaks every six months.
3. **Involvement of large peripheral joints:** the knee joint has been affected throughout this time, except for one occasion that involved the ankle, although it is described in the literature that it can happen [15]
4. **Predilection for a joint:** It is a typical element of IH, the same joint has always been, is and will be affected.
5. **Non-deforming arthritis:** Unlike other joint effusions, and other types of arthritis, IH never leaves sequela, guaranteeing joint functionality.
6. **Absence of systemic manifestations:** In the case in question, during the 5-year period, there have been no extra-articular or systemic manifestations.
7. **Absence of symptoms in the periods between crises:** Throughout the process, the patient has remained asymptomatic between crises.
8. **Exclusion of other entities with a pattern of recurrent joint effusion:** This criterion, per se, constitutes a diagnosis challenge, however, if the characteristic clinical elements of the disease mentioned above are considered, together with the absence of radiological and humoral manifestations, it is much easier to achieve the diagnostic. IH is part of the clinical spectrum of autoinflammatory

diseases; genetic studies have found mutations for the MEFV gene; however, is not considered a sine qua non requirement to establish the diagnosis, and there may be clinical symptoms in both homozygous and heterozygous carriers [19,20].

Treatment

The treatment of patients with IH has a particularity, and that is that it does not respond to the usual therapy with steroids, or the response is not as expected [21]. However, the benignity of the process and the absence of intra- or extra-articular complications guarantee its favourable evolution despite the poor response to anti-inflammatories. In our case, initially before establishing the diagnosis, treatment was started with low doses of steroids (20 mg/day) and ibuprofen (600 mg tds), later when the diagnosis was established the steroid was suspended and colchicine (1 mg/day) was added. Following the recommendations of the reviewed literature [22], in addition to topical diclofenac. After approximately 3 days of treatment, clinical improvement was seen after 6 days of medication.

Conclusions

Despite the apparent simplicity of the clinical manifestations of the disease. IH is considered a rare entity, belonging to the heterogeneous group of autoinflammatory diseases, with only 568 cases having been described in the literature since the first report in 1845 to the present, resulting in an average of approximately 3 cases per year. IH lacks diagnostic criteria, so establishing the presence of the entity requires a tedious differential diagnosis exercise. It is advisable, in the diagnostic approach, to consider the exclusion of mono- or oligoarticular arthropathies that affect large joints and are recurrent over time. The absence of functional or anatomical sequelae, as well as systemic manifestations, are highly suggestive of IH; its rhythmicity, chronicity and tropism are peculiar, being essential to establish the diagnosis. The disease, despite its infrequent reporting, may not be so rare if the doctor is able to quickly recognize its characteristic pattern. Making us wonder if this is a rare entity or a forgotten entity? Our answer is that it can be a combination of both elements.

References

- Berger H. Intermittent Hydrarthrosis with and allergic basis. *JAMA*. 1939;112(23):2402–2405.
- Intermittent Hydrarthrosis of Both Knees. Harry Jay Epstein and Louis Edeiken. *Radiology* 1940 35:3, 360-361.
- Reeves J. Intermittent hydrarthrosis – two cases. *Calif Med*. 1949;71(5): 359–361.
- Weiner AB, Ghormley RK. Periodic benign synovitis: idiopathic hydrarthrosis. *J Bone Joint Surg*. 1956;38:1034–55.2.
- Hiller RI. Intermittent hydrarthrosis. *Am J Obstet Gynecol*. 1952;64(1):209-12.
- Polyarthritits/Intermittent%20Hydrarthrosis%20disease_%20Malacards%20-%20Research%20Articles,%20Drugs,%20Genes,%20Clinical%20Trials.html
- Handa R, Aggarwal P, Wali JP. Intermittent hydrarthrosis. *J Assoc Physicians India*. 1998;46(6):571.
- Ensign DC, Sigler JW. Intermittent hydrarthrosis; periodic benign synovitis. *Postgrad Med*. 1958;24(1):30-35..
- Mattingly S. Intermittent hydrarthrosis. *Br Med J*. 1957;1(5011):139-143.
- Sanmarti R, Cañete JD, Salvador G. Palindromic rheumatism and other relapsing arthritis. *Best Pract Res Clin Rheumatol*. 2004;18(5):647-661.
- Gómez-Puerta J, García-Melchor E. Young woman with relapsing arthritis. *Reumatología clínica*. 2007;6:58-62.
- Ivory D, Velázquez CR. The forgotten crystal arthritis: calcium pyrophosphate deposition. *Mo Med*. 2012;109(1):64-8.
- Denis F, Franchimont P, van Cauwenberge H. Inflammatory arthropathies of an intermittent nature. *Rev Med Liege*. 1969;24(16):604-11.
- Gómez-Puerta JA, Sanmarti R. Artropatías asociadas a enfermedades inflamatorias del intestino. En: Alarcón-Segovia D, Molina J, Molina JF, Catoggio L, Cardiel MH, Angulo JM, editores. *Tratado Hispanoamericano de Reumatología*. Bogotá, Colombia: Editorial Nomos S.A.; 2006. p. 599–605.
- Selmi C, Gershwin ME. Diagnosis and classification of reactive arthritis. *Autoimmun Rev*. 2014;13(4-5):546-549.
- Klemp P, Halland AM, Majoos FL, Steyn K. Musculoskeletal manifestations in hyperlipidaemia: A controlled study. *Ann Rheum Dis*. 1993;52(1993):44-48.
- Andrés M, Pascual E. Anakinra for a refractory case of intermittent hydrarthrosis with a TRAPS-related gene mutation. *Ann Rheum Dis*. 2013;72(1):155.
- Mankia K, Emery P. What can palindromic rheumatism tell us? *Best Pract Res Clin Rheumatol*. 2017;31:90–8.
- Tani Y, Kishi T, Miyamae T, et al. The evaluation of gene polymorphisms associated with autoinflammatory syndrome in patients with palindromic rheumatism complicated by intermittent hydrarthrosis. *Clin Rheumatol*. 2020;39(3):841-845.
- Cañete JD, Aróstegui JI, Queiró R, et al. Association of intermittent hydrarthrosis with MEFV gene mutations. *Arthritis Rheum*. 2006;54(7):2334-2335.
- Queiro-Silva R, Tinturé-Eguren T, López-Lagunas I. Successful therapy with low-dose colchicine in intermittent hydrarthrosis. *Rheumatology (Oxford)*. 2003;42(2):391-392.
- Julkunen H. Successful Treatment of Intermittent Hydrarthrosis With Hydroxychloroquine. *J Clin Rheumatol*. 2015;21(8):454.