

Abrupt Closure during Percutaneous Coronary Intervention (PCI): Two Guide Technique

Dr. Adithya Udupa K, MBBS, MD, DM*

Consultant Cardiologist, Apollo BGS Hospital, Mysore, India.

*Correspondence:

Adithya Udupa K, Consultant Cardiologist, Apollo BGS Hospital, Mysore, India, E-mail: .

Received: 15 June 2018; Accepted: 02 July 2018

Citation: Adithya Udupa K. Abrupt Closure during Percutaneous Coronary Intervention (PCI): Two Guide Technique. *Cardiol Vasc Res.* 2018; 2(3); 1-3.

ABSTRACT

Abrupt closure during coronary intervention is defined as an abrupt cessation of coronary flow to TIMI grade 0 or I flow during coronary angioplasty. Primary causes for abrupt closure include dissection, thrombus formation or combination of both. Initial treatment for abrupt closure includes balloon redilatation and deployment of stent to stabilize a dissection. In unstable patients, a quick shift to Operation theatre with an Intra-aortic Balloon Pump (IABP) support could save the lives.

Here we present a case of abrupt closure during elective coronary intervention to Left Anterior Descending (LAD) artery which didn't respond to any of the routine techniques employed, but saved with two guide technique.

Keywords

Abrupt closure, Coronary intervention, Coronary dissection, Angioplasty.

Introduction

The incidence of abrupt closure during PCI has decreased from 3% in the balloon angioplasty era to 0.3% in the current era. This decreasing incidence corresponds to the increased use of stents and effective antithrombotics [1]. The common mechanism of abrupt closure is dissection followed by thrombus formation [2]. Patient-related factors of abrupt closure include unstable angina, multivessel disease, female gender and chronic renal failure.3 Angiographic risk factors predictive of abrupt closure are proximal tortuosity, diffuse lesion, pre-existing thrombus, degenerated vein graft and extremely angulated lesion [3]. In the DES era, common causes of abrupt closure are stent edge dissection and acute stent thrombosis. Here we discuss a case where abrupt closure occurred in a calcified LAD due to slippage of the balloon during inflation causing dissection.

Case Report

A 43 years old male with positive TMT was taken for coronary angiogram, which showed single vessel 90% proximal to mid LAD disease and after discussion with relatives taken for PCI

and stenting. The procedure continued from radial approach with 6 French sheath, a 5 French Judkins Left Guide was passed and engaged in left coronary system. A 2.0 ×12 mm sapphire balloon crossed through the lesion over coronary wire and inflated, forward slippage was seen and immediately deflated. Coronary shoot showed a small dissection at the proximal part of the lesion. Ballooning continued and withdrawn with good results. Then preceded with stenting, but 3×23 mm PRONOVA PLUS stent was not able to cross the proximal LAD and the coronary shoot showed abrupt closure of proximal LAD. As balloon was able to cross the lesion again, a prolonged inflation was done and again stenting tried but without success. The repeated try actually made the dissection flap big and made stenting almost impossible. The guide was changed to 6F and two wire techniques were tried, again prolonged ballooning tried but all without any results. By this time patient was getting severe angina and was getting unstable. So a 7F femoral sheath inserted into right femoral artery and 6F guide passed through it and engaged in left main and wire crossed through the lesion in true lumen and multiple similar attempts done from there. At last we inserted the radial guide deep enough to lay just against the proximal end of the dissection flap and stent was pushed over the femoral wire under radial guide which is blocking the dissection flap and giving the final result with TIMI III flow after keeping stent inflated for prolonged time. Patient

was haemodynamically stable and shifted to cardiac care unit for monitoring.

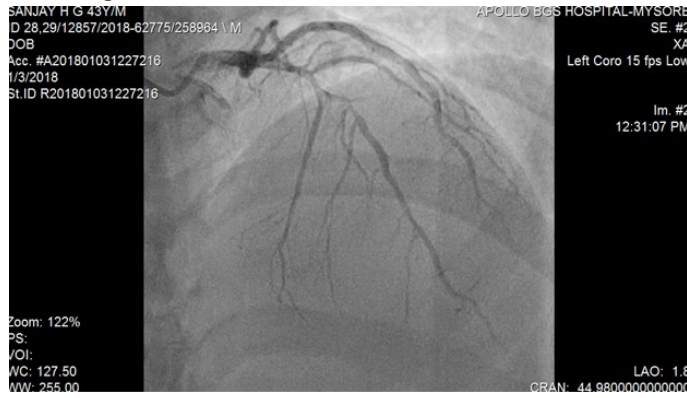


Figure 1: Showing mid LAD lesion in LAO cranial view.

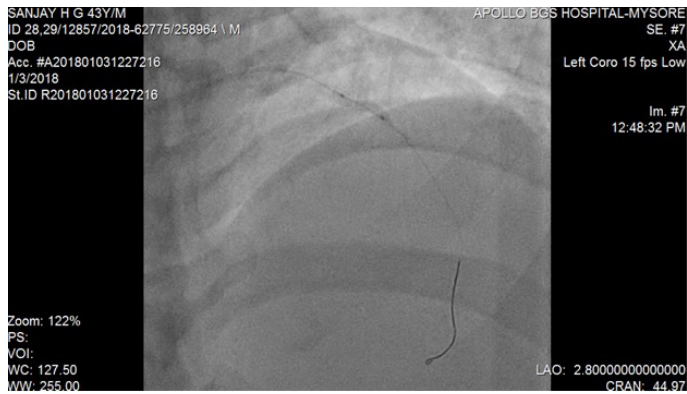


Figure 2: preparing the bed by ballooning of the lesion with 2.0×12 mm sapphire balloon in LAO cranial view.

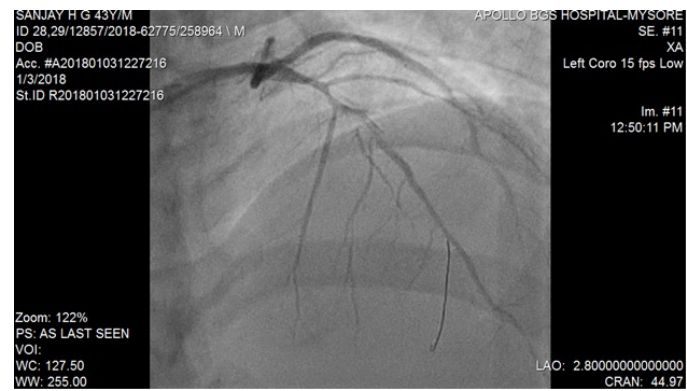


Figure 3: Showing dissection flap in distal end of lesion in same view.

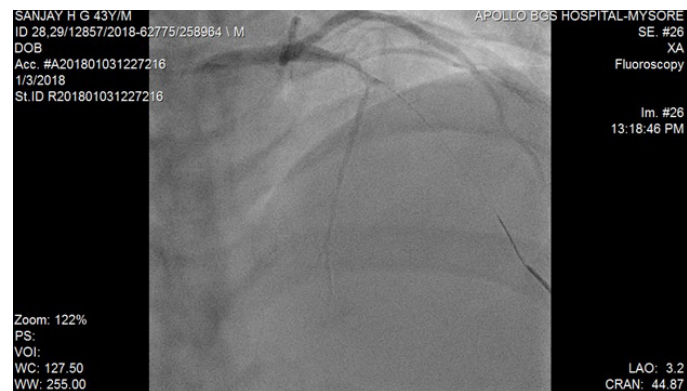


Figure 4: Abrupt closure after attempted stenting with 3×23 mm PRONOVA PLUS stent.

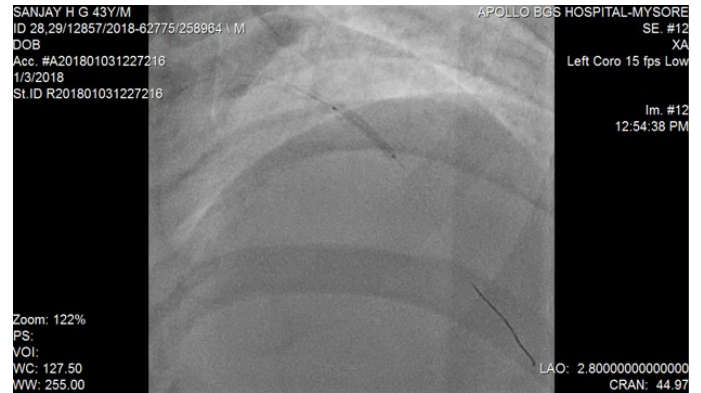


Figure 5: Showing prolonged ballooning to for abrupt closure.

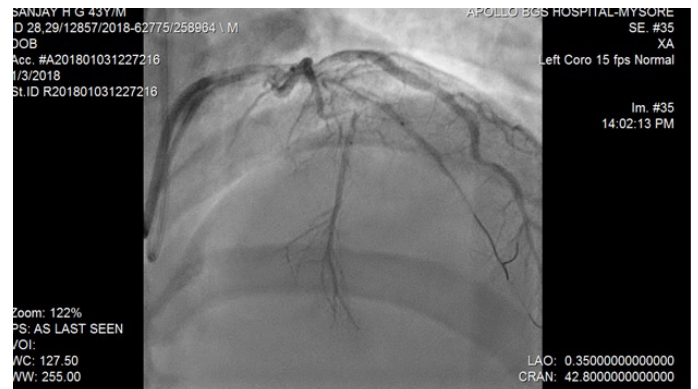


Figure 6: Showing two guide techniques for stent placement across the lesion.

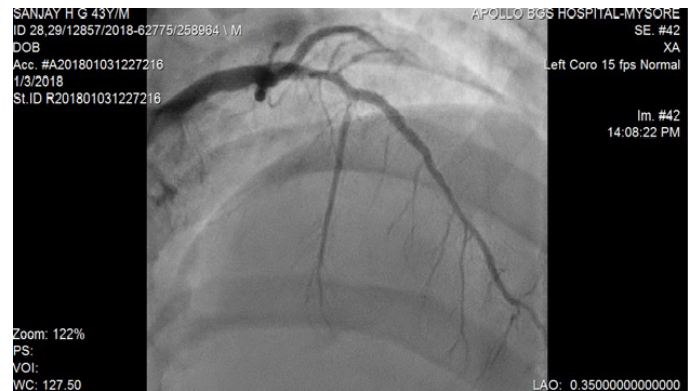


Figure 7: Showing end result with TIMI III flow and closure of dissection flap.

Discussion

Abrupt closure during PCI is less but still a significant contributor for morbidity and mortality if not treated in a brisk and timely fashion [1]. Dissection followed or accompanied by thrombus formation is the primary culprit for abrupt closure. Though tortuosity, diffuse nature of the disease contribute a lot to edge dissection, in our case calcification of LAD also played a significant role for slippage of balloon and dissection caused henceforth. In our case in contrast to many studies in which proximal dissection was more common [4], distal dissection caused the abrupt occlusion and added to the

difficulty.

Abrupt closure results in acute ischemia manifesting as ECG changes, hypotension, bradycardia, chest pain and ventricular arrhythmias. The priority lies in stabilizing hemodynamics and relieving ischemia. Vasopressors, inotropes and intra-aortic balloon pump (IABP) may be considered for unstable hemodynamics [5]. Throughout the procedure keeping the wire in true lumen is of utmost importance. Prolonged Balloon inflations are the most commonly used bailout procedure if the patient can withstand and hemodynamics permit. In our case most of the routine procedures failed and we had to try with two guide technique. Two guides from different ports permit us to tackle dissection separately and also not to worry about wire entangling.

Conclusions

Abrupt closure during PCI can be panicking if not intervened immediately. Dissection flap in itself or along with thrombus is the cause of total occlusion. Keeping the wire in true lumen is of at most importance. Prolonged inflation of balloon/stent will give good results in most of the cases. But in cases where usual

methods fail two guides technique can be a life saver.

References

1. Venkitachalam L, Kip KE, Selzer F, et al. Twenty-year evolution of percutaneous coronary intervention and its impact on clinical outcomes: a report from the National Heart, Lung, and Blood Institute-sponsored, multicenter 1985-1986 PTCA and 1997-2006 dynamic registries. *Cathet Cardiovasc Interv.* 2009; 2: 6-13.
2. Huber MS, Mooney JF, Madison J, et al. Use of a morphologic classification to predict clinical outcome after dissection from coronary angioplasty. *Am J Cardiol.* 1991; 68: 467-471.
3. Ellis SG. Coronary lesions at increased risk. *Am Heart J* 1995; 130: 643-646.
4. David R Holmes Jr, John B Simpson, Lisa G Berdan, et al. Abrupt closure: The CAVEAT I experience. *Journal of the American College of Cardiology.* 1995; 26: 1494-1500.
5. Debabrata Dash. Complications of coronary intervention: abrupt closure, dissection, perforation. *Heart Asia.* 2013; 5: 61-65.