



PRACTICE

ESSENTIALS

Testing the reflexes

A J Lees *neurologist*¹, Brian Hurwitz *former general practitioner*²

¹The National Hospital, Queen Square, London WC1N 3BG, UK; ²King's College London, London WC2B 6LE, UK

What you need to know

- Tendon reflex testing allows lower and upper motor neurone lesions to be distinguished reliably
- Interpret reflexes alongside a clinical history and any abnormalities of power, tone, and sensation found on examination
- Reflex testing is essential if you suspect spinal cord and cauda equina compression, acute cervical or lumbar disc compression, or acute inflammatory demyelinating polyradiculoneuropathy

Eliciting the deep tendon reflexes is a vital component of medical assessments in general practice (where 9% of medical problems are believed to be neurological in origin¹) and in hospital (where 10-20% of admissions have a primary neurological problem²). Reflex testing contributes to accurate bedside diagnosis in many cases of neuromuscular disease, providing localising diagnostic information that cannot be obtained by any other method (including clinical neurophysiological and neuroradiological investigations). It can be helpful in deciding if neurological, neurosurgical, or orthopaedic referral is required.

This article briefly describes the clinical and pathological rationales for reflex testing and gives practical tips on when and how to elicit the deep tendon reflexes.

What are deep tendon reflexes?

When a tendon is tapped briskly its muscle contracts as a consequence of a synchronous volley of afferent impulses from the primary sensory endings of the muscle spindles in the stretched muscle. This involves a two neurone reflex in the spinal or brain stem segment that innervates the muscle (fig 1). At the same time, neurones modulated by descending corticospinal fibres are stimulated which activate opposing muscle groups around the joint dampening the resulting jerk.

When to do it?

Patients presenting with motor or sensory symptoms in the limbs should have their reflexes tested to help distinguish between a lower motor neurone lesion (due to damage in the final common pathway that connects the anterior horn cells of the spinal cord

with muscles via the nerve roots, plexuses, peripheral nerves, and neuromuscular junction) and an upper motor neurone lesion (due to damage upstream from the anterior horn cell, including the corticospinal tracts, the brain stem, and motor cortex). This distinction is the first stage in locating the site of neurological damage.

There are situations where all the neurological symptoms occur above the neck (such as bulbar symptoms due to motor neurone disease) where reflex testing is also essential.

Box 1 lists some clinical scenarios where testing the deep tendon reflexes is discriminatory when coming to a diagnosis.

Box 1: Presentations in general practice where tendon reflex testing is essential and discriminatory

- Persistent pain radiating down the leg on straight leg elevation suggestive of a prolapsed lumbar disc—If a knee jerk is absent, a diagnosis of a L3/L4 nerve root entrapment can be made; if the ankle jerk on the side with pain is absent, a S1 root lesion is probable.
- Numbness of the feet and ankles in a stocking distribution and loss of knee and ankle jerks (even in the absence of impaired sensation to pinprick) indicate that a peripheral neuropathy needs excluding with nerve conduction studies.³
- Pain in one shoulder with weakness of the arm and absent triceps jerk suggest cervical disc prolapse or, in an older person, a cervical spondylotic root lesion. Further examination may reveal weakness of C7/C8 innervated muscles. If other reflexes in the arms are brisk, this suggests associated cervical cord compression.
- Pain or "heaviness" in the lower back, legs, hips, or buttocks and/or weakness after walking (spinal claudication) with absent ankle jerks, saddle anaesthesia, and new symptoms of urinary or bowel disturbance suggest a cauda equina lesion, which needs emergency neurological or neurosurgical referral.
- Subacute onset of increasing leg weakness with absent limb reflexes and no sensory loss may be due to acute inflammatory demyelinating polyradiculoneuropathy (Guillain-Barré syndrome), which needs emergency neurological referral
- Weakness of the legs with sphincter disturbance and sensory loss with a sensory level on the abdomen, brisk reflexes, Babinski signs, and absent cutaneous abdominal reflexes suggest spinal cord compression, which requires urgent neurosurgical referral.

Which reflexes to test?

The deep tendon reflexes (also sometimes referred to as stretch reflexes) most often tested are:

Arms

Biceps (C5/6 myotome)—Find the biceps tendon with your index and middle finger. Push down on the tendon and pull it slightly towards the patient's wrist then strike the tendon sharply with the patellar hammer and look for the contraction (fig 2).

Brachioradialis (supinator) (C6 myotome)—Strike with the hammer just proximal to the styloid process of the radius and look for flexion and supination of the forearm.

Triceps (C7/8 myotome)—With the patient supine, hold the arm down and across the trunk towards the opposite hip. Let the forearm rest lightly on the abdomen and then, with the patient's elbow flexed about 40°, strike the tendon at its insertion just proximal to the elbow.

Legs

Knee (L3/L4 myotome)—Flex the leg at the knee and hip. Hold the leg under the knee and then strike the patellar tendon and watch for quadriceps contraction.

Ankle jerks (S1/S2 myotome)—The ankle jerk is the most difficult reflex to elicit, and palpation of the Achilles tendon before striking to ensure the hammer is striking the correct location can be helpful when difficulties in interpretation are encountered (fig 3). A plantar strike (a firm strike of the patellar hammer on the ball of the foot) is an alternative technique to elicit the reflex (fig 3b). One study found that a plantar strike showed less inter-observer and intra-observer variability than an Achilles tendon strike.⁴ In a separate study, medical students found the plantar strike easier and more reliable.⁵ Practitioners are advised to use the technique with which they are most comfortable.

An absent ankle jerk can sometimes be heard as a dull thud. If the result is uncertain, a further effective way to test this reflex is to ask the patient to kneel on a chair with the Achilles tendon exposed (fig 3c) (this method was often used by endocrinologists to elicit the slow relaxation of ankle jerks in myxoedema).

The plantar reflex is often discussed alongside deep tendon reflexes, but it is a cutaneous reflex elicited by scratching the sole of the foot. If the great toe consistently goes up (dorsiflexes, Babinski's sign) then a lesion of the upper motor neurone is present (flexion withdrawal due to ticklishness or hypersensitivity can be confounding factors). There is some evidence that neurologists' interpretation of the plantar reflex is influenced by their presuppositions based on the clinical history.⁶

More detailed reflex testing

Neurologists sometimes carry out more detailed reflex testing, but this is beyond the scope of most non-specialist clinicians (box 2).

Box 2: More specialist reflexes

- A brisk response to tapping the trapezius, pectoralis major, and the finger flexors in the context of a tetraparesis suggests high cervical cord damage.
- Reflex spread (the fingers flex when eliciting the brachioradialis reflex) is also an indication of an upper motor neurone lesion.
- Testing of Hofmann's reflex involves loosely holding the middle finger and flicking the fingernail downwards. Flexion and adduction of the thumb on the same hand (a brisk finger flexion tendon reflex) is a positive response indicating an upper motor neurone lesion. It is often seen in association with brisk finger jerks elicited by lightly tapping the flexor surface of slightly flexed fingers with a patellar hammer
- Brisk reflexes due to corticospinal tract damage may be associated with sustained clonus on forcible stretching of the ankle or patella (more than five beats is definitely pathological), Babinski's sign, and a brisk jaw jerk (elicited by a downward tap on the chin with the jaw allowed to fall half open) may point to a pseudobulbar palsy due to involvement of the corticobulbar motor pathways. A crossed ankle reflex (eliciting the ankle jerk leads to adduction of the contralateral thigh and sometimes foot inversion) is sometimes present in motor neurone disease and hereditary spastic paraplegias.

How to do it?

Explain the process to the patient

Inform the patient that:

- Reflexes in the arms, legs, and jaw will be tapped
- This will be painless
- They should not be alarmed if their limbs jerk nor concerned if they don't.

A small minority of people become anxious at the prospect of reflex testing, similar to a fear of being tickled. Ideally the patient should be undressed so that the entirety of their arms and legs are visible and should either be sitting on the edge of the examination couch with the legs dangling or lying flat. If you are pressed for time, the examination can be conducted with the patient partly clothed. The one exception to this is the ankle jerk, where clear visualisation is needed to ensure the hammer lands centrally on the Achilles tendon.

Ensure good technique

The commonest cause of an absent reflex is a clumsy blow with a hammer off-centre to the tendon of a muscle held tightly by a fearful patient.

If the reflexes are difficult to elicit then try reinforcement (Jendrassik's manoeuvre): just before you tap the tendon is tapped, ask the patient to (a) clench their jaw for arm reflexes or (b) wring their hands together for knee and ankle jerks.

Special situations

Reflexes may be challenging to elicit in heavily built, muscular men because it can be difficult to generate enough force to stretch the tendon and initiate the reflex arc.

Reflexes can be done in children from the age of toddlers upwards. Usually there are no problems, but explain to the parents what you are doing and make a game of the procedure to avoid the child being frightened.

What does it tell us?

In general practice testing the reflexes can be helpful in deciding if neurological, neurosurgical, or orthopaedic referral is needed—despite this, there is evidence that most patients in the United Kingdom are not fully examined before referral.⁷ For

specific circumstances where tendon reflex testing is essential, see [box 1](#).

How to interpret reflex testing

An absent jerk points to a lower motor neurone lesion, whereas a very brisk reflex suggests an upper motor neurone lesion.

Single absent reflex—A single absent reflex is always pathological if supported by other findings, but if there are no other supportive symptoms or signs suggestive of a peripheral nerve or root lesion the “ignore one sign” rule is often applied by neurologists. At the very least, however, this finding warrants a follow-up reassessment in general practice.

No reflexes bilaterally—A small percentage of normal people have no tendon reflexes which is of no pathological consequence provided there is no associated weakness or muscle wasting.

Asymmetrical reflexes—Comparing reflexes on one side of the body with those on the other is important when trying to decide whether a hemiparesis due to an upper motor lesion is present. However, care is needed to avoid over-interpretation of mild reflex asymmetry (this can be normal if a patient, for example, is less relaxed on one side because of associated limb pain).

Determining site of neuromuscular damage

When a lower motor neuron lesion is suspected after reflex testing the next step is to try to determine the more precise site of neuromuscular damage:

- An absence of all reflexes in the presence of muscle weakness points to a demyelinating peripheral motor neuropathy or polyradiculopathy
- Patchy reflex loss suggests a multifocal or axonal sensorimotor neuropathy
- Loss of one reflex with focal weakness is usually due to a root lesion.
- Absent limb reflexes in the presence of sensory loss in the distribution of the nerve supplying the reflex suggests involvement of the afferent arc of the reflex, from either the nerve or dorsal root ganglion lesion, commonly from a sensory ganglionopathy or a compression neuropathy.
- If absent limb reflexes are accompanied by motor weakness without sensory change then damage to the anterior horn cell, motor root, plexus, or peripheral nerve are all possible causes for the lower motor neurone lesion. There are multiple causes for this constellation of signs, but common ones include motor radiculopathies due to disc disease and motor neuropathies.
- Brisk reflexes in a wasted, weak limb with fasciculations strongly suggest a diagnosis of motor neurone disease.
- An inverted reflex where there is an absent biceps jerk but with spread to produce a brisk triceps or brachioradialis jerk suggests a lesion of the C5 nerve root with an upper motor lesion due to cord damage, as can occur in cervical spondylotic myelopathy.
- A tendon reflex which had been absent on earlier examination but is now present (also termed a returning reflex) is a good indicator of a more proximal nerve lesion that has since resolved.

How to describe and document deep tendon reflexes?

Tendon reflexes can be described (and recorded) as very brisk (+++), brisk (++) , present (+), or absent (−). They may also be “present with reinforcement.”

There is variation in the notation of tendon reflex responses, and as many as 20 different descriptions and scales are in use. In one study carried out in a university department of neurology evaluating the Mayo Clinic and NINDS scales, the agreement among three physicians was never better than “fair” or modest, and it was recommended that a verbal description (such as “very brisk”) of the responses was more appropriate.⁸

Terms such as “sluggish” or “a bit brisk” provide little discriminatory diagnostic information and may indicate poor technique. The term “mute” to describe an absent reflex is best avoided as the reflex is seen not heard.

History of deep tendon reflexes

Deep tendon reflex testing has been an integral part of the clinical neurological examination since Erb and Westphal first described the knee jerk in 1875.⁹ William Gowers, in the course of his research into the patellar reflex, stated: “It is not a little curious that this knee-jerk, which has for generations amused schoolboys, should have become an important clinical symptom.”¹⁰

Charles Phillips and William Landau referred to the division of neurological disease into lower and upper motor neurone lesions with the help of reflex testing as “the little old synecdoche that still works”¹¹

Sources and selection criteria

Reflex testing is based on largely historical neurophysiological and neuropathological studies. There are limited data on the sensitivity and specificity of reflex testing in particular conditions and clinical settings¹² but compelling descriptive evidence that it can provide important clinical diagnostic information that has not been supplanted by technological advances in clinical neurophysiology or neuroimaging.

Education into practice

- Do you have easy access to a patellar hammer?
- When testing a patient’s tendon reflexes, do you explain why you are tapping the reflexes and what you are looking for?

How patients were involved in the creation of this article

No patients were involved in the creation of this article.

We thank David Nicholl and Andrew Elder for their encouragement and advice and Kate Adlington for in-house editing. The University of Birmingham has produced a useful video of tendon reflex testing incorporated into a brief neurological examination <https://eur01.safelinks.protection.outlook.com/?url=https%3A%2F%2Fwww.youtube.com%2Fwatch%3Fv%3Dq56WgXvn0iU&data=02%7C01%7Candrew.lees%40ucl.ac.uk%7C2c8c58141273489beb8408d6ee81219a%7C1f1af88fea9984c5b93c9210a11d9a5c2%7C0%7C0%7C636958636403545682&data=IKY8T%2F%2BpXgbqS0tLxojkGynLLIPCkrn4z6UeU0dLT4U%3D&reserved=0>.

Competing interests: We have read and understood BMJ policy on declaration of interests and have no relevant interests to declare.

Provenance and peer review: Commissioned; externally peer reviewed

- 1 Salisbury C, Procter S, Stewart K, et al . The content of general practice consultations: cross-sectional study based on video recordings. *Br J Gen Pract* 2013;63:e751-9. 10.3399/bjgp13X674431 24267858
- 2 Douglas MR, Peake D, Sturman SG, Sivaguru A, Clarke CE, Nicholl DJ. The inpatient neurology consultation service: value and cost. *Clin Med (Lond)* 2011;11:215-7. 10.7861/clinmedicine.11-3-215 21902069
- 3 Perkins BA, Olaleye D, Zinman B, Bril V. Simple screening tests for peripheral neuropathy in the diabetes clinic. *Diabetes Care* 2001;24:250-6. 10.2337/diacare.24.2.250 11213874

- 4 O'Keeffe ST, Smith T, Valacio R, Jack CI, Playfer JR, Lye M. A comparison of two techniques for ankle jerk assessment in elderly subjects. *Lancet* 1994;344:1619-20. 10.1016/S0140-6736(94)90411-1 7695707
- 5 Clarke CE, Davies P, Wilson T, Nutbeam T. Comparison of the tendon and plantar strike methods of eliciting the ankle reflex. *J Neurol Neurosurg Psychiatry* 2003;74:1351-2. 10.1136/jnnp.74.9.1351 12933960
- 6 Van Gijn J, Bonke B. Interpretation of plantar reflexes: biasing effect of other signs and symptoms. *J Neurol Neurosurg Psychiatry* 1977;40:787-9. 10.1136/jnnp.40.8.787 303691
- 7 Appleton JP, Ilinca A, Lindgren A, et al. Improving the likelihood of neurology patients being examined using patient feedback. *BMJ Qual Improv Rep* 2015;4:u209610.w4063. 10.1136/bmjquality.u209610.w4063 26734445
- 8 Manschot S, van Passel L, Buskens E, Algra A, van Gijn J. Mayo and NINDS scales for assessment of tendon reflexes: between observer agreement and implications for communication. *J Neurol Neurosurg Psychiatry* 1998;64:253-5. 10.1136/jnnp.64.2.253 9489542
- 9 Boes CJ. The history of examination of reflexes. *J Neurol* 2014;261:2264-74. 10.1007/s00415-014-7326-7 24695995
- 10 Gowers W. On the So-Called Tendon-Reflex. *The Alienist and Neurologist* 1881;2(3):297-308. *The Alienist and Neurologist* 1881;2:297-308.
- 11 Phillips CG, Landau WM. Clinical neuromyology. VIII. Upper and lower motor neuron: the little old synecdoche that works. *Neurology* 1990;40:884-6. 10.1212/WNL.40.6.884 2189081
- 12 Cook C, Roman M, Stewart KM, Leithe LG, Isaacs R. Reliability and diagnostic accuracy of clinical special tests for myelopathy in patients seen for cervical dysfunction. *J Orthop Sports Phys Ther* 2009;39:172-8. 10.2519/jospt.2009.2938 19252263

Published by the BMJ Publishing Group Limited. For permission to use (where not already granted under a licence) please go to <http://group.bmj.com/group/rights-licensing/permissions>

Figures

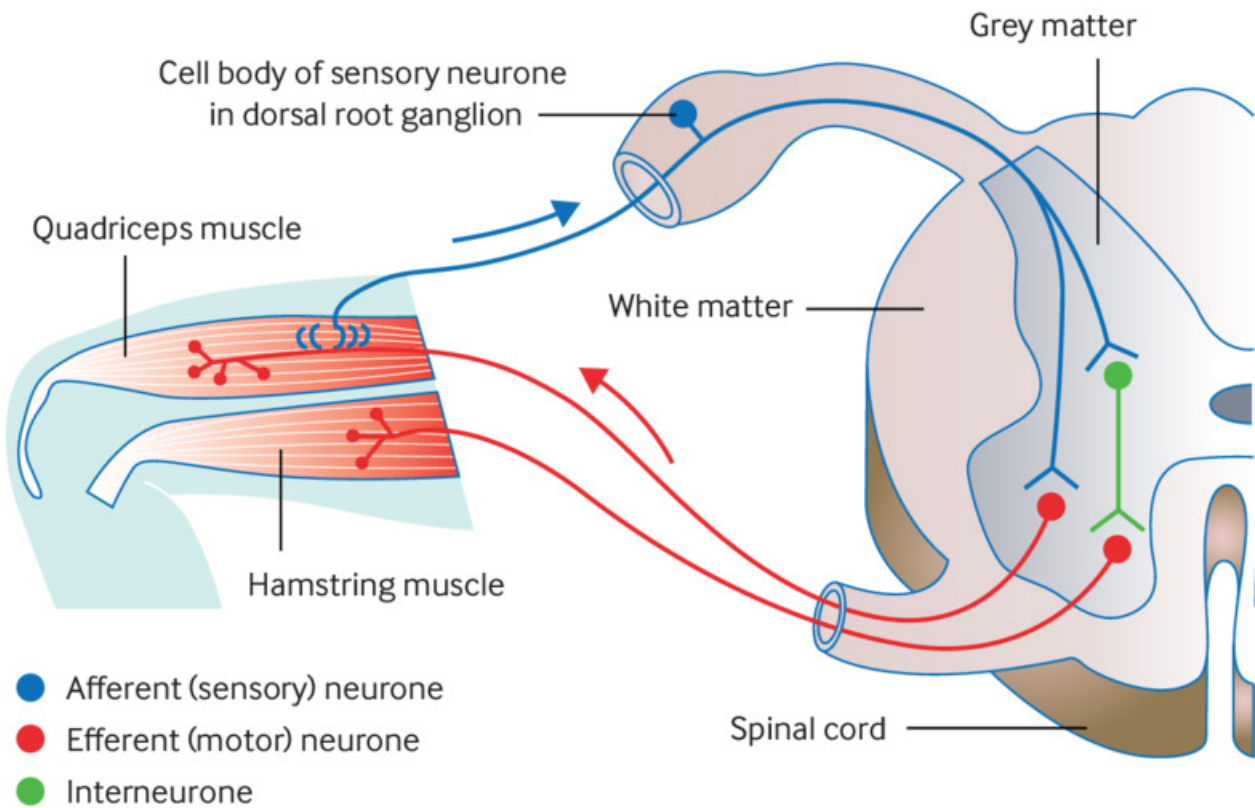


Fig 1 The reflex arc

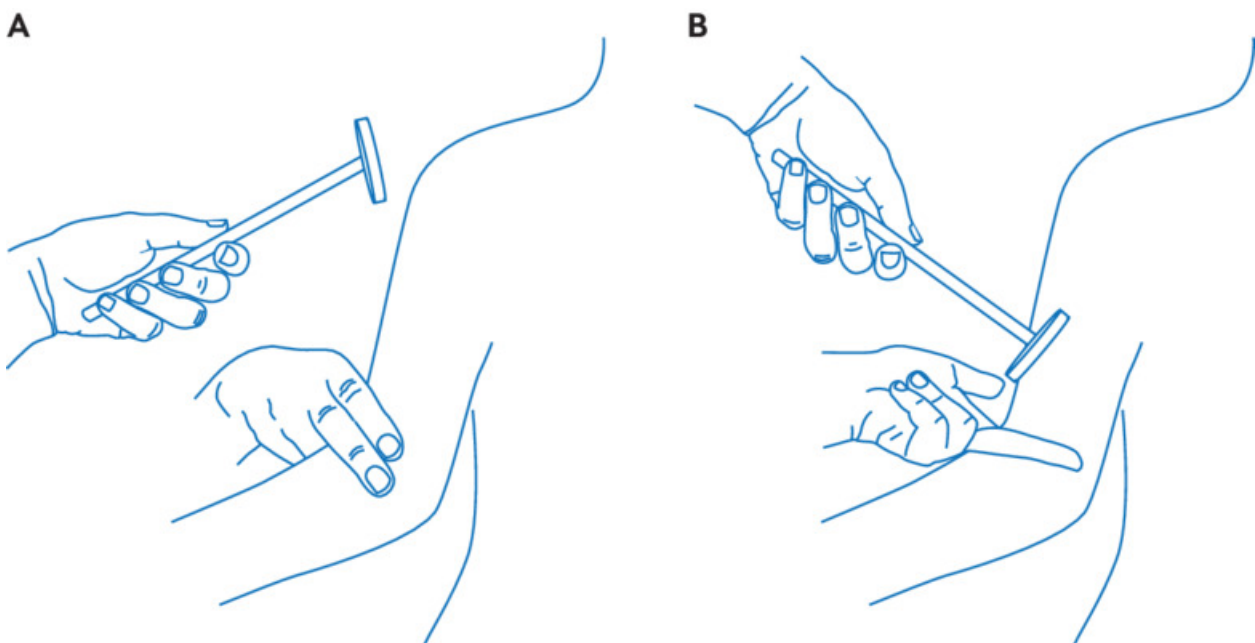


Fig 2 Testing the biceps tendon reflex: locate the biceps tendon with index and middle fingers, push down on the tendon and pull it slightly towards the wrist, then strike with the patellar hammer and assess the contraction

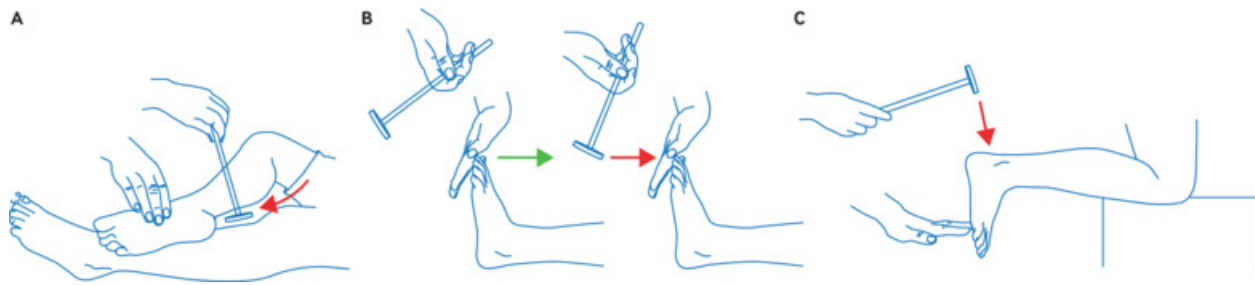


Fig 3 Testing the ankle jerk reflex by (a) tapping the Achilles tendon, (b) plantar strike, or (c) with the patient kneeling on a chair to expose the tendon