

stryker

Aequalis[®] FX

Shoulder System

Operative technique



This publication sets forth detailed recommended procedures for using Stryker devices and instruments. It offers guidance that you should heed, but, as with any such technical guide, each surgeon must consider the particular needs of each patient and make appropriate adjustments when and as required.

Important

- The patient should be advised that the device cannot and does not replicate a normal healthy bone, that the device can break or become damaged as a result of strenuous activity or trauma and that the device has a finite expected service life.
- Removal or revision of the device may be required sometime in the future.
- Cleaning and sterilization information is provided in the applicable instructions for use.
- Non-sterile devices, including implants and instruments, must be cleaned and sterilized prior to use, in accordance with validated methods.
- Devices that are able to be disassembled should be disassembled prior to point-of-use processing. Additionally, devices with movable components that do not facilitate disassembly should be manually articulated during the point-of-use processing step in order to evacuate additional soils.
- Please remember that the compatibility of different product systems has not been tested unless specified otherwise in the product labeling.
- Consult Instructions for Use (<https://ifu.stryker.com>) for a complete list of potential adverse effects and adverse events, contraindications, warnings and precautions.
- The surgeon must advise patients of surgical risks, and make them aware of adverse effects and alternative treatments.
- An implant whose packaging is open or damaged or whose expiration date has passed must not be used. Every precaution must be taken to ensure sterility when opening the packaging of the implant and during implantation.

Aequalis FX

Shoulder System

Table of contents

Operative technique	4
• Preoperative planning	4
• Patient positioning	5
• Deltopectoral approach and exposure	6
• Identification of the lesser and greater tuberosities and anterosuperior arthrotomy.....	6
• Tenotomy and excision of the long head of the biceps.....	6
• Extraction of humeral head fragment and selecting proper prosthetic head replacement	7
• Placing four horizontal stay sutures in the rotator cuff.....	7
• Humeral reaming.....	7
• Choice of the trial prosthesis and attachment to the fracture jig	8
• Setting height and retroversion	9
• Implantation and reduction of the trial prosthesis.....	10
• Identification of the epicondyles and stabilization of the trial prosthesis	10
• Reduction of the greater tuberosity around the trial prosthesis and testing of the height	11
• Removal of the trial prosthesis	11
• Drilling of the diaphysis and placement of the 2 vertical sutures.....	11
• Assembling the implant.....	12
• Cementing the implant	13
• Removal of excess cement and placement of the cancellous bone graft	13
• Removal of two cancellous bone grafts with the bone graft cutter	14
• Positioning the bone graft into the fenestration of the prosthesis	15
• Placement of four horizontal sutures around the prosthetic neck.....	15
• Positioning the bone graft on the flat lateral aspect of the stem	15
• Placing two horizontal cerclage sutures around the greater tuberosity	16
• Placing two horizontal cerclage sutures around both tuberosities	16
• Adding vertical tension band sutures on both tuberosities	17
• Closing and tenodesis of the long head of the biceps	17
• Evaluation of the prosthetic stability and mobility.....	18
• Final closing and immobilization of the arm in abduction and neutral rotation	18
Postoperative rehabilitation	19
Aequalis Fracture Shoulder Prosthesis Extra-Long Stems	20
Assembly instructions	23
Instruments	25
Implants	26

1. Operative technique

1. Preoperative planning

- Obtain stabilization of the prosthesis while using the fracture jig.
- The prosthetic retroversion is fixed at 20 degrees from the trans-epicondylar axis (average value).
- The prosthetic height can be chosen:
 - Intraoperatively, using the bony aspect and soft tissue without any preoperative planning (approximate height).
 - Preoperatively, using a scaled x-ray of the healthy contralateral humerus (precise height).

A ruler with two marker points, with a distance of 100mm, will allow for radiographic magnification conversion.

Recommendation: Place the ruler with the marker point and the arm parallel to the x-ray cassette to minimize errors of measurement. A small cushion is placed under the elbow.

Example:

Calculation of humeral length taking into account the radiological magnification: the real length between the two markers is 100mm; the measured length between the two markers (A-B) is 105mm; the measured length of the healthy humerus (C-D) is 330mm.

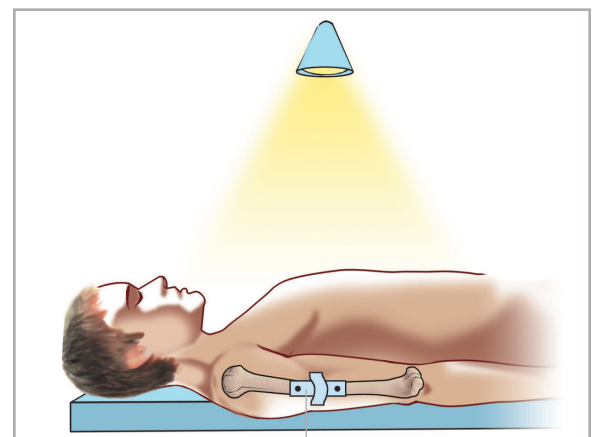
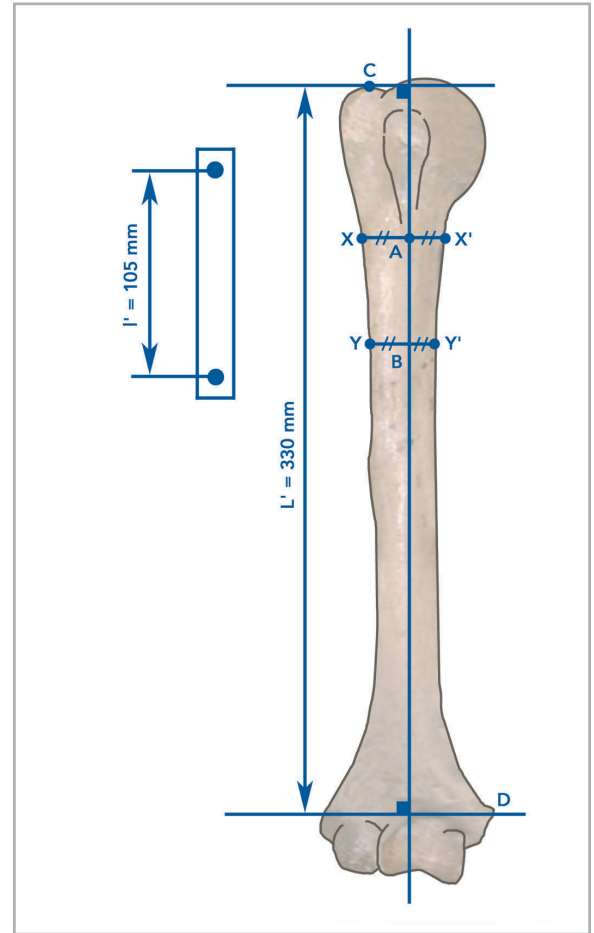
Therefore, using a rule of three:

105mm —————> 100mm

330mm —————> L'

$$L = 330 \times 100/105 = 314 \text{ mm}$$


The real length of the healthy humerus is therefore 314mm, a measurement that should be entered on the fracture jig height ruler (see page 7).



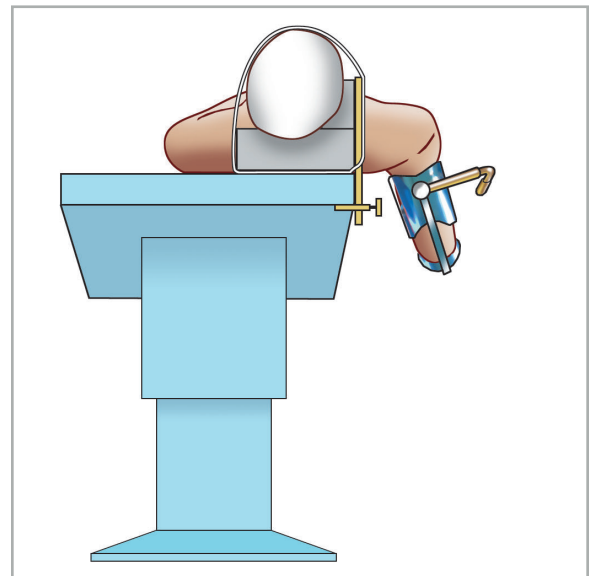
1. Operative technique (continued)

2. Patient positioning

General anesthesia, beach chair position, shoulder free from the table. The shoulder and entire upper extremity are prepped and draped. The arm support for the fracture jig is secured to the arm using a sterile elastic bandage. The elbow must be carefully positioned to fit correctly in the arm support.



The arm support is fixed, leaving the elbow uncovered at the level of the angle of the support. The entire shoulder must be free from the table to allow the jig to be correctly positioned.

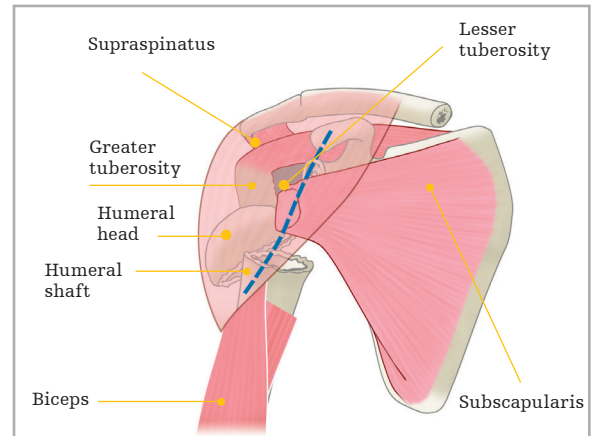


1. Operative technique (continued)

3. Deltopectoral approach and exposure

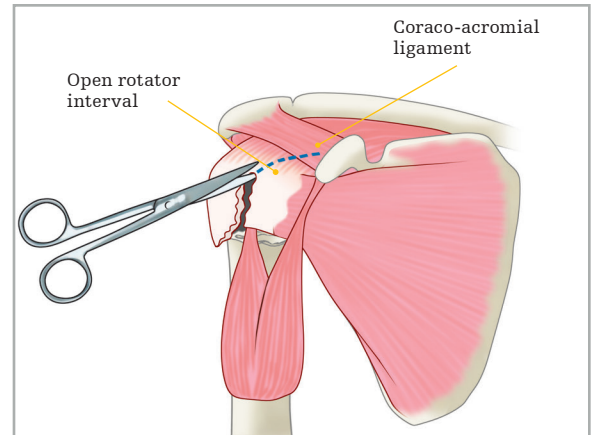
An incision is made from the tip of the coracoid process along the deltopectoral groove, slightly lateral to avoid postoperative scars in the axillary fold. The deltopectoral groove is opened to the insertion of the pectoralis major, and the deltoid and cephalic vein are retracted laterally.

The coracoid process is identified to allow for the insertion of a Hohmann retractor above it. The clavicular, acromial and humeral insertions of the deltoid are always preserved. The clavipectoral fascia is incised at the lateral border of the conjoined tendon of the coracobrachialis and the short head of the biceps. Usually, the coracoacromial ligament is preserved.

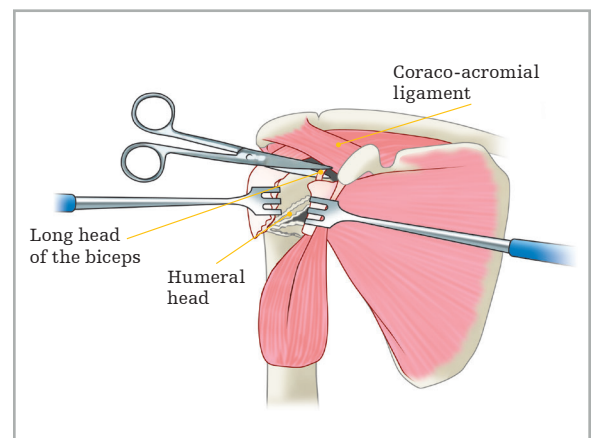


4. Identification of the lesser and greater tuberosities and anterosuperior arthrotomy

The glenohumeral joint is exposed by extending the fracture line between the tuberosities, incising the rotator interval over the long head of the biceps tendon.



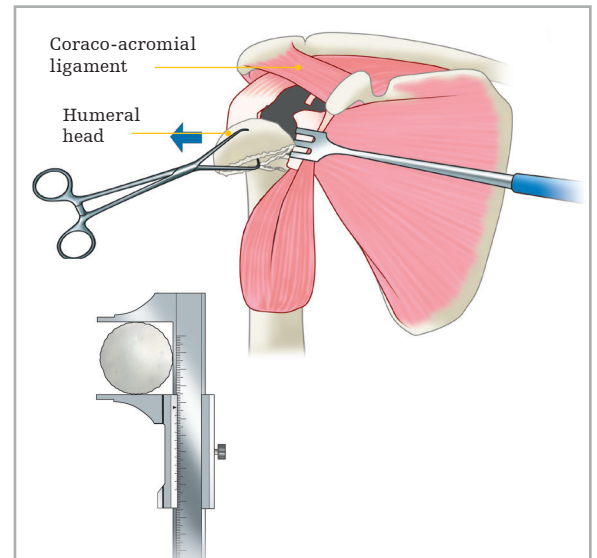
5. Tenotomy and excision of the long head of the biceps



1. Operative technique (continued)

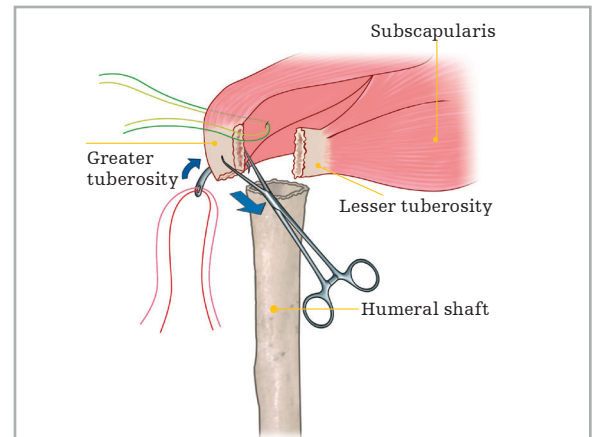
6. Extraction of humeral head fragment and selecting proper prosthetic head replacement

The diameter of the humeral head is determined by measuring the humeral head diameter with a caliper, or by using the trial head support tray as a template. Hint: If the humeral head is between sizes, select the smaller size. The most common mistake is to use a too large size.



7. Placing four horizontal stay sutures in the rotator cuff

Two non-absorbable sutures are placed in the infraspinatus tendon and two more are placed in the teres minor tendon.

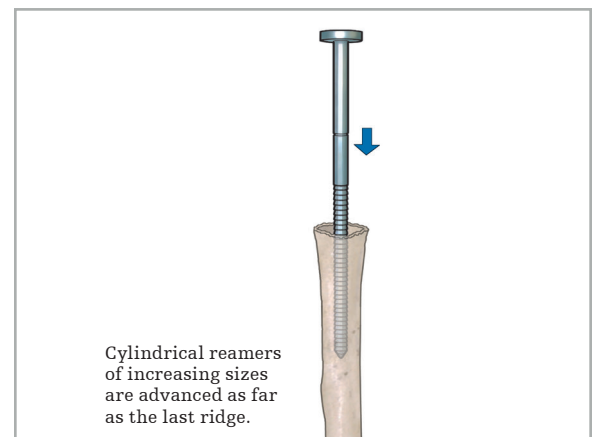


8. Humeral reaming

With the arm in adduction, external rotation and extension, the humerus is progressively reamed using cylindrical reamers of increasing diameter (6.5mm, 9mm, and 12mm).

The final reamer used will determine the diameter of the humeral stem.

At this stage, in case of revision, it is also important to remove as much residual cement as possible in order to avoid compromising the healing of the tuberosities.




1. Operative technique (continued)

9. Choice of trial prosthesis and attachment to the fracture jig

To accurately re-establish the humeral head, we recommend the use of a prosthetic humeral head of the same size as the removed head.

The humeral head should be positioned either on the **R** for a right arm or on the **L** for left arm.



The trial stem is secured to the prosthesis holder (right or left depending on the side) using the two holes located on the low profile lateral part of the implant. The prosthesis holder is then fixed to the fracture jig.

1. Operative technique (continued)

10. Setting height and retroversion

- The height has been determined by the preoperative planning (page 4).
- The retroversion is set at 20° , which is an average value based on anatomic studies from Gilles Walch, MD, and Pascal Boileau, MD.*

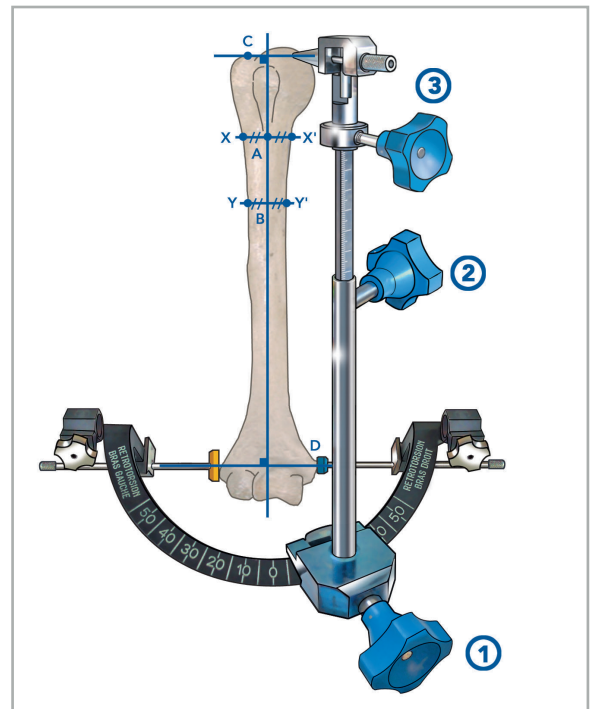


The Aequalis Fracture Jig is composed of:

- a ruler, to determine the humeral height
- a protractor, to determine the humeral retroversion.

The humeral height is determined in relation to the metaphyso-diaphyseal axis (A-B), the top of the greater tuberosity (C) and the medial epicondyle (D), while the humeral retroversion is determined in relation to the axis of the epicondyles (D-E).

The proximal metaphyso-diaphyseal axis (A-B) represents the axis of the future prosthetic stem. It must not be confused with the diaphyseal axis, at the risk of causing a valgus position of the prosthesis and giving a false measurement of length.

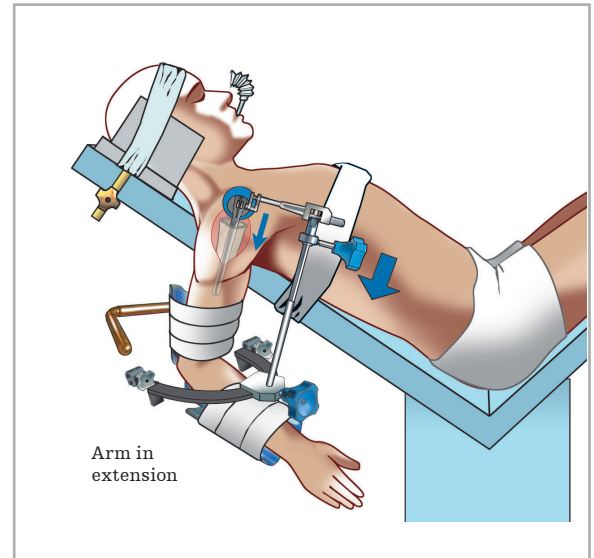


*Walch, Gilles and Boileau, Pascal. Shoulder Arthroplasty. Spring 1999.

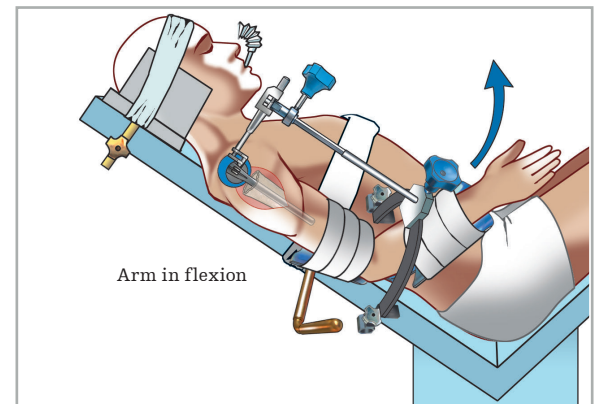
1. Operative technique (continued)

11. Implantation and reduction of the trial prosthesis

Positioning of the remaining components of the fracture jig assembly (protractor, ruler, prosthesis holder and trial prosthesis) must be done with the **arm in extension**.



Once the trial prosthesis has been inserted into the humerus, **the arm is placed in flexion** to reduce the glenohumeral joint.




12. Identification of the epicondyles and stabilization of the trial prosthesis

Accurate recreation of height and retroversion begins with the placement of the epicondylar pads on the medial and lateral epicondyles.

The surgeon positions each epicondylar pad on the prominences of the lateral and medial epicondyles.

At the same time, the assistant connects the protractor to the arm support, securing the two angle joints by using knob n° 4.

The fracture jig is then secured, allowing the selection of height and retroversion and a trial reduction.

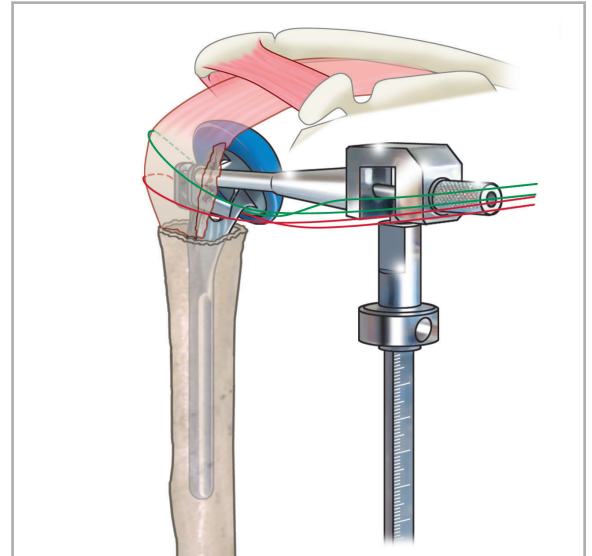


1. Operative technique (continued)

13. Reduction of the greater tuberosity around the trial prosthesis and testing of the height

The initial reduction of the prosthesis and the greater tuberosity enables both the height and the retroversion to be tested. The greater tuberosity is placed on the diaphysis and the prosthesis, effectively testing the height of the prosthesis. There are three landmarks of interest:

1. The height of the acromiohumeral space, which is usually **10mm**.
2. The top of the greater tuberosity, which should be located **5mm below** the upper limit of the prosthetic head.
3. **There must be no diastasis or overlap between the greater tuberosity and the humeral diaphysis.** The lesser tuberosity is then reduced to verify the adjustment with the greater tuberosity and the diaphysis. Once all of the adjustments have been performed, the trial prosthesis is withdrawn.

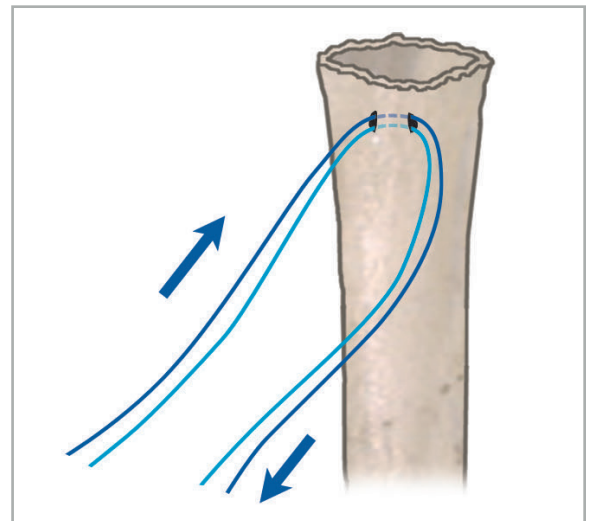


14. Removal of the trial prosthesis

The shoulder is placed in extension to dislocate the trial prosthesis. The prosthetic holder and the trial prosthesis are removed, leaving the remaining component of the fracture jig in place.

15. Drilling of the diaphysis and placement of the 2 vertical sutures

Two holes are drilled laterally to the bicipital groove. Two non-absorbable sutures are passed through the holes.



1. Operative technique (continued)

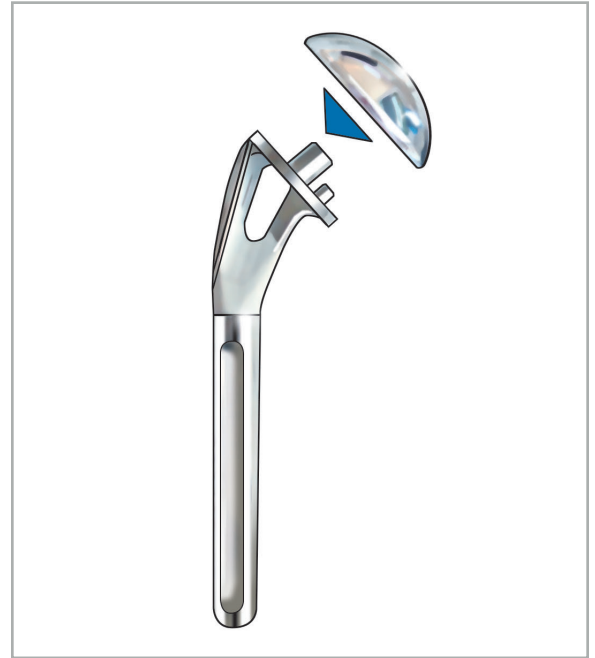16. Assembling the implant

Assembling

The assembly of the implant is done by impaction of the prosthetic head onto the stem.

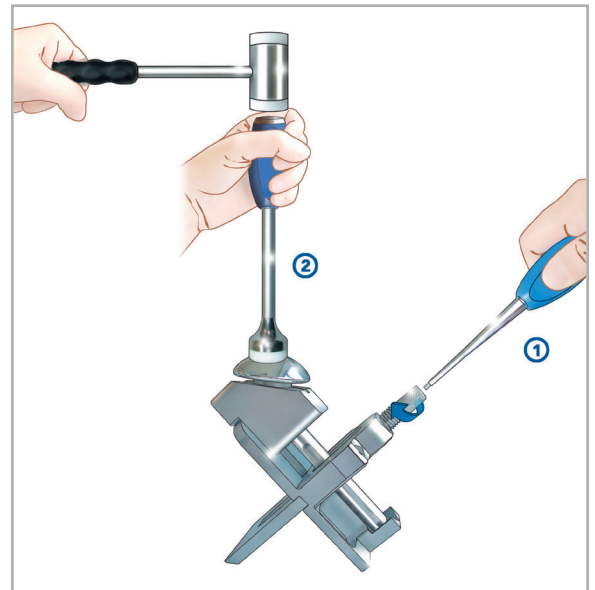
The assembly is secured by a taper lock system.

The prosthetic head is positioned on the stem, aligning the preselected offset number with the superior aspect of the stem.



Impaction

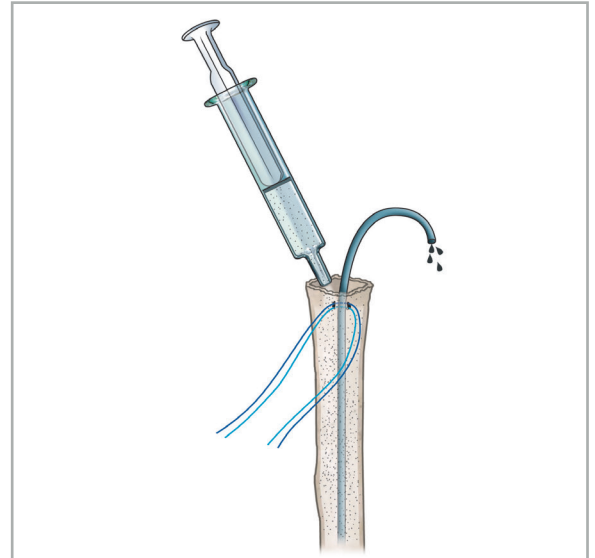
The prosthesis is positioned on the impaction support. The locking screw of the impaction support is tightened with a 4.5mm screwdriver to secure the prosthesis during impaction. A mallet is used to firmly engage the head onto the stem taper.



1. Operative technique (continued)

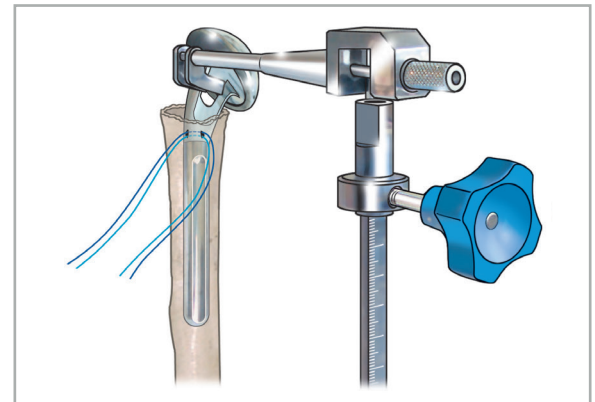
17. Cementing the implant

After placement of a cement restrictor, the canal is dried and cement is injected using a large syringe.



The implant is attached to the prosthesis holder in the same manner as the trial stem.

The prosthesis is introduced into the medullary canal as the prosthesis holder is introduced into the ruler. Knob n° 3 is then tightened, to secure the implant holder to the jig assembly.

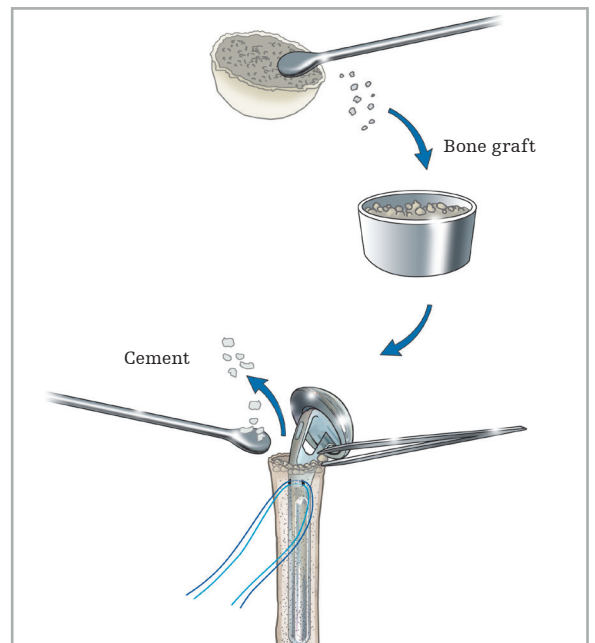


18. Removal of excess cement and placement of the cancellous bone graft

Excess cement is removed from the metaphyseal region and replaced with cancellous bone, taken from the humeral head to promote healing between the tuberosities and the diaphysis.

At this stage, if the humeral head doesn't provide enough bone graft (or in case of revision), it is possible to use other graft sources.

Once the cement is set, the prosthesis holder and the rest of the Aequalis Fracture Jig are removed.



1. Operative technique (continued)

19. Removal of two cancellous bone grafts with the bone graft cutter

Bone grafting is highly recommended to improve tuberosity healing. Two bone grafts are removed from the resected humeral head using the bone graft cutter.

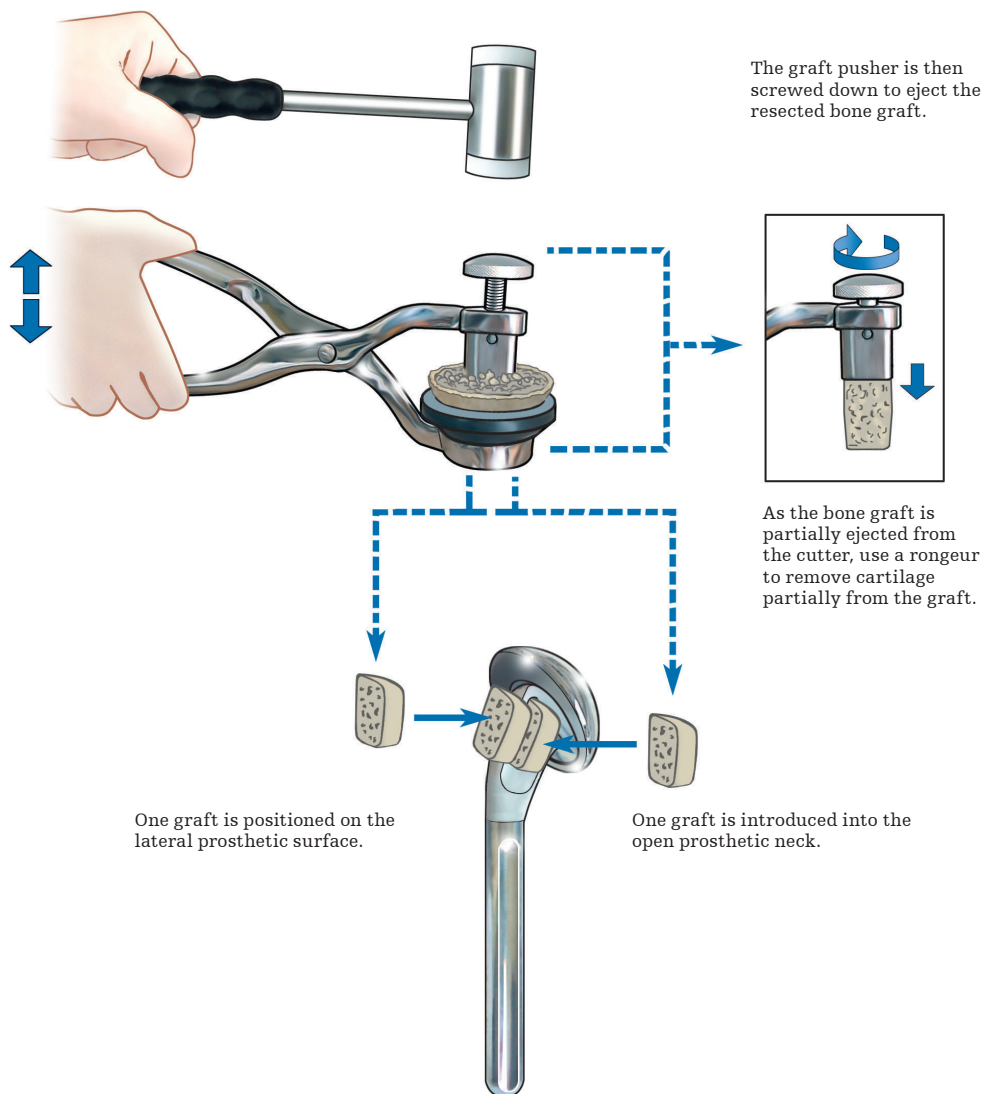
The bone graft cutter allows two bone grafts shaped according to the fenestration of the prosthesis to be removed from the resected humeral head.

The graft pusher is unscrewed and the bone graft source is placed in the base of the bone graft cutter.

The bone graft cutter handles are firmly tightened to cut the bone graft.

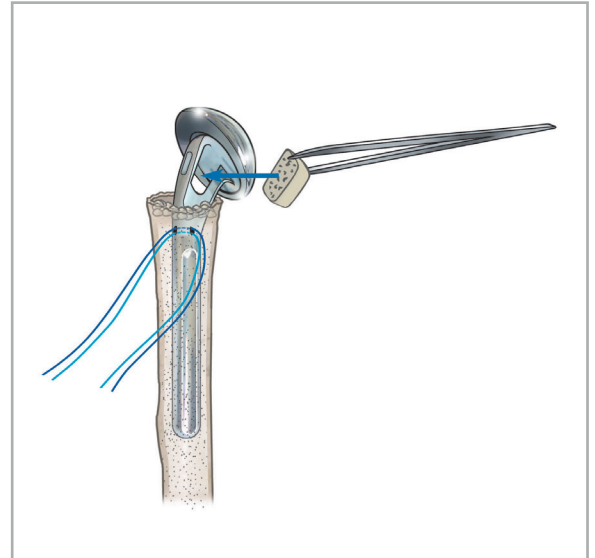
In the case of exceptionally hard bone, a mallet can be used to impact the clamp.

The positioning of the two bone grafts is described in sections 20 and 22.



1. Operative technique (continued)

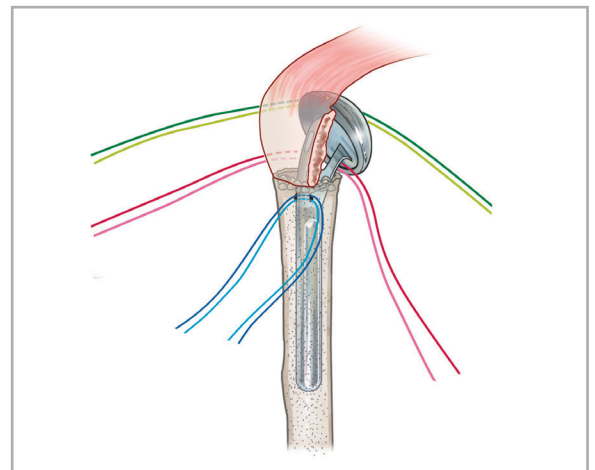
20. Positioning the bone graft into the fenestration of the prosthesis



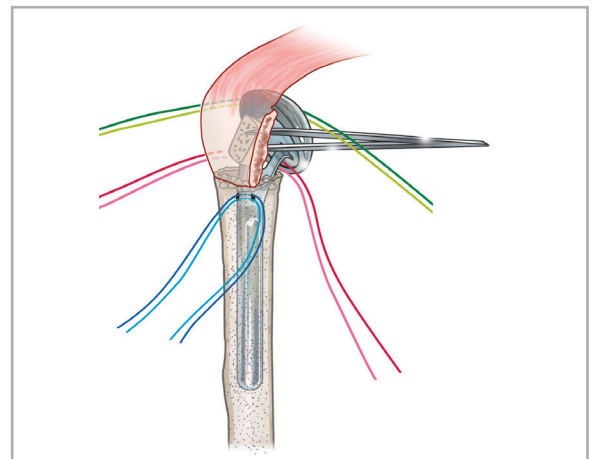
21. Placement of four horizontal sutures around the prosthetic neck

Reconstruction begins with the greater tuberosity and employs two of the four horizontal sutures placed earlier. Passing these sutures through the prosthetic fin does not provide enough stability for the fixation of the tuberosities.

Therefore, it is recommended that the sutures are passed medially around the prosthetic neck.



22. Positioning of the bone graft on the flat lateral base of the neck

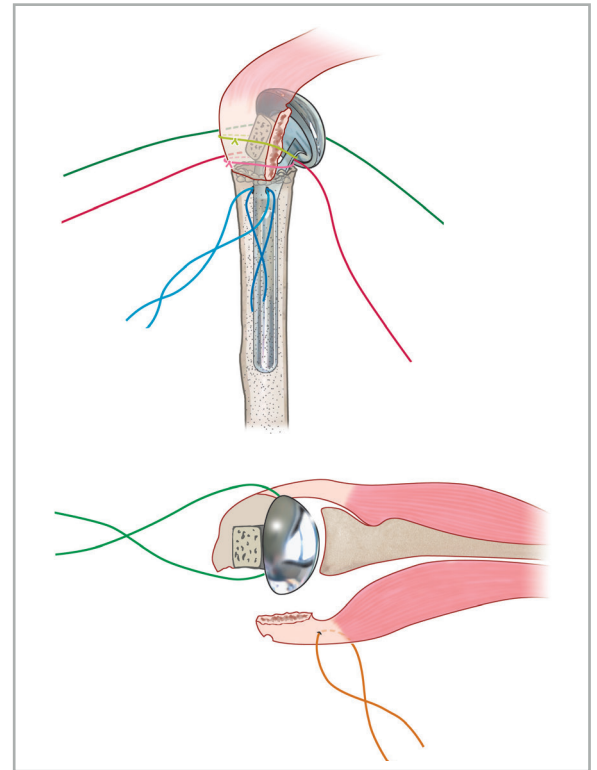


1. Operative technique (continued)

23. Placing two horizontal cerclage sutures around the greater tuberosity

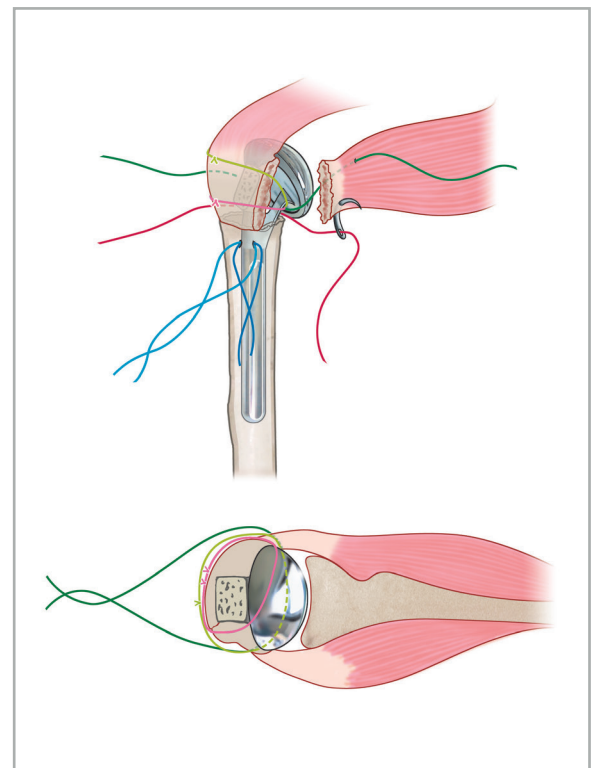
Fixation of the greater tuberosity begins with two horizontal cerclage sutures to anatomically position the tuberosity.

The arm is placed in neutral position. A clamp is used to pull the greater tuberosity anteriorly, reducing the greater tuberosity to the prosthesis. The two horizontal cerclage sutures (one superior, one inferior) are then tied to secure the greater tuberosity to the prosthesis.



24. Placing two horizontal cerclage sutures around both tuberosities

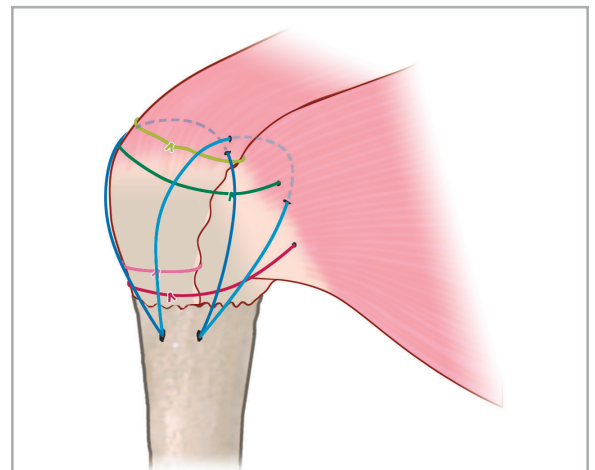
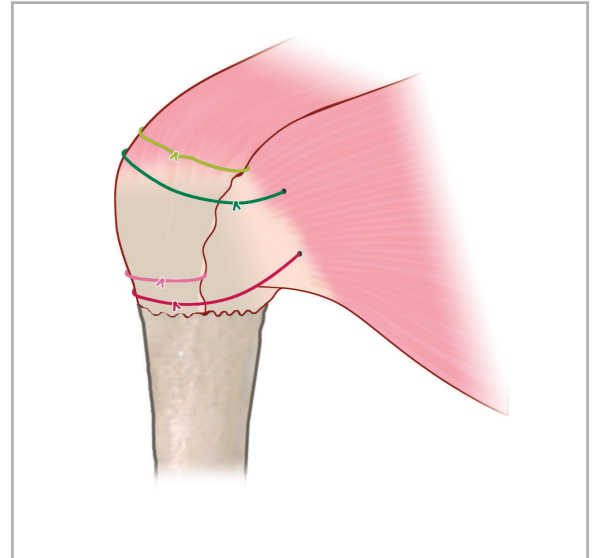
The next step is the reconstruction of the lesser tuberosity, which also uses two of the four horizontal sutures. The two remaining horizontal sutures, which have initially been passed around the greater tuberosity, and the prosthetic neck are then passed through the subscapularis tendon from inside to outside. This maneuver pulls the lesser tuberosity into position under the prosthetic head.



1. Operative technique (continued)

25. Adding vertical tension band sutures on both tuberosities

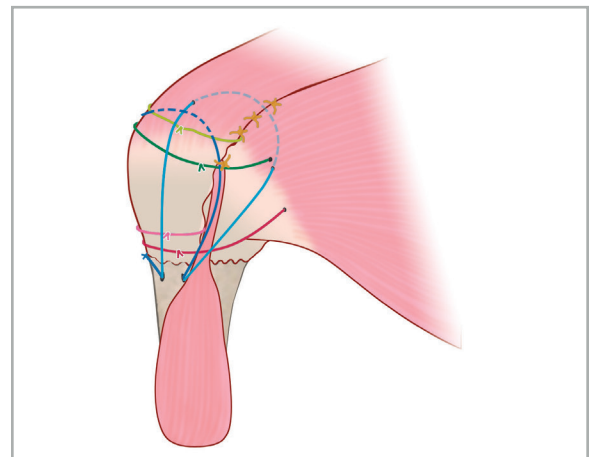
The final tightening is performed in the vertical plane using the two nonabsorbable sutures from the diaphysis in a tension-band technique. One suture is passed anteriorly through the subscapularis and the supraspinatus tendons, while the other suture is passed posteriorly through the infraspinatus and supraspinatus tendons. This provides the all-important fixation of the tuberosity fragments to the humeral shaft.



26. Closing and tenodesis of the long head of the biceps

Biceps tenodesis

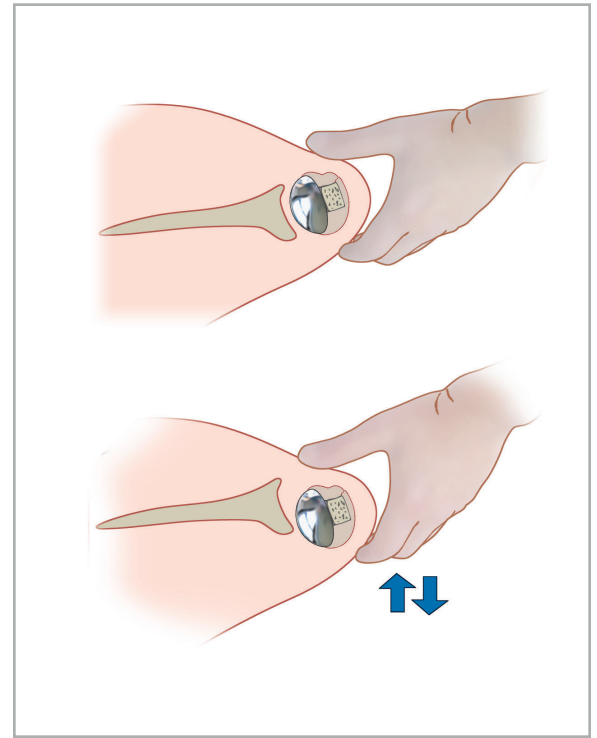
After resecting the intra-articular portion of the long head of the biceps, a nonabsorbable suture is passed through its free end using a modified Kessler stitch. The tendon is relocated in the bicipital groove with one end of the suture passed through the supraspinatus tendon. The suture is then tied.



1. Operative technique (continued)

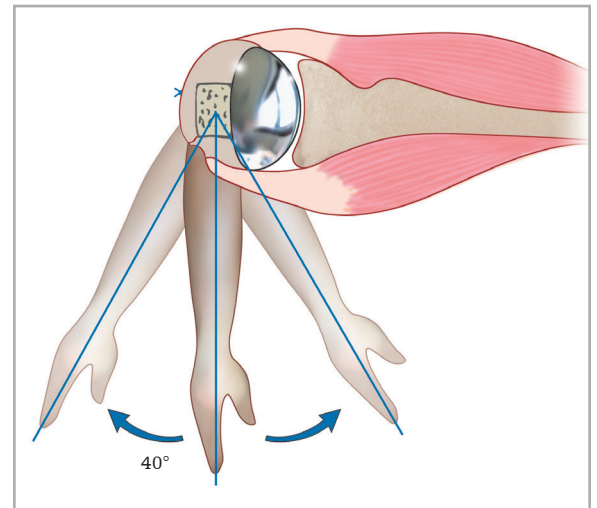
27. Evaluation of the prosthetic stability and mobility

With the arm in neutral position, it is recommended to have a posterior translation of approximately 25% to 50% with an automatic rebound.



A minimum external rotation of 40° is recommended.

The greater tuberosity should not move as the arm is internally rotated.



28. Final closing and immobilization of the arm in abduction and neutral rotation.

2. Postoperative rehabilitation

Postoperative rehabilitation is as equally important after shoulder arthroplasty for a fracture case as it is following shoulder arthroplasty for chronic etiologies, contributing at least 50% to the final outcome. Rehabilitation after prosthetic replacement of a 4-part proximal humerus fracture is perhaps the most challenging aspect of shoulder rehabilitation.

In order to avoid complications such as hemarthrosis, hematoma, and prosthetic instability, it is recommended to delay the postoperative rehabilitation until the tuberosities have healed, 45 to 60 days postoperatively.

Because of frequent tuberosity fixation failure previously observed, the aggressiveness of postoperative rehabilitation has been reduced to avoid these potentially catastrophic complications. Early passive motion is not recommended because it is easier to treat a stiff shoulder than a tuberosity migration or nonunion.

The patient's arm is immobilized in 45° abduction and neutral rotation for a period of 4 to 6 weeks. During the first 3 postoperative weeks, active mobility of the hand, fingers and elbow is allowed without any movement of the shoulder joint.

In the fourth postoperative week, after ensuring the tuberosities have remained in place radiographically, passive abduction of the arm is permitted starting from a resting position of 45 degrees abduction. No rotation is allowed at this time as this could cause suture failure before the tuberosities have healed.

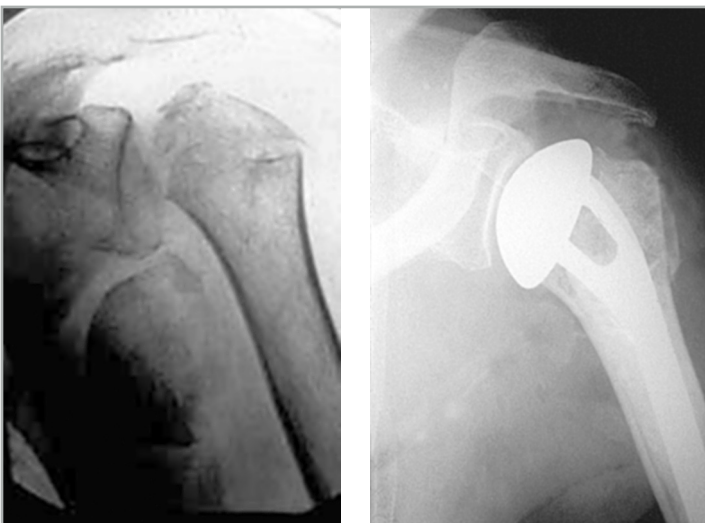
At 6 weeks postoperative, passive rehabilitation is initiated emphasizing elevation and rotation. The patient sees a physiotherapist 3 times per week, but the patient, with the assistance of family, carries out therapy exercises at home on days they do not see the therapist. Rehabilitation in a warm water pool is particularly helpful when feasible from the 21st postoperative day.

Once the tuberosities clearly show radiographic healing (2 to 3 months postoperative), active mobility is permitted in elevation and internal rotation. These exercises can be performed by the patient at home many times during the day. Strengthening and resistance exercises are avoided as these can be responsible for pain and have shown no proven benefit.

Experience with this rehabilitation protocol has demonstrated tuberosity migration and nonunion to occur infrequently. Patients must be informed of the risk of postoperative stiffness during the first 6 to 9 postoperative months. This stiffness invariably diminishes, provided the anatomy has been properly re-established. Final mobility is usually obtained by 12 months postoperatively. In summary, rehabilitation following humeral head replacement for fracture focuses on obtaining union of the tuberosities.

The postoperative radiographs show anatomical reconstruction using the Aequalis fracture solution.

Pascal Boileau, MD, and Gilles Walch, MD



The postoperative x-rays show a perfect anatomical reconstruction using the Aequalis fracture solution

3. Aequalis Fracture Shoulder Prosthesis Extra-Long Stems

The operative technique for the Aequalis Fracture X-Long Stem slightly differs from the standard Aequalis Fracture Stem procedure.

Some steps of the standard surgical protocol have been modified. To ensure correct implantation of this x-long stem, please follow the directions below regarding paragraphs 8, 9, 16, 17, 18 and 19 of the standard Aequalis Fracture Stem surgical procedure.

8. Humeral reaming (page 7)

With the arm placed in abduction, external rotation, and extension, the humerus is progressively reamed, using cylindrical reamers of increasing diameter (6.5mm, 9mm, and 12mm).

The reamer should be inserted carefully, until the scribed line for “long” on the smooth section of the reamer is buried approximately 3cm into the bone.

At this stage, it is also important to remove as much of the residual cement as possible because it might compromise healing tuberosities.

The remainder is exactly the same as the standard Aequalis Fracture operative technique.

9. Choice of trial prosthesis (page 8)

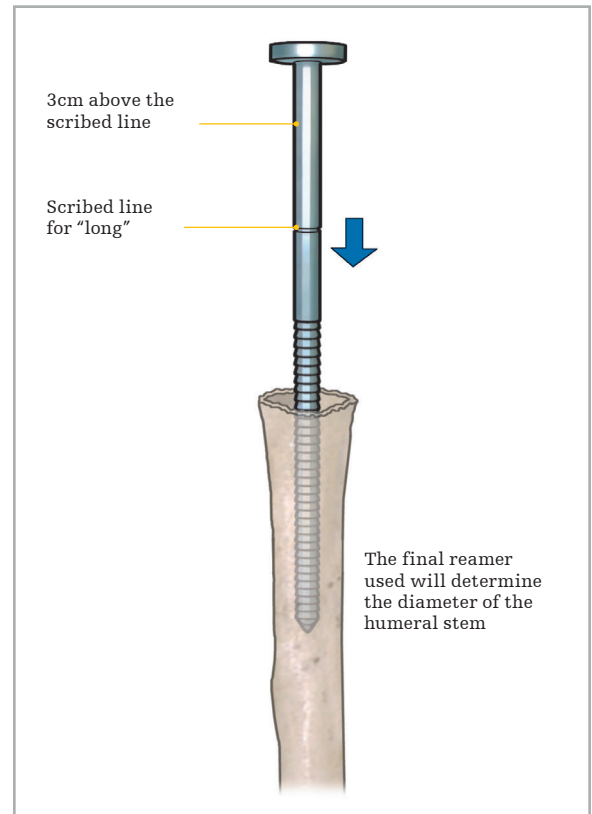
Trial humeral stems (shorter than the final stem) are included in the instrument set (YKAD50) for the Aequalis Fracture X-Long Stems.

For head/trial stem assembly, and attachment of the trial prosthesis to the fracture jig prosthesis holder, use the standard technique.

16. Assembling the implant (page 12)

The assembly of the definitive implant is made on a specific impaction support for the long Aequalis Fracture Stems available in the YKAD50 instrument set. For correct assembly of the implant, the support should be moved to the edge of the table so that the stem can hang off the table.

The remainder is exactly the same as the standard Aequalis Fracture operative technique.



3. Aequalis Fracture Shoulder Prosthesis Extra-Long Stems (continued)

17. Cementing the implant (page 13)

After placement of a cement restrictor, **10mm under the extremity of the prosthesis**, the canal is dried, and cement is injected using a large syringe.

The remainder is exactly the same as the standard Aequalis Fracture operative technique.

18. Removal of excess cement and placing the cancellous bone graft (page 13)

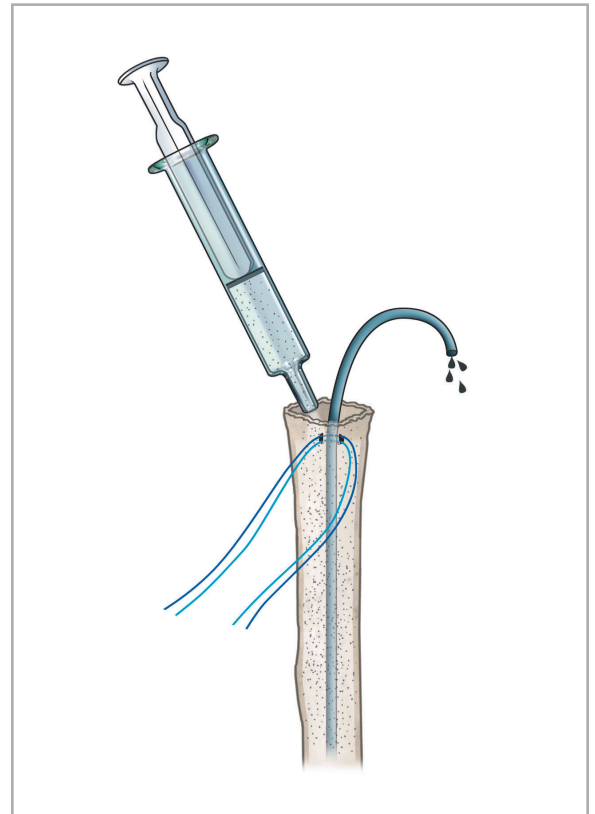
Remove any excess cement from the humeral upper shaft and insert bone grafts to promote healing of the tuberosities to the shaft. Bone graft can be taken from the humeral head (if still available), or from other bone graft sources in case of revision.

The remainder is exactly the same as the standard Aequalis Fracture operative technique.

19. Removal of two cancellous bone grafts with the bone graft cutter (page 14)

Bone grafting is highly recommended to improve tuberosity healing. The bone graft cutter allows two bone grafts shaped according to the fenestration of the prosthesis to be removed from the resected humeral head, when possible, or from the bone graft source. The graft pusher is unscrewed and the humeral head or the other bone graft source is placed in the base of the bone graft cutter. The bone graft cutter handles are firmly tightened to cut the bone graft. In case of exceptionally hard bone, a mallet can be used to impact the clamp. The positioning of the two bone grafts is described in paragraphs 20 and 22 of the standard operative technique.

The remainder is exactly the same as the standard Aequalis Fracture operative technique.



3. Aequalis Fracture Shoulder Prosthesis Extra-Long Stems (continued)

Postoperative rehabilitation (page 19)

The postoperative rehabilitation protocol is identical to the one described in the standard Aequalis Fracture operative technique. However, it is recommended to wait for the radiographic bone healing of all the bony fragments prior to the start of the passive motion rehabilitation procedure.

Except for the above specifications, all other steps of the operative technique and the use of the instrumentation are unchanged, and strictly identical to the Aequalis Fracture literature enclosed with this document.

Instruments

In addition to the basic Aequalis Fracture Instrument Set, a specific tray for extra-long stem (YKAD50) should be used.

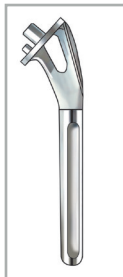Basic instrumentation

YKAD08-09 + YKAD01 + YKAD33 or YKAD30 + YKAD01

Ref. YKAD50

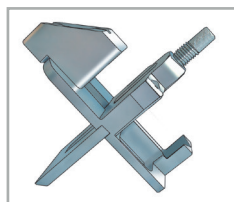
Long trial stems

Size ref.	Ref.
6.5mm / L 170mm	MWA320
9mm / L 180mm	MWA321
12mm / L 180mm	MWA322



Impaction support


Ref. MWA325



4. Assembly instructions: left arm

For assembly on an instrument table.

The yellow items are on the outside of the operative arm.



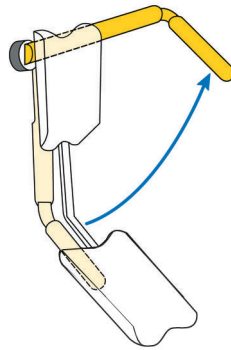
1 Preparation of arm support

What you need

- Arm support

What you do

- Pivot the angle joint horizontally.



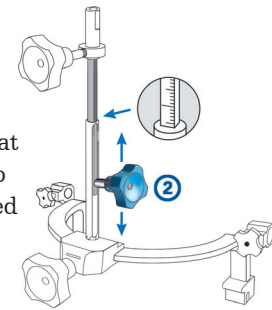
4 Attachment of ruler

What you need

- Graduated ruler
- Blue handle n° 2

What you do

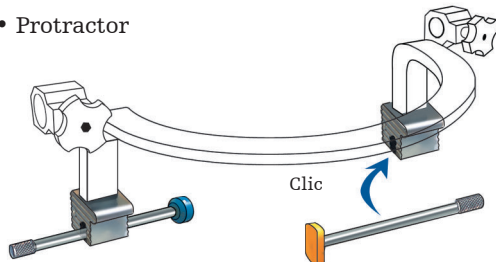
- The definitive height is that of the healthy humerus. To slide the ruler to the desired measurement, loosen the blue knob n° 2 and then tighten.



2 Attachment of epicondylar pads

What you need

- Rectangular yellow feeler (lateral epicondyle)
- Round blue feeler (medial epicondyle)
- Protractor



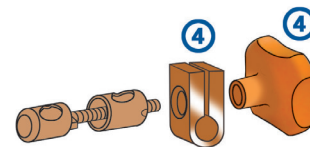
5 Attachment of handle n° 4

What you need

- Yellow male part
- Yellow female part
- Yellow ring n° 4
- Yellow handle n° 4

What you do

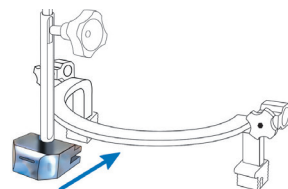
- Leave the unit untightened to allow assembly 6.



3 Attachment of slide

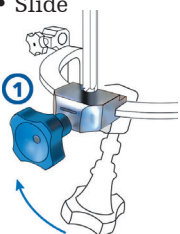
What you need

- Protractor
- Blue handle n° 1
- Slide



What you do

- Place slide on 20° (side marker "retroversion left arm").
- To alter the retroversion loosen blue knob n° 1, slide and then tighten.



6 Attachment of swivel joint to small angle joint

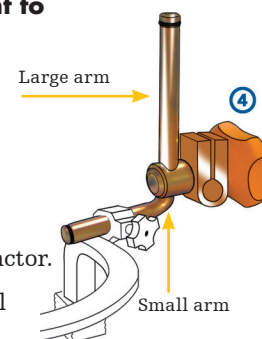
What you need

- Small angle joint
- Articulated swivel joint

What you do

- Attach angle joint to protractor.
- Loosen knob n° 4 and small thumbwheel to allow free assembly.

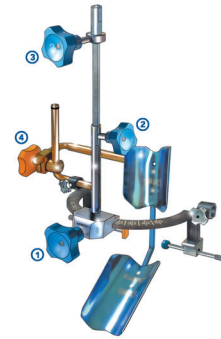
Parts used later: 1 right prosthesis holder - knob n° 3.

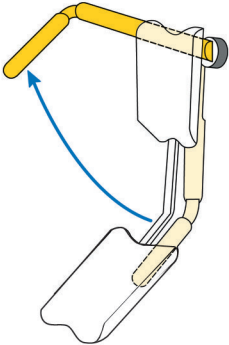
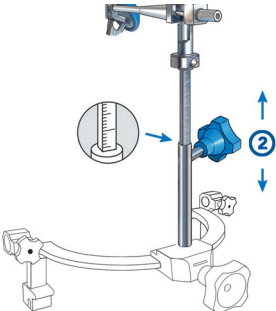
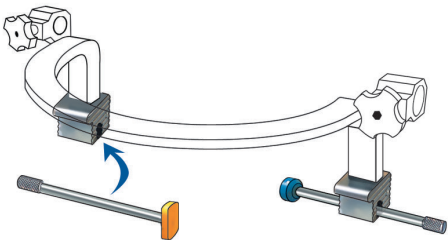
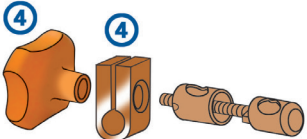
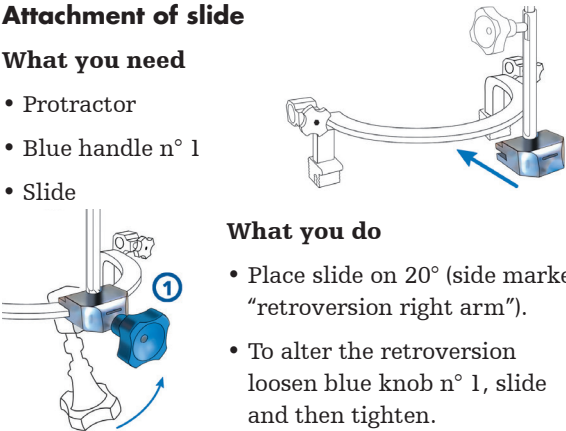
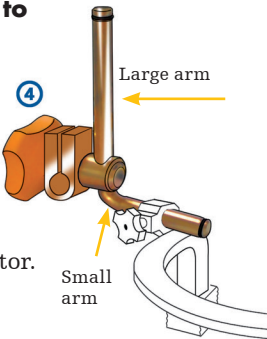


4. Assembly instructions: right arm

For assembly on an instrument table.

The yellow items are on the outside of the operative arm.




<p>1 Preparation of arm support</p> <p>What you need</p> <ul style="list-style-type: none"> • Arm support <p>What you do</p> <ul style="list-style-type: none"> • Pivot the angle joint horizontally. 	<p>4 Attachment of ruler</p> <p>What you need</p> <ul style="list-style-type: none"> • Graduated ruler • Blue handle n° 2 <p>What you do</p> <ul style="list-style-type: none"> • The definitive height is that of the healthy humerus. To slide the ruler to the desired measurement, loosen the blue knob n° 2 and then tighten. 
<p>2 Attachment of epicondylar pads</p> <p>What you need</p> <ul style="list-style-type: none"> • Rectangular yellow feeler (lateral epicondyle) • Round blue feeler (medial epicondyle) • Protractor 	<p>5 Attachment of handle n° 4</p> <p>What you need</p> <ul style="list-style-type: none"> • Yellow male part • Yellow female part • Yellow ring n° 4 • Yellow handle n° 4 <p>What you do</p> <ul style="list-style-type: none"> • Leave the unit untightened to allow assembly 6. 
<p>3 Attachment of slide</p> <p>What you need</p> <ul style="list-style-type: none"> • Protractor • Blue handle n° 1 • Slide  <p>What you do</p> <ul style="list-style-type: none"> • Place slide on 20° (side marker "retroversion right arm"). • To alter the retroversion loosen blue knob n° 1, slide and then tighten. 	<p>6 Attachment of swivel joint to small angle joint</p> <p>What you need</p> <ul style="list-style-type: none"> • Small angle joint • Articulated swivel joint <p>What you do</p> <ul style="list-style-type: none"> • Attach angle joint to protractor. • Loosen knob n° 4 and small thumbwheel to allow free assembly. <p>Parts used later: 1 right prosthesis holder - knob n° 3.</p> 

Instruments


Cylindrical reamers

6.5mm	Ref. MWA607
9mm	Ref. MWA609
12mm	Ref. MWA612



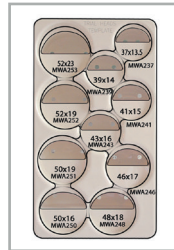
Hexagonal screwdriver 3.5 mm

Ref. MWA124




Trial head template

Ref. MWA162



Trial head

39mm x 14mm	Ref. MWA239
41mm x 15mm	Ref. MWA241
43mm x 16mm	Ref. MWA243
46mm x 17mm	Ref. MWA246
48mm x 18mm	Ref. MWA248
50mm x 16mm	Ref. MWA250
50mm x 19mm	Ref. MWA251



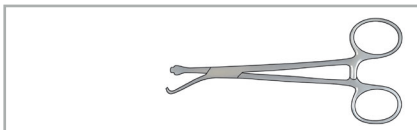
Cement restrictor inserter

Ref. MBO101



Trial head clamp

Ref. MWA103



T handle

Ref. MWA106



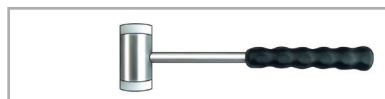
Humeral prosthesis impactor

Ref. MWA108



Mallet

Ref. MWA122



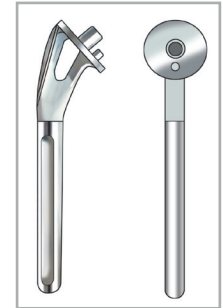
Hexagonal screwdriver 4.5 mm

Ref. MWB012



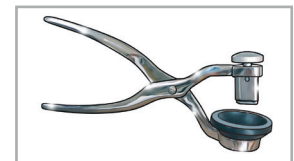
Trial stem

6.5mm	Ref. MWA308
9mm	Ref. MWA309
12mm	Ref. MWA310



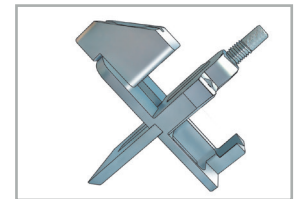
Bone graft cutter

Ref. MWA301




Impaction support

Ref. MWA302



Fracture jig



Implants

Trial head

Size	Ref.
37mm x 13.5mm	DWB237
39mm x 14mm	DWB239
41mm x 15mm	DWB241
43mm x 16mm	DWB243
46mm x 17mm	DWB246
48mm x 18mm	DWB248
50mm x 16mm	DWB250
50mm x 19mm	DWB251
52mm x 19mm	DWB252
52mm x 23mm	DWB253



Extended sizes head

Size	Ref.
54mm x 23mm	DWB254*
54mm x 27mm	DWB255*

*Available upon special request

Humeral stems HA coated

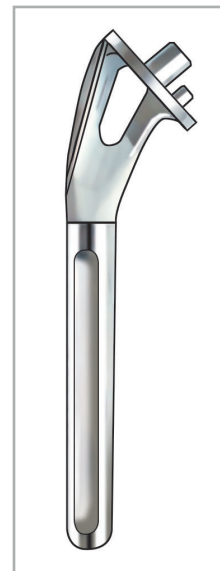Size	Ref.
6.5mm / L 130mm	DWB171
9mm / L 130mm	DWB172
12mm / L 130mm	DWB173

Humeral long stems HA coated

Size	Ref.
6.5mm / L 170mm	DWB161*
9mm / L 180mm	DWB162*
12mm / L 180mm	DWB163*

Humeral extra-long stems HA coated

Size	Ref.
9mm / L 210mm	DWB165*
12mm / L 210mm	DWB166*



This document is intended solely for the use of healthcare professionals. A surgeon must always rely on his or her own professional clinical judgment when deciding whether to use a particular product when treating a particular patient. Stryker does not dispense medical advice and recommends that surgeons be trained in the use of any particular product before using it in surgery.

The information presented is intended to demonstrate a Stryker product. A surgeon must always refer to the package insert, product label and/or instructions for use, including the instructions for cleaning and sterilization (if applicable), before using any Stryker product. Products may not be available in all markets because product availability is subject to the regulatory and/or medical practices in individual markets. Please contact your Stryker representative if you have questions about the availability of Stryker products in your area.

The instructions for use, operative techniques, cleaning instructions, patient information leaflets and other associated labeling may be requested online at ifu.stryker.com or wright.com. If saving the instructions for use, operative techniques, cleaning instructions from the above mentioned websites, please make sure you always have the most up to date version prior to use.

Stryker Corporation or its divisions or other corporate affiliated entities own, use or have applied for the following trademarks or service marks: Aequalis, Stryker, Tornier. All other trademarks are trademarks of their respective owners or holders.

Content ID: AP-015523A 29-Sep-2021

Copyright © 2021 Stryker

Manufacturer:

Tornier SAS
161 Rue Lavoisier
38330 Montbonnot Saint Martin
France
t: +33 (0)4 76 61 35 00
stryker.com