

Purpose and Instructions for the Interdisciplinary Lower Leg Assessment Form

Purpose

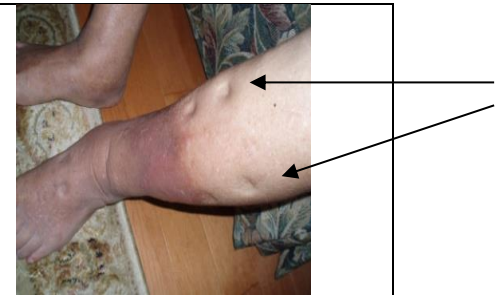
The Interdisciplinary Lower Leg Assessment Tool, developed by members of the SWRWCP, is an assessment tool to be used for individuals with wounds or swelling of their legs. The form is intended:

- To be utilized by health care professionals when assessing an individual with a leg ulcer/edema
- To be completed at the point of entry to the health care system for individuals with a leg wound/edema or when a wound/edema is identified in an individual already within the system
- To be completed by a generalist health care provider, such as an RN, RPN, etc., or by a Wound Care Specialist or ET Nurse if they are the first person to assess the wound/edema at the time of admission into the health care system
- To follow the individual as they move through the health care system, providing all subsequent health care providers access to the initial information



Instructions

- **Demographics:** Before beginning the Tool, ensure that the individual's name, ID number (or identifying number), and date are added to every page (the top of the first page and the header space of the subsequent pages).
- **Edema:** Indicate the date of onset of the edema of each leg and note if the edema is asymmetrical by ticking the appropriate box. Indicate the location of the edema by checking the appropriate box and describe the edema using the following guidelines:

Pitting edema can be demonstrated by applying pressure to the swollen area by depressing the skin with a finger x 10 – 15 seconds. If the pressing causes an indentation that persists for some time after the release of the pressure, the edema is referred to as pitting edema. It is graded based on the depth of the indentation:
 1+ = 0 - ¼" **2+** = ¼" – ½" **3+** = ½ - 1" **4+** = takes several minutes to rebound






South West Regional Wound Care Program

| | |
|--|---|
| <input type="checkbox"/> In non-pitting edema , pressure that is applied to the skin does not result in a persistent indentation. Non-pitting edema can occur in certain disorders of the lymphatic system such as lymphedema, where edema is particularly prominent on the dorsum of the feet and in the toes. |  |
| <input type="checkbox"/> Brawny Induration - Brawny means swollen and hardened, while induration is abnormal firmness of tissues with margins. Palpate where it starts and stops. Induration results in an inability to pinch the tissues. |  |

For edema measurements, using a measuring tape, measure the midfoot, and then the lower leg in increments of 10cm. I.e. with your tape measure at the base of the person's foot, measure up the person's leg 10cm and take a circumferential measure. With your tape measure at the base of the person's foot, measure up the person's leg 20cm and take a circumferential measure, etc. until you have measured the entire lower leg and upper leg, if edema exists there as well. Further, check the appropriate boxes indicating whether or not the person has previously used compression stockings, if they were adherent to using them, and the age of their current stockings.

- **Lymphedema Assessment¹**: Read the descriptors present in the tool and check off all descriptors that apply.
- **Lipedema Assessment**: Read the descriptors present in the tool and check off all descriptors that apply.
- **Skin and Anatomy²⁻⁵**: Review the various signs/symptoms of venous and arterial disease listed and check those present in each leg using the following descriptors:

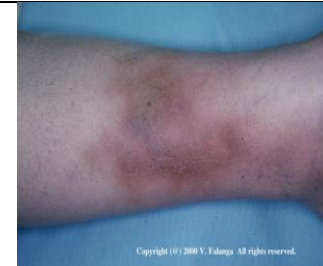Signs/Symptoms of Venous Disease

| Descriptors | Examples |
|--|--|
| <input type="checkbox"/> Varicosities - either small or larger vessels. |  |
| <input type="checkbox"/> Hemosiderin staining - Brown or brownish red pigmentation and purpura caused by extravasation of red blood cells into the dermis. |  |
| <input type="checkbox"/> Chronic Lipodermatosclerosis - lower 1/3 of leg becomes sclerotic and woody. Leg becomes champagne bottle or bowling-pin shaped – ulcers are more difficult to heal. |  |

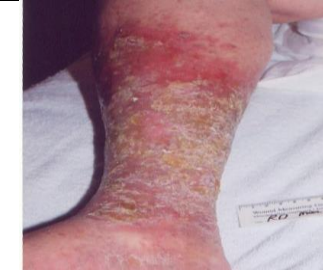South West Regional Wound Care Program

Acute lipodermatosclerosis- This presents as a painful and tender condition of the leg. It is frequently misdiagnosed as cellulitis or morphea. It represents a panniculitis associated with venous insufficiency. Ulcers can occur within the lesion, which becomes intensely fibrotic over time.

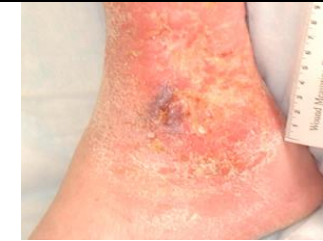Photograph used with permission of Dr. V. Falanga.



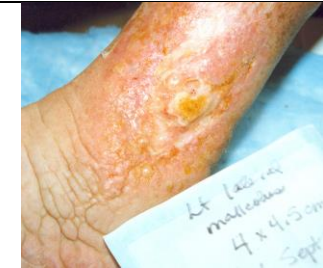Stasis or venous dermatitis - erythema, scaling, pruritus, and sometimes weeping- may develop cellulitis through breaks in the skin.



Atrophie blanche - Located on the ankle or foot, ivory white lesions, atrophic plaques. Ulcerations tend to be exquisitely painful. The white lesions represent scarring from previous injuries.

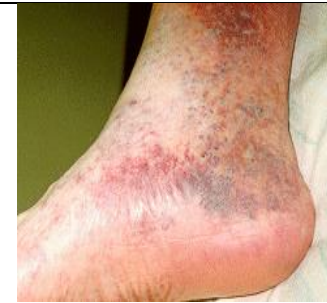

Woody fibrosis - deposits of fibrin in the deep dermis and fat results in a woody induration of the gaiter area of the leg

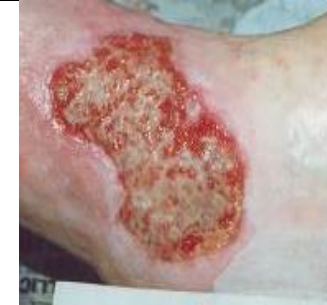

South West Regional Wound Care Program

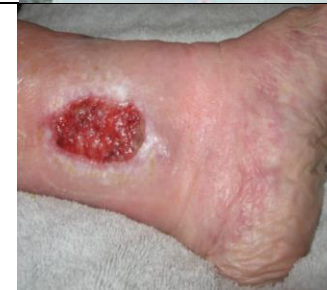Ankle (submalleolar) flare - Incompetence in perforating vein valve which results in venous hypertension and causes dilation of the venules.



Ulcer base moist with granulation &/or yellow slough/ fibrin.

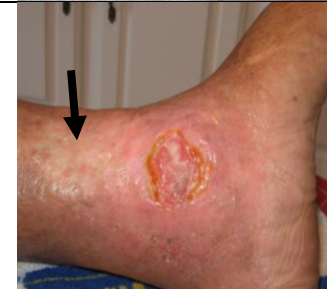

Ulcer located in gaiter region (lower 1/3 of calf) - Ulceration usually on the medial lower leg superior to malleolus but can be on lateral aspect as well. Ulcerations may encircle the entire ankle; ulcers occurring above mid-calf or on the foot likely have other origins.





Ulcer located superior to the medial malleolus




Scarring from previous ulcer(s) - evidence of previous ulcerations noted.



Signs/Symptoms of Arterial Disease

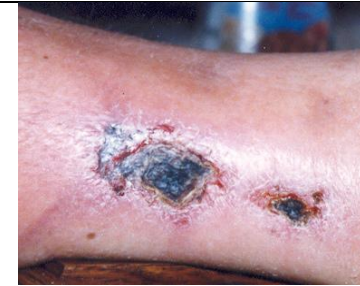| Descriptors | Examples |
|--|---|
| <input type="checkbox"/> Hairless –little or no hair on the lower legs or feet. | No illustration available |
| <input type="checkbox"/> Thin- skin appears thin and fragile and pale in color. | No illustration available |
| <input type="checkbox"/> Shiny skin on legs and feet. | No illustration available |
| <input type="checkbox"/> Dependent rubor – occurs in the presence of arterial compromise and can mimic cellulitis. The rubor disappears when the foot is elevated, which would not happen with cellulitis. It can be bilateral. |  <p>(Gangrene also present)</p> |
| <input type="checkbox"/> Blanching on elevation - occurs in the presence of arterial compromise and represents decrease in arterial flow without the gravitational effect of having the foot below the level of the heart. It can be bilateral. |  <p>(Gangrene also present)</p> |
| <input type="checkbox"/> Feet cool/cold/blue —this occurs in the presence of arterial disease, often just involving one leg or foot in comparison to the other. | No illustration available |

South West Regional Wound Care Program

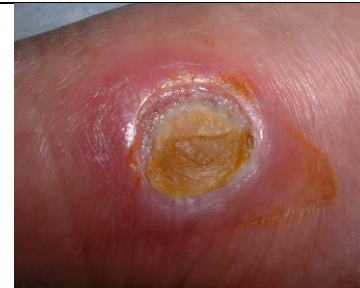| | |
|--|---|
| <p><input type="checkbox"/> Toes cool/cold/blue- in this photograph, the 4th toe is becoming ischemic secondary to infection.</p> |  |
| <p><input type="checkbox"/> Lower temperature in one leg compared to other—one leg feels cooler than the corresponding area on the other leg – this generally suggests the presence of PAD in the cooler leg, but can also be from increased temperature in a leg with infection or cellulitis.</p> | <p>No illustration available</p> |
| <p><input type="checkbox"/> Capillary refill time: > 3 seconds Delayed capillary refill time (CFT) is suggestive of peripheral arterial disease. Normal CFT is less than 3 seconds.</p> <p>Photographs used with permission of myfootshop.com.</p> |  |
| <p><input type="checkbox"/> Ulcer located on foot or toes - often on the heels, tips of toes, between the toes where the toes rub against one another or anywhere the bones may protrude and rub against bed sheets, socks or shoes.</p> <p>Definition from : http://my.clevelandclinic.org/heart/disorders/vascular/legfootulcer.aspx</p> |  |

South West Regional Wound Care Program

Ulcer base pale and dry &/or contains eschar – the ulcer may initially have grey or purplish tissue that bleeds very little and will turn to eschar if allowed to dry out.



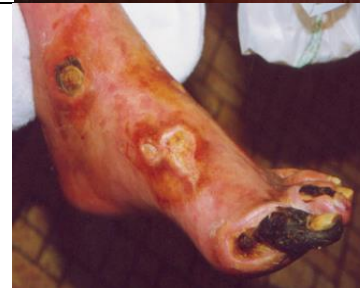Ulcer round and punched out in appearance –arterial ulcers do not usually have irregular edges and the edges do not slope gently down to the wound bed.



Gangrene dry/wet

Dry gangrene (ischemia) may start out red in color and cool to touch, then turn blue or brownish and then becomes black and will desiccate if allowed to dry.



Wet gangrene (infection causing ischemia) starts out with swelling and putrefies, may have foul smelling exudate, fever.



- **Ulcer or Pre-Ulcerous Conditions:** Review the items listed for the right and left leg, and fill in the information/check the appropriate boxes as indicated. Please add the history of previous ulcer(s) and date of onset of the new ulcer(s)/pre-ulcerous condition(s). If there are numerous sites, please list.
- **Unusual Ulcer⁶:** The acronym PULL can be used to describe unusual ulcers:
 - P (purpura)
 - U (undermining border)

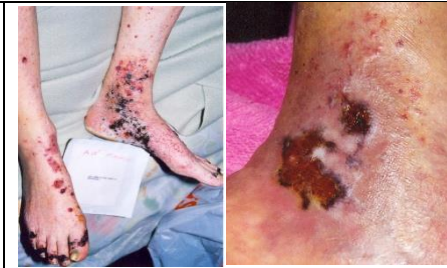- L (Livedo)
- L (Location)

Examples of Unusual Leg Ulcer Appearances

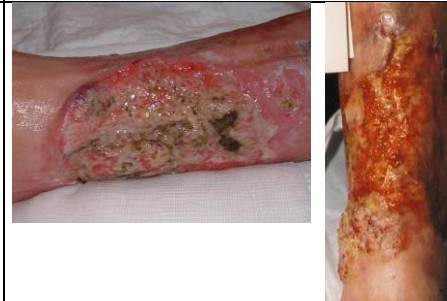| Description | Examples |
|--|--|
| <p>Bullous Pemphigus- Chronic, autoimmune, sub-epidermal, blistering skin disease that rarely involves mucous membranes. If untreated, the disease can persist for months or years, with periods of spontaneous remissions and exacerbations.</p> |  |
| <p>Calciphylaxis- Lesions develop suddenly and progress rapidly; may be singular or many and they usually occur on the lower extremities; however, may also appear on the hands and torso. There is intense pain, which may require pain specialist interventions. Initially they appear as nonspecific violaceous mottling; as a bluish-red discoloration of the skin with a characteristic network pattern (livedo reticularis) or as erythematous papules, plaques, or nodules. As the disease progresses, more developed lesions have a star-like purple colored configuration with central skin necrosis. Less commonly, lesions may manifest as either bullae or distinct erythematous nodules.</p> |  <p data-bbox="1486 938 1780 966">Early stage new lesions</p> <p data-bbox="1549 1279 1717 1307">Older lesions</p> |

South West Regional Wound Care Program

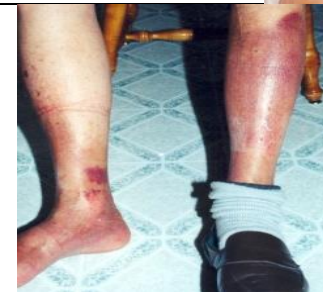Cutaneous Vasculitis- Often seen associated with palpable purpura, and a livid erythematous halo, can appear as nodules, bullae or skin infarction, leading to ulceration which can contain necrotic tissue. These are also highly painful and have multiple sites, with unusual shapes and configurations.



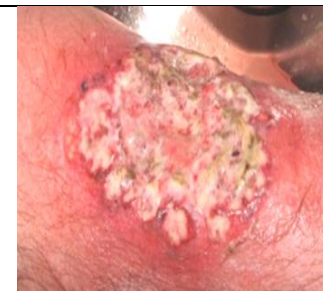Three types of malignant wounds can occur on the legs: Squamous cell carcinoma, basal cell carcinoma, and malignant melanoma. Of these, squamous can occur within a chronic non-healing ulcer (Marjolin's ulcer) or at the margins of a previously grafted site, and appear as raised or thickened edges.



Necrobiosis Lipoidica Diabeticorum -Lesions appear as well-circumscribed, erythematous plaques, with a depressed, waxy yellow atrophic center, often in the pre-tibial area. They can also be described as slightly raised shiny red-brown patches occurring on the lower legs.



Pyoderma Gangrenosum – Lesions are red, tender nodules/ pustules, bluish undermined edges when ulceration occurs; edges may appear “moth-eaten” and can be exquisitely painful.



South West Regional Wound Care Program

- **Leg Pain:** Check off the box that identifies the type of pain the person is experiencing. If pain is uncontrolled use the tick box to indicate that you are requesting or referring to pain specialist to address control.
- **Pulse Assessment:** Palpate the person's dorsalis-pedis and posterior-tibial pulses and indicate by checking the appropriate box, whether the pulses are present, diminished, or absent.
- **ABPI Testing^{7,8}:** To be completed by a wound care specialist, ET Nurse or in a vascular/diagnostic imaging lab.

References:

- 1 International Society of Lymphology (ISL). Lymphoedema Staging (From International Consensus Document Best Practices for the Management of Lymphoedema). Retrieved from: http://www.lympho.org/mod_turbolead/upload/file/Lympho/Best_practice_20_July.pdfInternational Society of Lymphology (ISL)
- 2 Hess CT. Venous ulcer checklist. *Advances in Skin and Wound Care*. 2010;23(8):384.
- 3 Moloney MC, Grace P. Understanding the underlying causes of chronic leg ulceration. *JWC*. 13(6):215-218.
- 4 Coutts et al. RNAO Assessment and Management of Venous Leg Ulcers Guideline supplement. 2007.
- 5 Dissemond J, Körber A, Grabbe S. Differential diagnosis of leg ulcers. *Journal der Deutschen Dermatologischen Gesellschaft*. 2006;4:627-634.
- 6 Patel K, Grey JE, Harding KG. ABC's Of Wound Healing: Uncommon Causes Of Ulceration. *British Medical Journal*. 2006;332(7541):594-596.
- 7 Vowden P, Vowden K. Doppler assessment and ABPI: Interpretation in the management of the leg ulceration. *Worldwide Wounds*. 2001. Available at: <http://www.worldwidewounds.com/2001/march/Vowden/Doppler-assessment-and-ABPI.html>.
- 8 Suzuki K. How to diagnose Peripheral Arterial Disease. *Podiatry Today*. 2007;20(4).