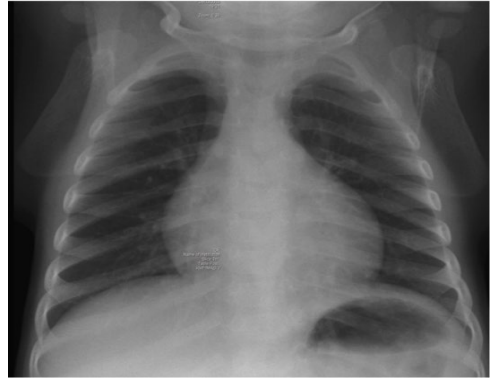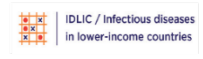


TB-Speed



CHEST X-RAY TRAINING (CXR)

To diagnose childhood Tuberculosis



Pre-Test

Learning objectives

Module 1

1. To recognise both a normal and an unreadable paediatric CXR on a front and lateral view
2. To learn a systematic approach for interpreting paediatric CXRs using a '3 circles' approach

Module 2

3. To recognize CXRs '**Suggestive of TB**' or '**Not suggestive of TB**' using a simplified reading tool that describes 6 CXR features that are 'suggestive TB'

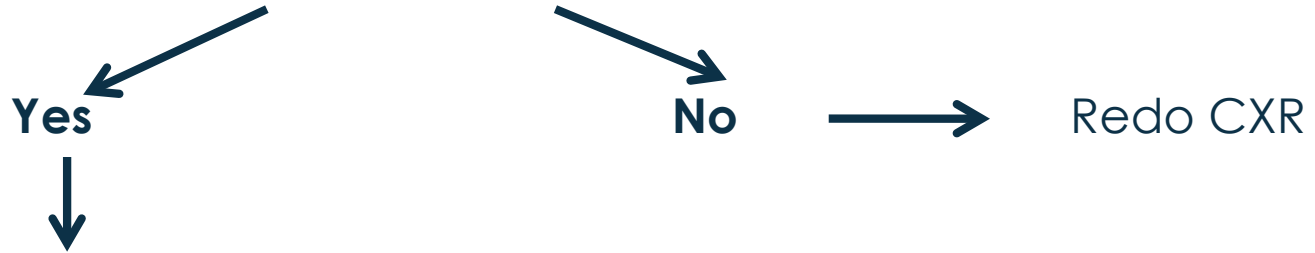
Simplified CXR reading tool

6 CXR features suggestive of paediatric TB

1. Enlarged lymph nodes (lateral view required)
2. Alveolar opacity of the lung tissue
3. Airway compression (may lead to asymmetry between left / right lung)
4. Cavitation
5. Pleural or pericardial effusion
6. Miliary infiltrates

Diagnosis algorithm

Q1. Are both the antero-posterior and the lateral view readable ?



Q2. Is the CXR normal ?



Q3. Is one of the 6 CXR features suggestive of TB present ?

- | | |
|--|--------|
| 1. Enlarged lymph nodes | yes/no |
| 2. Alveolar opacity of the lung tissue | yes/no |
| 3. Airway compression | yes/no |
| 4. Cavitation | yes/no |
| 5. Pleural or pericardial effusion | yes/no |
| 6. Miliary infiltrates | yes/no |

All No: Not suggestive of TB
1 Yes or more: Suggestive of TB

Interactive 1.5-day child CXR course support

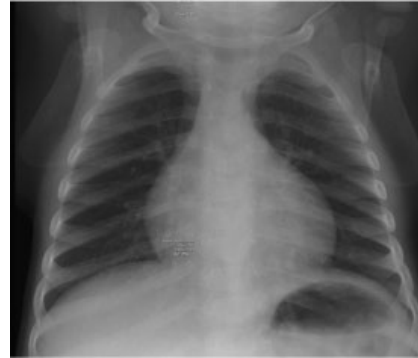Training modules and pre-post training test

Module 1

How to read a child CXR

Ch.1 Technical and anatomical aspects

Ch.2 Systematic approach for CXR interpretation



Module 2

How to diagnose TB on a child CXR with a simplified reading tool

8 chapters

Course summary, paediatric CXR exercise booklets for self training and reference doc



Diakhite's CXR

- . Course summary booklet
- . Paediatric CXR exercises

Agenda

DAY 1

08:00 - 08:30

Paediatric CXR Pre-Test

08:30 - 08:45

Learning objectives

08:45 - 09:15

How to read a *paediatric CXR* using a systematic approach

09:15 - 10:15

❶ Is the CXR readable ? Quality factors : inspiration, rotation, penetration

10:15 - 10:30

Break

10:30 - 12:00

❷ Is the CXR Normal ? 1st , 2nd and 3rd circle – Hidden zones

12:00 - 01:00

Lunch

01:00 - 03:00

❸ Is this TB ? Enlarged lymph nodes, alveolar opacity and differential diagnosis

03:00 - 03:15

Break

03:15 - 04:00

CXR exercises

DAY 2

08:00 - 08:15

Previous day summary

08:15 - 10:15

❹ Is this TB ? Airway compression, TB cavities, pleural or pericardial effusion

Miliary infiltrates and differential diagnosis

10:15 - 10:30

Break

10:30 - 11:00

Key points and TB exercises

11:00 - 11:30

Child post test

11:30 - 12:00

Test corrections and conclusions

Module 1

How to read a child CXR

Chapter 1

Technical and anatomical aspects



Hello, my name is Diakhite

I am going to take you on a journey to explore my lungs

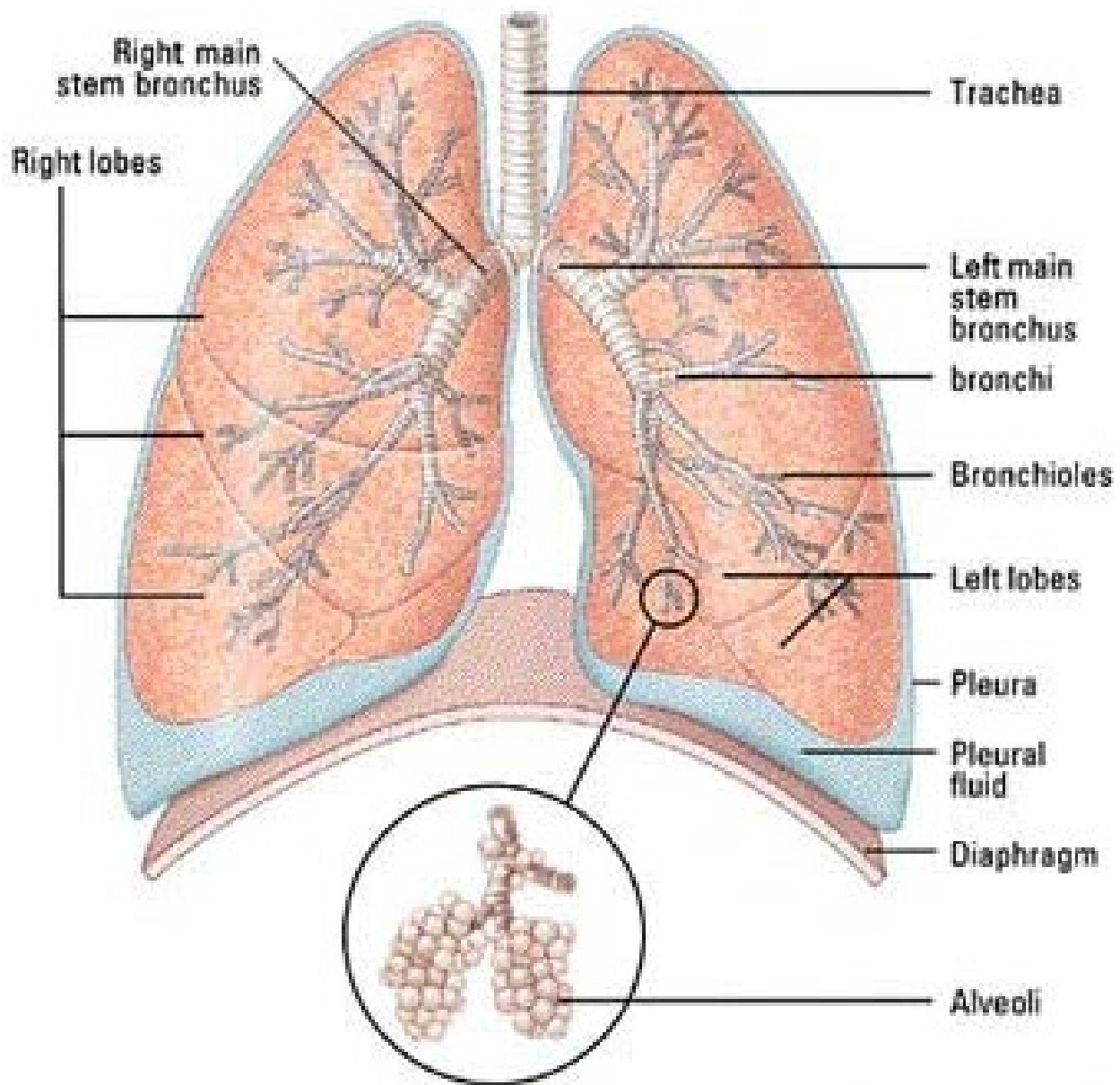
See what they look like on a CXR

Learn how to recognize 6 suggestive signs of child TB

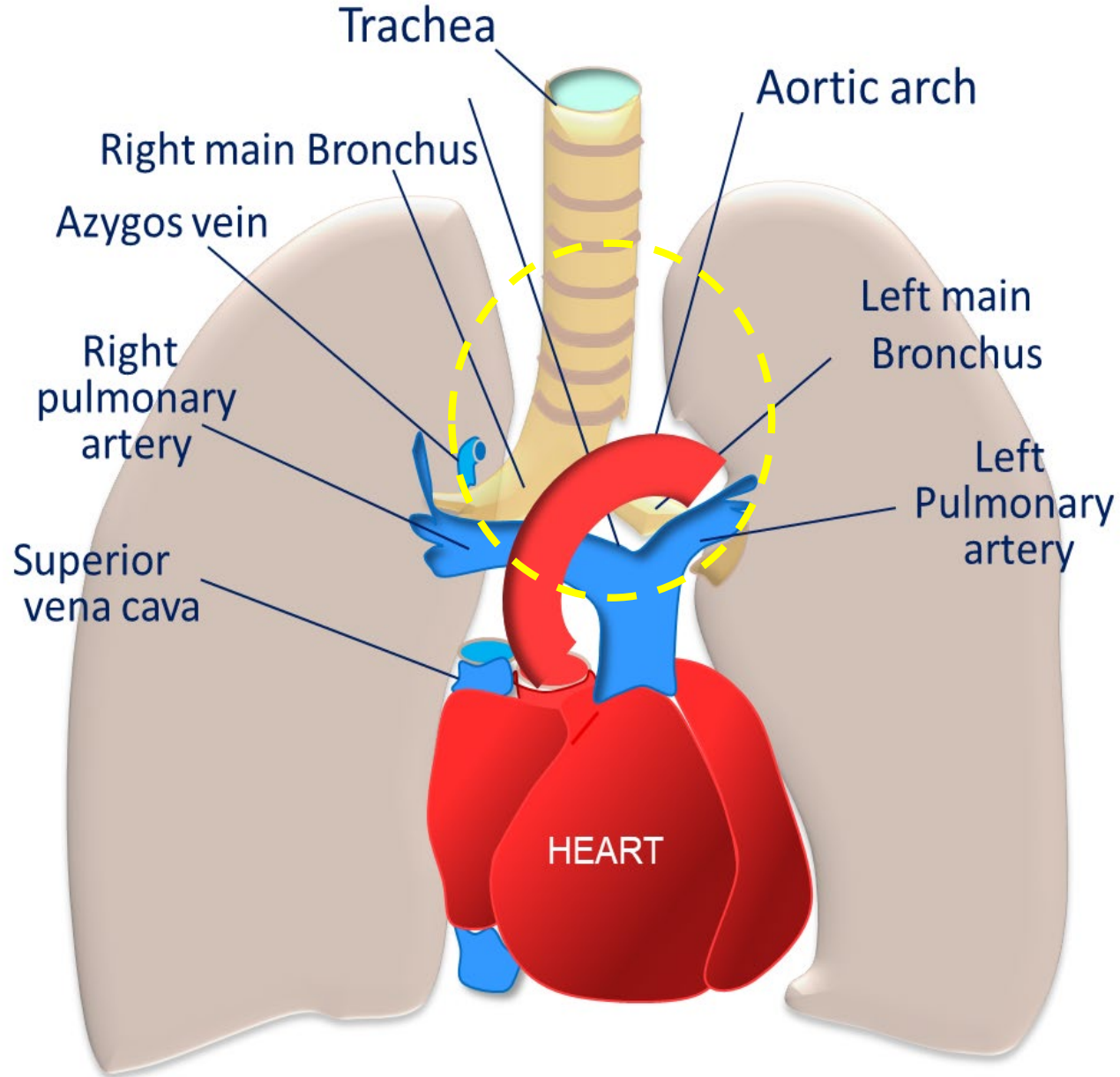


First let me show you
what my lungs look like

Lung anatomy recap

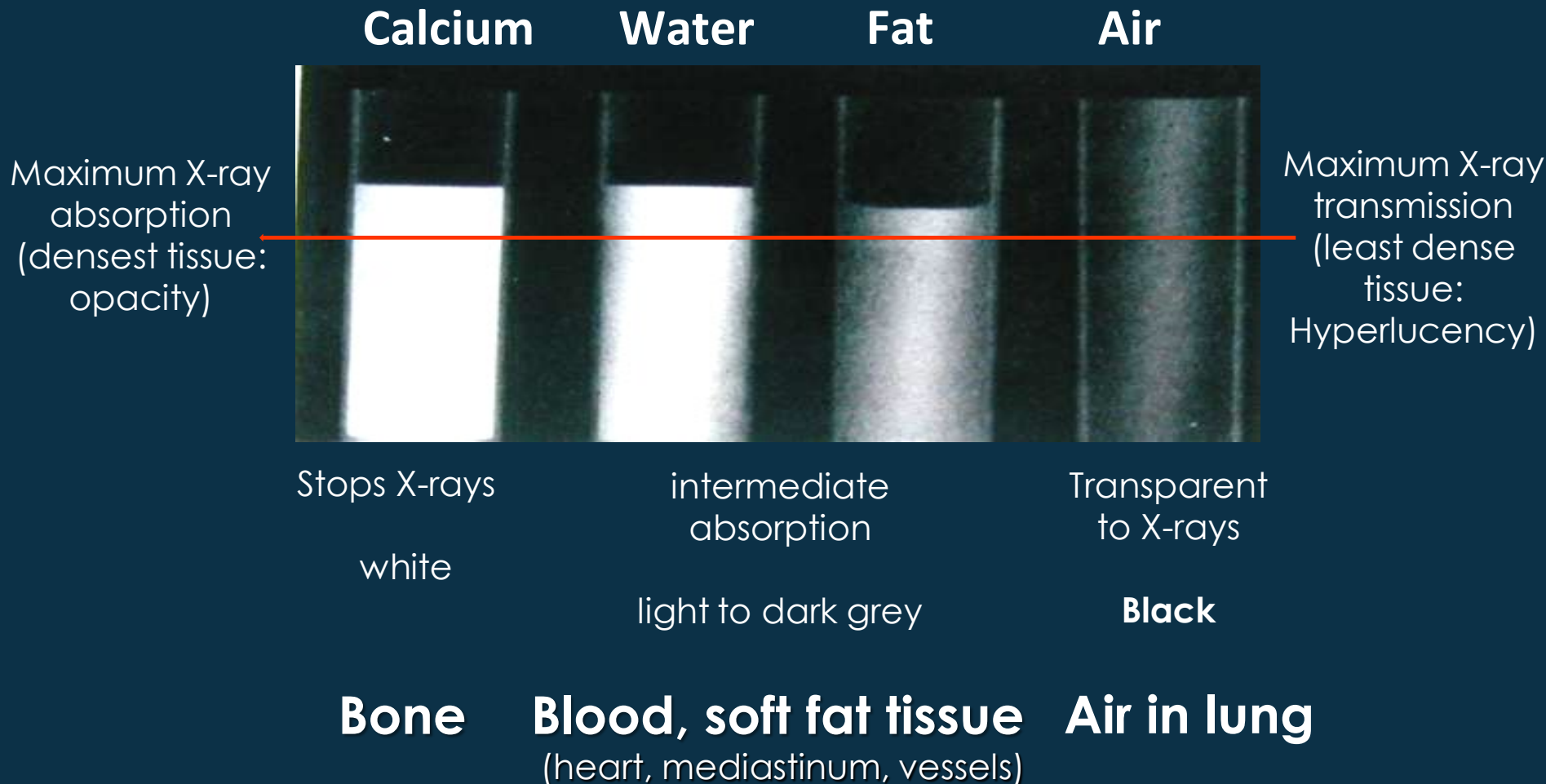


Main anatomical cardio-vascular features

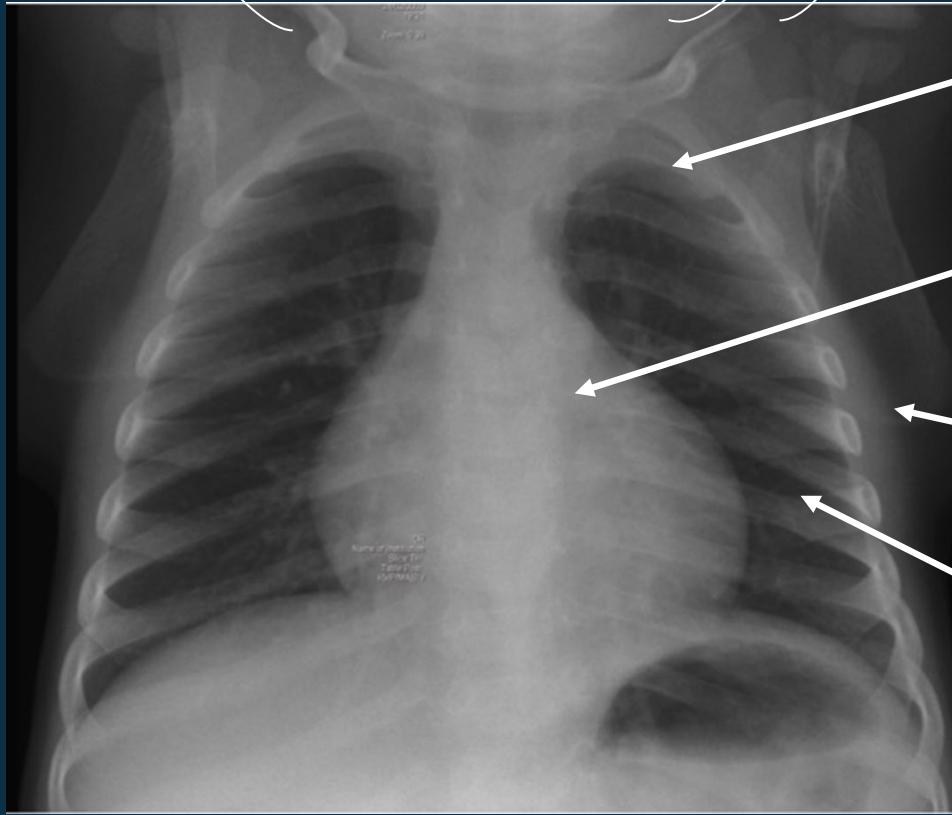


CXR is safe and non invasive X-Ray photon absorption to transmission

X-ray absorption depends on : beam / tissue density



The 4 radiographic densities



Calcium = white opaque

Fluid soft tissue = light grey

Fat = dark grey

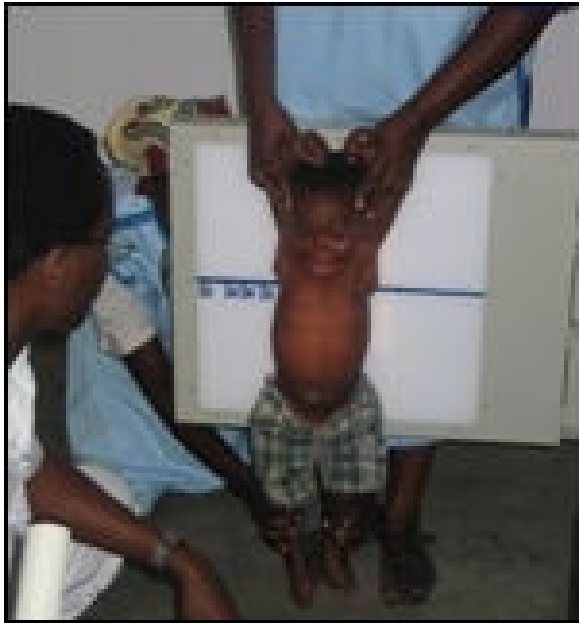Air = black (hyperlucent)



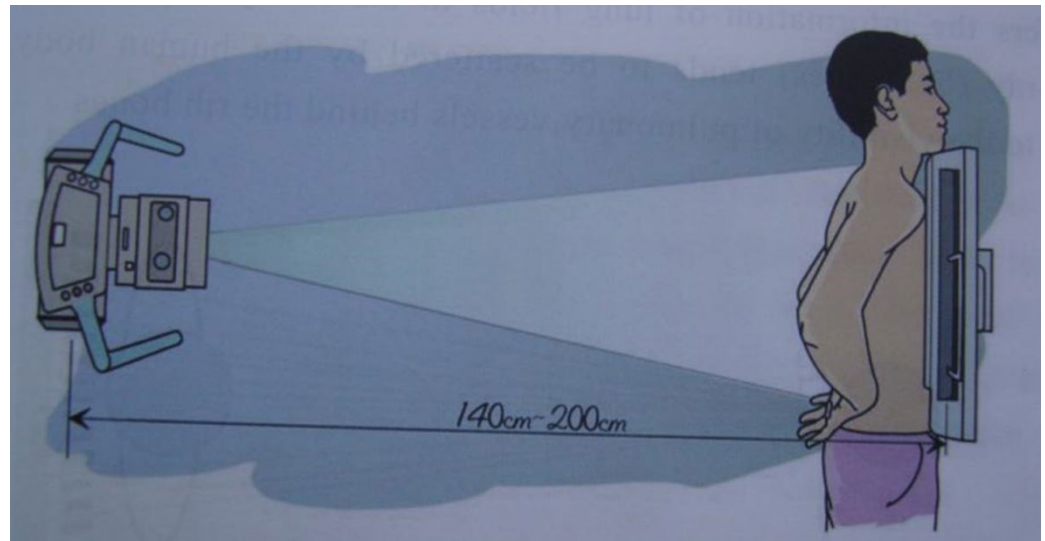
Know which different views to ask for
and some specific appearances

Basic radiographic views:

Front view – Anteroposterior (AP) versus Posteroanterior (PA)



Under 5 years old (AP)



Over 5 years old (PA)

Presumptive TB patients in TB Speed

≤ 5 years

AP and lateral views should be performed

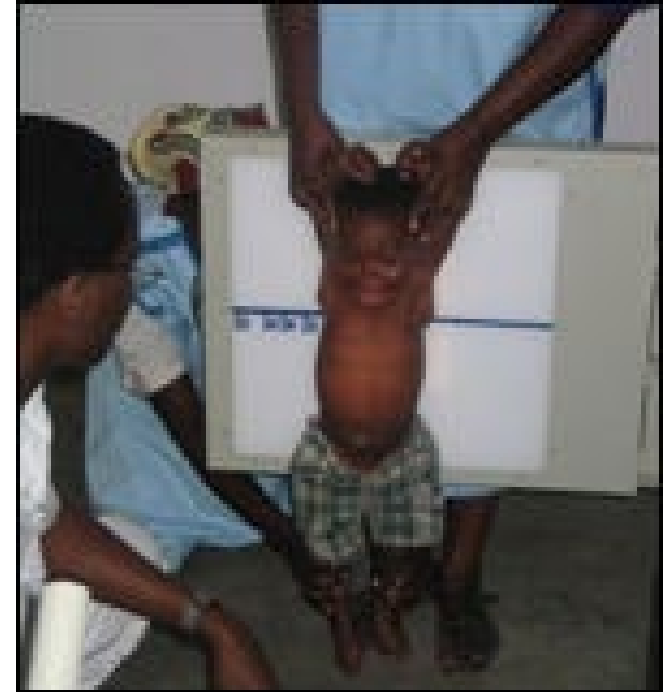> 5 years

PA view should be performed (lateral if needed only)

Front View in < 2 year infant

In children < 2 years old AP radiography is challenging because:

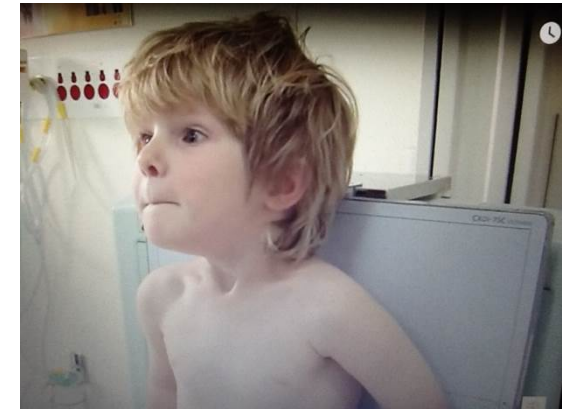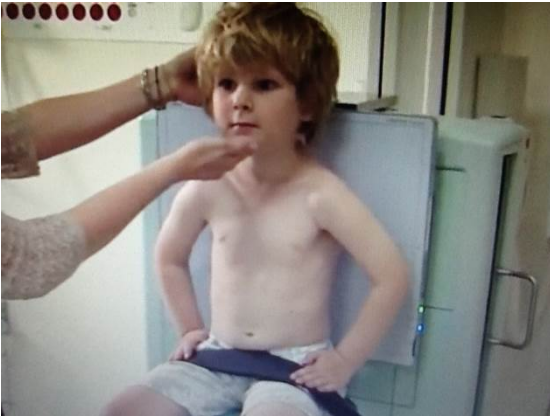- . Children don't keep still
- . Children twist and turn (rotate)
- . Deep inspiration is not always obtained



Supine (laying down) AP position performed at the bedside with a portable X-ray if a child cannot sit up or stand or is critically ill

Front view in > 2 years infant and young children

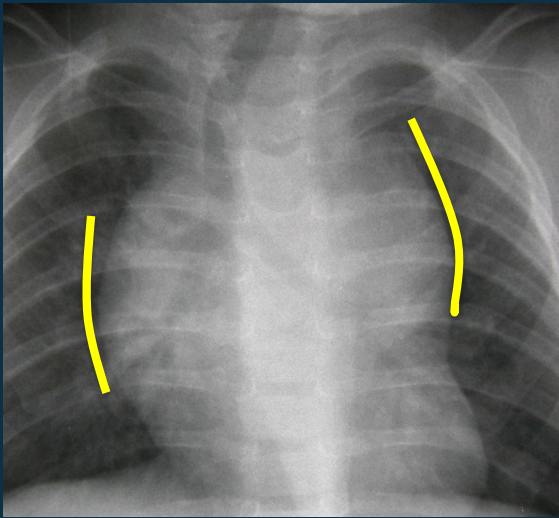
> 2 years: upright (erect) AP position



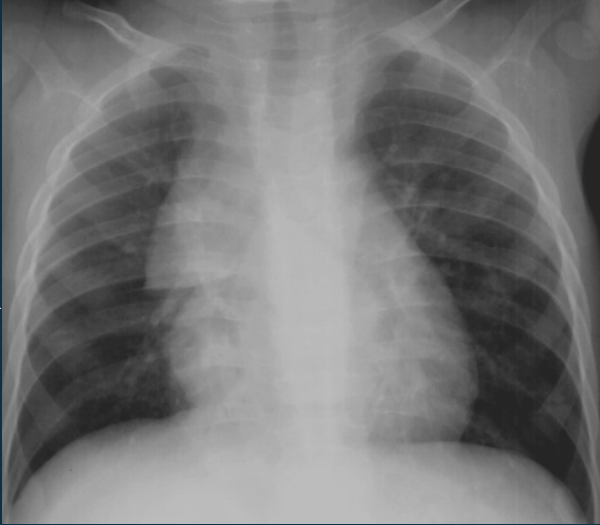
Correct position: take a deep breath and hold it

Sitting position usually used until at least 4 years

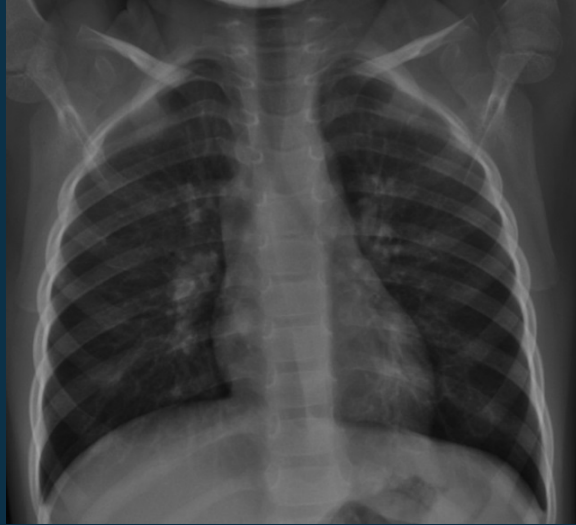Particular aspects according to age: thymus, trachea buckling



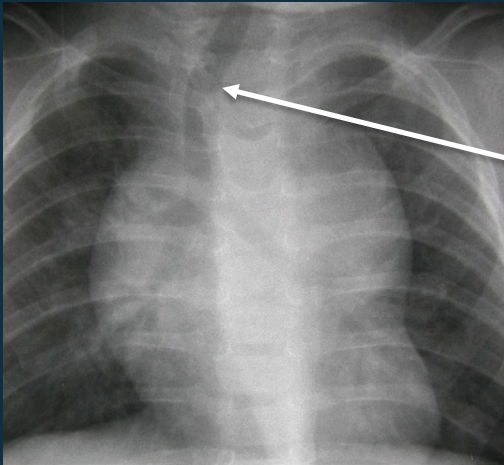
2 month old



7 month old

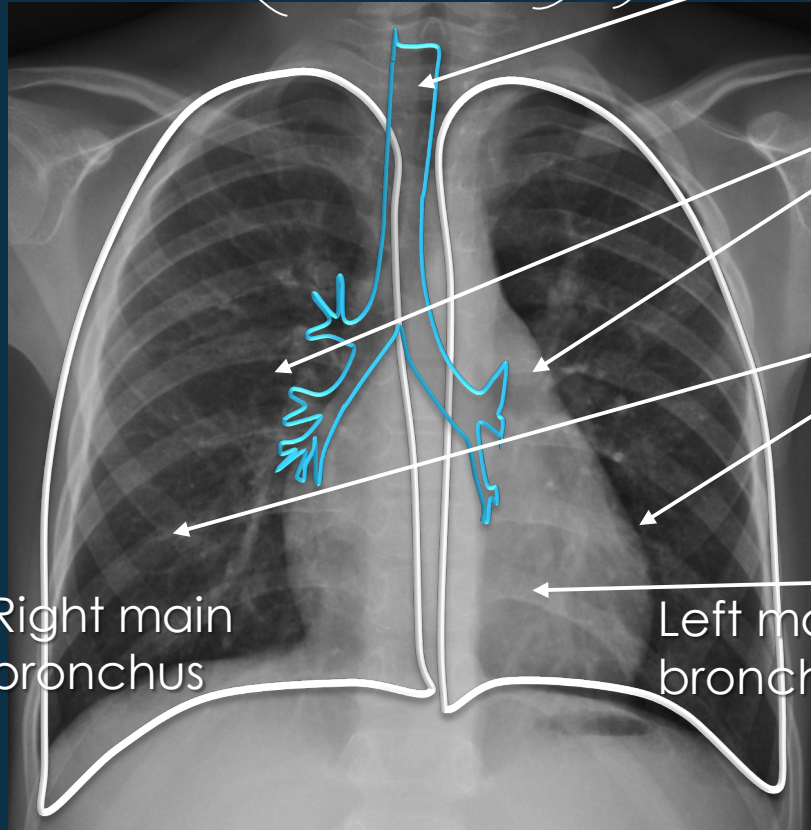


2 year old



Trachea buckling

What main anatomic structures do you see on a child's CXR?



Right main
bronchus

Left main
bronchus

PA view >5 years old

1. Trachea ?

More rigid, stays straight in breathing process, to the right of the aorta

2. Hilum or hilar region ?

Major bronchi and pulmonary veins and arteries.

3. The lungs ?

Filled with air, appear black
Central pulmonary vasculature more visible and prominent

4. The heart ?

Closer to the film and thus less magnified

Thymus gland?
has regressed

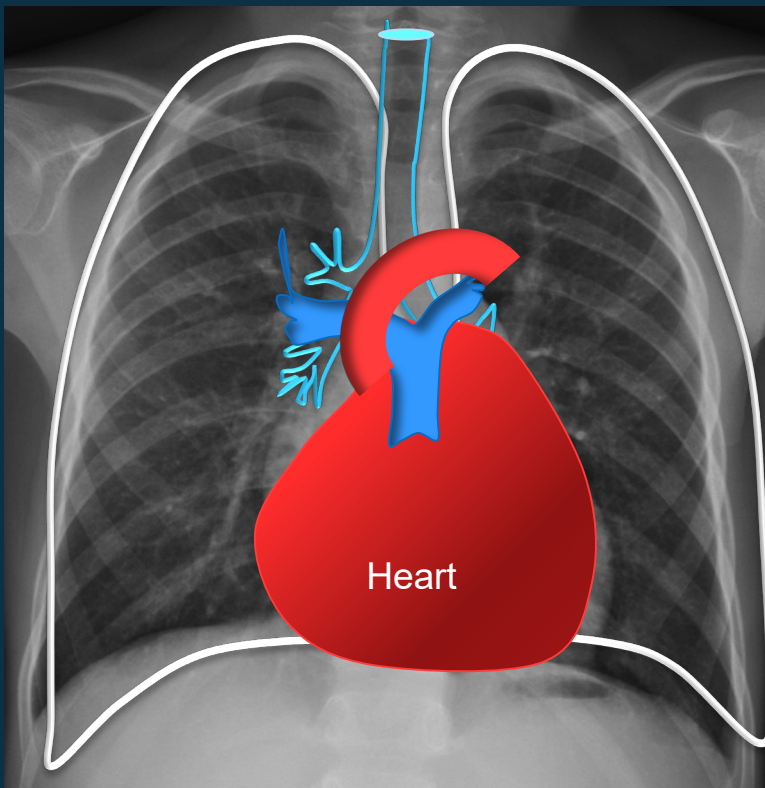
What main anatomic structures do you see on a child's CXR?



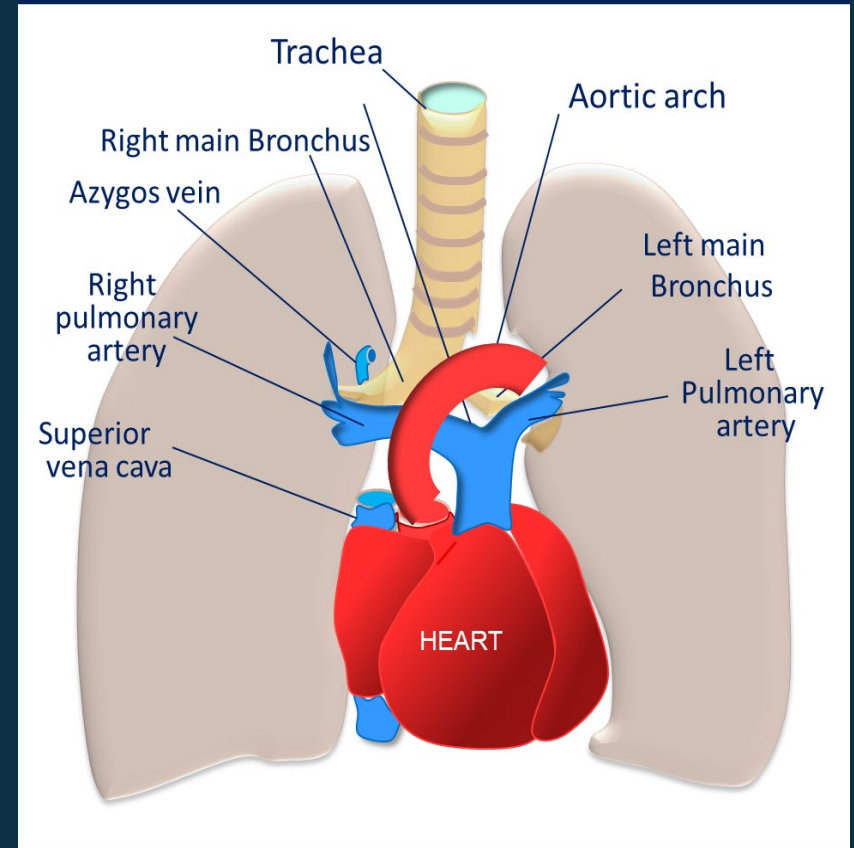
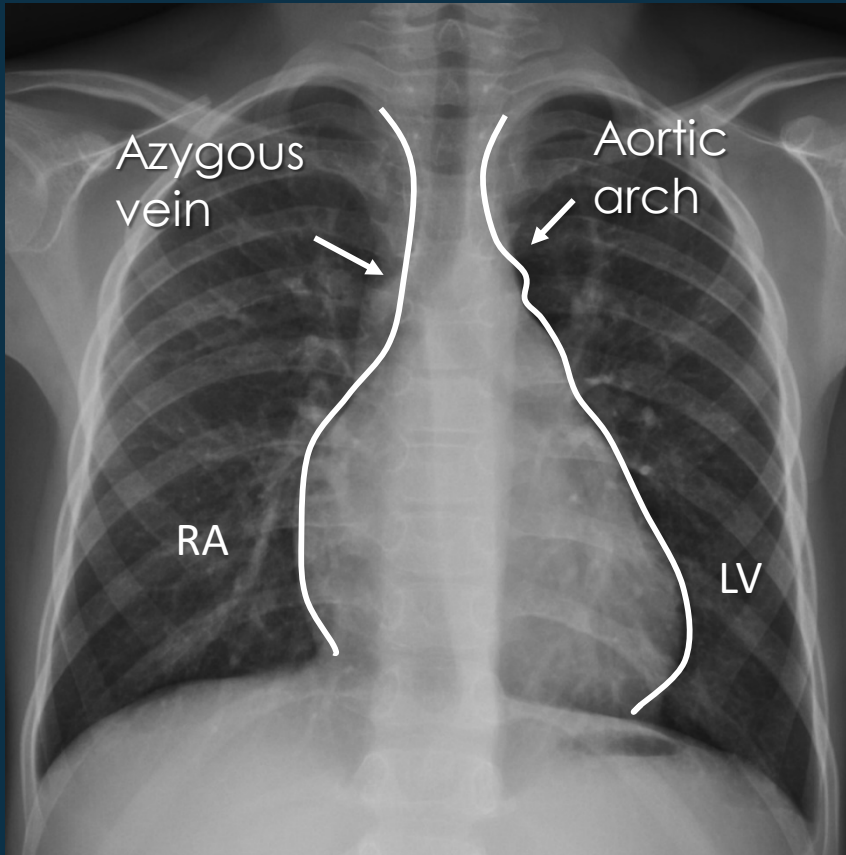
PA view >5 years old

1. The Aortic arch and Right pulmonary artery overlie the left main stem bronchus

2. The Aorta pushes the trachea to the right

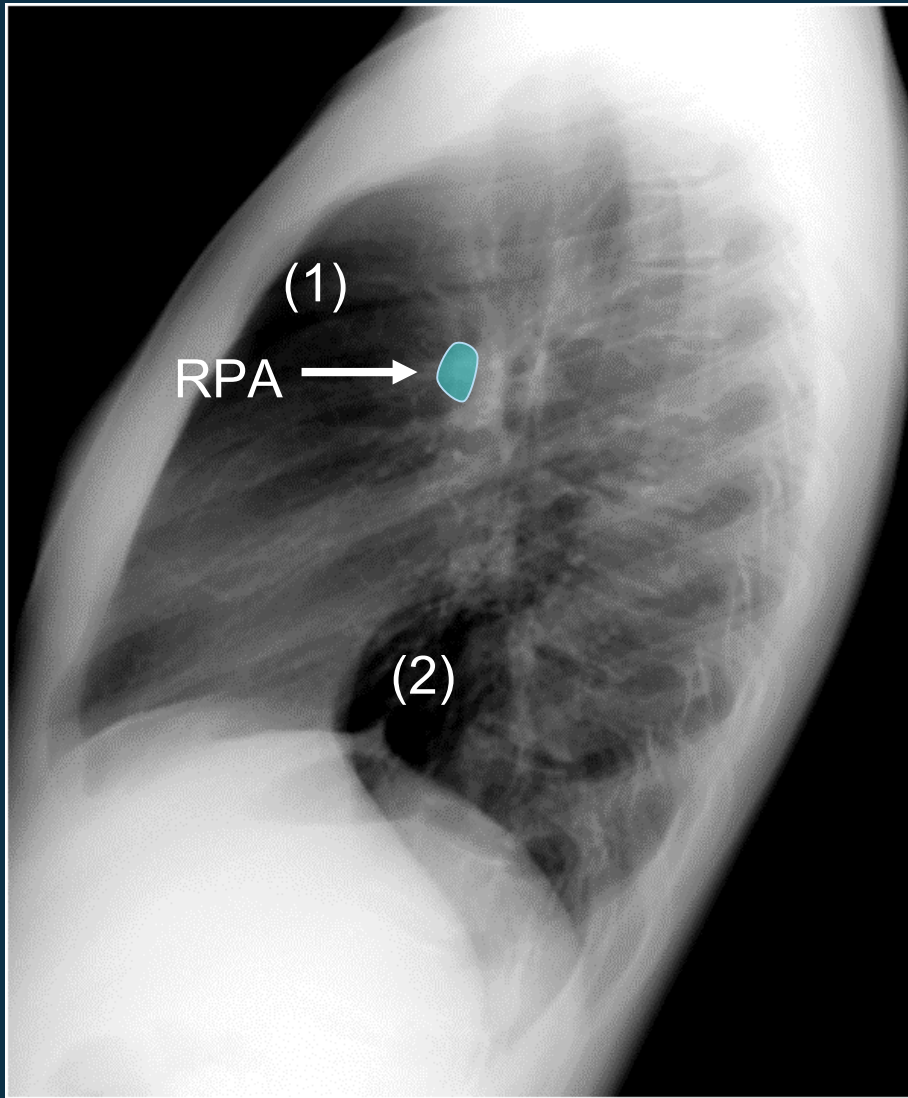


Specific technical and anatomical aspects of CXR in child and adolescent



- . Aortic arch appears as discrete bulge
- . The azygous vein is seen as a small round opacity to the right of the trachea

Reading lateral view



Lateral view for all presumptive TB patients

≤ 5 years of age

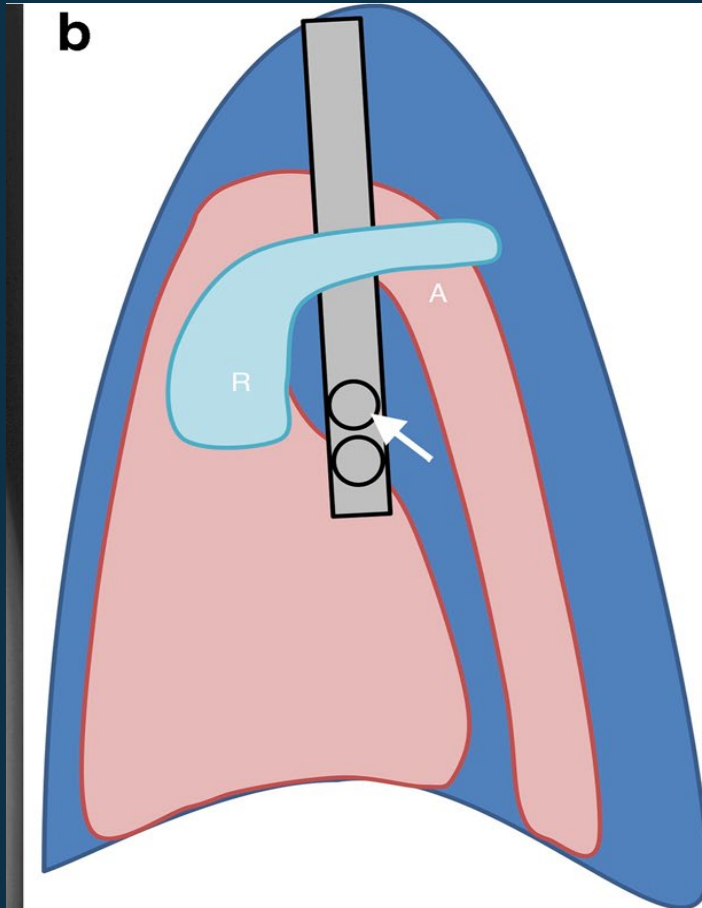
You are looking for lymph nodes !!

The Clear spaces

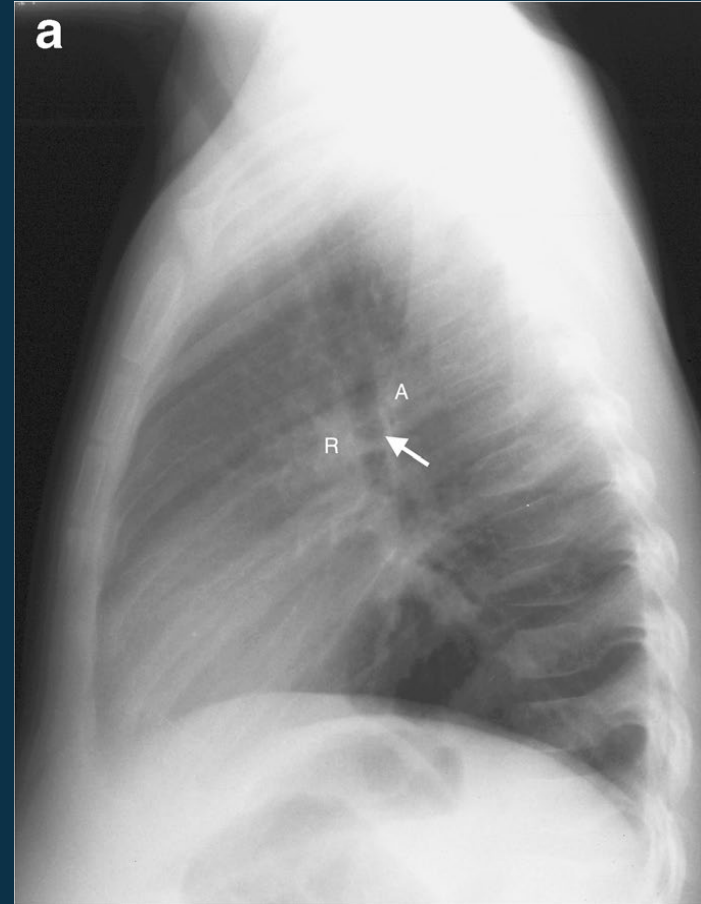- . Retrosternal clear space (1)
- . Retrocardiac clear space (2)

Right Pulmonary Artery (RPA), anterior to the trachea, should not be mistaken for a mass or a lymph node

Normal lateral CXR in a 6-year-old girl



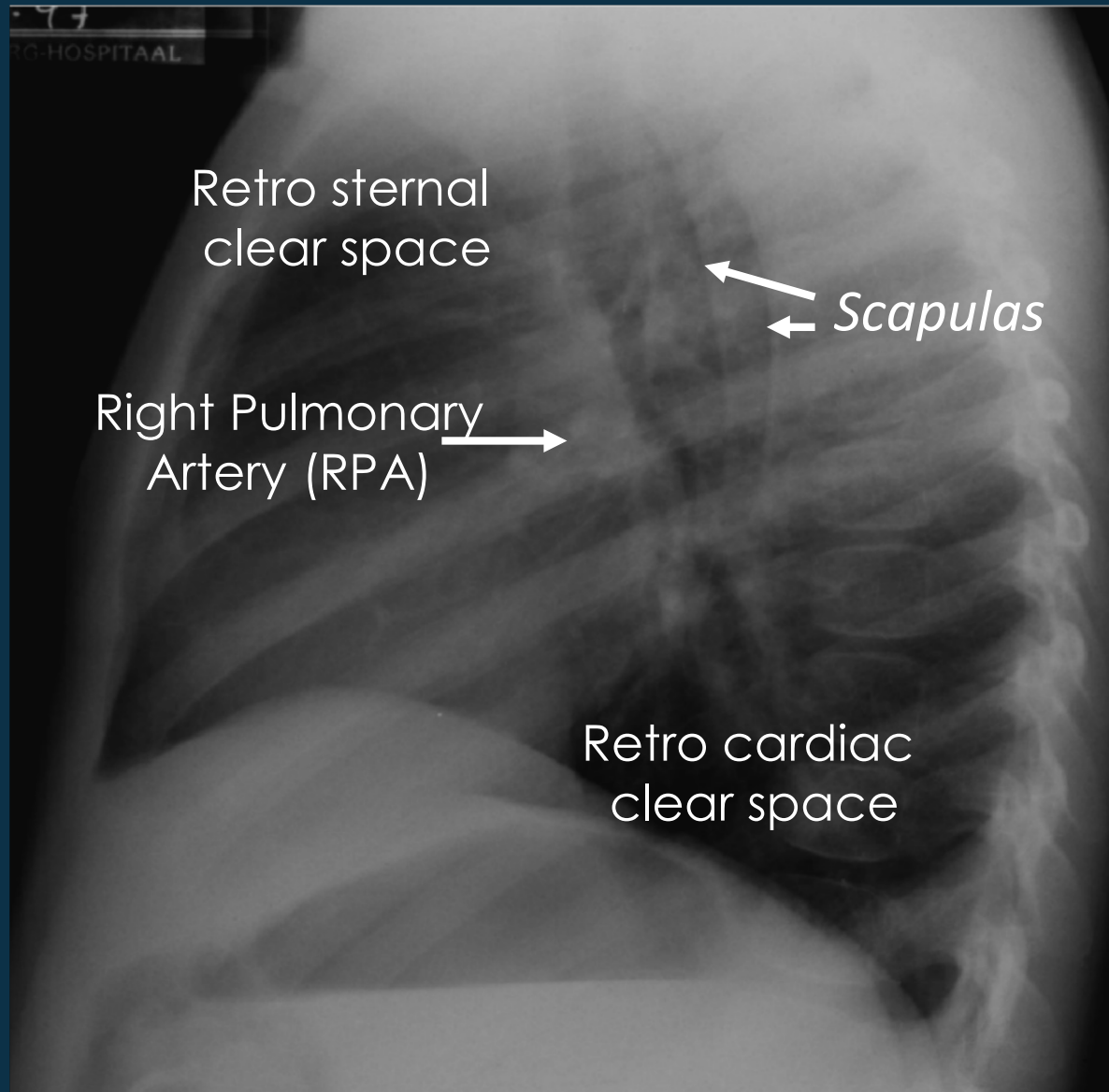
Upper right
and left
bronchi
lucency



Upper right
and left
bronchi
lucency

Right pulmonary artery is ahead of trachea
Aortic arch is behind trachea

Lateral view

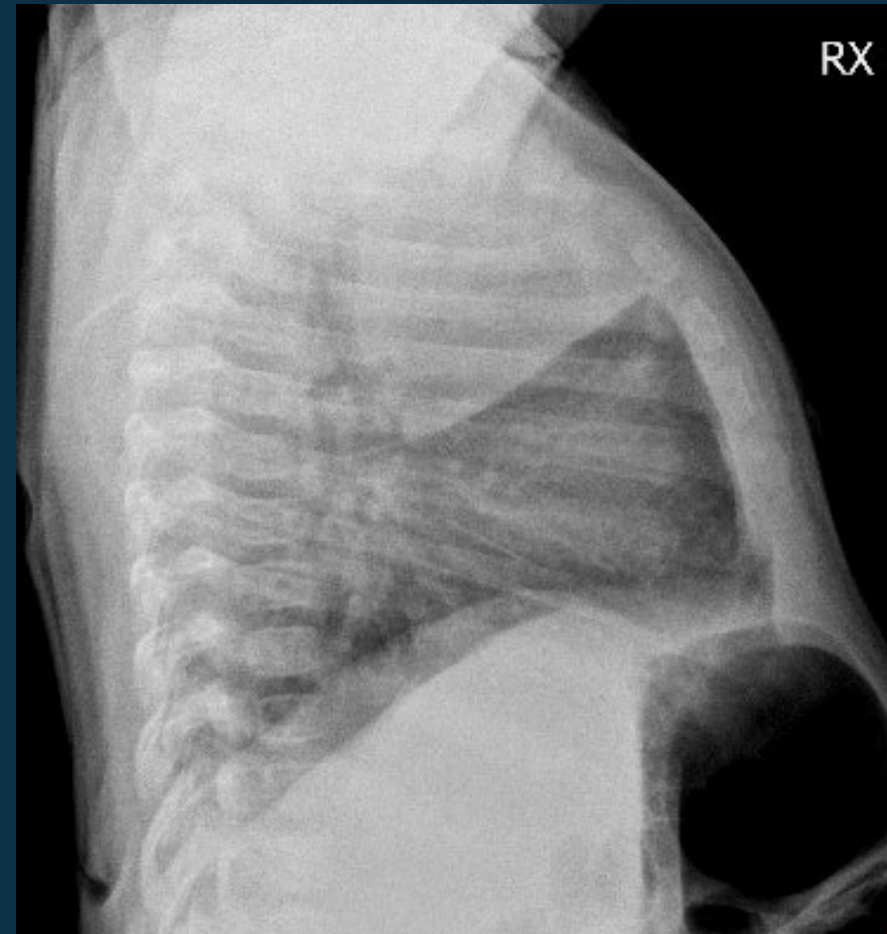


What do you see on this lateral view ?

- . A soft tissue density mass
- . Filling up the retrosternal space

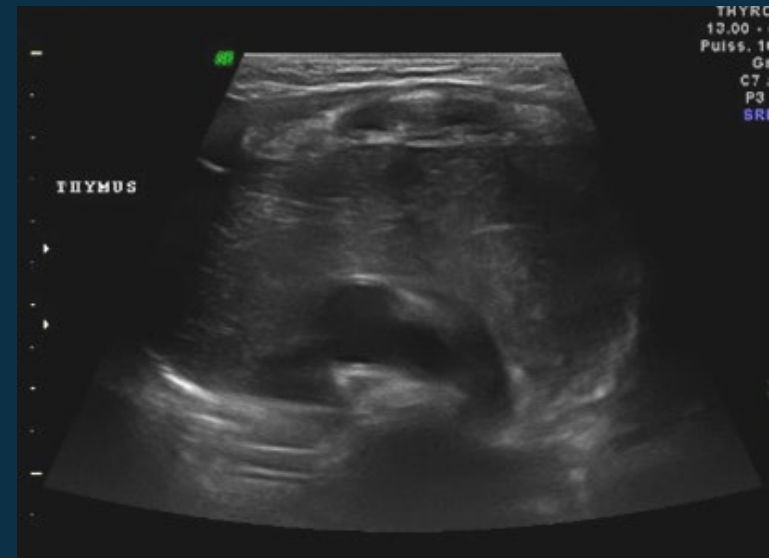
What is it ?

- . Thymus



Retrosternal space filled with a thymus

Sonography if available : homogeneous,
echogenic = normal thymus

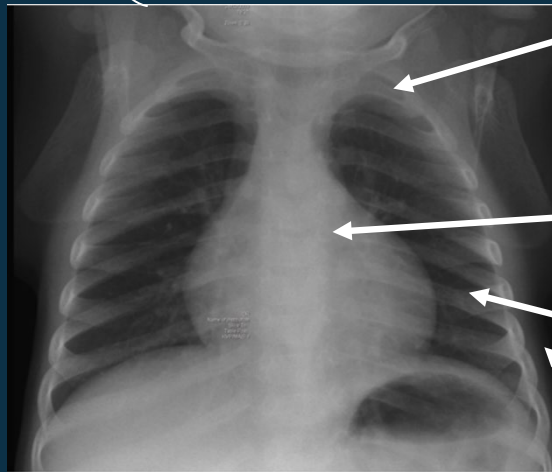


How many radiographic densities do we know ?

1. One
2. Two
3. Three
4. Four
5. Five

How many radiographic densities do we know ?

1. One
2. Two
3. Three
- 4. Four**
5. Five



Calcium = white
opaque

Fluid soft tissue
= light grey

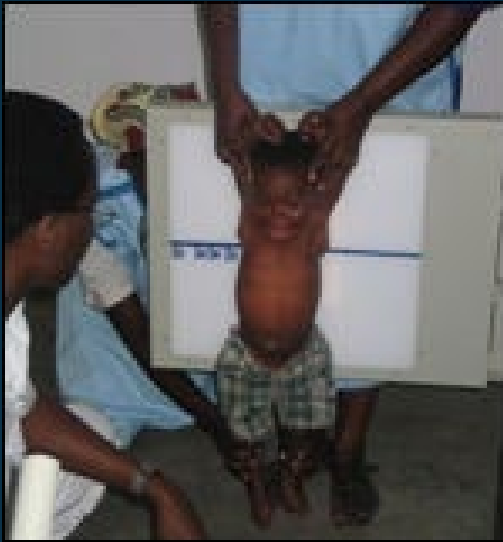Air = black
(hyperlucent)

Fat = dark grey

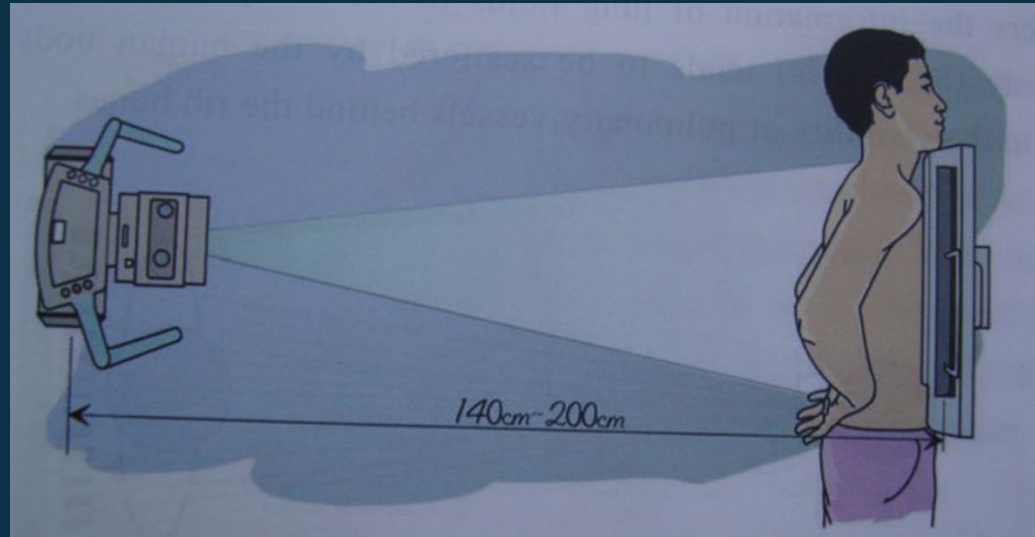
4 radiologic densities

What are the basic radiographic views ?

1. AP in child \leq 5 years age
2. PA in child \leq 5 years age
3. AP in child $>$ 5 years age
4. PA in child $>$ 5 years age



AP



PA

What are the basic radiographic views ?

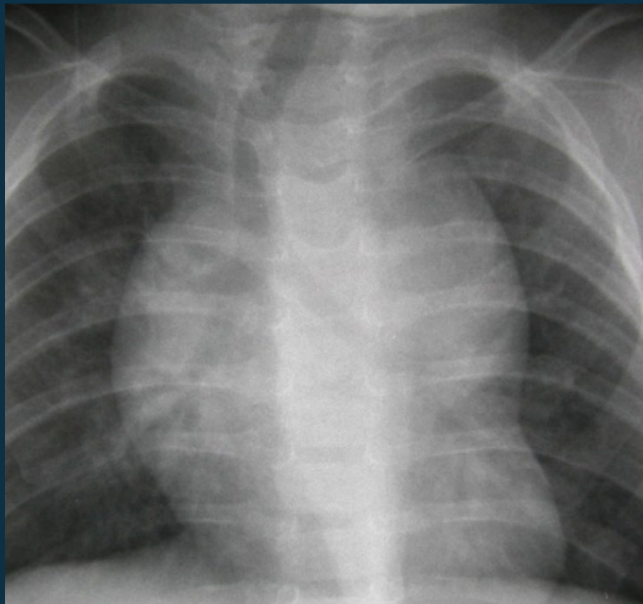
1. AP in child \leq 5 years age
2. PA in child \leq 5 years age
3. AP in child $>$ 5 years age
4. PA in child $>$ 5 years age

Name a main anatomical feature in paediatric CXR? (before 2 years old)

1. Thyroid
2. Thymus
3. Aorta
4. Right Pulmonary Artery (RPA)

Name a main anatomical feature in paediatric CXR? (before 2 years old)

1. Thyroid
2. Thymus
3. Aorta
4. Right Pulmonary Artery (RPA)



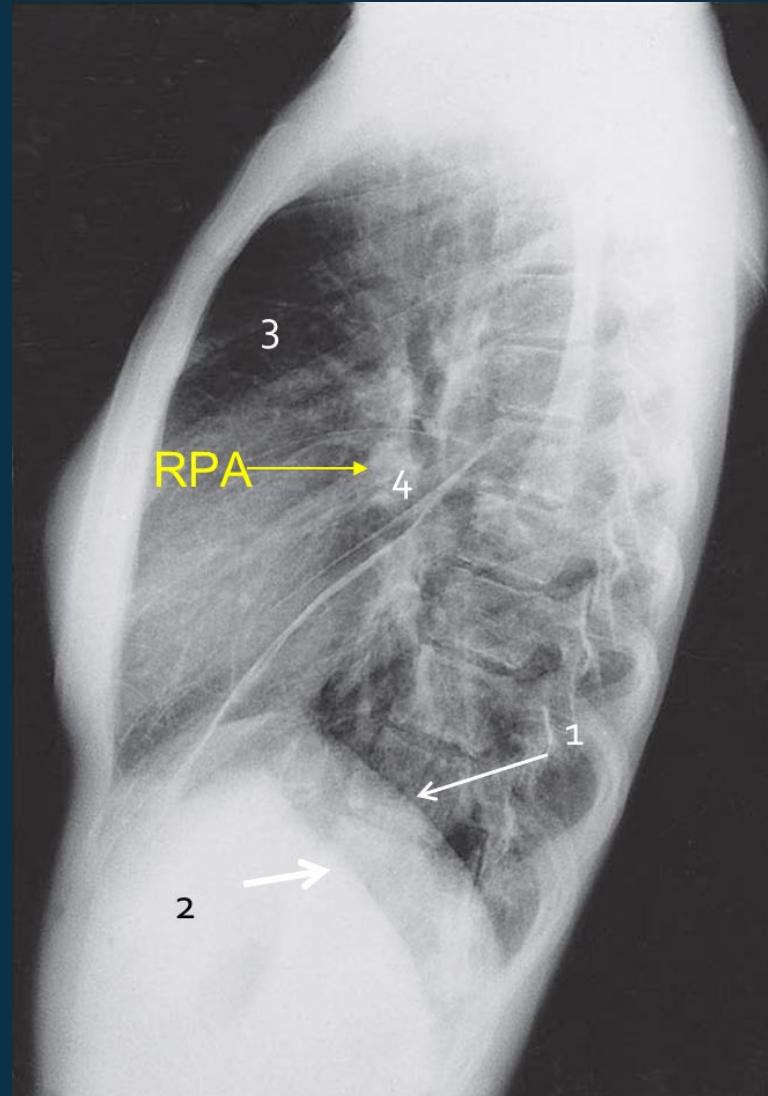
Thymus
(with trachea buckling)

What view do you ask for in order to identify lymph nodes ?

1. Lateral view
2. AP view
3. PA view

What view do you ask for in order to identify lymph nodes ?

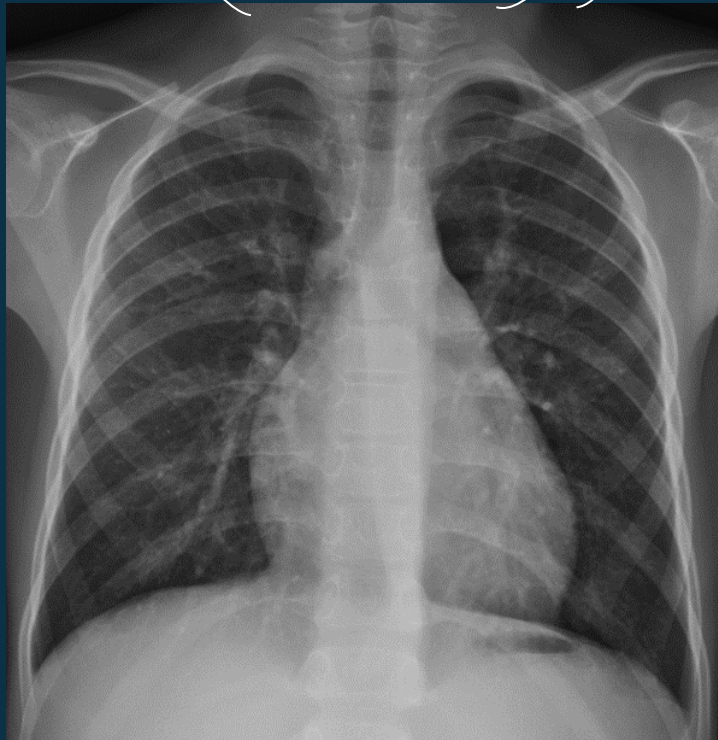
1. Lateral view
2. AP view
3. PA view



Technical and anatomical aspects

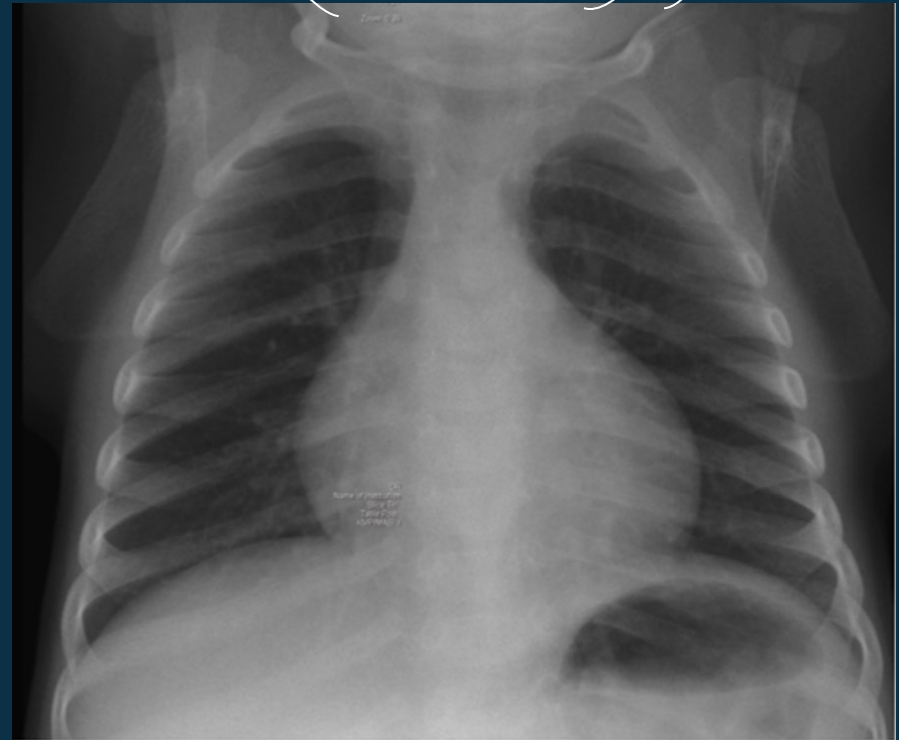

Know which different views to ask for
and the importance of the lateral view



PA view over 5 years old

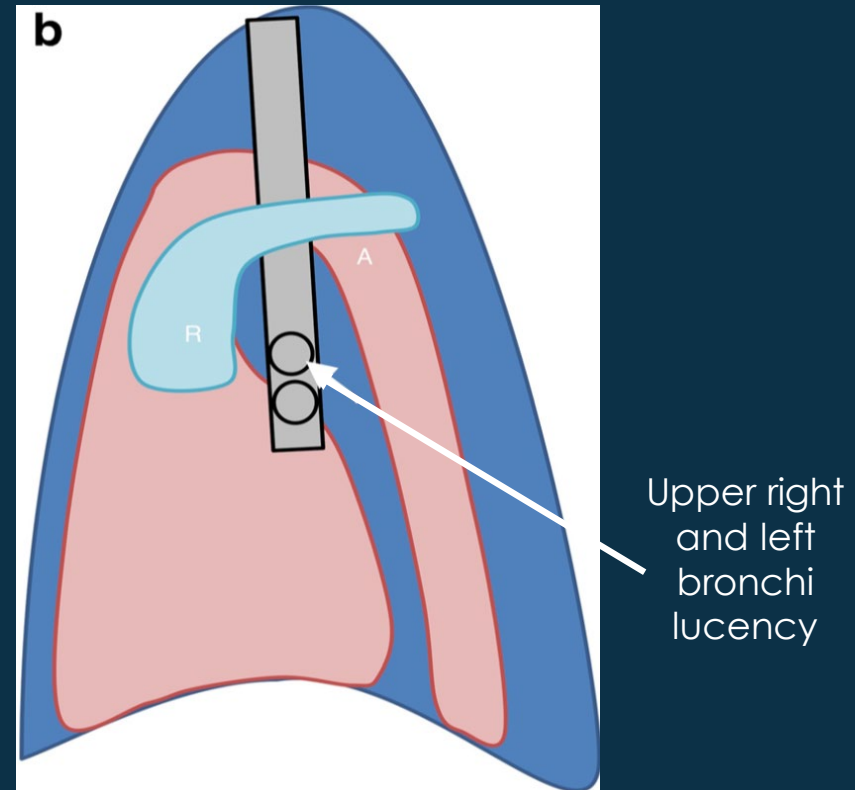
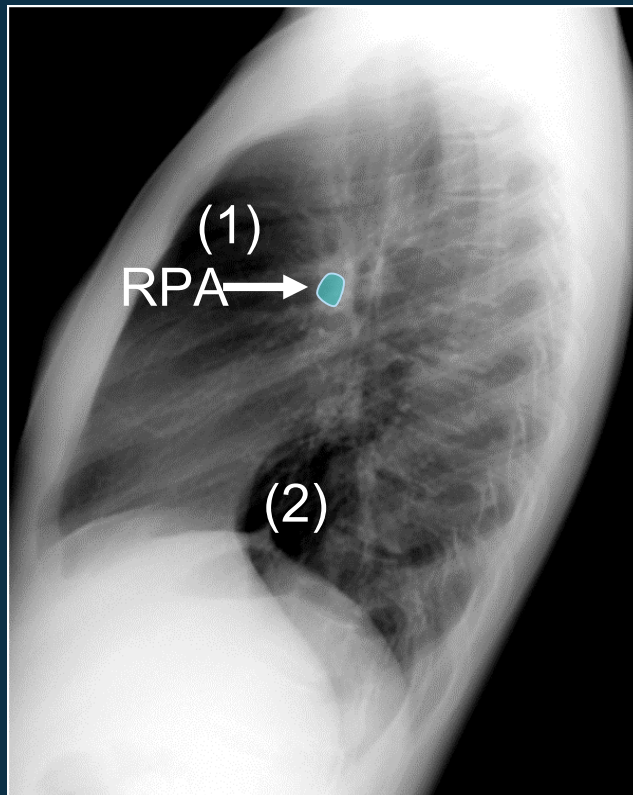
- . Trachea is straight
- . No thymus
- . Heart is of normal size



AP view \leq 5 years old

- . Beware of thymus and trachea buckling below 2 yrs
- . Heart is magnified

Importance of lateral view: normal lateral view



1. Retrosternal clear space (should be black) - check that it is not filled

2. Retro cardiac clear space (check that there is no opacity)
 The *Right pulmonary artery (RPA)* and aortic arch are well visualised which means that there are **No Lymph Nodes**



Now you know the technical and anatomical aspects
of paediatric CXRs

Now let's learn a method called **'the systematic approach'**

Module 1

How to read a child CXR

Chapter 2:

how to read a paediatric CXR
Systematic approach to CXR interpretation

Paediatric CXR: introduction to the systematic approach



We will develop a systematic approach.
Do not skip any item on the following list

Systematic approach for CXR- check list

1. Check the identification: name, date, supine or erect
2. Check the clinical history and findings
3. Check the technical quality factors : inspiration, rotation, penetration
4. Assess
 - . 1st circle : thoracic wall and thoracic skeleton
 - . 2nd circle: each lung field, one after the other
 - . 3rd circle: airways, cardio-mediastinal contour
 - . The hidden areas = worth a second look: apices, hilar regions, retro cardiac areas (left & right), sub-diaphragmatic areas



Have you checked the identification and patient's history ?

Now we need to know if the CXR is readable or not

Module 1 How to read a CXR

Chap1: Technical and anatomical aspects

Chap2: Systematic approach to CXR interpretation

Part1. Quality factors

Part2. Normal CXR

Part3. First circle

1. Soft part of the chest wall
2. Diaphragmatic areas
3. Bony Thorax abnormalities

Part4. Second circle

4. Lung
5. Pleura

Part5. Third circle

6. Airways
7. hili and Mediastinum
8. Lymph nodes
9. Heart

Part6. The hidden areas

Part7. Conclusion



Is the CXR readable or not ?

The technical quality factors will help you
to decide if a CXR is readable or not

Check the technical quality factors

Is the CXR readable or not ?

1. Deep inspiration: was the film taken in full inspiration ?
2. Rotation: was the patient in a good position (facing directly forwards) ?
3. Penetration: is the film over or under penetrated?
Is there adequate density / contrast ?

Before we start : how many pairs of ribs do we have

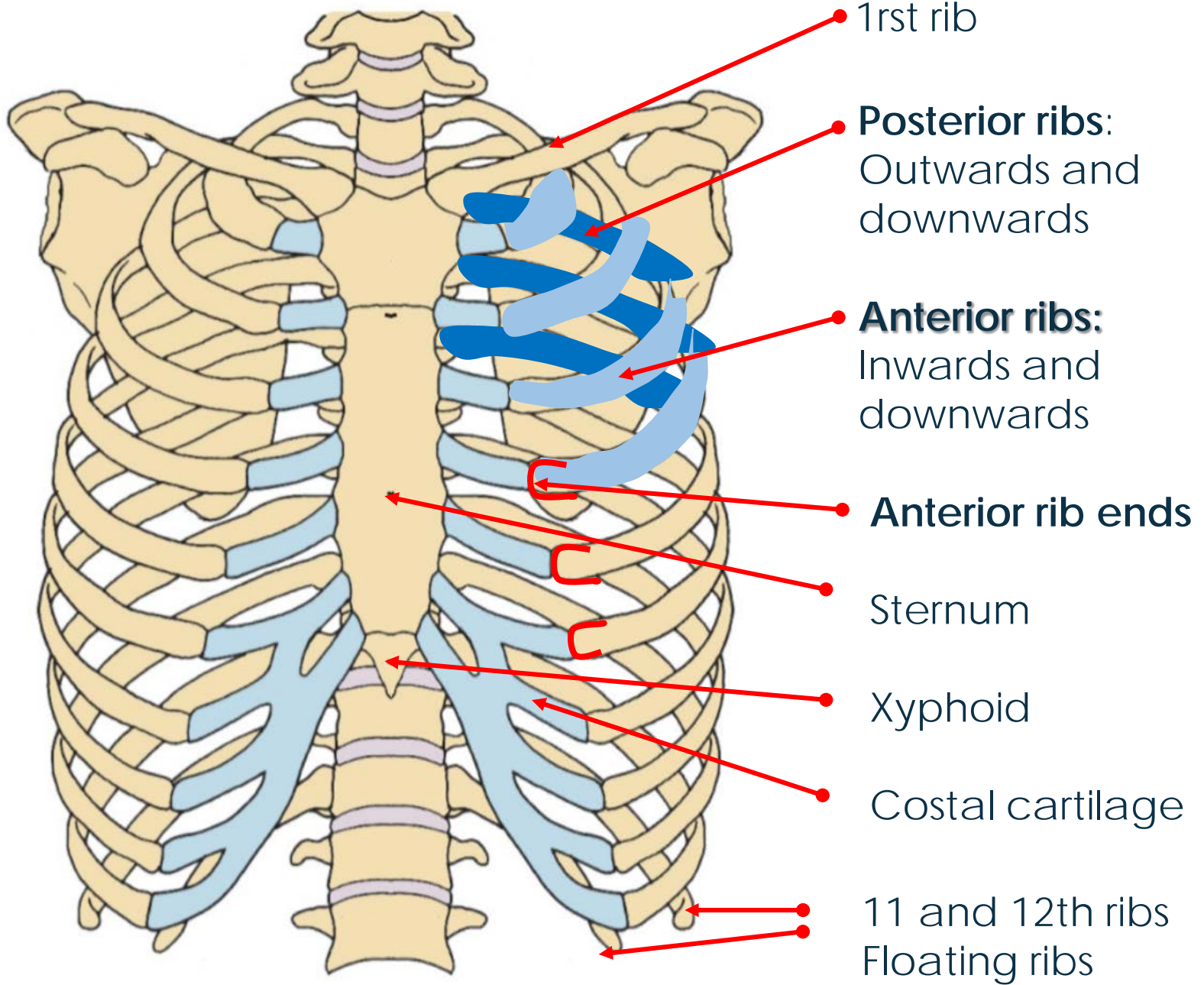
1. 8
2. 10
3. 12
4. 14



Before we start : how many pairs of ribs do we have

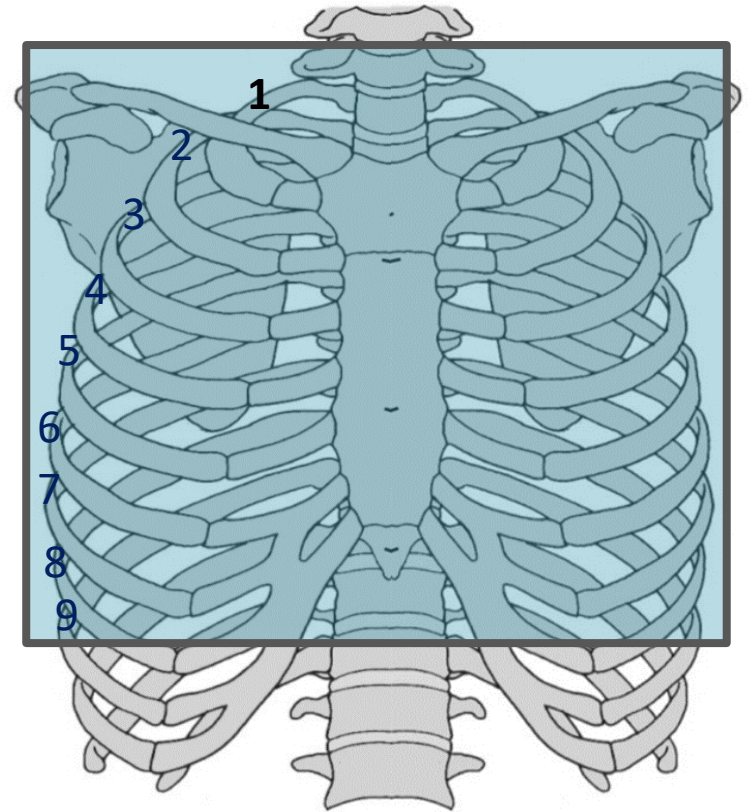
1. 8
2. 10
- 3. 12**
4. 14

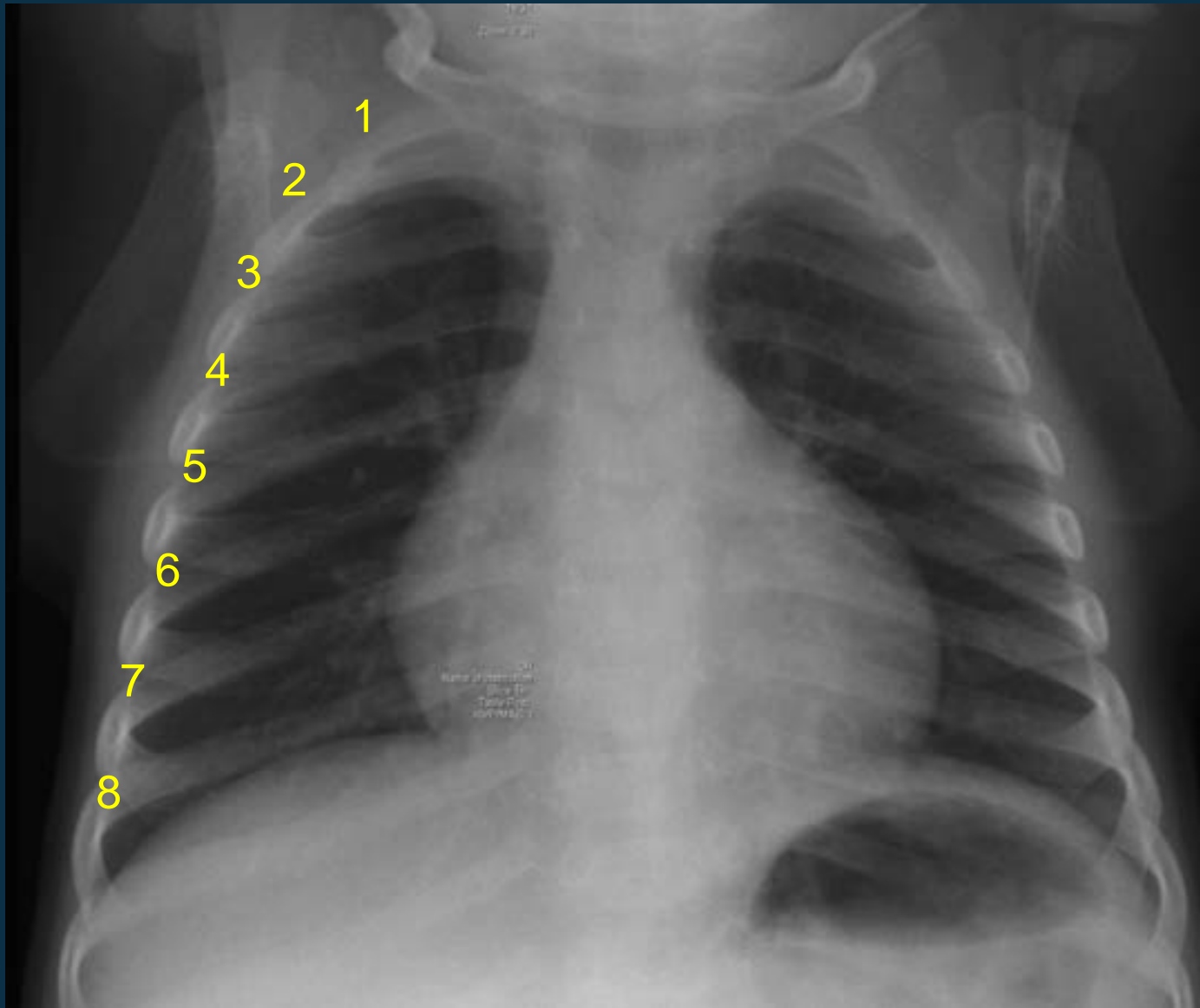




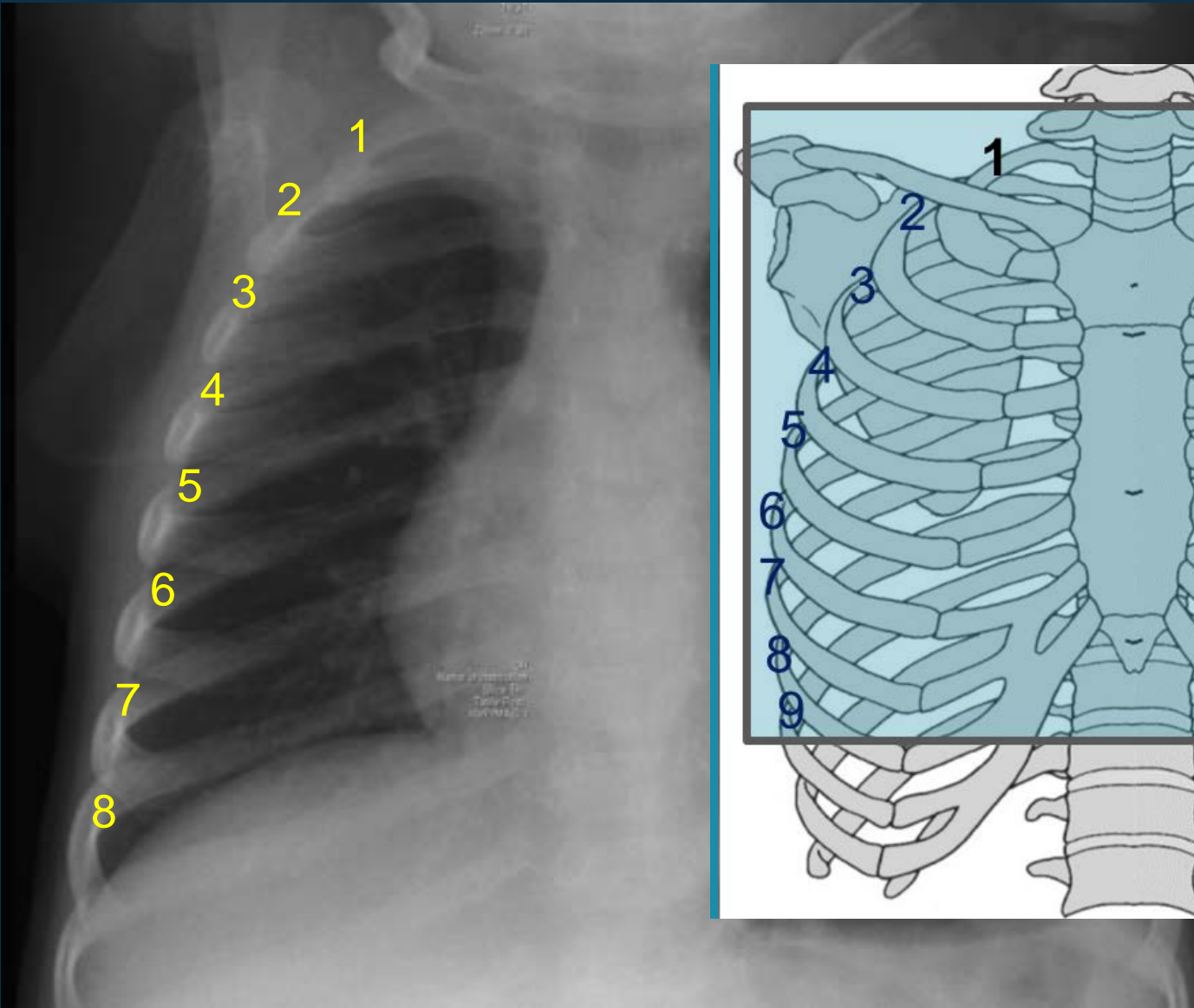
Inspiration

1. Adequate inspiration is when the 8-9th posterior rib is visible
2. Use only posterior ribs in younger children. The ribs closer to the film (posterior) are most apparent

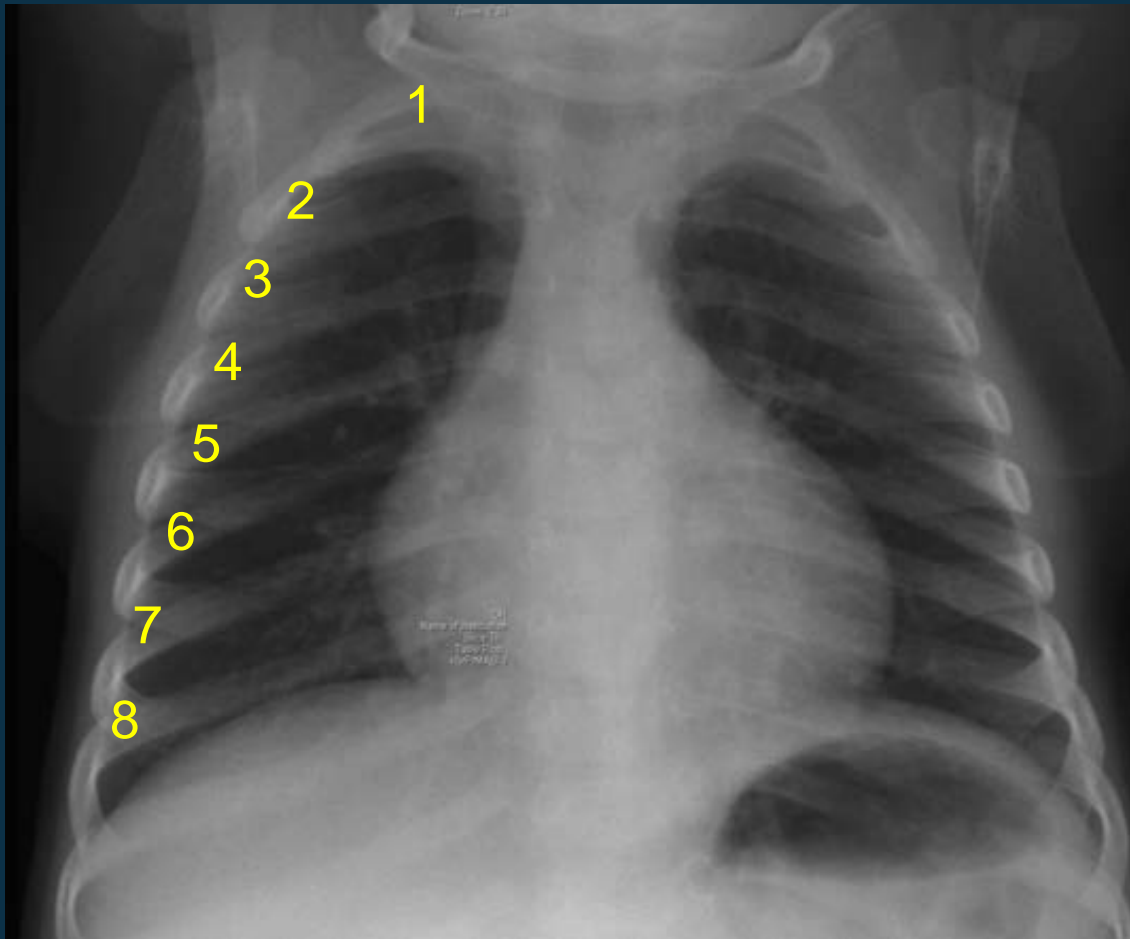




Adequate inspiration: if you can count 8 or 9 posterior ribs



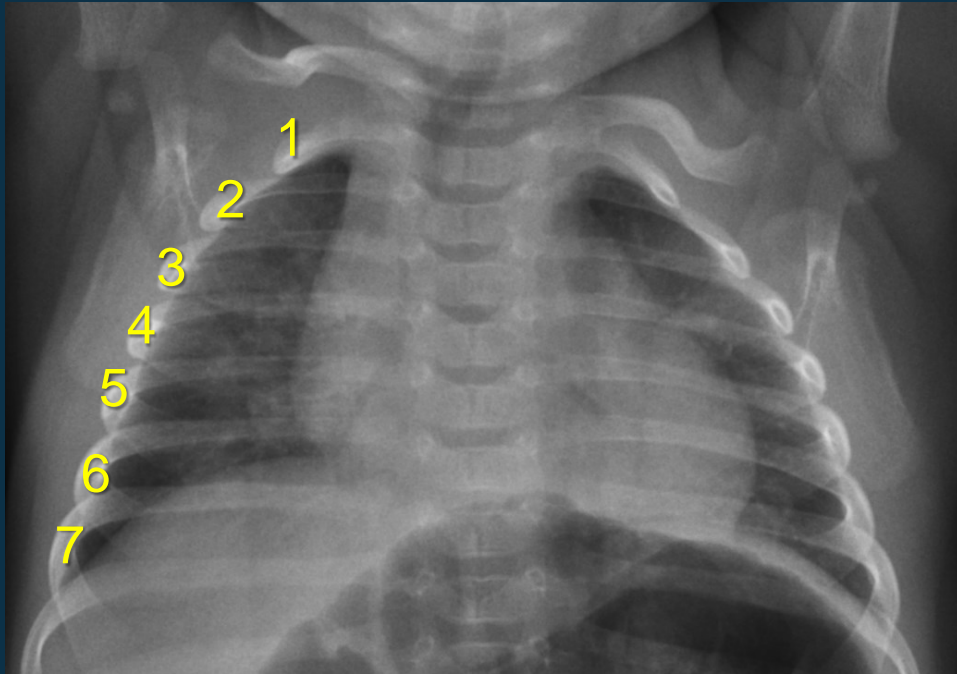
Adequate inspiration: if you can count 8 or 9 posterior ribs



Criteria for normal inspiration (normal lung volume)

1. 8/9th posterior rib above the diaphragm
2. Less than 1/3rd of the heart below the diaphragm
3. The domes of the diaphragm are rounded
4. The lungs are air-filled (black)

What do you think about this CXR ?



How many posterior ribs?
. 7 ribs

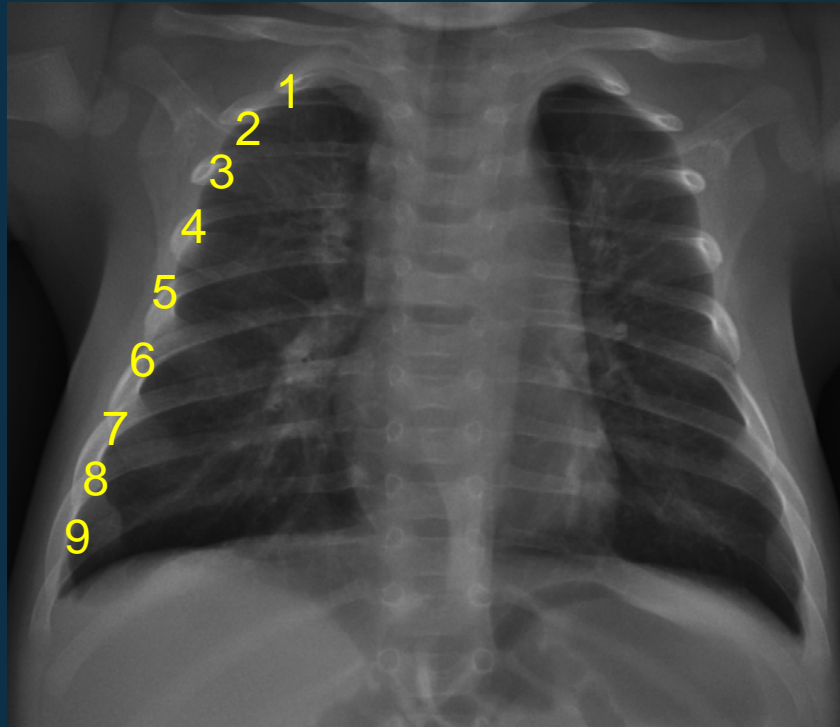
How are the lungs ?
. Too opaque = not enough air

Why ?
. This is an expiration view

Is the CXR readable or not ?

1. Not readable: Expiration < 8 posterior ribs
2. The heart appears enlarged
3. The amount of air within the lungs is decreased
4. The lungs appear more opaque than normal (white).

What about this CXR ?



Inspiration: how many posterior ribs?
· Over 9 posterior ribs

How are the lungs ?
· Very black = hyperlucent = excess of air = hyperinflation

Why ?
· Hyperinflation > 9 posterior ribs (mainly in teenagers)

Required quality criteria for CXR interpretation

1. Adequate inspiration is when the 8-9th posterior rib is visible. Use only posterior ribs in younger children

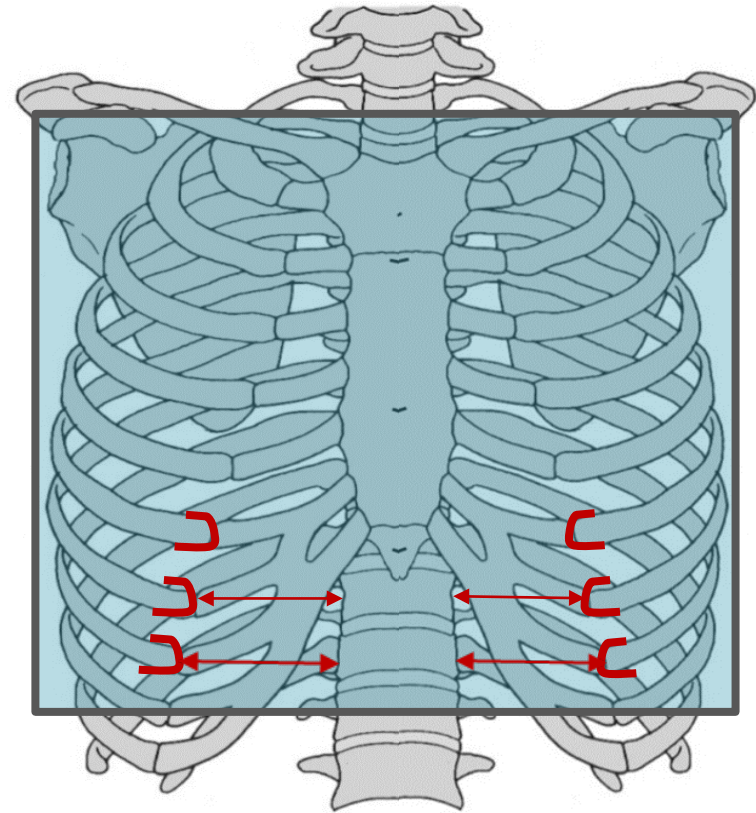
- . Hypoinflation < 8 posterior ribs (*poor inspiration or expiratory film*)
- . Hyperinflation > 9 posterior rib (*more frequent in adolescent*)

Required quality criteria for CXR interpretation

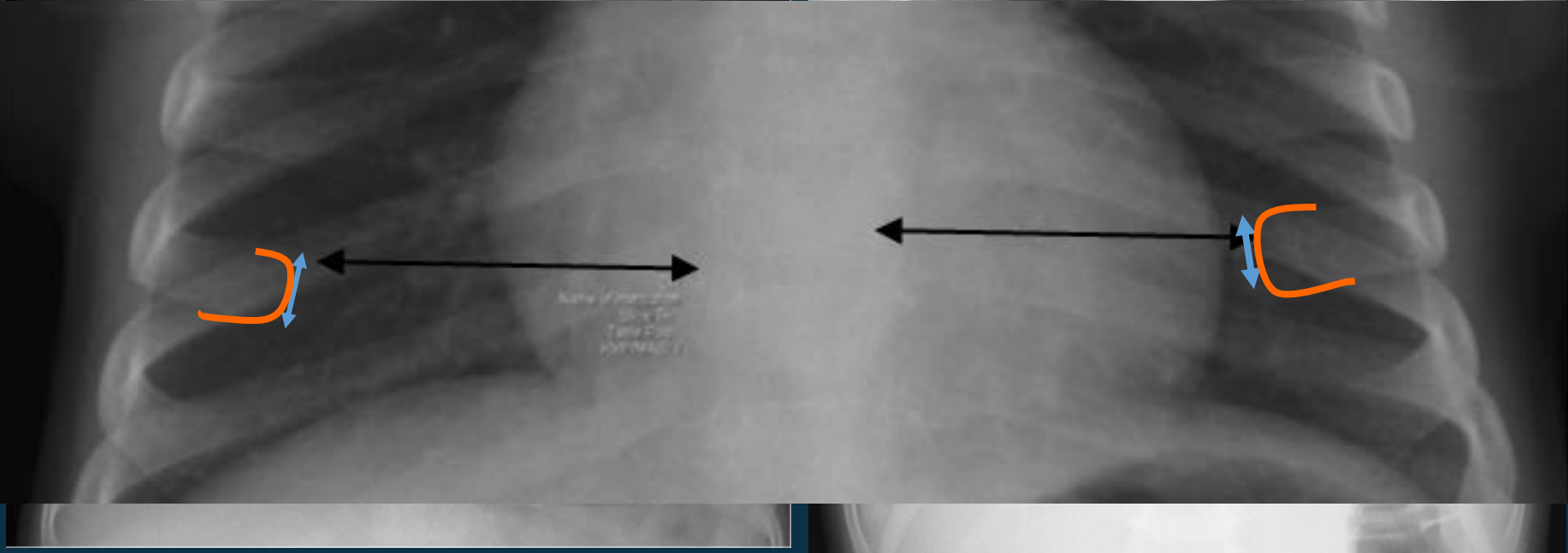
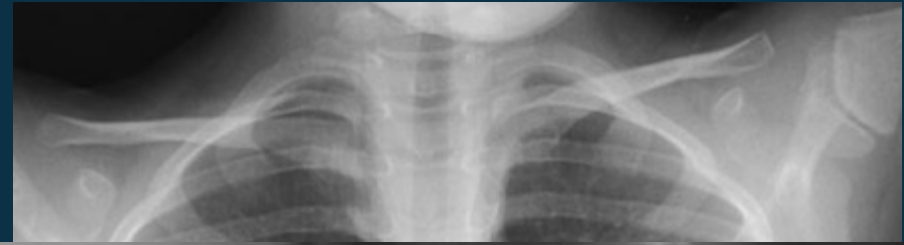2. No notation

Look for asymmetry of the skeletal structures

- . In children use the anterior rib ends
- . Clavicle ends are difficult to locate

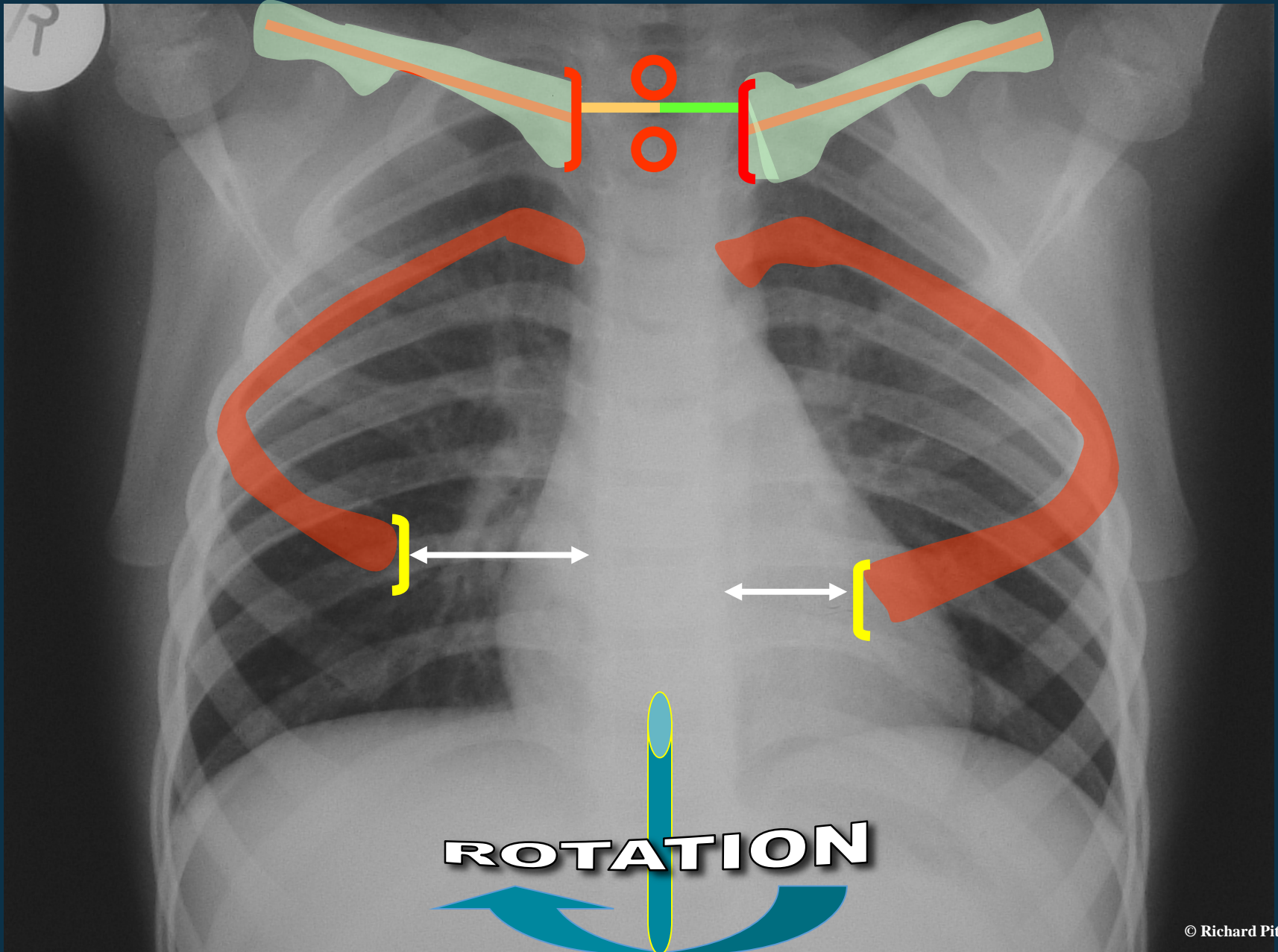


Check if the anterior ends of the ribs are all an equal distance from the spine.

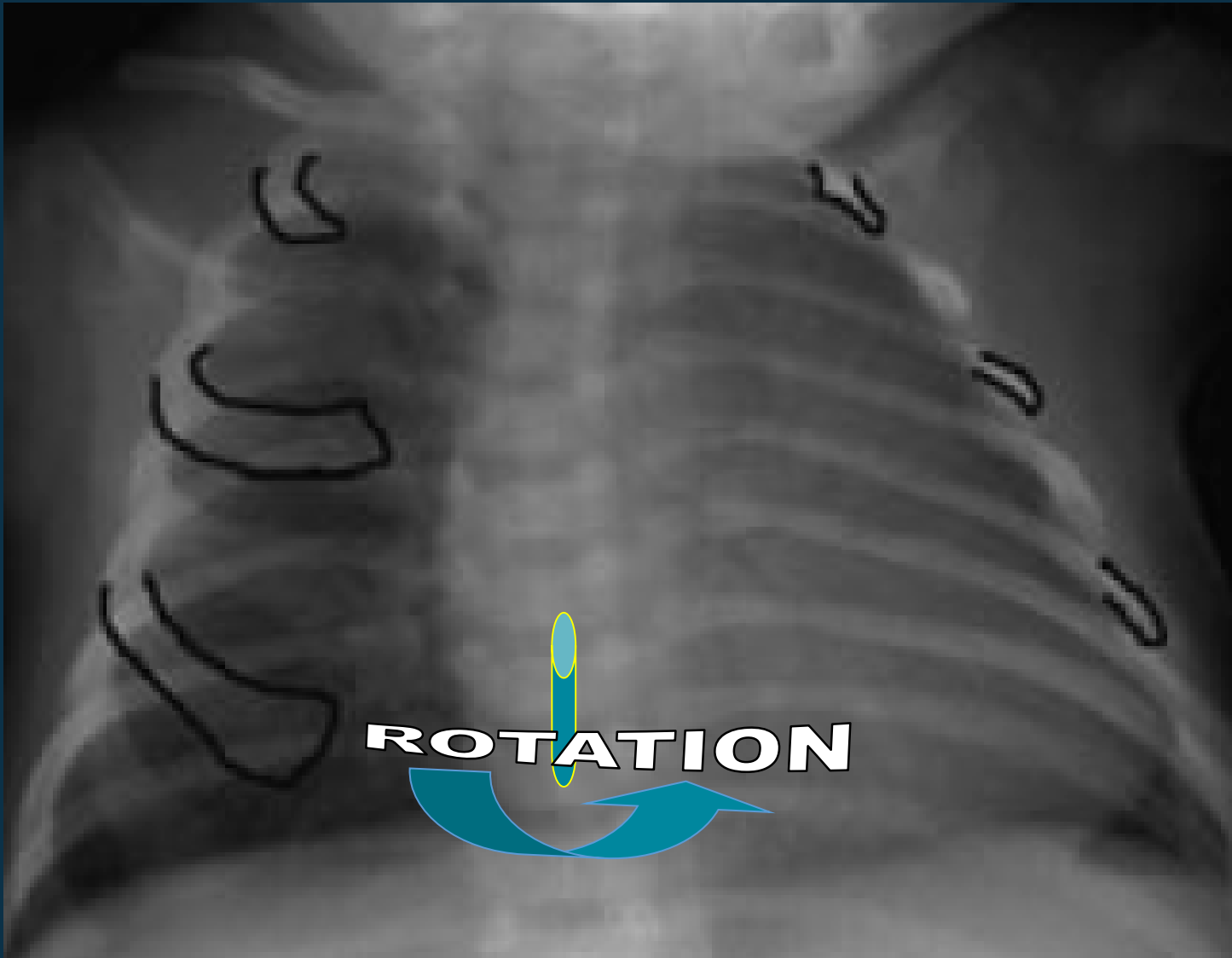


Criteria for non-rotated film*

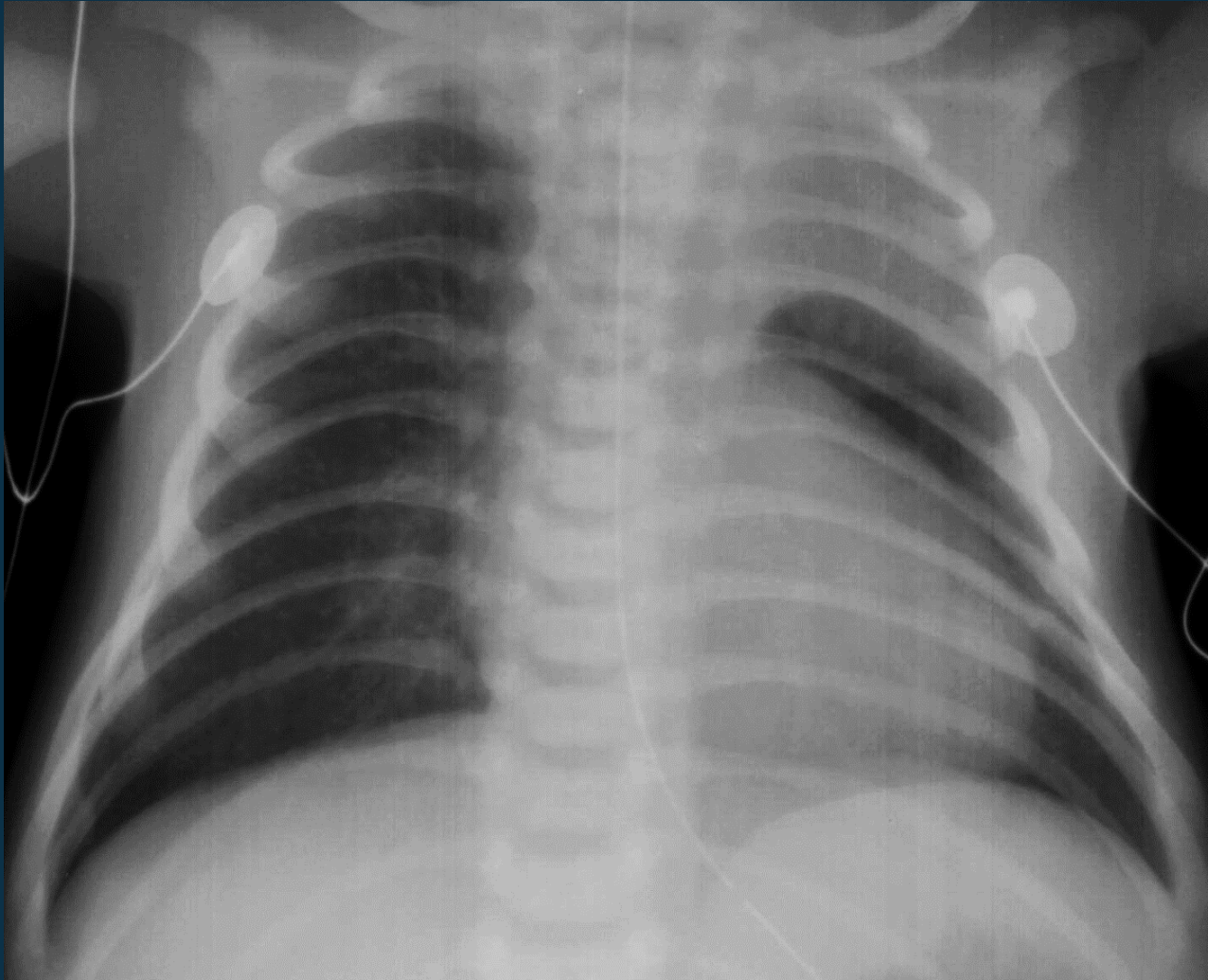
- . Anterior ribs equidistant from the pedicles
- . Medial aspects of the clavicles are symmetrically positioned in relation to midline
- . No difference in aeration between the two lungs



Rotation to the right makes the heart appear central



Follow the ribs : the right anterior ribs are much closer to the spine
Rotation to the left makes the heart look large
and can make the right heart border disappear.



Rotated positioning, mimicking pathology

- . Rotation to the left
- . Hyperlucency
- . Thymus simulating atelectasis or pulmonary infiltrates

Rotation

1. Look for asymmetry of the skeletal structures
 - . In children use the anterior rib ends
 - . Clavicle ends are difficult to locate
2. Check if the anterior ends of the ribs are all an equal distance from the spine.
3. Rotation to the right makes the heart appear central
4. Rotation to the left makes the heart look large and can make the right heart border disappear.

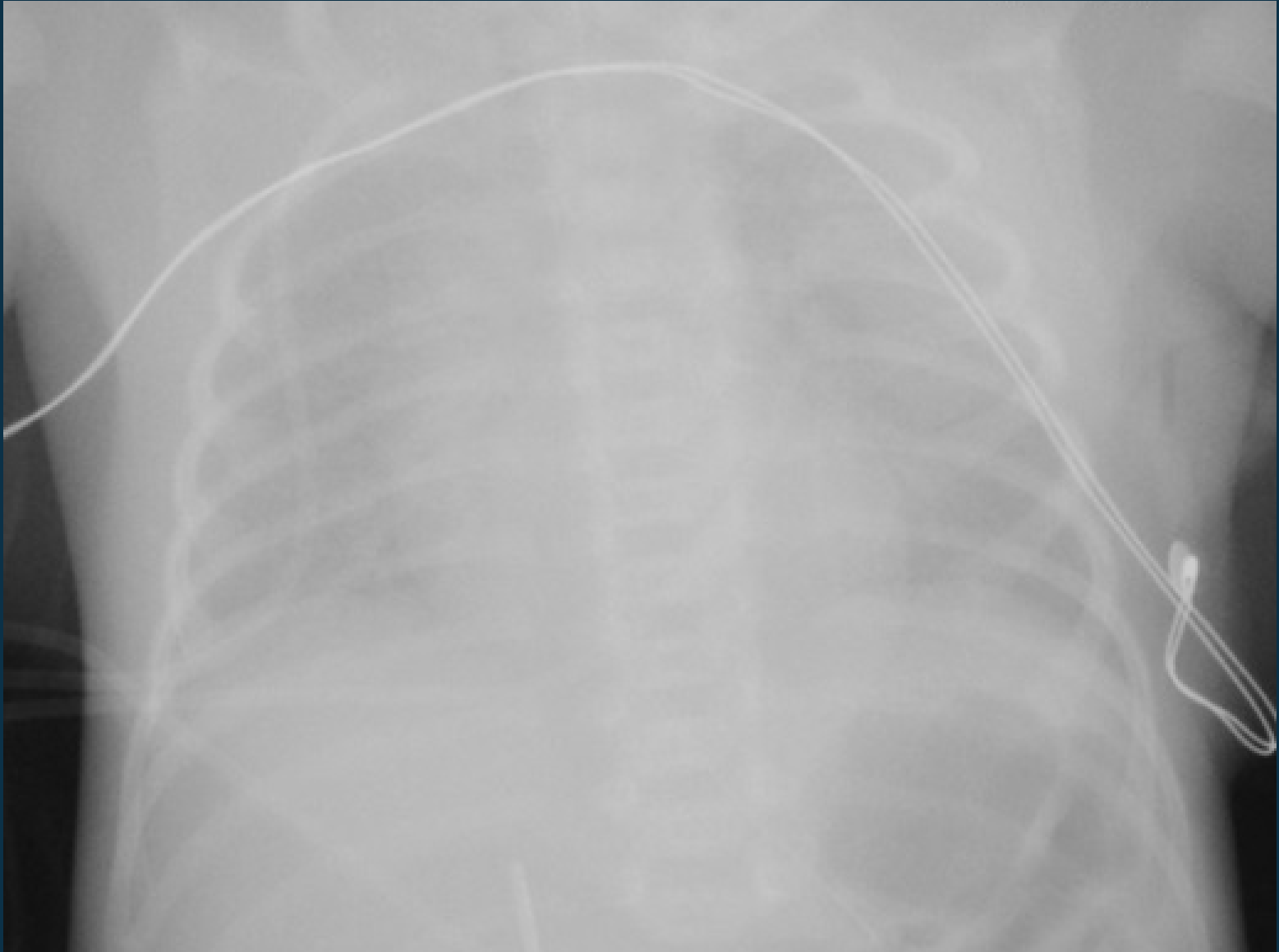
Required quality criteria for CXR interpretation

3. Penetration

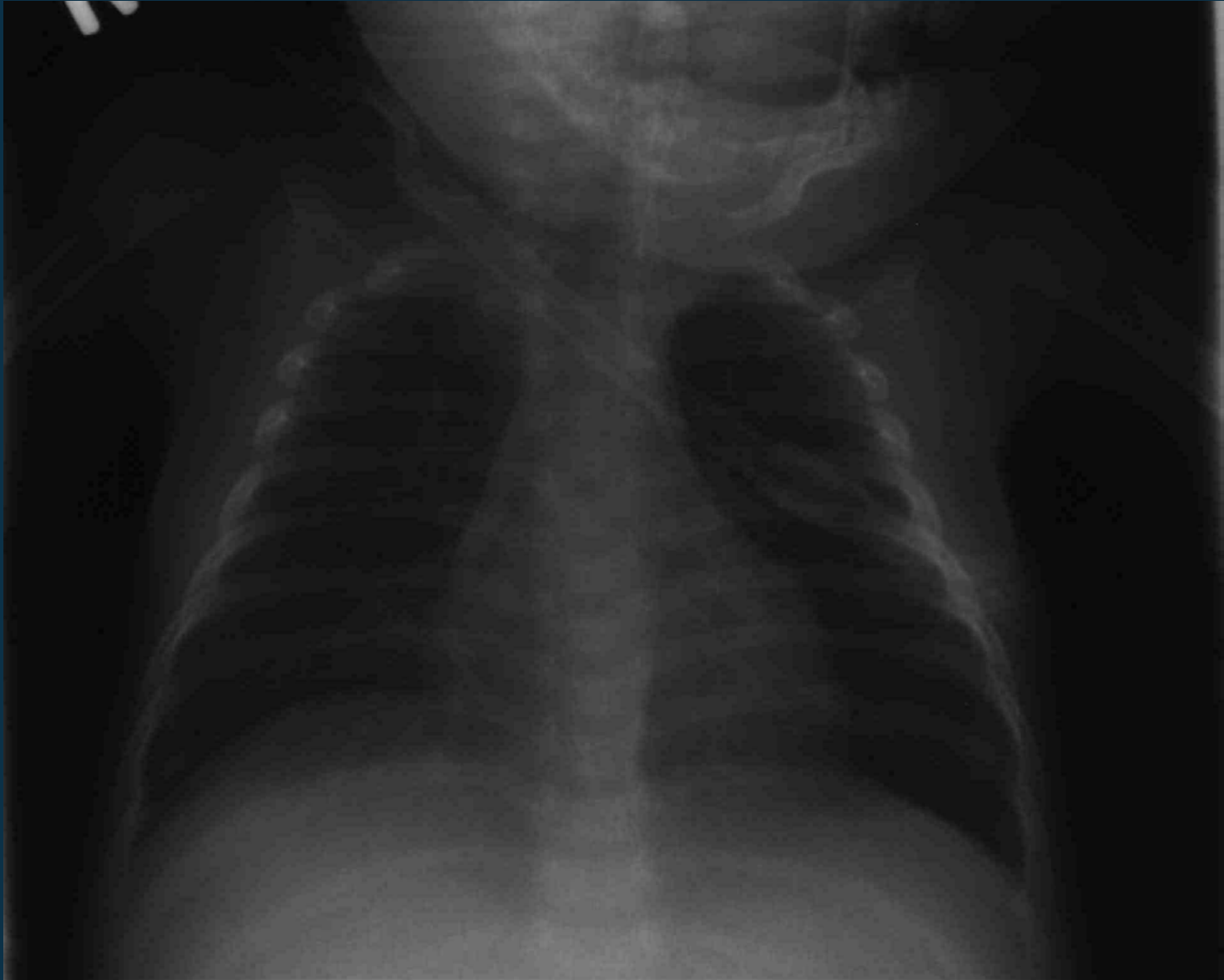
1. In an adequately penetrated film you should be able to:
 - . See vessels behind heart
 - . See pulmonary vessels in 2/3 of the lung (from central to periphery)
 - . See trachea and proximal bronchi
 - . Distinguish the intervertebral spaces through the heart shadow.

2. Under-penetration : **white x-ray**

3. Over-penetration : **black x-ray**



Under-penetration : **white x-ray**



Over-penetration : **black x-ray**

Is the CXR readable or not ?

Good quality factors

1. Deep inspiration

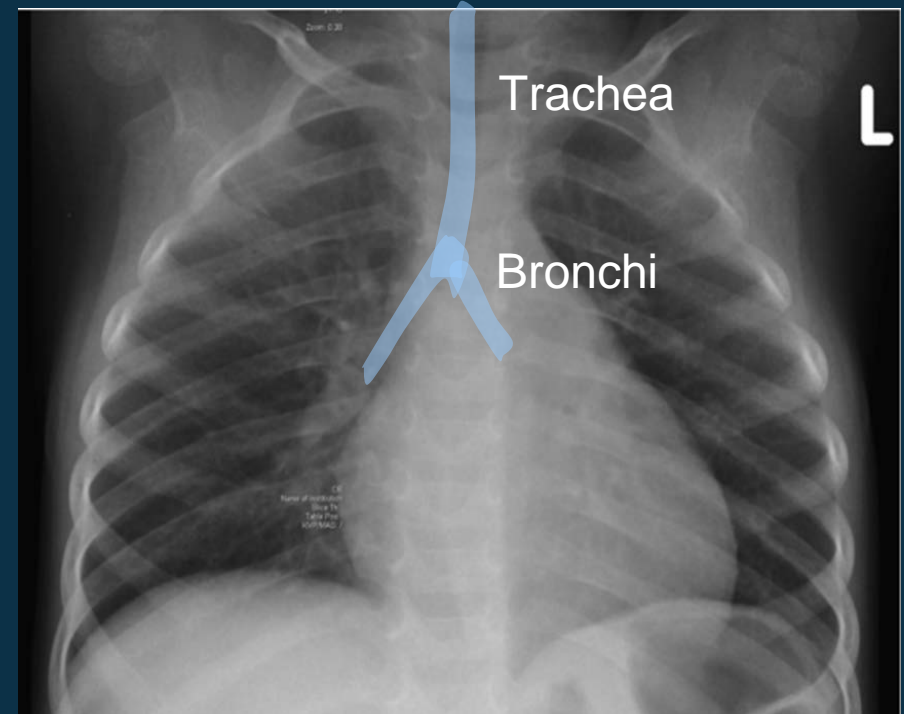
- . 8 or 9th posterior ribs above the diaphragm

2. Rotation

- . Check the symmetry of the anterior rib ends

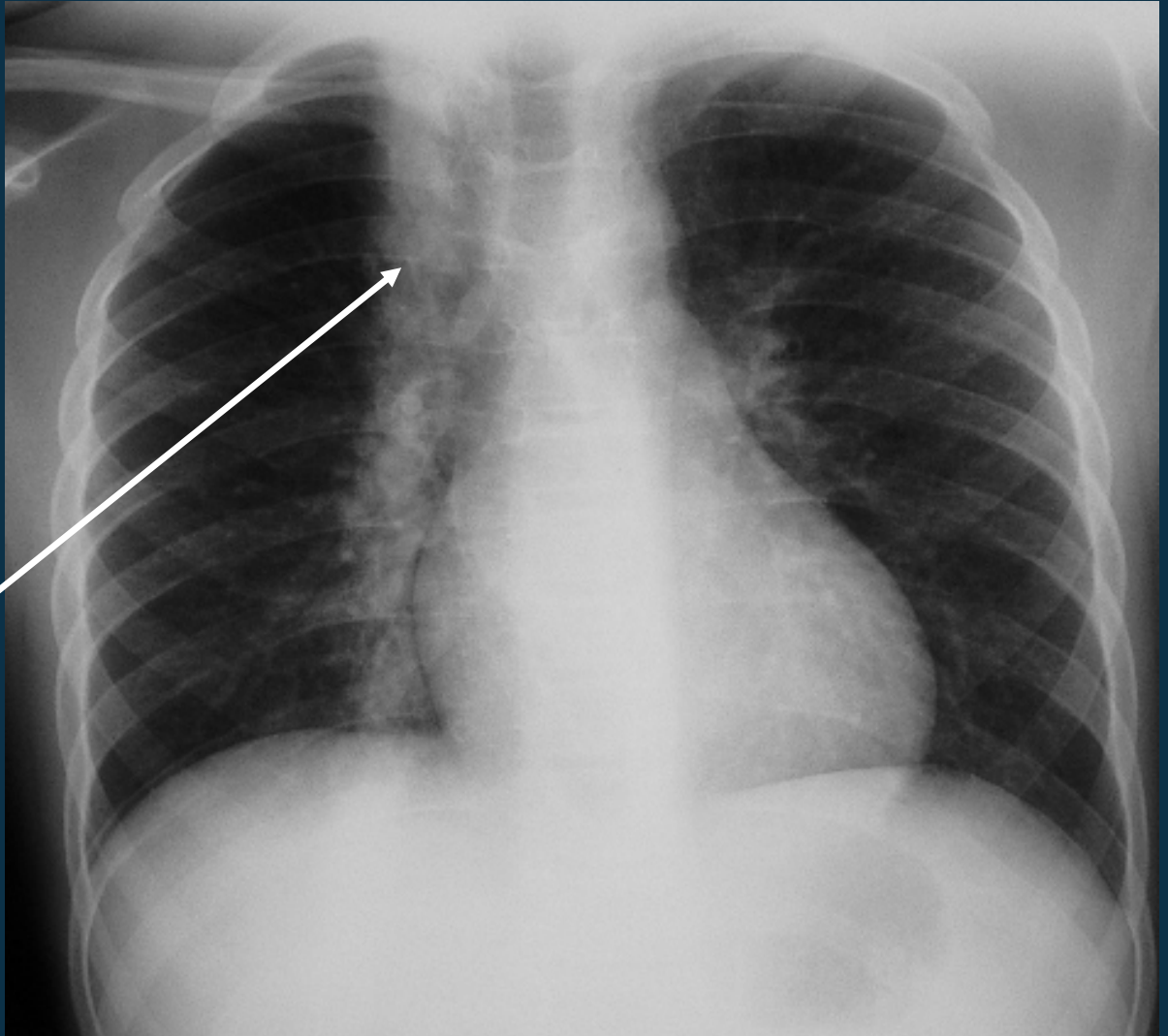
3. Penetration

- . You must be able to clearly see vessels in the central parts of the lungs , the trachea , the bronchi , the diaphragm, the costo-diaphragmatic angles and the spinal structures



Pitfalls and Artefacts

What do you see on this X-ray ?



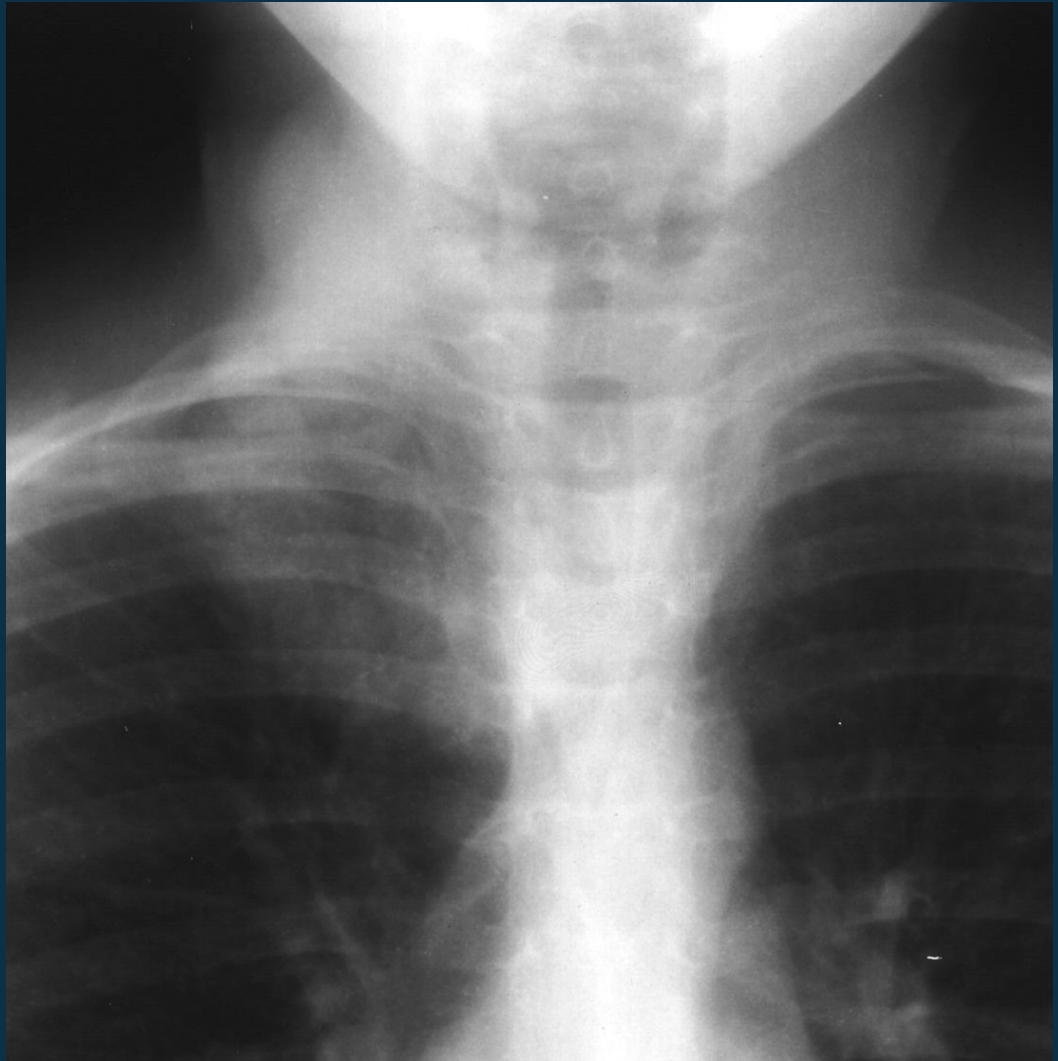
Linear opacity
extending
over the thorax:
. **brade / plait**

Pitfalls and Artefacts

What do you see on this X-ray ?

Blurry opacity
over the thorax:

. **Hair**



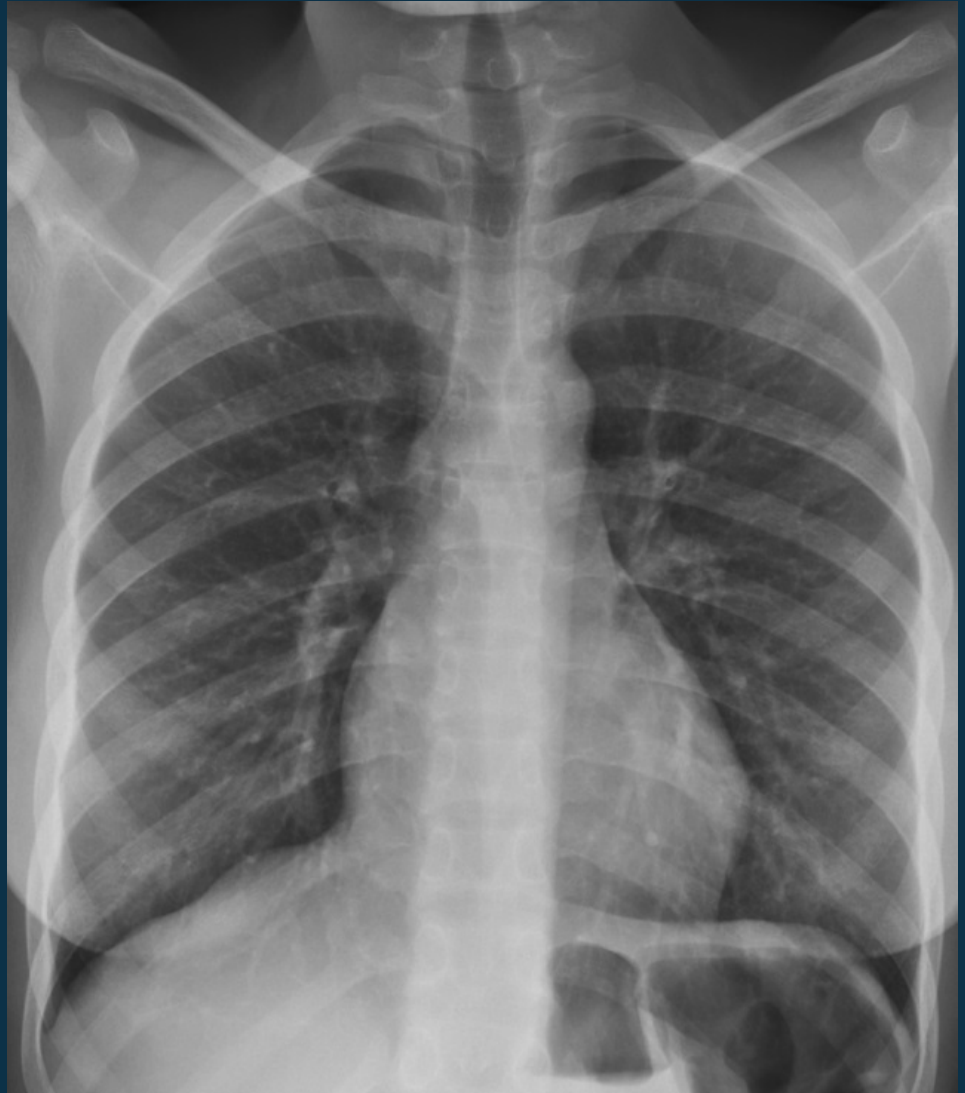Pitfalls and Artefacts

What do you see on this X-ray ?

Lower pulmonary
opacities :

- . **Breasts**

*(could appear from 10
years old)*

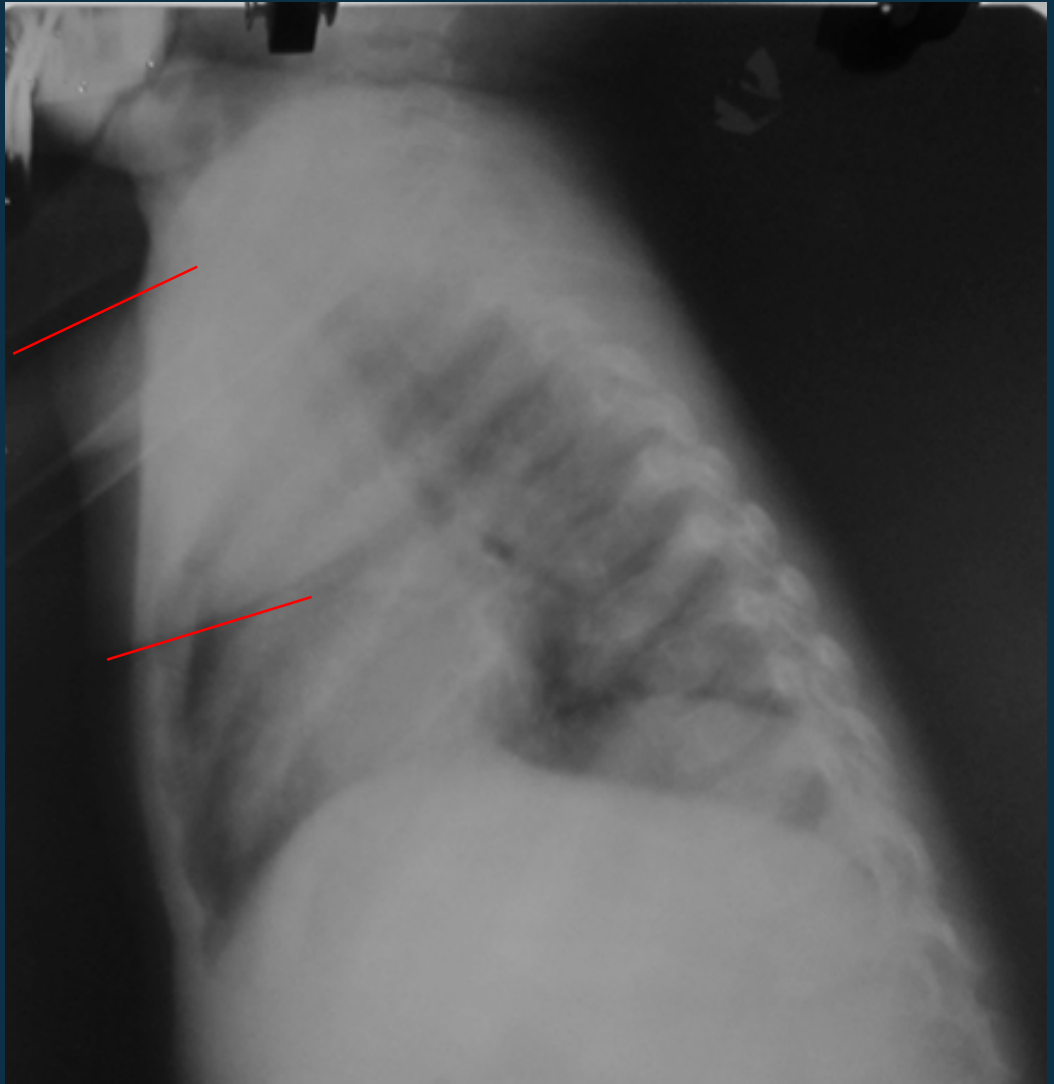


Pitfalls and Artefacts

What do you see on this X-ray ?

Retrosternal opacity ?

. **Arm !!**

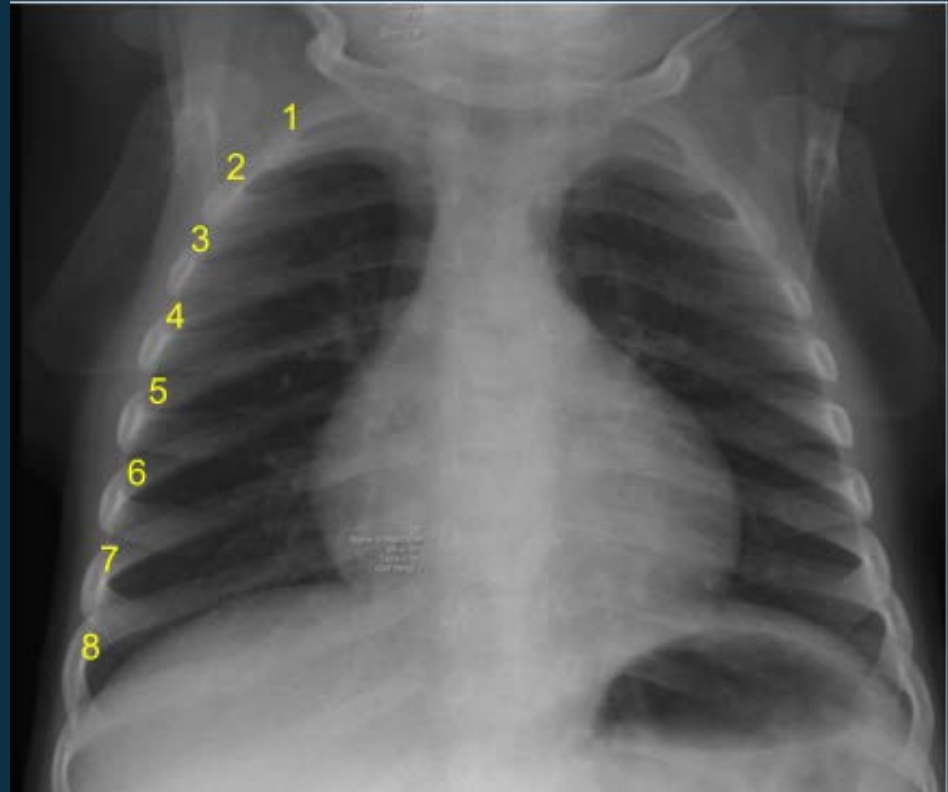
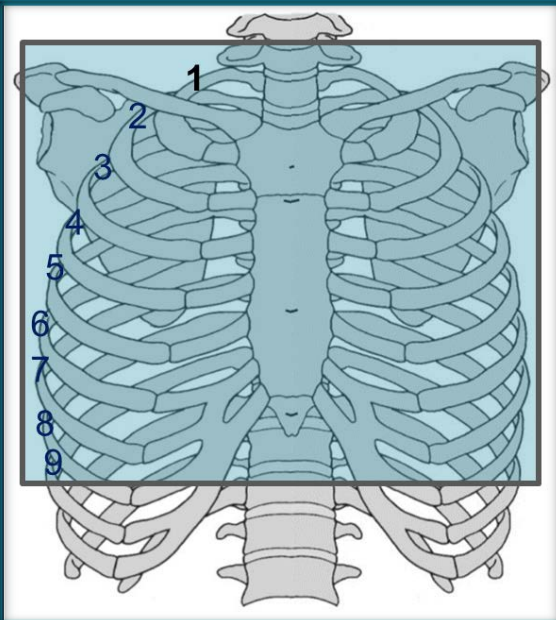


There is adequate inspiration when you can see how many posterior ribs ?

1. Five
2. Six
3. Seven
4. Eight

There is adequate inspiration when you can see how many posterior ribs ?

1. Five
2. Six
3. Seven
4. Eight



Adequate inspiration if you can count 8 or 9 posterior ribs

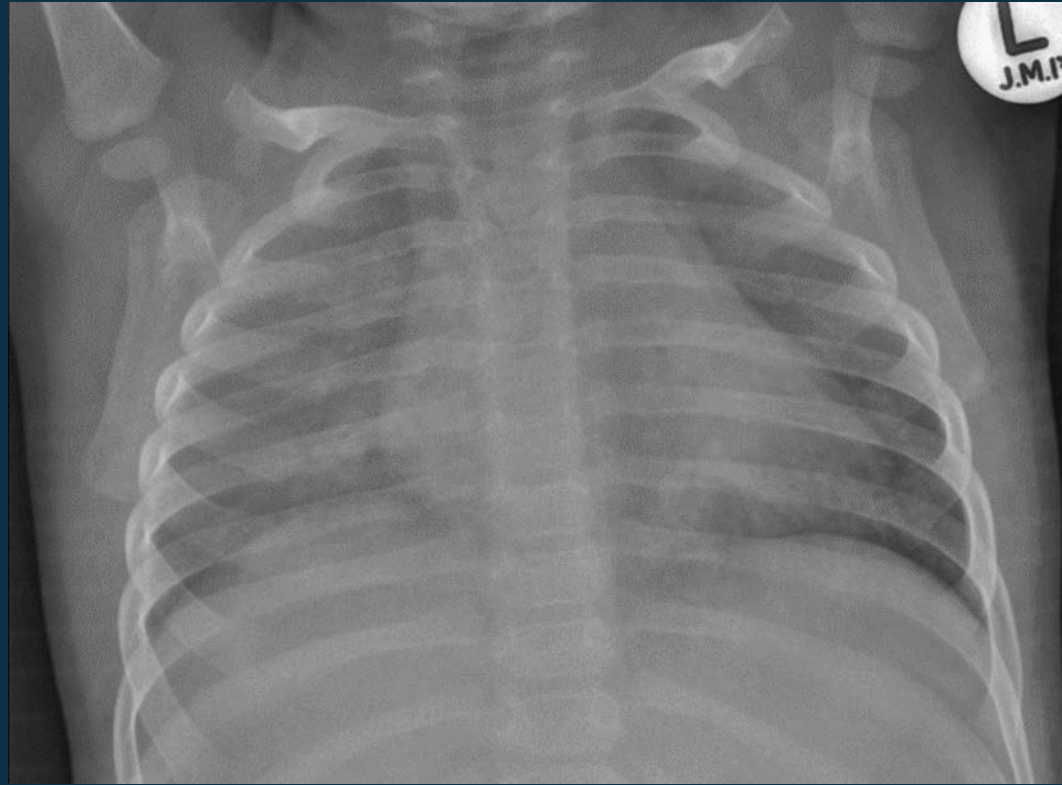
When you count less than 8 posterior ribs it is

1. A normal inspiration view
2. An expiration view

When you count less than 8 posterior ribs it is :

1. A normal inspiration view
2. An expiration view

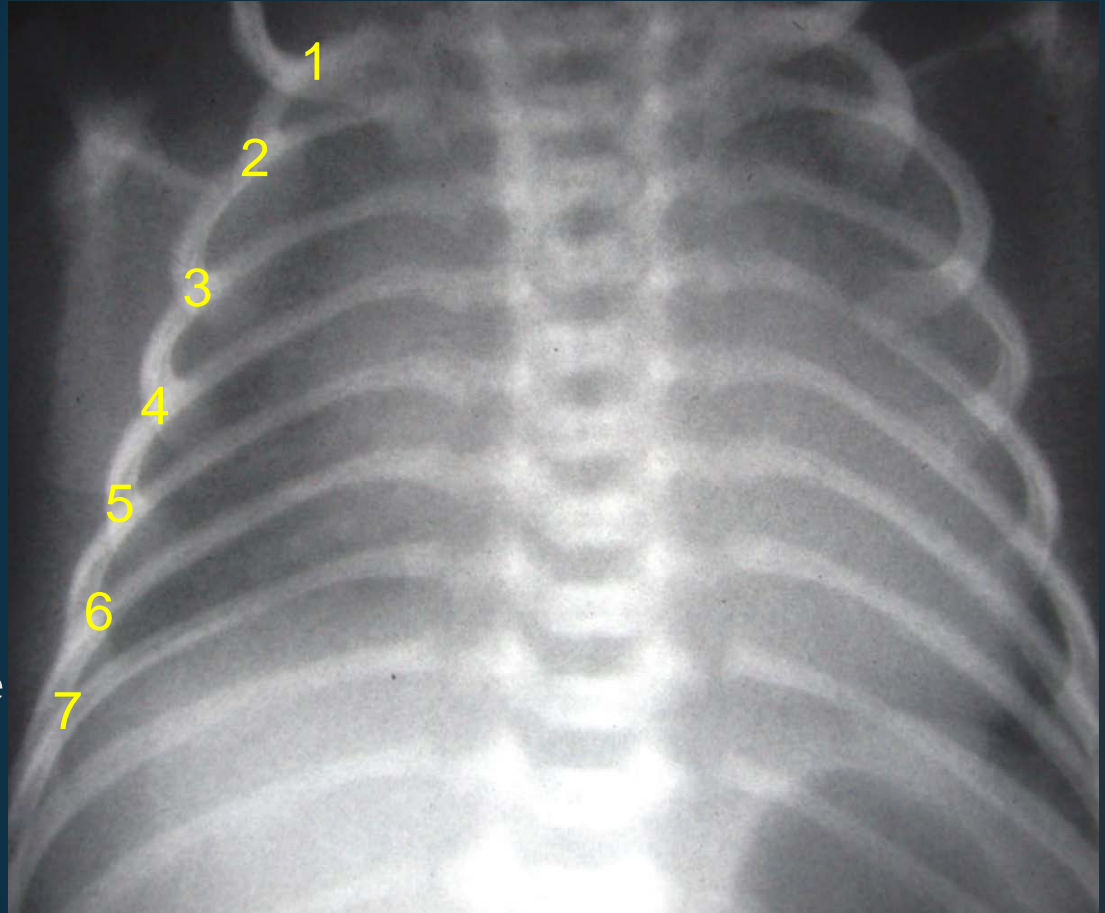
- . Airways are difficult to see
- . Lungs are too white
- . Small lung volumes
- . Increased heart size
- . Buckling of the trachea



Is the CXR readable or not ?

Not readable : expiratory radiograph

- . The lungs appear small in volume and hazy in density
- . No air is visible in the tracheobronchial tree

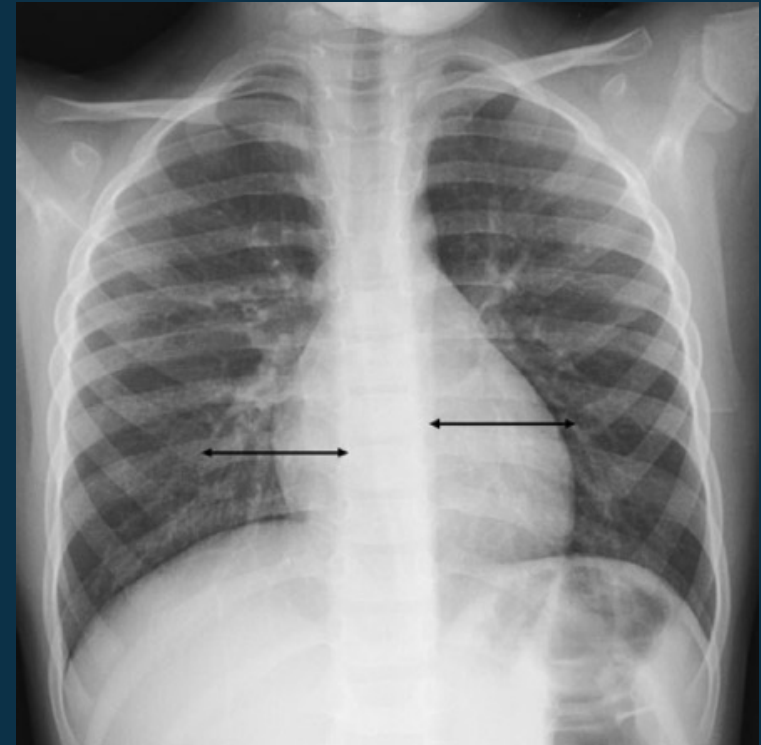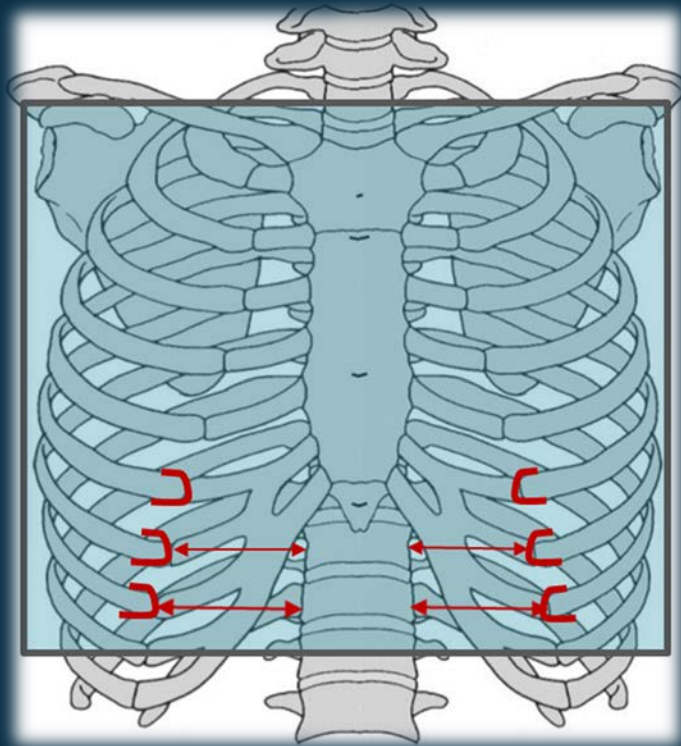


On a child's CXR you check the absence of rotation by

1. Posterior rib ends
2. Anterior rib ends
3. Clavicle ends

On a child's CXR you check the absence of rotation by

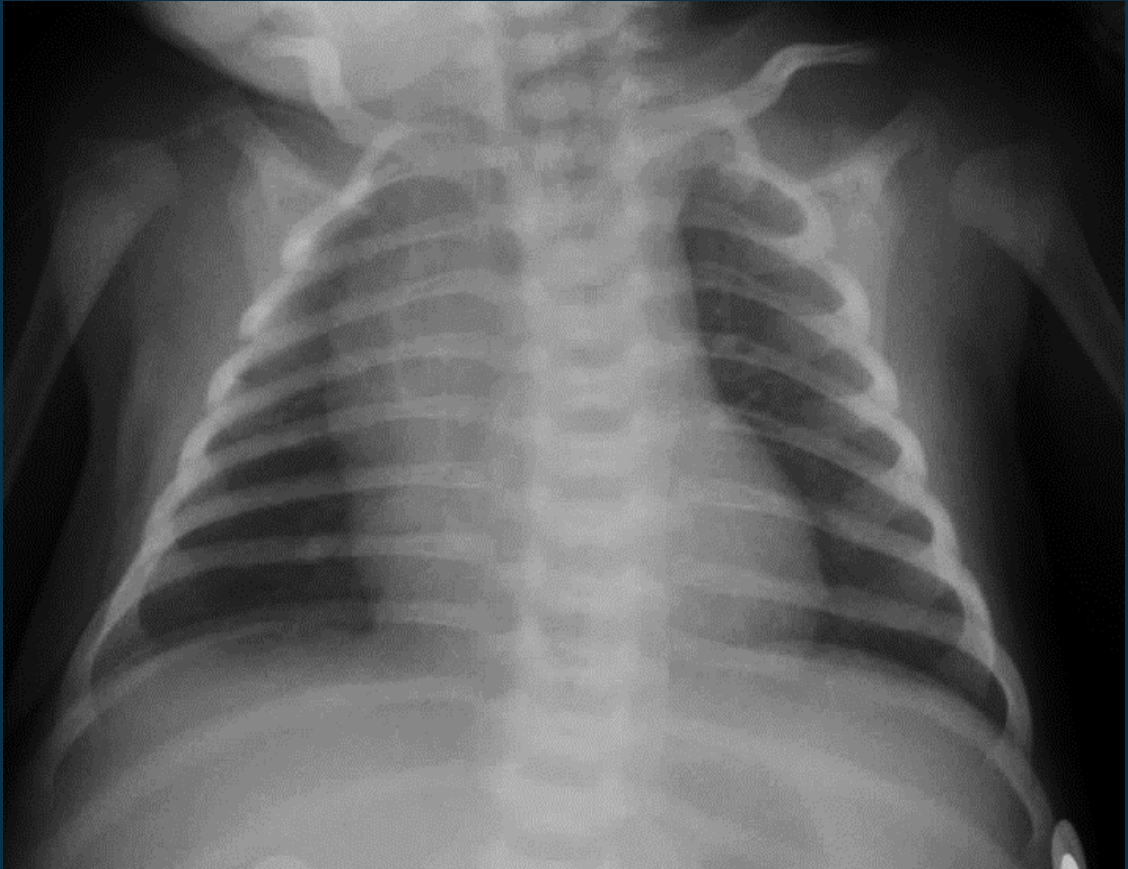
1. Posterior rib ends
2. Anterior rib ends
3. Clavicle ends



Proper CXR despite
asymmetry of clavicles

What is wrong with this child's CXR ?

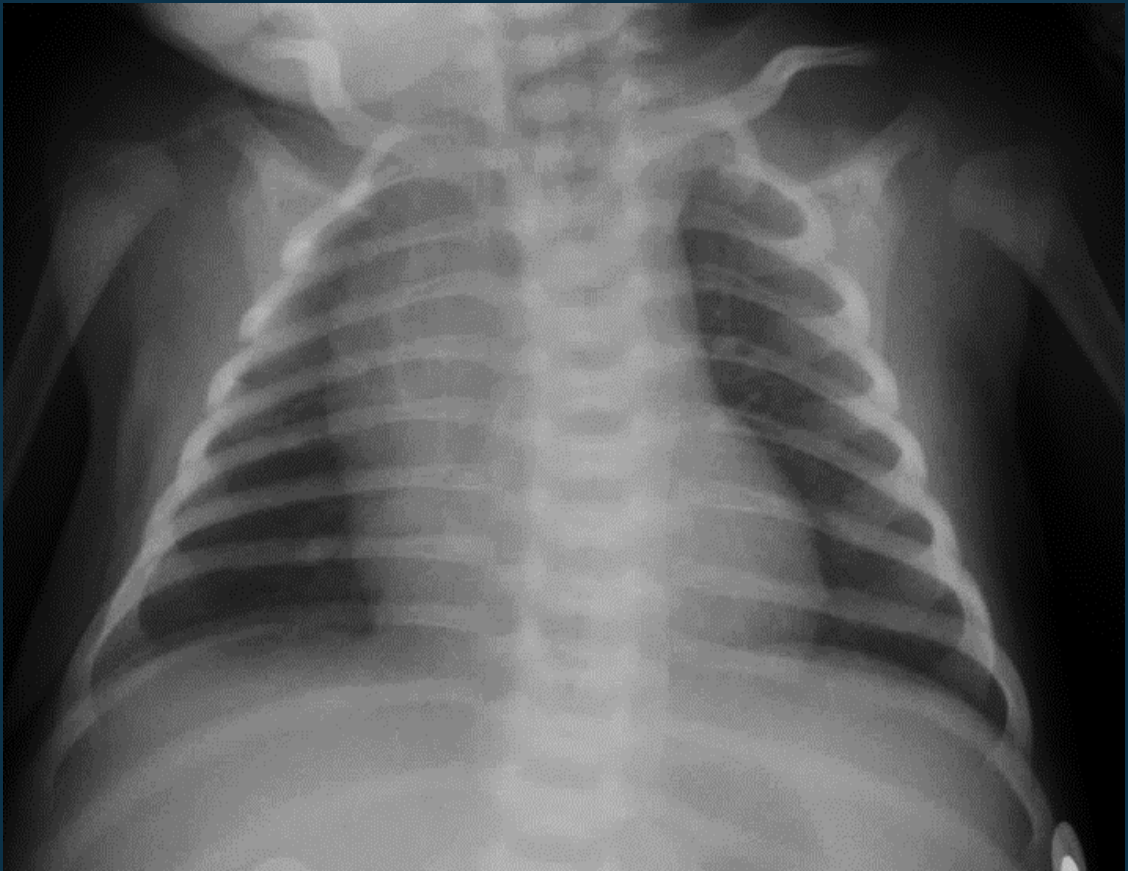
1. Rotated to the left
2. Rotated to the right



What is wrong with this child's CXR ?

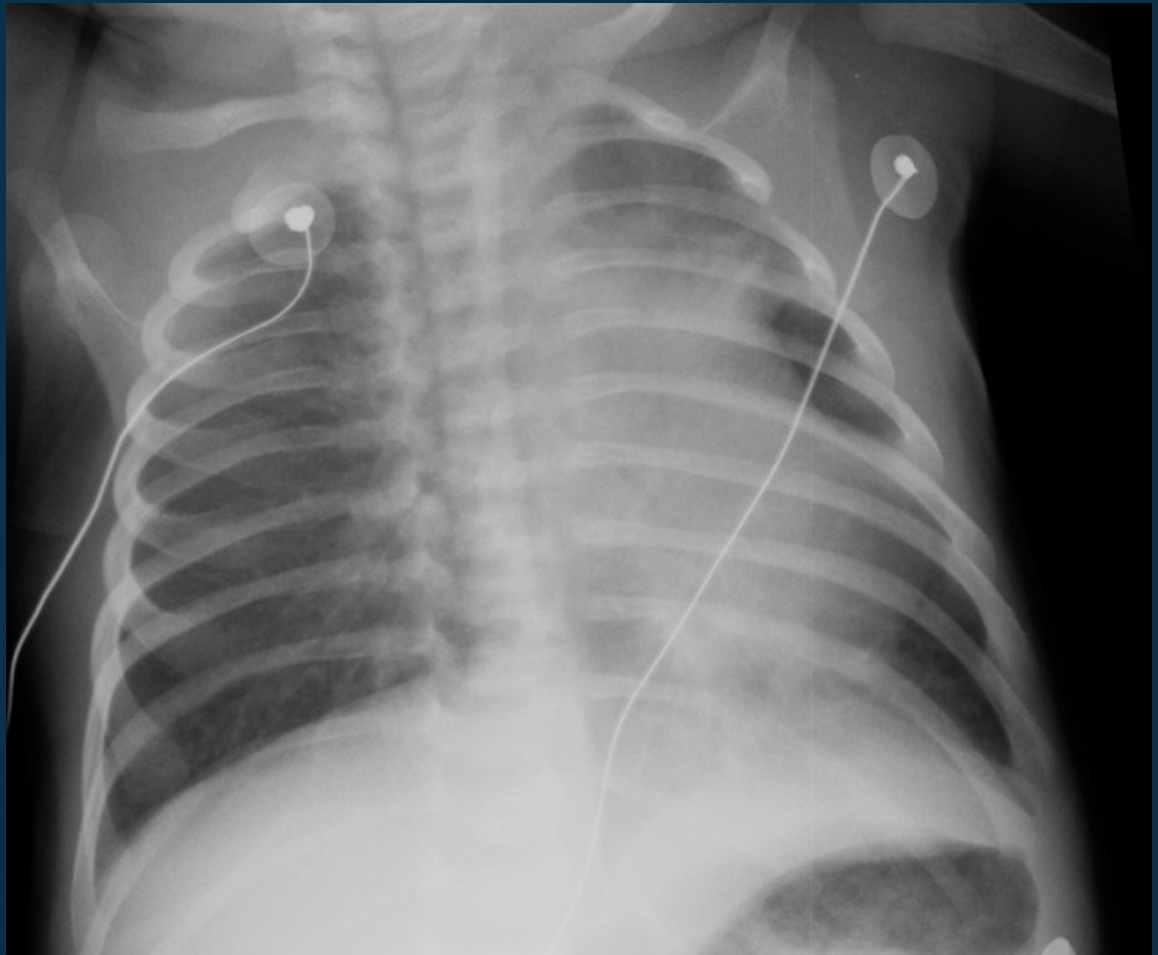
1. Rotated to the left
2. Rotated to the right

Rotation to the right makes the heart appear central



What is wrong with this child's CXR ?

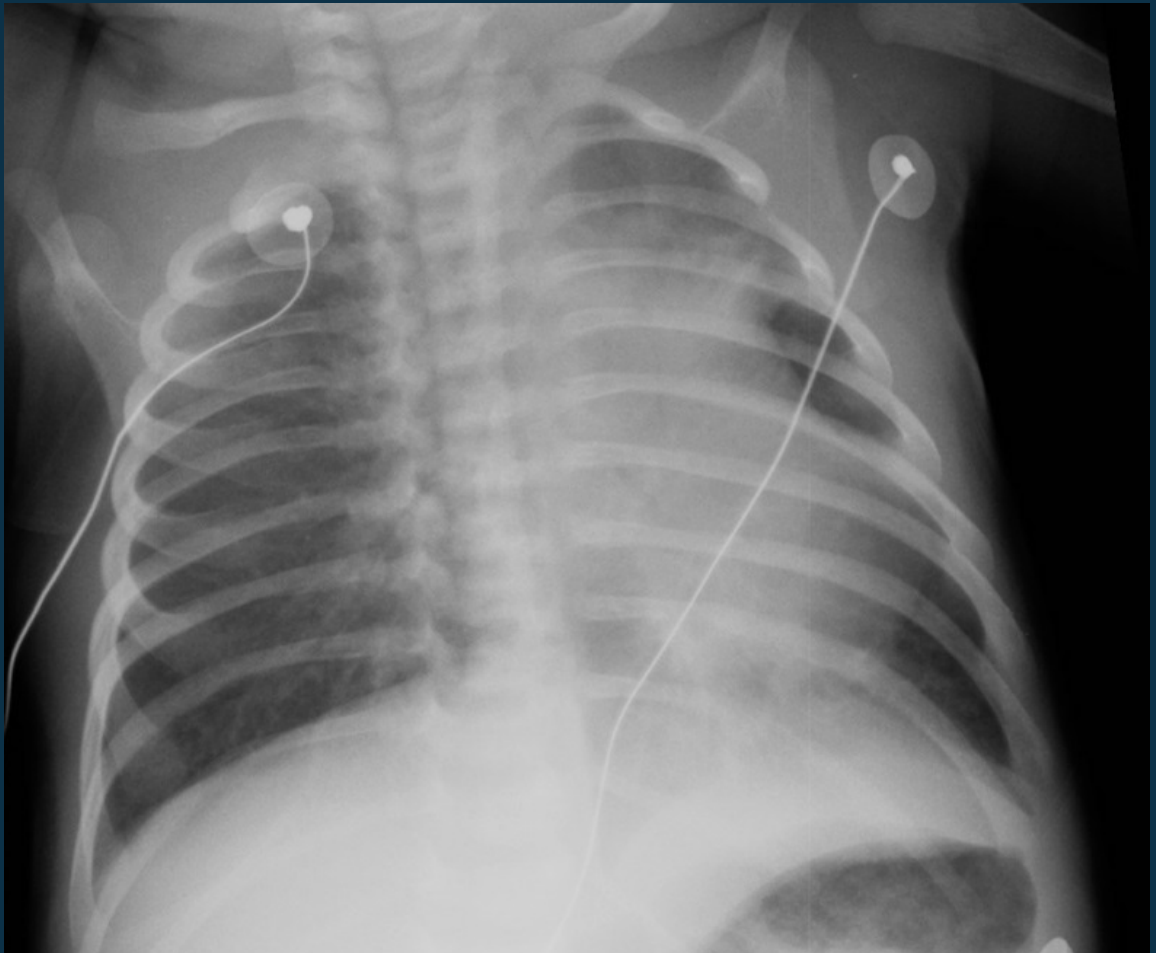
1. Rotated to the left
2. Rotated to the right



What is wrong with this child's CXR ?

1. Rotated to the left
2. Rotated to the right

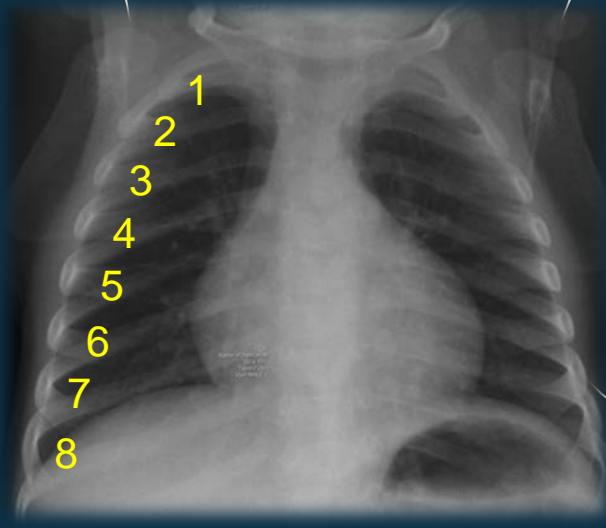
Rotation to the left makes the heart look large and can make the right heart border disappear.



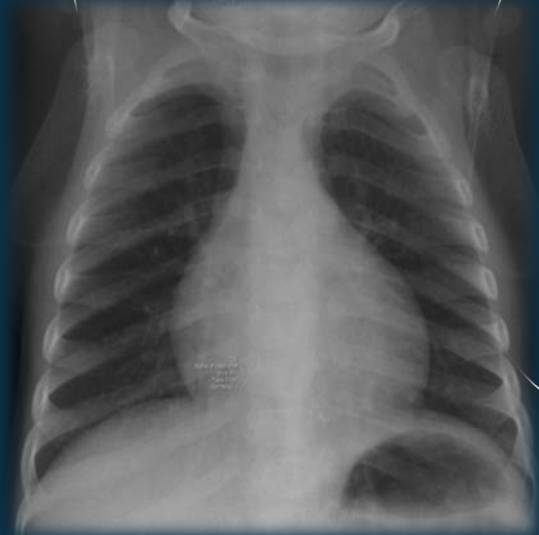

Is the CXR readable or not ?

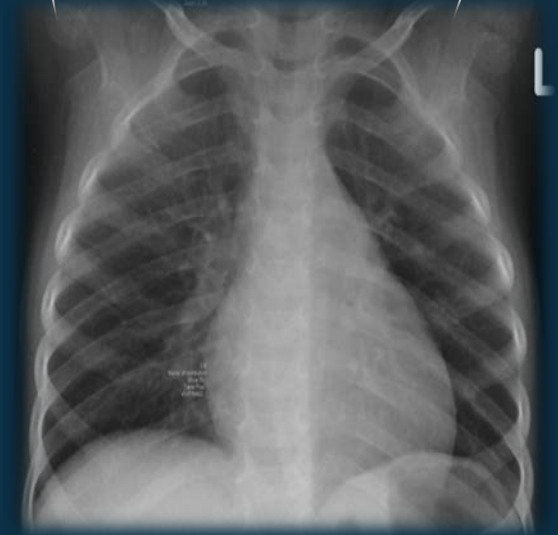The technical quality factors will help you to decide if a CXR is readable or not



Adequate inspiration
count 8 or 9 posterior ribs



No rotation
Anterior rib ends equidistant from pedicles

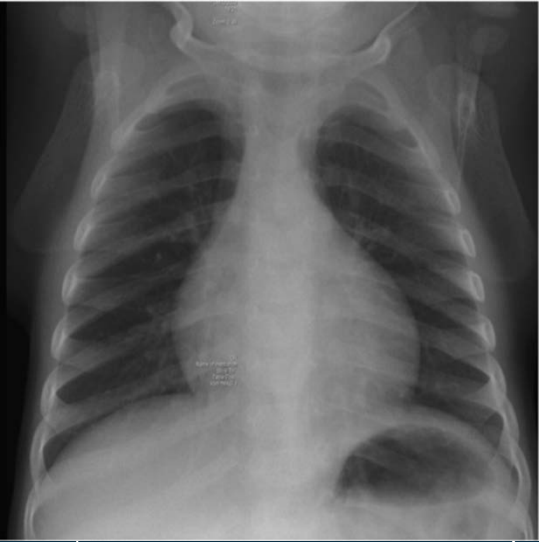

Good penetration
You can clearly see the trachea, bronchi, diaphragm, spinal structures

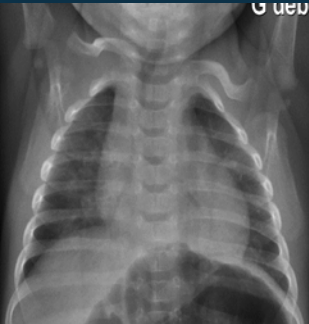Are both the AP and the lateral readable?

Yes

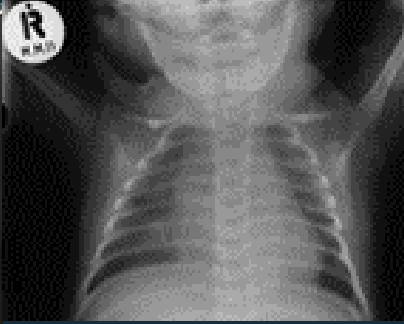No, not readable : redo CXR



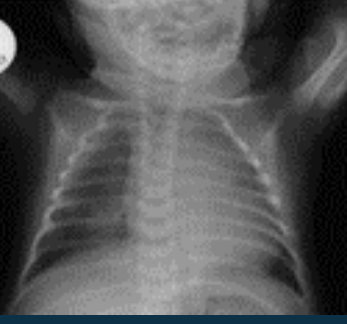Yes: good quality



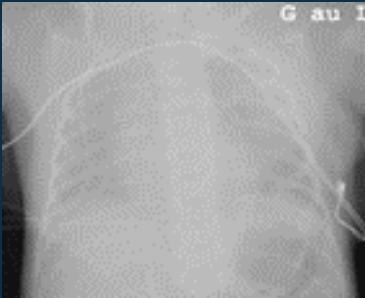Poor inspiration



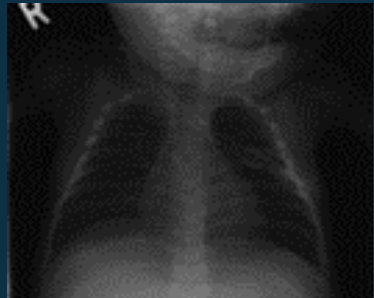rotated right



rotated left



Underpenetration



Overpenetration

Module 1 How to read a CXR

Chap1: Technical and anatomical aspects

Chap2: Systematic approach to CXR interpretation

Part1. Quality factors

Part2. Normal CXR

Part3. First circle

1. Soft part of the chest wall
2. Diaphragmatic areas
3. Bony Thorax abnormalities

Part4. Second circle

4. Lung
5. Pleura

Part5. Third circle

6. Airways
7. hili and Mediastinum
8. Lymph nodes
9. Heart

Part6. The hidden areas

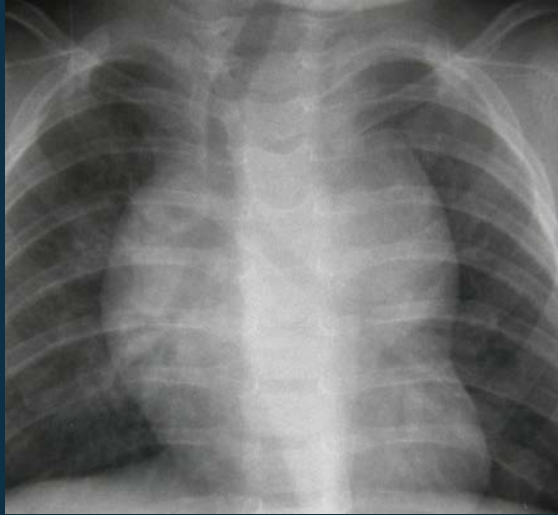
Part7. Conclusion



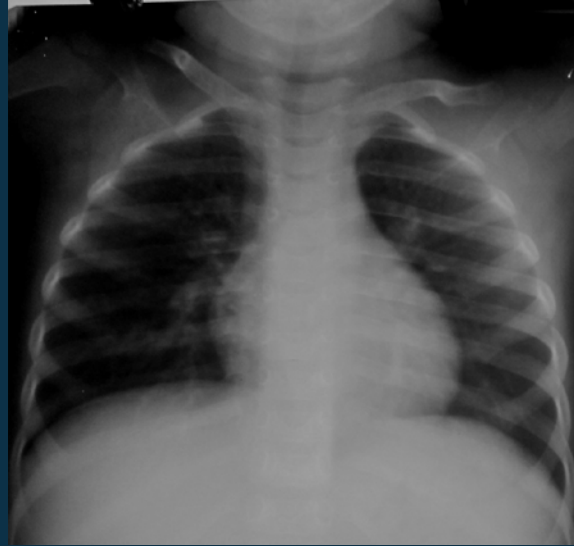Is the CXR normal ?

Normal CXR according to the age - AP

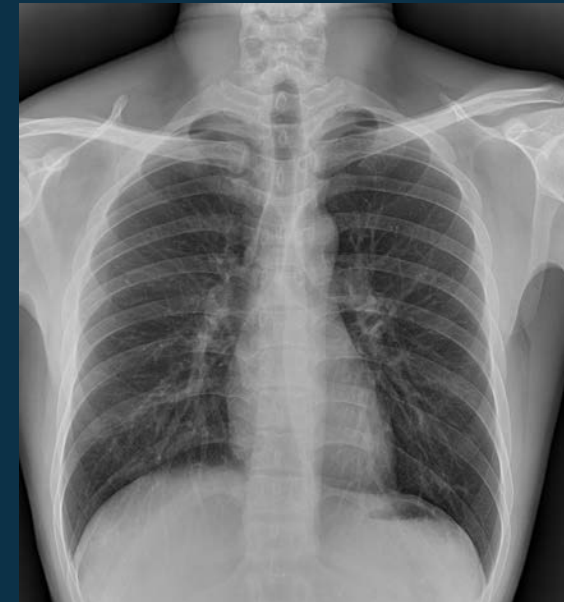Few months years old



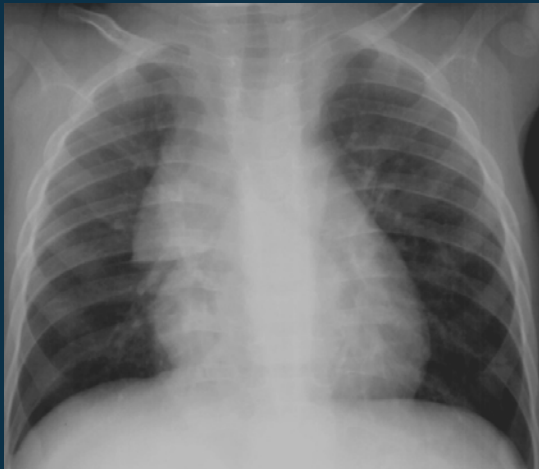
2 -3 years od years old



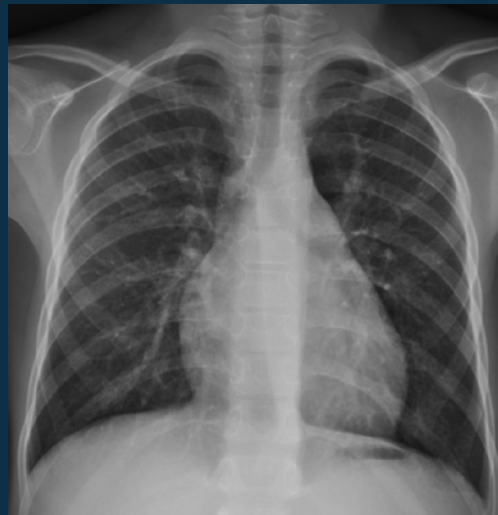teenager



1 to 2 years old

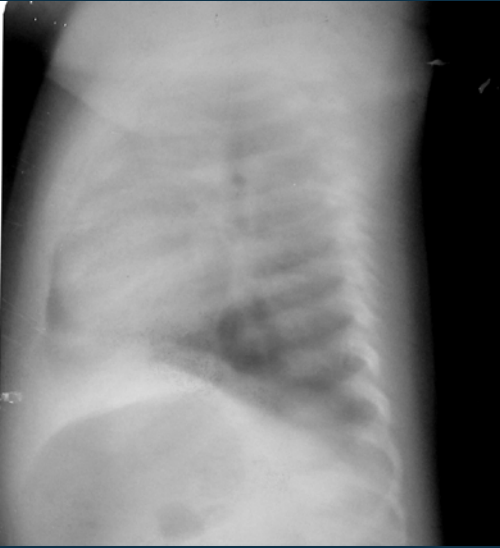

4-5 years old

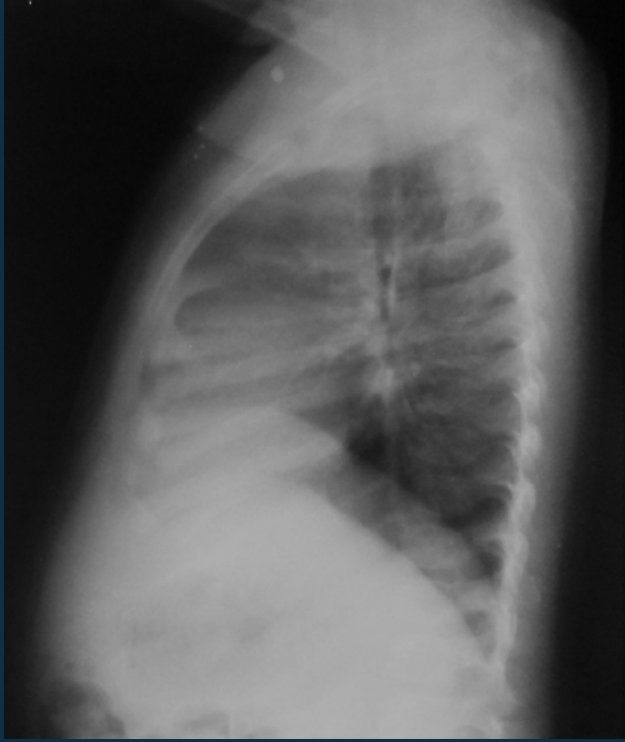


Normal CXR according to the age - profil

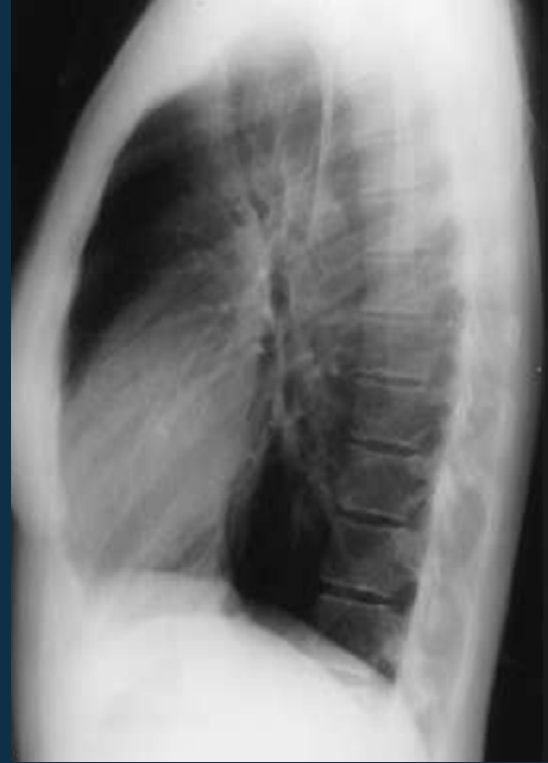Few months years old



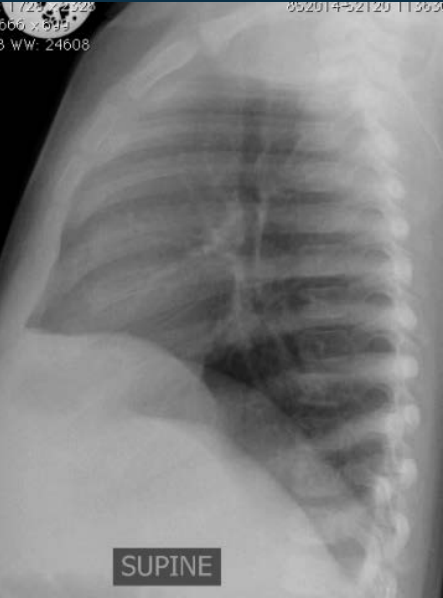2 -5 years od years old



teenager



1 to 2 years old



Systematic approach to CXR – check list

1. Check the identification: name, date, supine or erect
2. Check the Clinical history and findings
3. Check the quality factors inspiration, rotation, penetration
4. **Assess:**
 - . **1st circle**
 - . **2nd circle**
 - . **3rd circle**
 - . **Hidden areas**

First Circle:

1. Soft tissue of the chest wall
2. Diaphragmatic areas
3. Bony thorax abnormalities

Second Circle:

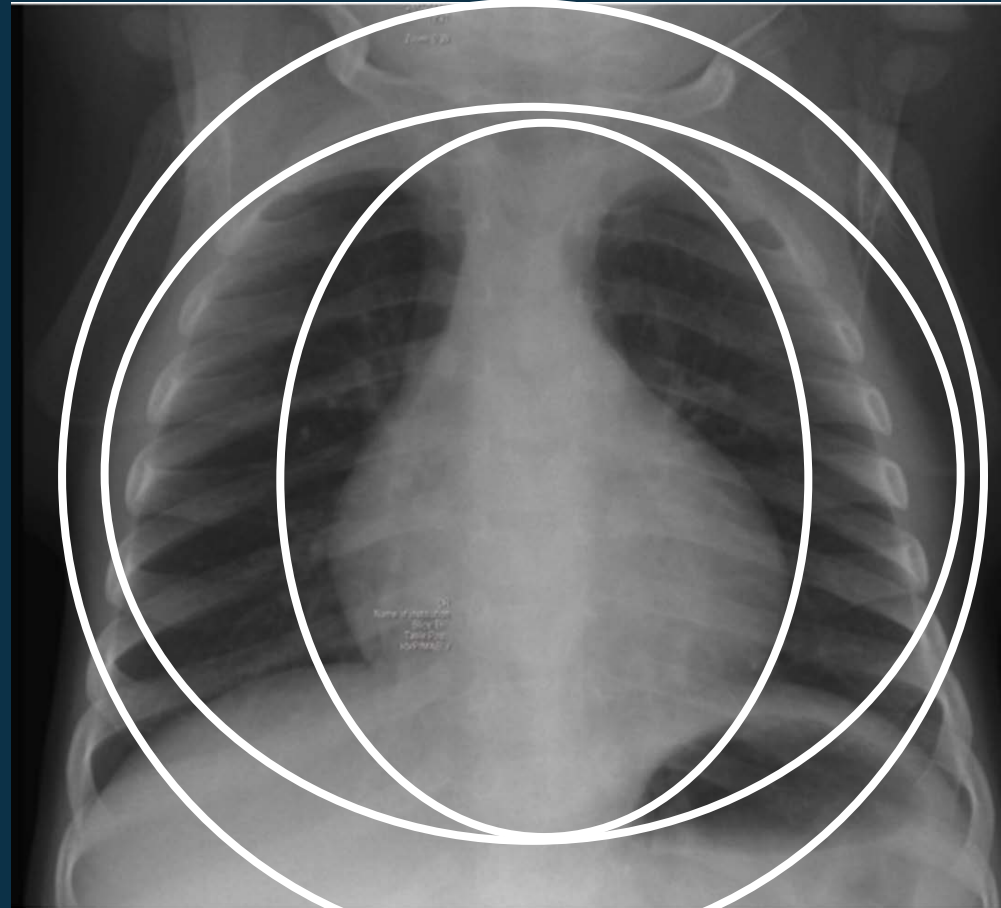
4. Lung
5. Pleura

Third circle:

6. Airways
7. Hilar and mediastinum
8. Lymph nodes
9. Heart

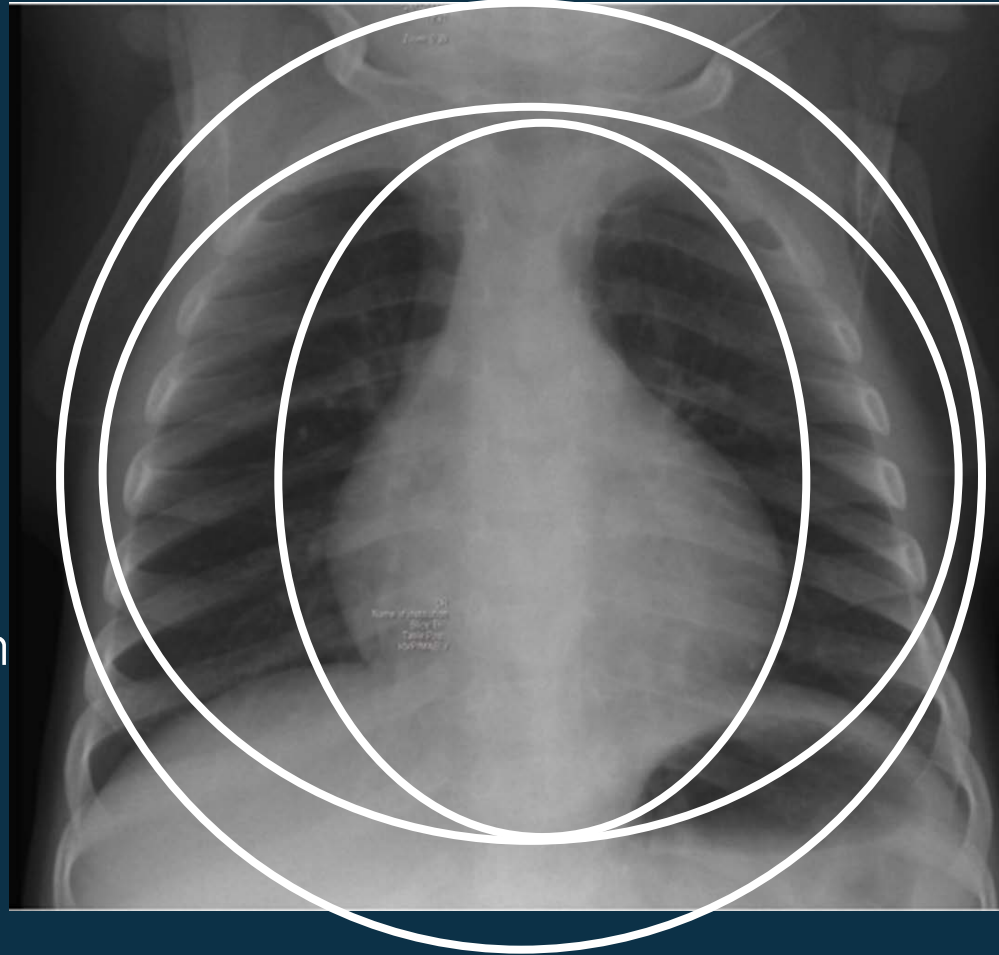
Hidden areas:

Worth a second look: apices, hilar regions, retrocardiac areas (left and right), below diaphragm



In each circle look for the 6 CXR features that are suggestive of TB

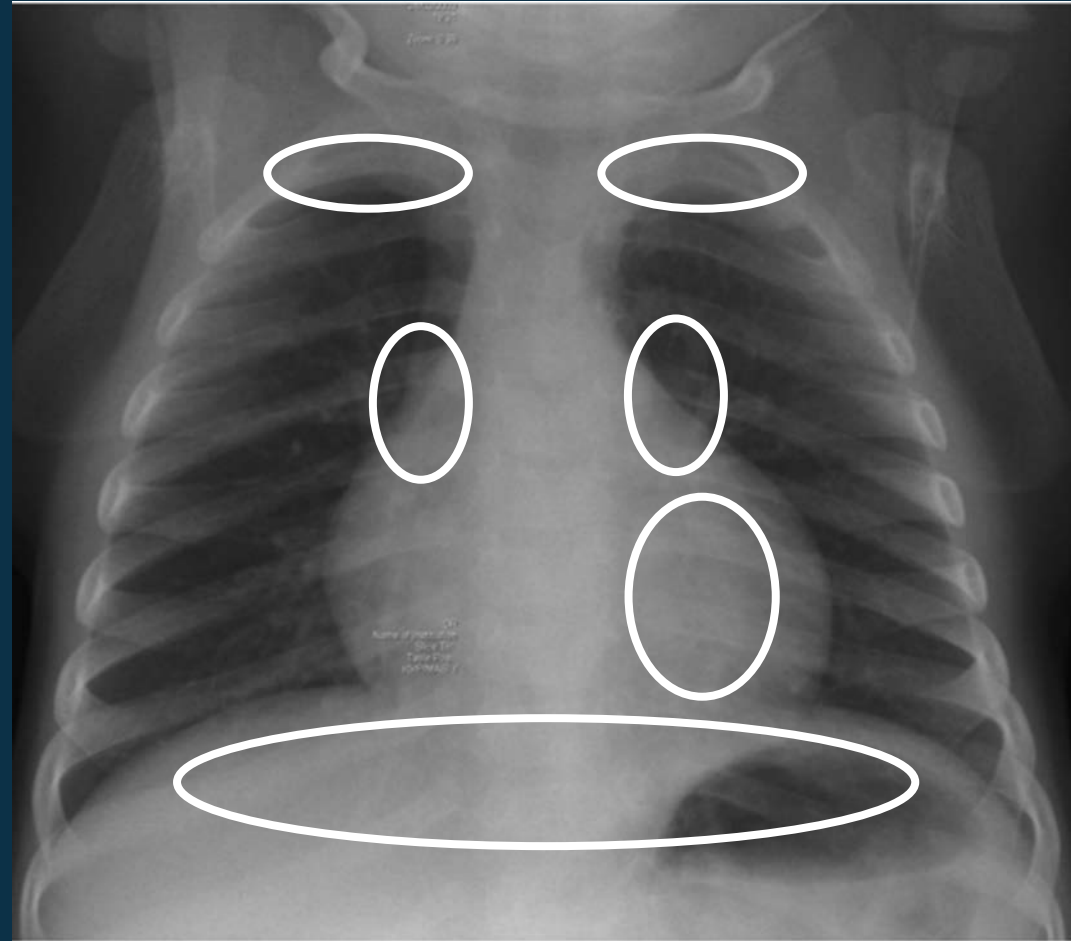
1. Enlarged lymph nodes
(lateral view required)
2. Alveolar opacity in the lung
3. Airway compression
4. Cavitation
5. Pleural or Pericardial effusion
6. Miliary



The hidden areas: worth a second look

There are some areas that need special attention, because pathology in these areas can easily be overlooked:

- . Apical zones
- . Hilar zones
- . Retro-cardiac zone
- . Sub-diaphragmatic zone



Module 1 How to read a CXR

Chap1: Technical and anatomical aspects

Chap2: Systematic approach to CXR interpretation

Part1. Quality factors

Part2. Normal CXR

Part3. First circle

1. Soft part of the chest wall
2. Diaphragmatic areas
3. Bony Thorax abnormalities

Part4. Second circle

4. Lung
5. Pleura

Part5. Third circle

6. Airways
7. hili and Mediastinum
8. Lymph nodes
9. Heart

Part6. The hidden areas

Part7. Conclusion



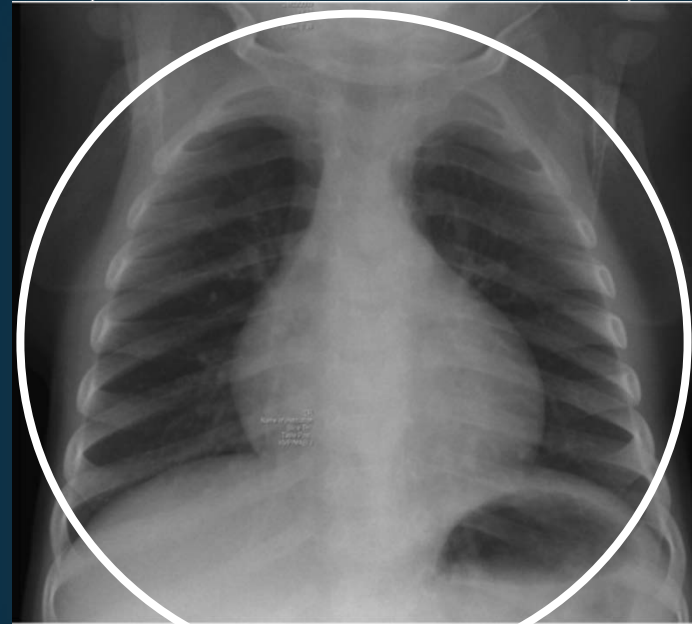Now you are ready to test the systematic approach
We will go through these 3 circles,
step by step with a series of case studies

Look for the 6 CXR features that are suggestive of TB

First Circle



1. Soft tissue of the chest wall
2. Diaphragmatic areas
3. Bony thorax abnormalities



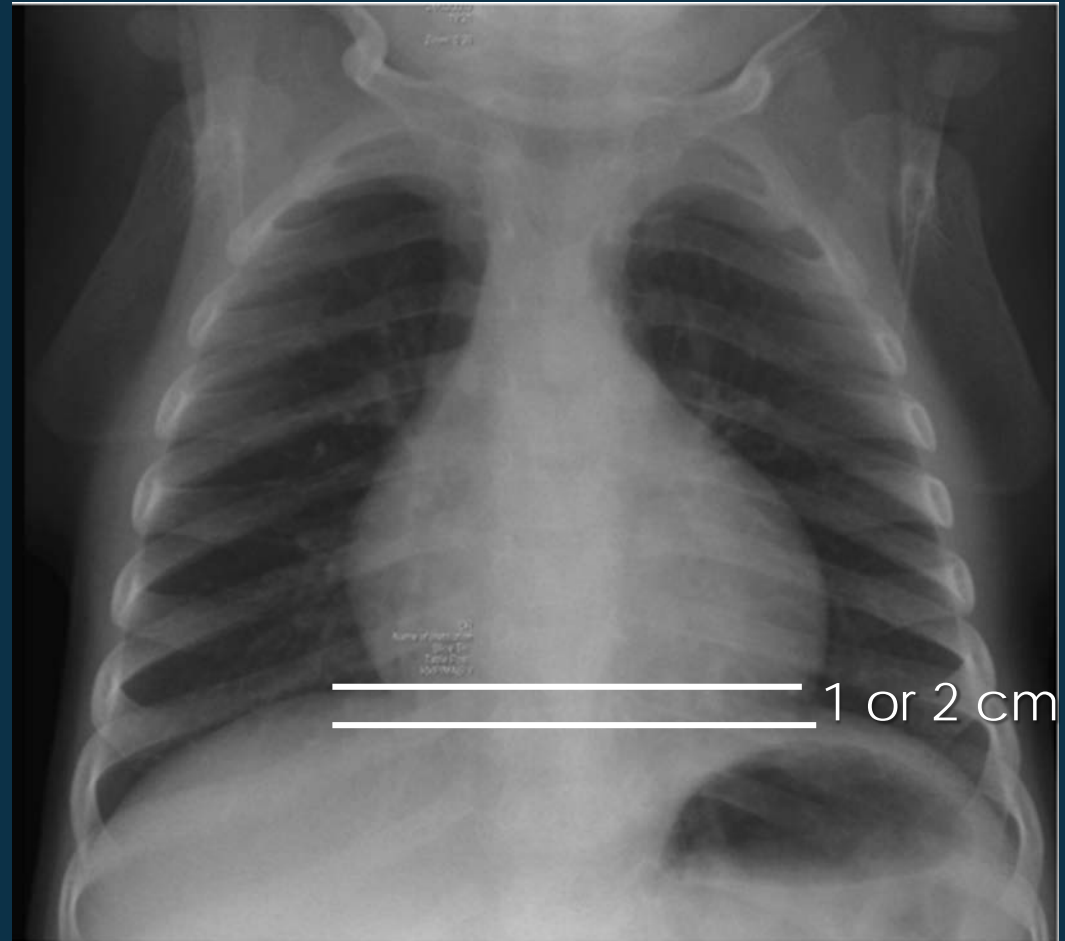
Focus on the diaphragmatic areas

Diaphragm : position

- . The hemidiaphragms have a slightly domed contour
- . The right side is higher than the left side (liver)

Costophrenic angles

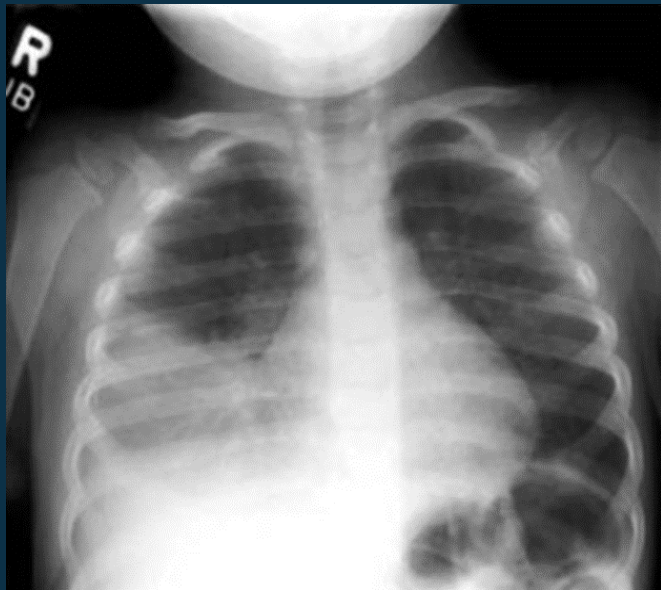
- . Fairly deep and sharply pointed



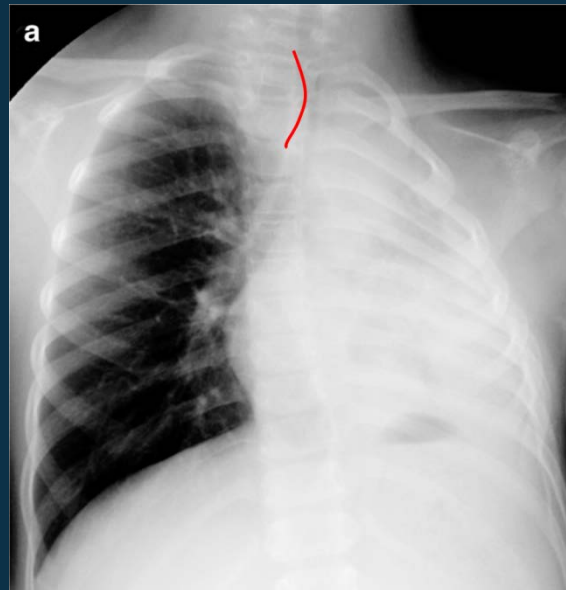
Check that the stomach bubble on the left is in the correct position

What can change the appearance of the diaphragm ?

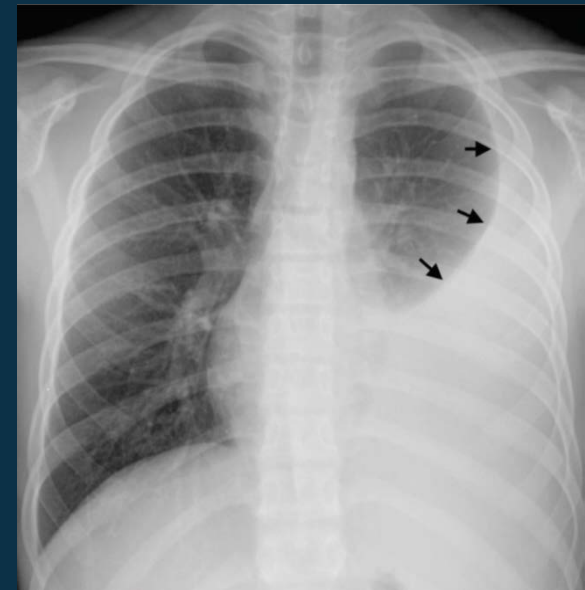Opacities can obscure the diaphragm partially or completely



Alveolar opacity



Total lung opacity



Pleural opacity

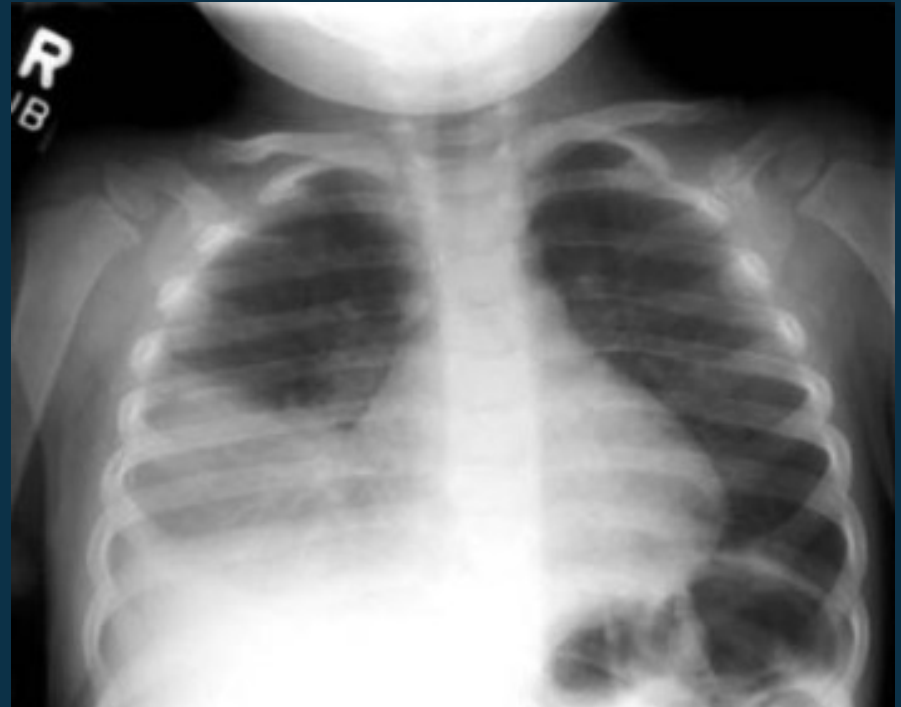What do you see on this CXR ?

Is the CXR readable ?

. yes

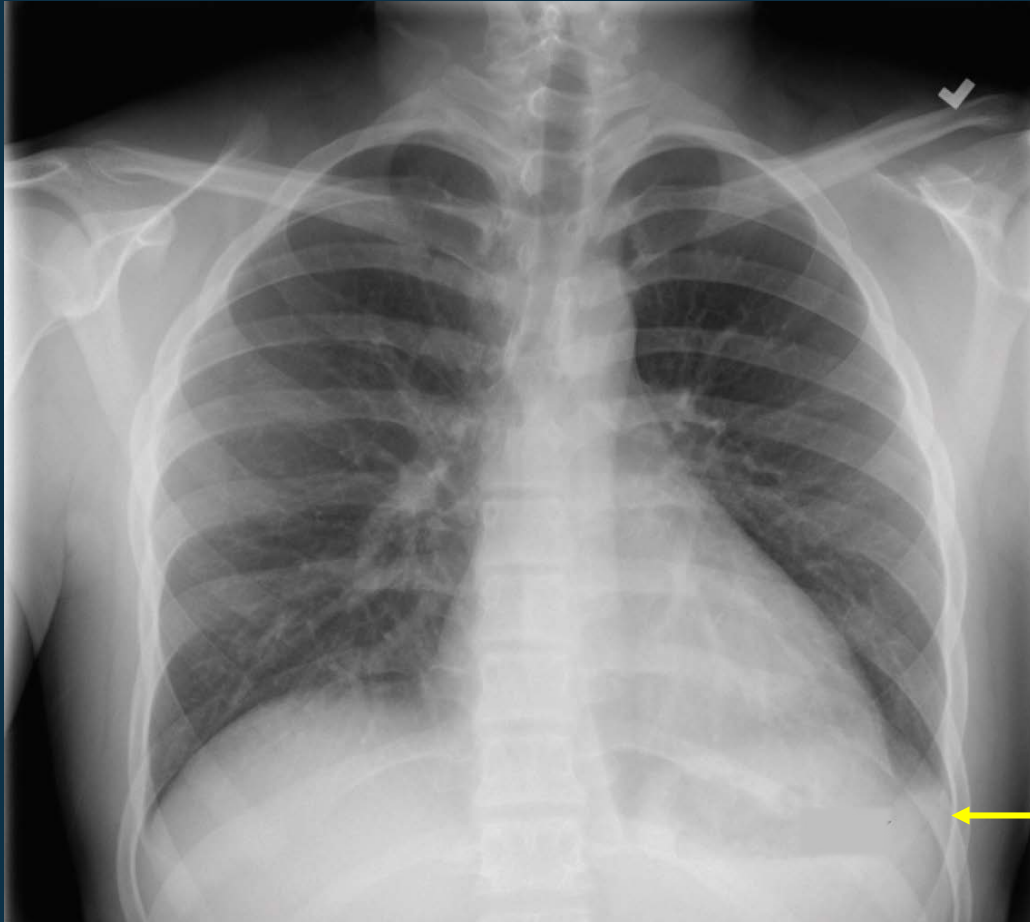
Is there an abnormality on the CXR ?

. Alveolar opacity of the right lung



Alveolar opacity of the lung tissue

Shortness of breath




What do you see in this CHR ?

. Blunting of the costophrenic angle

What is your diagnosis ?

Frontal view small pleural effusion

First circle

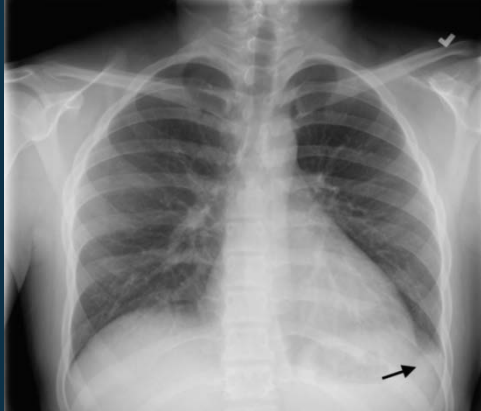


Assess the diaphragm and
costophrenic angles

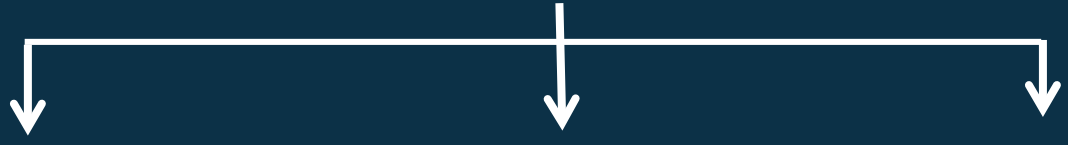Key points - First circle

Assess costophrenic angles
↓

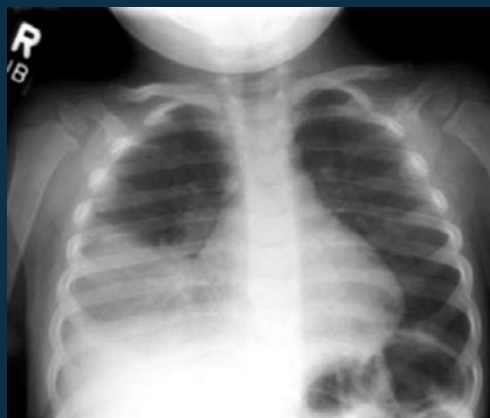
Are they blunted?



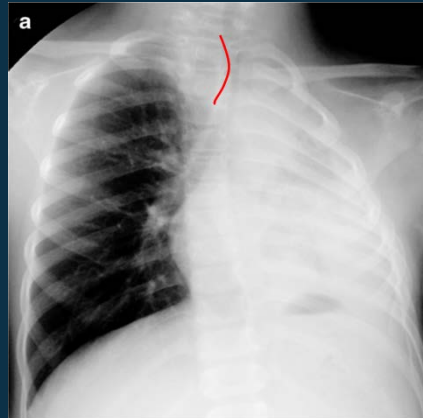
Look for opacities obscuring the diaphragm



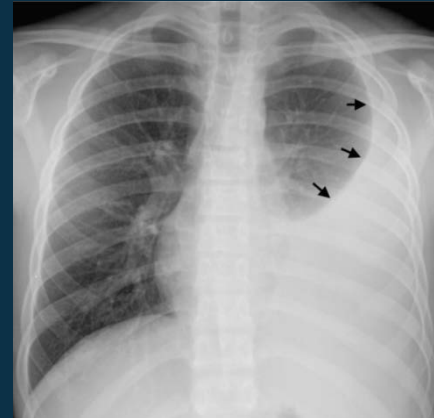
Alveolar opacity



Lung opacity



Pleural opacity



Check diaphragmatic position:

- . Elevated?
- . Flattened?
- . Increased density over or under the diaphragm?

Module 1 How to read a CXR

Chap1: Technical and anatomical aspects

Chap2: Systematic approach to CXR interpretation

Part1. Quality factors

Part2. Normal CXR

Part3. First circle

1. Soft part of the chest wall
2. Diaphragmatic areas
3. Bony Thorax abnormalities

Part4. Second circle

- 4. Lung**
- 5. Pleura**

Part5. Third circle

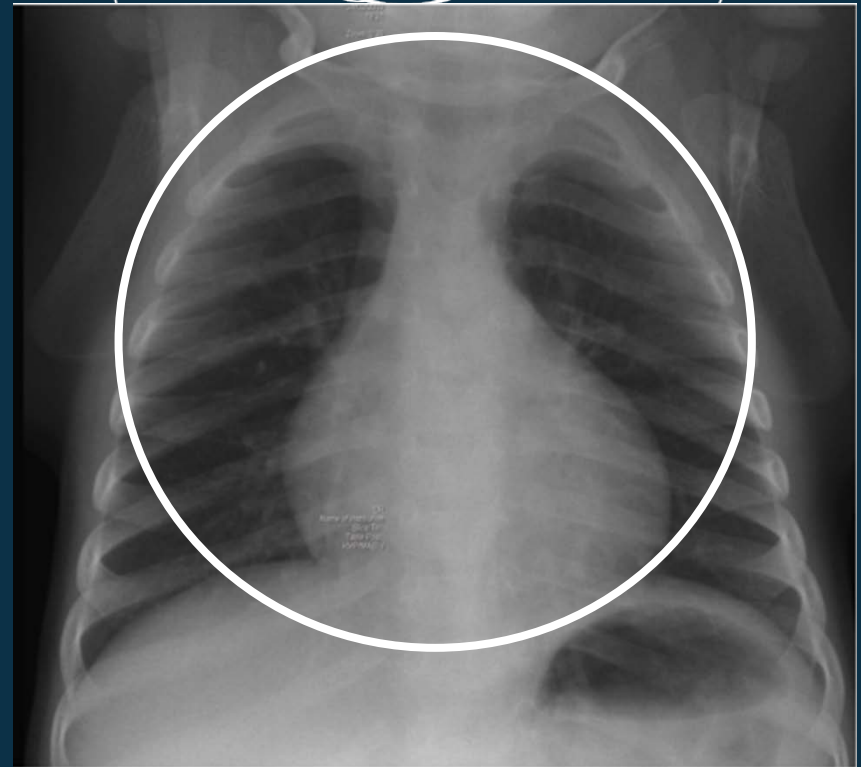6. Airways
7. Hili and Mediastinum
8. Lymph nodes
9. Heart

Part6. The hidden areas

Part7. Conclusion

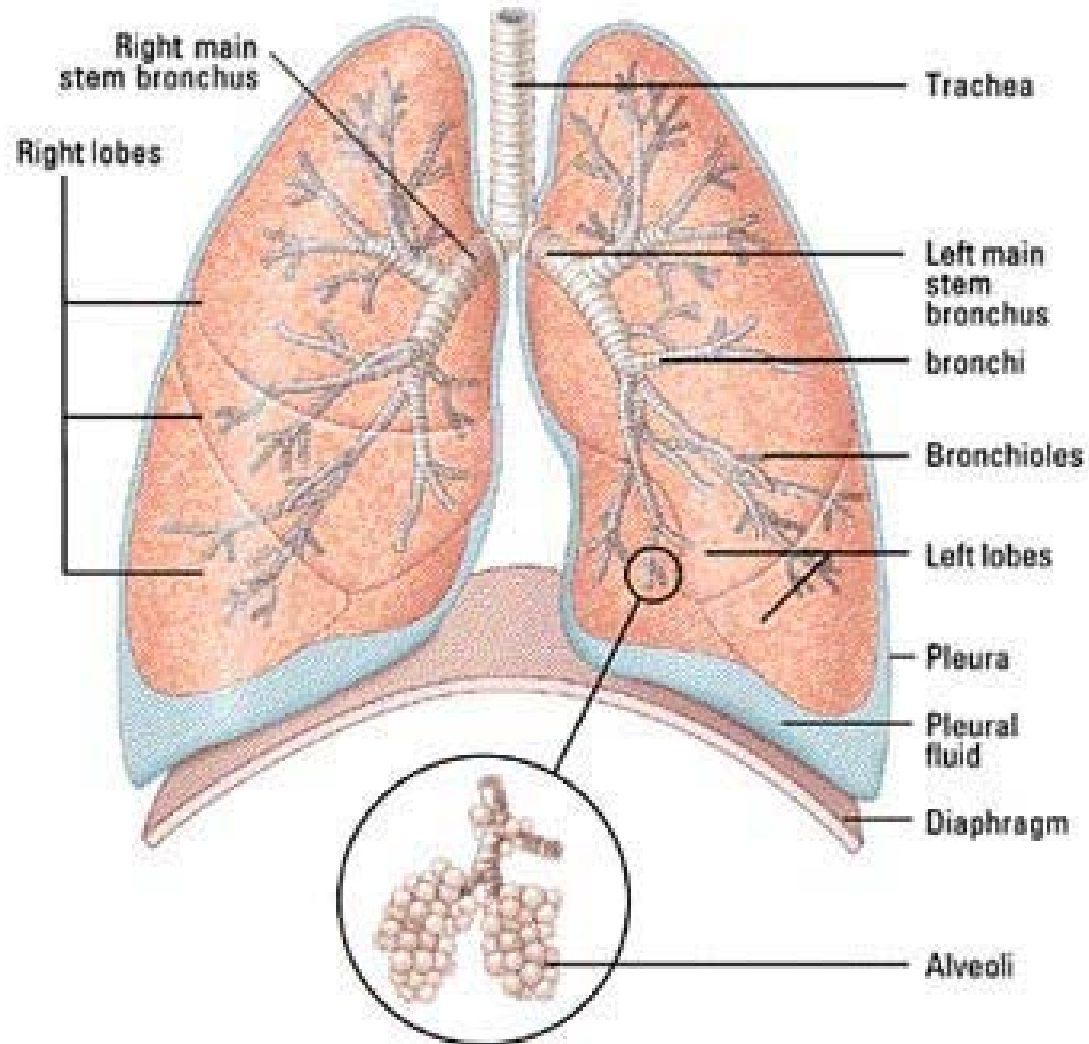
Second Circle

4. Lungs hyperlucencies and opacities
5. Pleura



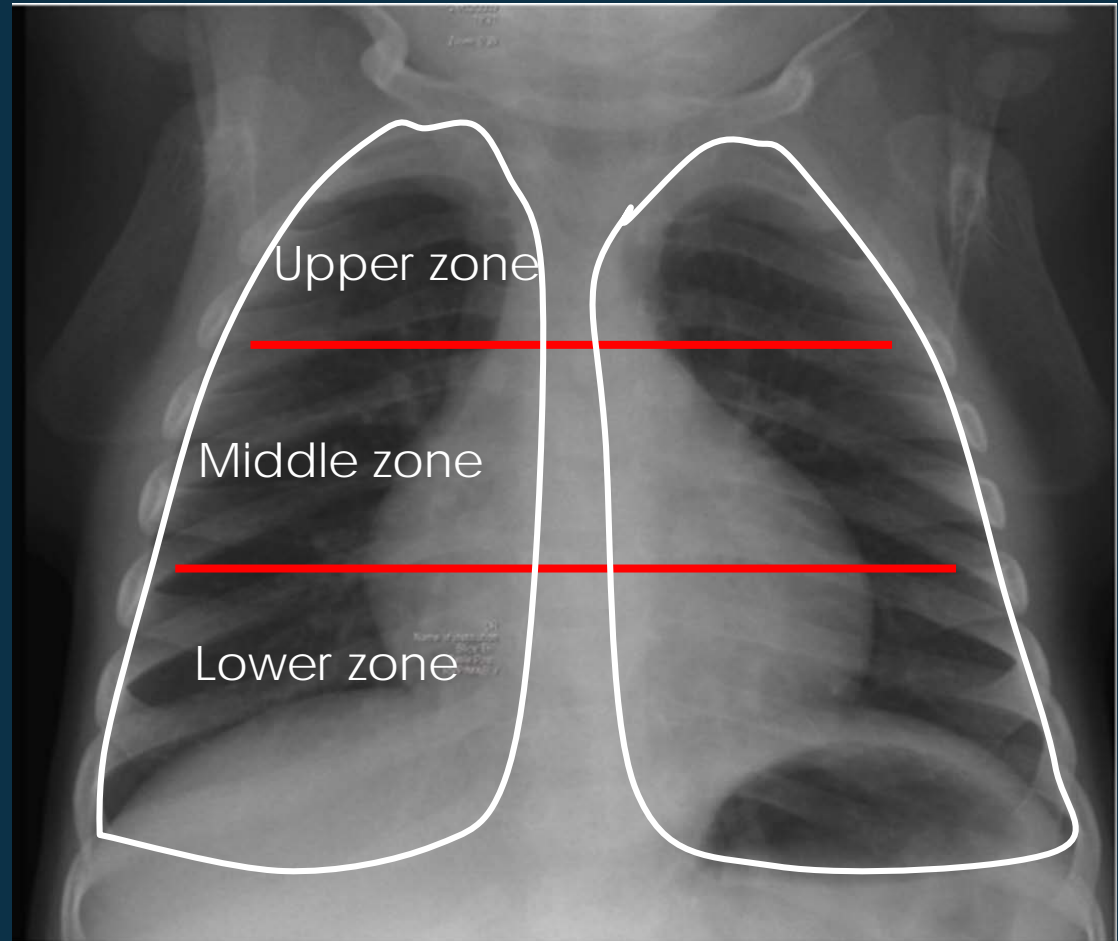
Lung anatomy recap

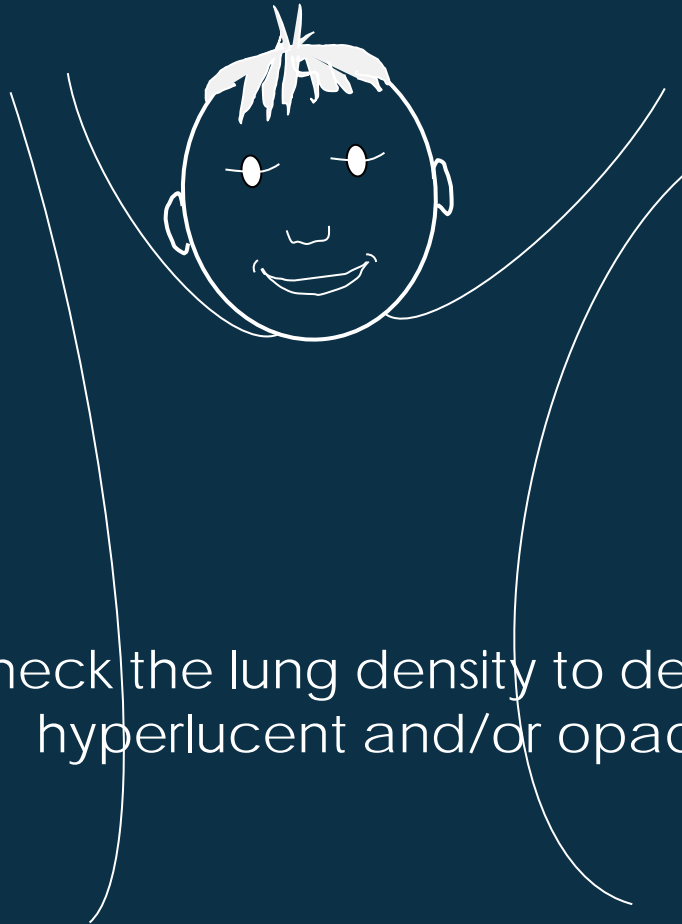
Lungs





Second circle: Lungs

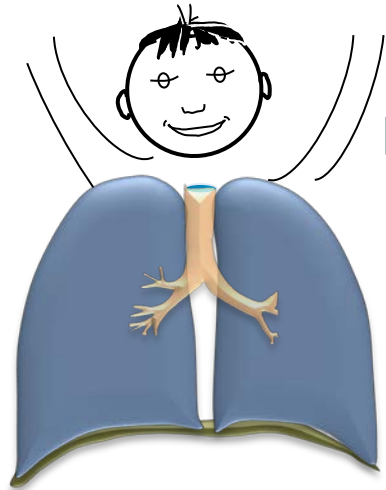
1. Lung parenchyma and vasculature
2. Divide the lungs into 3 zones
3. Read from top to bottom
4. Look for areas of different lucency: whiter (=opacity) or blacker (=hyperlucency)
5. The lower zones reach below the diaphragm





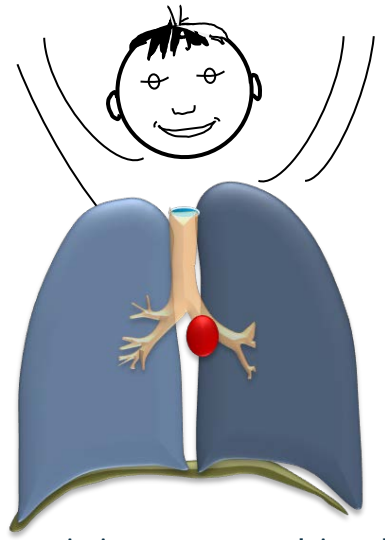
You will check the lung density to decide if normal,
hyperlucent and/or opaque





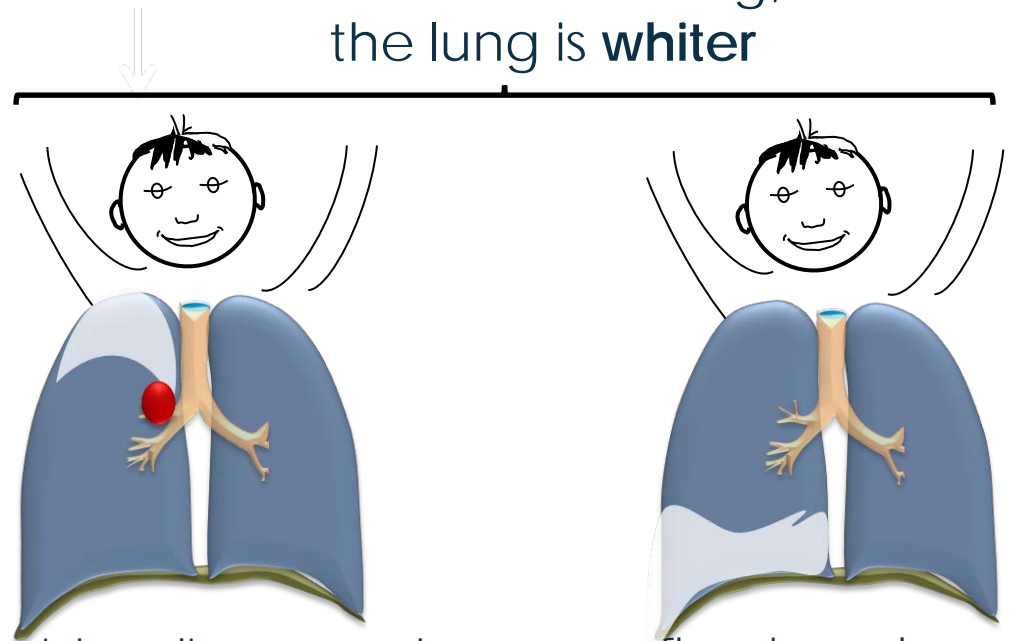
Normal lungs

Hyperlucencies
More air in the lung,
the lung is **blacker**



The air is trapped in the lung (partial airway compression)

Opacities
Less air in the lung,
the lung is **whiter**

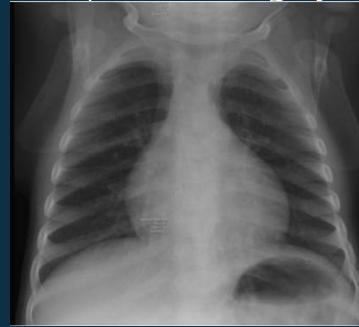

The air has disappeared
Part of the lung collapsed
(complete airway compression)

The air can be replaced by fluid
(infection or pleu.eff)

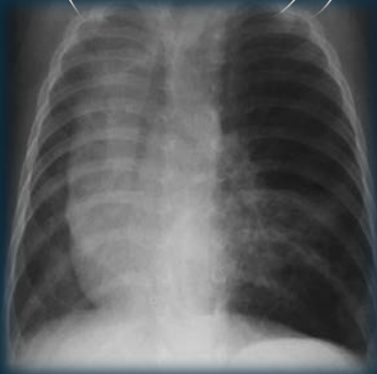

Normal lungs

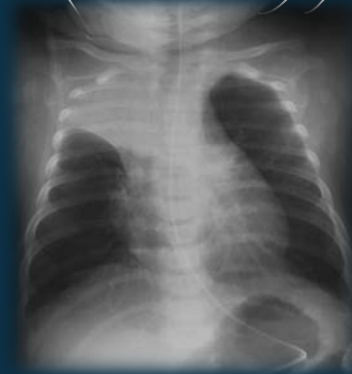

Hyperlucencies

More air in the lung, the lung is **blacker**



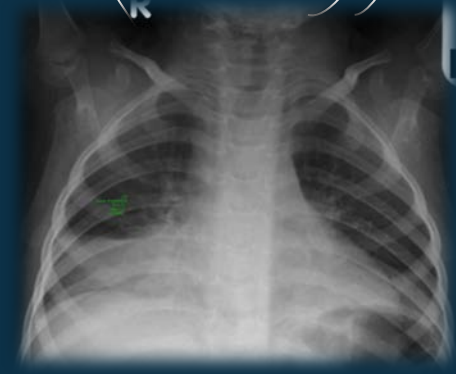The air is trapped in the lung (partial airway compression)




The air has disappeared
Part of the lung collapsed
(complete airway compression)

Opacities

Less air in the lung, the lung is **whiter**

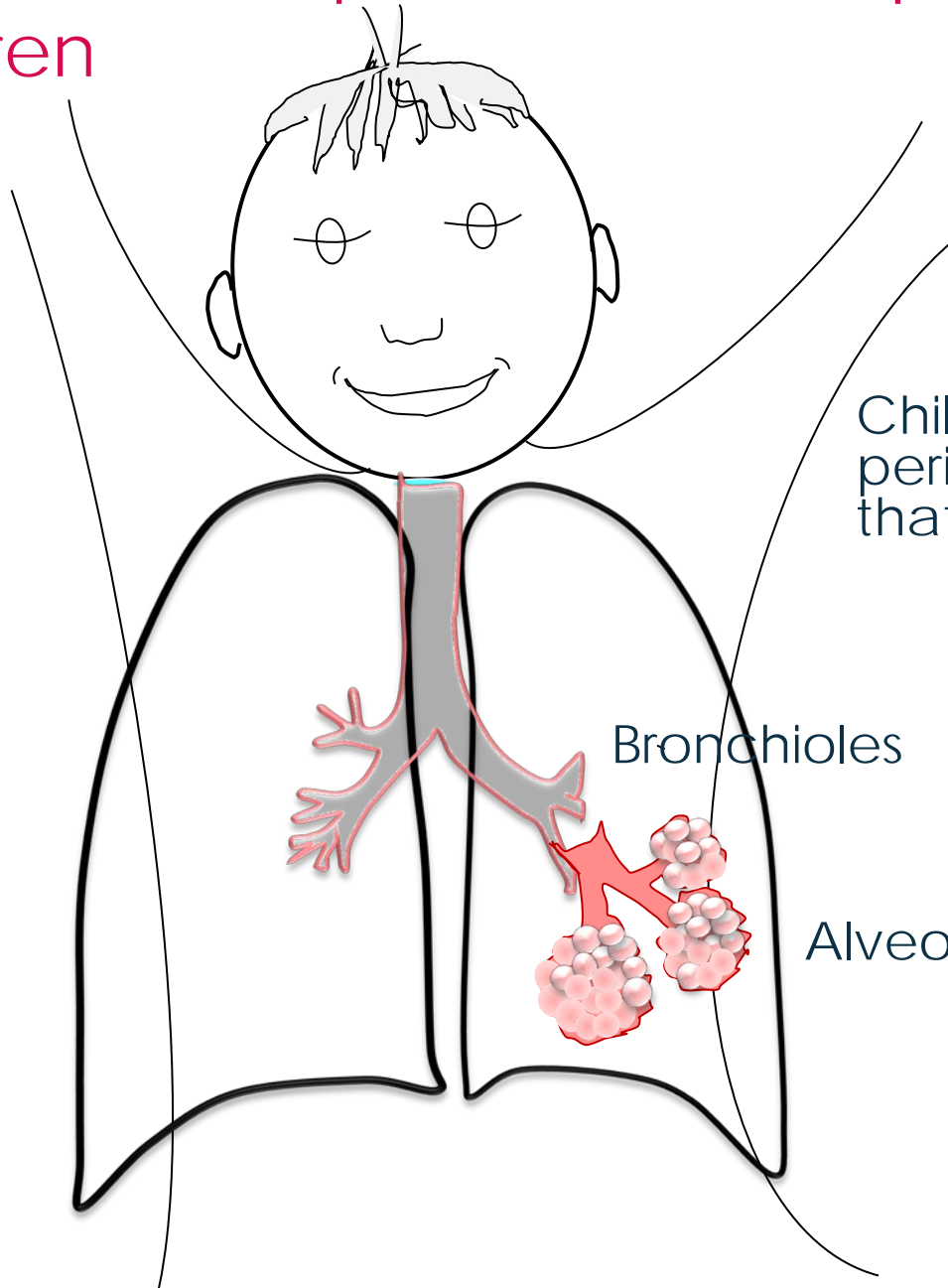


The air can be replaced by fluid
(infection or pleu.eff)



Did you say airway compression ?
You need to know more about the specifics
of children's airways

Anatomical aspects that are specific to infants and children



Children have narrow peripheral airways that are easily compressed

Bronchioles

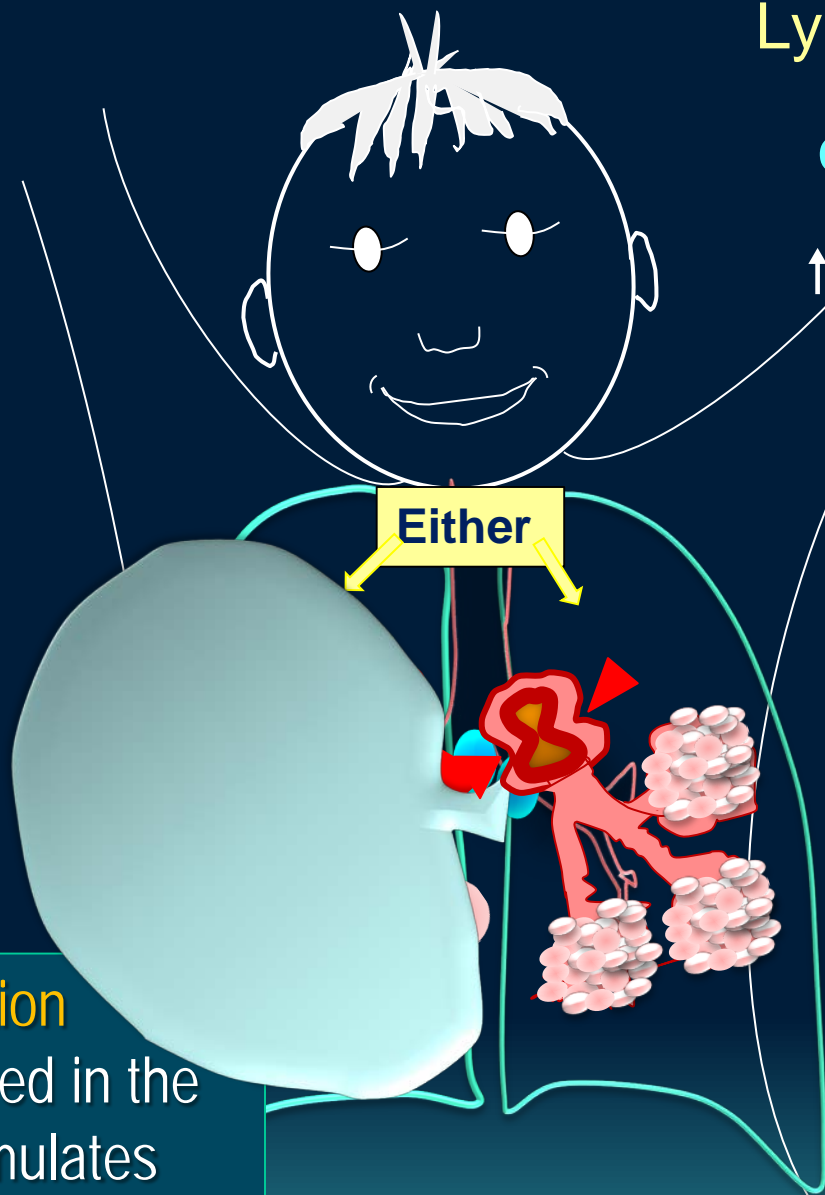
Alveoli

Particular anatomical aspects in Infants and child

Lymphnode compression
increased narrowing
of peripheral airways



↑ Resistance to airflow



Either

Partial obstruction

The air is trapped in the lung and accumulates
Check-valve -air trapping

Complete obstruction

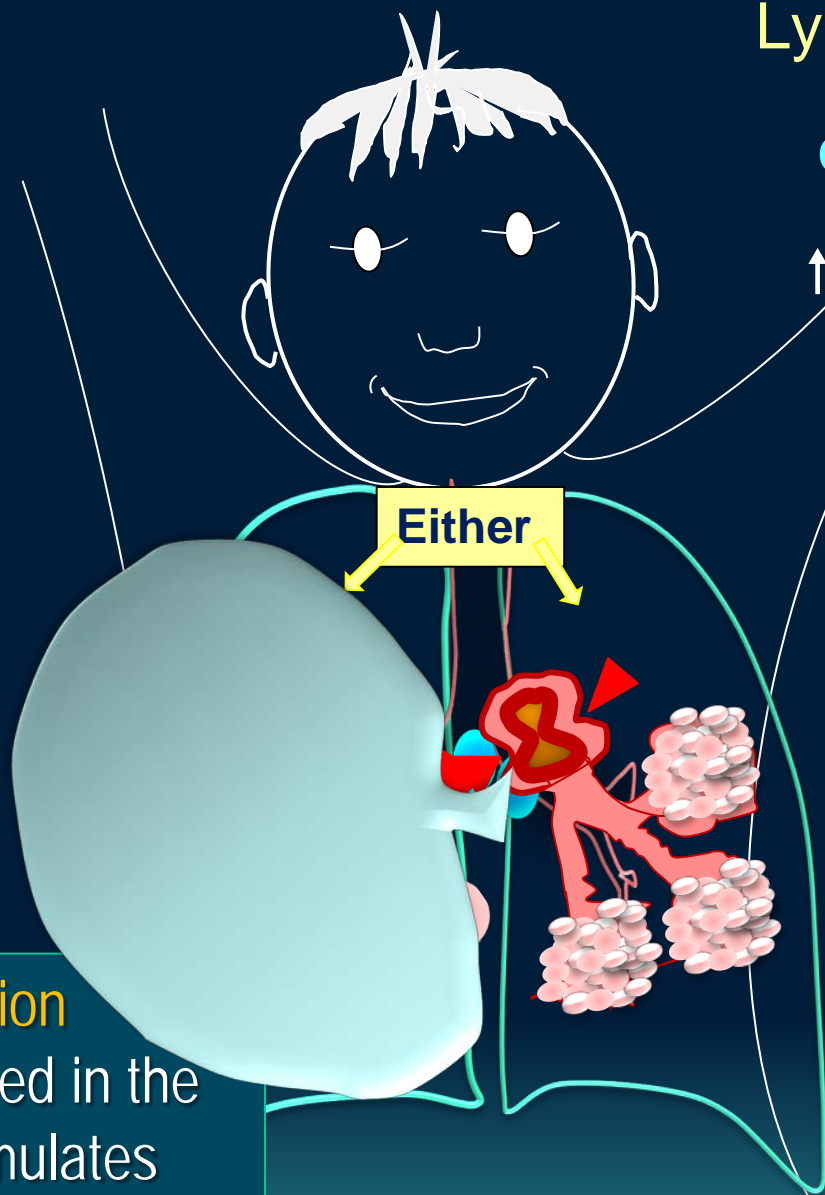
The air has disappeared
Collapsed alveoli,
loss of volume
atelectasis

Particular anatomical aspects in Infants and child

Lymphnode compression
increased narrowing
of peripheral airways



↑ Resistance to airflow



Either

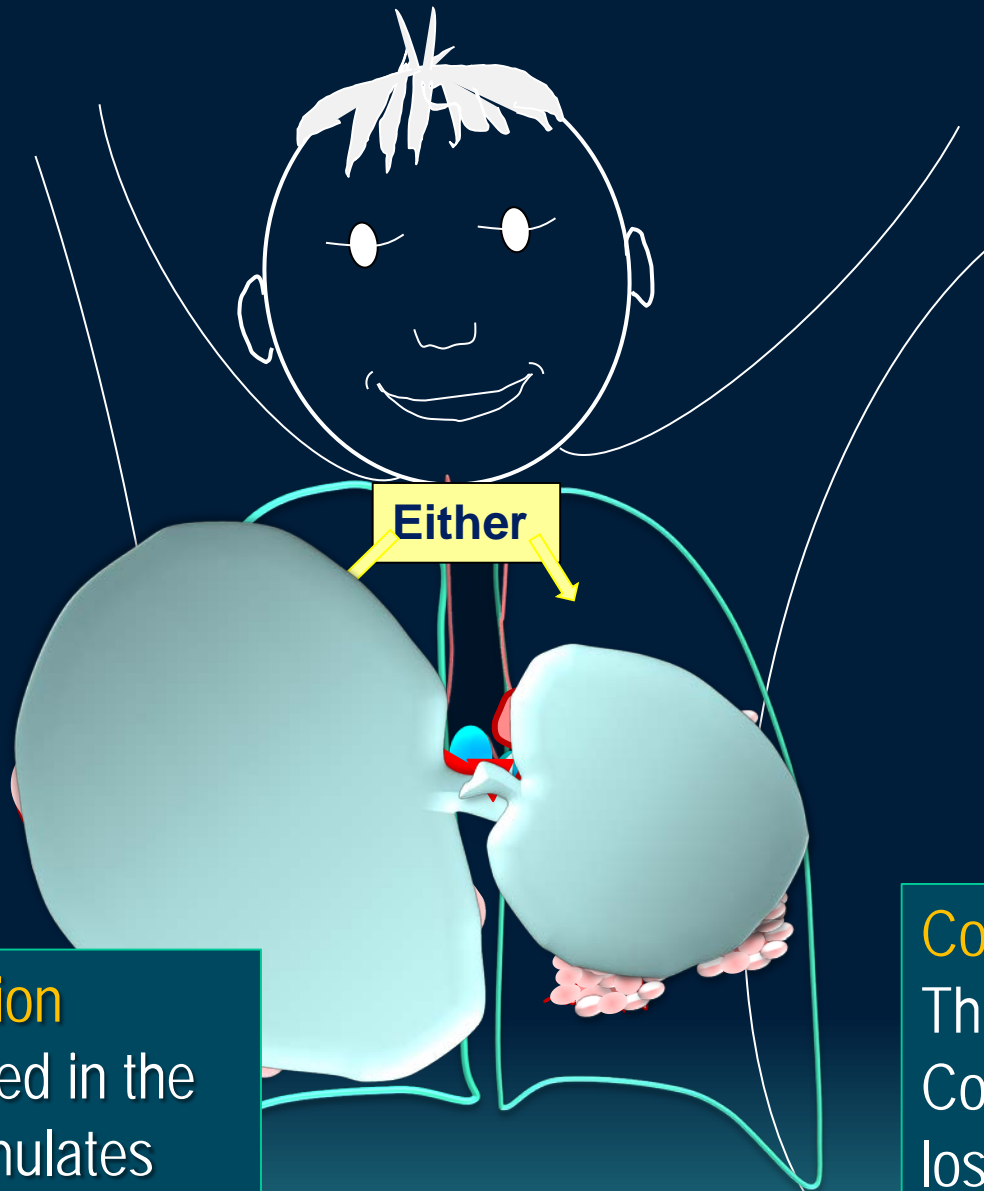
Partial obstruction

The air is trapped in the lung and accumulates
Check-valve -air trapping

Complete obstruction

The air has disappeared
Collapsed alveoli,
loss of volume
atelectasis

Particular anatomical aspects in Infants and child

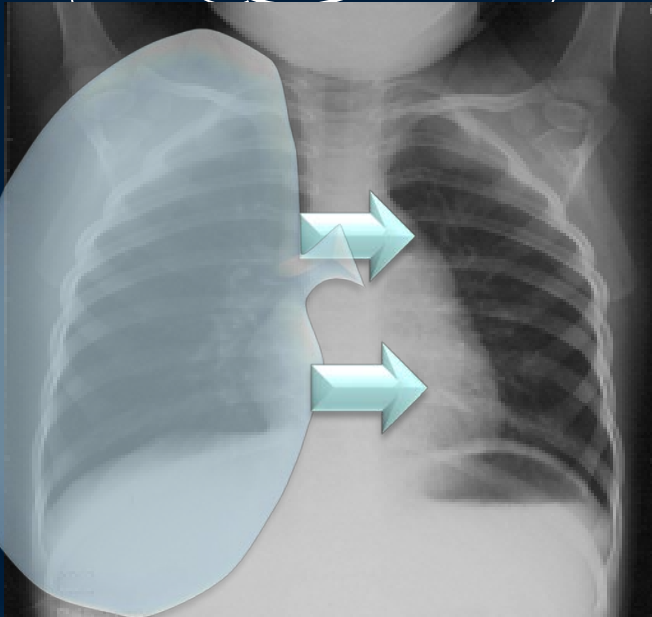


Partial obstruction
The air is trapped in the lung and accumulates
Check-valve -air trapping

Complete obstruction
The air has disappeared
Collapsed alveoli,
loss of volume
atelectasis

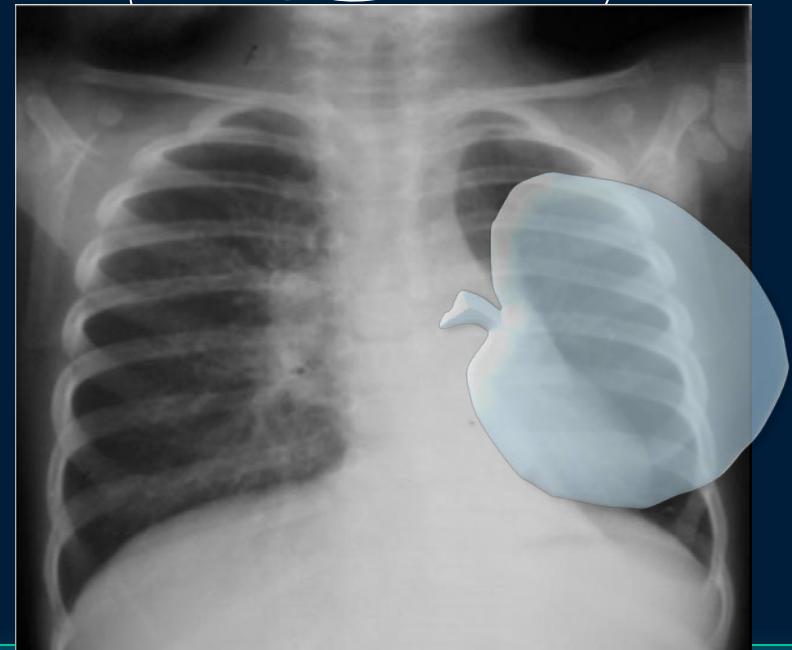
Radiologically responsible for

HYPERLUCENCY
Blacker



Partial obstruction
Check-valve -air trapping
With shift of surrounding structures

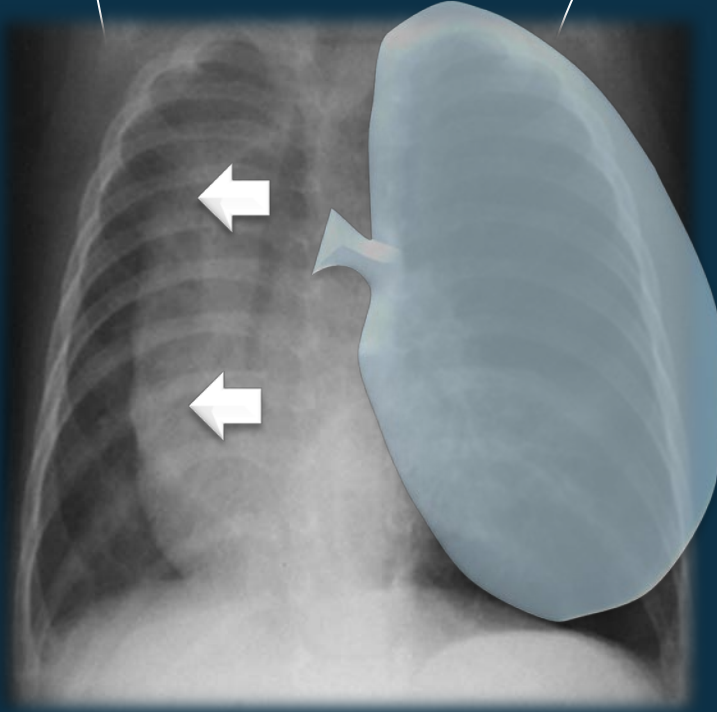
OPACITY
Whiter



Complete obstruction
loss of volume –**atelectasis**
With attraction of surrounding structures

Radiologically responsible for

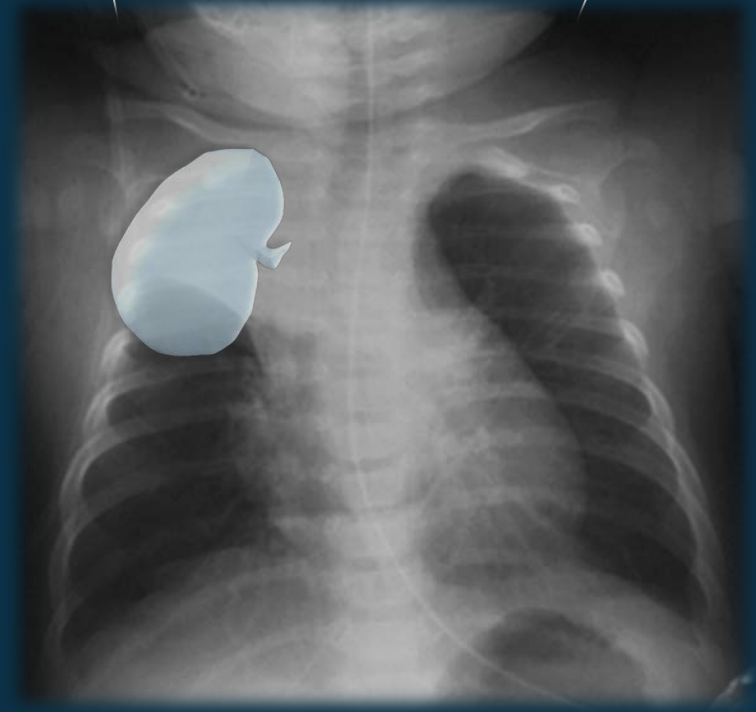
Hyperlucency: blacker



Partial obstruction

Check-valve / air trapping
which PUSHES surrounding structures

Opacity: whiter



Complete obstruction

Alveolar collapse with loss of volume
(atelectasis) which PULLS surrounding
structures

Hyperlucencies

More air in the lung : the lung is blacker


Can create asymmetry between right and left lung

Mainly due to partial airway obstruction leading to air trapping and retention of excess of air in all or part of the lung

Expiratory images are of a great help

Most common aetiologies :

- . Lymph nodes as seen in TB
- . Foreign body aspiration (FBA)
- . Mediastinal masses



Hyperlucencies

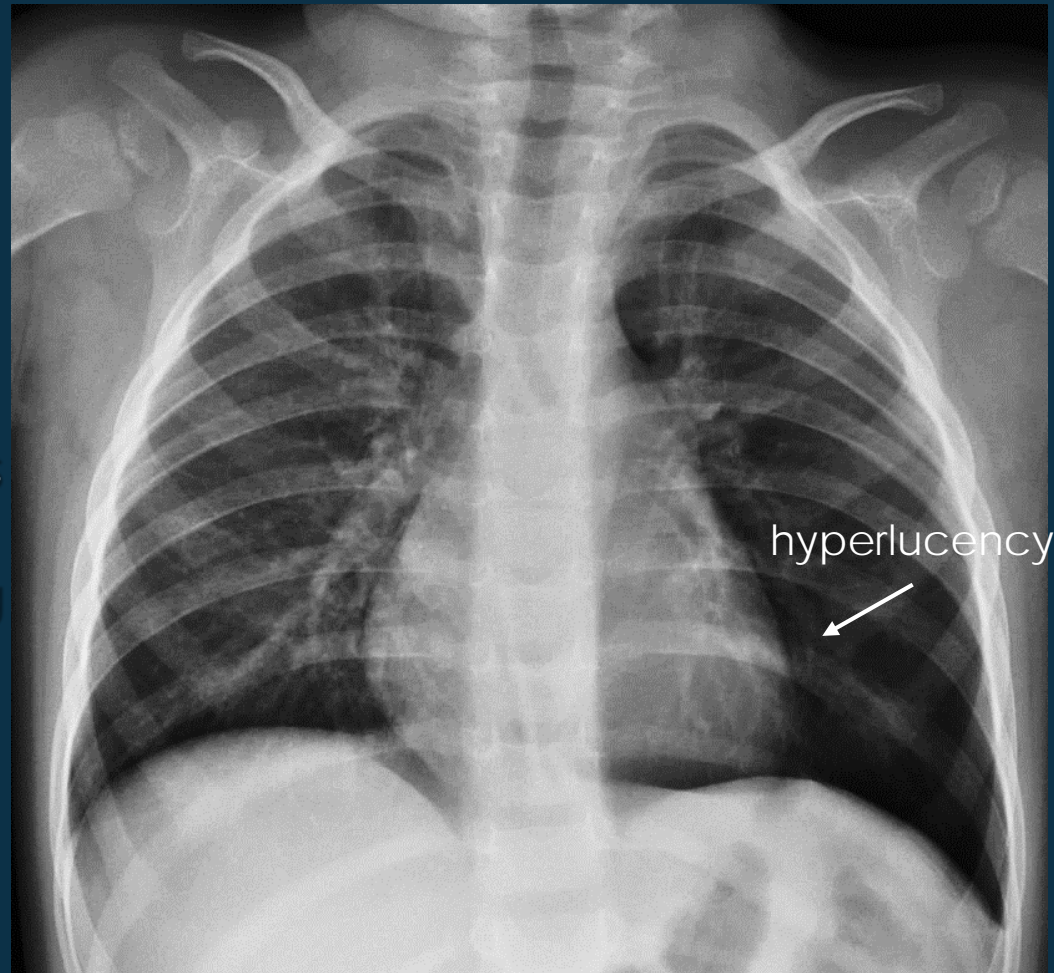
What do you see on this X-ray ?

- . Asymmetry in density :
left hemithorax much
more lucent

What is your diagnosis ?

- . Foreign body aspiration
in the left main bronchus
with air trapping and
hyperinflation of left lung

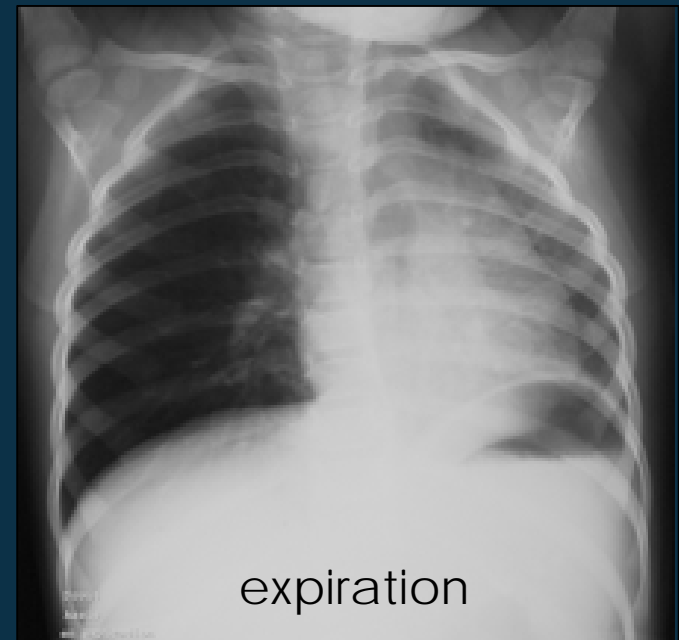
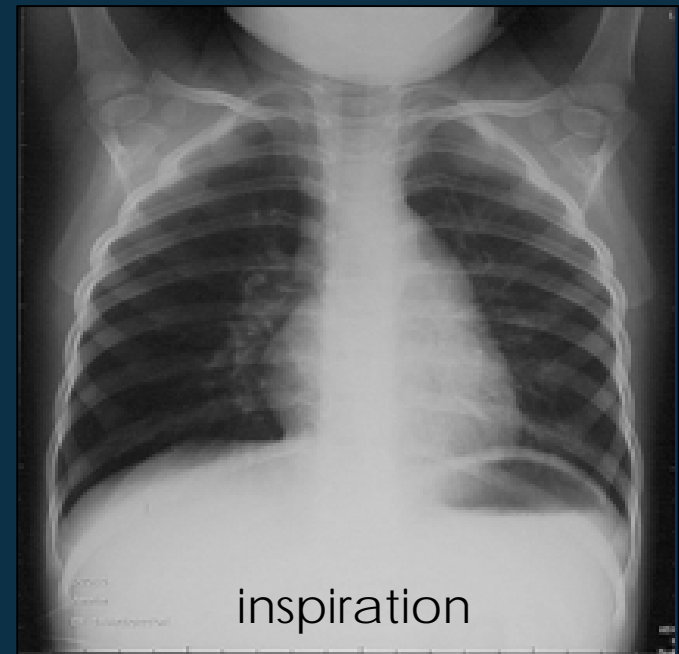
2 year old with acute
respiratory distress



3-year-old child with cough and dyspnoea of sudden onset, and decreased breath sound on the right side

What do you see on this CXR ?

- . The air is trapped in expiration in the right lung with mediastinal shift towards the normal contralateral side :
Foreign body in the right main bronchus

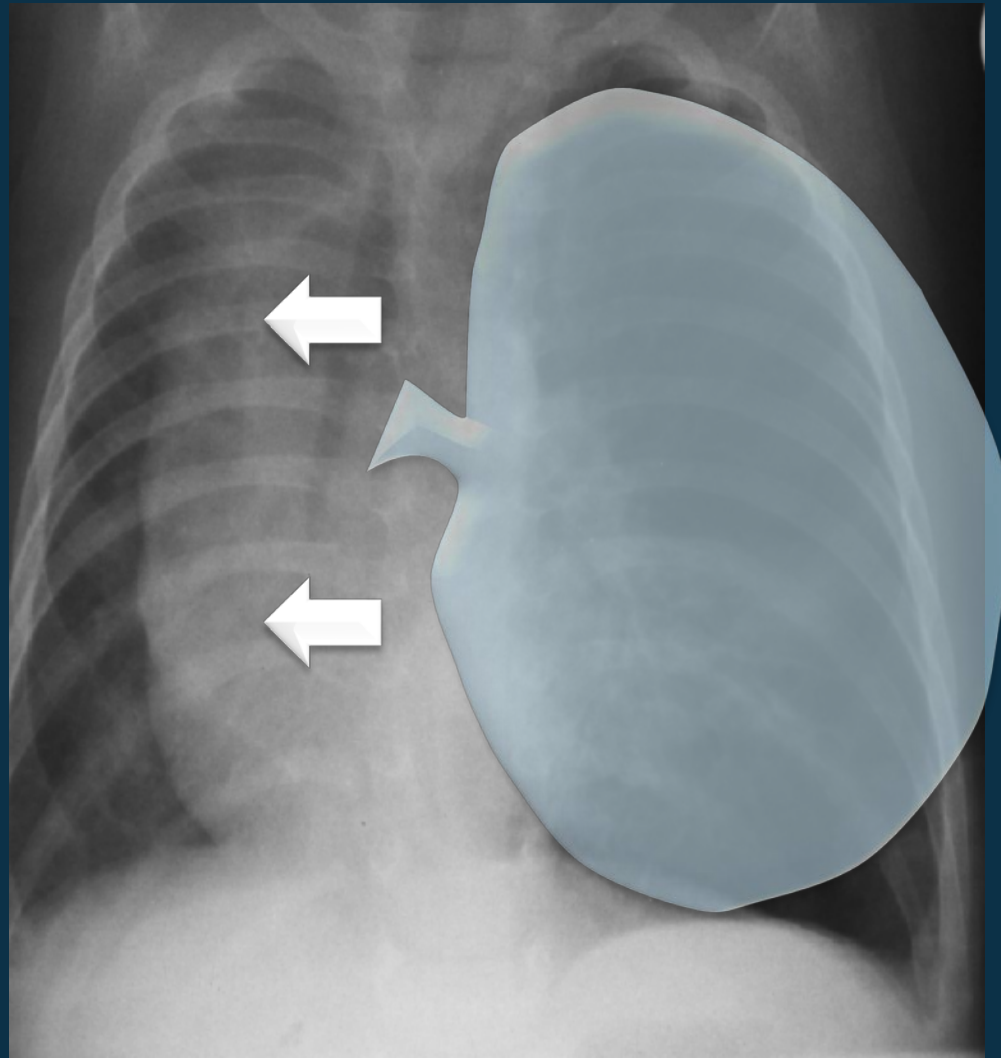


What do you see on this X-ray ?

- . Unilateral hyperlucency
- . Left main bronchus partially obstructed
- . Mediastinal shift

What is your diagnosis ?

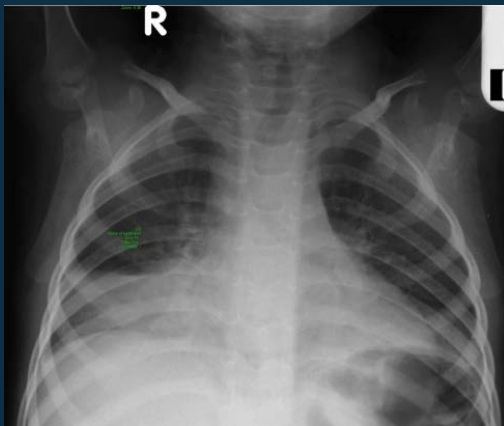
- . Complicated TB :
Check valve
(the main left bronchus
is partially obstructed)



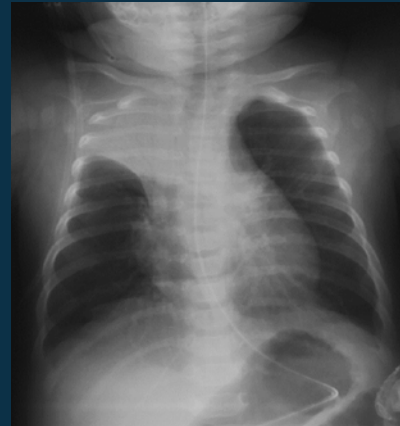Opacities

Less air in the lung : the lung is whiter

Main aetiologies: Alveolar opacities
(involve the alveolar air space)

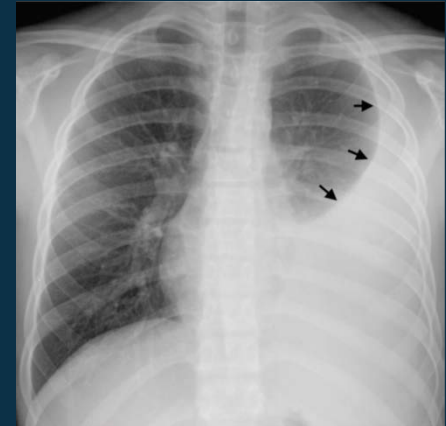

Consolidation:
the air in the alveoli
is replaced by fluid
(infection)



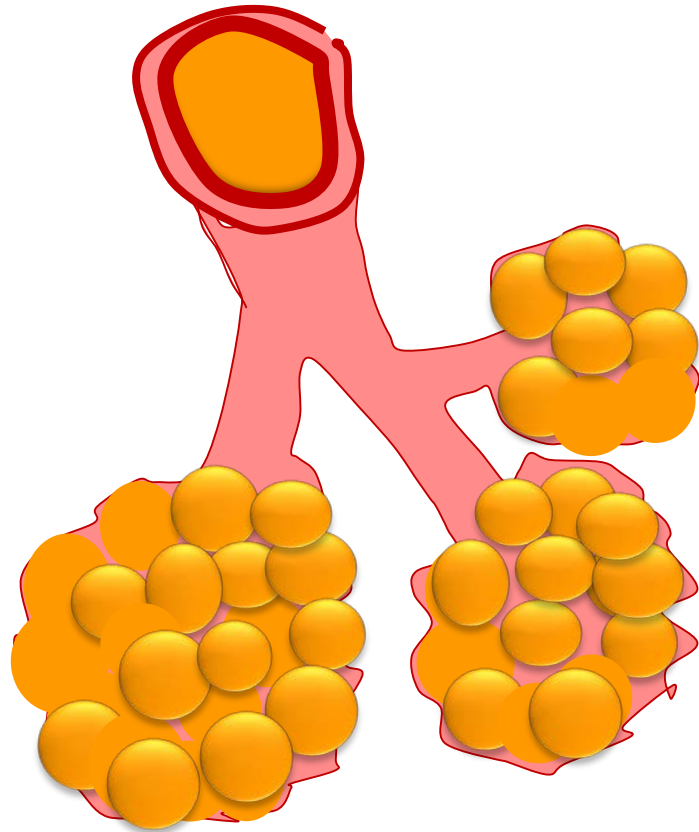
Atelectasis:
the air has disappeared and
part of the lung is collapsed /
alveolar collapse
(complete airway obstruction)

Pleural opacities



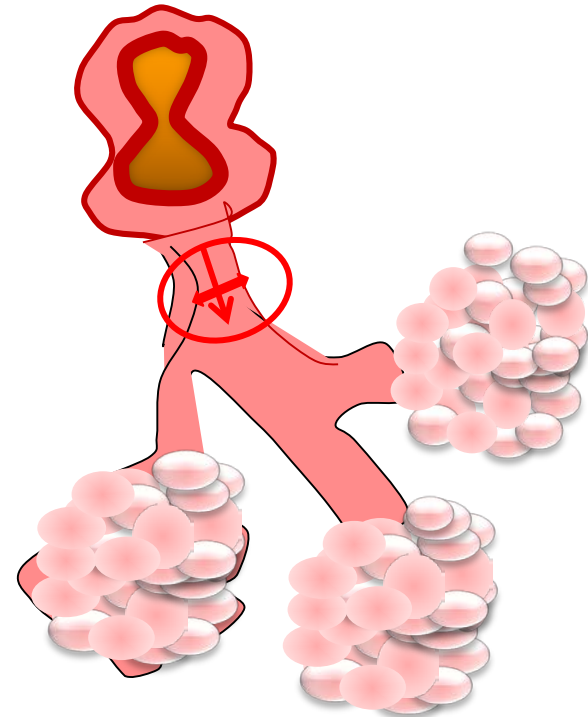
Pleural effusion:
increase of fluid
in the pleura

Alveolar opacities: involve alveolar air space



1. Consolidation

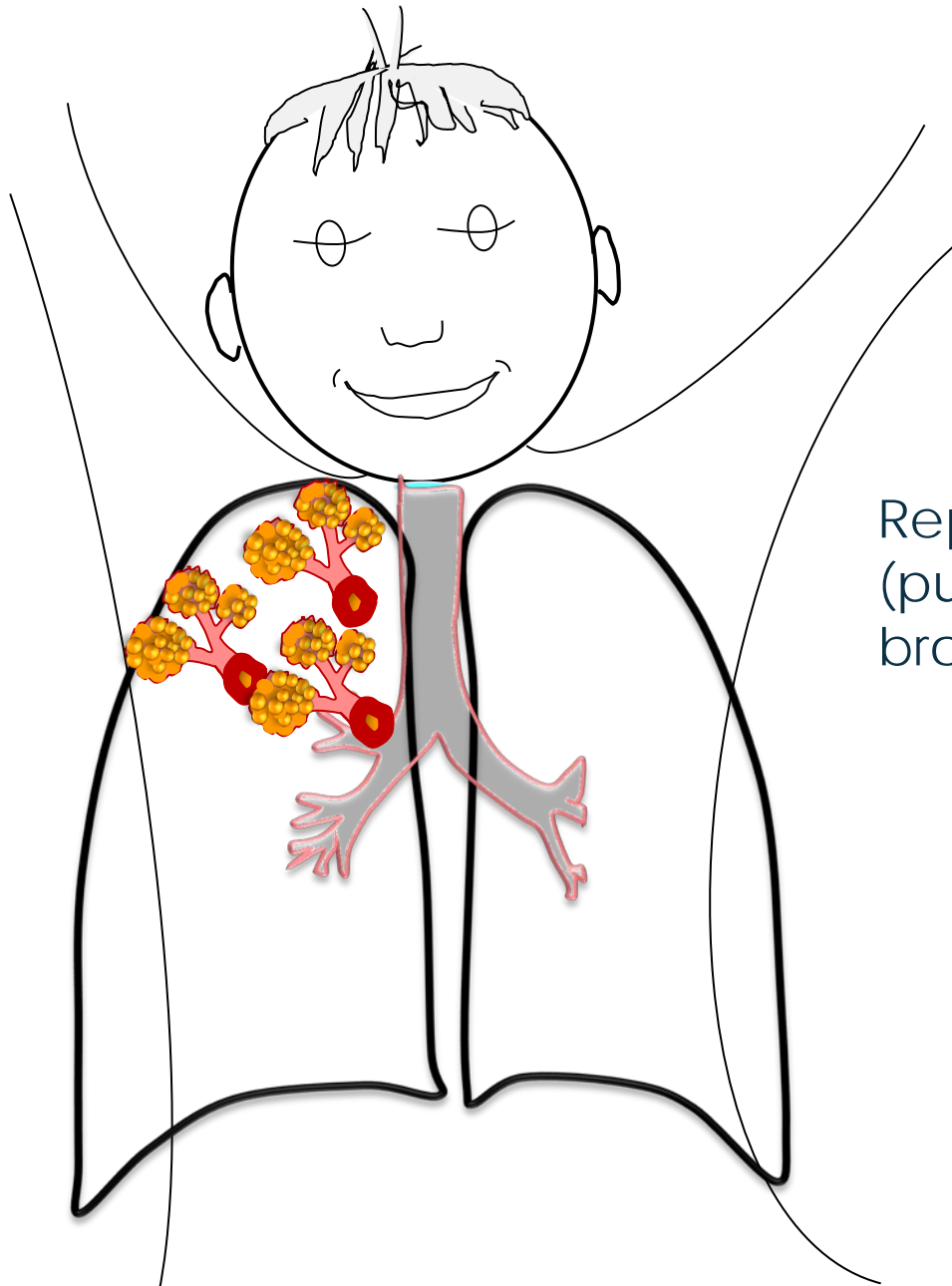
The air is replaced by fluid (infection such as pneumonia)



2. Air space collapse / atelectasis

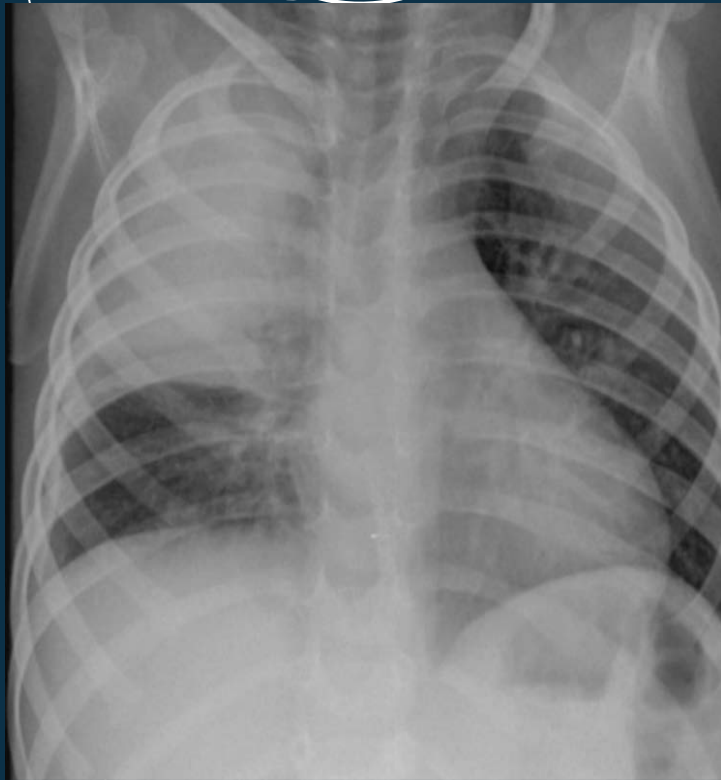
The air has disappeared (alveolar collapse)

Consolidation



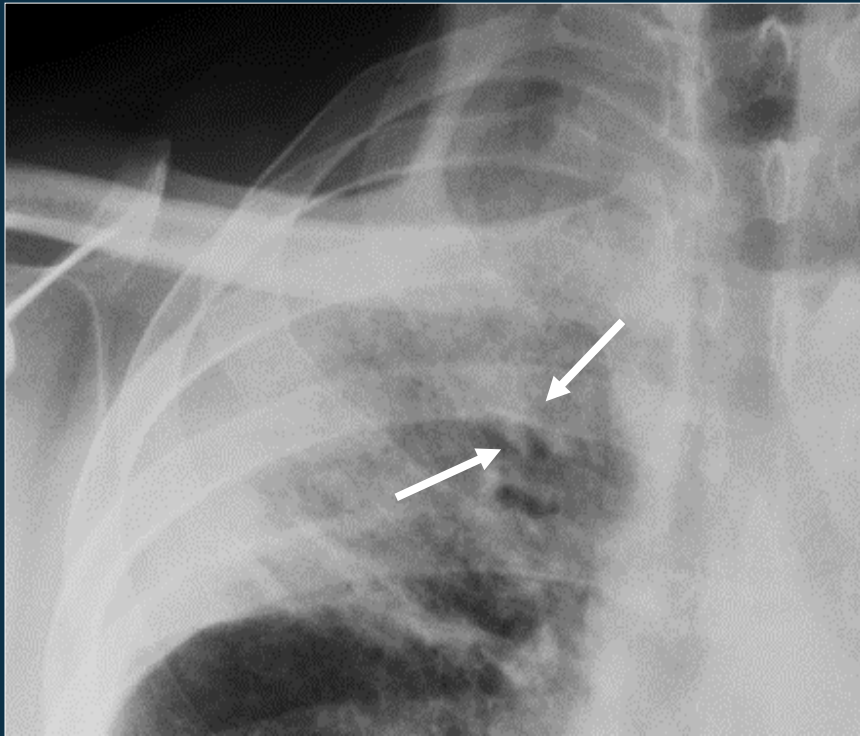
Replacement of air by fluid (pus) in the smaller bronchi, bronchioles, and alveoli

Consolidation




Replacement of air by fluid (pus) in the smaller bronchi, bronchioles, and alveoli is responsible for radiographic opacity

Consolidation



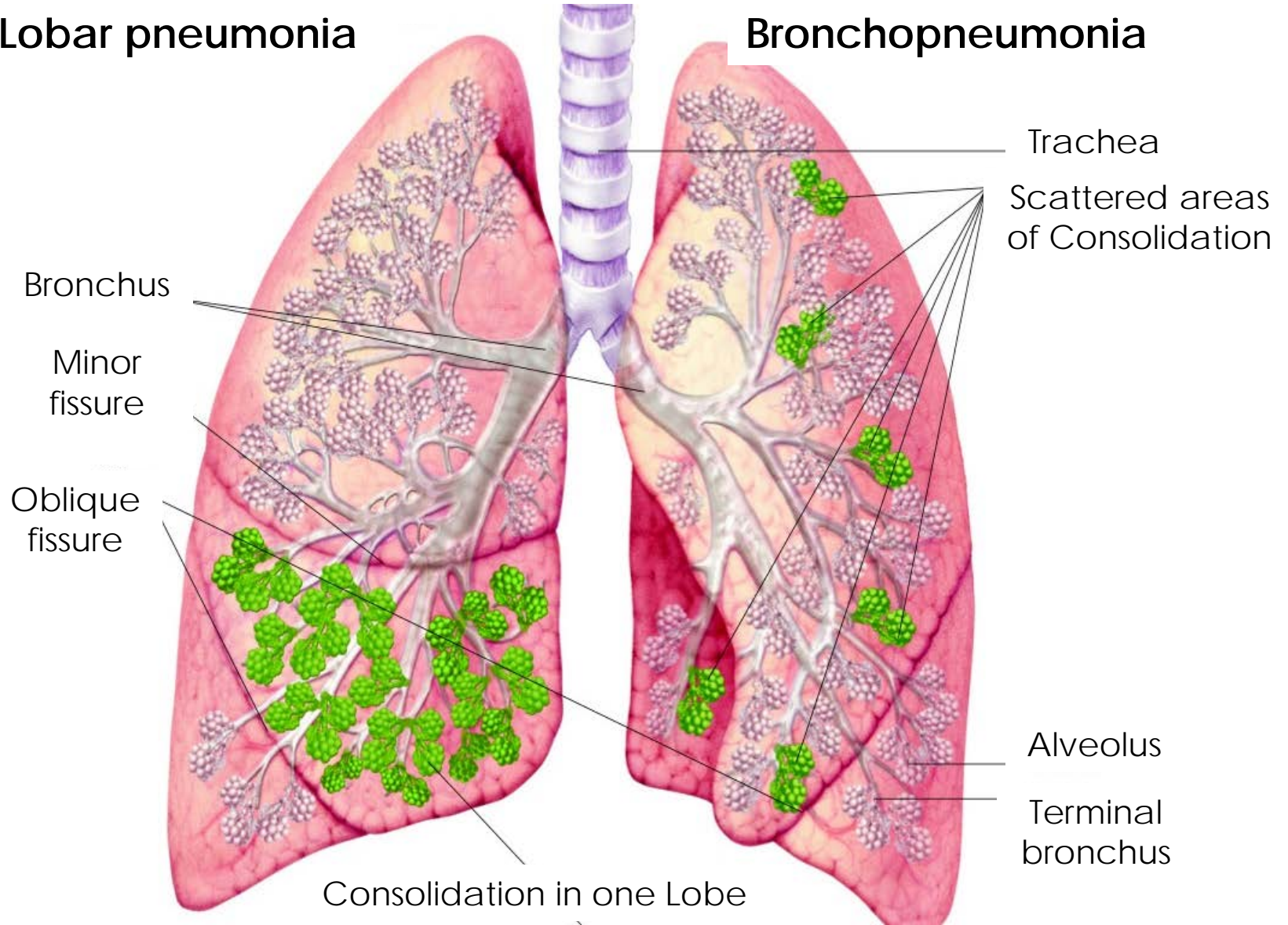
'Air bronchograms' are the hallmark of consolidation and usually involve the smaller bronchi, bronchioles and alveoli



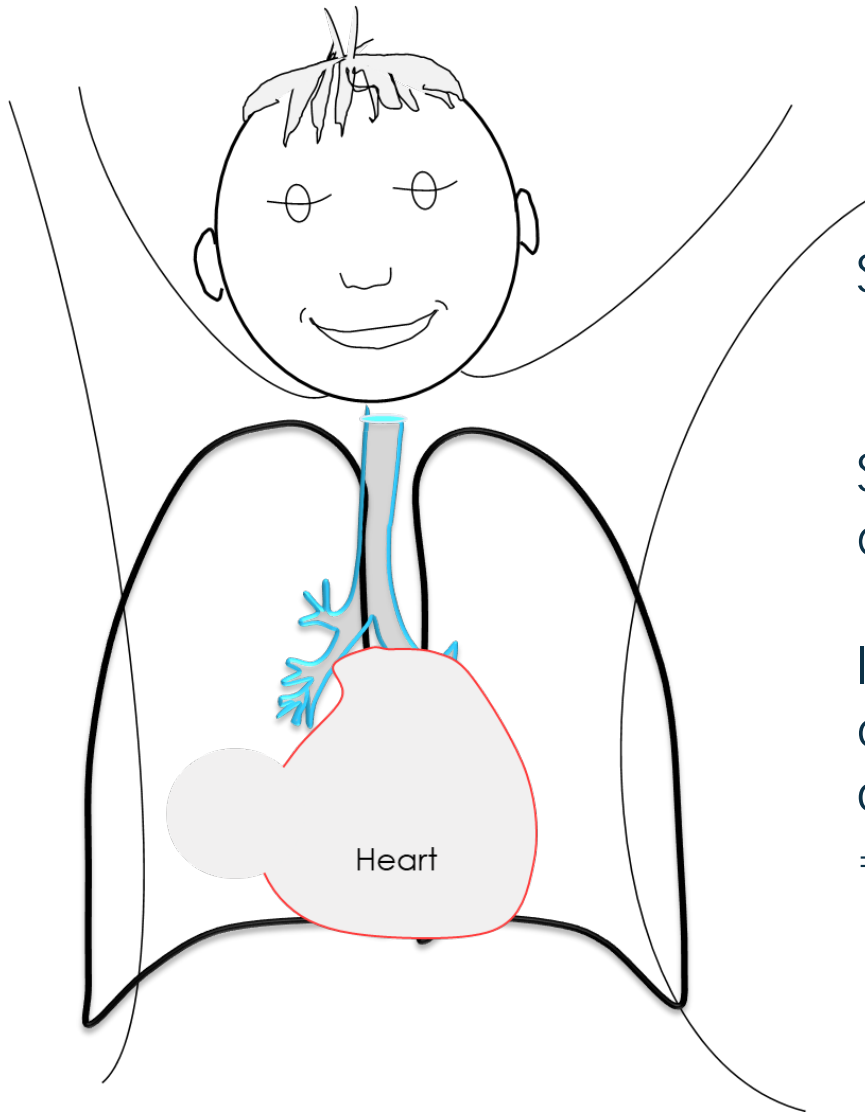
- . As the air spaces fill with fluid, the alveoli are first affected and the bronchi are relatively spared
- . The air-filled bronchi stand out against the fluid-alveoli

Lobar pneumonia

Bronchopneumonia



Opacities

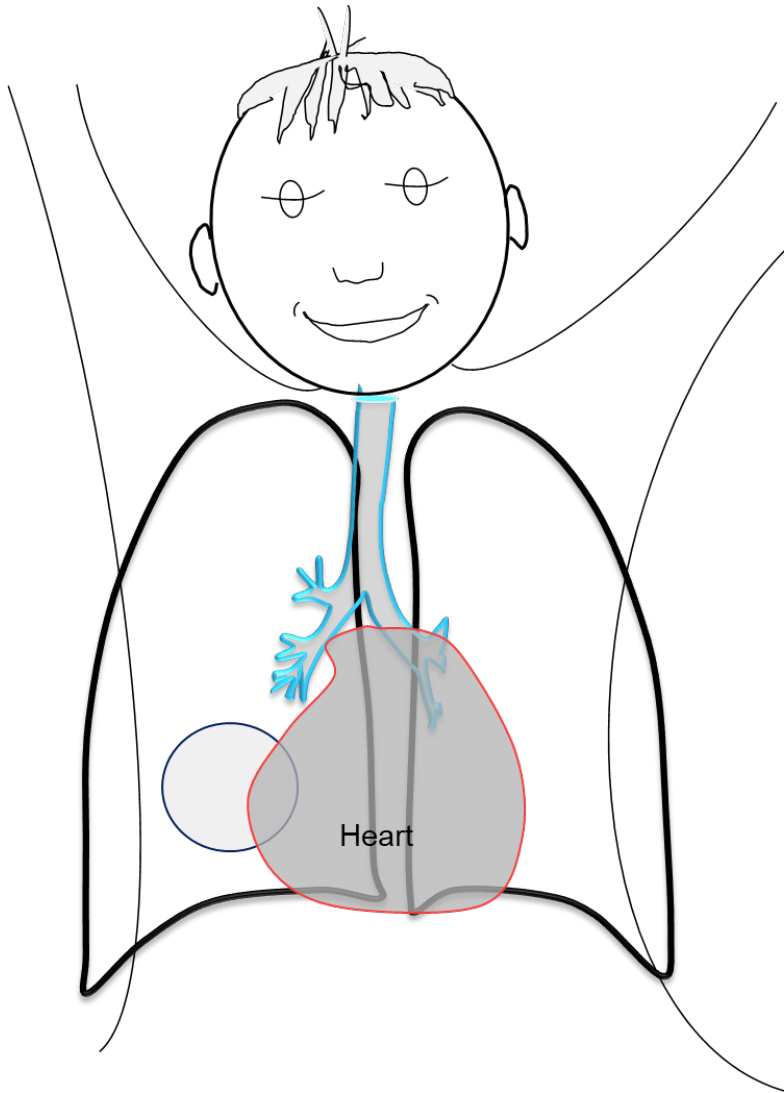


Silhouette sign (Felson)

Some opacities near the heart (or diaphragm) are difficult to identify.

If these opacities are anatomically in contact with the heart then they will obscure the border of the heart
=> anterior opacity

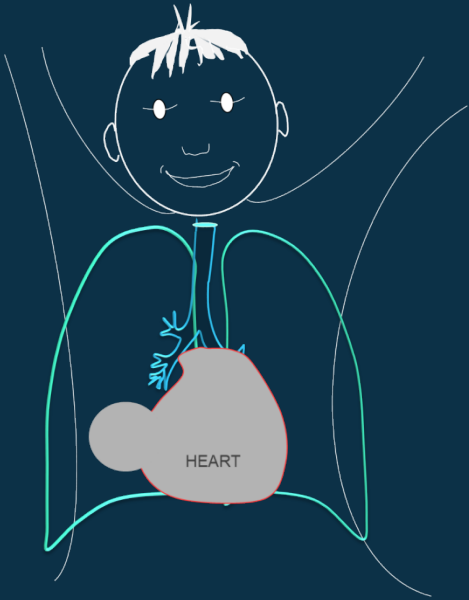
Opacities



Silhouette sign (Felson)

Some opacities near the heart are **not anatomically** in contact with the heart and will **NOT** obscure the border of the heart
=> posterior opacity

Opacities

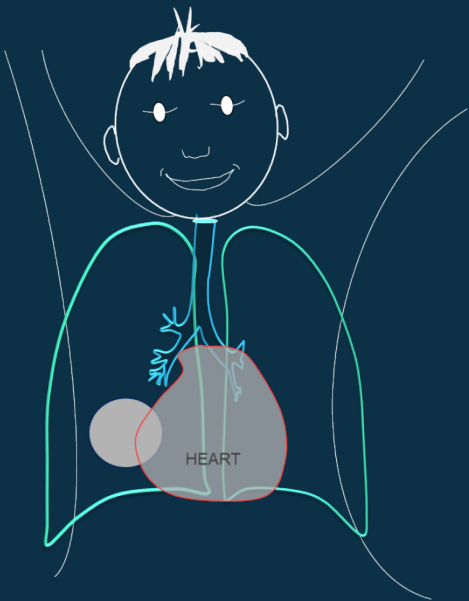


Silhouette sign (Felson)

A useful sign to localize opacities, especially when a lateral view is not available

When 2 opacities of the same density are anatomically in contact with each other, their borders will disappear.

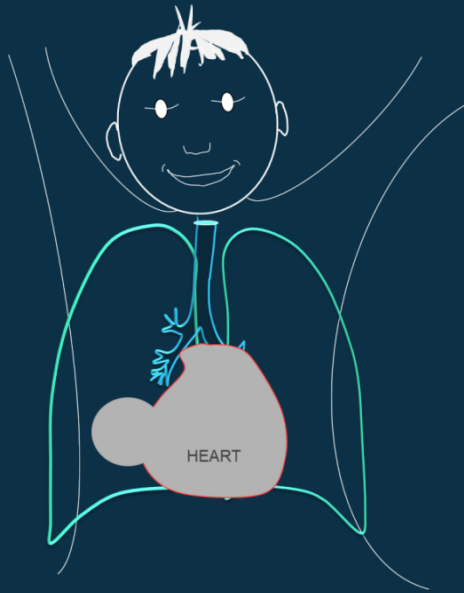
=> **anterior opacity**



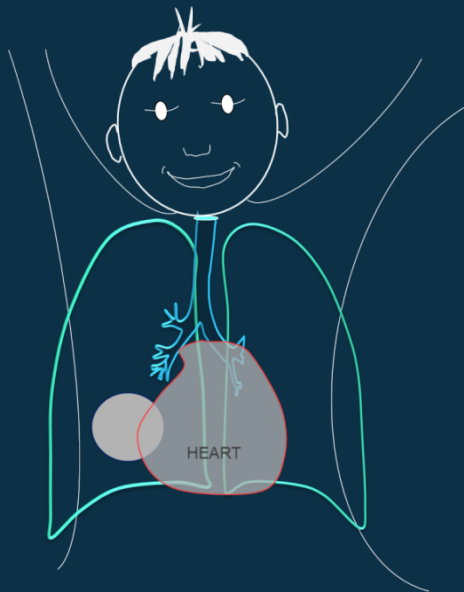
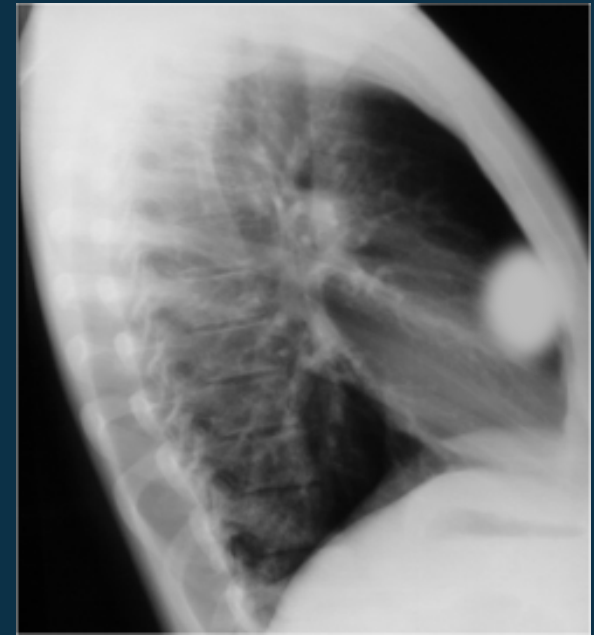
When 2 opacities are separated by any tissue of a different density (example: air), their respective borders are visible.

=> **posterior opacity**

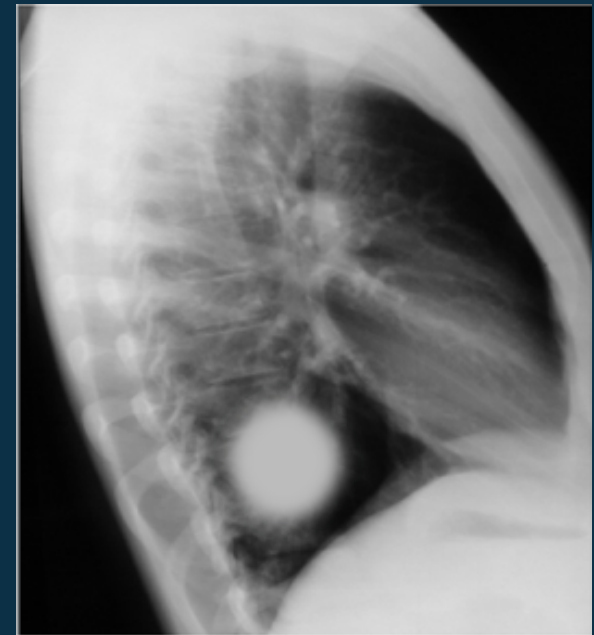
Opacities



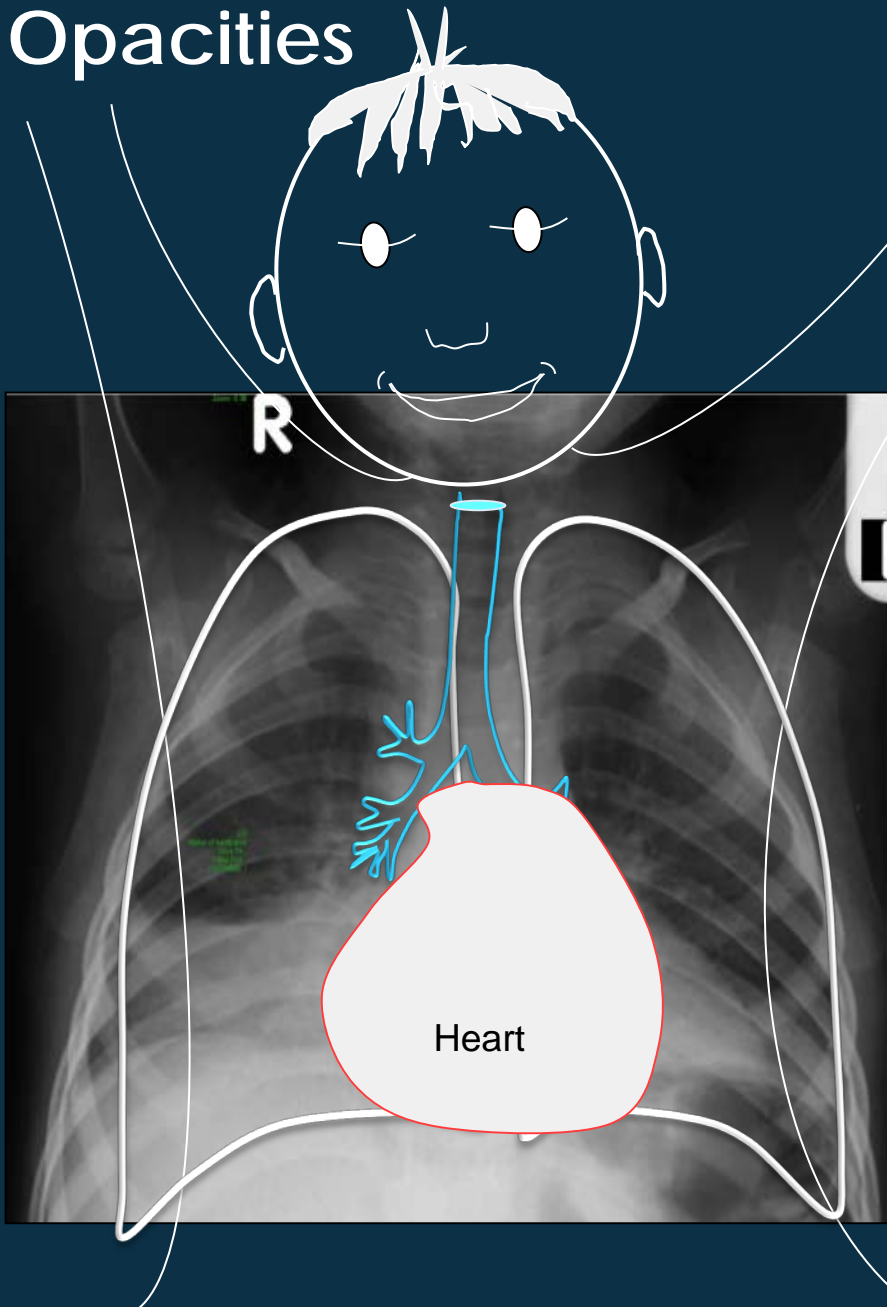
anterior opacity



posterior opacity



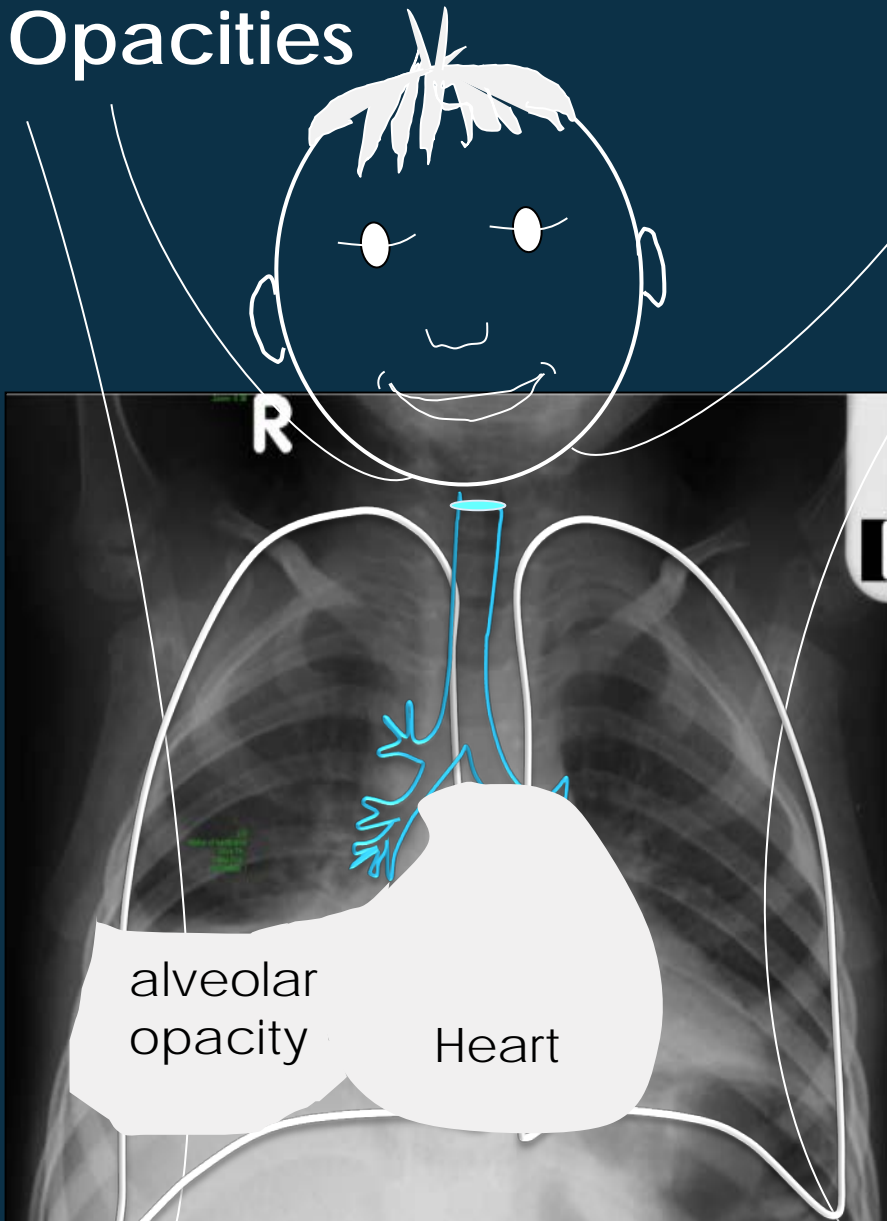
Opacities



Silhouette sign (Felson)

When 2 opacities
of the same density
are in contact
with each other,

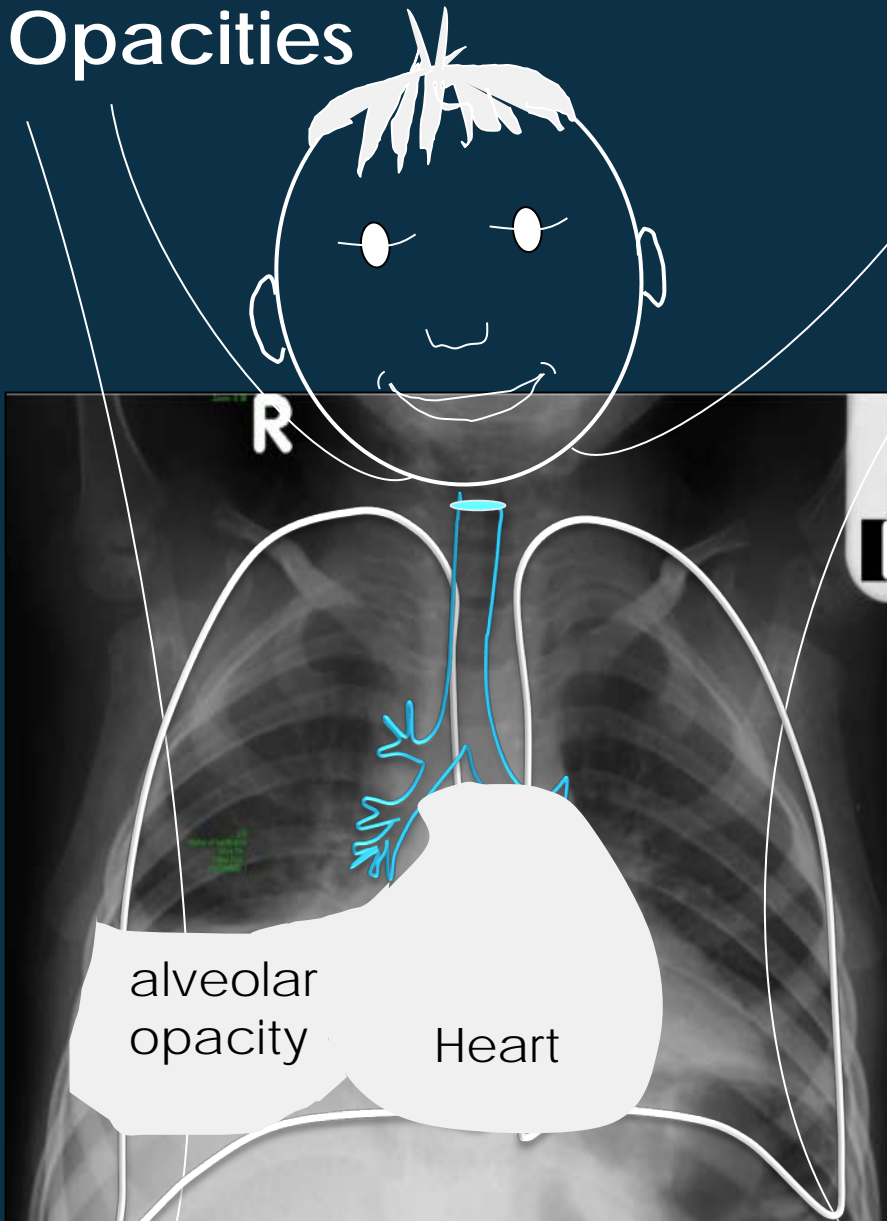
Opacities



Silhouette sign (Felson)

When 2 opacities
of the same density
are anatomically in contact
with each other,
their borders disappear.
=> **anterior opacity**

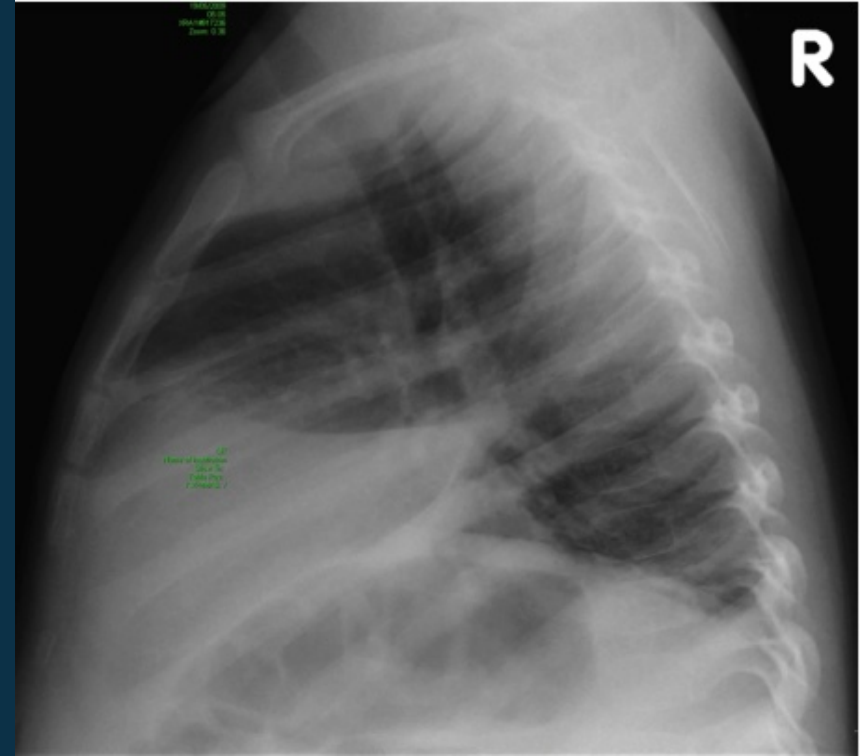
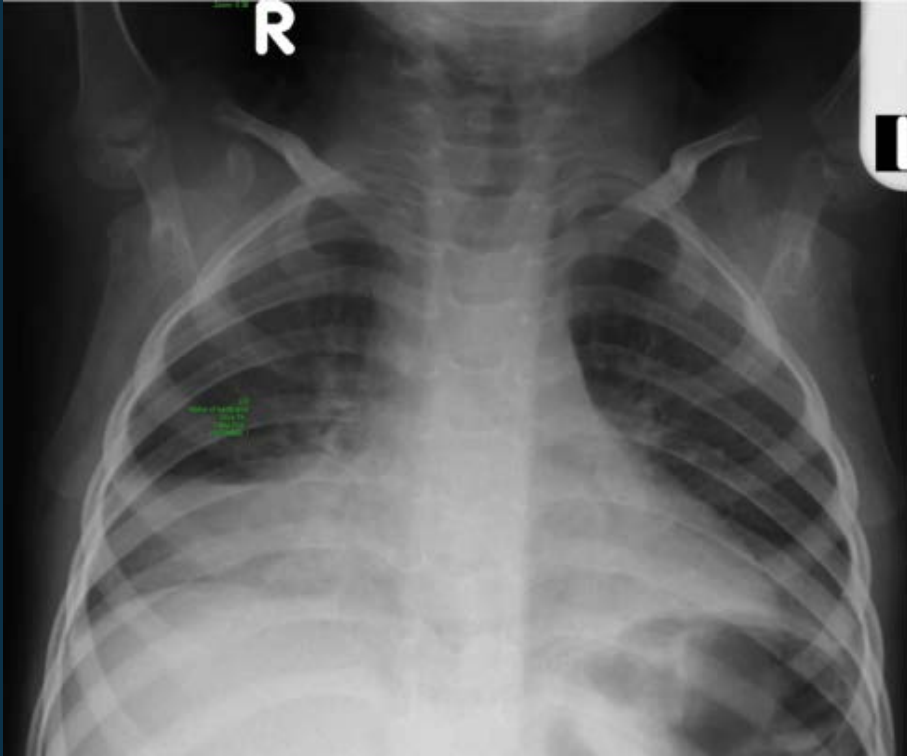
Opacities



Silhouette sign (Felson)

When 2 opacities of the same density are anatomically in contact with each other, their borders disappear.
=> **anterior opacity**

Consolidation



Anterior or posterior opacity?
. Anterior alveolar Opacity

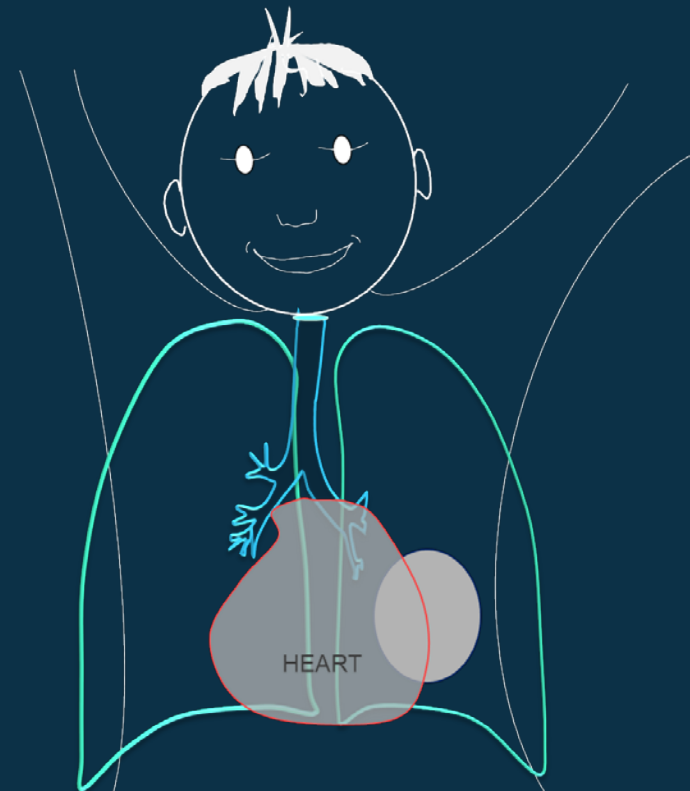
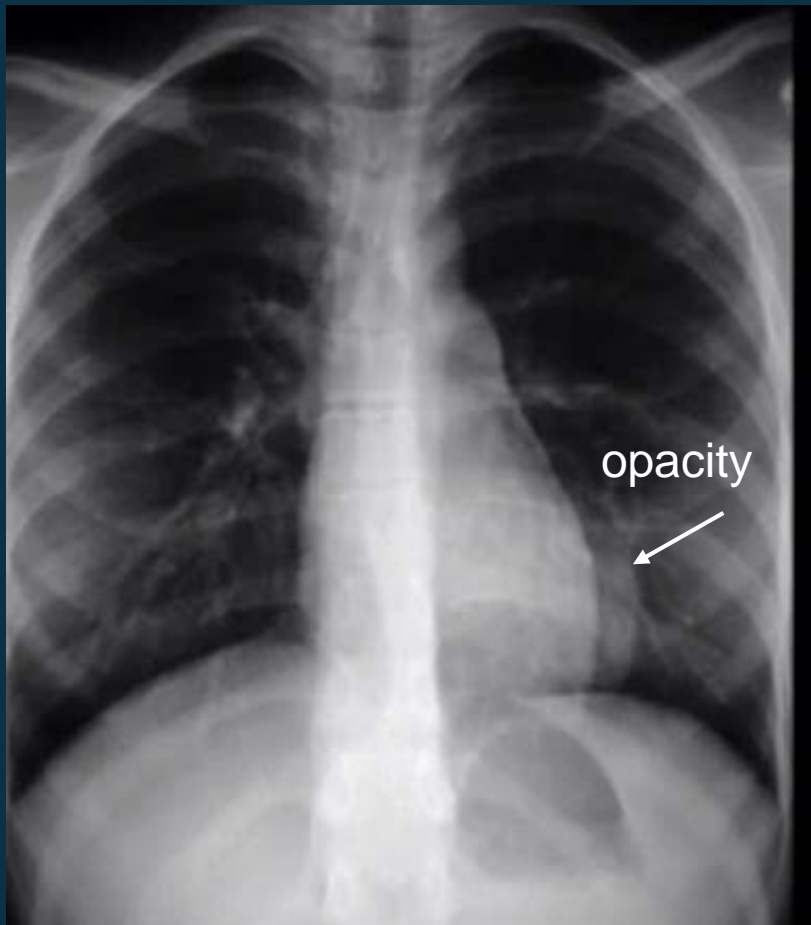Why ?

. Cannot see the right border of the heart

5 year old with cough and fever

Anterior or posterior opacity?

1. Retrocardiac opacity



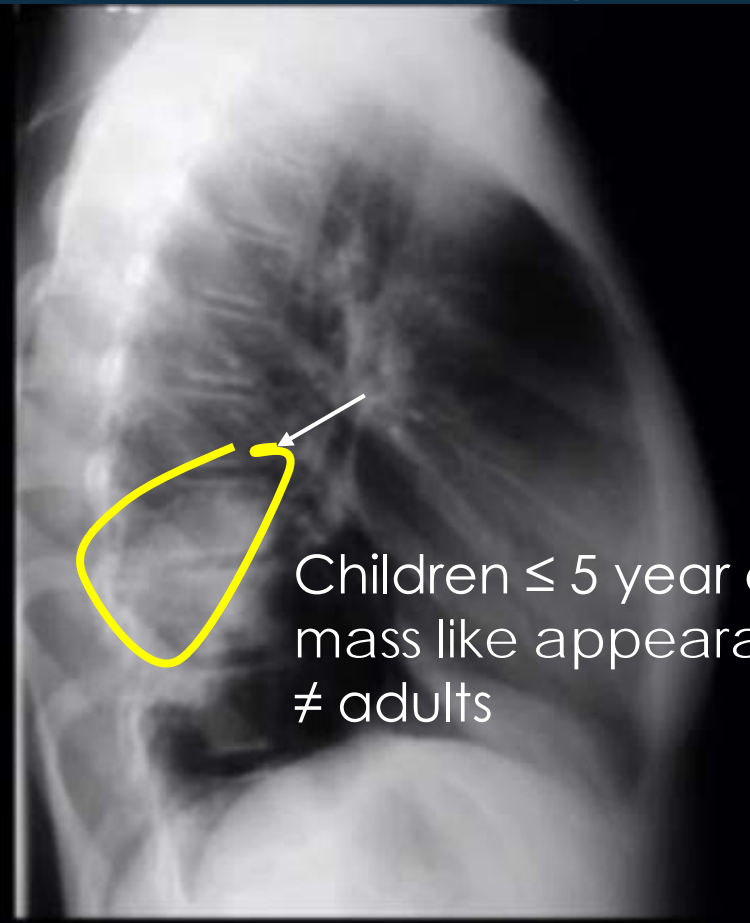
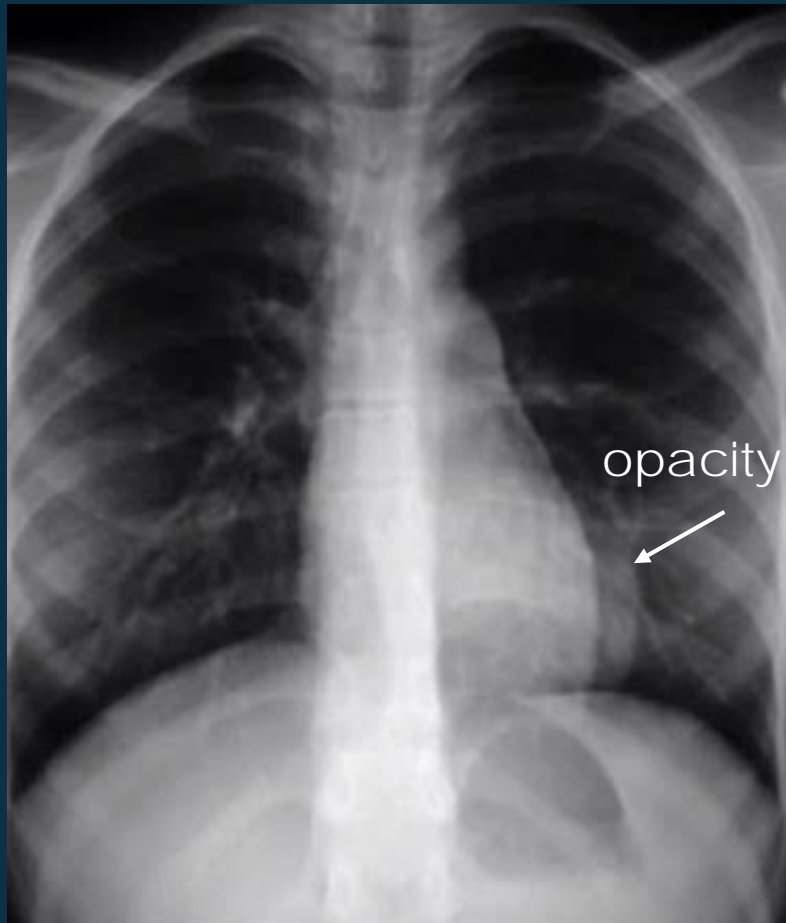Opacity not in contact
with the heart
(does not erase the border
of the heart)
=> **Posterior opacity**

5 year old with cough and fever

Anterior or posterior opacity?

1. Retrocardiac opacity

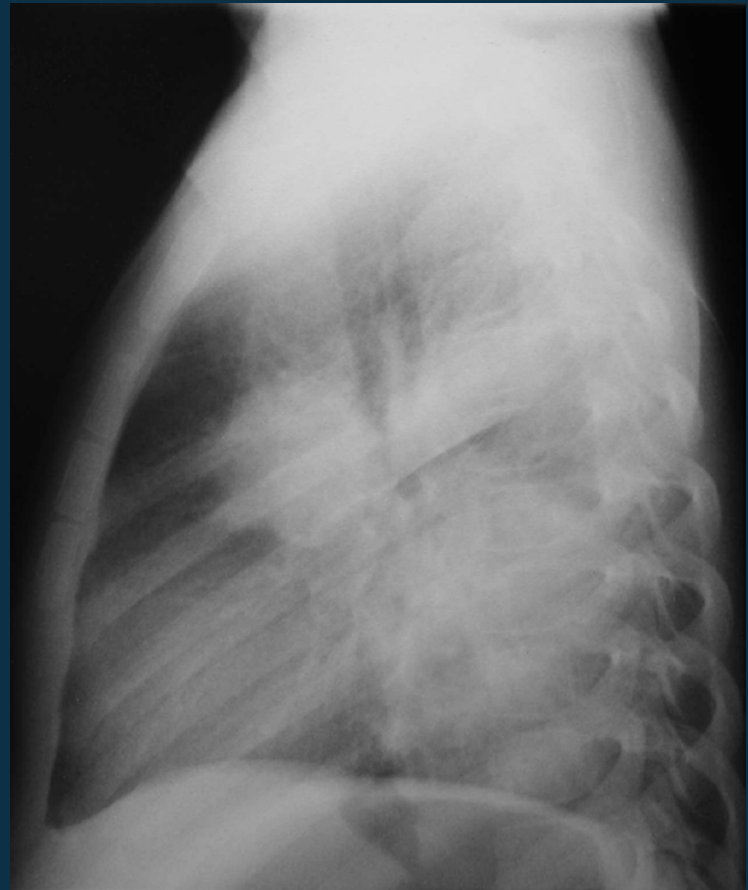
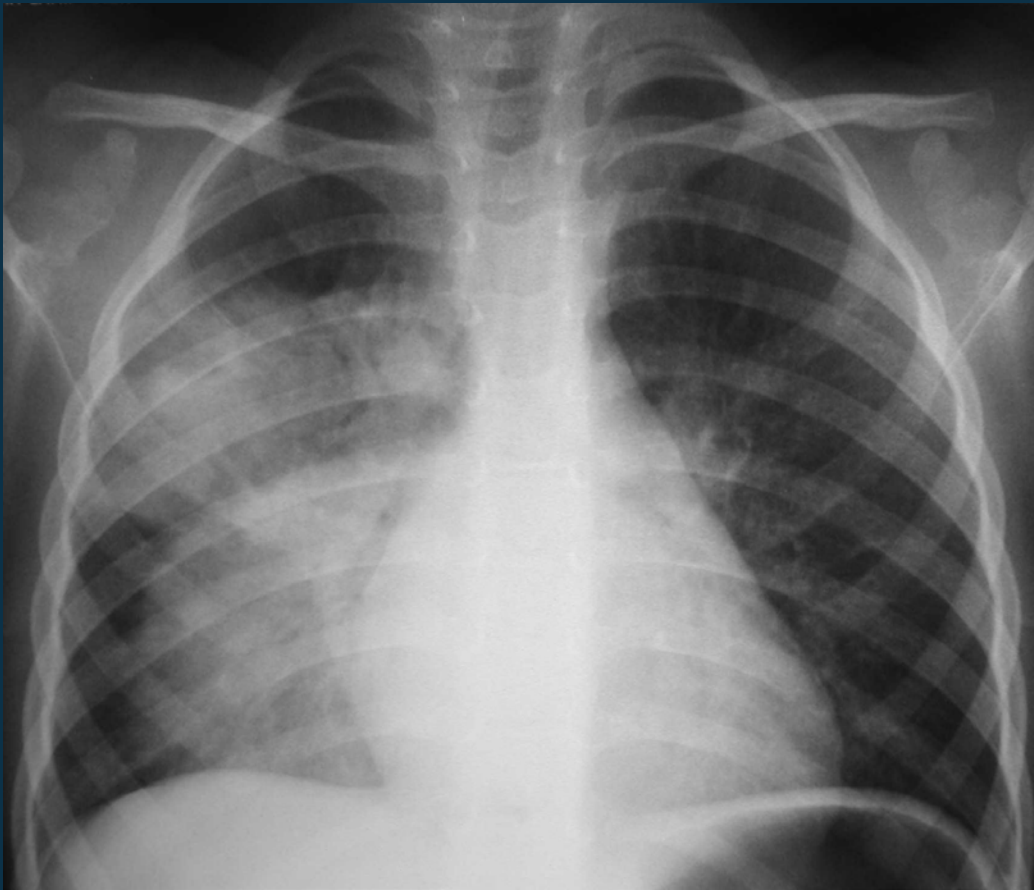
2. 'round' mass overlying the spine



What is your diagnosis ?

Left posterior alveolar opacity

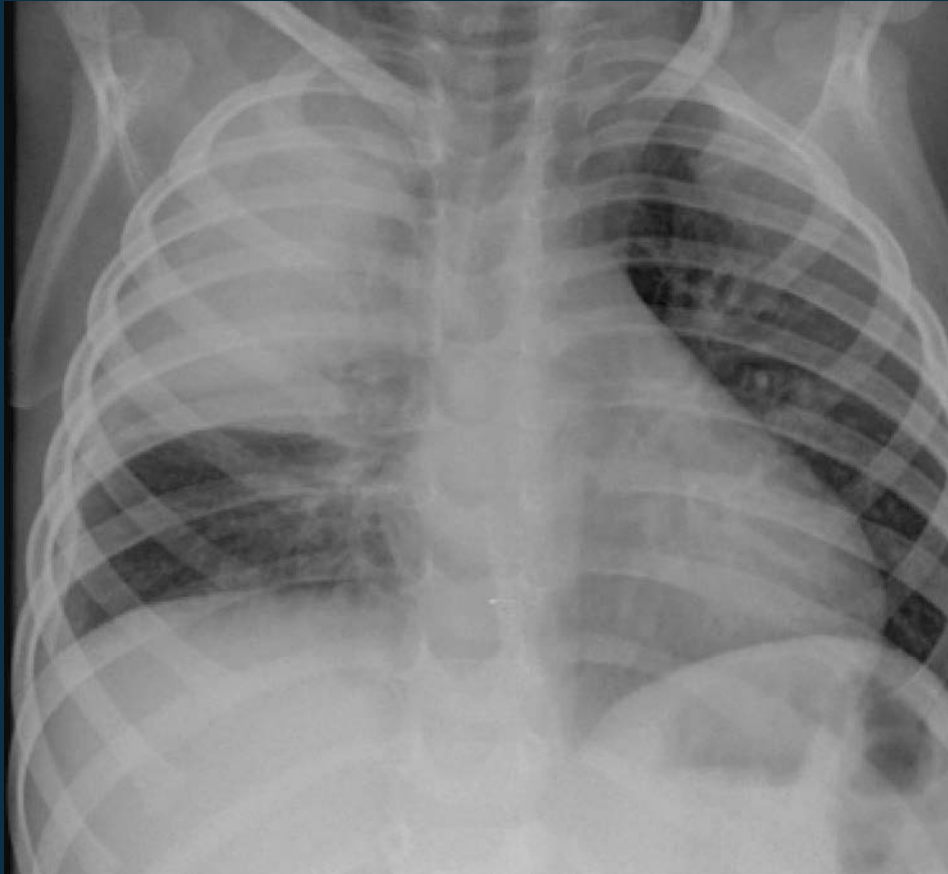
Sopheap, 3 years old with cough and fever



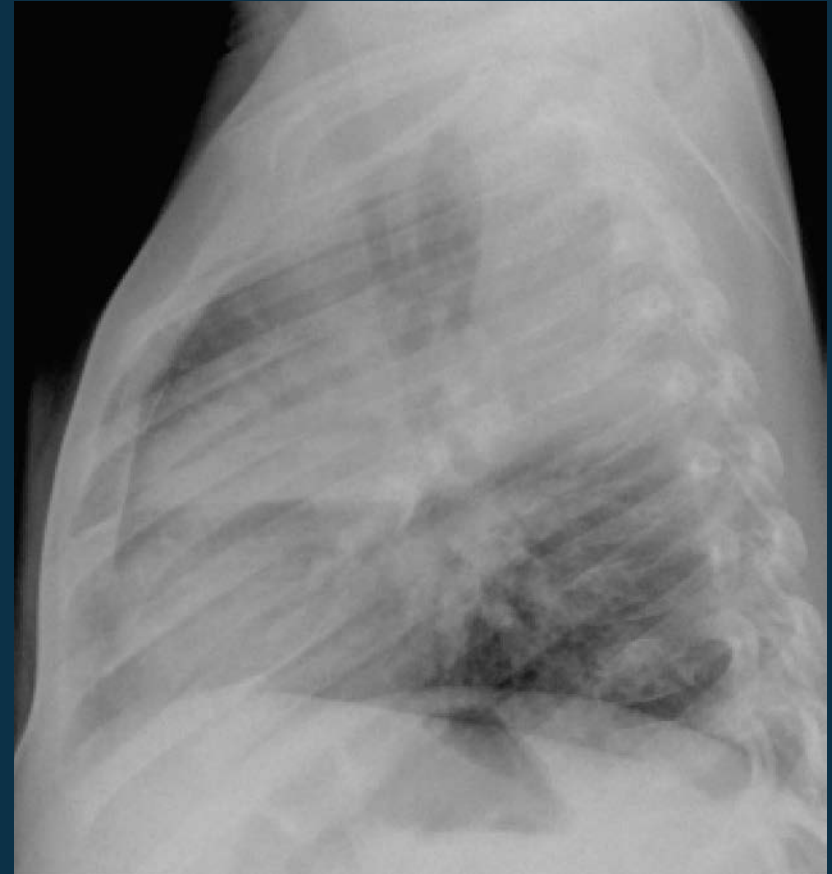
What do you see on this CXR ?

- . 2 opacities
 - right upper alveolar opacity
 - right lower posterior alveolar opacity (not erasing cardiac border)

What do you see on this CXR ?

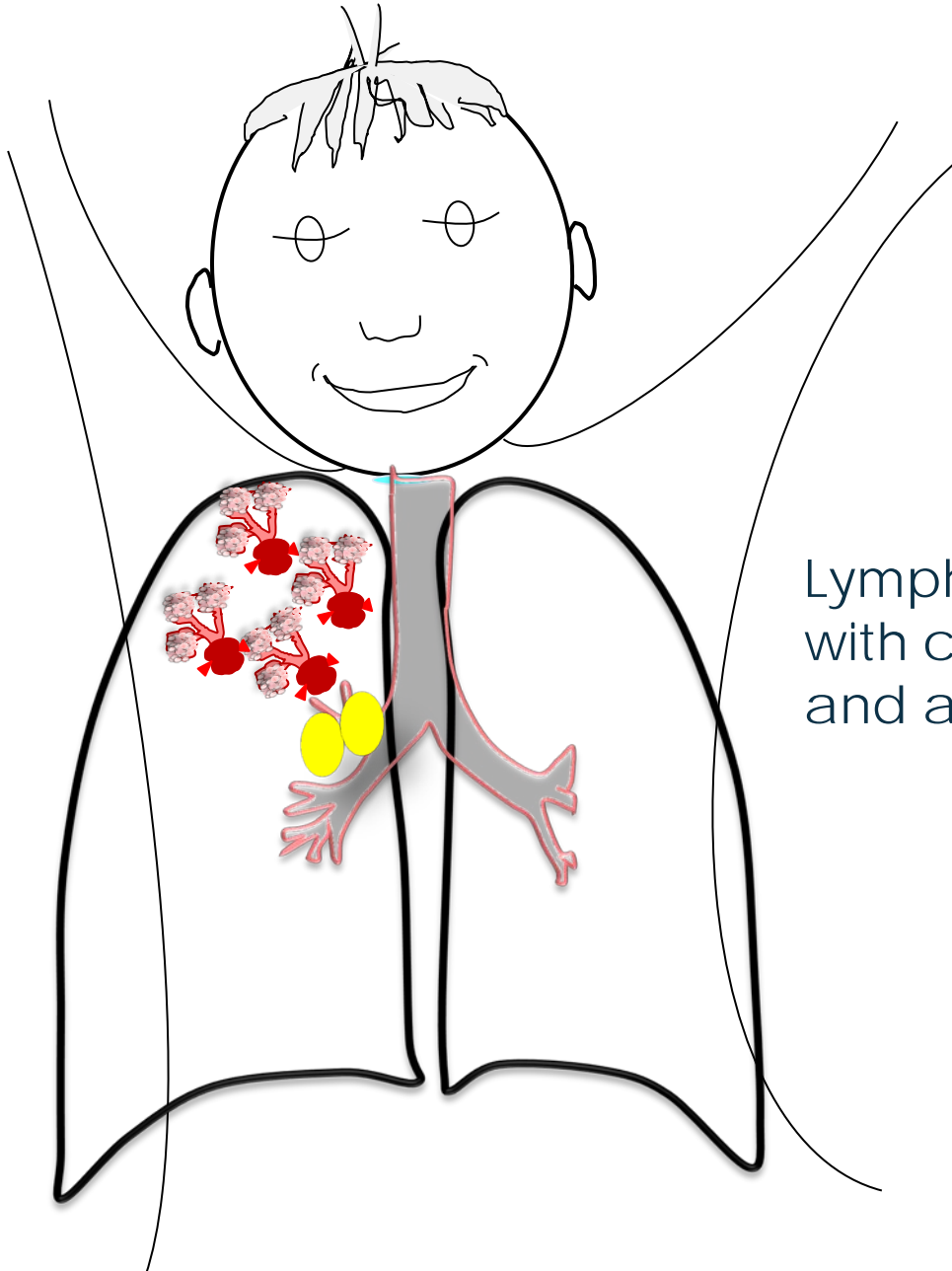


Front view:
Right upper alveolar opacity



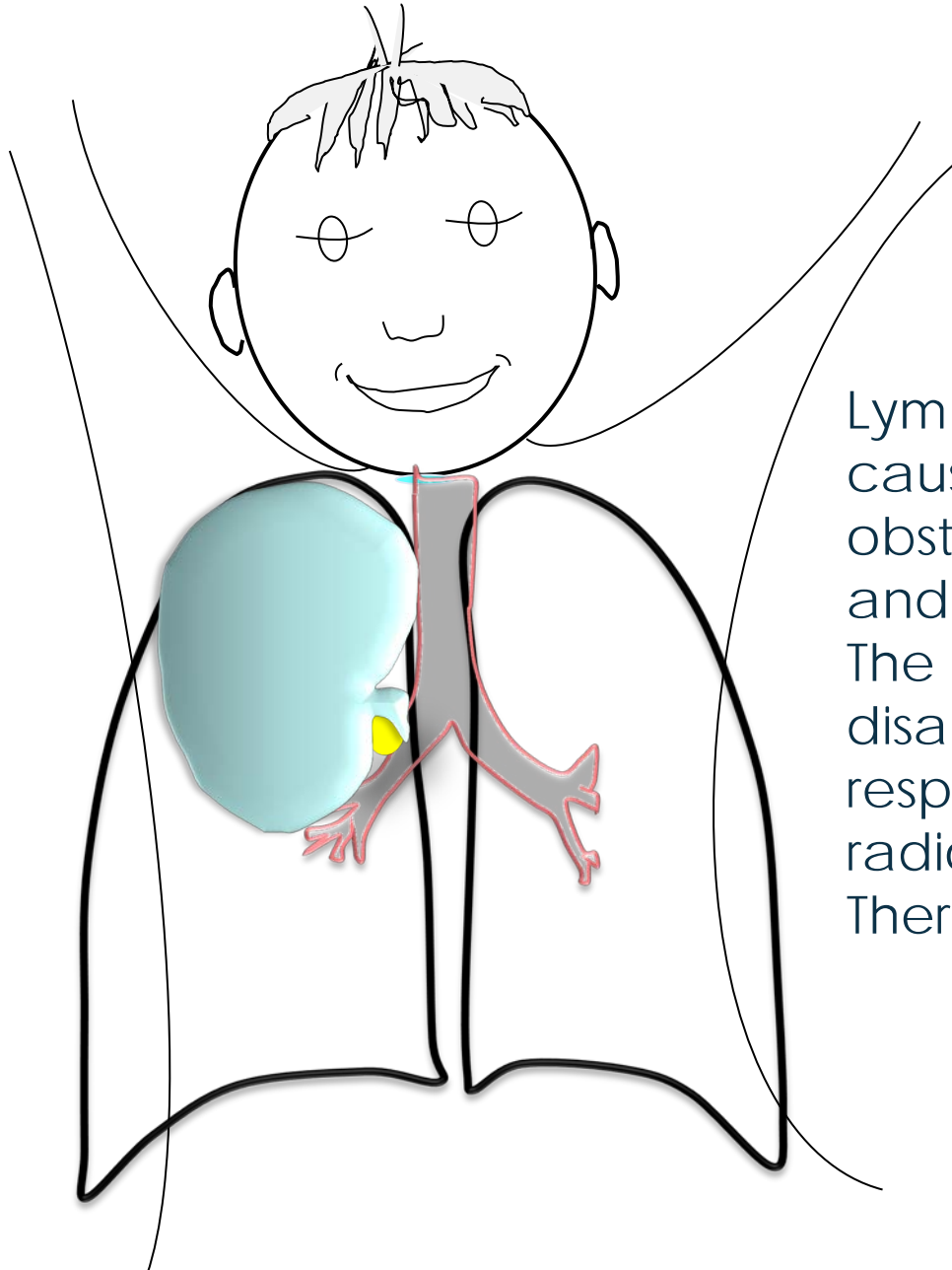
Lateral view (same patient):
minor fissure remains in a normal position,
indicating a space occupying process
with no volume loss

Atelectasis / alveolar collapse



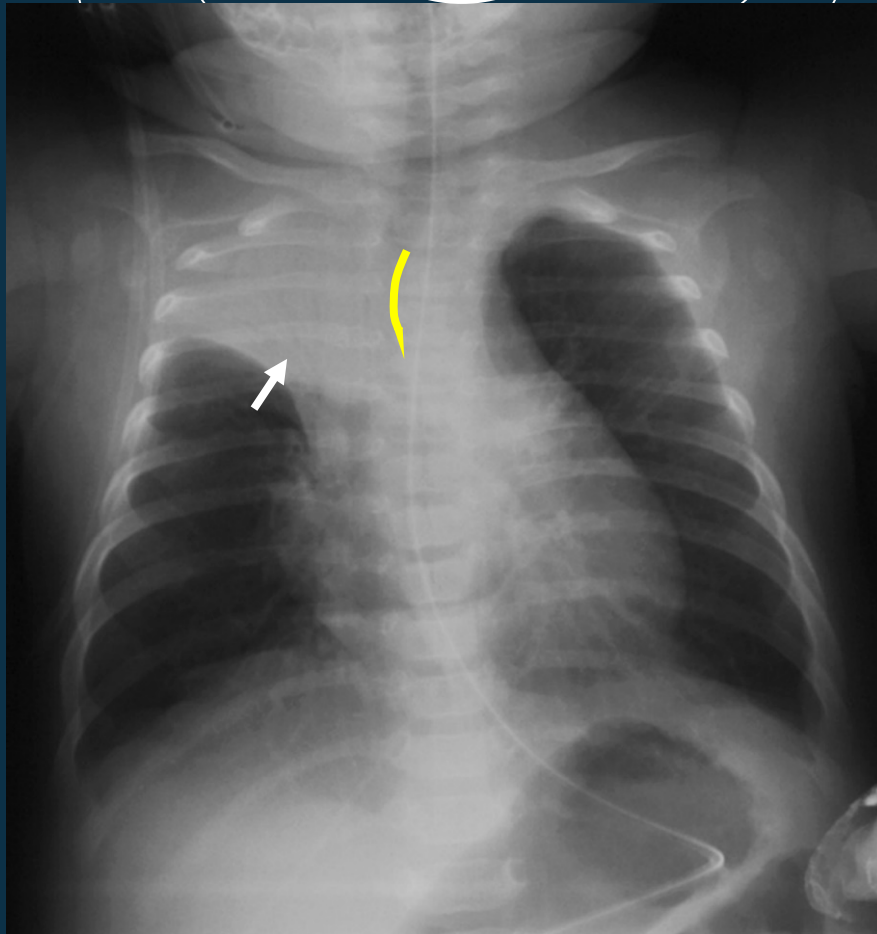
Lymph node compression
with complete obstruction
and alveolar collapse

Atelectasis / alveolar collapse



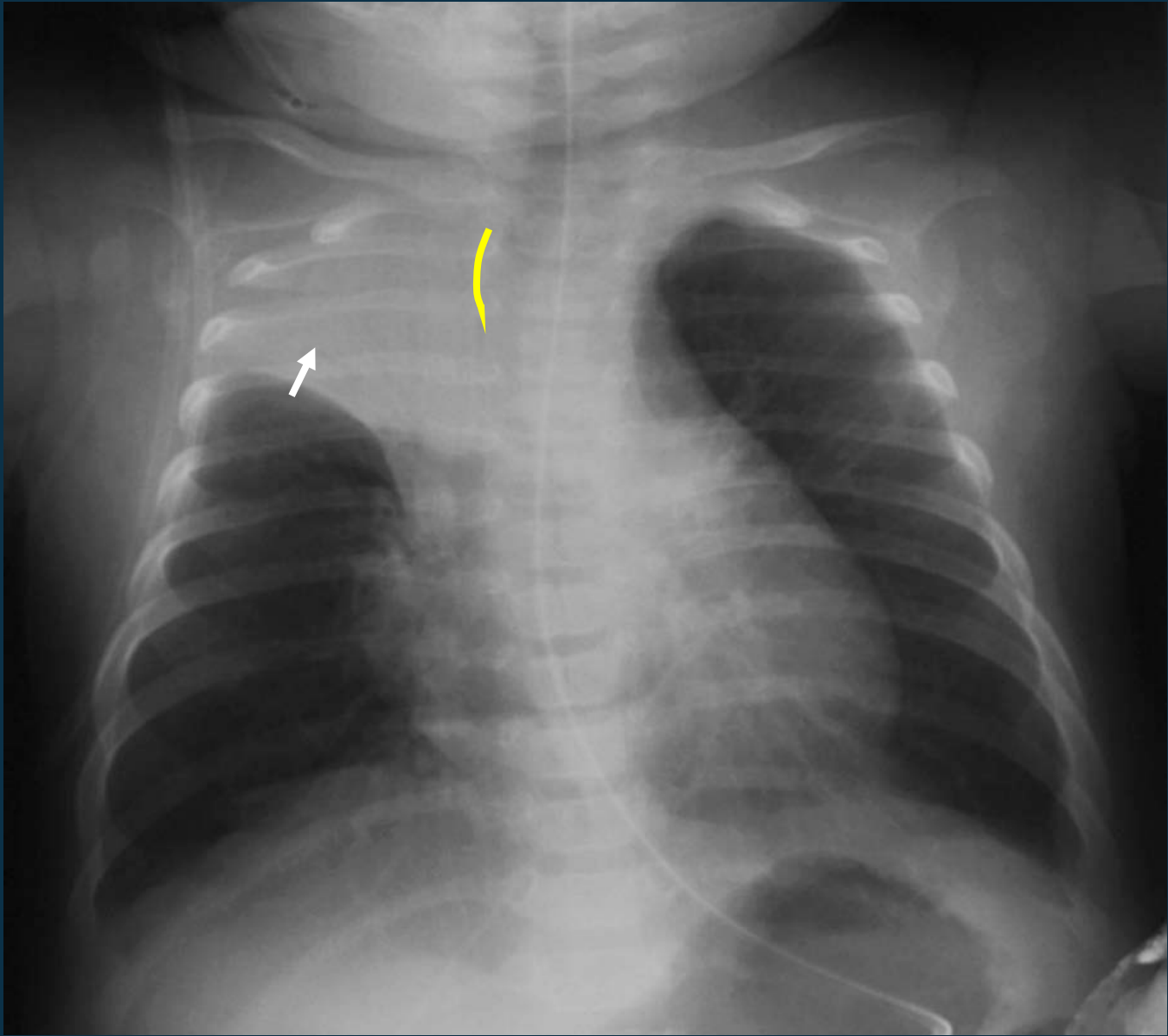
Lymph node compression causing complete airway obstruction and alveolar collapse. The alveolar air gradually disappears which is responsible for radiographic opacity. There is also loss of volume

Atelectasis / alveolar collapse



Lymph node compression with alveolar collapse causes radiographic opacity with loss of volume

Shift of trachea towards the side of the atelectasis (PULL)



Right upper lobe atelectasis

Atelectasis

What do you see on this X-ray ?

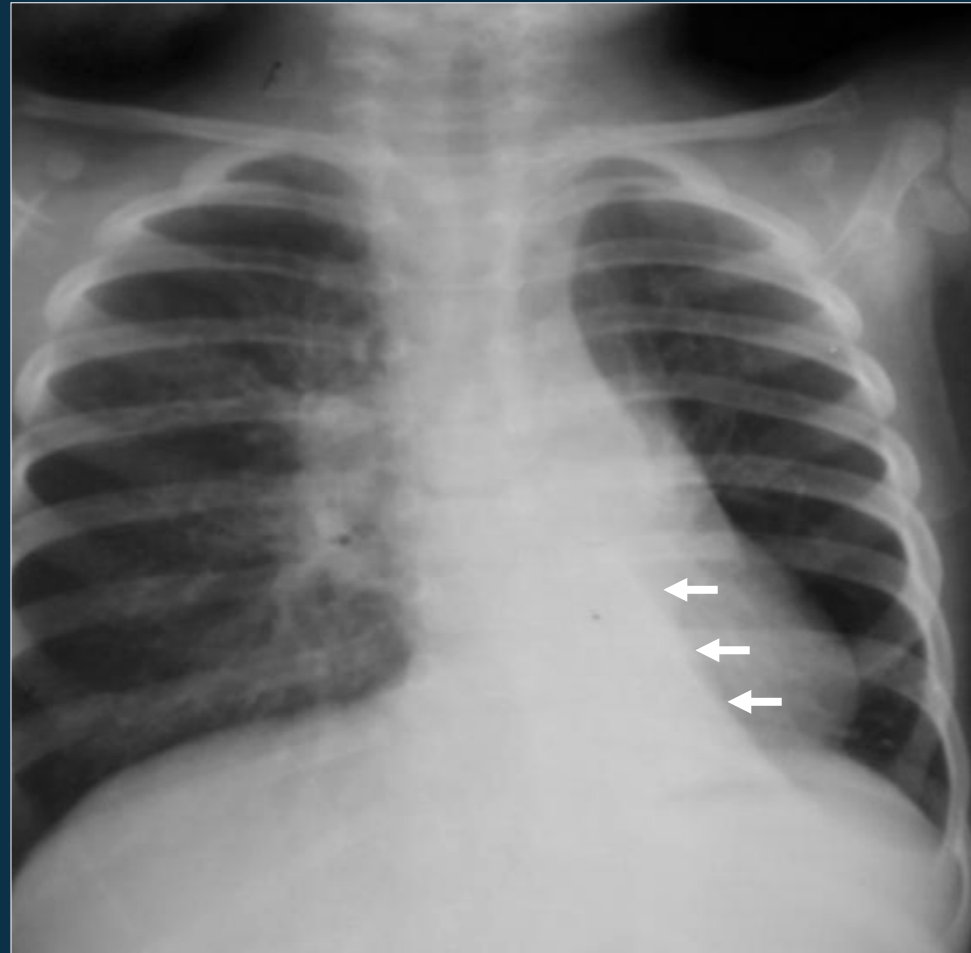- . Bilateral lymph nodes
- . Downward displacement of major fissure
- . Hyperinflation of upper lobe
- . Triangular paraspinal opacity

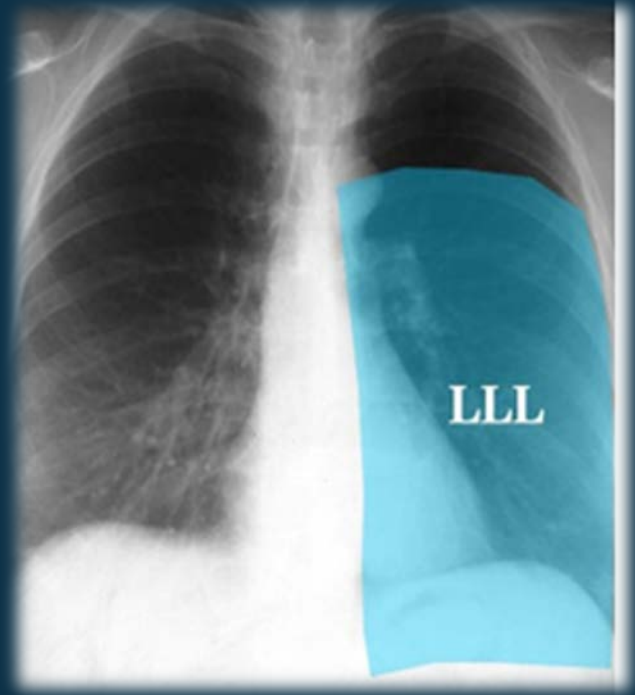
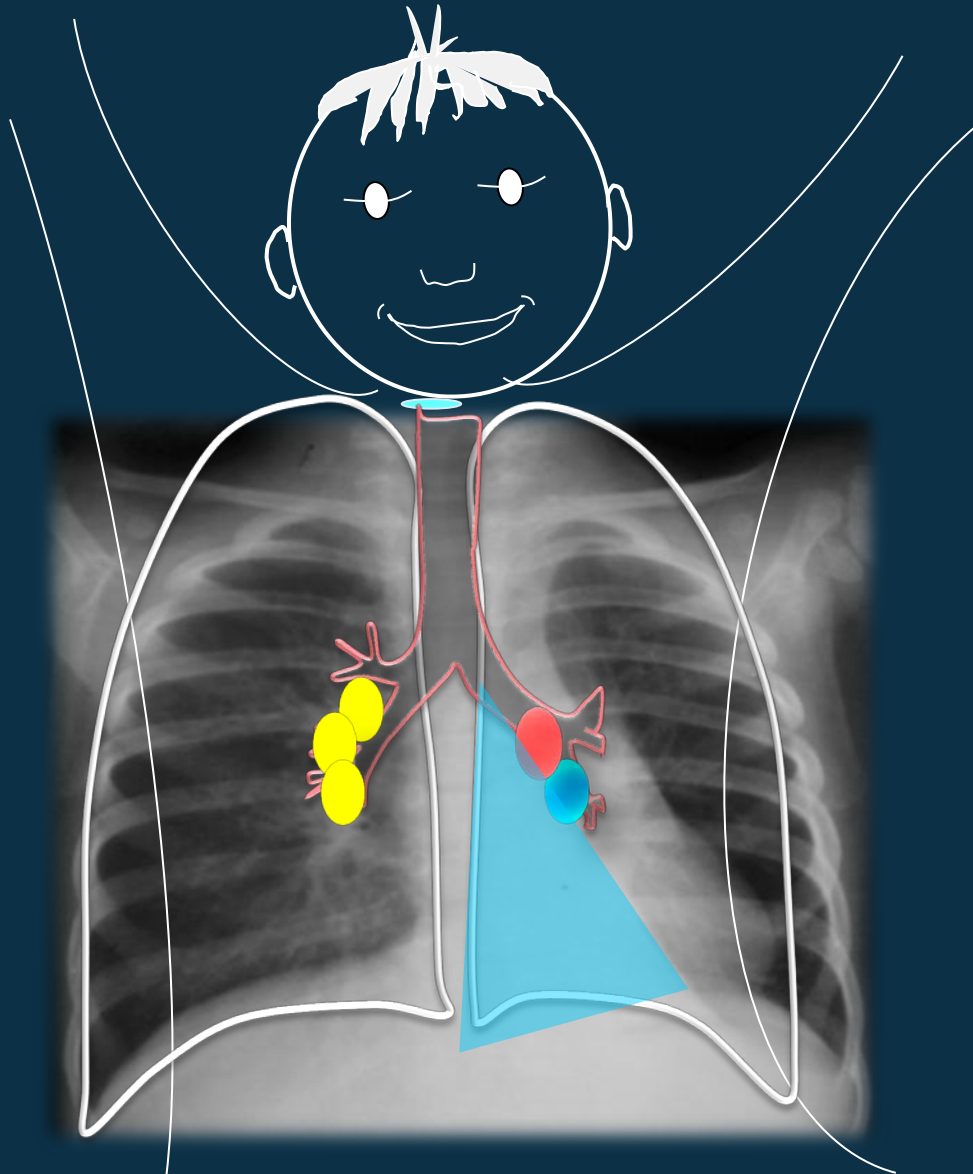
What is your diagnosis ?

- . Left lower lobe atelectasis :
compression of the left
inferior bronchus
by mediastinal lymph
nodes

TB

1 year old child







Normal Left Lower Lobe

Atelectasis

Atelectasis + round hilar mass:

- . In adults = most often cancer
- . In children = most often TB

Key Points: alveolar opacities

	Consolidation 	Atelectasis 
	Air in the lung is replaced by fluid – pus (infection)	Complete obstruction of a bronchus with alveolar collapse
Aspect	Non homogeneous With air bronchogram Non retractile Usually ill-defined	Homogeneous, Without air bronchogram Retractile - “volume loss “
Aetiology	<ul style="list-style-type: none">- TB pneumonia- Bacterial pneumonia	<ul style="list-style-type: none">- Tuberculosis- Foreign body- Mediastinal mass

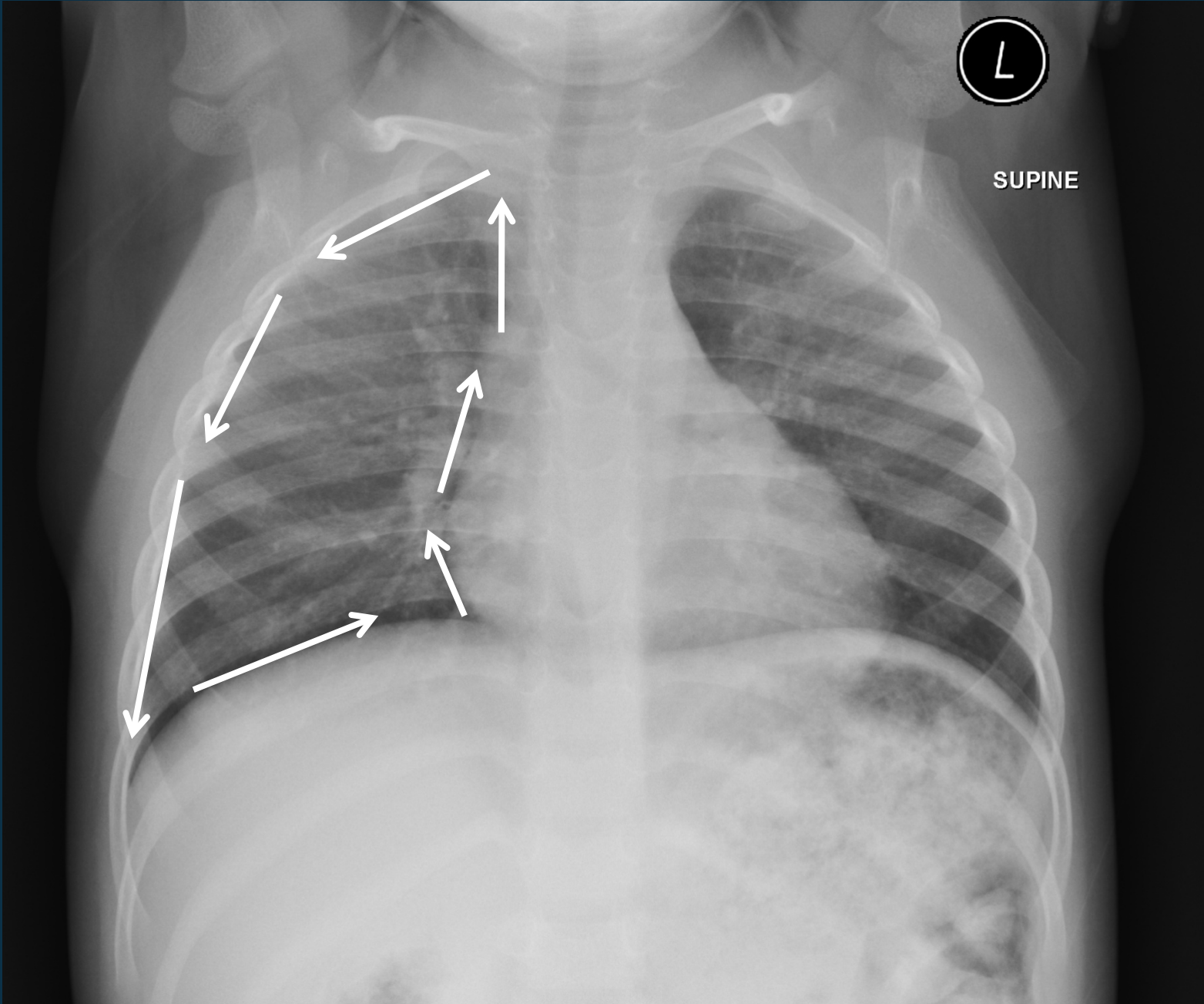
Pleura

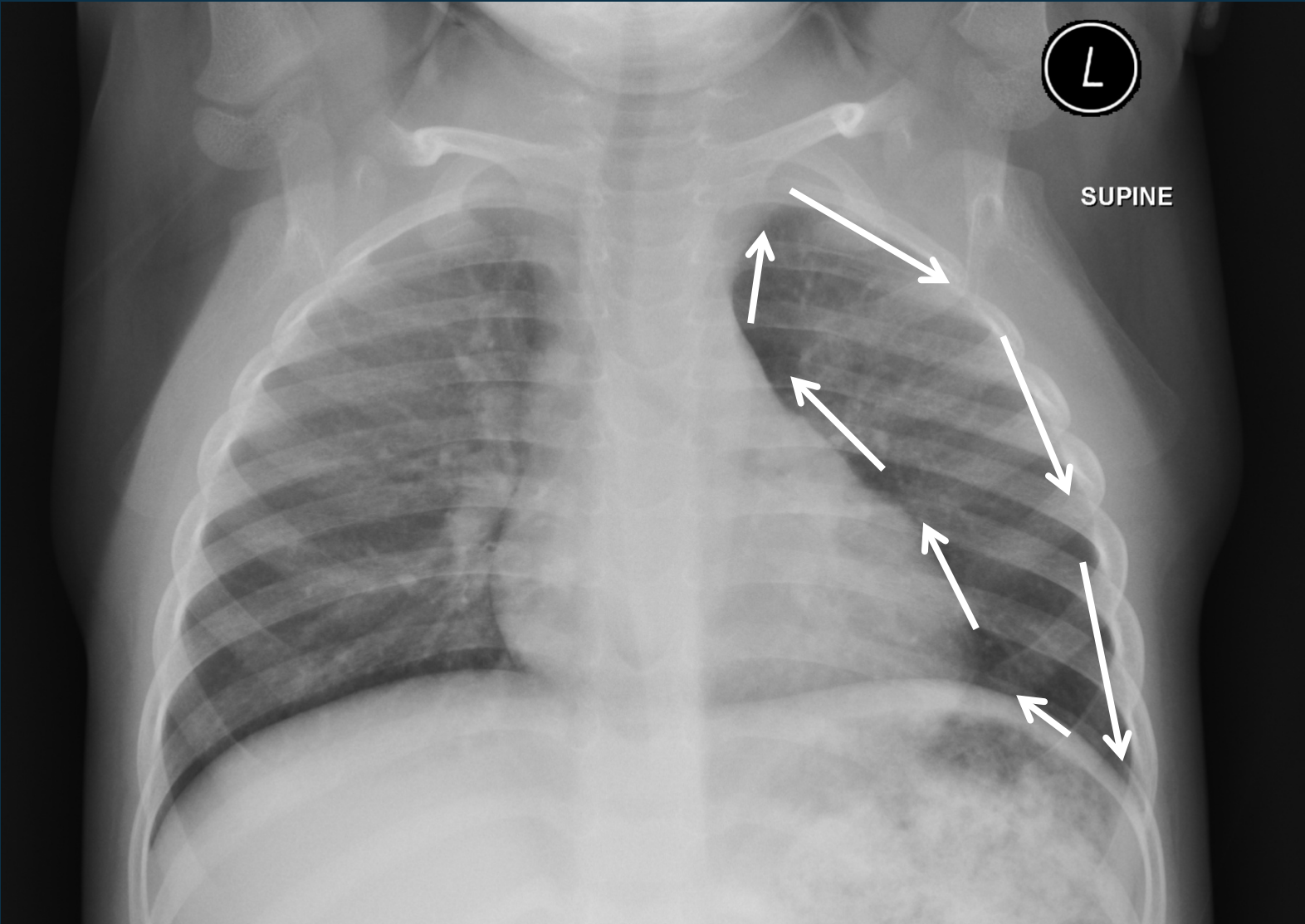
The pleura and pleural spaces are only visible when abnormal

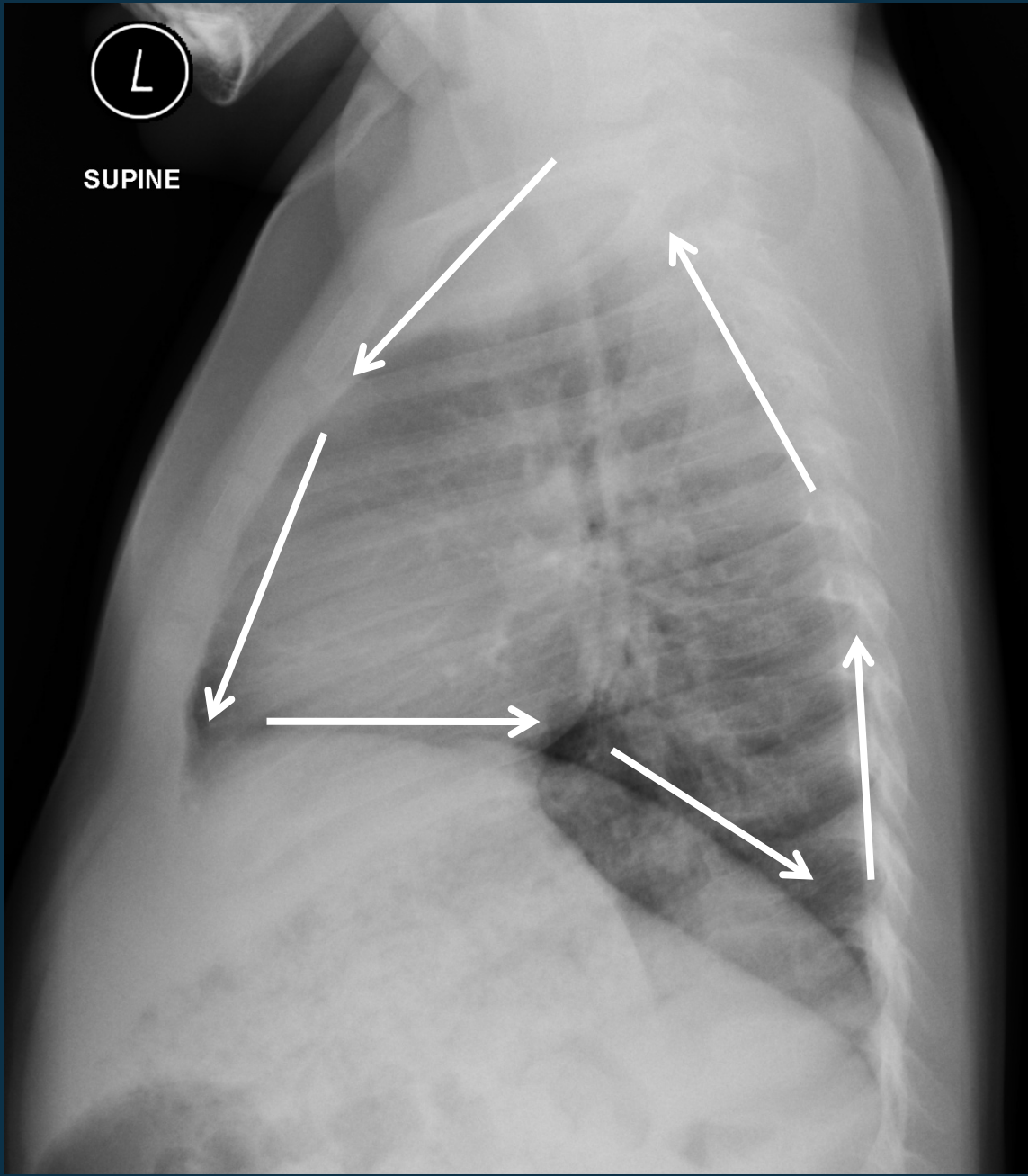
AP: run your eye around the inside of both lungs

- . Apex to costo-phrenic angle
- . From costo-phrenic angle to cardio-phrenic border
- . From cardio-phrenic border to apex
- . Right then left

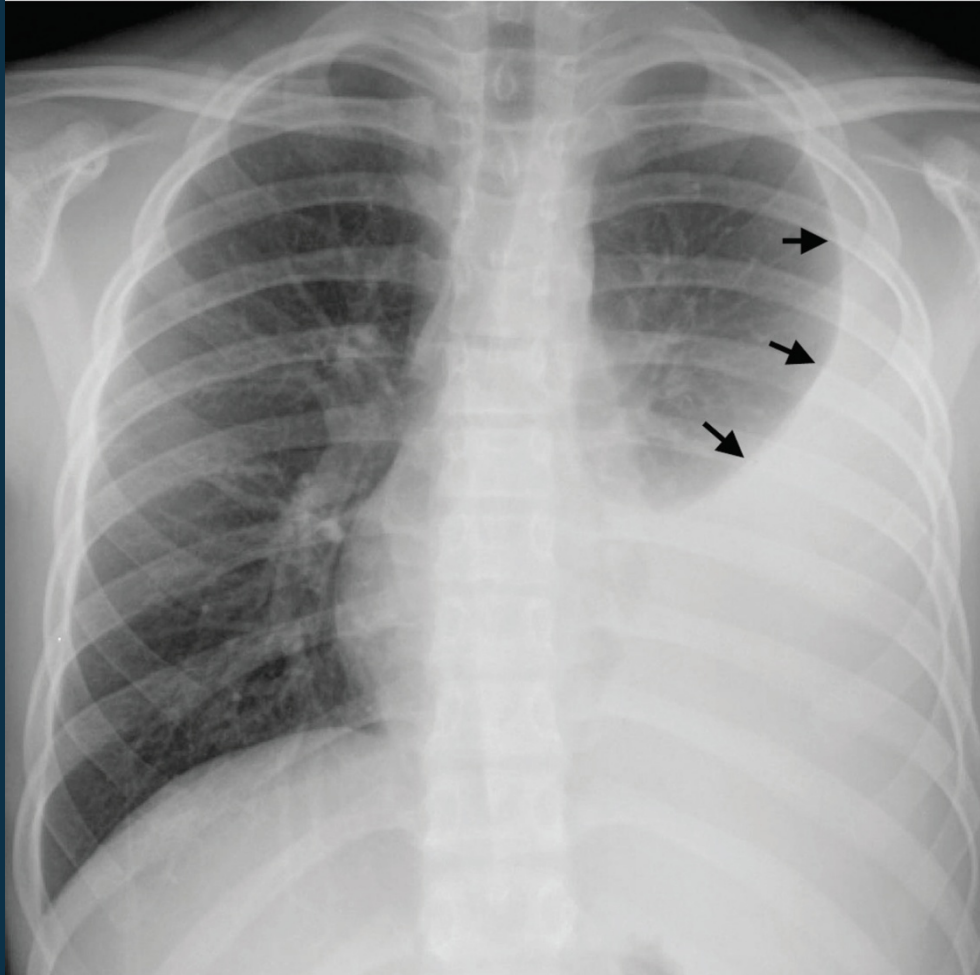
Lateral : do the same as for the AP







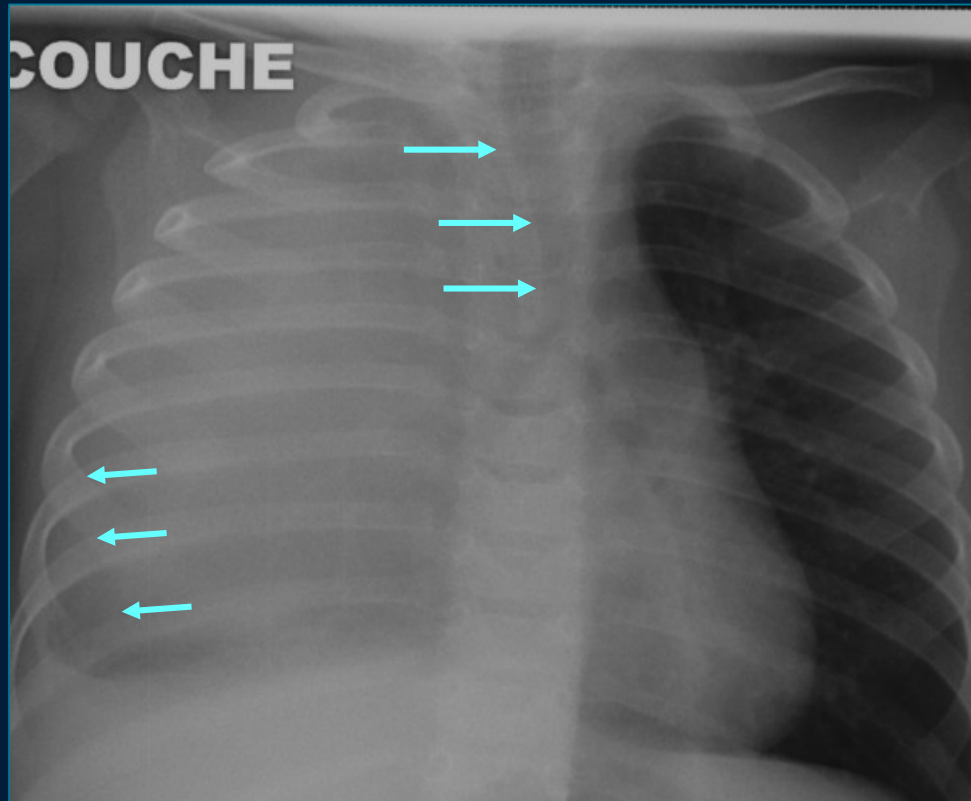
Pleural opacities: pleural effusion (standing position)



Pleural effusion:

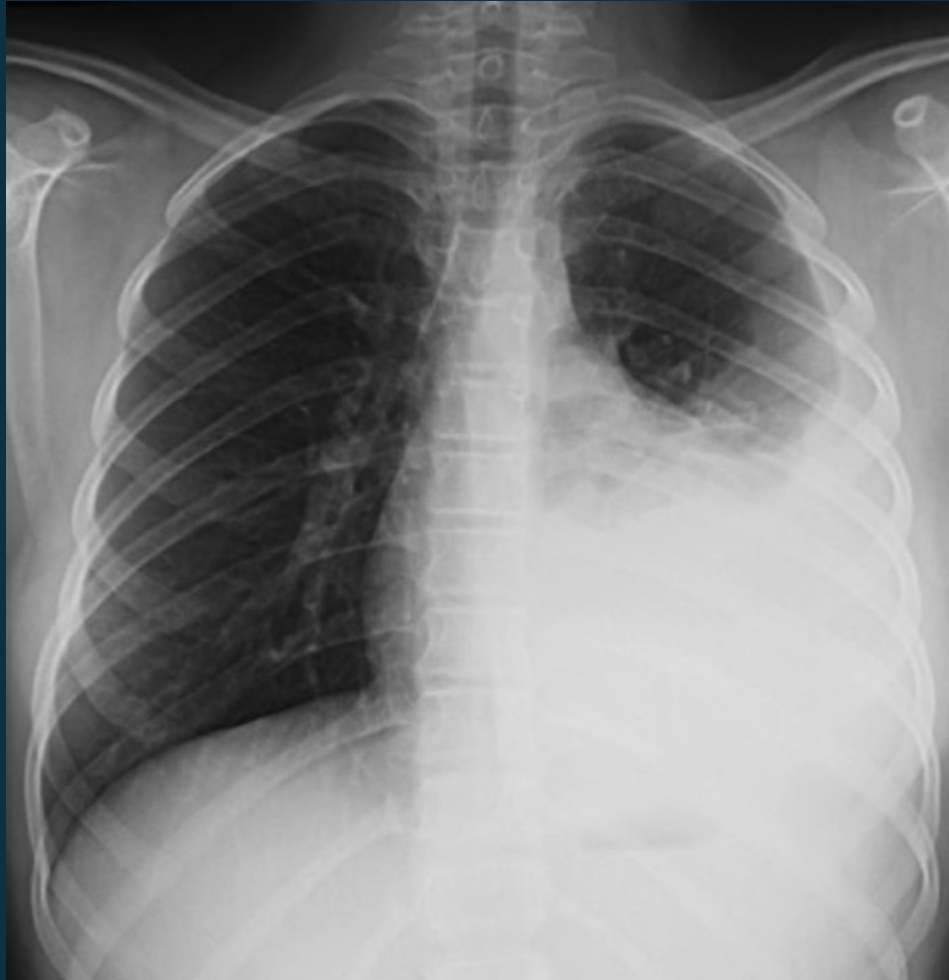- . Homogeneous opacity
- . Concave
- . Declive
- . Not systematized
- . Pushes surrounding structures away

=> Frontal view : pleural effusion.




Right large compressive Pleural effusion
CXR in supine position

Pleural opacities: pleural effusion



Left pneumonia with large pleural effusion

Second circle



Do the lungs have an abnormal density?

Key points second circle : Is there an Abnormal density of the lungs ?

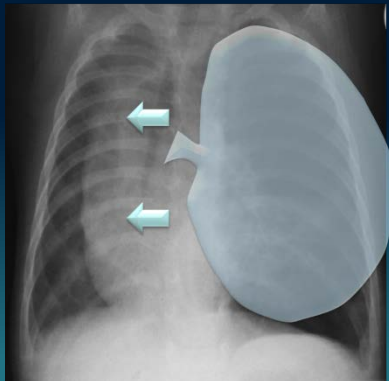
HYPERLUCENCIES

Blacker

Asymmetry between right and left lung

Air-trapping

- Shift of surrounding structures



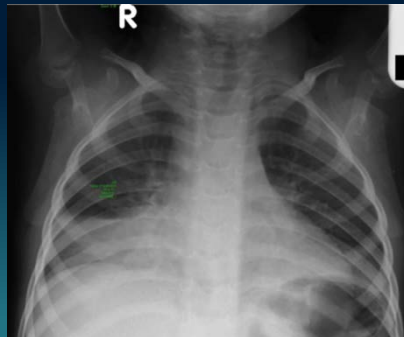
OPACITIES

Whiter

Alveolar opacities

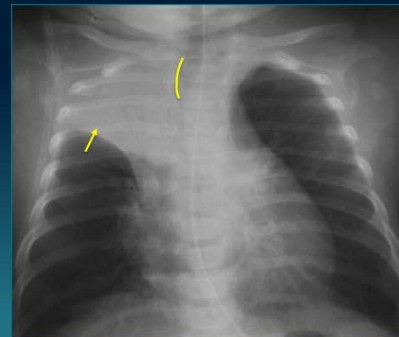
Consolidation

- non homogeneous (Air bronchogram)
- Ill-defined or systematized



Atelectasis

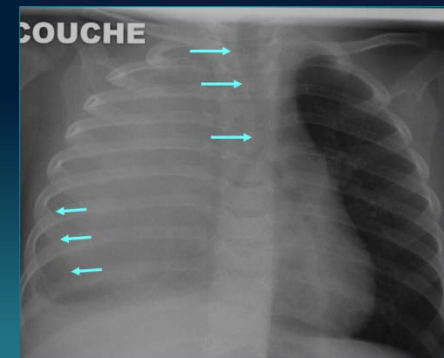
- Homogeneous
- Loss of volume
- Attracts surrounding structures



Pleural opacities

Pleural effusion

- Homogeneous
- Pushes surrounding structures



Module 1 How to read a CXR

Chap1: Technical and anatomical aspects

Chap2: Systematic approach to CXR interpretation

Part1. Quality factors

Part2. Normal CXR

Part3. First circle

1. Soft part of the chest wall
2. Diaphragmatic areas
3. Bony Thorax abnormalities

Part4. Second circle

4. Lung
5. Pleura

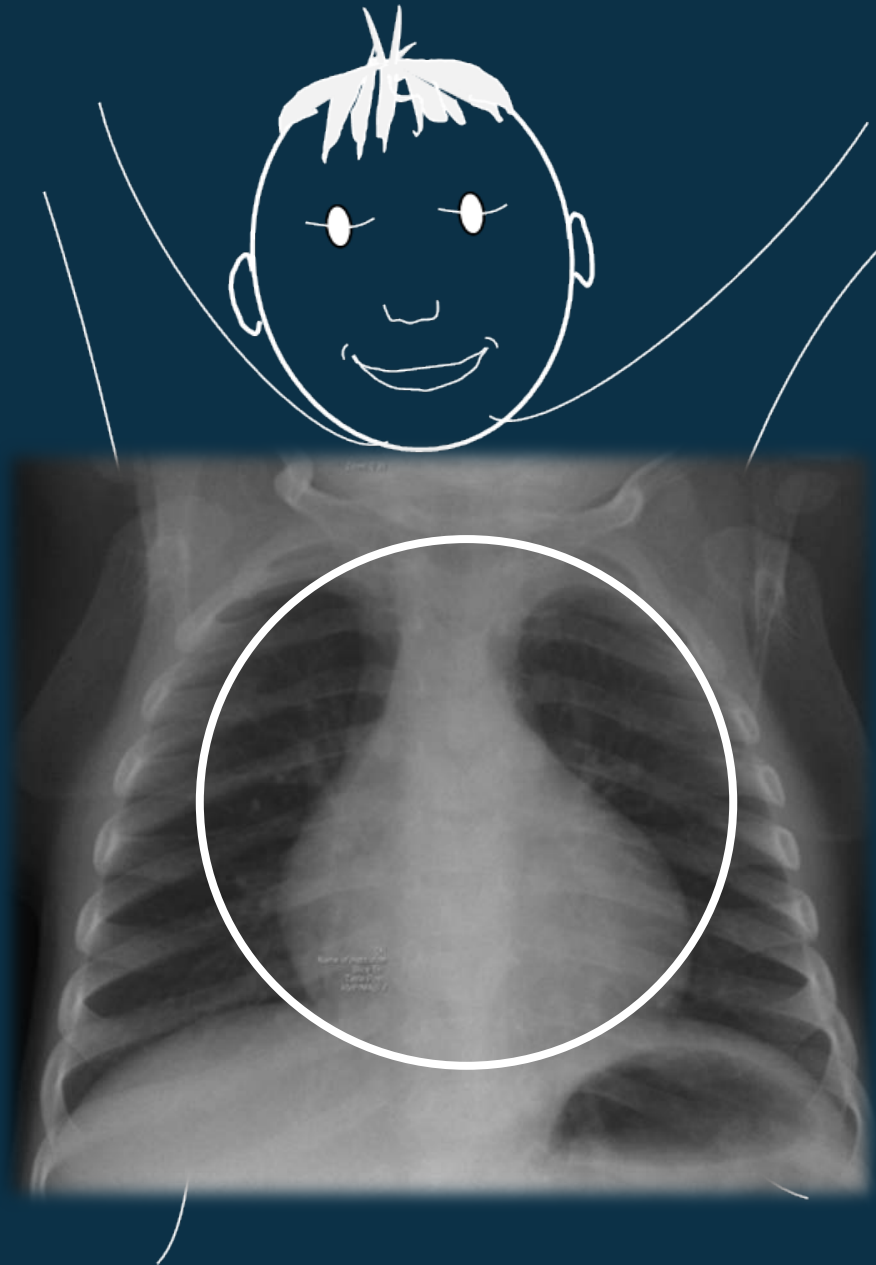
Part5. Third circle

- 6. Airways**
- 7. Hili and Mediastinum**
- 8. Lymph nodes**
- 9. Heart**

Part6. The hidden areas

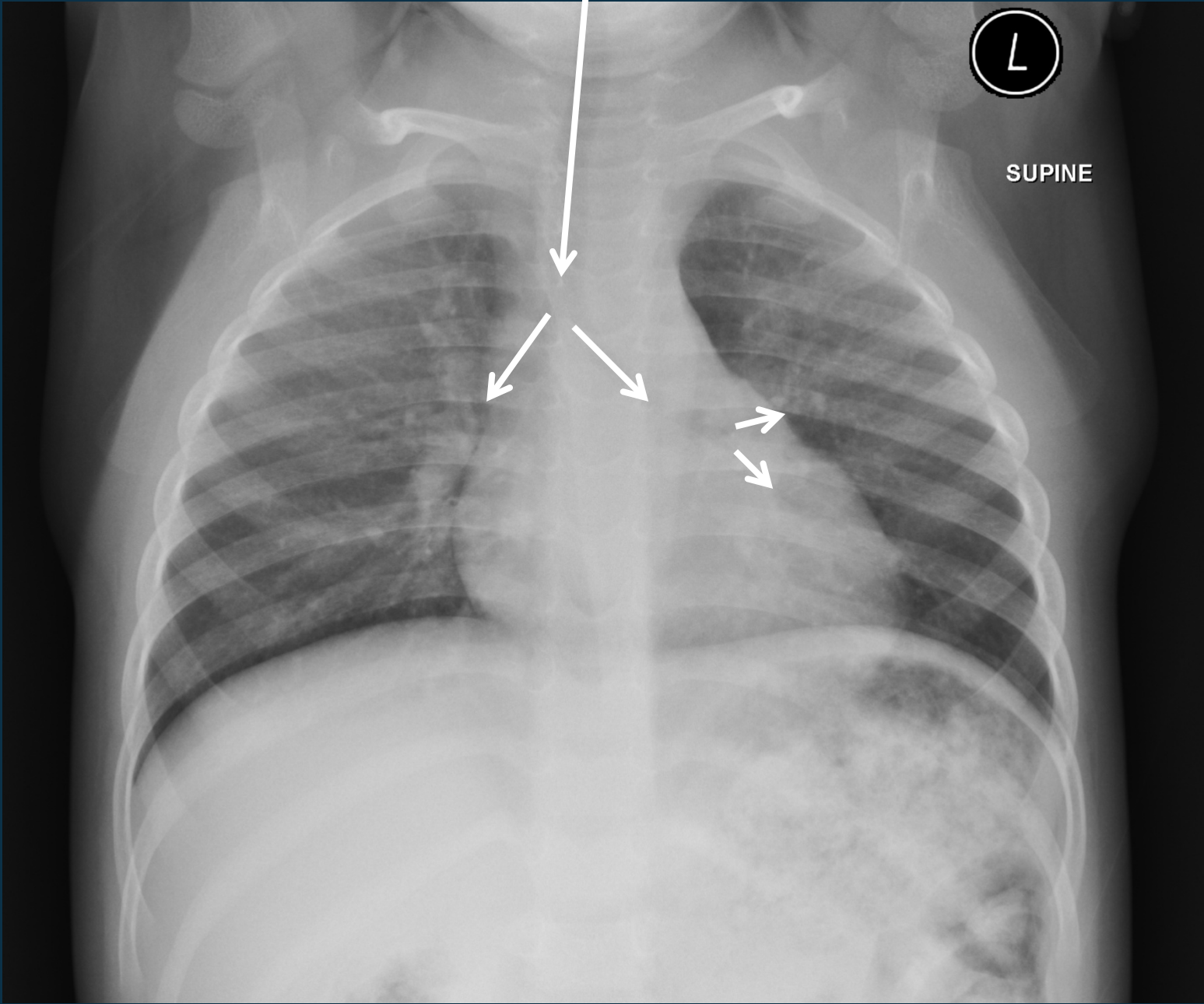
Part7. Conclusion

Third circle



Airways

1. Use AP (lateral not useful to assess airways)
2. Follow the trachea from the head to the bifurcation :
normal trachea is displaced to the right
by the presence of a normal left-side aortic arch
(or should be at least central)
3. Trace both main bronchi
4. Assess the airways : position, calibre, displacement
5. Look for:
 - . Airway narrowing
 - . Airway deviation
 - . Splaying of the carina



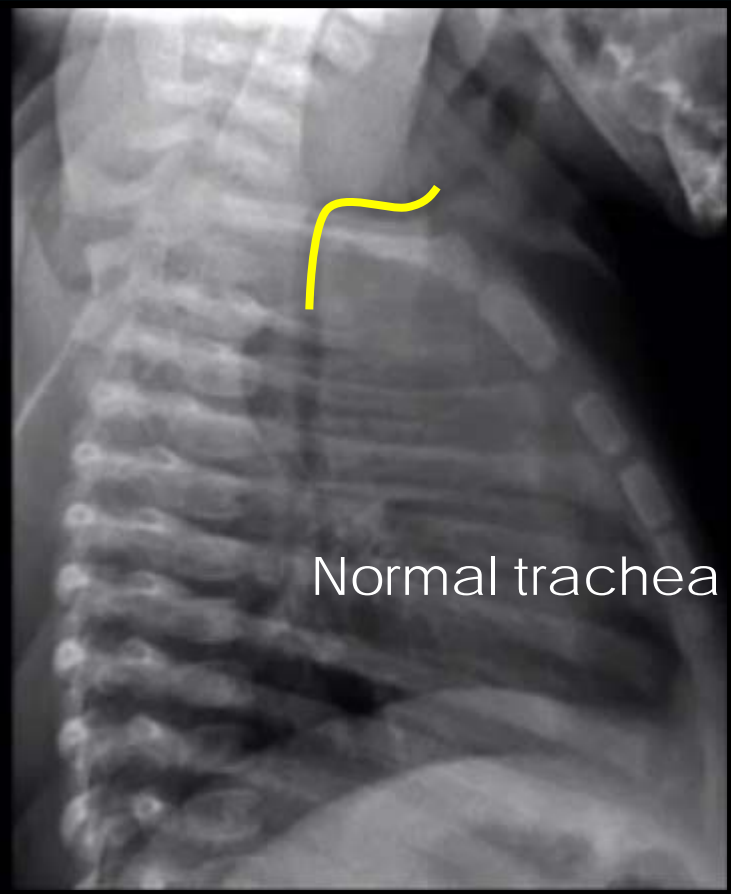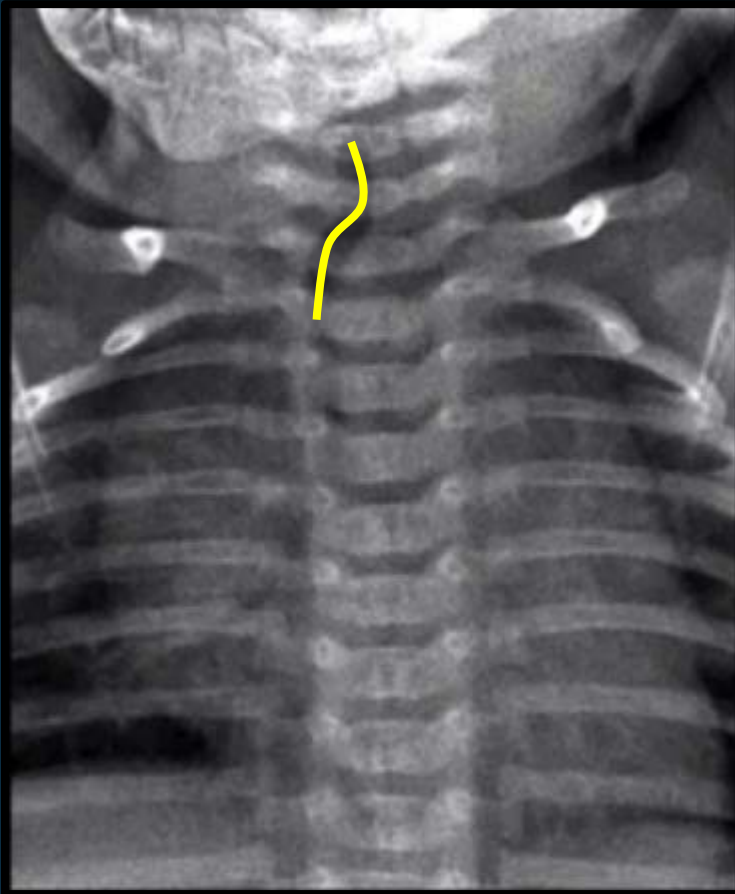
L

SUPINE

Airway : 2 month old with cough and fever

What do you see on this X-ray ?

Is the trachea normal ?

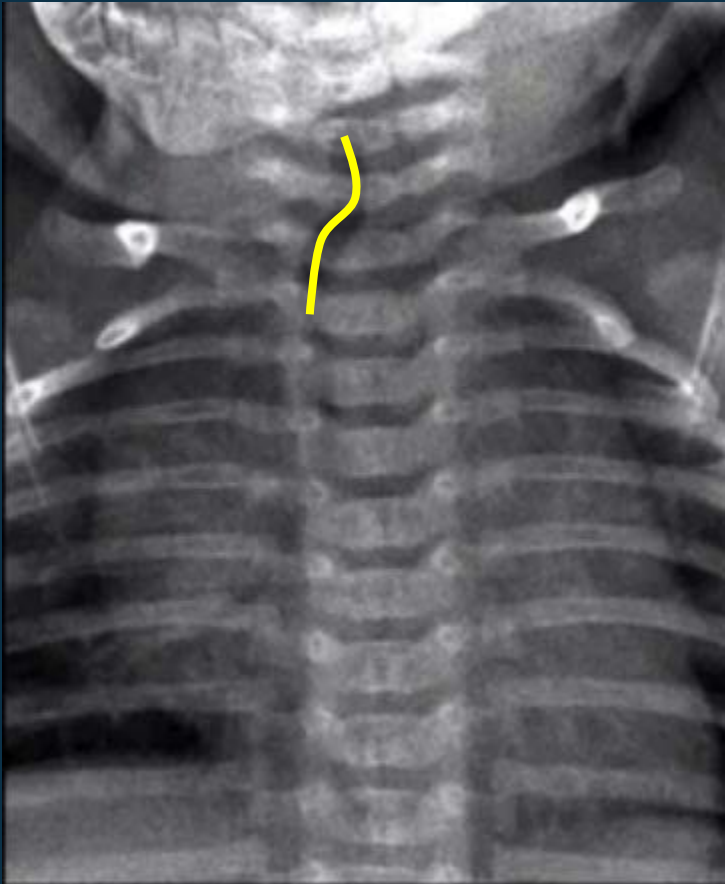


What is your diagnosis ?

Normal expiratory tracheal buckling

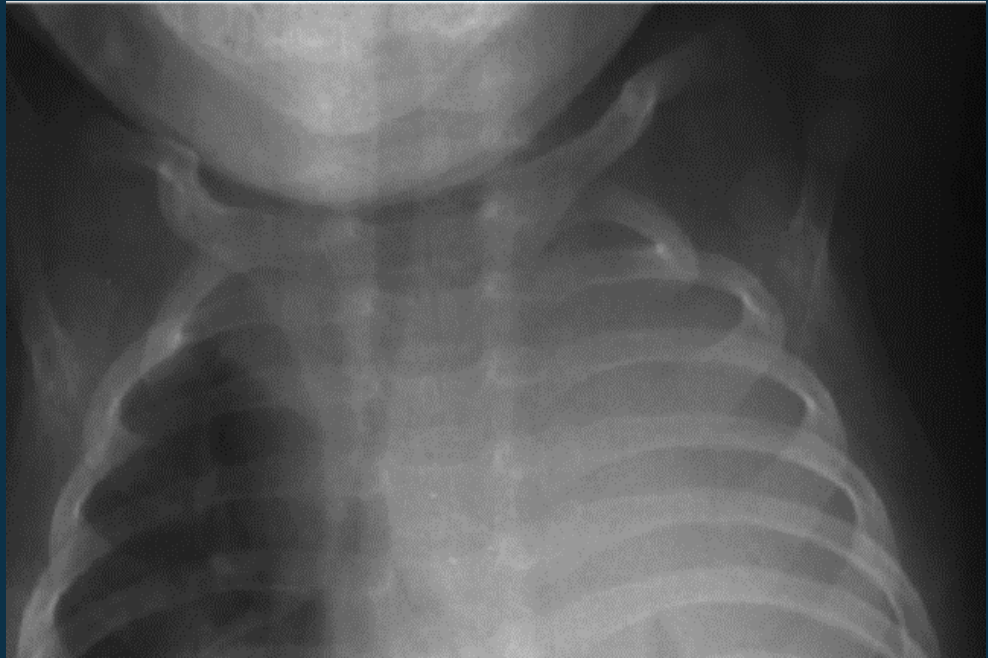
Airway : 2 month old with cough and fever

What do you see on this CXR ?



Trachea buckle

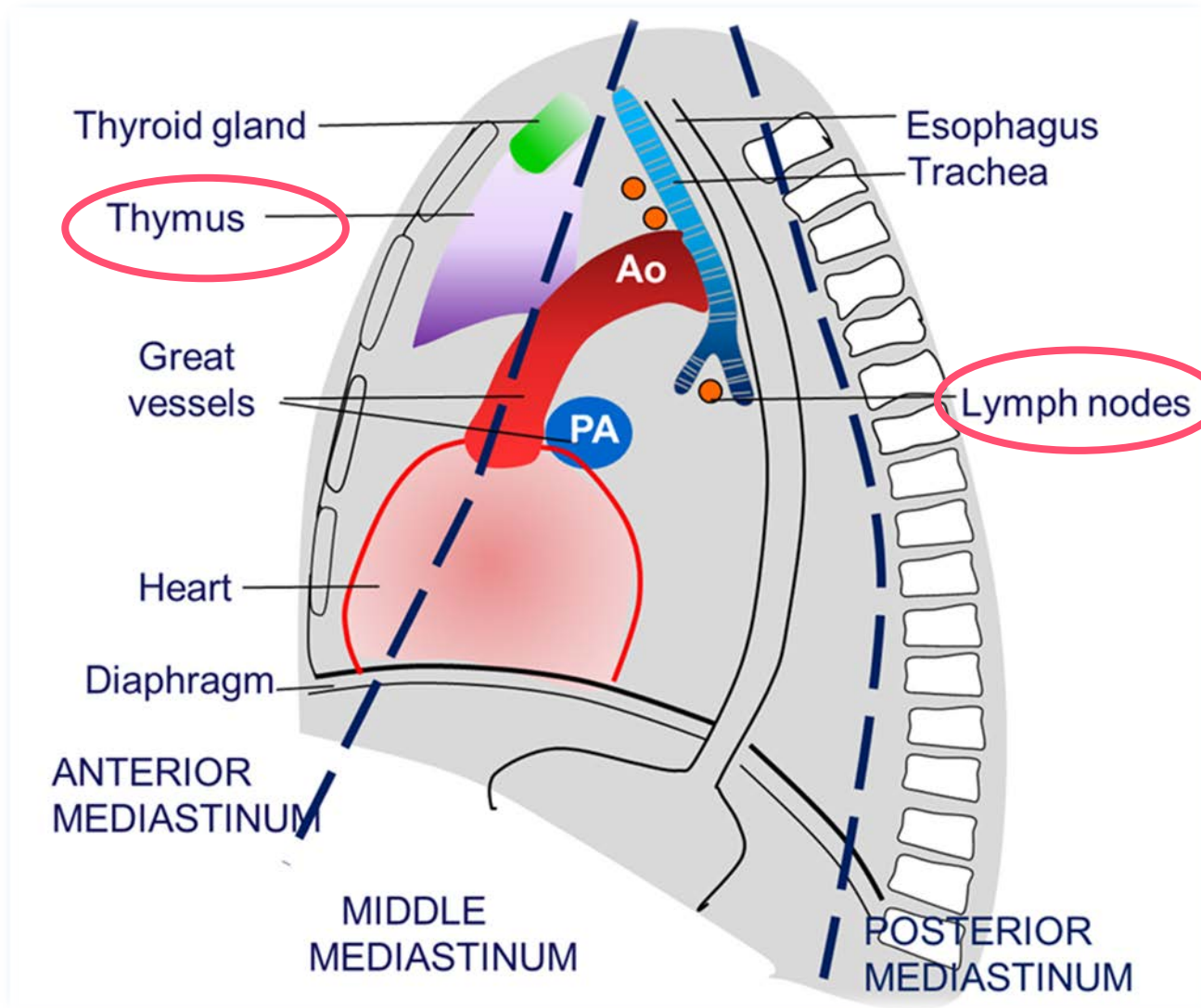
Do not confuse with



Compression and displacement of the trachea by a mass

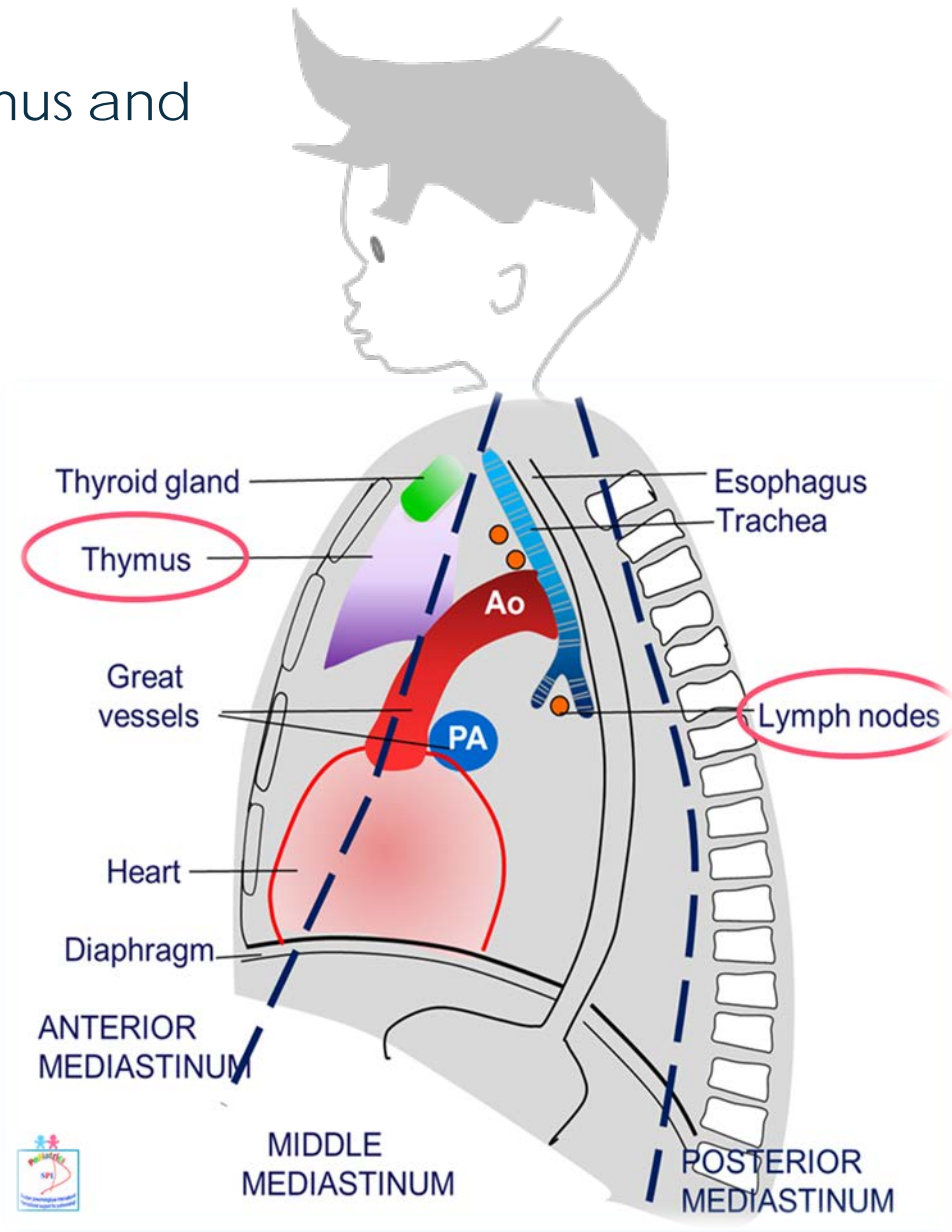
Mediastinum

Space between the 2 lungs containing



Mediastinal masses

We will focus on thymus and lymph nodes

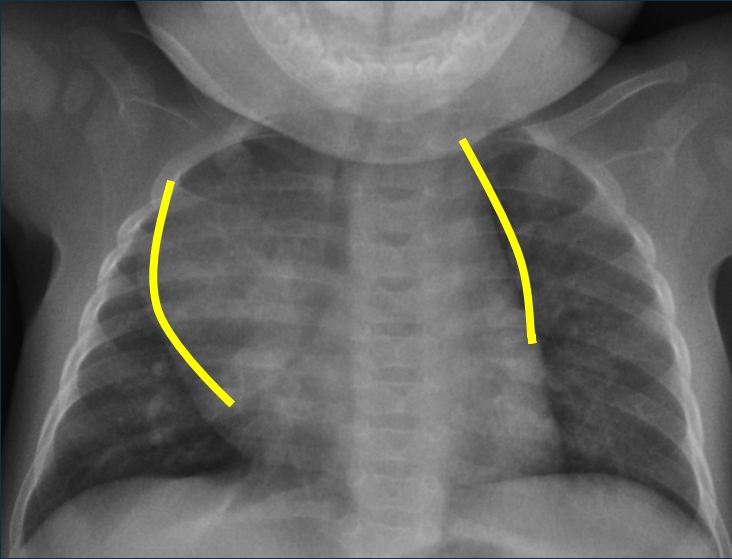


Beware of thymus

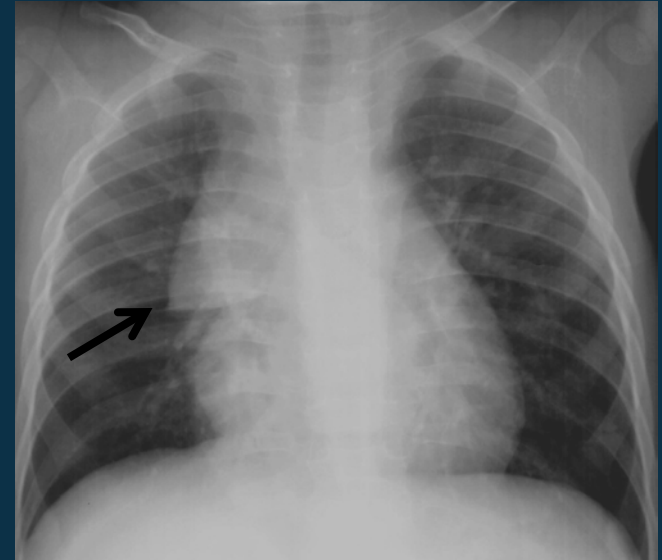
1. Common cause of widened mediastinum

2. It is disproportionately larger in child (smaller body mass)
 - . Increases in the first few months of life
 - . Gradually regresses by the end of the first year
 - . Usually visible < 2 years old and occasionally beyond
 - . It regresses in size under stress conditions
(acute respiratory illness, surgery, steroid therapy, radiotherapy ..)

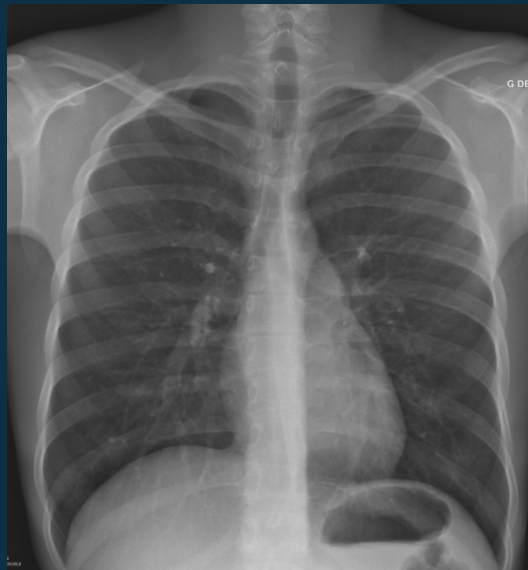
Thymus : image evolution with age



2 month old



7 month old

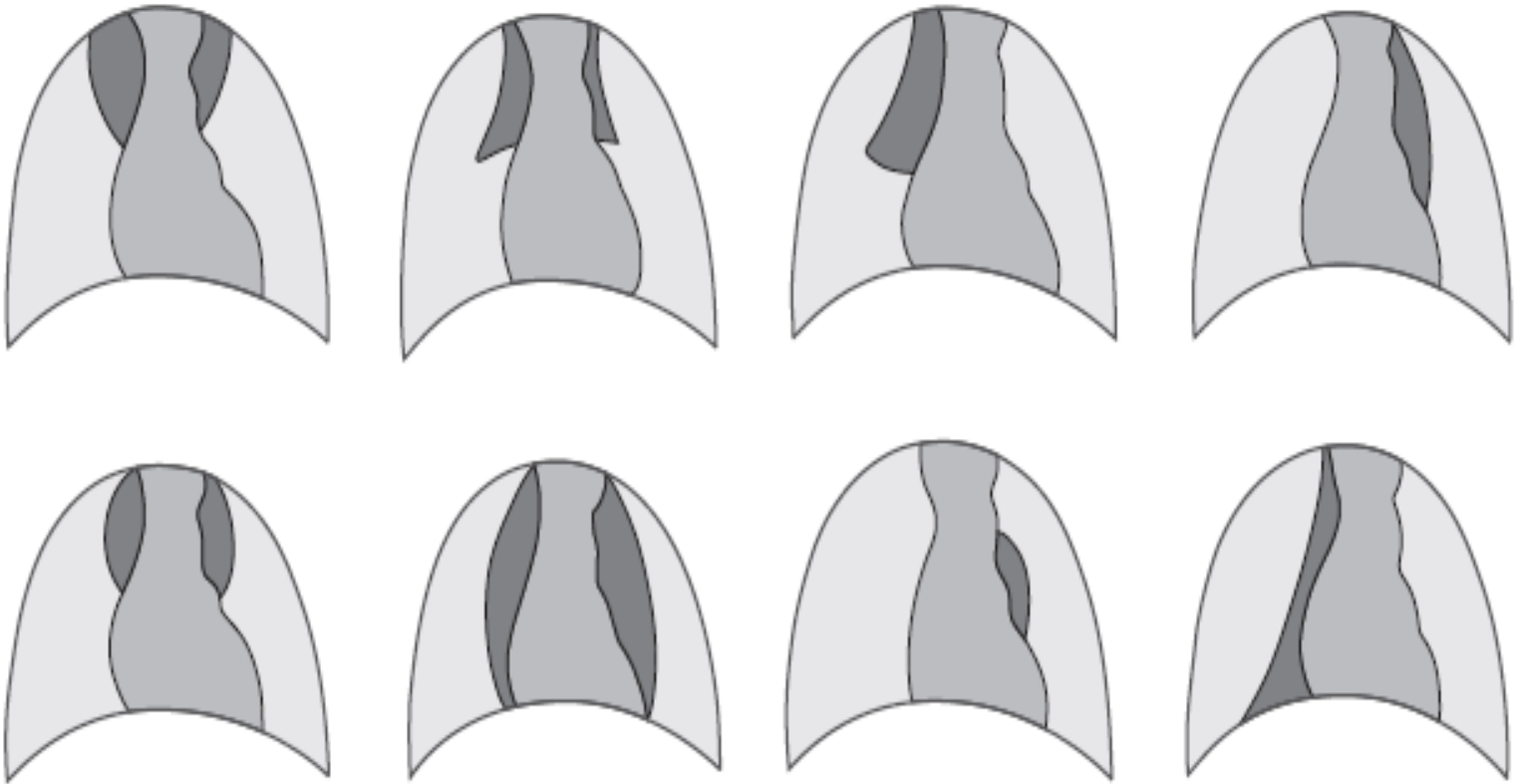


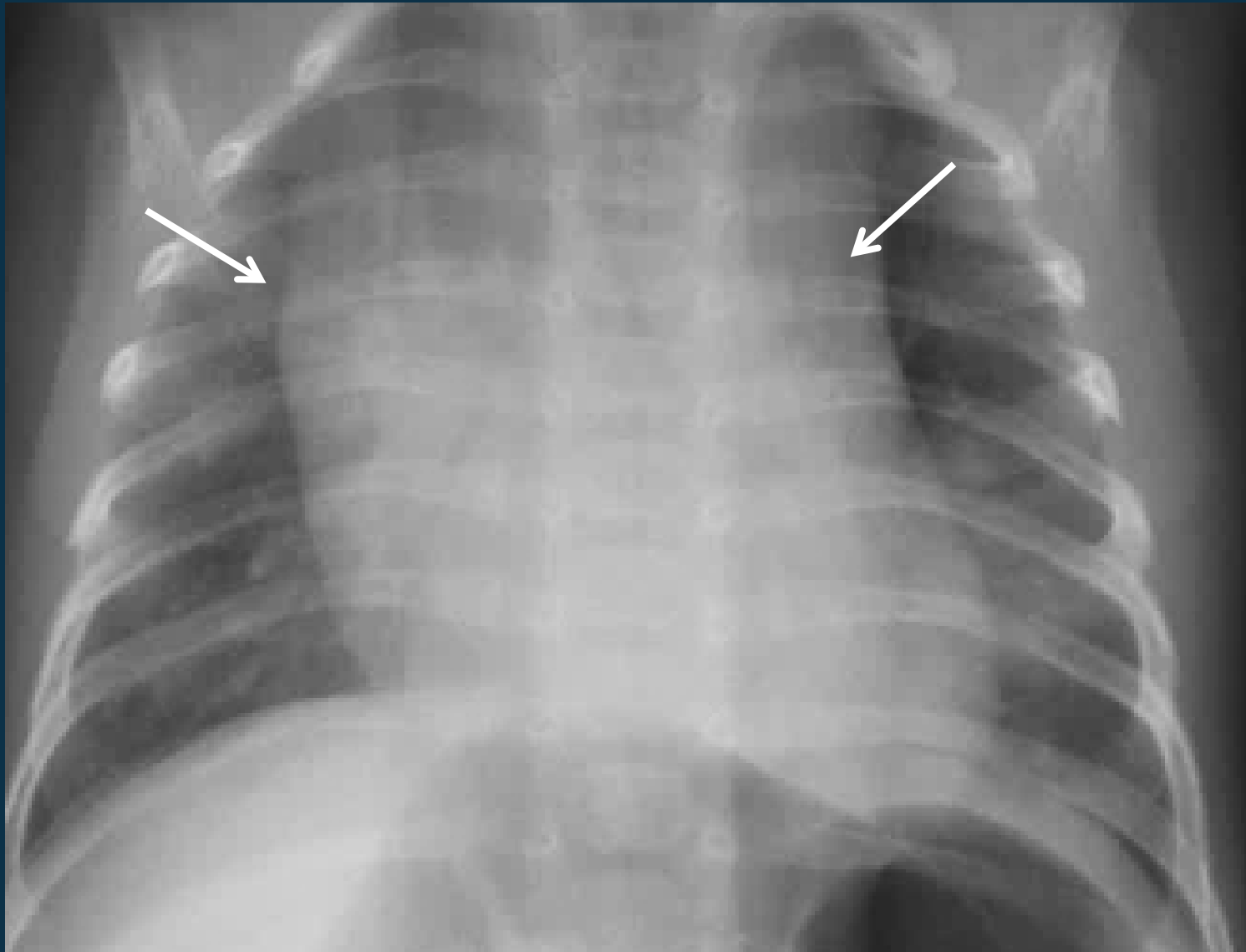
16 year old

Thymus : characteristics

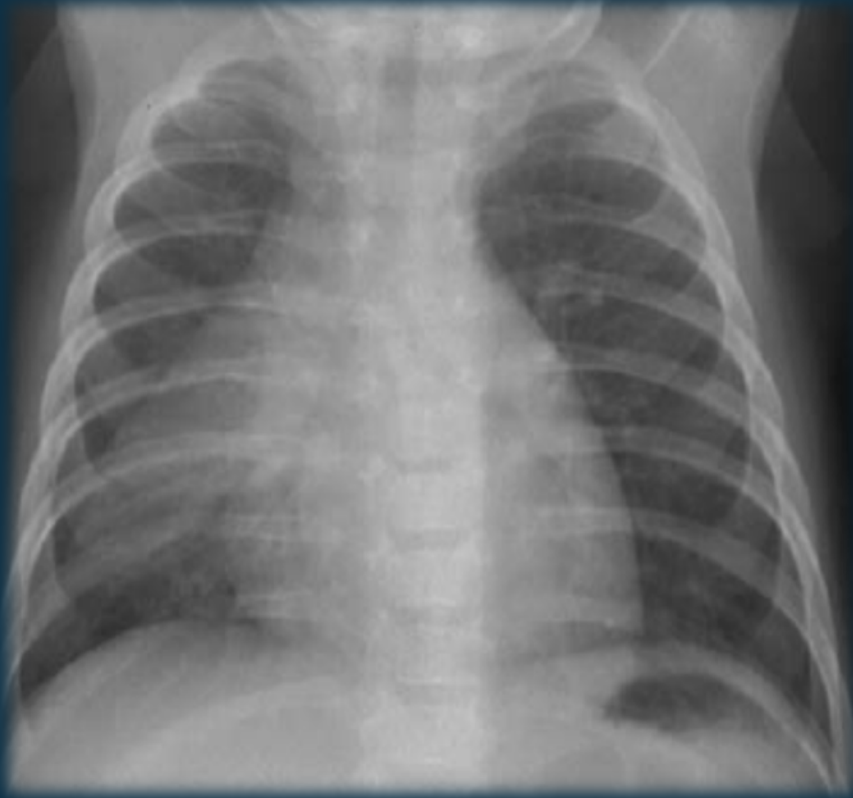1. It is soft tissue
2. Same density as the heart (soft tissue & fluid)
3. Antero-superior and contiguous to the heart
4. Causing the borders of the 2 structures to be indistinguishable on CXR
5. The cardio mediastinal silhouette is enlarged
6. It widens on expiration and narrows on inspiration
7. Never compresses or displace adjacent structures

Thymus: various shapes and sizes

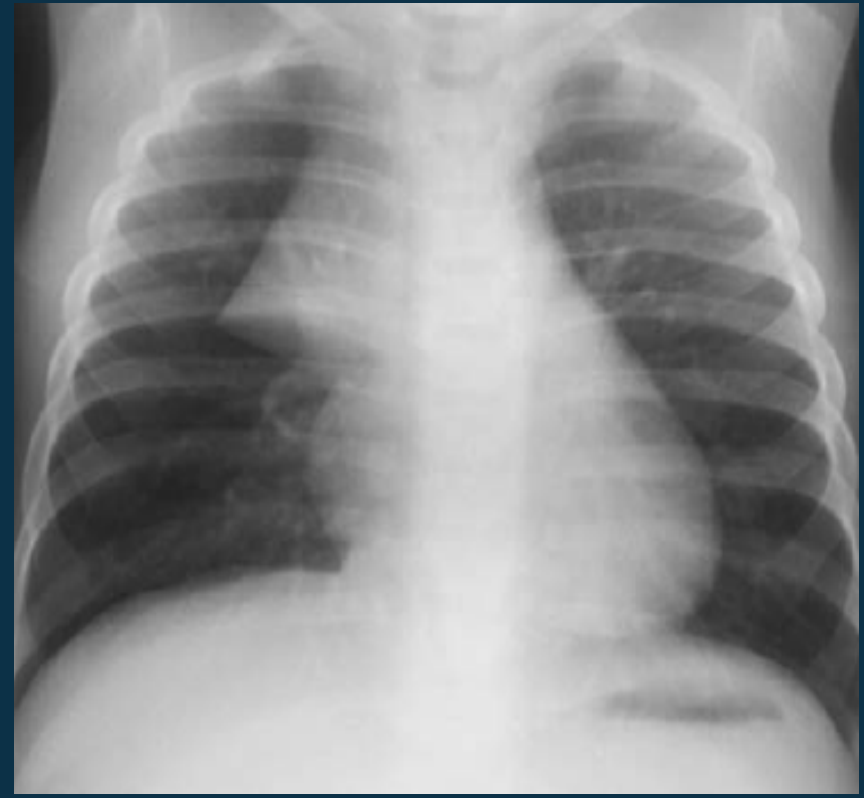



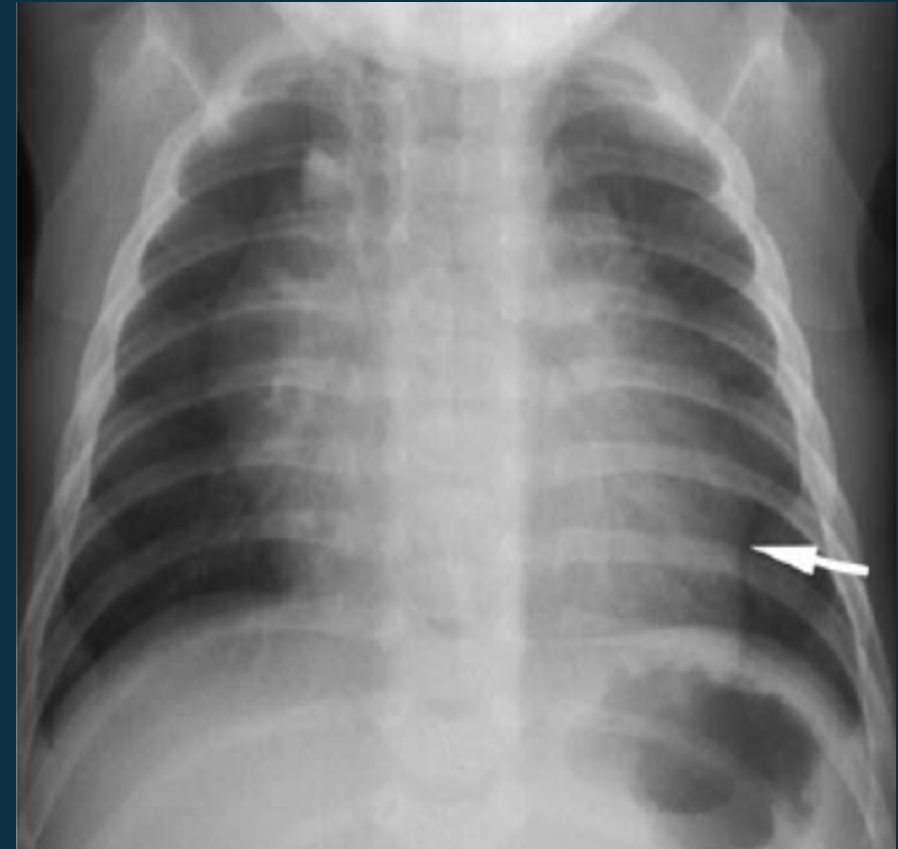
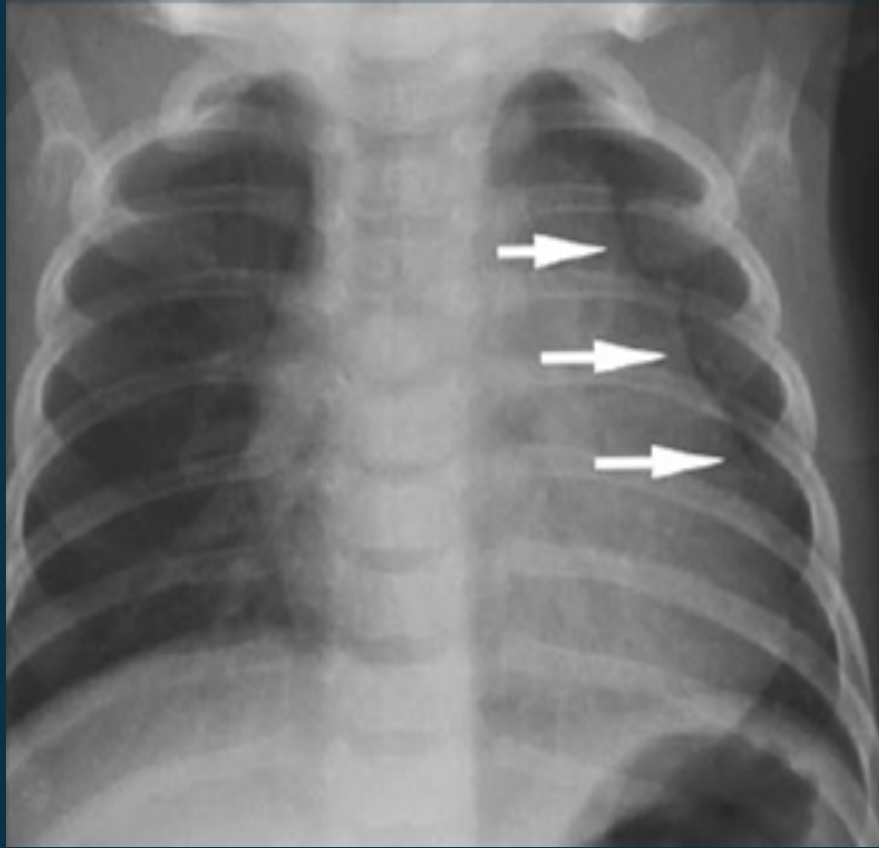
Frontal view in an infant
A prominent thymus gives an impression
of widened mediastinum



Asymmetric hypertrophy of the right lobe of the thymus



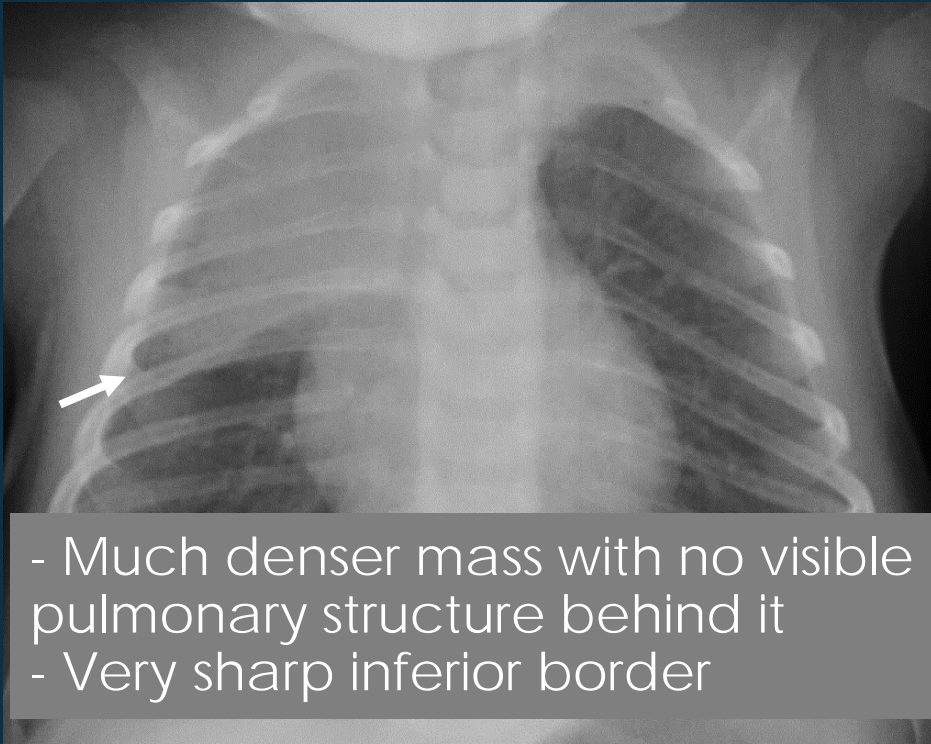
'Sail sign' triangular appearance
Hypertrophy of the right lobe
Angular corner flattened
at the right minor fissure



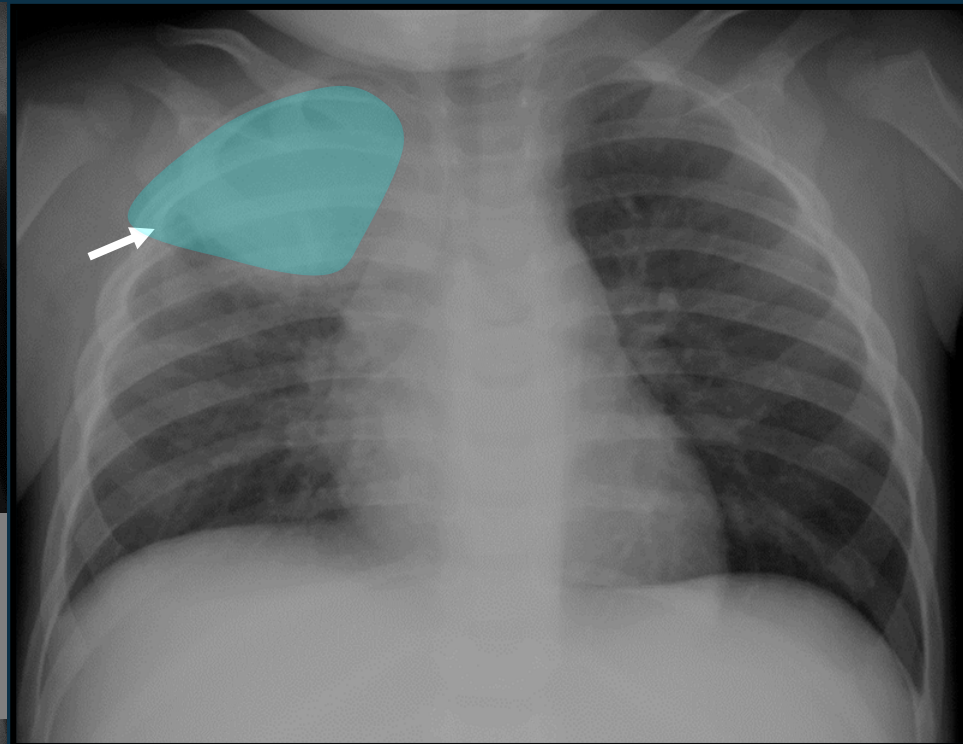
'Wave' or 'ripple' sign.
Undulating appearance of the left margins of the thymus from the overlying anterior parts of ribs and cartilages

'Notch' sign :cardiothymic incisure
Small indentation between the inferior border of the left lobe of the thymus and the heart

Thymus: differential diagnosis

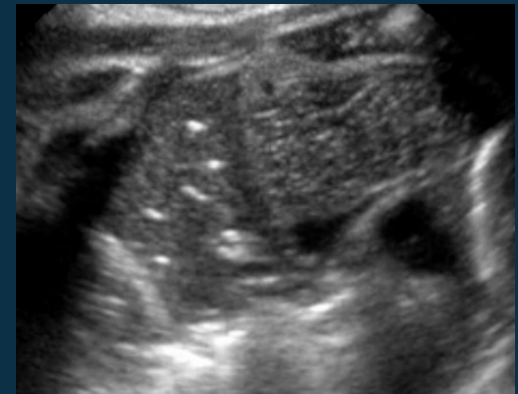

Normal thymus



Upper alveolar opacity

Sonographic signs of pneumonia :
hypoechoic region with hyperechoic spots of variable size (air bronchogram)

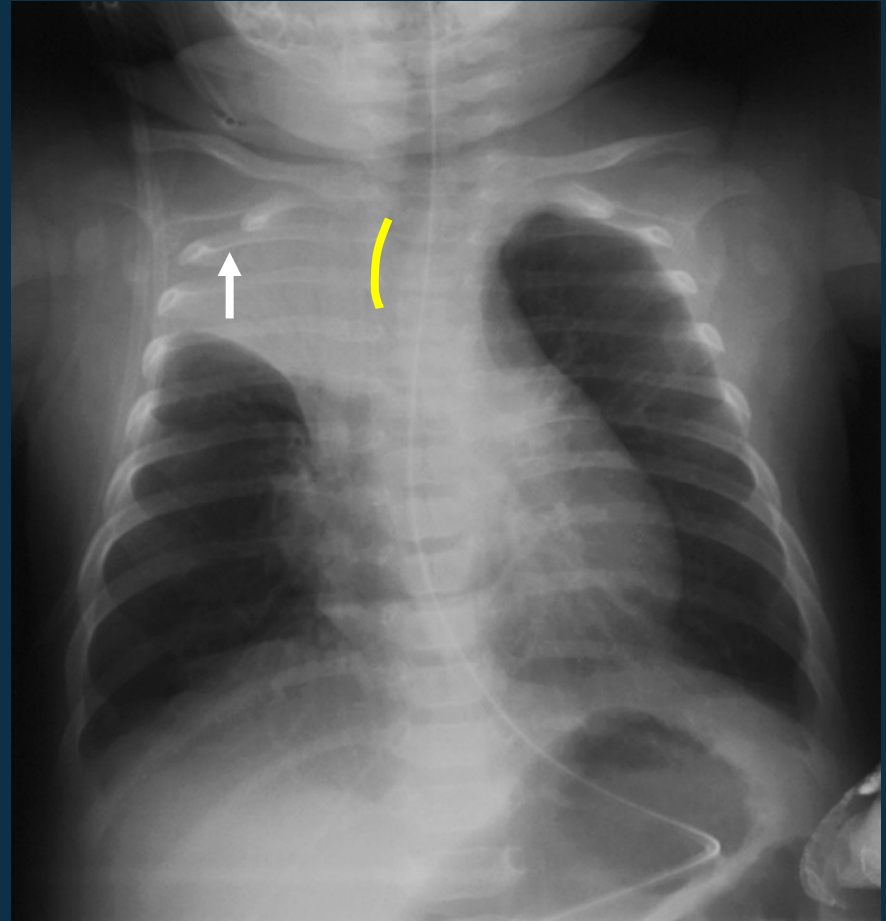


Thymus: differential diagnosis

Elevation of the minor fissure

Trachea is displaced towards this lesion

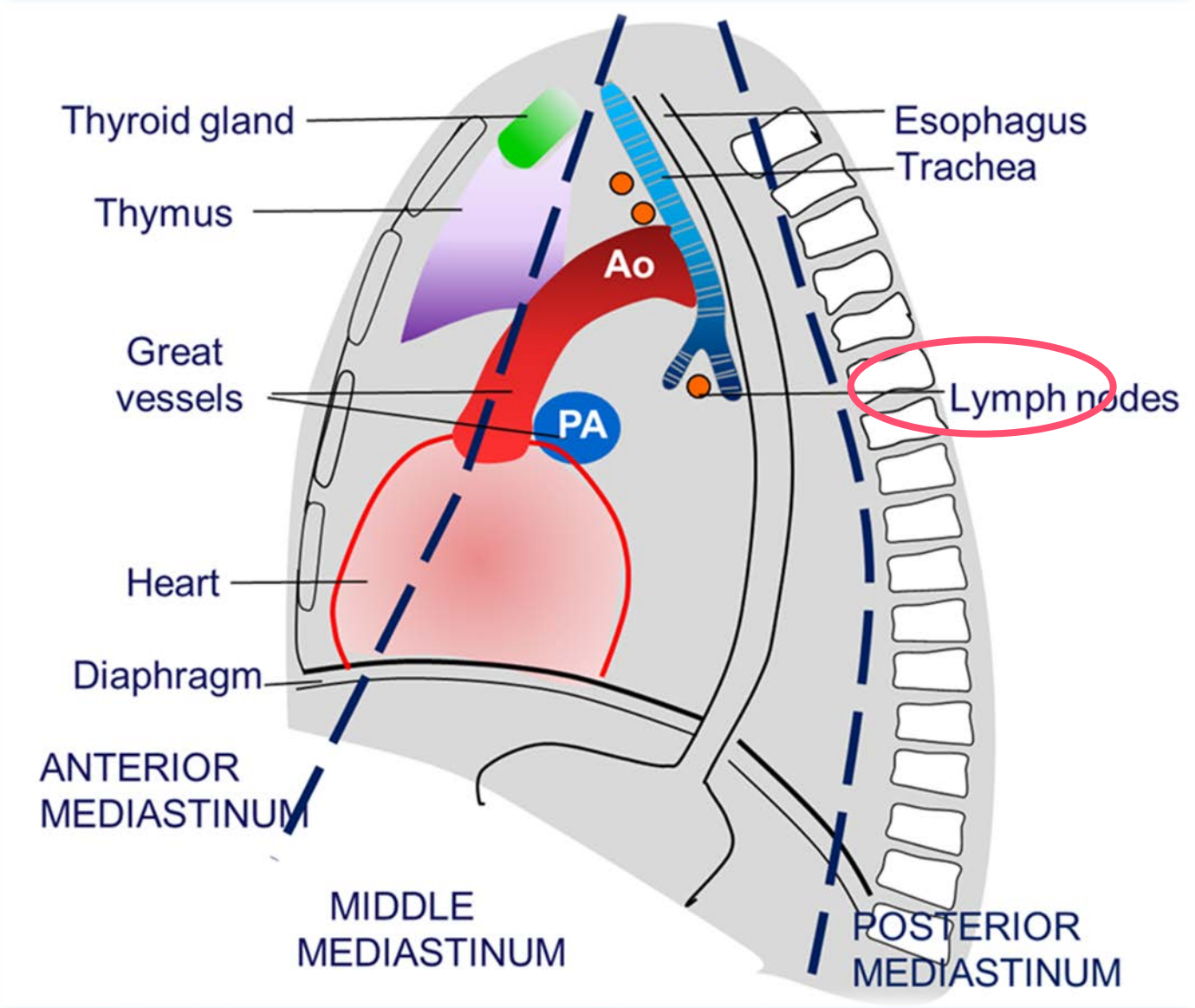
Atelectasis :
upper alveolar opacity
with loss of volume



Thymus picture in children

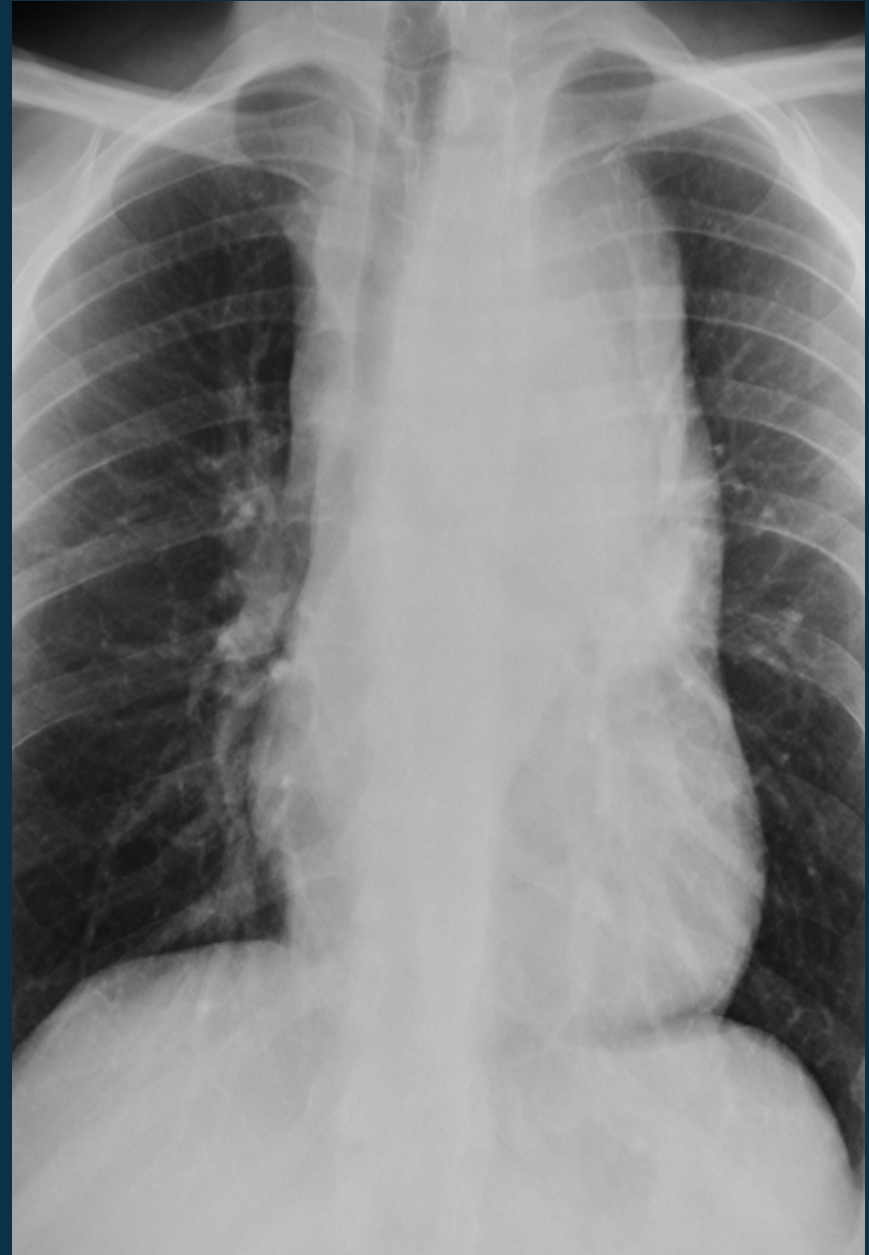
1. Particularly visible before 2 years old
2. Never compressive
3. Mobile with change of position
4. Change in size if inspiration or expiration
5. Various radiological appearances
6. Can cause confusion:
 - . can simulate cardiac enlargement, atelectasis, alveolar opacities and mediastinal masses

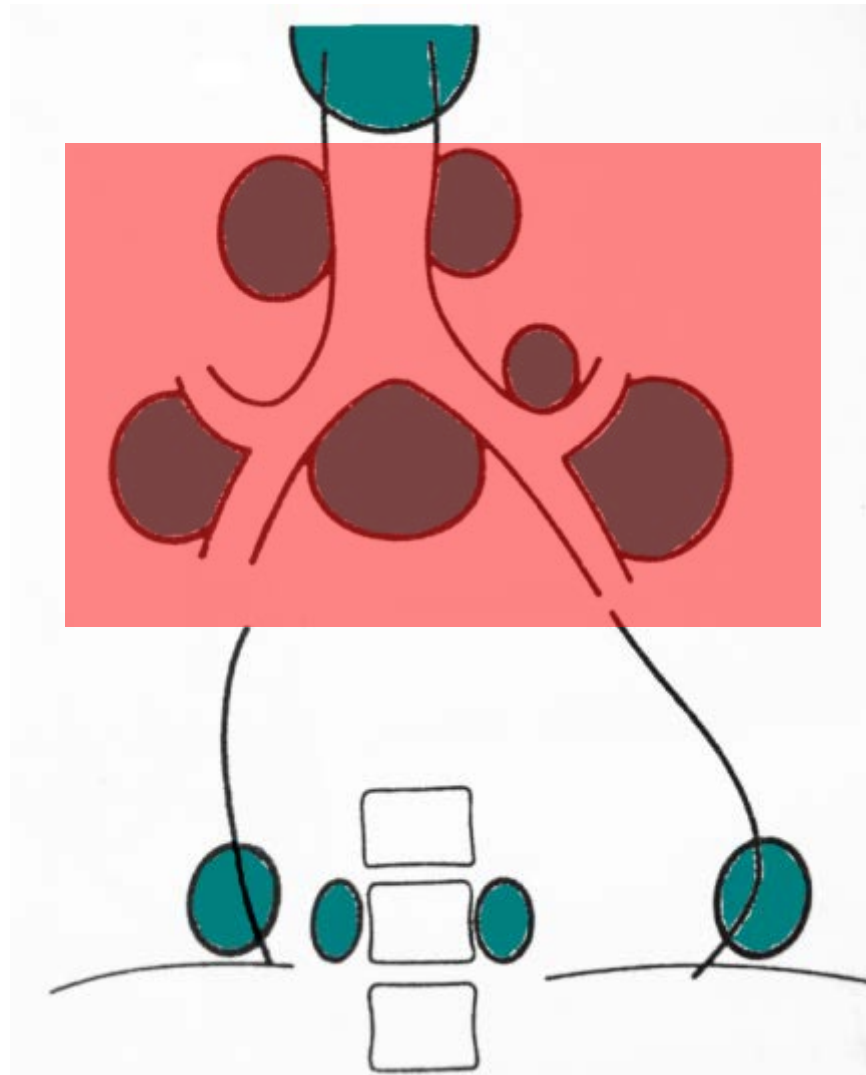
Look for lymph nodes



The most frequent mediastinal
Mass is a lymph node

The most frequent aetiology
of enlarged lymph nodes
in high TB incidence
countries is TB



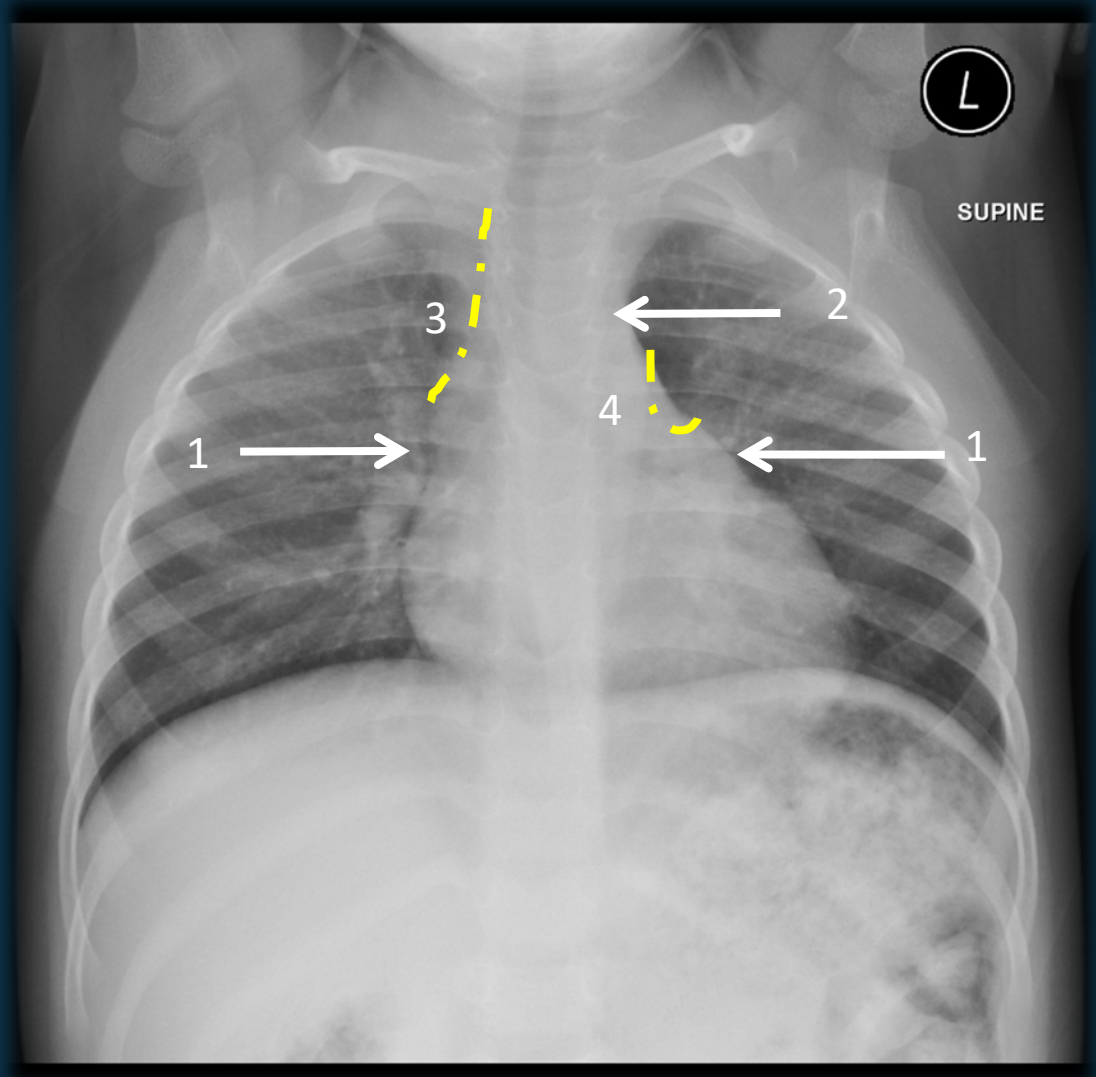


The most frequent localisation of TB lymph nodes is in this area and lateral view is very useful for diagnosis

Look for lymph nodes

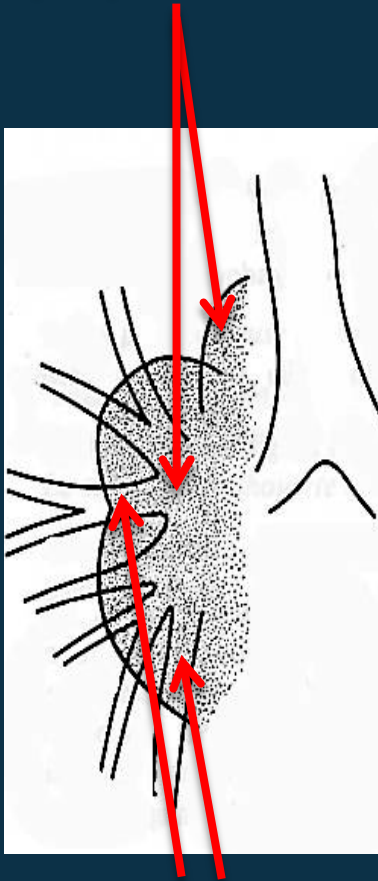
Front view check:

1. Hilar left and right
2. Paratracheal space on left
3. Paratracheal line
4. Aorto-pulmonary line

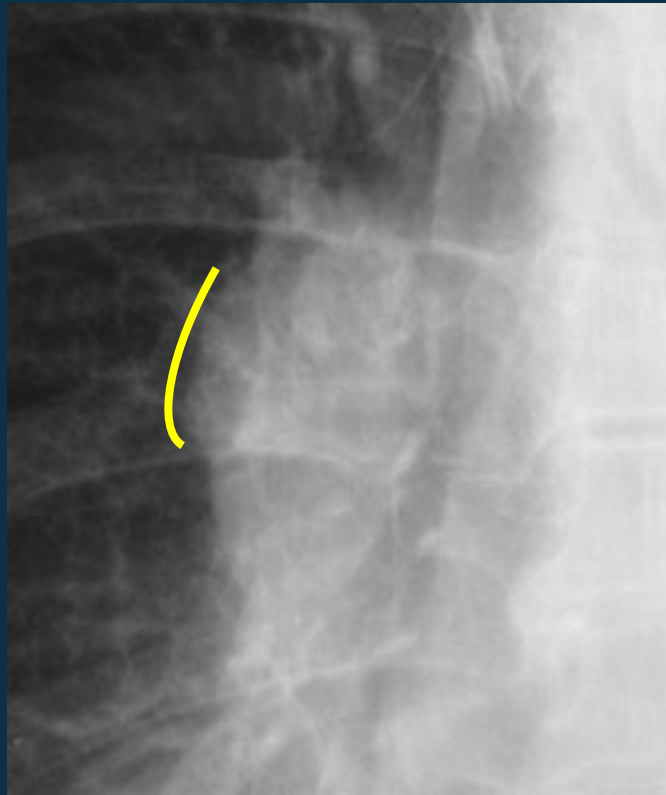


Hilar Opacities : enlarged lymph nodes

Lymph nodes

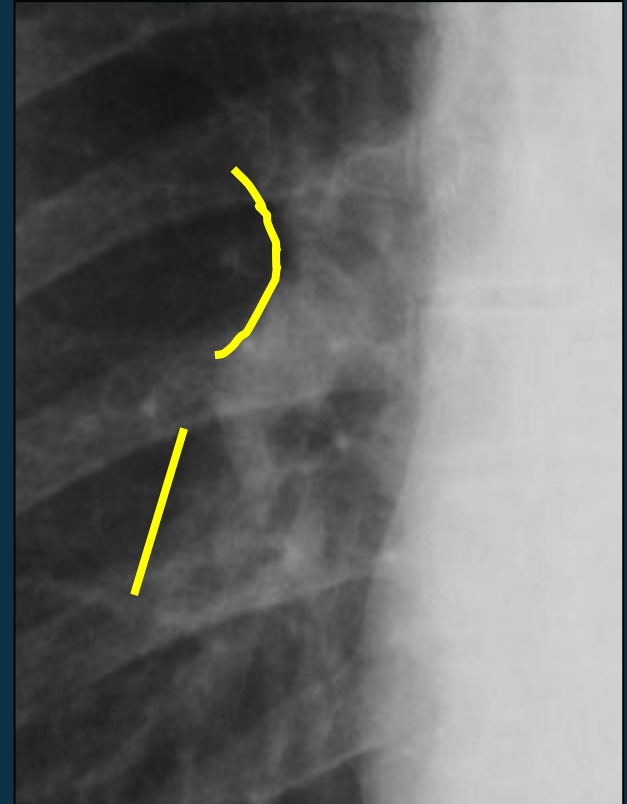


Hilar lymph nodes



Convex external edge

Normal hilar

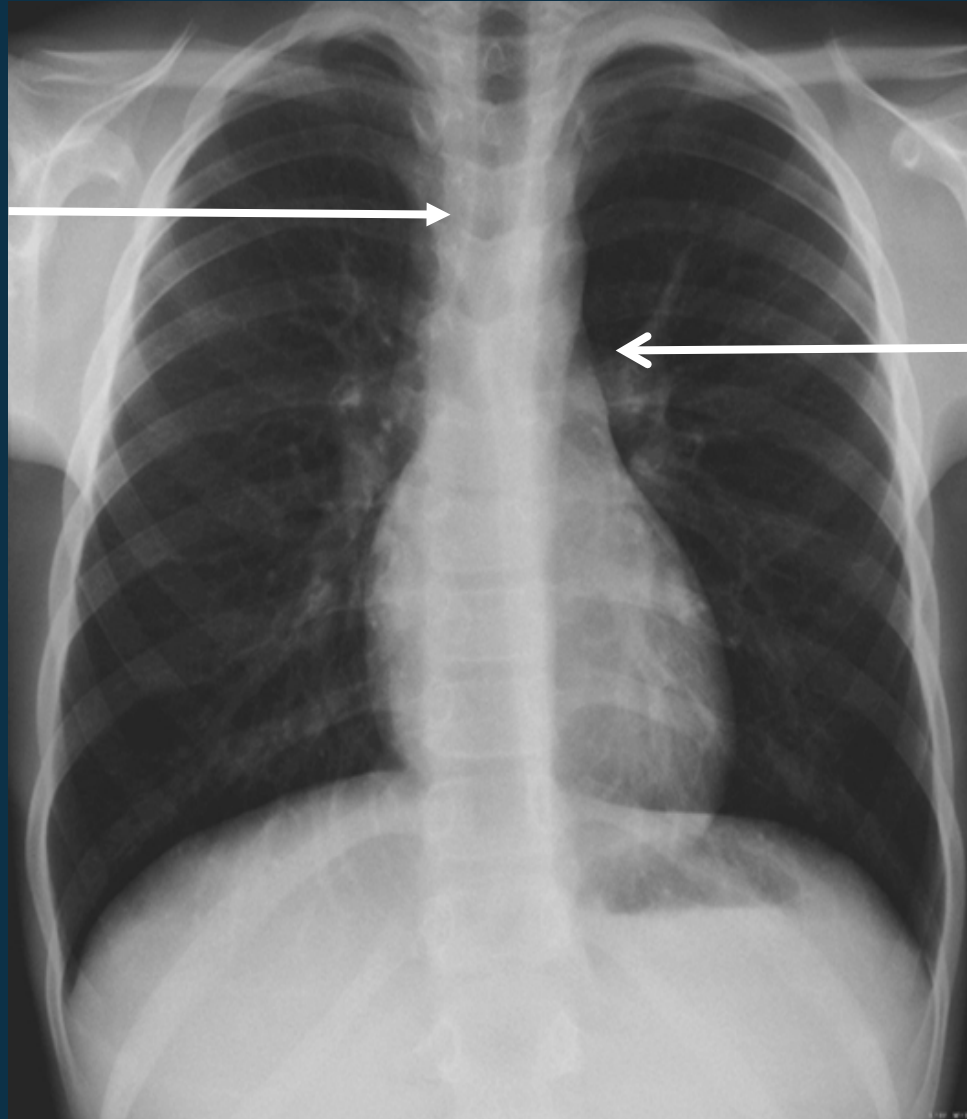

Rectilinear or concave external edge

Normal arterial vessels visible through opacity

Mediastinum Lines

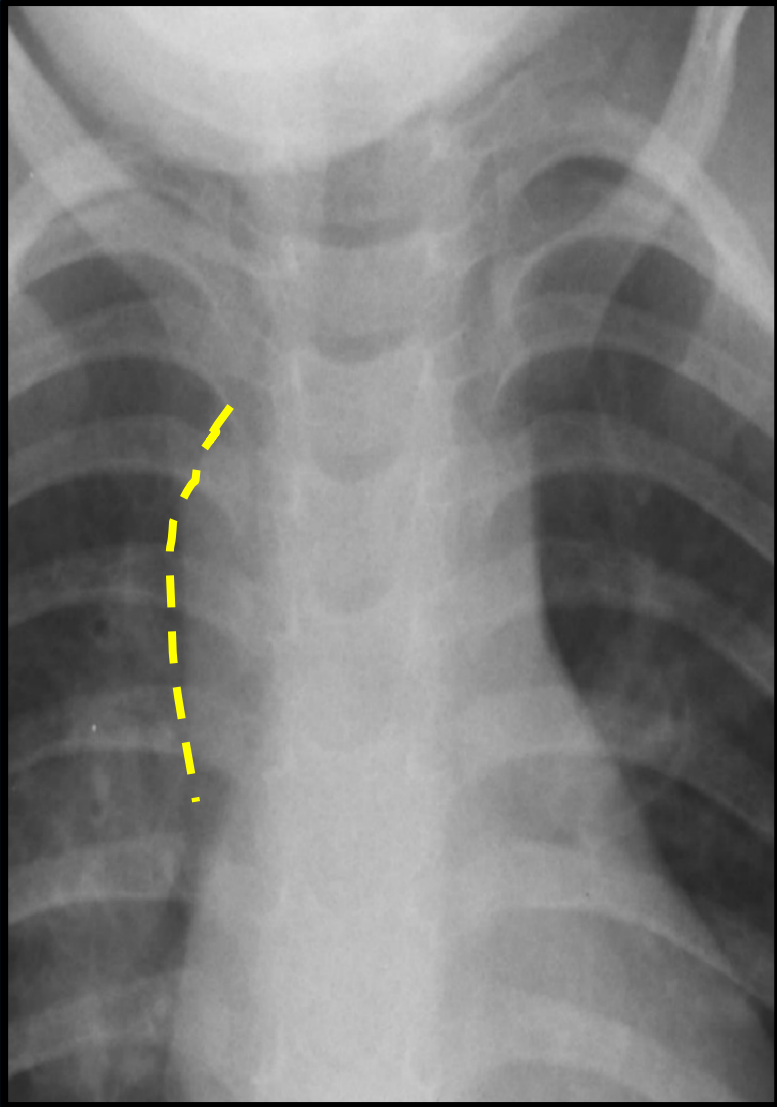
Right
Paratracheal
line



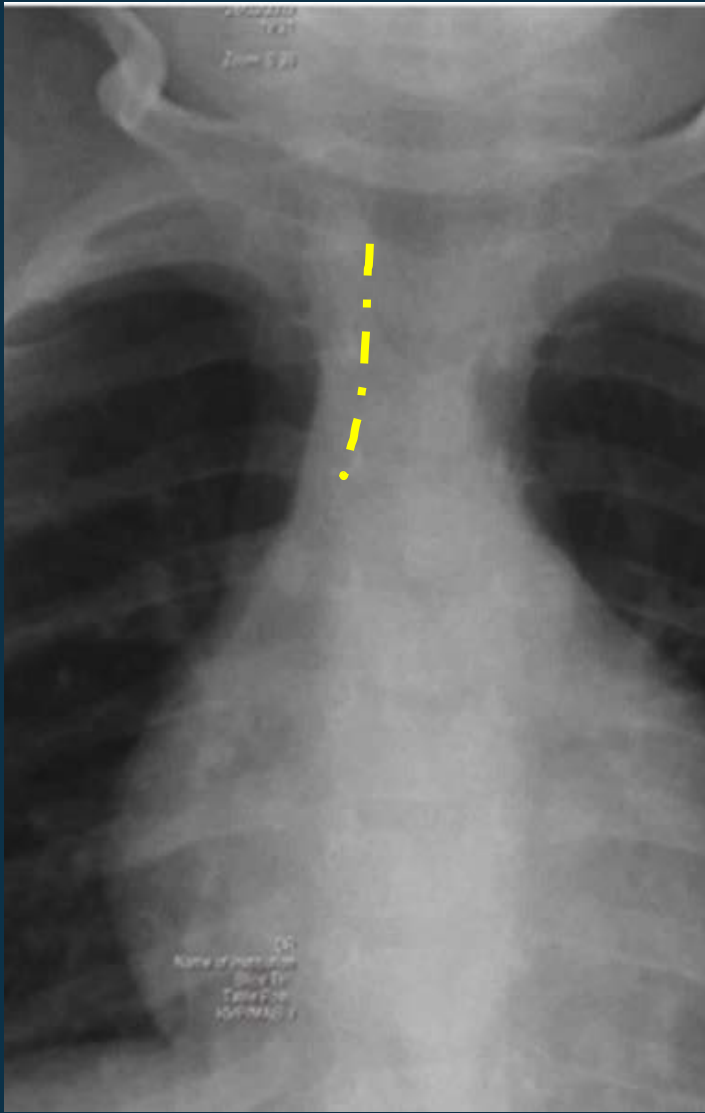
Aorto-
Pulmonary
line

Both are really important to detect lymph nodes, especially for older children

Right paratracheal line

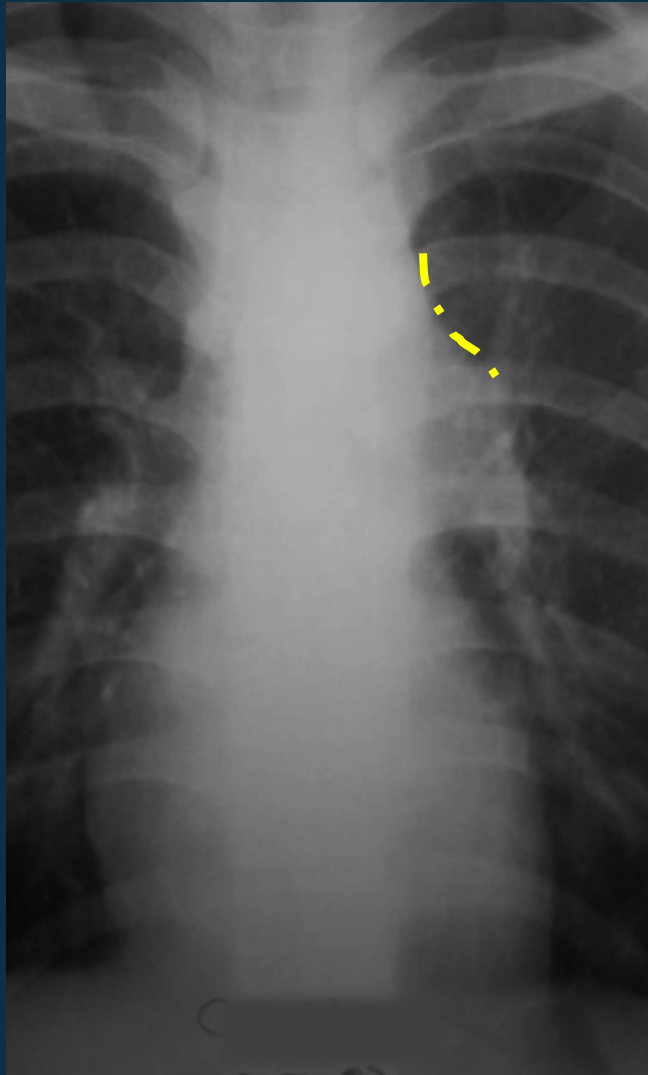


TB lymph node
in the latero-tracheal area

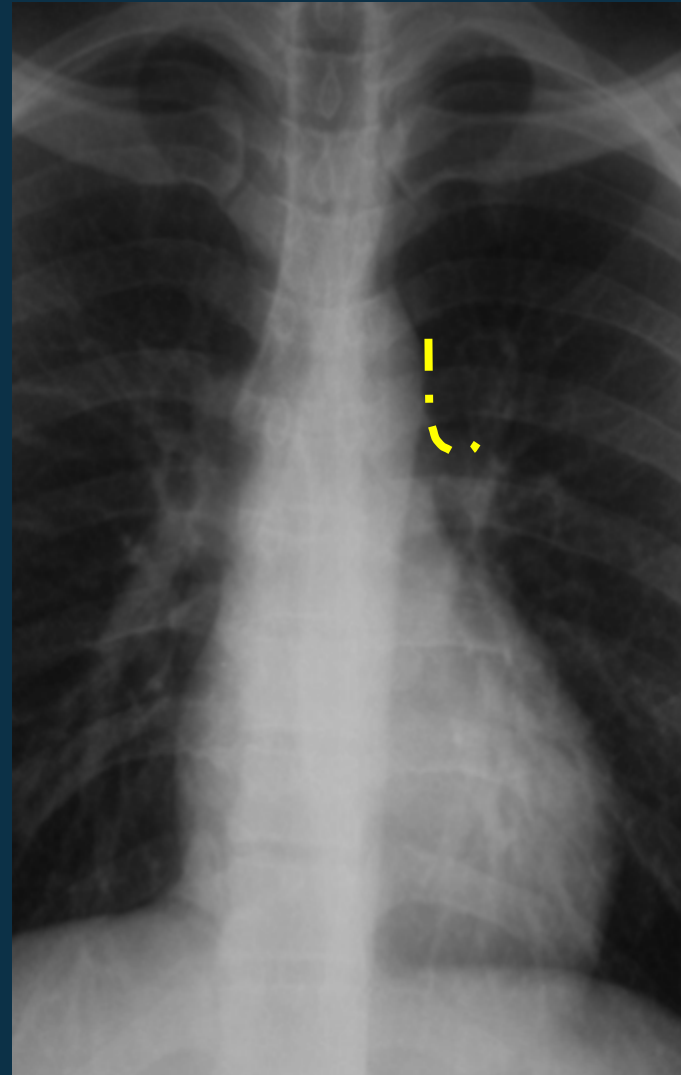


Normal CXR

Aorto-pulmonary line



Lymph node
in aorto-pulmonary window

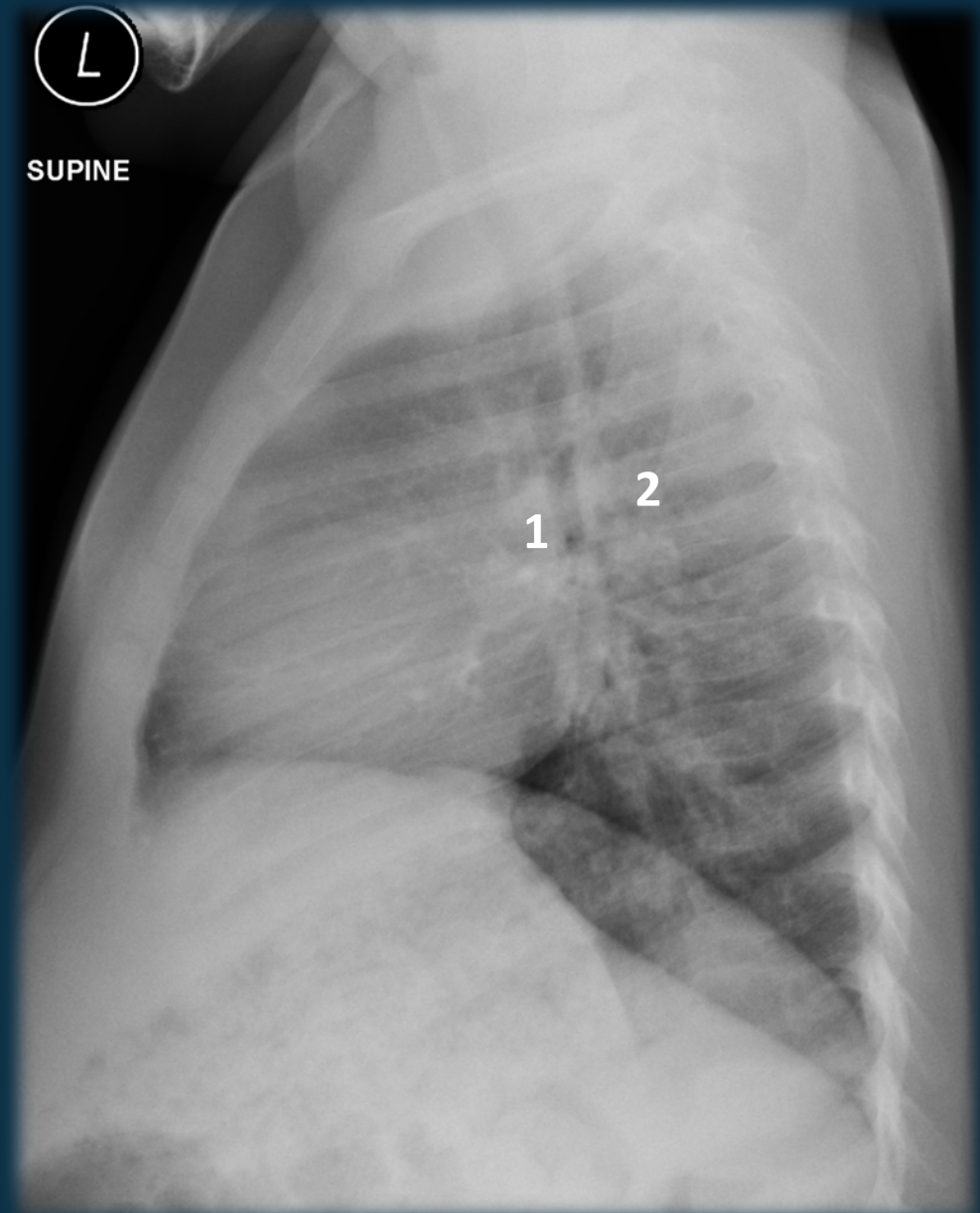


Normal CXR

Look for lymph nodes

Lateral view check :

1. Right pulmonary artery
2. Aortic arch

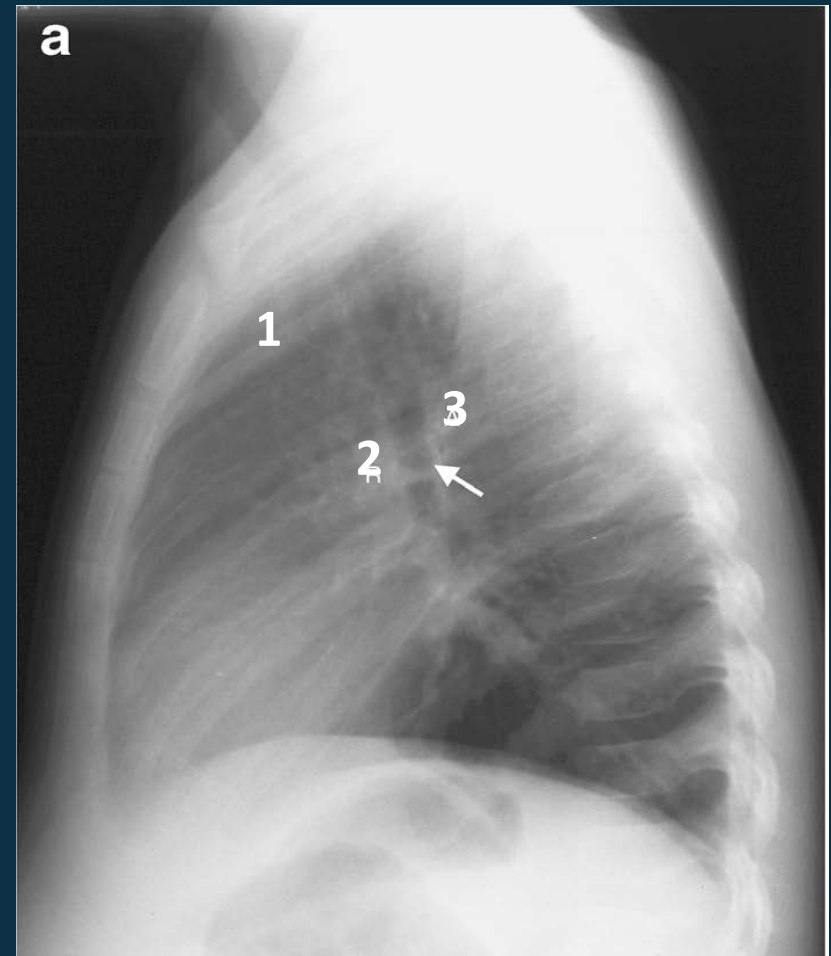


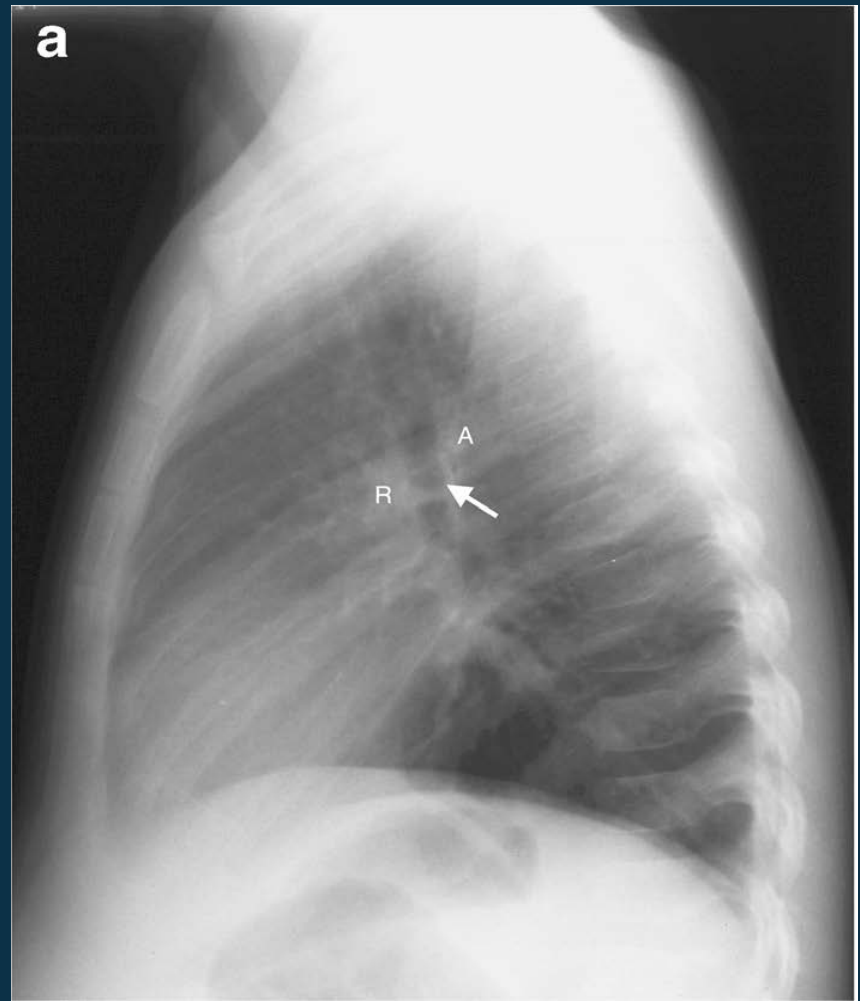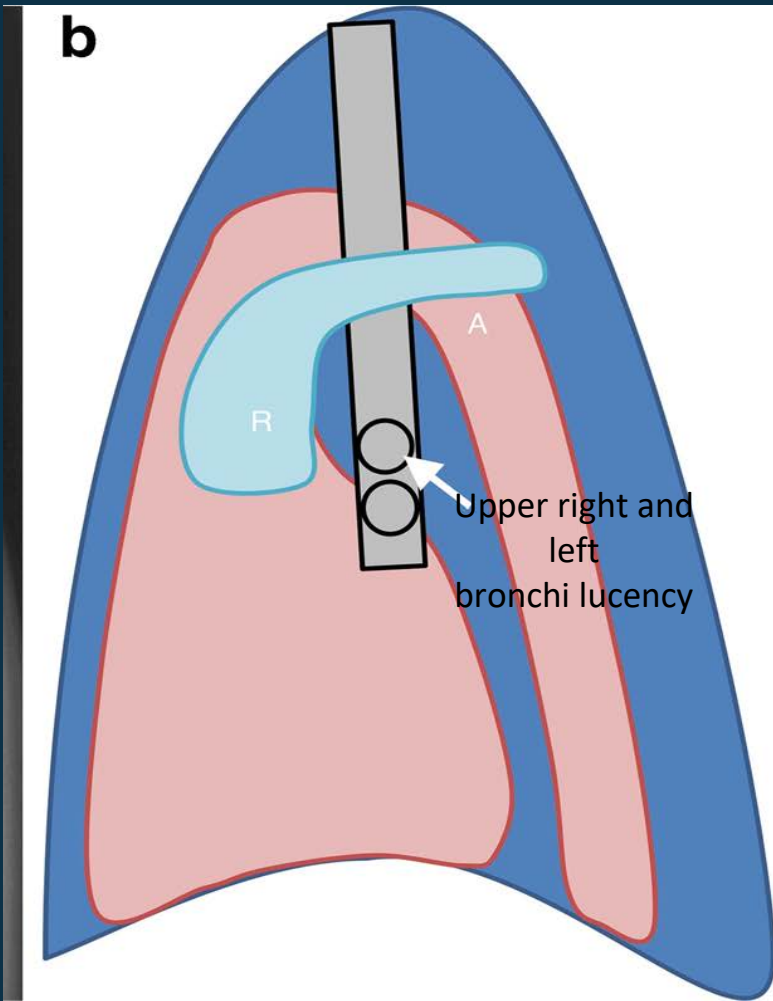
Describe what you see on this lateral view :

1. Retrosternal clear space
2. Right pulmonary artery
3. The aortic arch
4. Any sign of lymph nodes ?
. No

So this is.....

**Normal lateral chest radiograph
in a 6-year-old girl.**





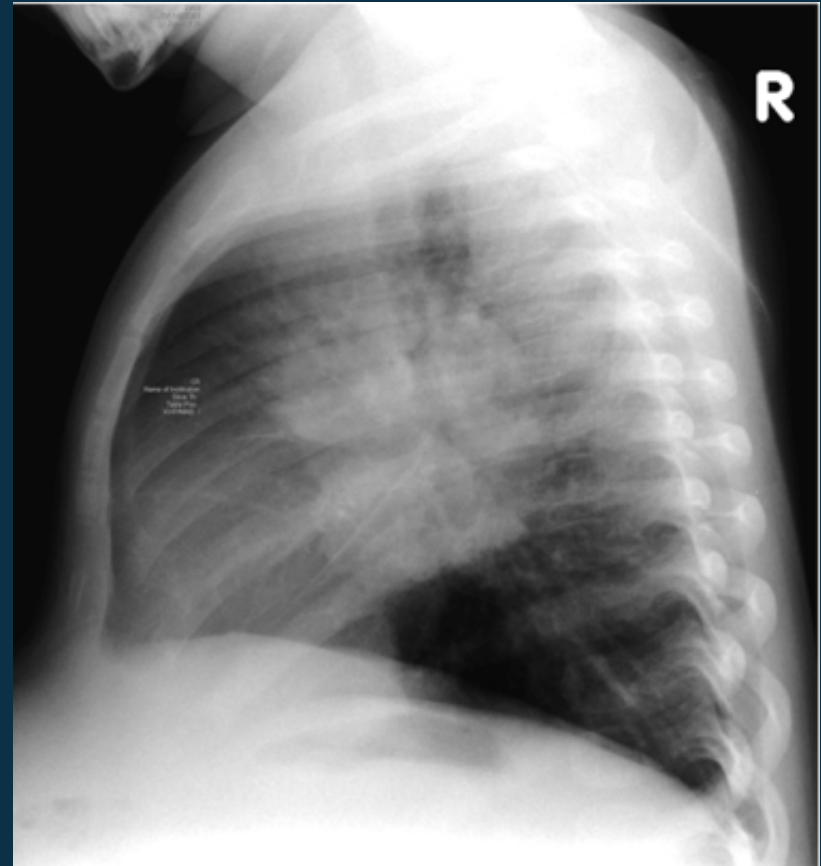
Normal lateral chest radiograph in a 6-year-old girl. The pulmonary arteries and aortic arch surround inferior part of trachea (just above the right upper lobe bronchus ↗ ...first oval lucency ↗)

Describe what you see on this lateral view :

1. Retro sternal clear space
 - . Not filled
2. Diaphragms
 - . You can see both right and left
3. The hilar area
 - . Can you see the right pulmonary artery ?
 - No

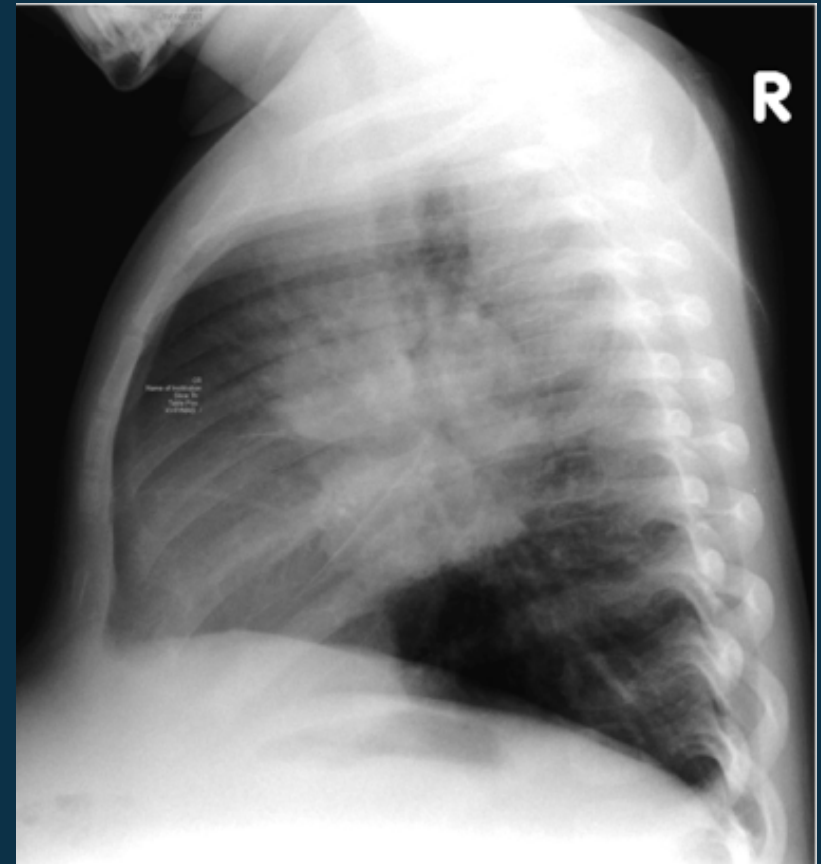
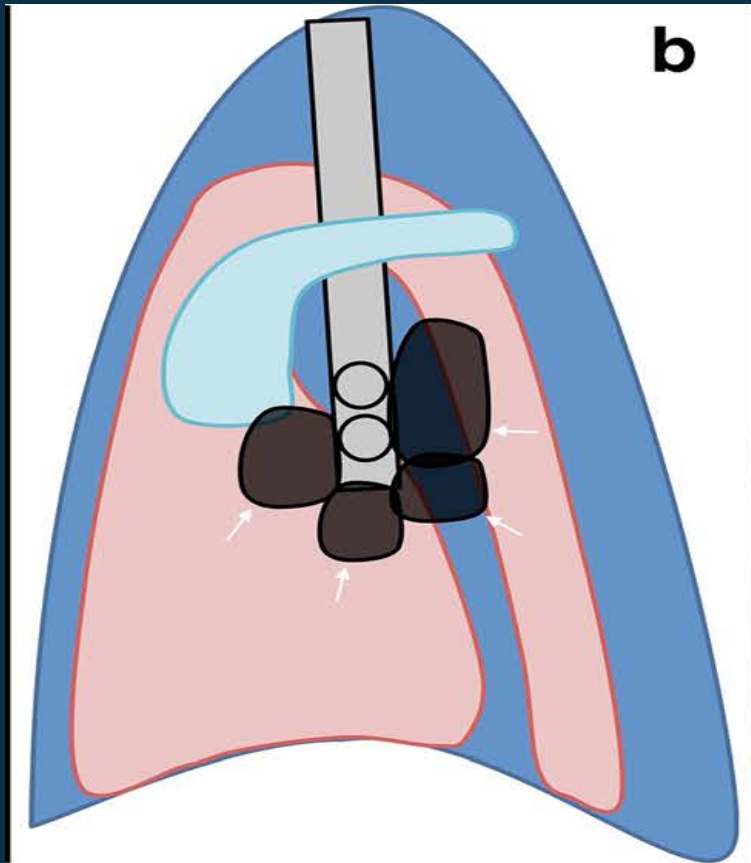
What do you see ?

- . Lobulated mass-like densities posterior and inferior to the bronchus intermedius



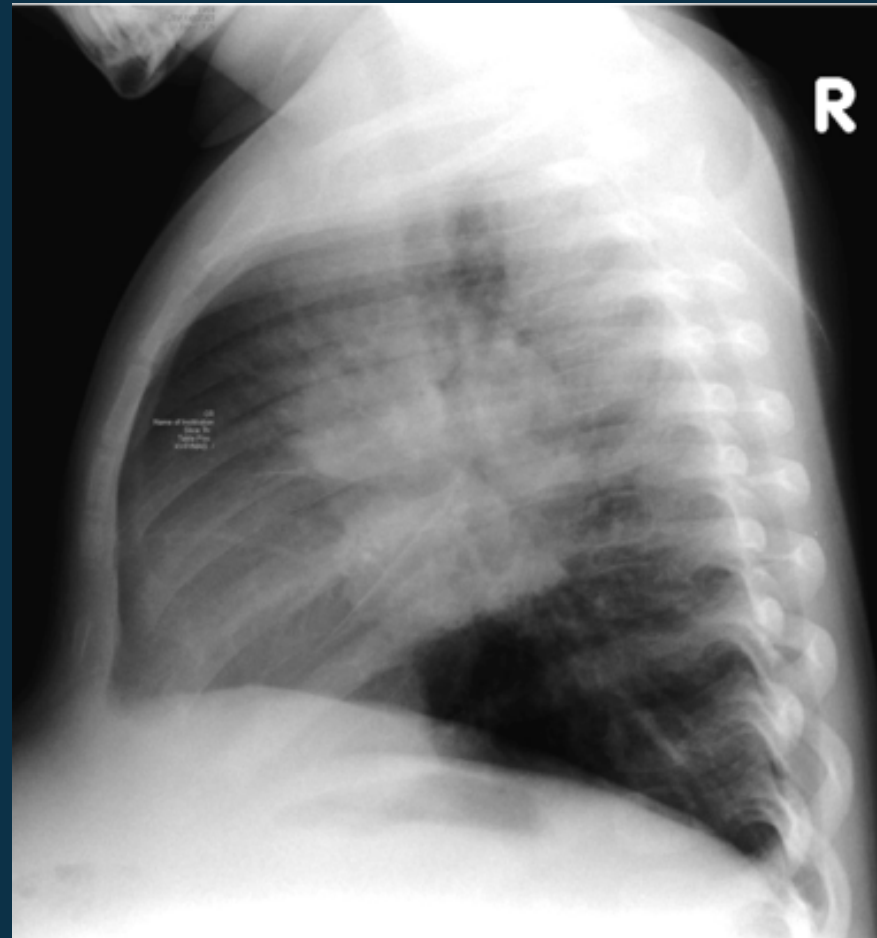
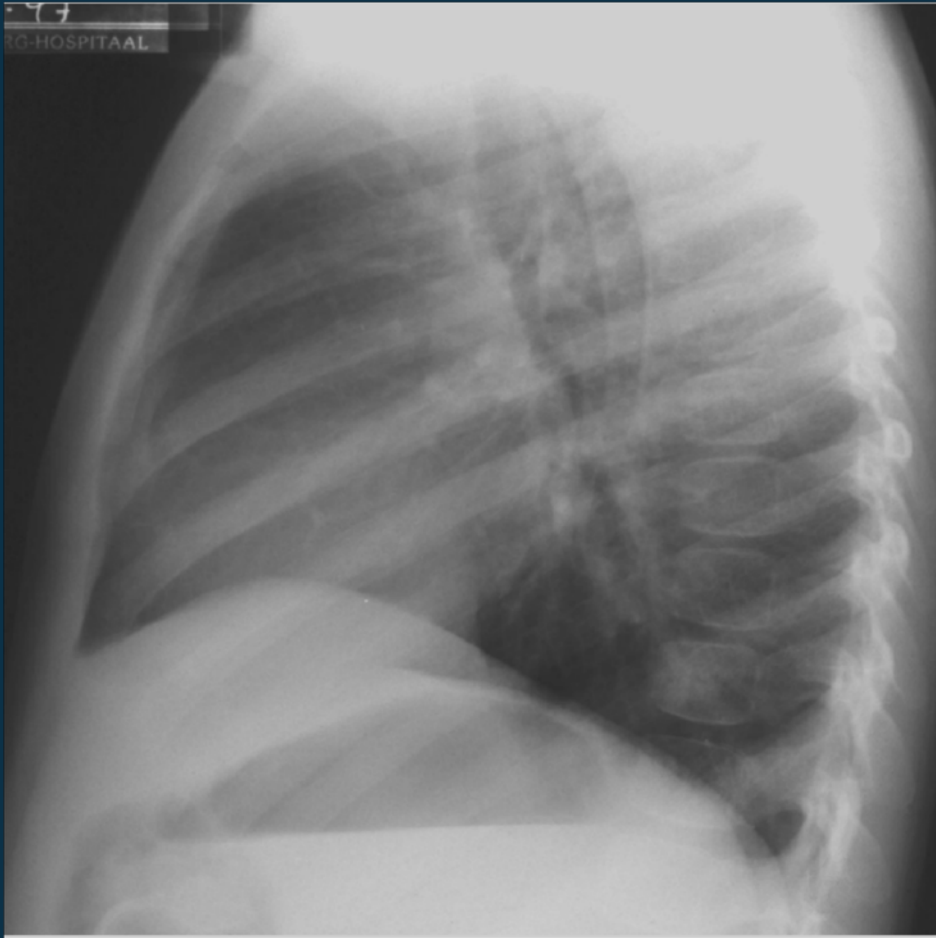
So it is

Enlarged TB sub-carinal and retro-carinal lymph nodes



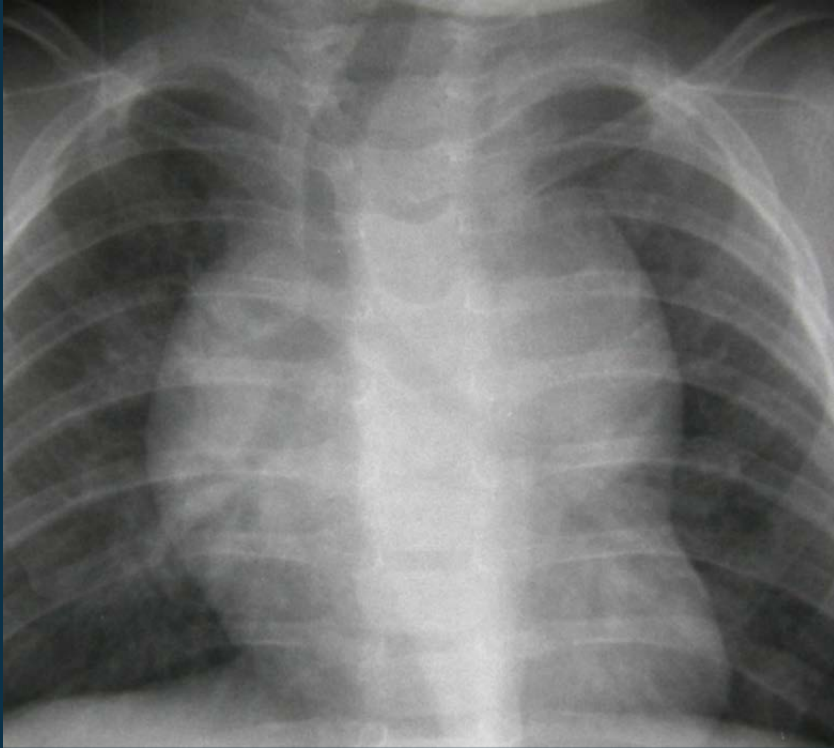
Tuberculous lymph nodes involving the pre, sub, and retro-carinal regions with the appearance of lobulated, mass-like densities posterior and inferior to the bronchus intermedius = TB lymphadenopathy.

Where are the lymph nodes ?

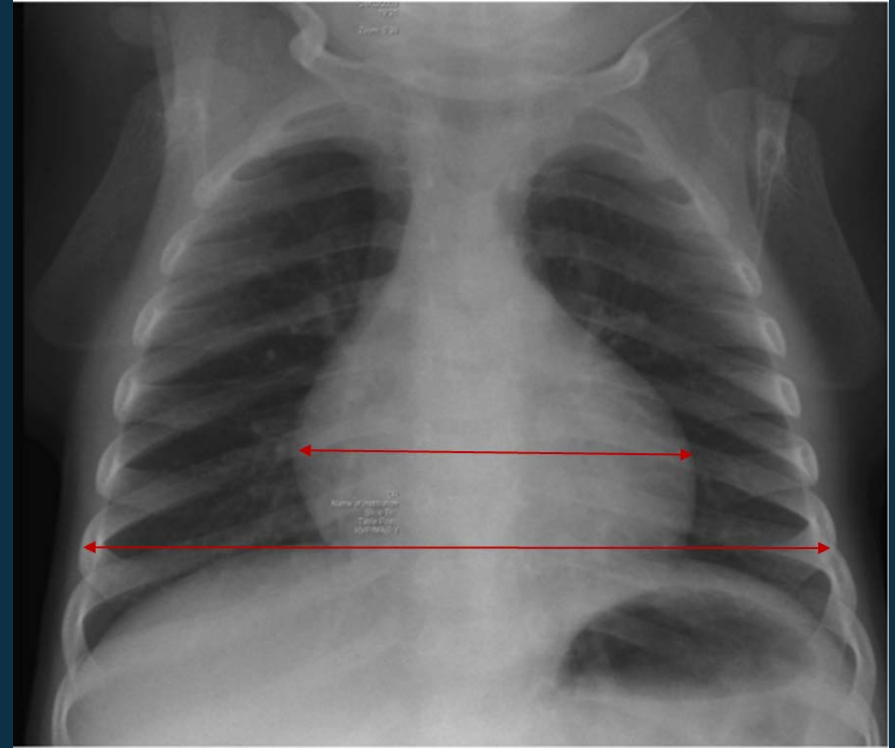


1. On the left
2. On the right

Cardiac images in infants



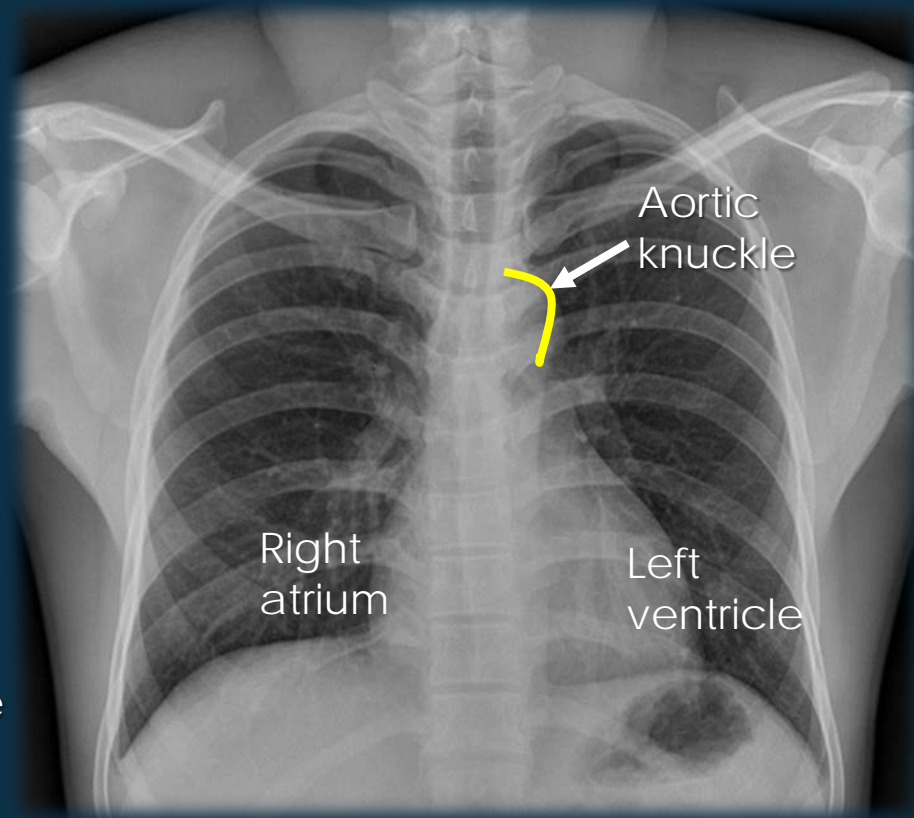
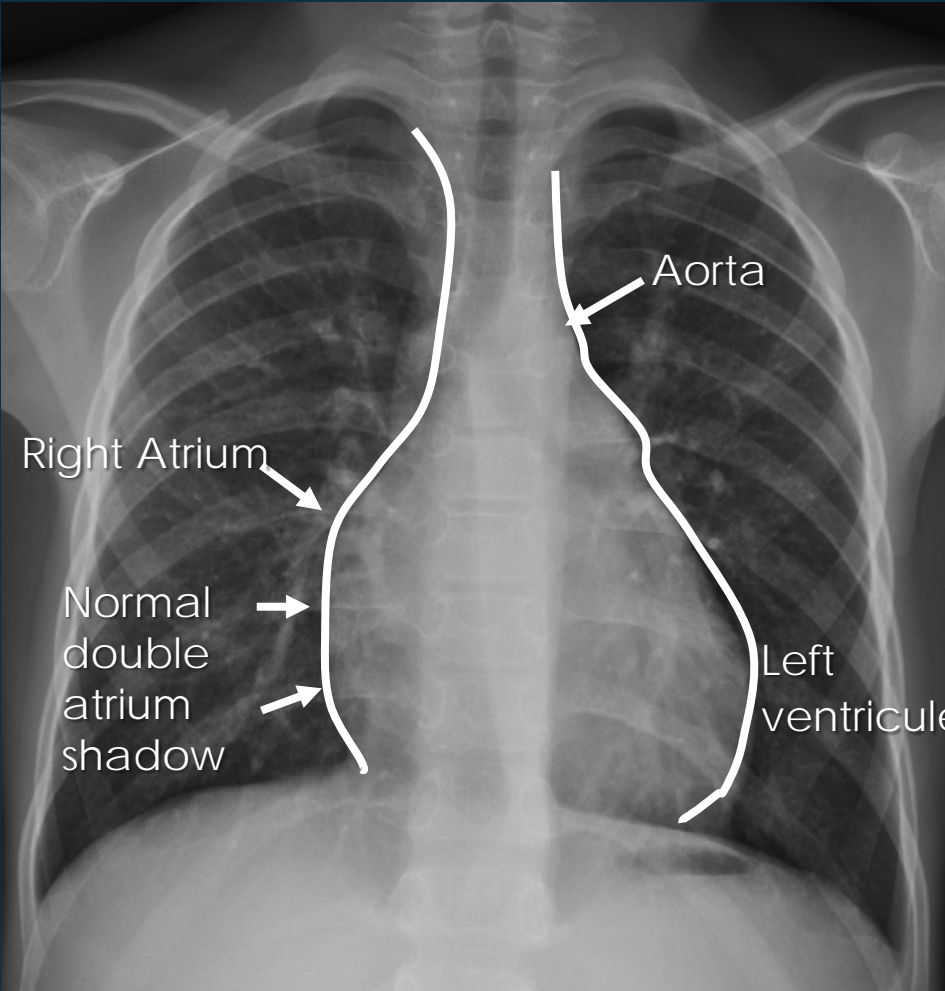
Cardio-thymic
silhouette



Cardiothoracic index
 $\leq 55\%$

Heart contours :5-year-old

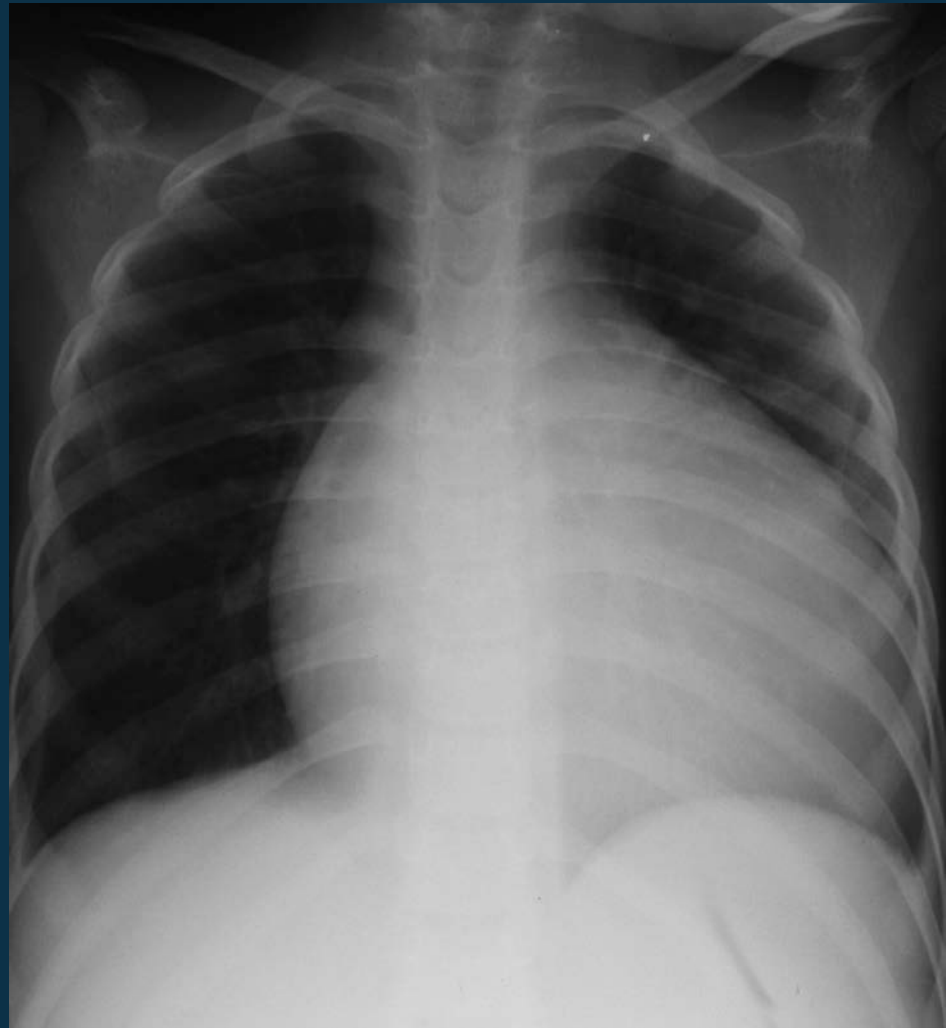Normal adult chest x-ray




Normal double atrium shadow with prominent left atrial shadow
 Normal appearance by 6 to 8 years

What do you see on this X-ray ?
• Cardiomegaly Large water bottle shaped heart

What is your diagnosis ?
Pericardial effusion



Third circle



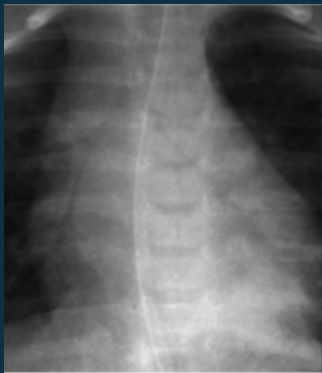
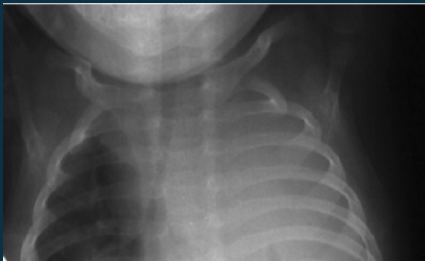Assess the airways and mediastinum

Key points third circle

Assess the airways



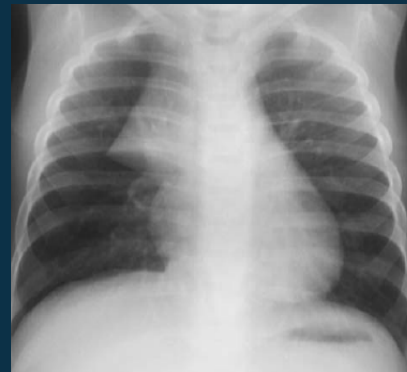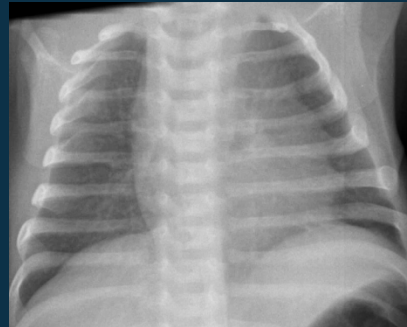
Are there signs of compression?
Narrowing?
Displacement?



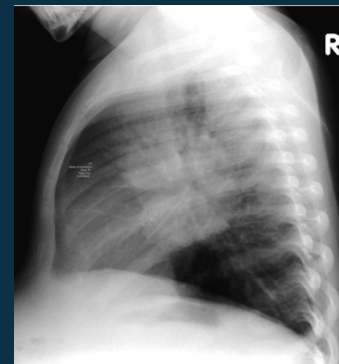
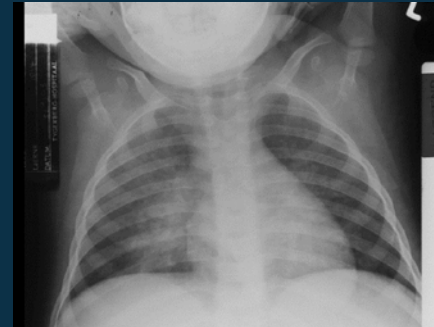
Assess the mediastinum



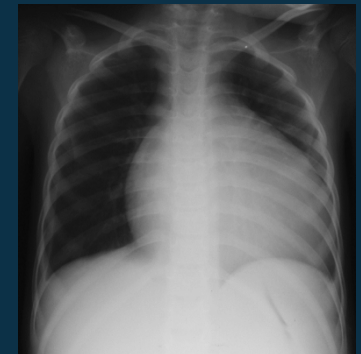
Is there a thymus?



Are there enlarged lymph nodes?



Is there cardiomegaly?



Module 1 How to read a CXR

Chap1: Technical and anatomical aspects

Chap2: Systematic approach to CXR interpretation

Part1. Quality factors

Part2. Normal CXR

Part3. First circle

1. Soft part of the chest wall
2. Diaphragmatic areas
3. Bony Thorax abnormalities

Part4. Second circle

4. Lung
5. Pleura

Part5. Third circle

6. Airways
7. hili and Mediastinum
8. Lymph nodes
9. Heart

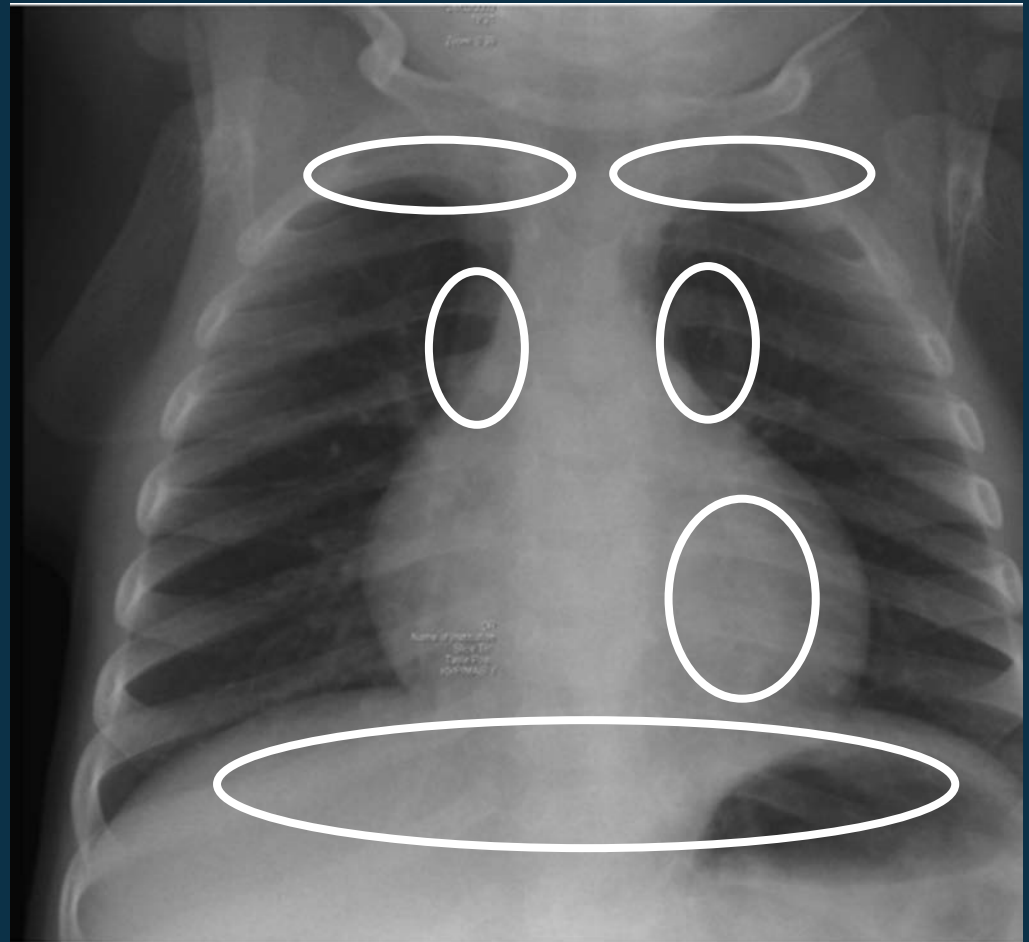
Part6. The hidden areas

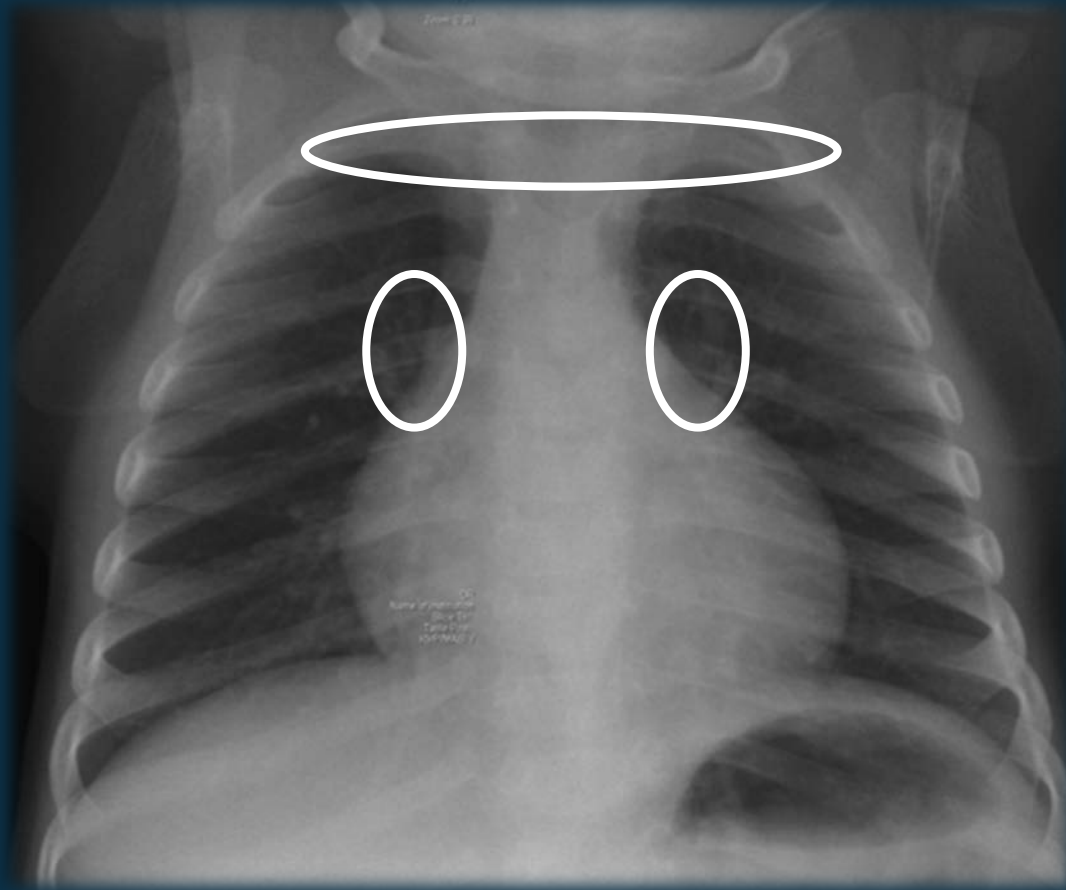
Part7. Conclusion

The hidden areas: worth a second look

There are some areas that need special attention, because pathology in these areas can easily be overlooked:

- . Apical zones
- . Hilar zones
- . Retrocardiac zone
- . Subdiaphragmatic zone

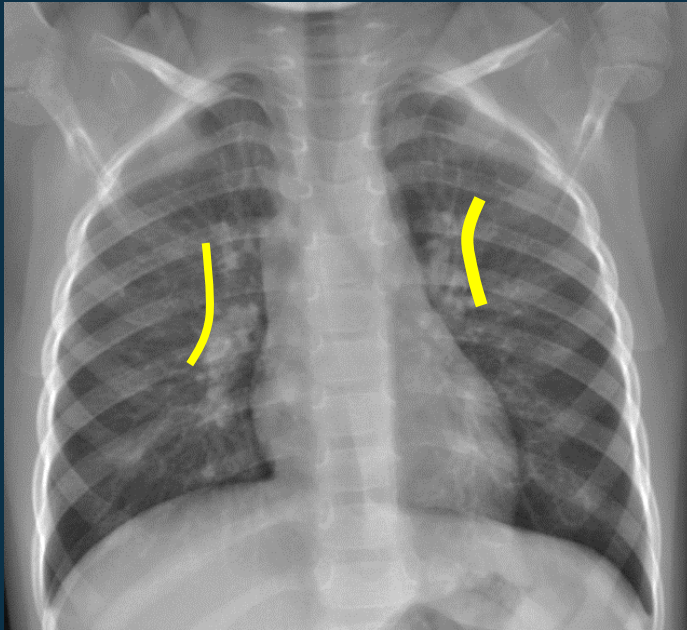




Apical zones : tuberculous changes in the older child

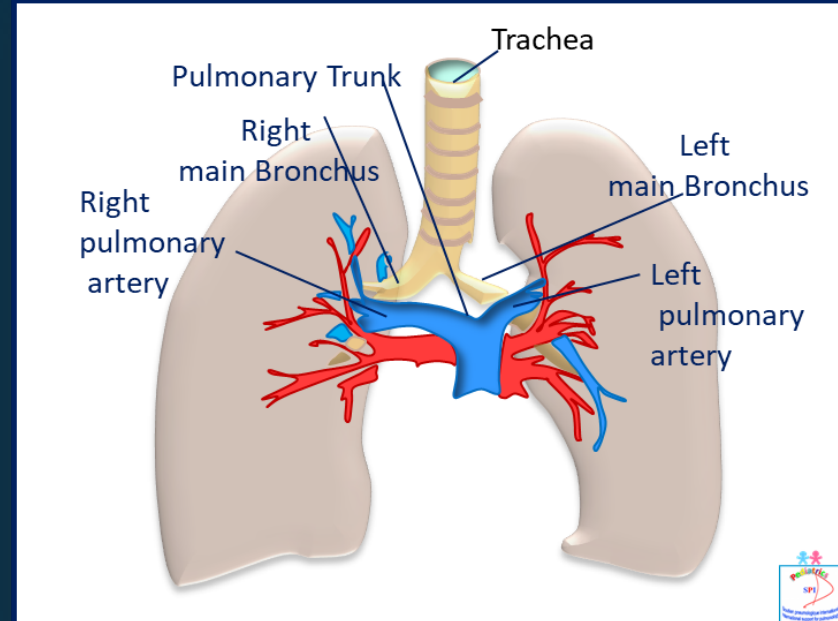
Hilar zones:
One of the most difficult area to evaluate in infants

Lateral views are helpful.



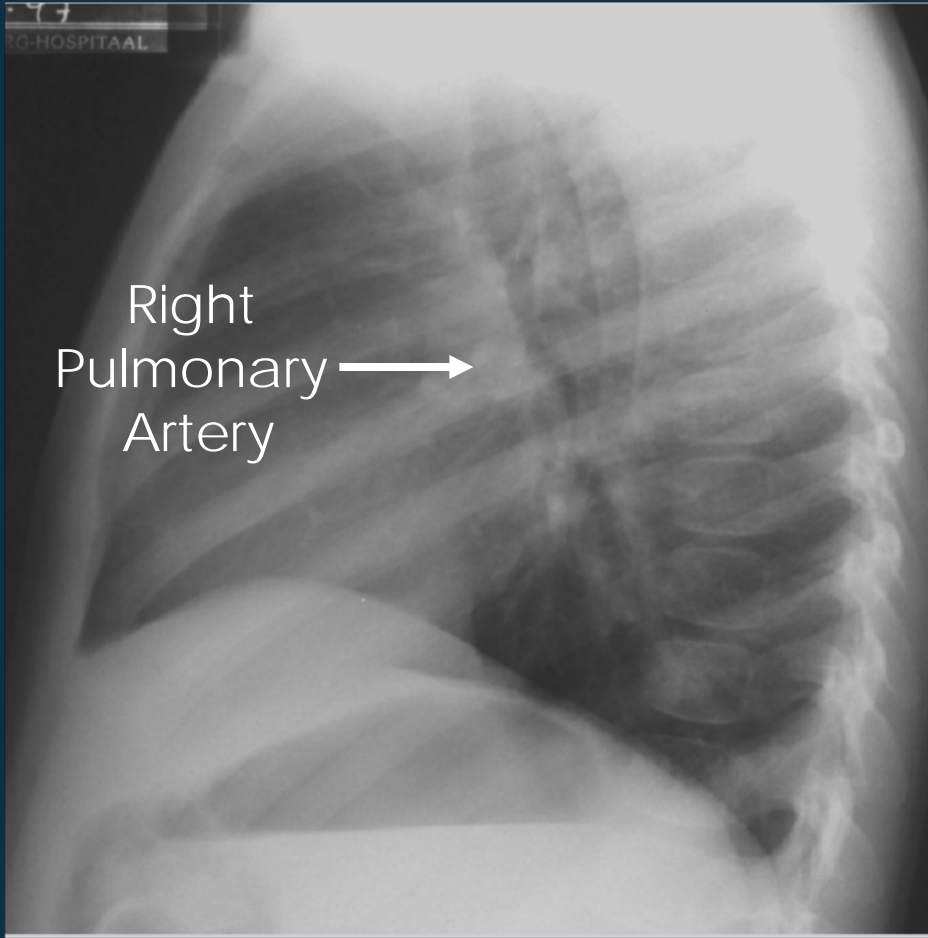
Normally hilum:

- . Must be visible
- . Should have a clear external edge with concave aspect
- . Should have no soft tissue density masses overlapping hilar area

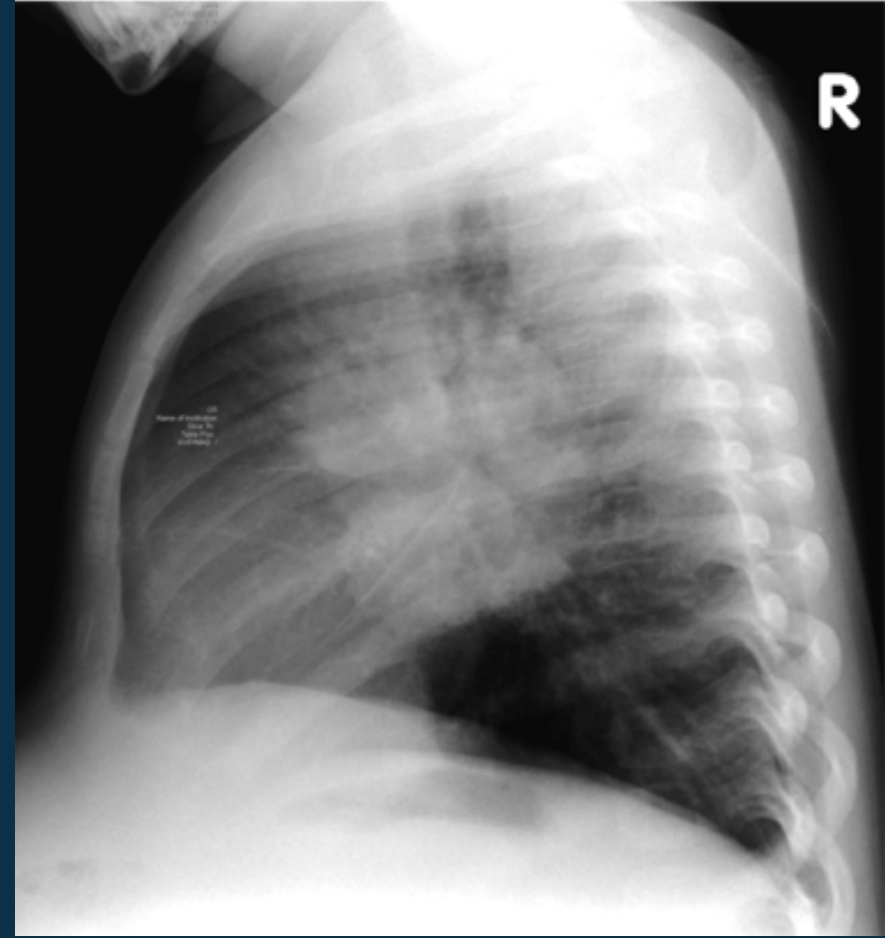

The hilar area includes pulmonary veins and arteries, main bronchi, lymph nodes

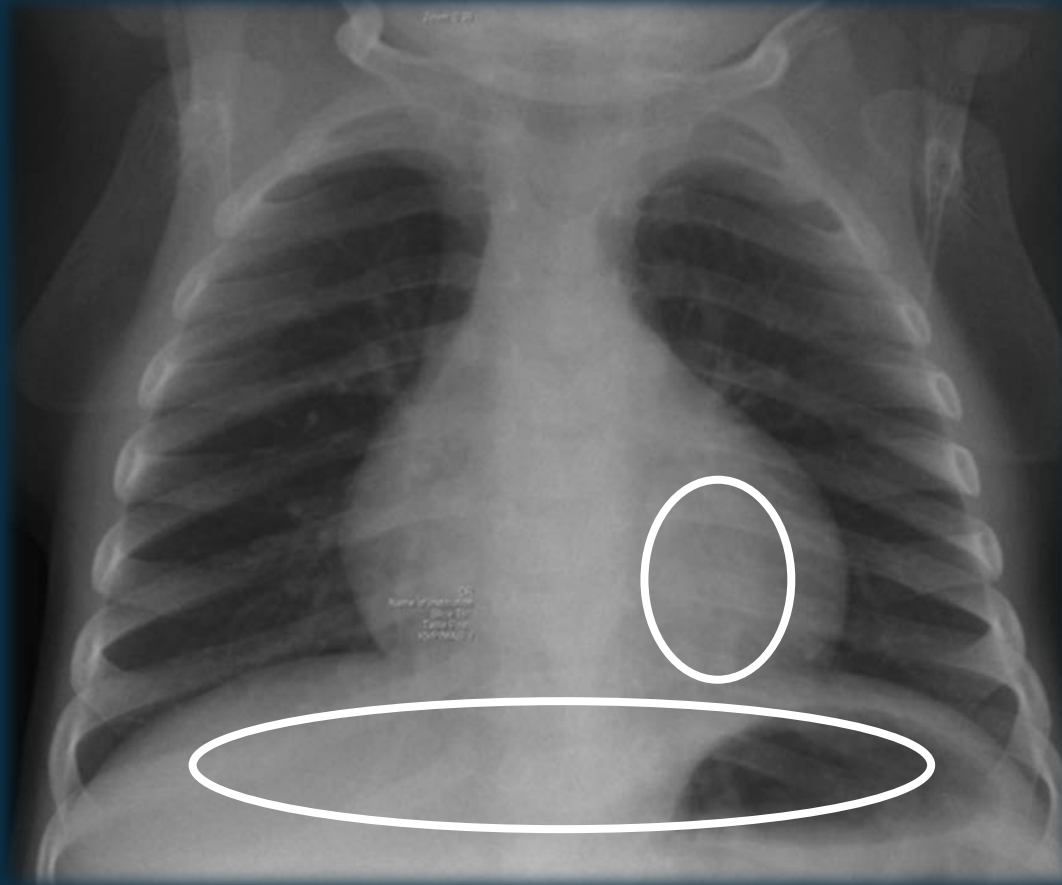
Normally bronchi and lymph nodes are not seen.



Normal lateral view



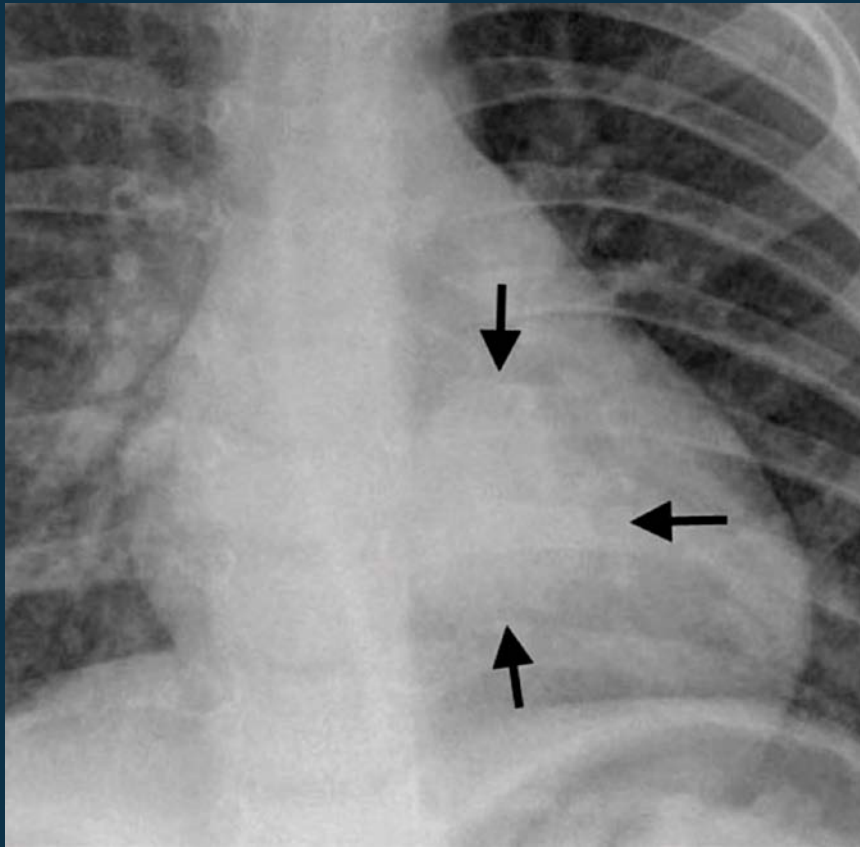
TB adenopathies



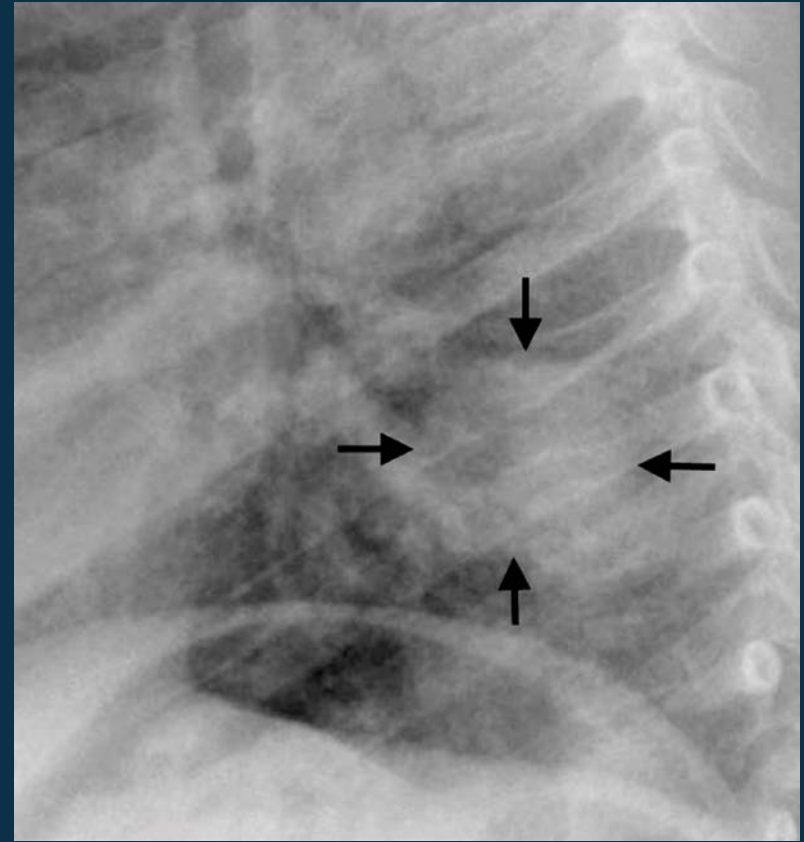
Retrocardiac region : left retrocardiac area should be homogeneously translucent

Look for signs of pneumonia in the zone below the diaphragm

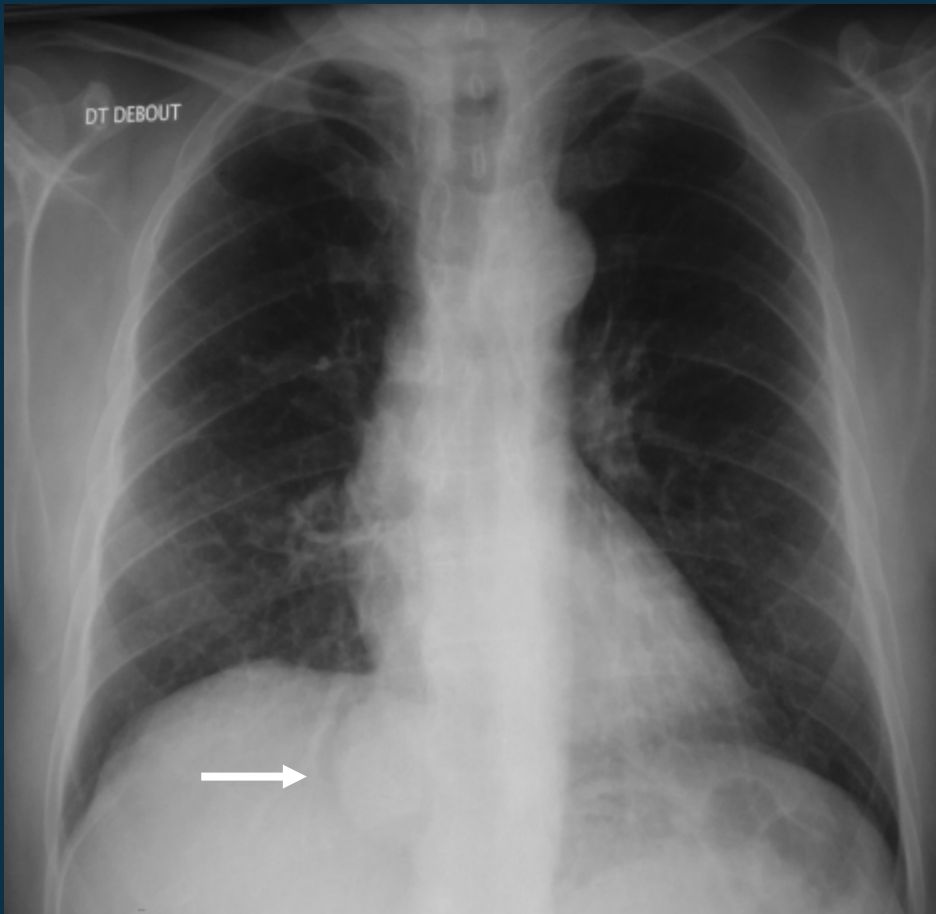
What is abnormal on this CXR ?



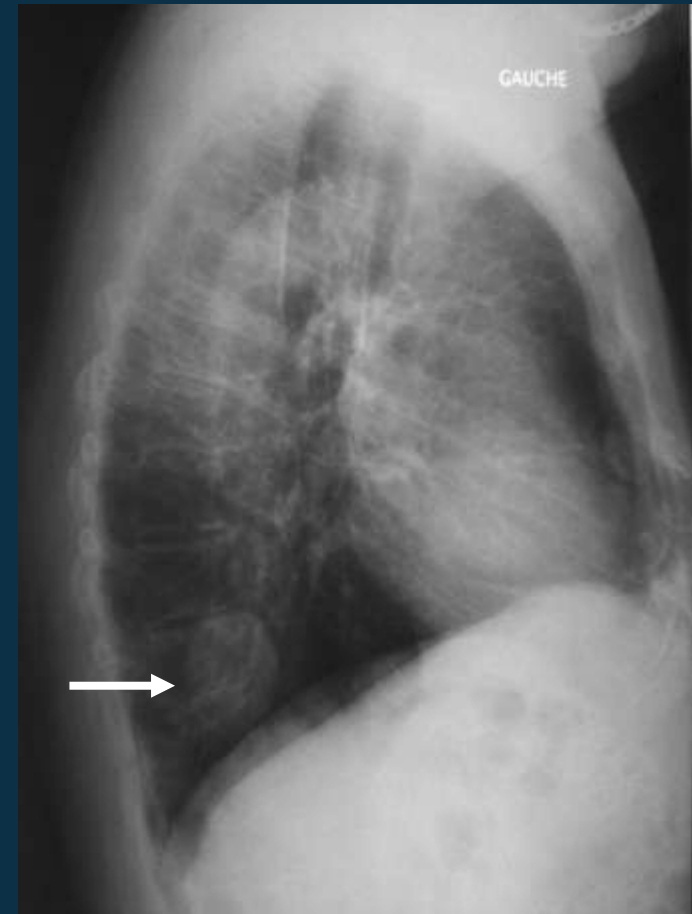Front view :
 Round pneumonia.
 Note the rounded solid opacity
 in the left lower lobe on PA
 (arrows).



Lateral view:
 Bacterial pneumonia in
 children sometimes appears
 round and well defined
 resembling a pulmonary mass.



Beware of the
hidden zones



The opacity is completely
intra-thoracic,
behind the right diaphragm

Module 1 How to read a CXR

Chap1: Technical and anatomical aspects

Chap2: Systematic approach to CXR interpretation

Part1. Quality factors

Part2. Normal CXR

Part3. First circle

1. Soft part of the chest wall
2. Diaphragmatic areas
3. Bony Thorax abnormalities

Part4. Second circle

4. Lung
5. Pleura

Part5. Third circle

6. Airways
7. hili and Mediastinum
8. Lymph nodes
9. Heart

Part6. The hidden areas

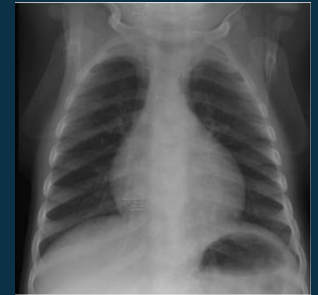Part7. Conclusion

Algorithm

Are both the AP and the Lateral readable? → No → Not readable → Redo CXR

↓
Yes
↓

Is the CXR normal? → Yes → Normal

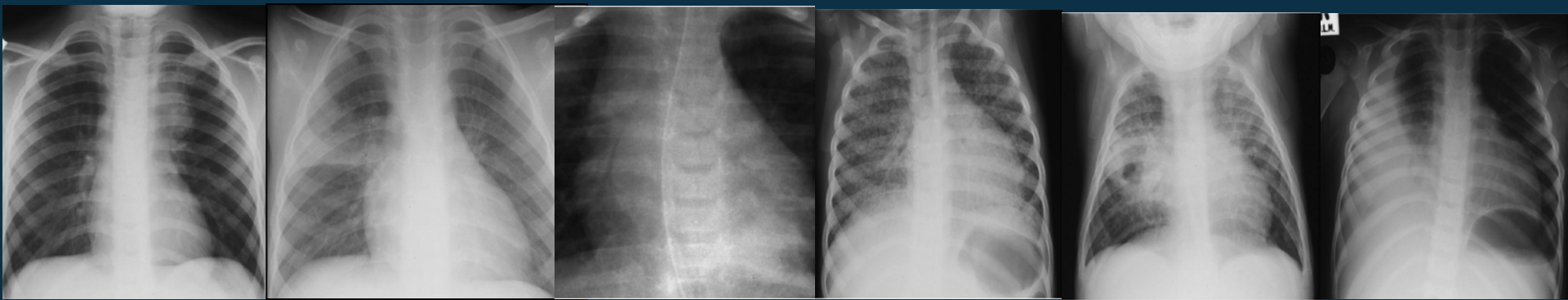


↓
No
↓

Abnormal: one of the 6 signs suggestive of TB present ? →

- Enlarged lymph nodes
- Alveolar opacity of the lung tissue
- Airway compression
- Miliary infiltrates
- Cavitation
- Pleural or pericardial effusion

- yes/no
- yes/no
- yes/no
- yes/no
- yes/no
- yes/no



Key points on the systematic approach to CXR reading:

Is the CXR readable or not ?

- . Check the technical quality factors: inspiration, rotation, penetration

Assess the 3 circles with inward progression. Is the CXR Normal ?
Suggestive of TB?

- . Look for 6 suggestive TB signs in each circle

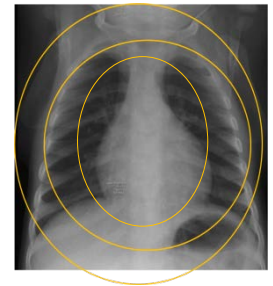
1st circle

Diaphragms: check their shape, symmetry and elevation

2nd circle

Lungs: read from top to bottom, compare right and left

- . Look for hyperlucencies (black) asymmetry between right and left lung due to partial airway compression by TB lymph node
- . Look for alveolar opacities (white): pneumonia , atelectasis Pleura: look for pleural effusion



Key points on the systematic approach to CXR reading:

3rd circle

1. Airways:

- . Normally the trachea buckles in expiration in infants
- . Look for airway compression : look at size, position narrowing, deviation, splaying of the carina

2. Mediastinum: beware of thymus, varies in size with age

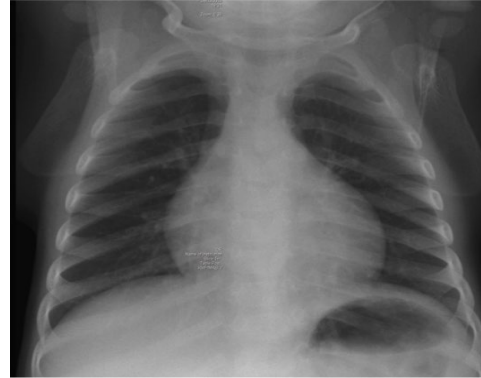3. Lymph nodes: TB is the main aetiology of enlarged lymph nodes in high TB incidence countries

4. Heart:

- . Shape changes with age and position
- . Look for pericardial effusion
- . Make sure you look at the lung behind the heart (a favorite place for pneumonia)

The End





CHEST X-RAY TRAINING (CXR)

**Module 2: How to diagnose TB
on a paediatric CXR
using a simplified reading tool at PHC level**



Learning Objectives

Module 1

1. To recognize a Normal child CXR on a front and lateral view and an Unreadable CXR (even of poor quality)
2. To learn systematic approach to interpret child CXR with 3 circles approach

Module 2

3. To recognize **Suggestive** or **Not suggestive** of TB on CXR using a simplified reading tool that identifies 6 paediatric CXR patterns classified as 'suggestive of TB'

Learning Objectives

Module 2: diagnose TB on a paediatric CXR using a simplified reading tool at PHC level

Chap1. Introduction

Chap2. Enlarged lymph nodes

Chap3. Alveolar opacity of the lung tissue

Chap4. Airways compression

Chap5. Cavitation

Chap6. Pleural or pericardial effusion

Chap7. Miliary

Chap8. Reading tool in a nutshell

WHO: CXR is part of the diagnostic pathway in children


1. Diagnostic pathway combining

- . Clinical assessment
- . Risk factors assessment
- . Exposure history
- . Bacteriological tests
- . and ... CXR

2. Quality CXRs are essential for diagnosis

3. Lateral CXR required under 4 years of age, can identify hilar lymphadenopathy

4. Useful in children where bacterial confirmation is challenging. Adolescents similar as adults



World Health
Organization

END TB

TB-Speed : role of CXR in improving TB diagnosis in children

Childhood TB is pauci-bacillary and seldom bacteriologically confirmed. Consequently the diagnosis of intrathoracic TB in children depends largely on CXR evaluation

To assess the added value of a simplified CXR reading tool

To strengthen CXR interpretation skills by training all staff involved in TB diagnosis

To develop an External Quality Assurance EQA to review the quality of CXR interpretation

CXR reading tool

Identifies 6 paediatric CXR features suggestive of TB

- 1- Enlarged lymph nodes (lateral view required)
- 2- Alveolar opacity of the lung tissue
- 3- Airway compression (which may lead to asymmetry between left and right lung)
- 4- Cavitation
- 5- Pleural or pericardial effusion
- 6- Miliary infiltrates

Diagnostic algorithm

Question 1: Are both the AP and the lateral CXR readable ?

Yes No : redo CXR

Question 2: is the CXR normal ?

No: abnormal

Yes: normal

Question 3: Are one of the 6 signs suggestive of TB present ?

- | | |
|--|--------|
| 1. Enlarged lymph nodes | yes/no |
| 2. Alveolar opacity of the lung tissue | yes/no |
| 3. Airway compression | yes/no |
| 4. Cavitation | yes/no |
| 5. Pleural or pericardial effusion | yes/no |
| 6. Miliary infiltrates | yes/no |

All no: Not suggestive of TB
→ 1 Yes or more: Suggestive of TB

If the CXR is abnormal, is it suggestive of TB ?

The 6 signs suggestive of TB

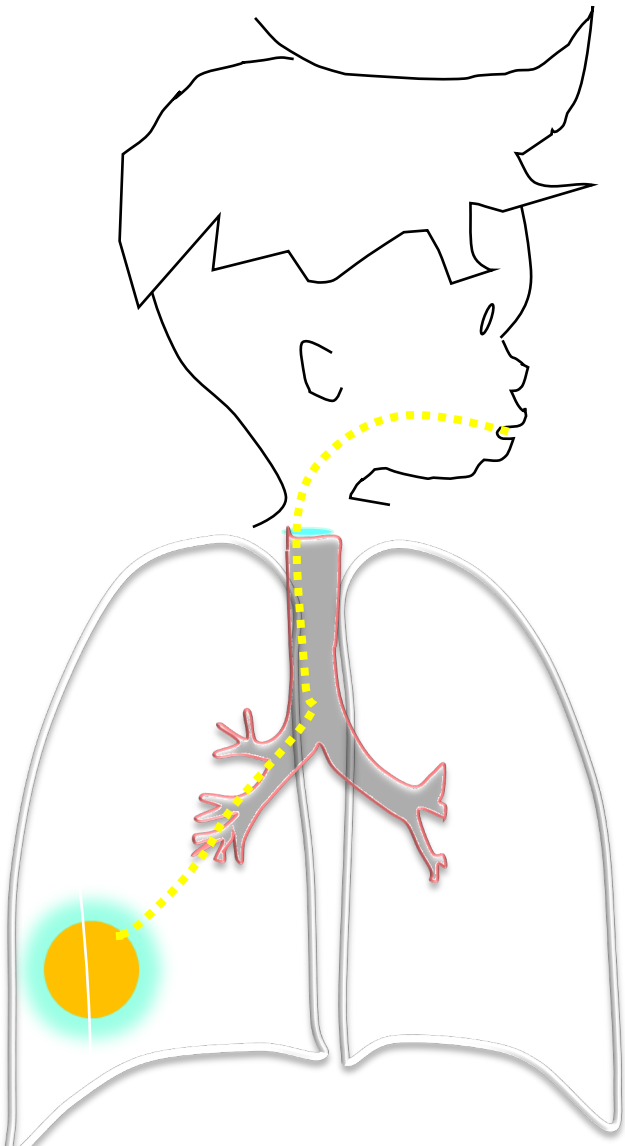

- 1- Enlarged lymph nodes
- 2- Alveolar opacity
- 3- Airway compression
- 4- Cavitation
- 5- Pleural or pericardial effusion
- 6- Miliary infiltrates



Pathophysiology of childhood TB and correlation with the 6 radiographic features

Inhalation of *M. tuberculosis*

Proliferation in alveoli: primary focus or Ghon focus



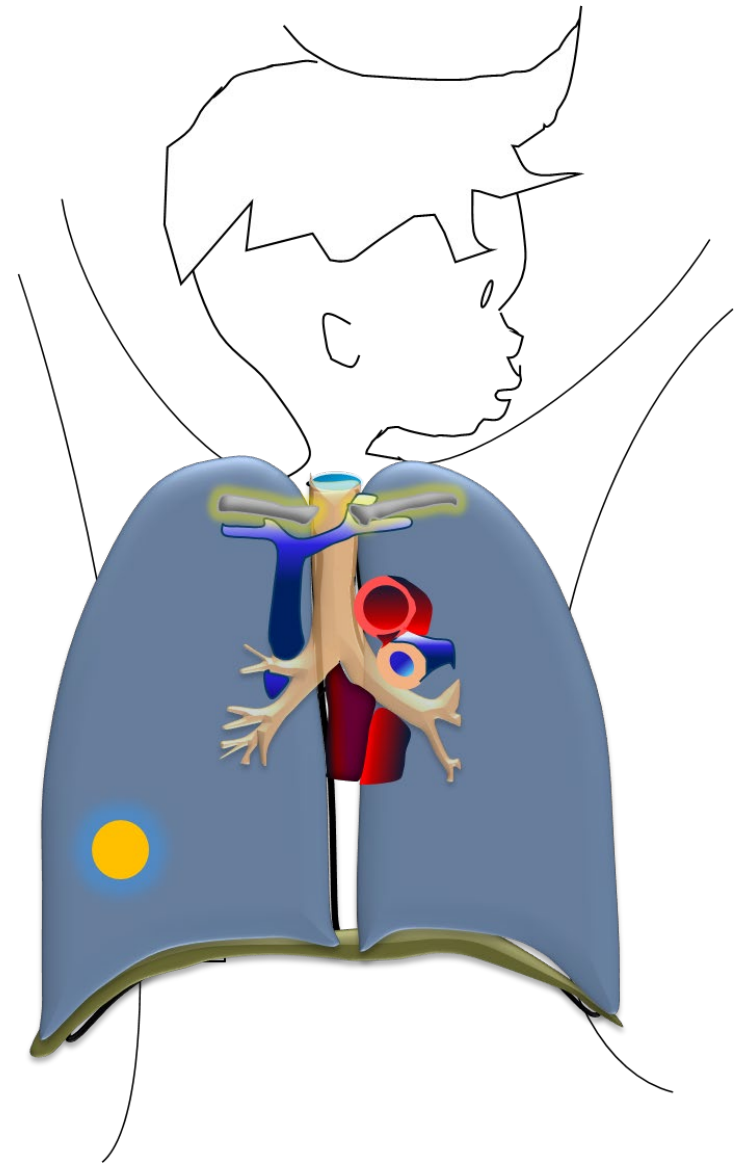
- Flugge Droplets : 1-5 bacilli / droplets
- . Cough → 3,500 droplets
- . Sneeze → 20 to 40,000 droplets

Uncomplicated primary TB (Ghon focus / complex)

The parenchymal focus are called pulmonary tuberculomas defined ovoid granulomas, solitary or multiple from 0.4 cm to 5 cm diameter

Radiologically the primary focus is often so small that it is most often not visible

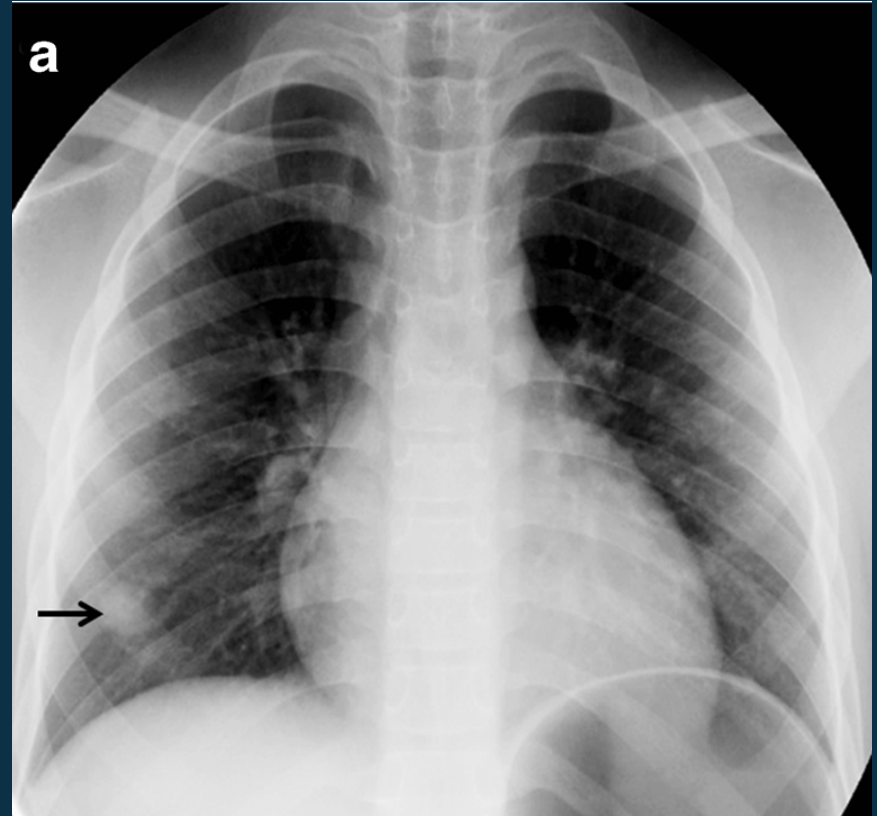
- . It can calcify with time
- . Calcification is a sequela of LTB occurring after infection



What do you see on this X-ray ?
 . A dense round opacity

Where?
 . Inferior part of right lung

What is your diagnosis ?
**Right Lower Lobe Primary Focus
 Ghon focus in a 7- year-old boy**



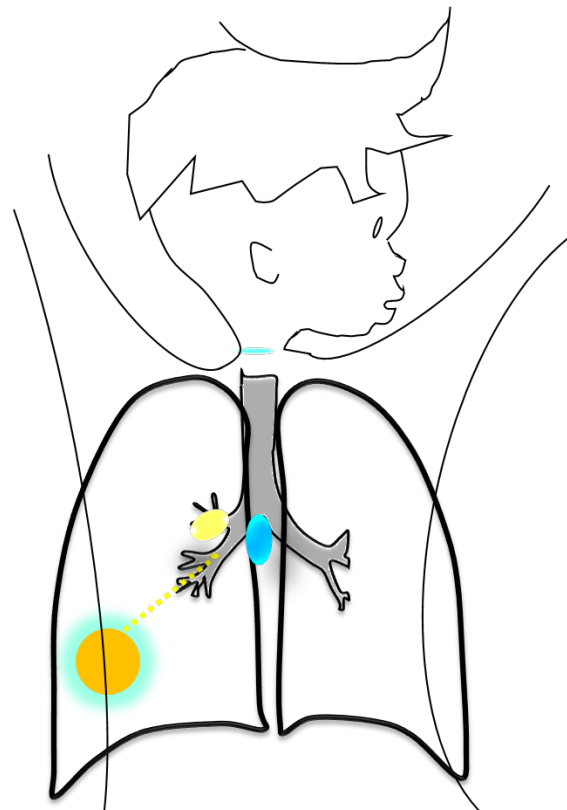
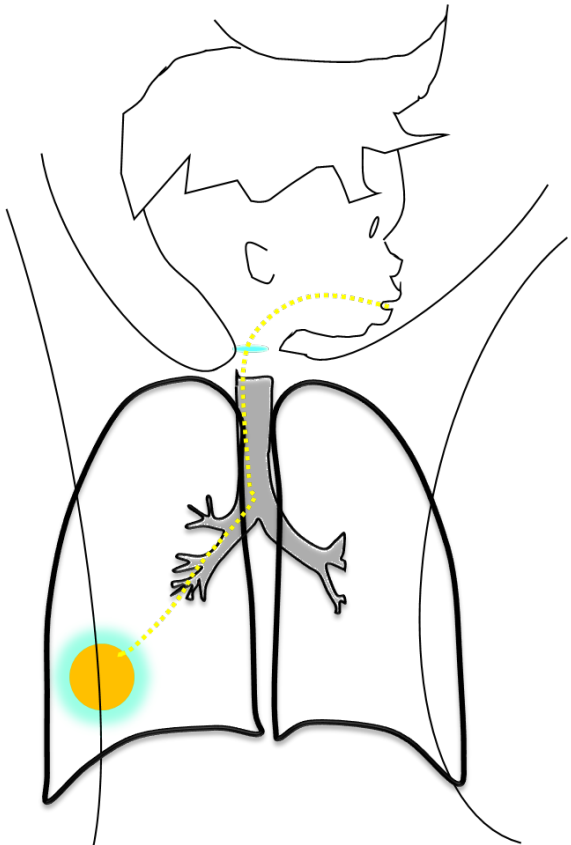

Inhalation of *M. tuberculosis*



Proliferation in alveoli
 Primary focus = Ghon focus



Spread via the lymphatic system
 Primary complex = Ghon complex



Learning Objectives

Module 2: diagnose TB on a paediatric CXR using a simplified reading tool at PHC level

Chap1. Introduction

Chap2. Enlarged lymph nodes

Chap3. Alveolar opacity of the lung tissue

Chap4. Airways compression

Chap5. Cavitation

Chap6. Pleural or pericardial effusion

Chap7. Miliary

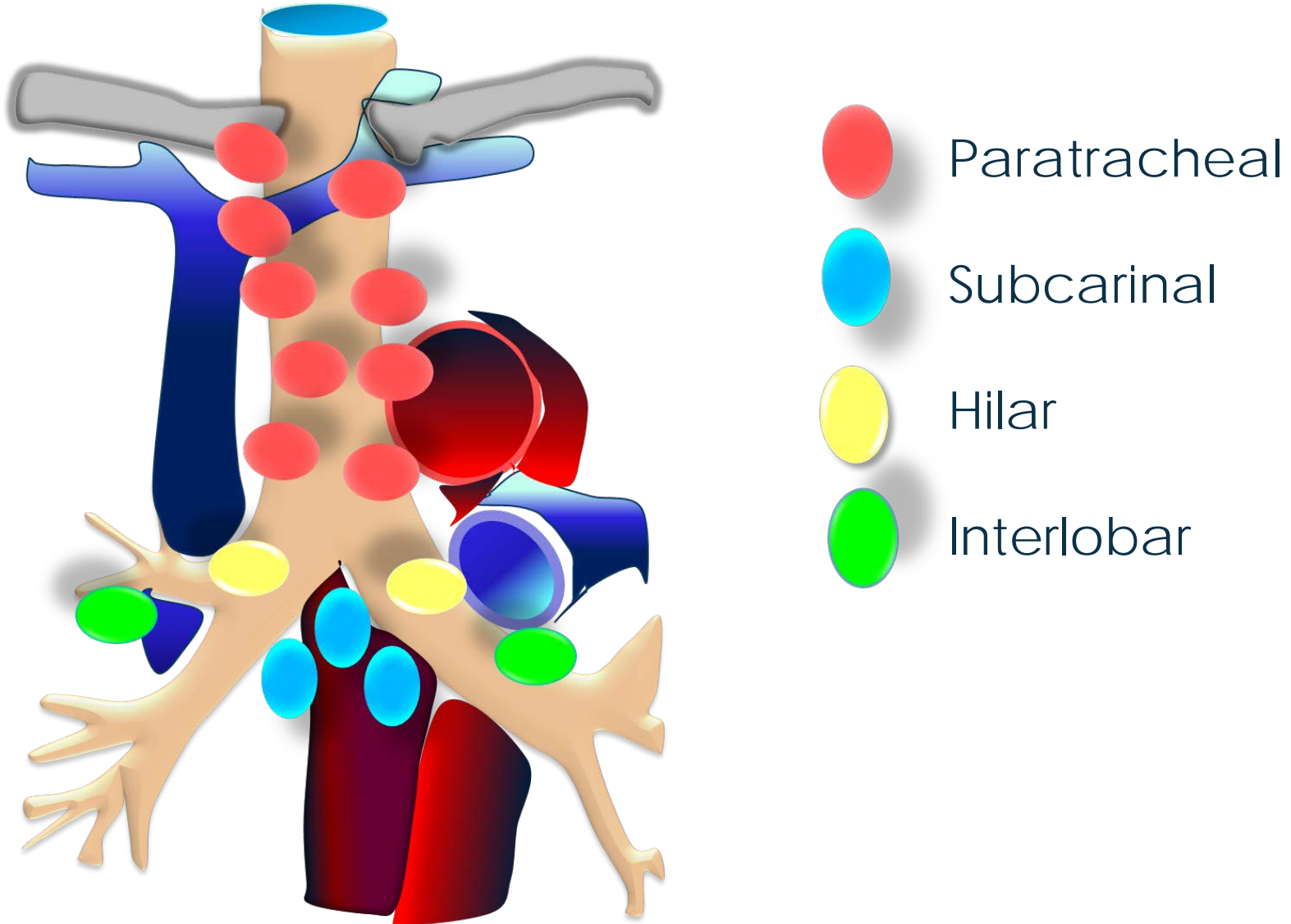
Chap8. Reading tool in a nutshell

Enlarged lymph nodes

Hilar and mediastinal lymph node enlargement are the most common appearance on CXR

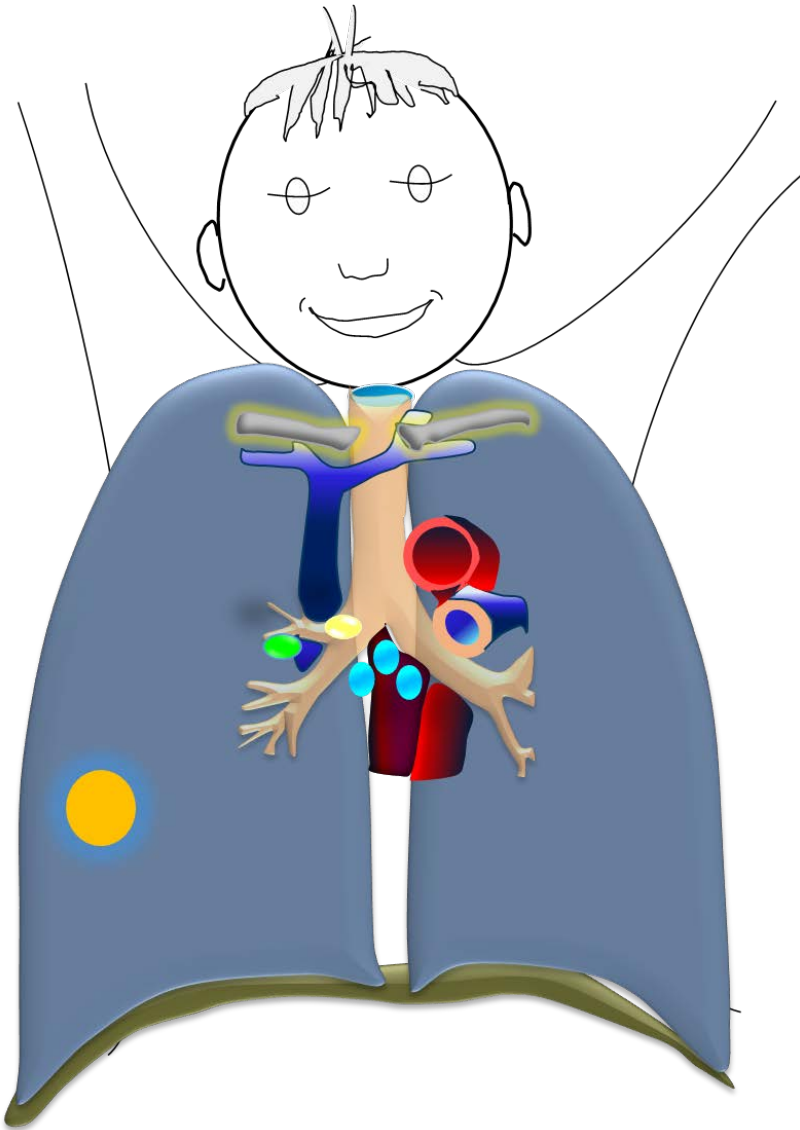
- . Usually unilateral
- . Sometimes bilateral
- . Sometimes latero-tracheal
- . Infiltration into the surrounding lung tissue is common

Localisation of TB lymph nodes



Diagnosis of TB in children
=
**Identification of enlarged lymph
nodes on CXR**
=
Hallmark of childhood TB

Primary pulmonary infection



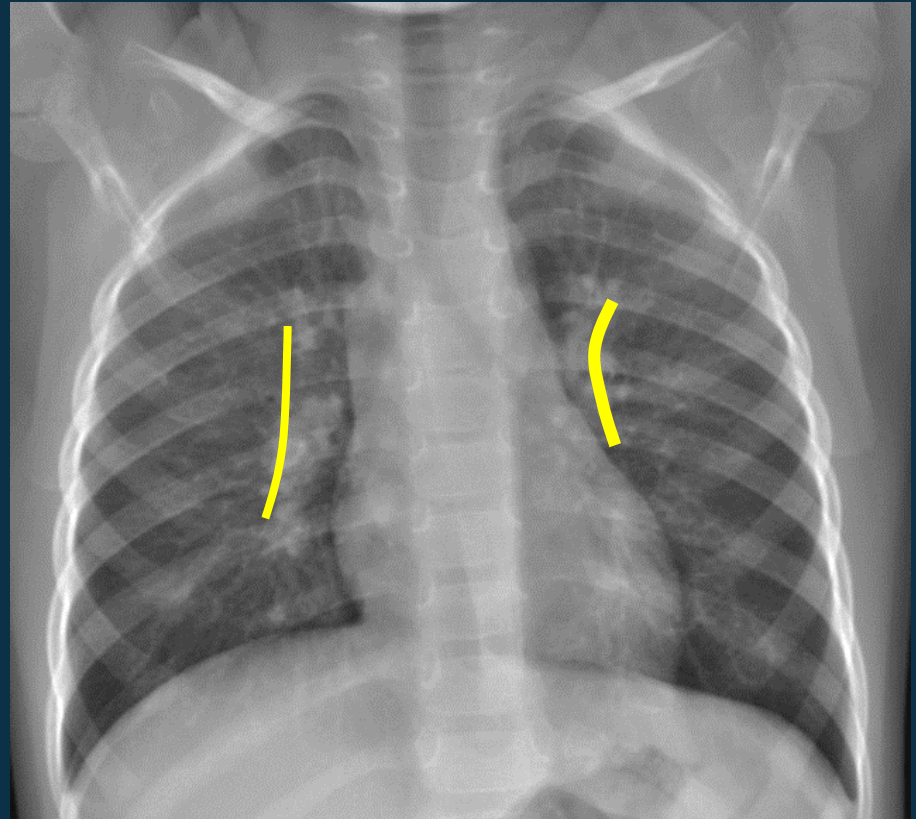
1. Ghon focus
2. Spread via draining lymphatic vessel to central and regional lymph nodes
3. Ghon complex = Ghon focus and enlarged lymph nodes

In an immunocompromised child, the lesions extend 90% within 1 year after primary infection [see comment](#)

The lower lobes drain to the perihilar nodes

Normal hilum

1. Must be visible
2. Should have a clear external edge with concave aspect
3. Should have no soft tissue density masses overlapping the hilar region



What do you see on this CXR ?

- . Soft tissue density mass
- . Convex appearance
- . Lobulated density

Where?

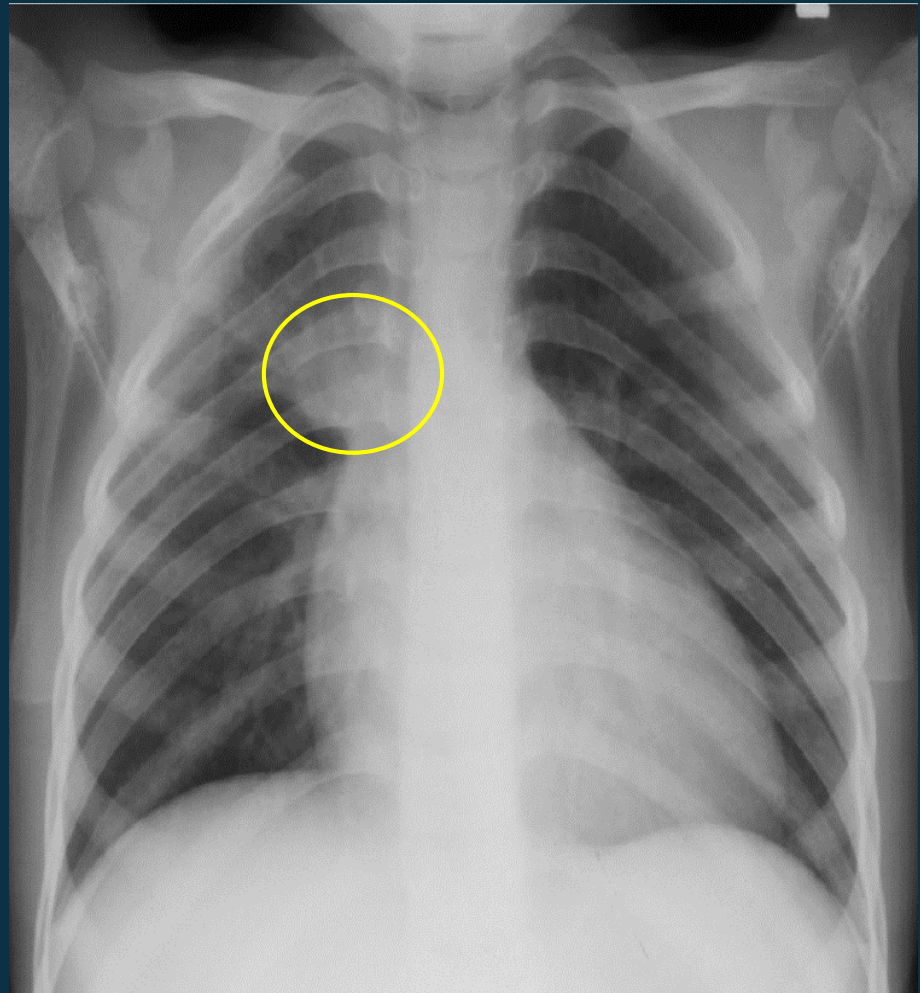
- . Right hilar region

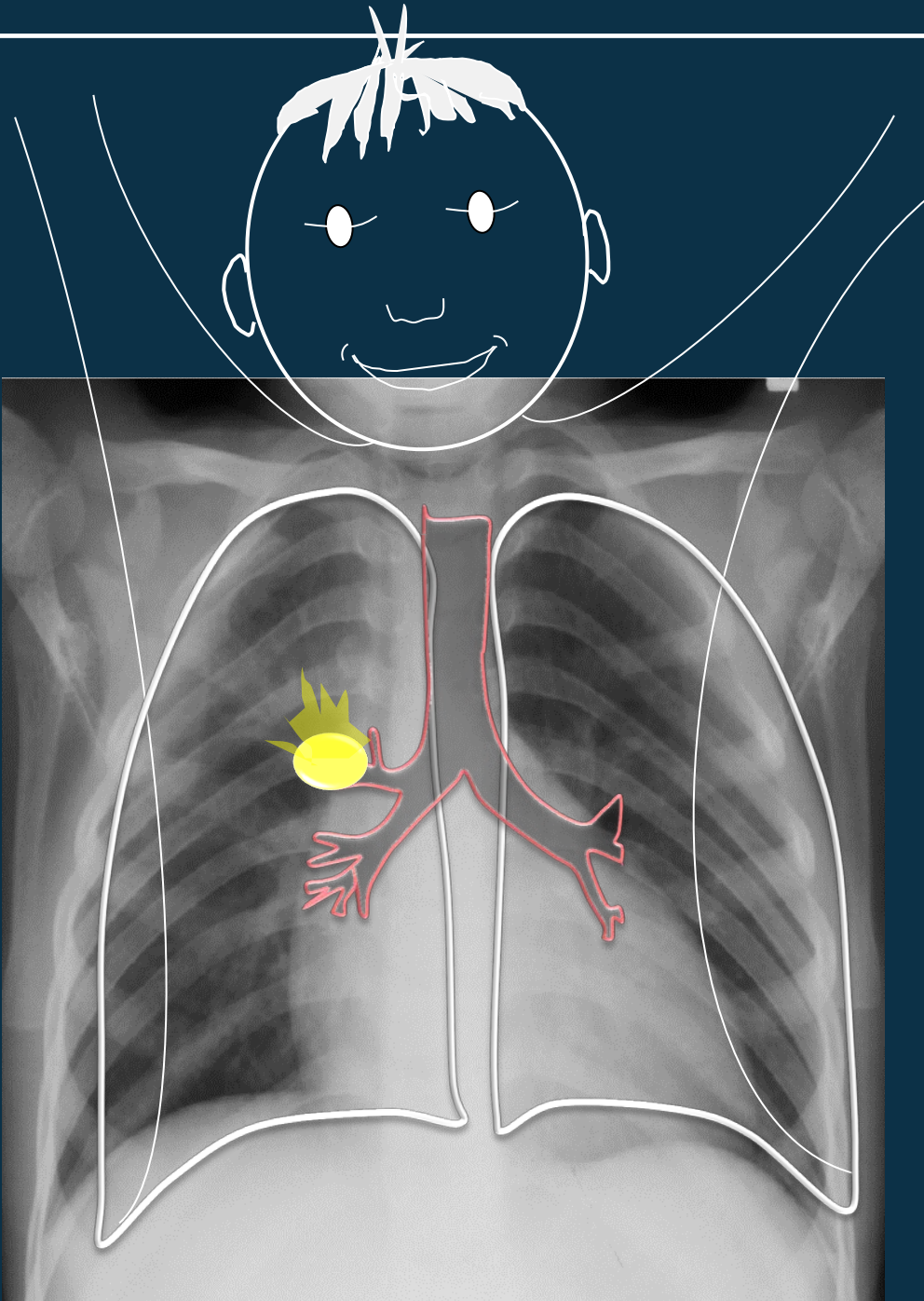
Do you see the right hilar area?

- . No, it is overlapped by an abnormal opacity

What is your diagnosis ?

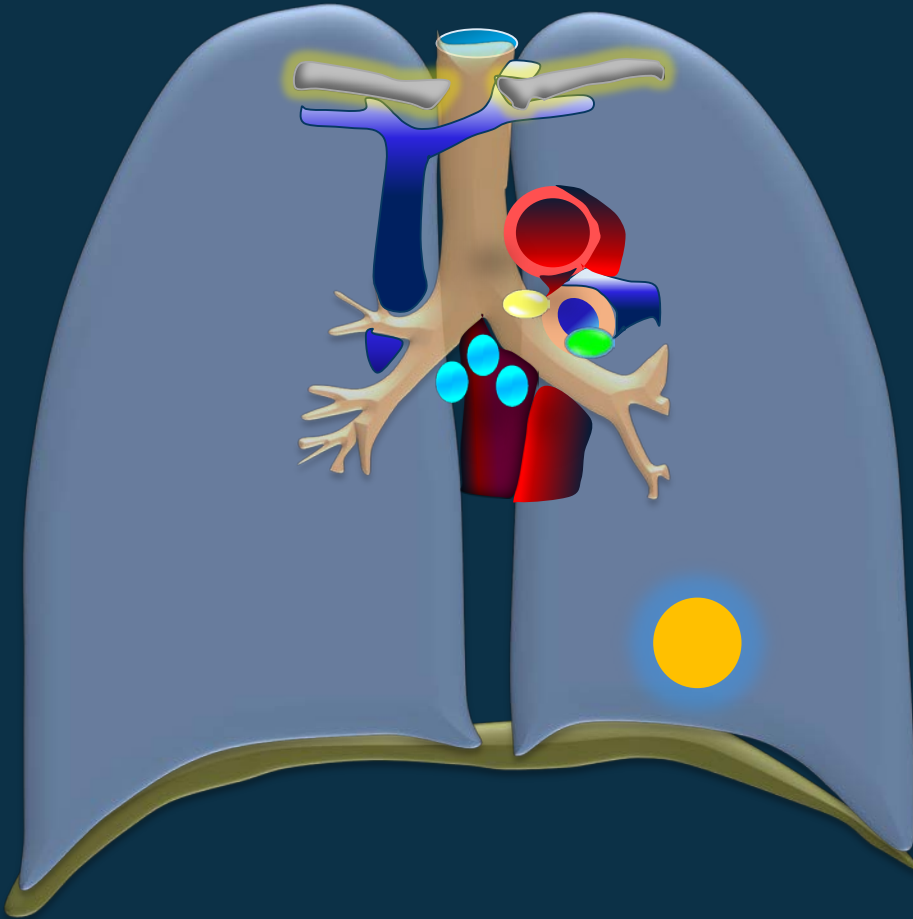
Enlarged lymph node in the right hilum with infiltration into the surrounding tissue





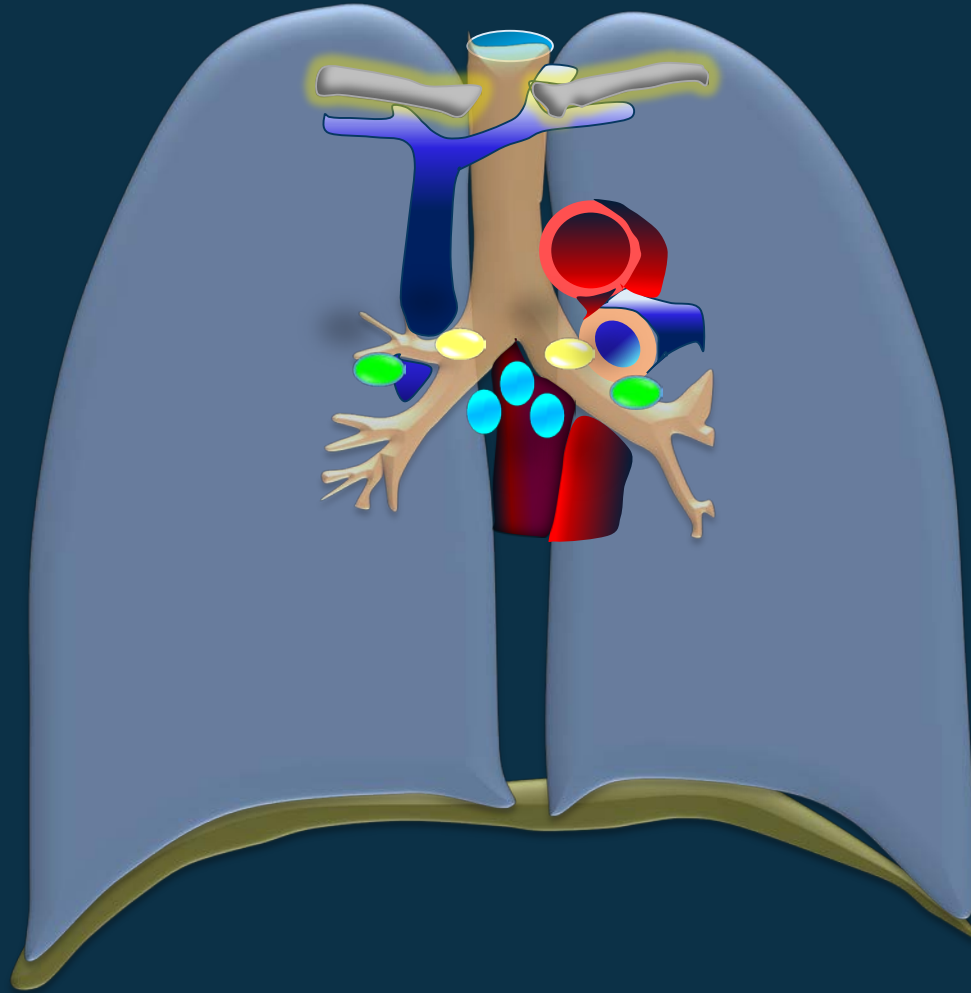
Enlarged lymph node in the right hilum with infiltration into the surrounding tissue

Primary pulmonary infection



1. Ghon focus
2. Spread via draining lymphatic vessel to central and regional lymph nodes
3. Ghon complex = Ghon focus and enlarged lymph nodes

The lower lobes drain to the perihilar nodes



Lymph nodes can be the only sign

What do you see on this CXR ?

- Convex soft tissue density mass
- Lobulated density

Where?

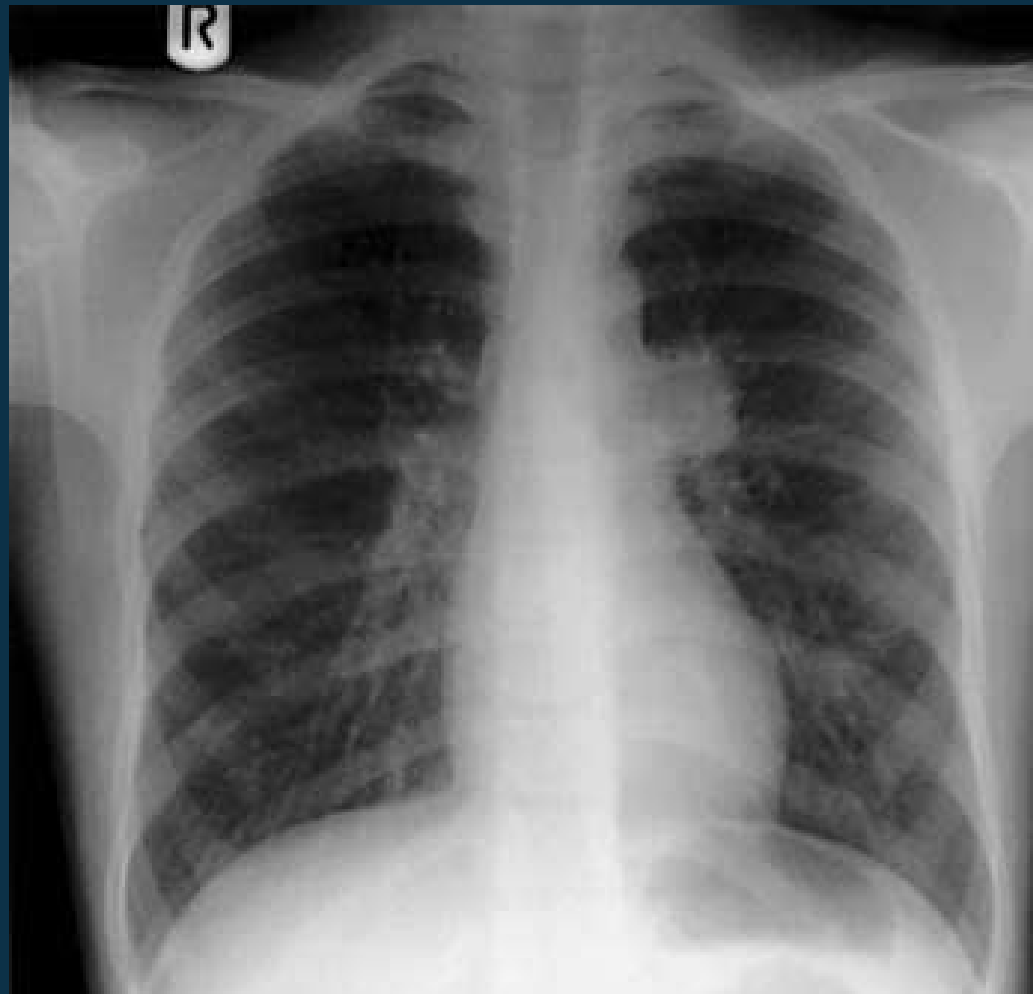- Left hilar region

Describe the external edge
look like?

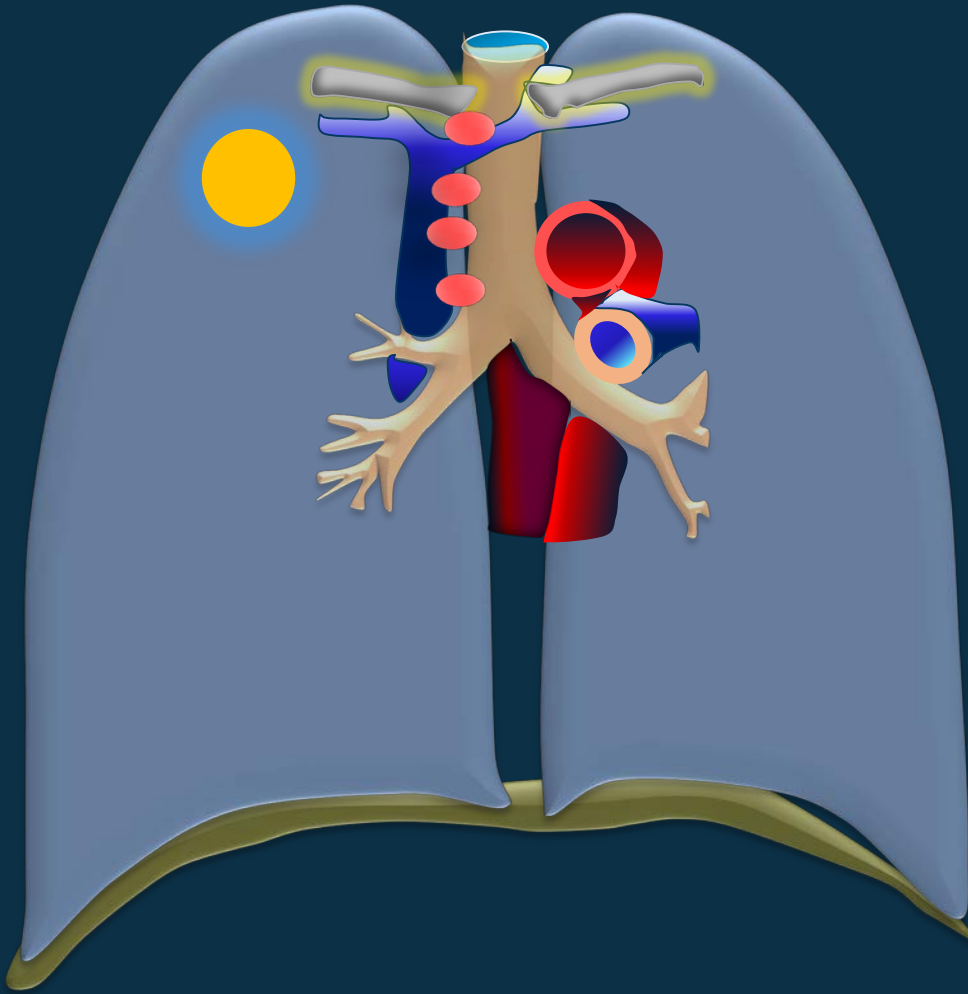
- Concave

What is your diagnosis ?

Enlarged lymph node in the left hilum



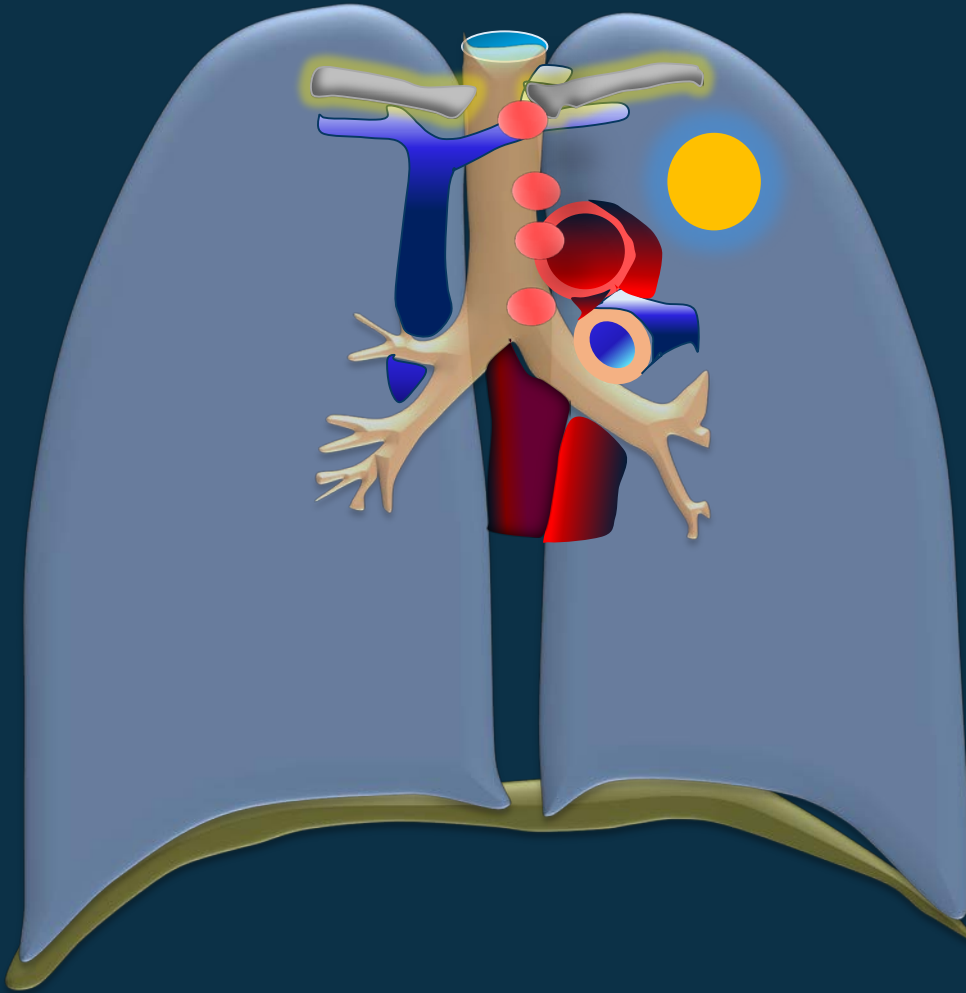
Primary pulmonary infection



1. Ghon focus
2. Spread via draining lymphatic vessel to central and regional lymph nodes
3. Ghon complex = Ghon focus and enlarged lymph nodes

The upper lobes drain to the paratracheal nodes

Primary pulmonary infection



1. Ghon focus
2. Spread via draining lymphatic vessel to central and regional lymph nodes
3. Ghon complex = Ghon focus and enlarged lymph nodes

The upper lobes drain to the paratracheal nodes

What do you see on this CXR ?

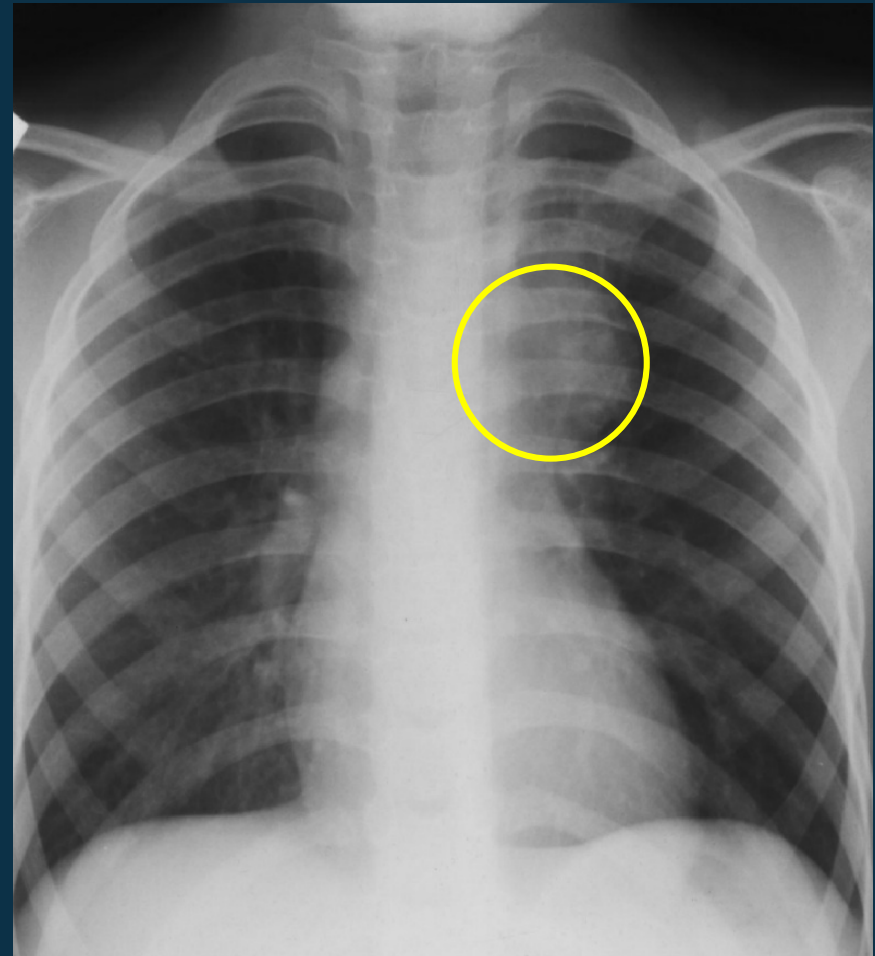
- . Lobulated soft tissue density mass
- . Convex appearance

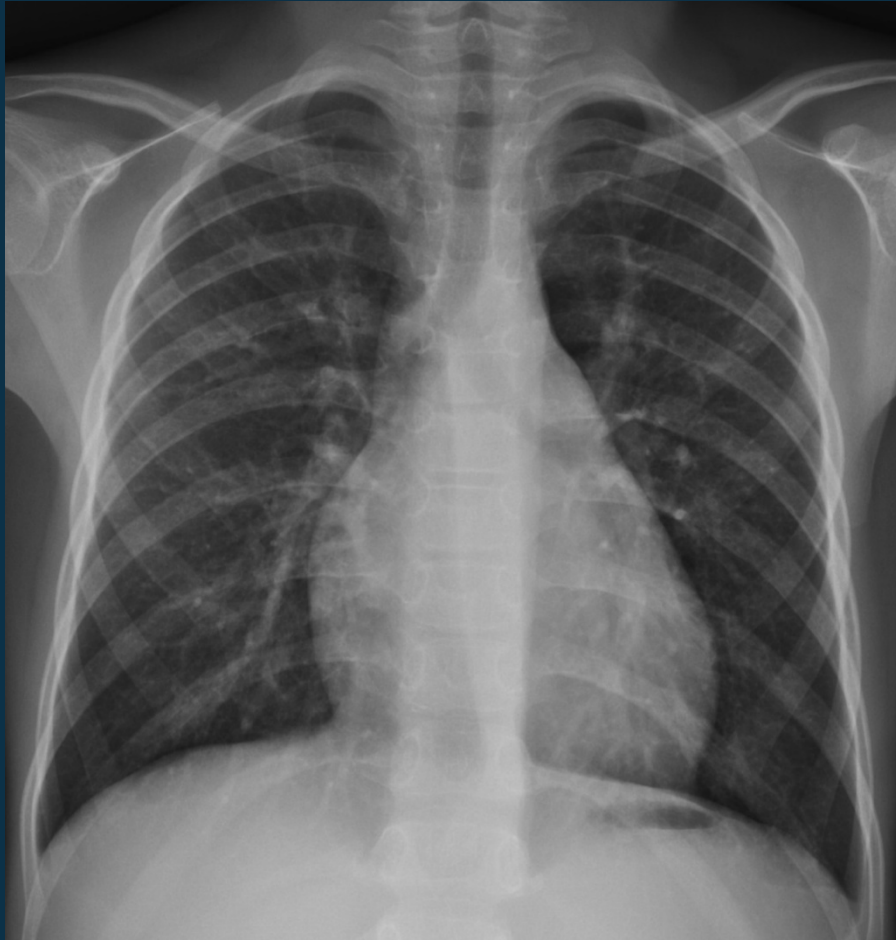Where?

- . Left paratracheal area

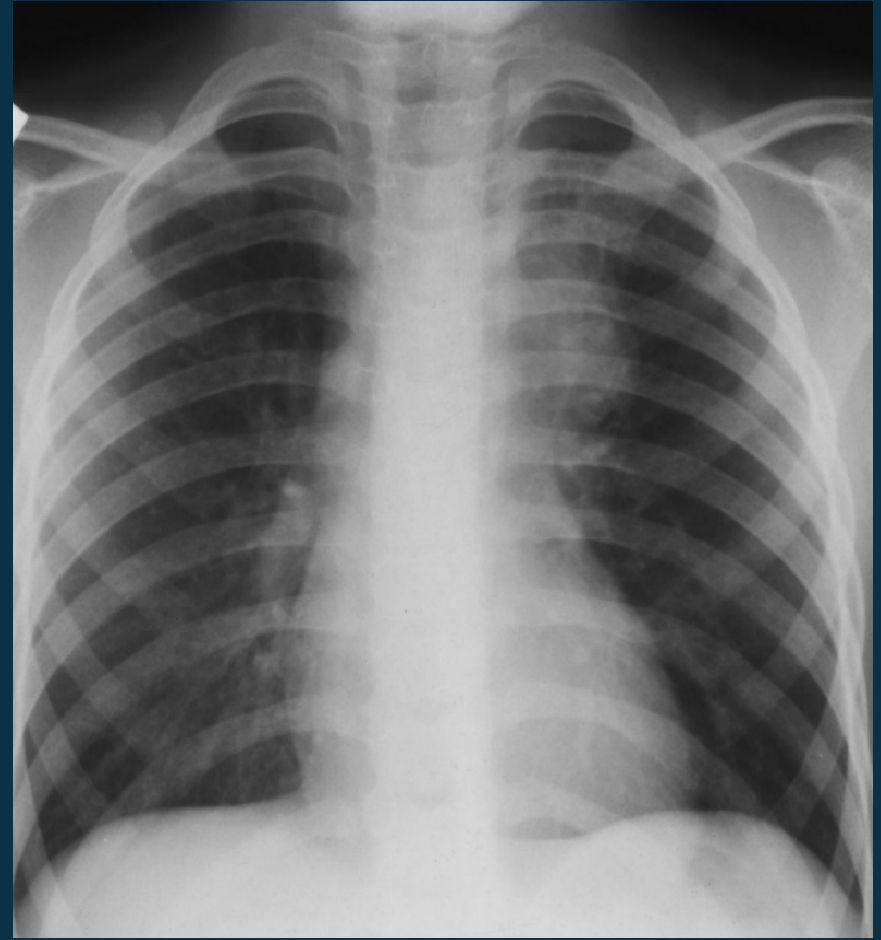
What is your diagnosis?

Enlarged lymph node, left paratracheal





Normal CXR



Left paratracheal lymph node

What do you see on this CXR?

- . Prominent perihilar opacity with convex edge

Where is it located?

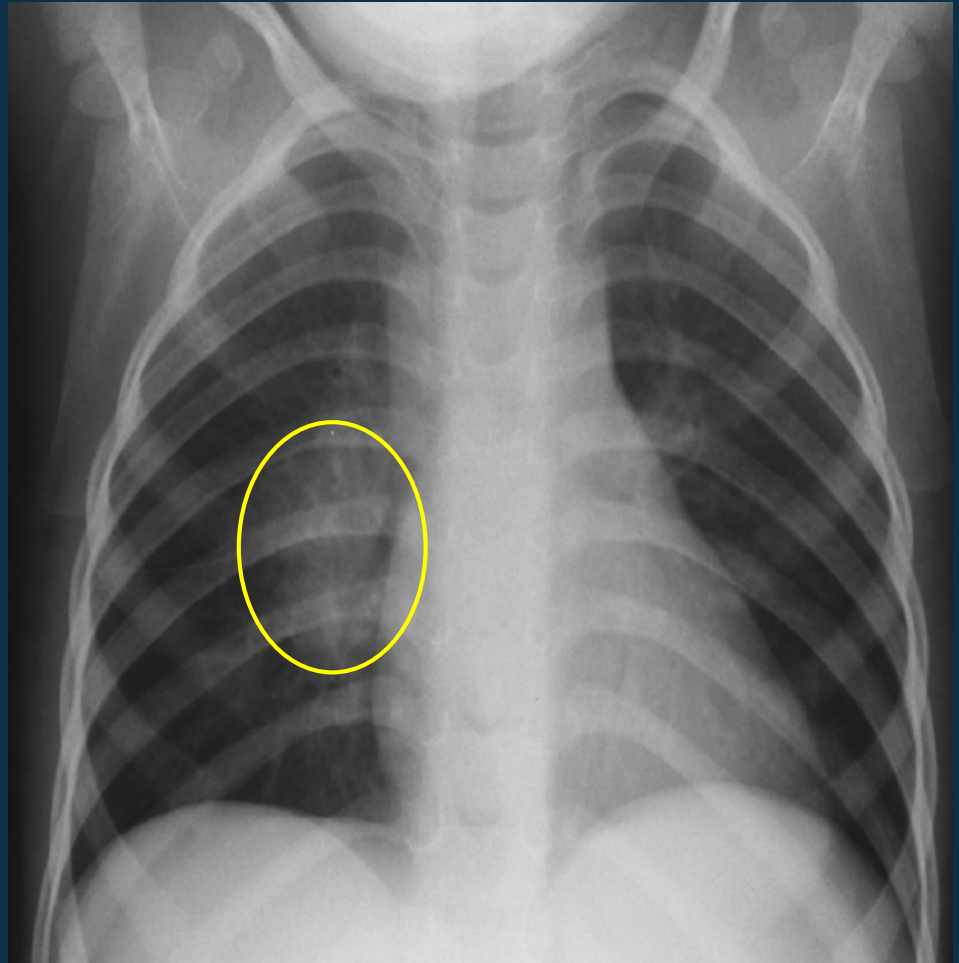
- . On the right

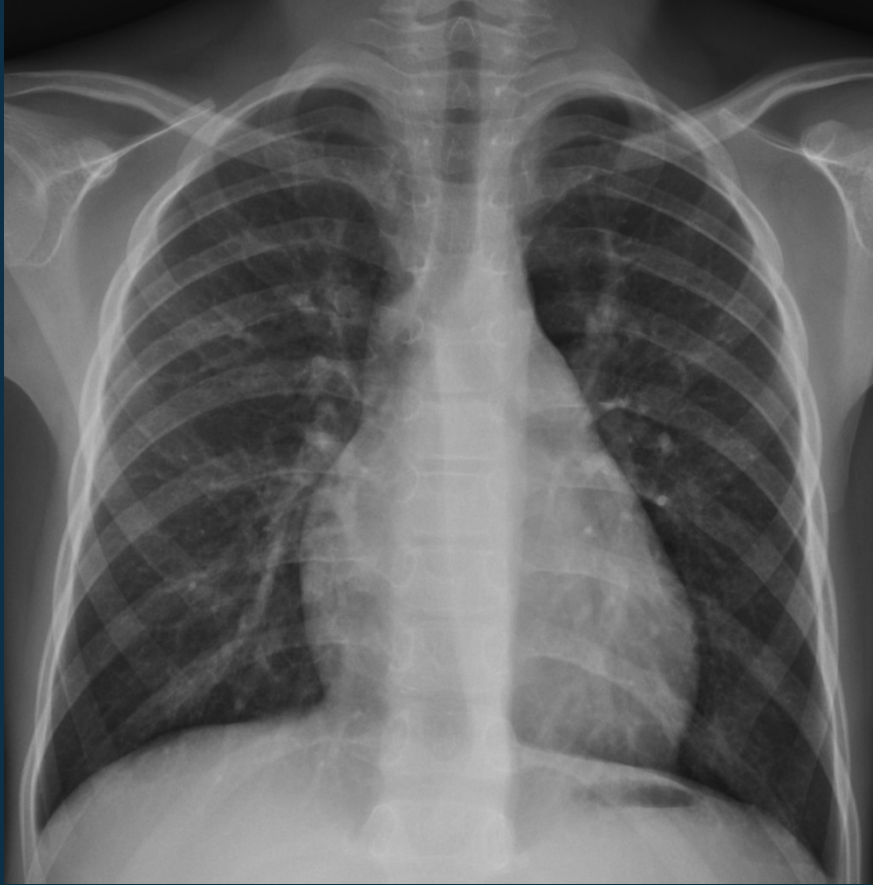
Describe the external edge ?

- . Convex not concave

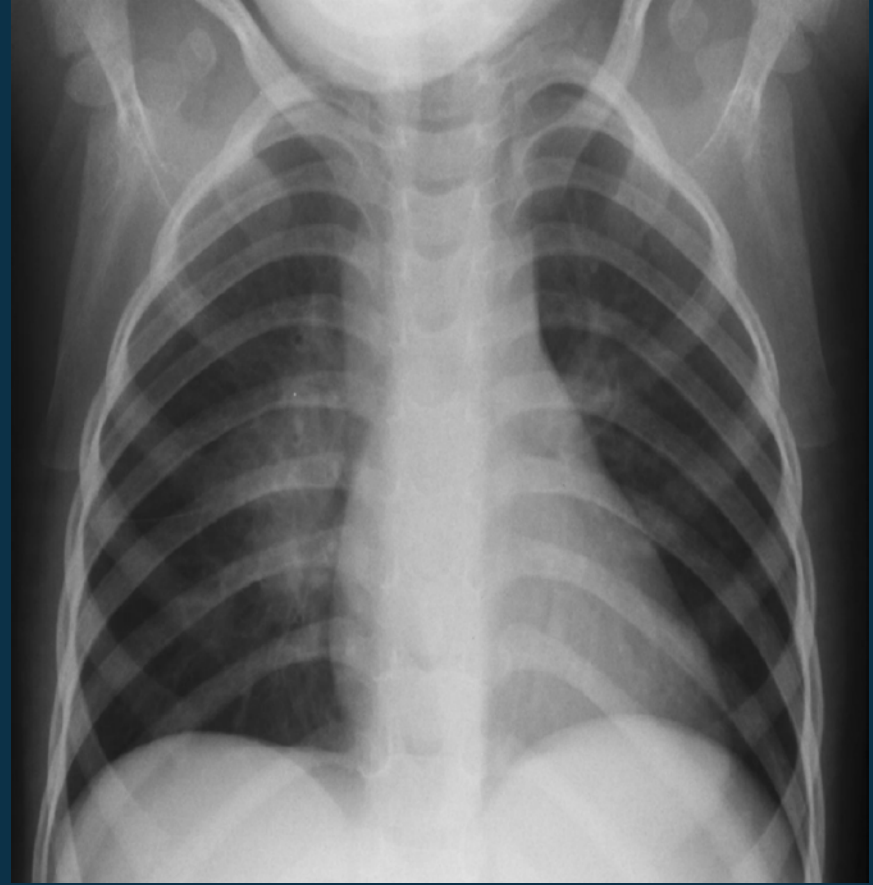
What is your diagnosis?

Enlarged right hilar lymph node





Normal CXR



Enlarged right hilar
lymph node
(note superior mediastinal
enlargement suggesting associated
mediastinal adenopathies)

What do you see on this CXR ?

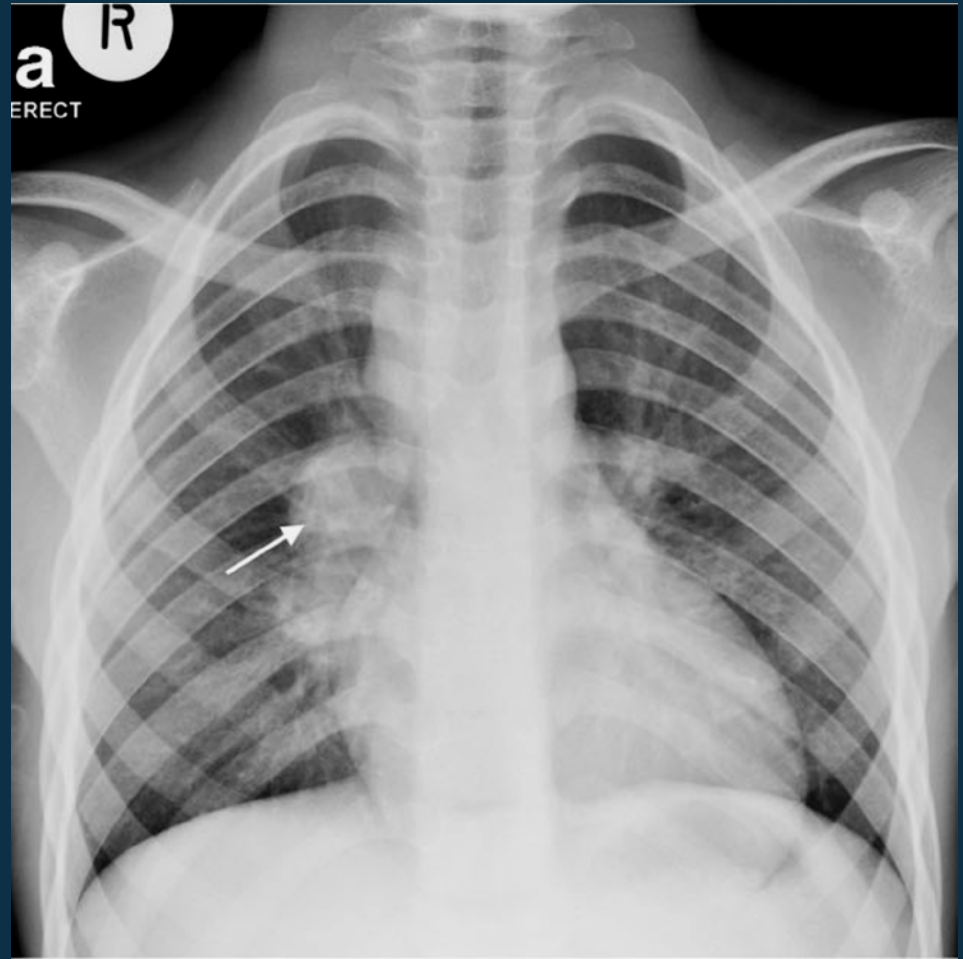
- . Lobulated dense soft tissue mass

Where?

- . Right hilar region

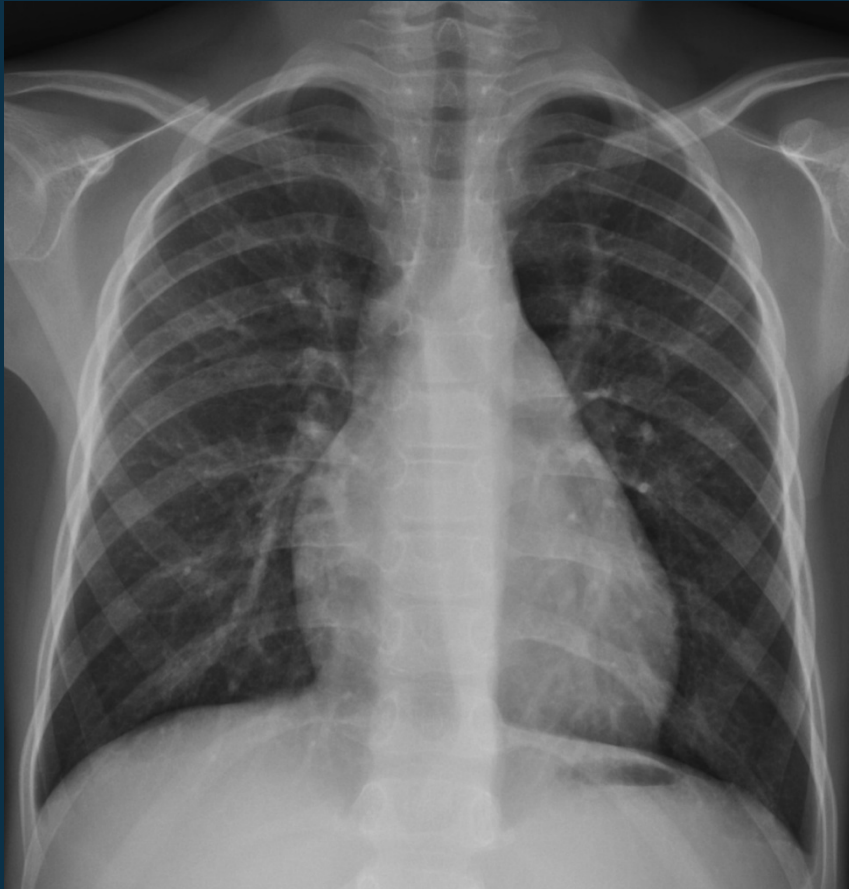Describe the external edge ?

- . Convex (see arrow)

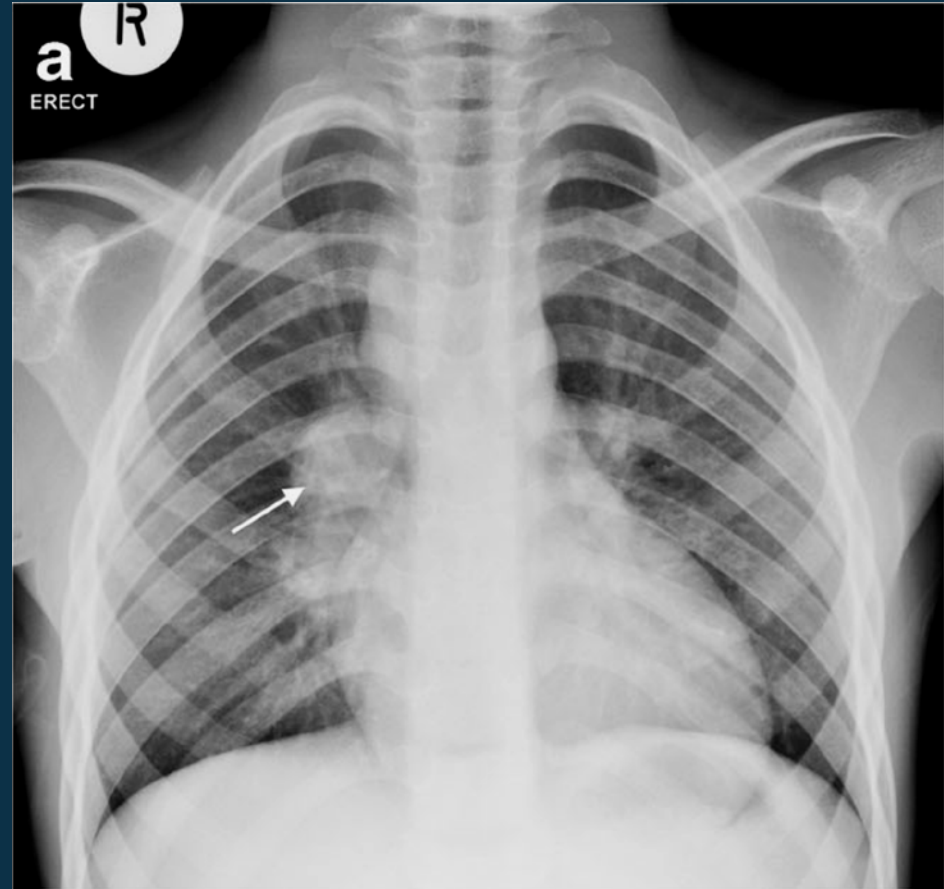


What is your diagnosis ?

Enlarged right hilar lymph node in a 9-month-old girl.

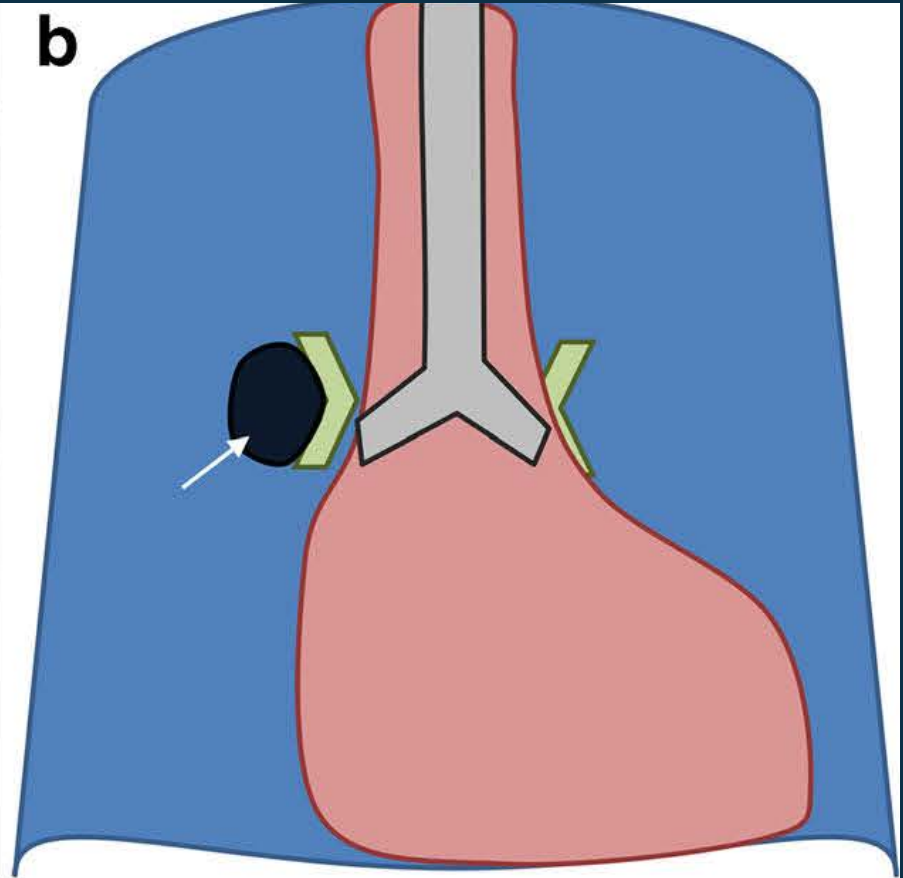
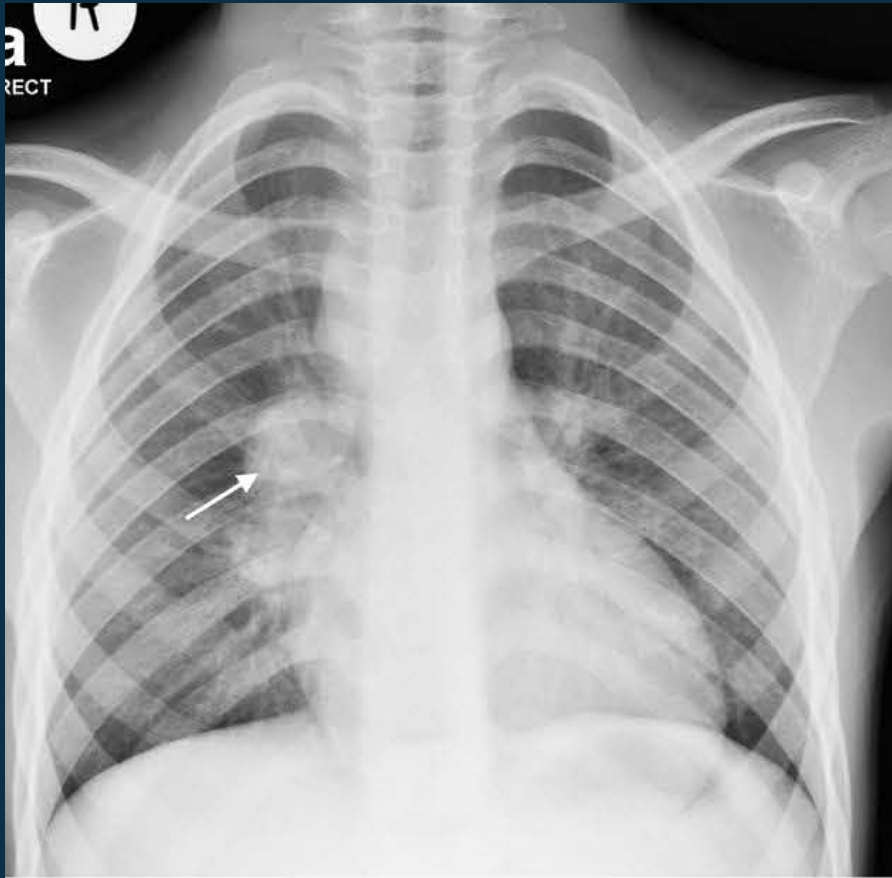

Normal CXR



Enlarged right hilar lymph node
(note superior mediastinal enlargement suggesting right paratracheal adenopathy)

Right hilar lymphadenopathy



What could you have asked for to confirm the enlarged hilar lymph nodes ?

A lateral view

What do you see on this CXR ?

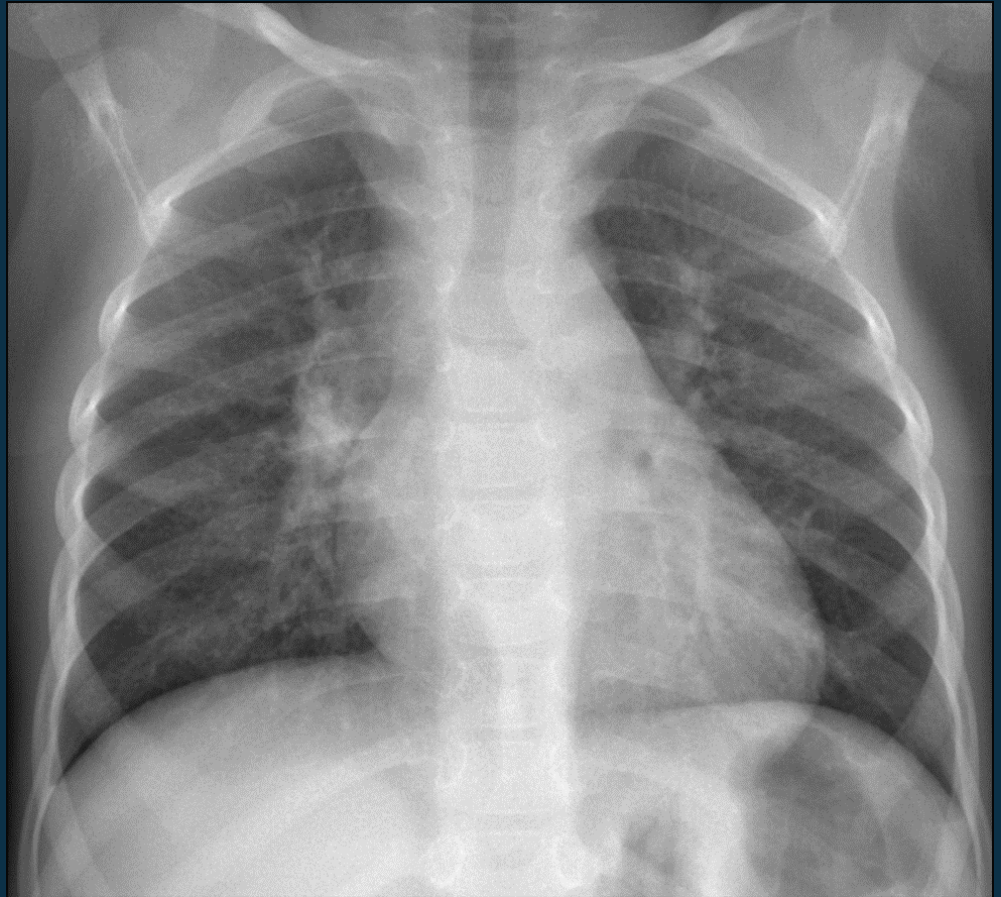
- . Lobulated dense soft tissue mass

Where?

- . Right hilar region

Describe the external edge?

- . Convex



What is your diagnosis ?

Enlarged right hilar lymph node in a 9-month-old girl.

The lateral view is very important

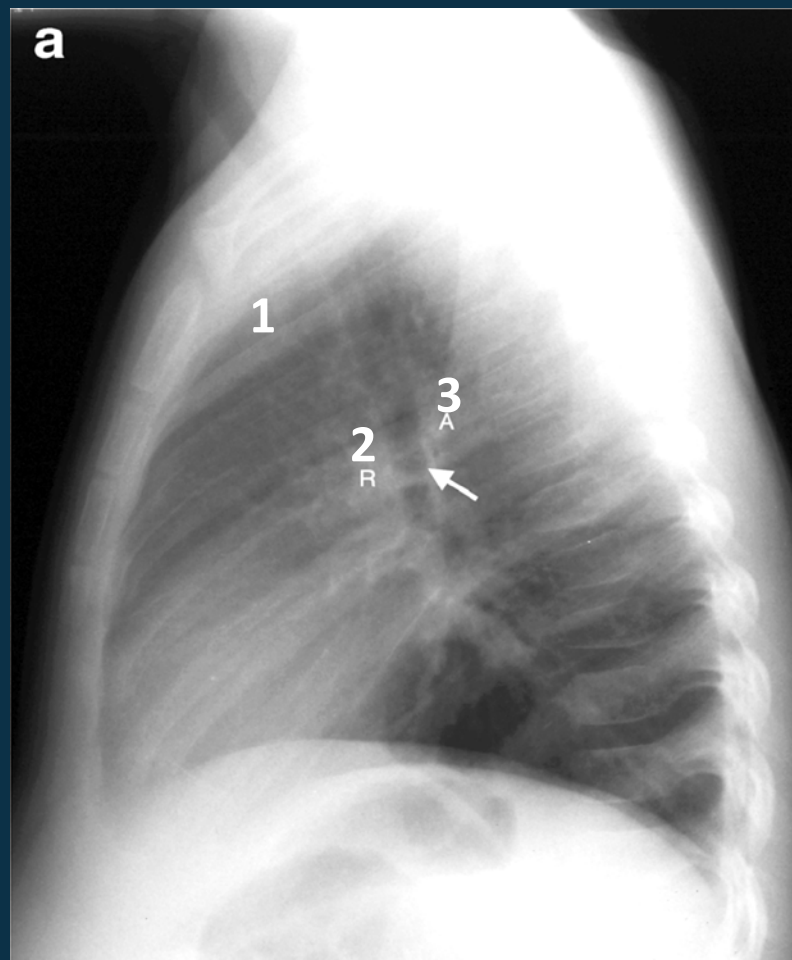
Describe what you see
on this lateral view :

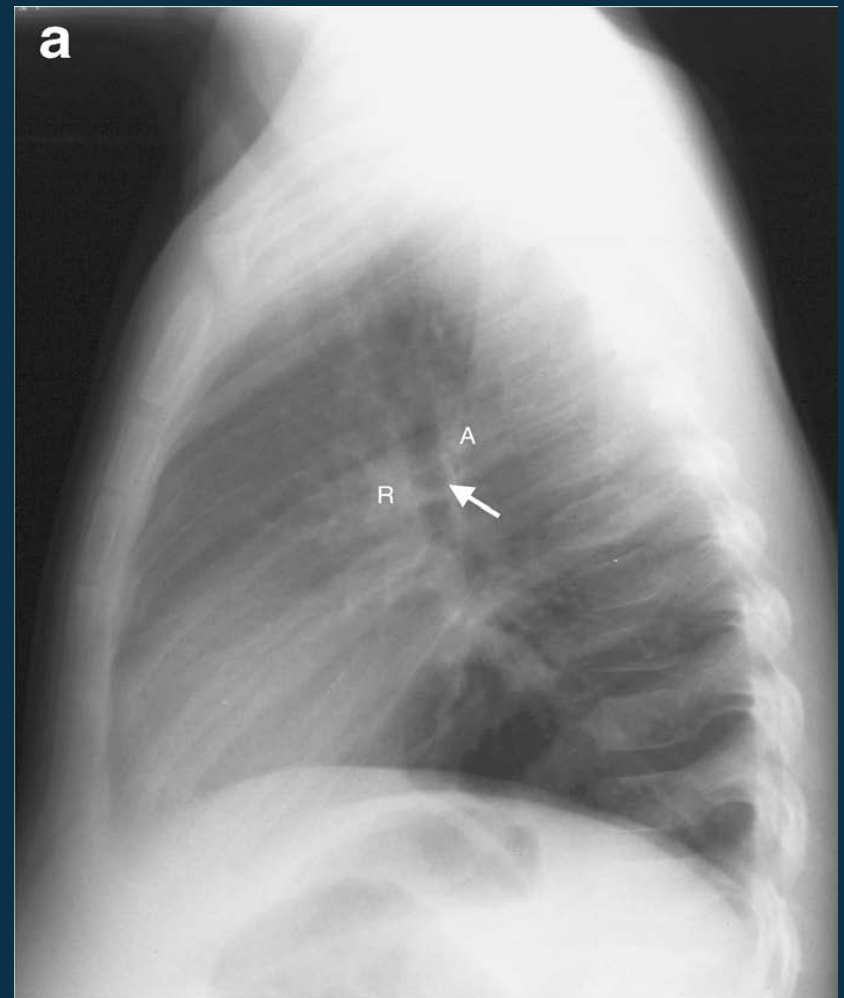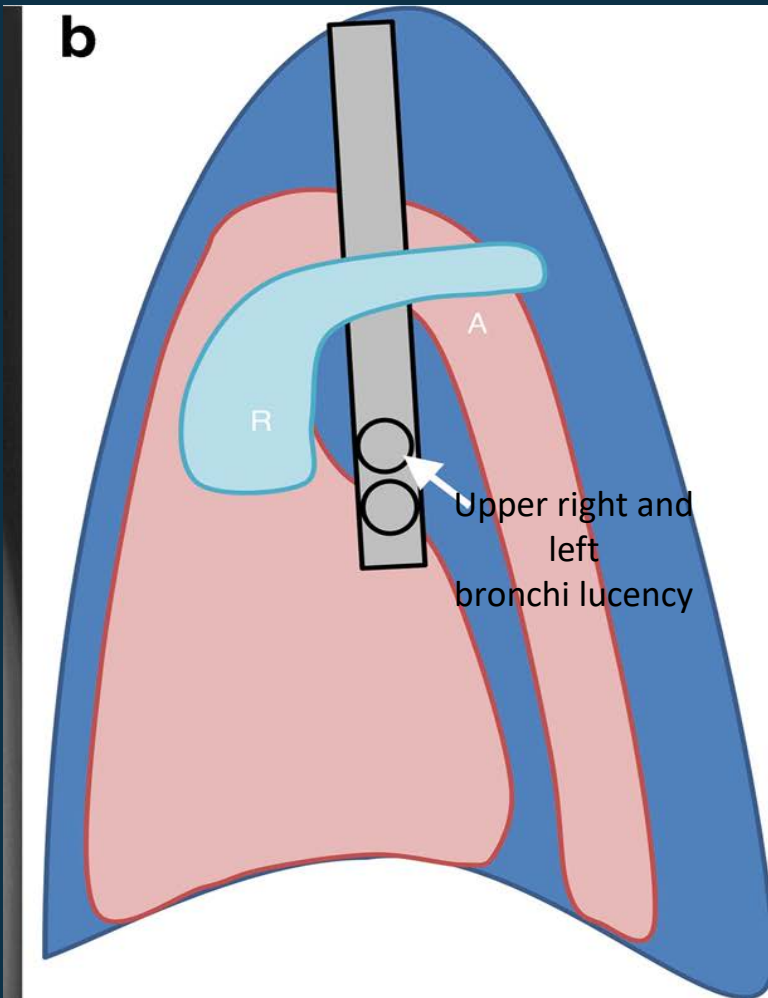
1. Retrosternal clear space
2. Right pulmonary artery
as soft tissue densities anterior
to the trachea
3. The aortic arch

Any sign of lymph nodes ?
. No

So this is.....

Normal lateral chest radiograph in a 6-year-old girl





Normal lateral chest radiograph in a 6-year-old girl. The pulmonary arteries and aortic arch surround the inferior part of trachea (just above the right upper lobe bronchus ↗ ...first oval lucency ↗)

Describe what you see on this lateral view

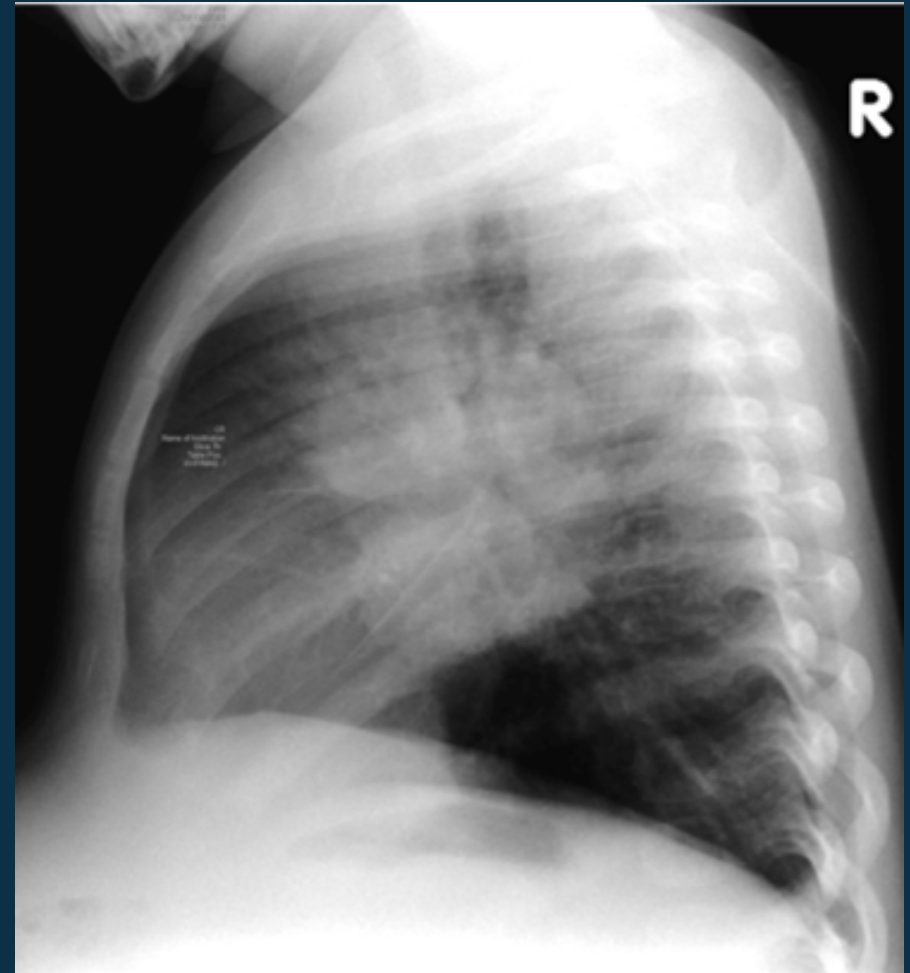
- . Retro sternal clear space
- . Diaphragms
- You can see both right and left
- . The hilar area

Can you see the right pulmonary artery?

- . No

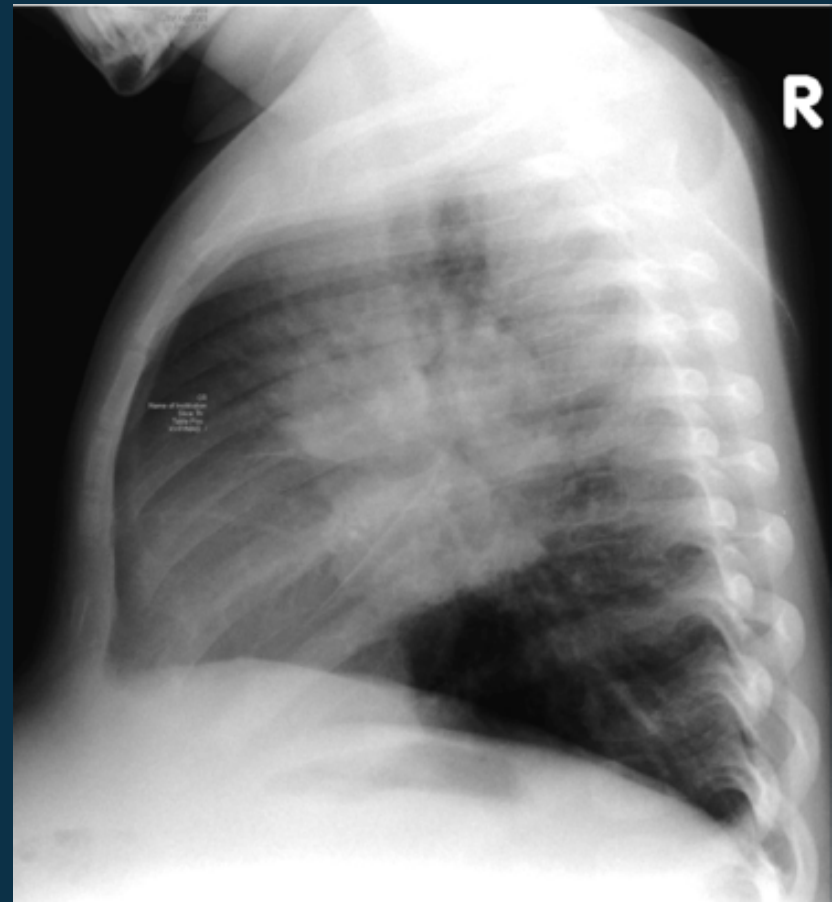
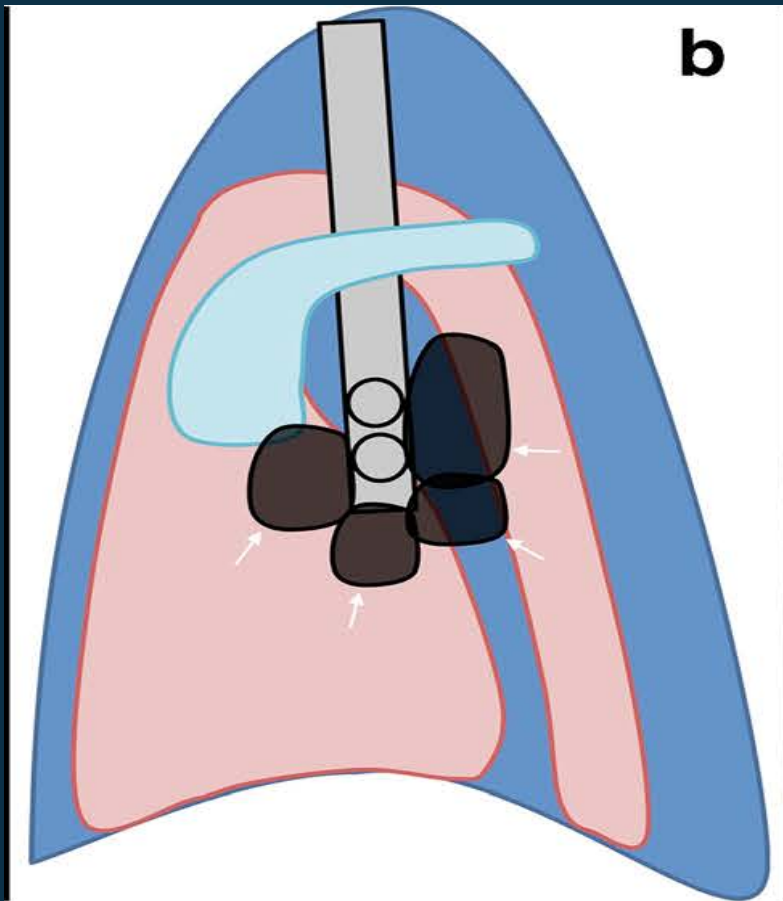
What do you see?

- . Lobulated mass-like densities posterior and inferior to the bronchus intermedius

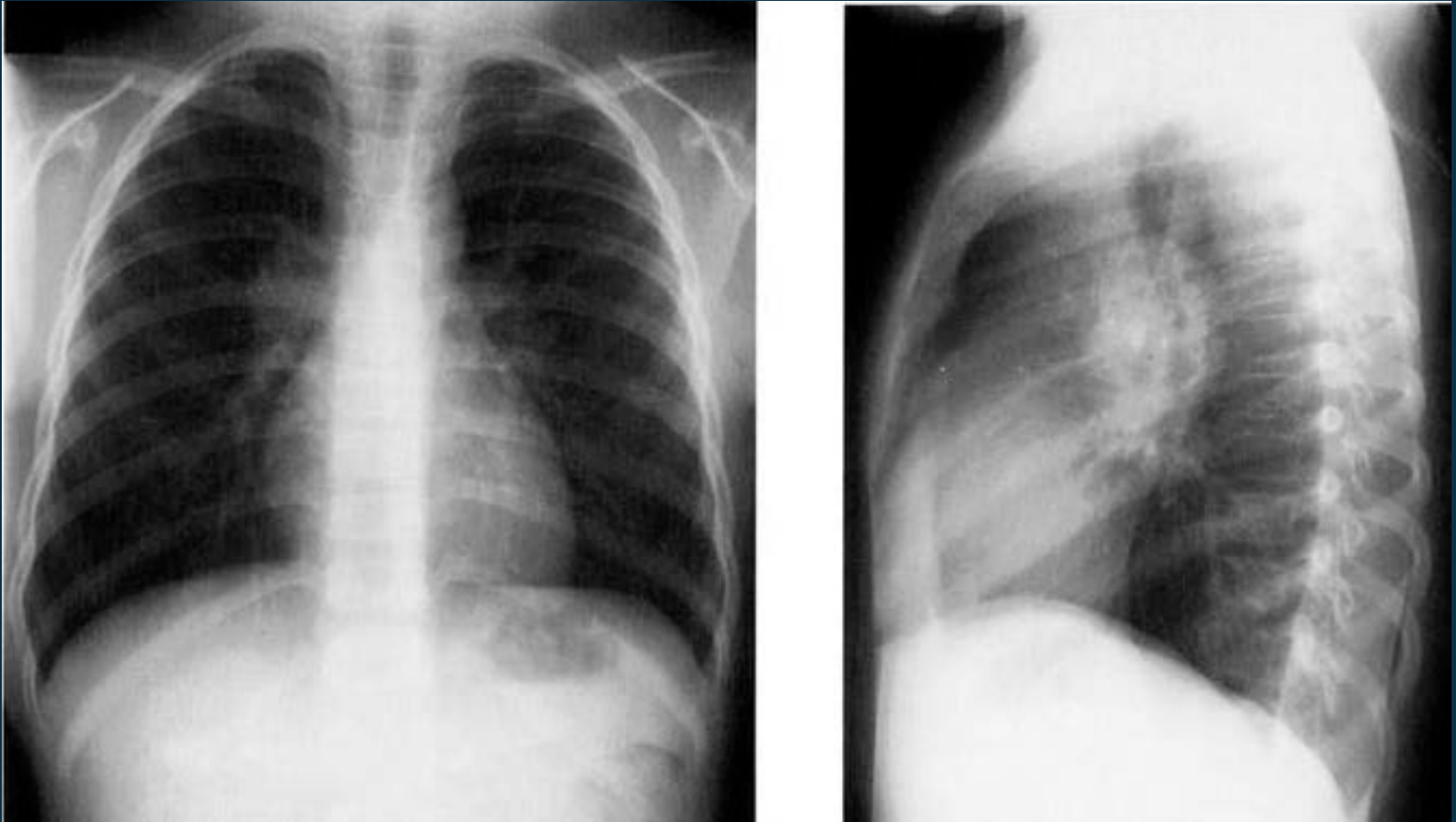


So it is

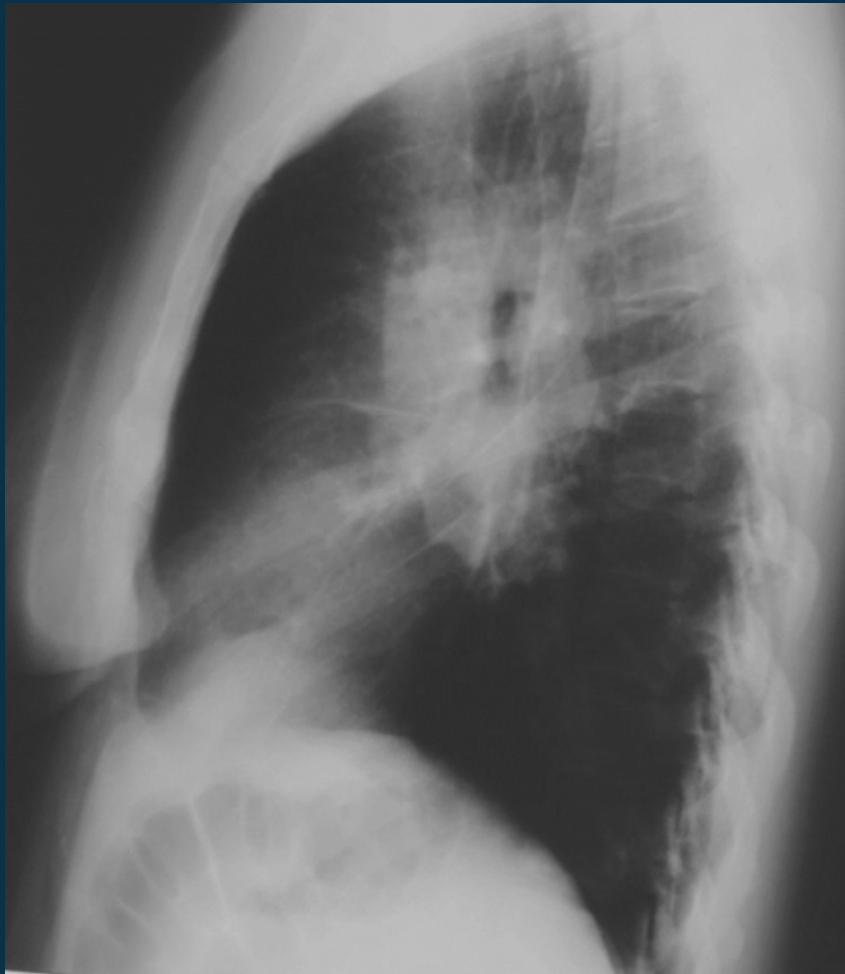Enlarged TB sub-carinal and retro-carinal lymph nodes



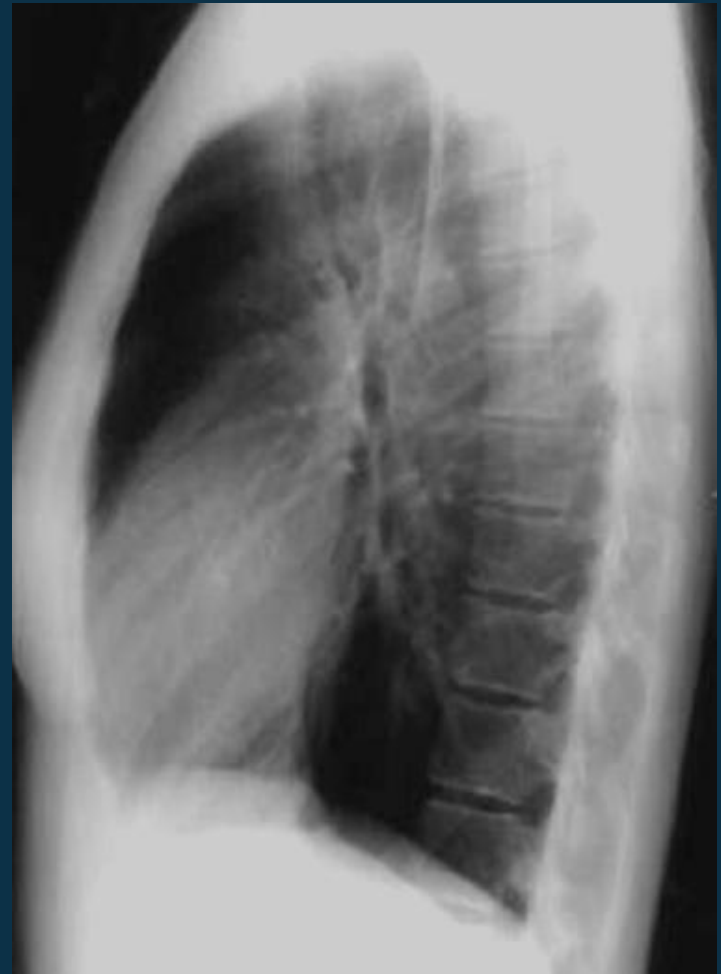Lobulated, mass-like densities in the pre, sub, and retro-carinal regions posterior and inferior to the bronchus intermedius = TB lymphadenopathy.



Lateral view is useful to assess
for enlargement of hilar lymph nodes



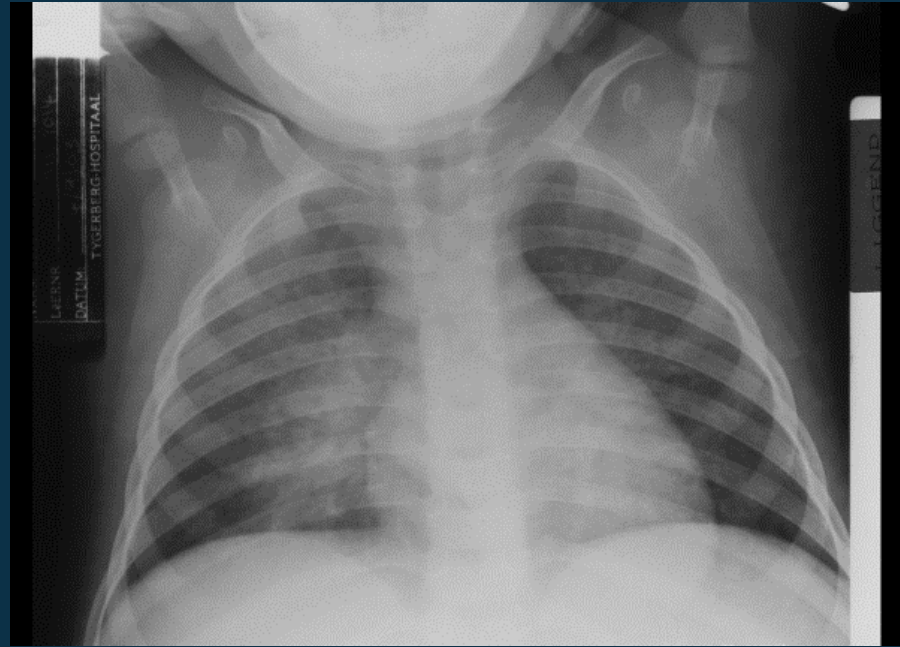
Lateral view is useful to assess for enlargement of hilar lymph nodes in sub-carinal and inter trachea bronchial areas



Normal lateral view

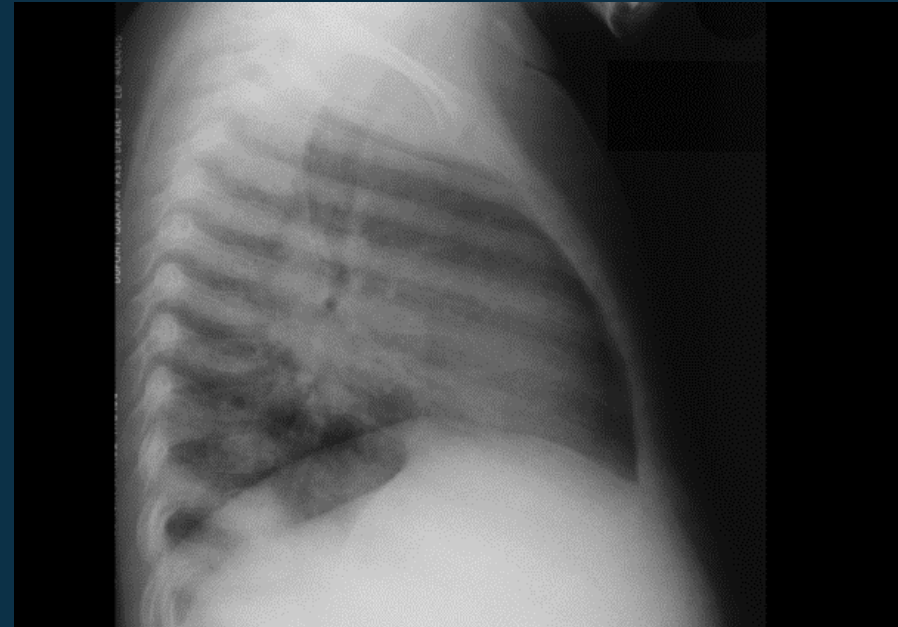
What do you see on these CXRs ?

- Right peri-hilar lymph node enlargement with surrounding opacities



What is your diagnosis ?

TB lymphadenopathy with pulmonary involvement



What do you see on this CXR ?

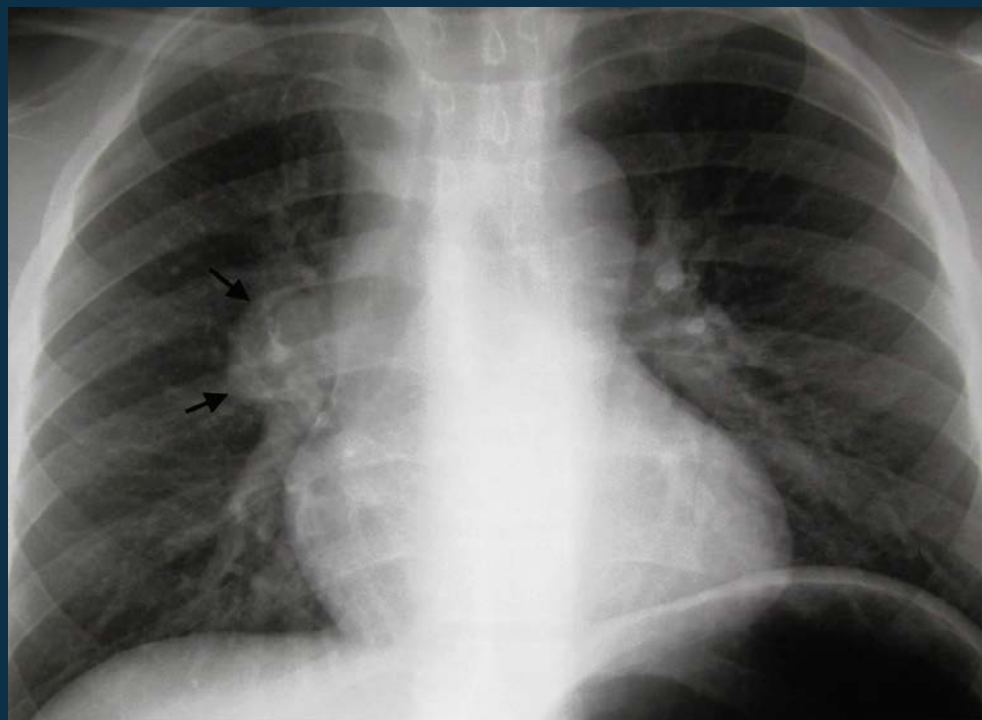
- . Lobulated soft tissue density mass

Where?

- . Right hilar region

Describe the external edge ?

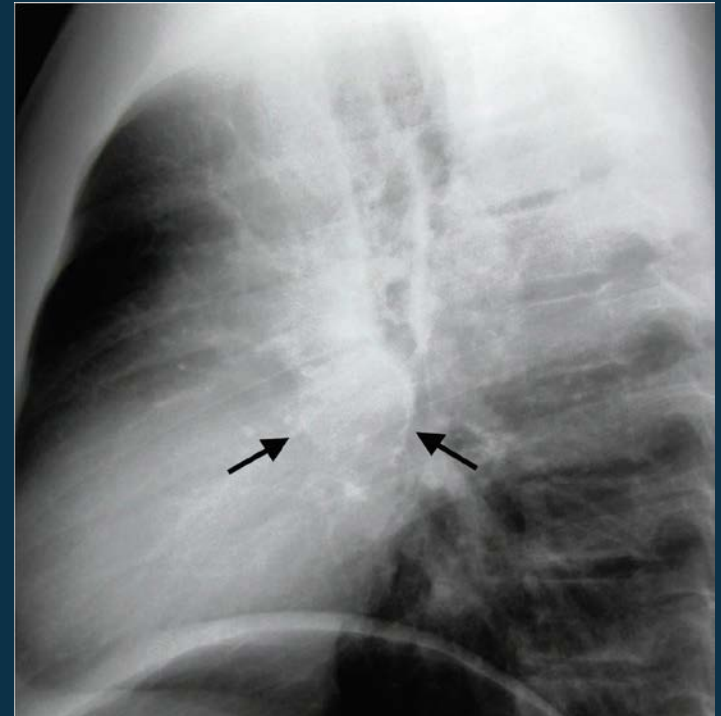
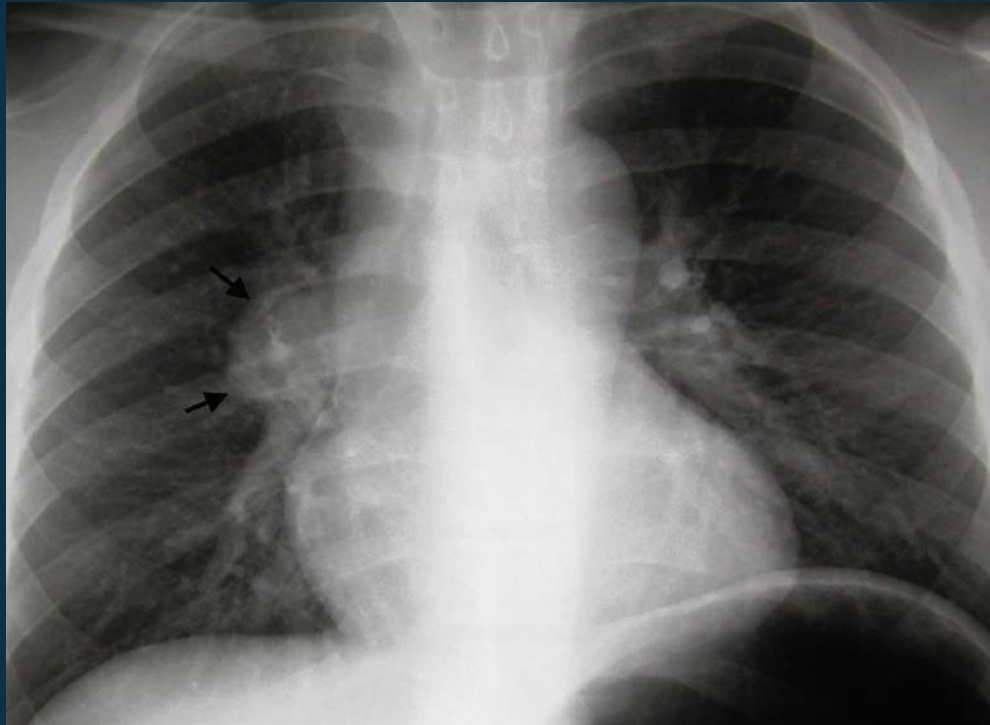
- . Convex



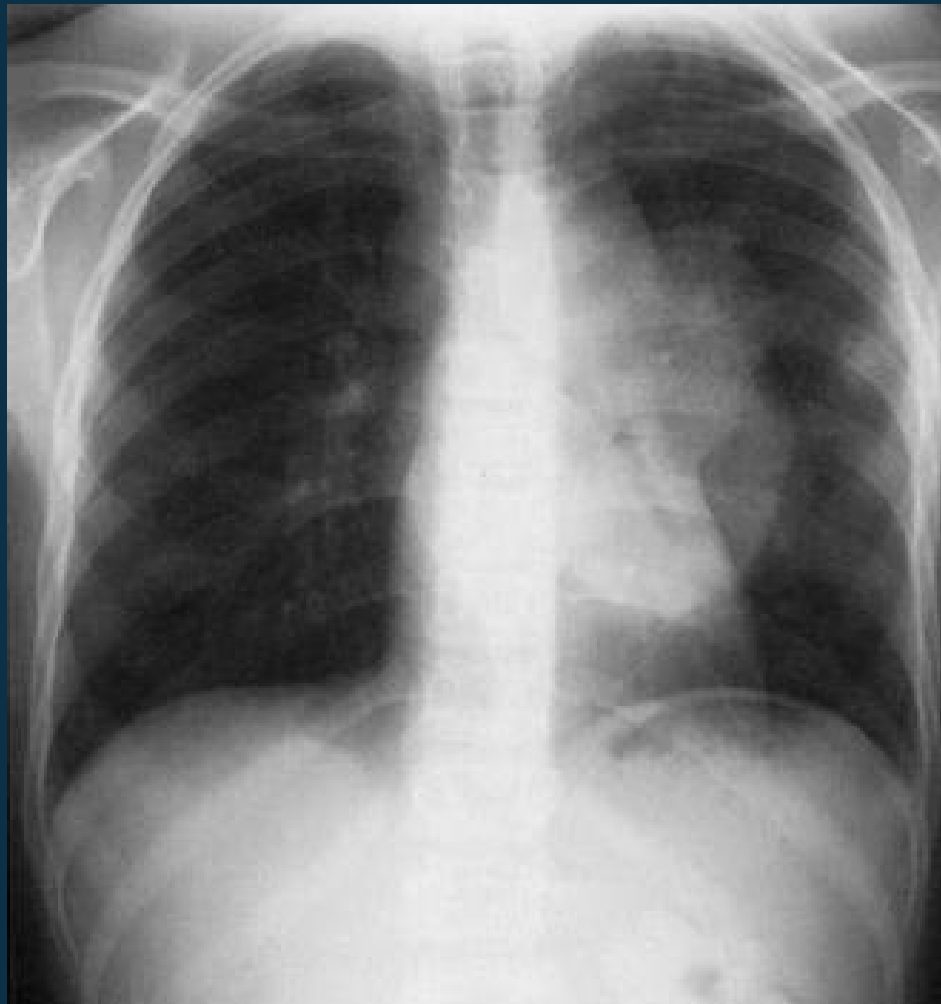What is your diagnosis ?

Enlarged right hilar lymph node

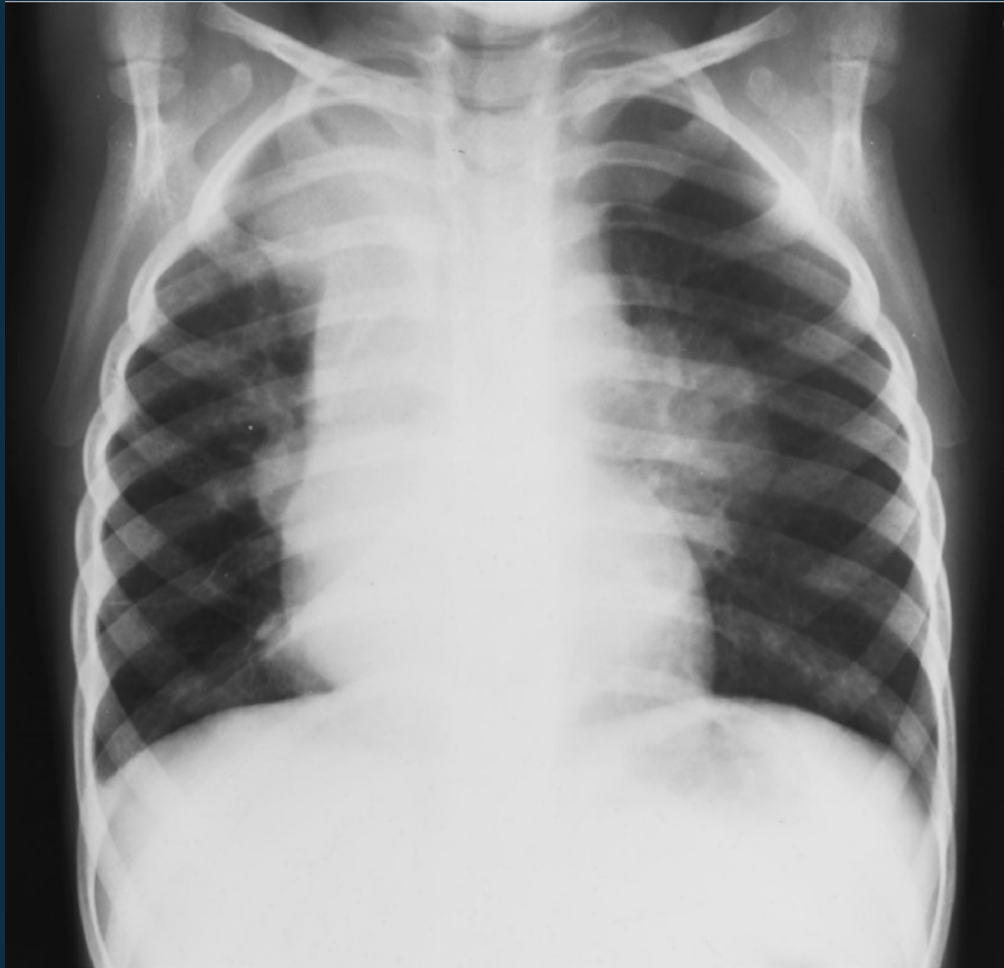What could you ask for to confirm?



Lateral view : hilar lymphadenopathy.
Round lymph node visible at the lower
margin of the hilar area (arrows)..



Bulky lymph node involvement which can be observed in HIV infected children.
Confusion with lymphoma is possible



Bulky lymph node involvement which can be observed in HIV infected children.

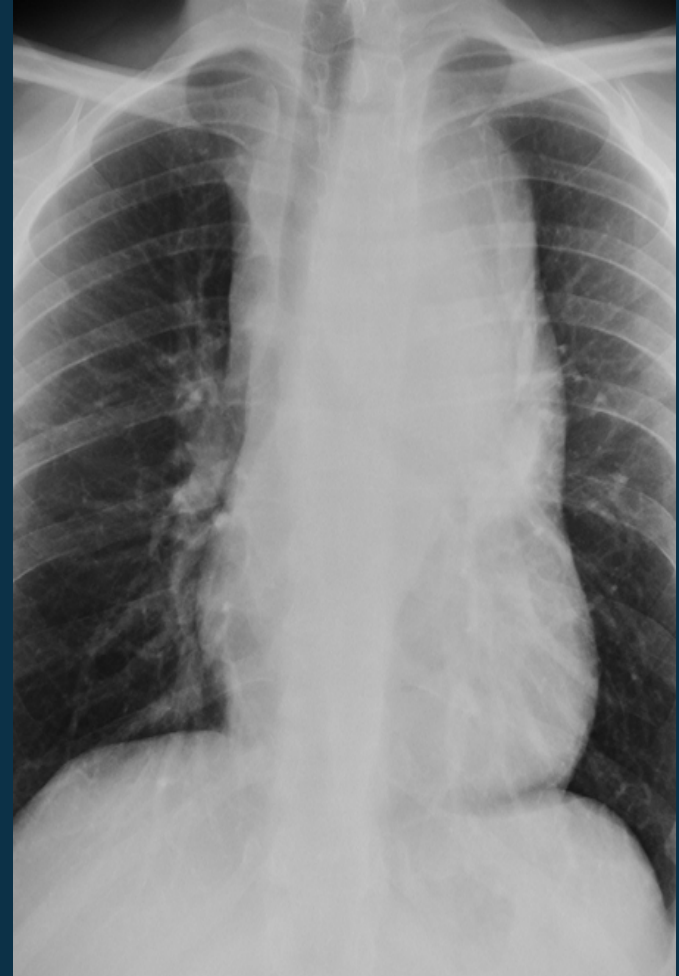Confusion with hematologic diseases (Hodgkins lymphoma) is possible

About TB lymphadenopathy

1. The most frequent radiological image
2. Hallmark of primary infection in children
3. May be the only abnormal finding to support the diagnosis of TB
4. Children are often asymptomatic and respiratory samples are smear and GeneXpert negative
5. Usually unilateral, sometimes bilateral
6. Hilar enlargement
7. Lateral view is of major importance

The most frequent mediastinal mass is a lymph node

The most frequent aetiology of enlarged mediastinal lymph nodes in high TB incidence countries is TB

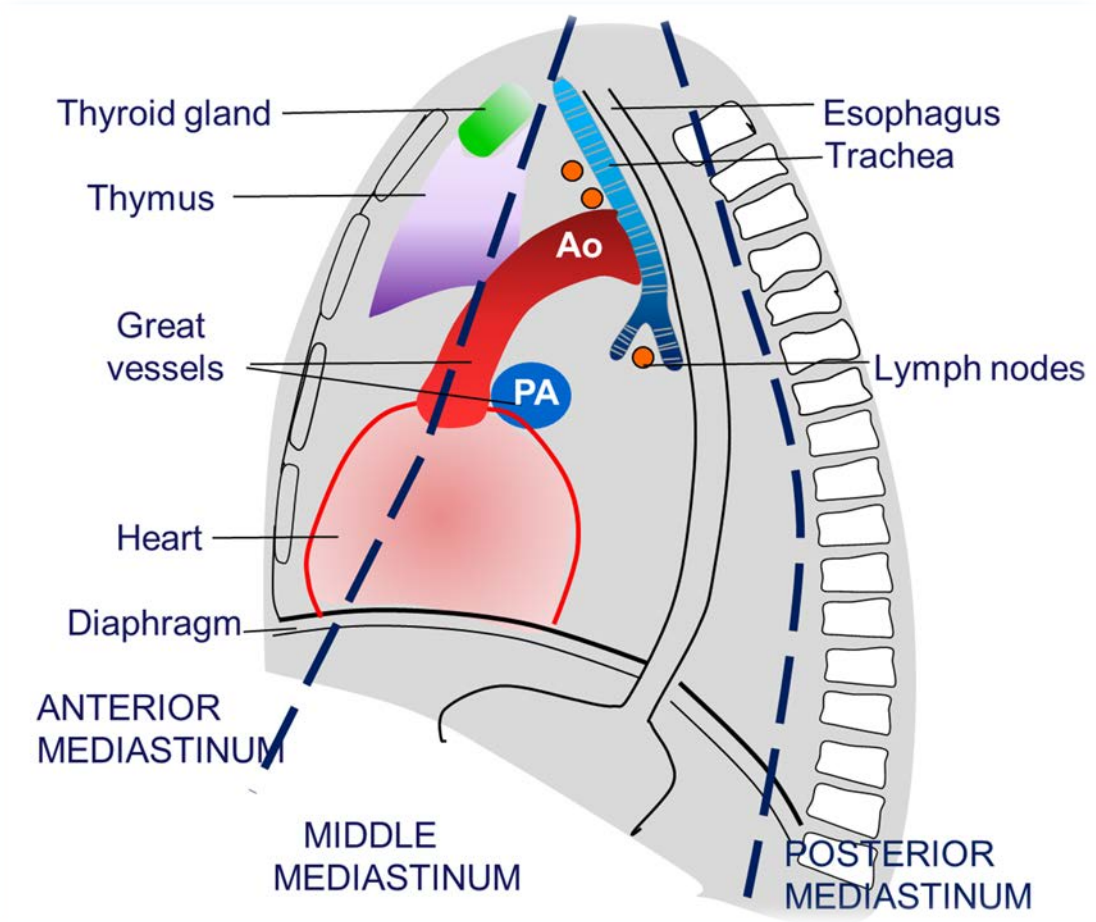


Enlarged lymph nodes

Differential diagnosis

Lymph nodes can be confused with other mediastinal masses

Anterior mediastinum **thymus**



Middle mediastinum TB lymph nodes and lymphoma

What do you see on this CXR ?

What do you see ?

- . Opacity on the right hemithorax

Is it anterior or posterior ?

- . Anterior

Why ?

- . Obscures the right border of the heart

Is it compressive ?

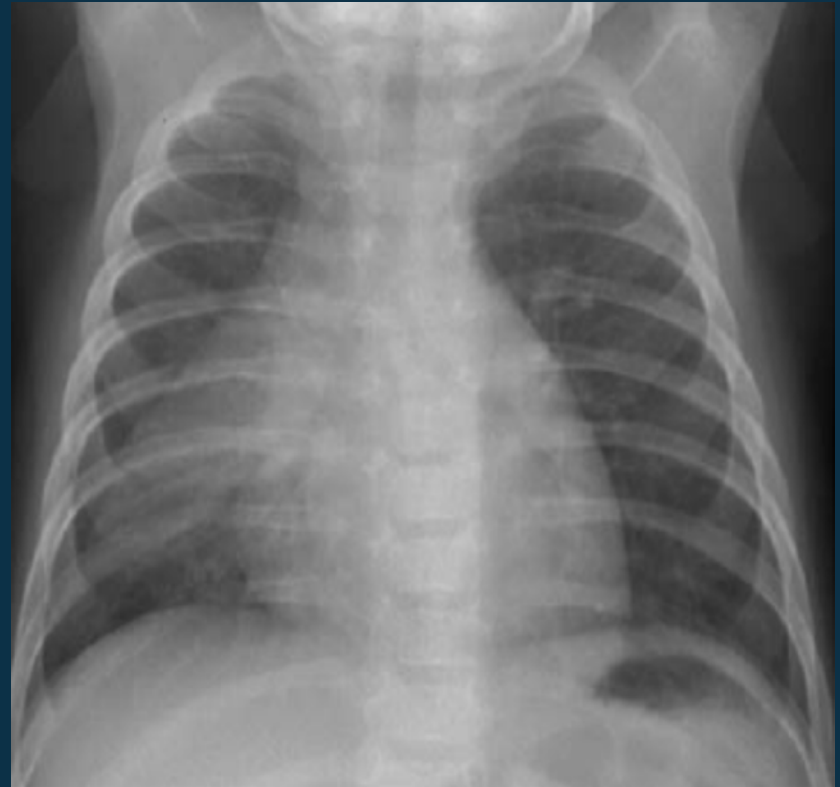- . No

Can you see through it ?

- . Yes

So it is

Soft tissue density mass



What is your diagnosis ?

Asymmetric hypertrophy of the right lobe of the thymus

What do you see on this CXR ?

- . Triangular opacity on the upper right hemithorax

Is it anterior or posterior ?

- . Anterior

Why ?

- . Obscures the right border of the heart

Is it compressive ?

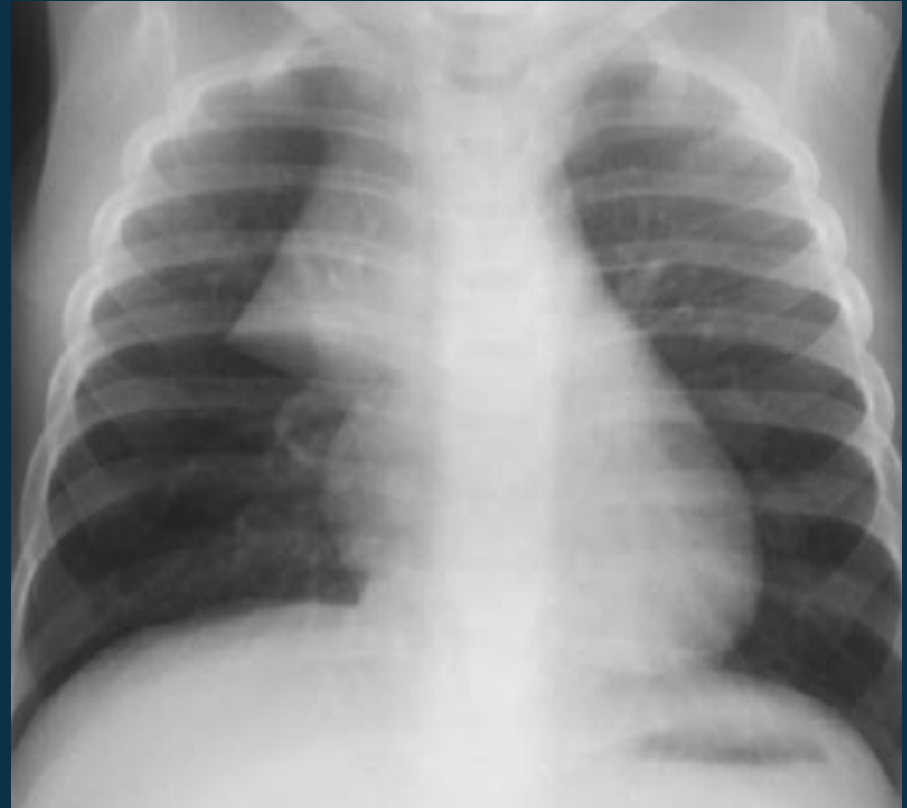- . No

Can you see through it ?

- . Yes

So it is

A triangular soft tissue density mass



What is your diagnosis ?

Thymus: 'sail sign'

(triangular appearance, hypertrophy of the right lobe angular corner flattened at the right minor fissure)

What do you see on this CXR ?

- . Wavy opacity in the left hemithorax
-it moulds to the ribs

Is it anterior or posterior ?

- . Anterior

Why ?

- . Obscures the left border of the heart

Is it compressive ?

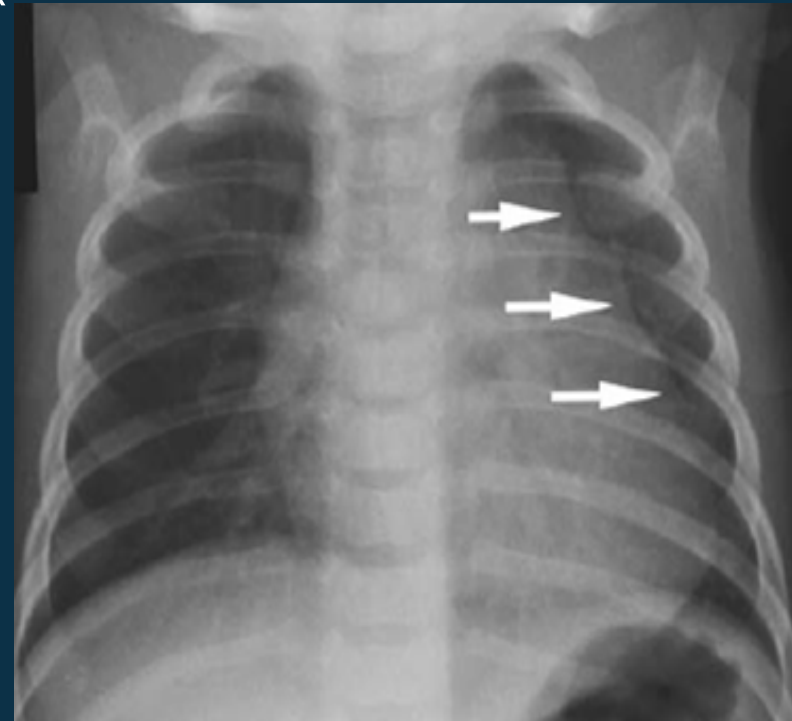
- . No

Can you see through it ?

- . Yes

So it is

**A wavy soft tissue
density mass**



What is your diagnosis ?

Thymus:

**'wave' or 'ripple' sign.
Undulating appearance
of the left margin of the
thymus**

What do you see on this CXR ?

. An opacity contiguous to the heart

Is it anterior or posterior ?

. Anterior

Why ?

. Obscures the borders of the heart

Is it compressive ?

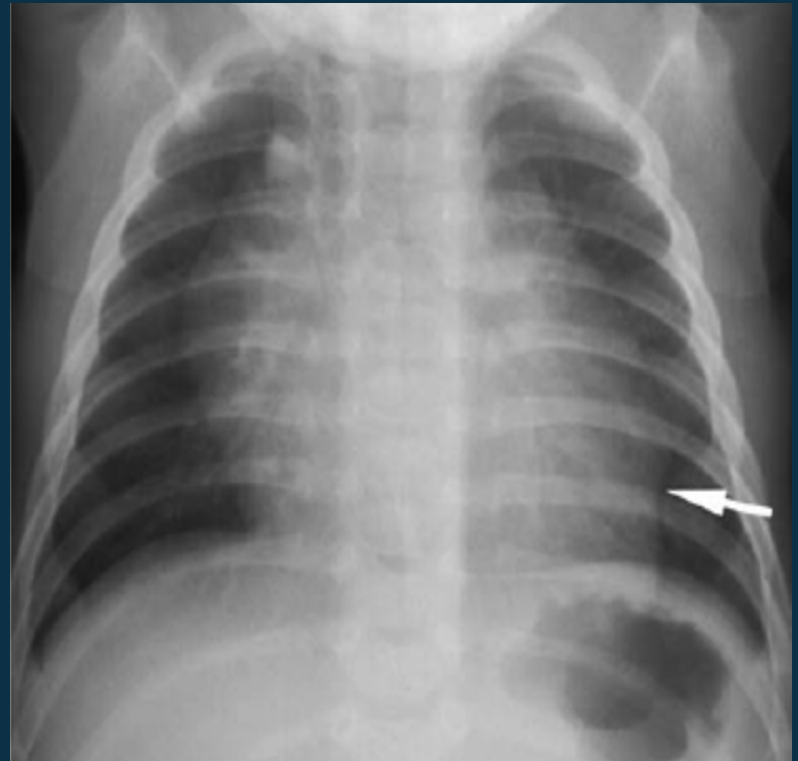
. No

Can you see through it ?

. Yes

So it is

**A huge soft tissue
density mass**



What is your diagnosis ?

**Thymus: 'notch' sign :
cardiothymic incisure**
(small indentation between the
inferior border of the left lobe
of the thymus and the heart)

What do you see on this CXR ?

. A right peri-hilar opacity

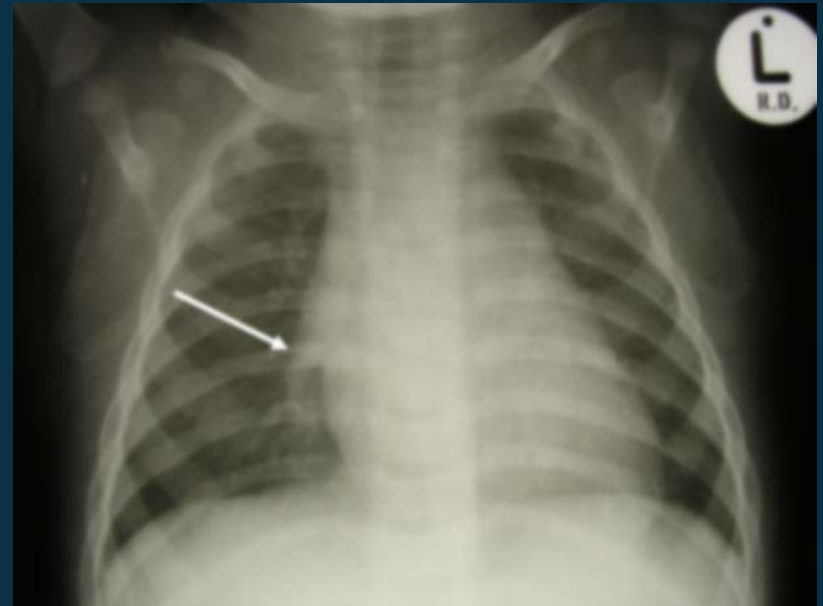Is it anterior or posterior ?

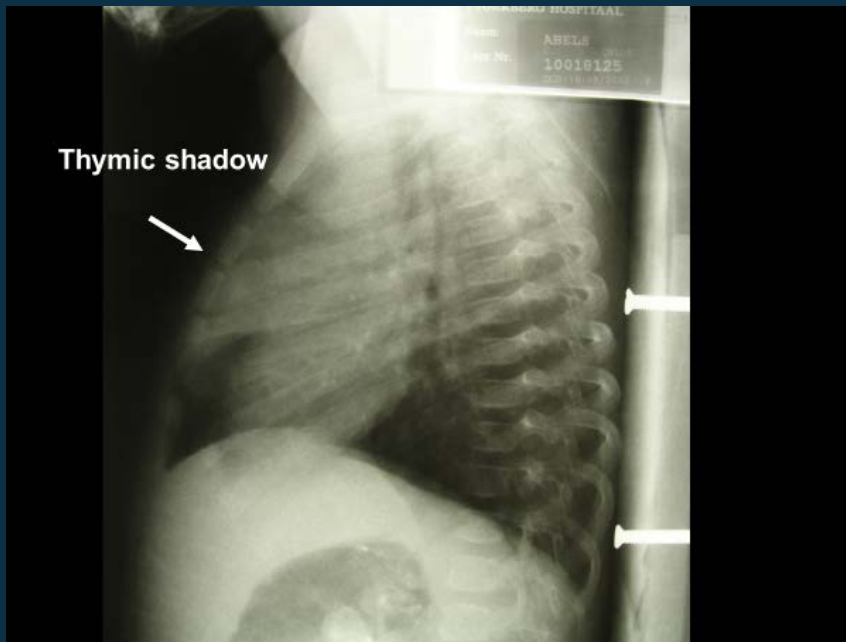
. Anterior

Why ?

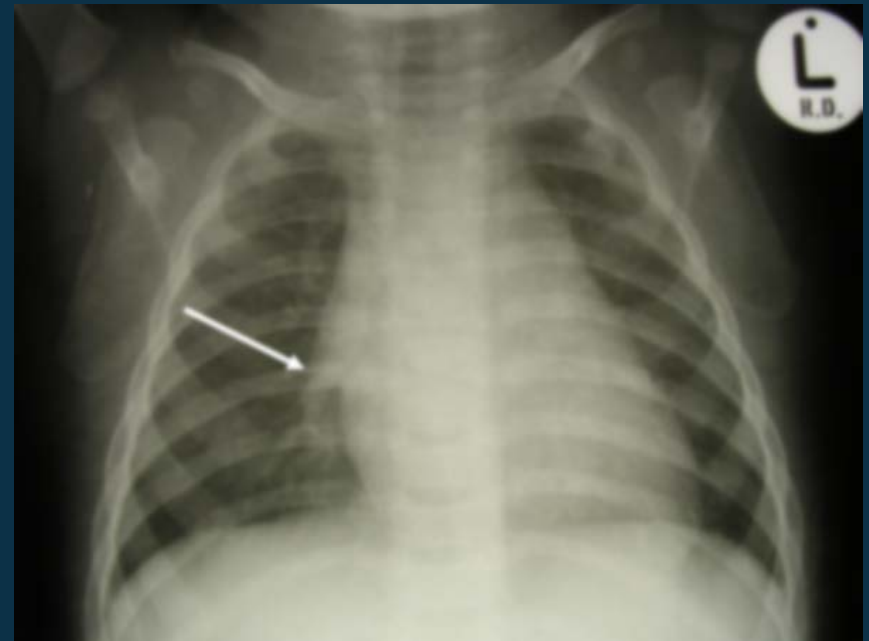. Obscures the border of the heart

What could you request
if you are not sure ?





A lateral view



What is your diagnosis ?

Thymus:

Retro-sternal clear space is filled

What do you see on this CXR ?

How is the trachea ?

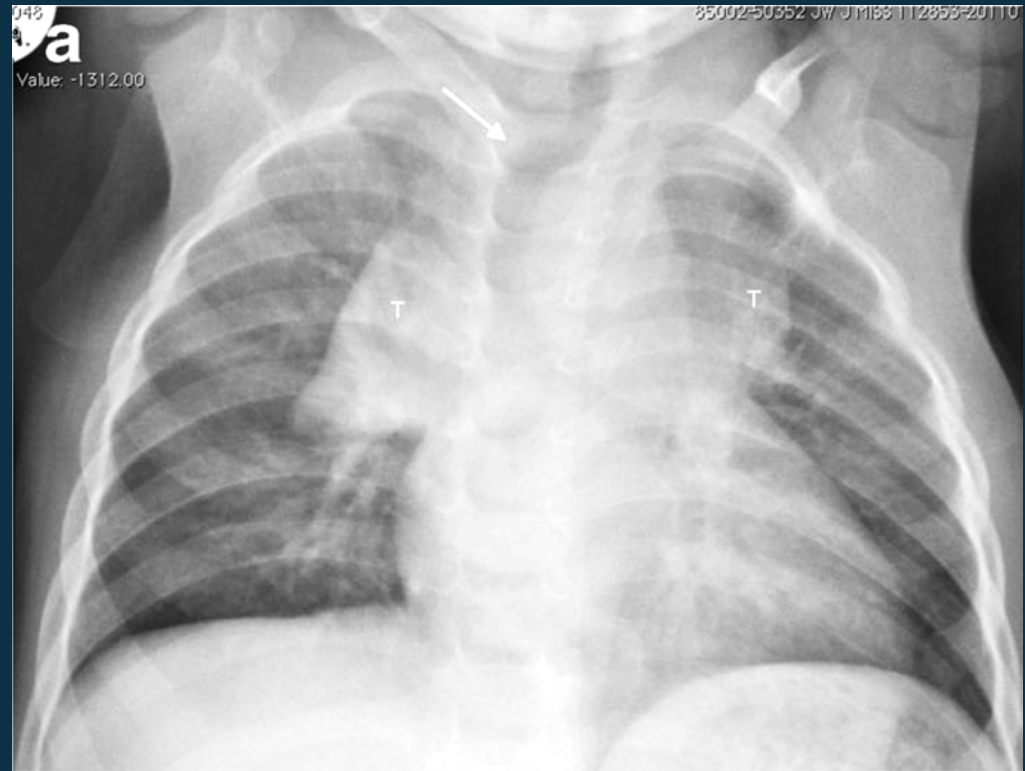- . Physiological buckling

How is the mediastinum ?

- . Widened
- . With a large opacity

Is it anterior or posterior ?

- . Anterior

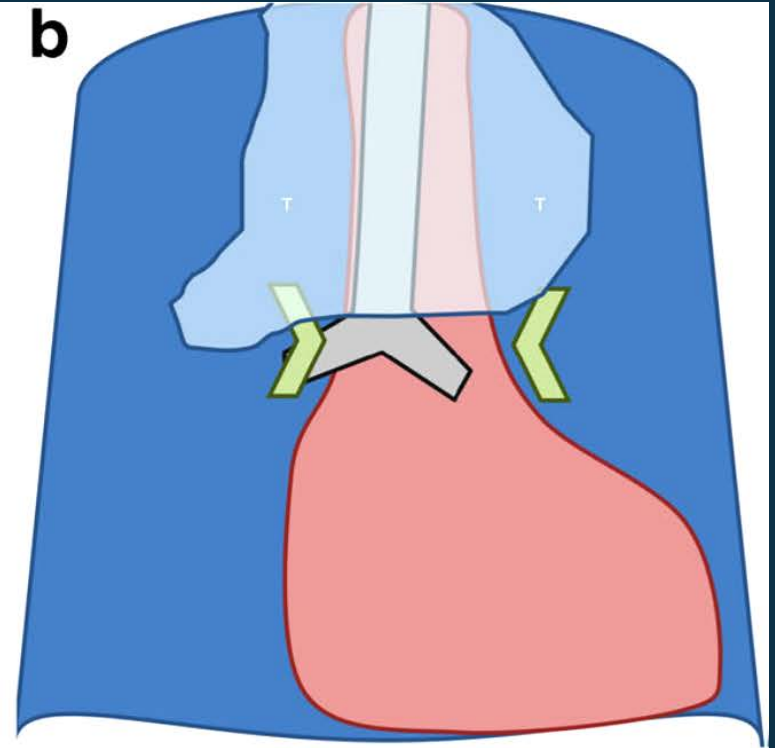
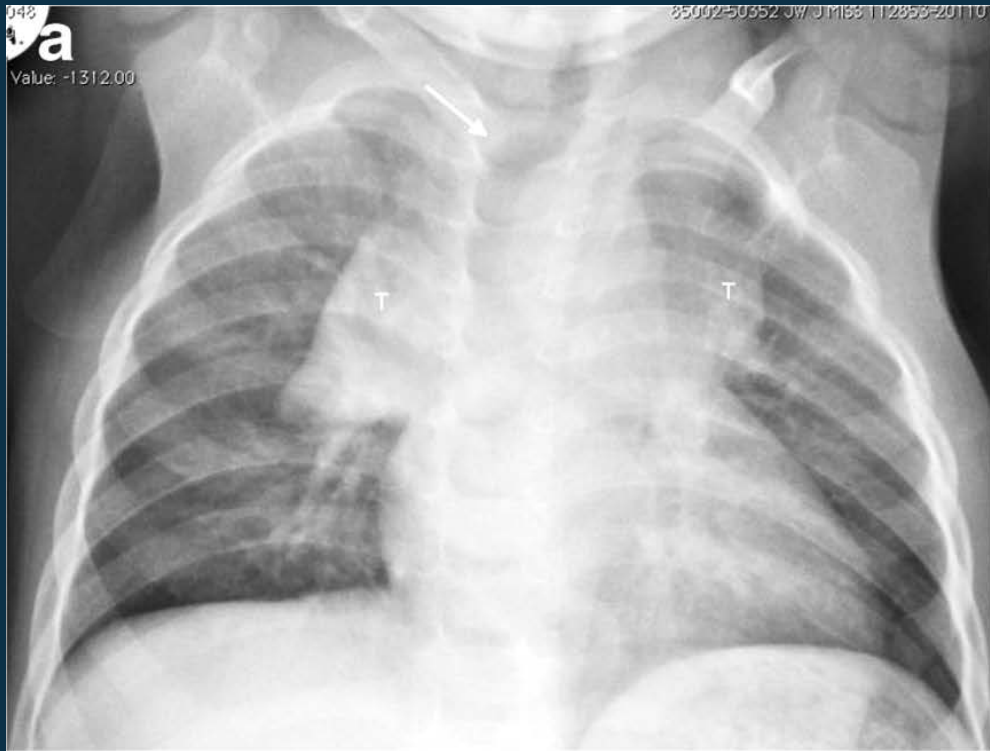

What is your diagnosis ?

Thymus

Why ?

- . Obscures the borders of the heart



Normal chest radiography
in a 14-month-old girl.

Enlarged Lymph nodes – Differential diagnosis: thymus

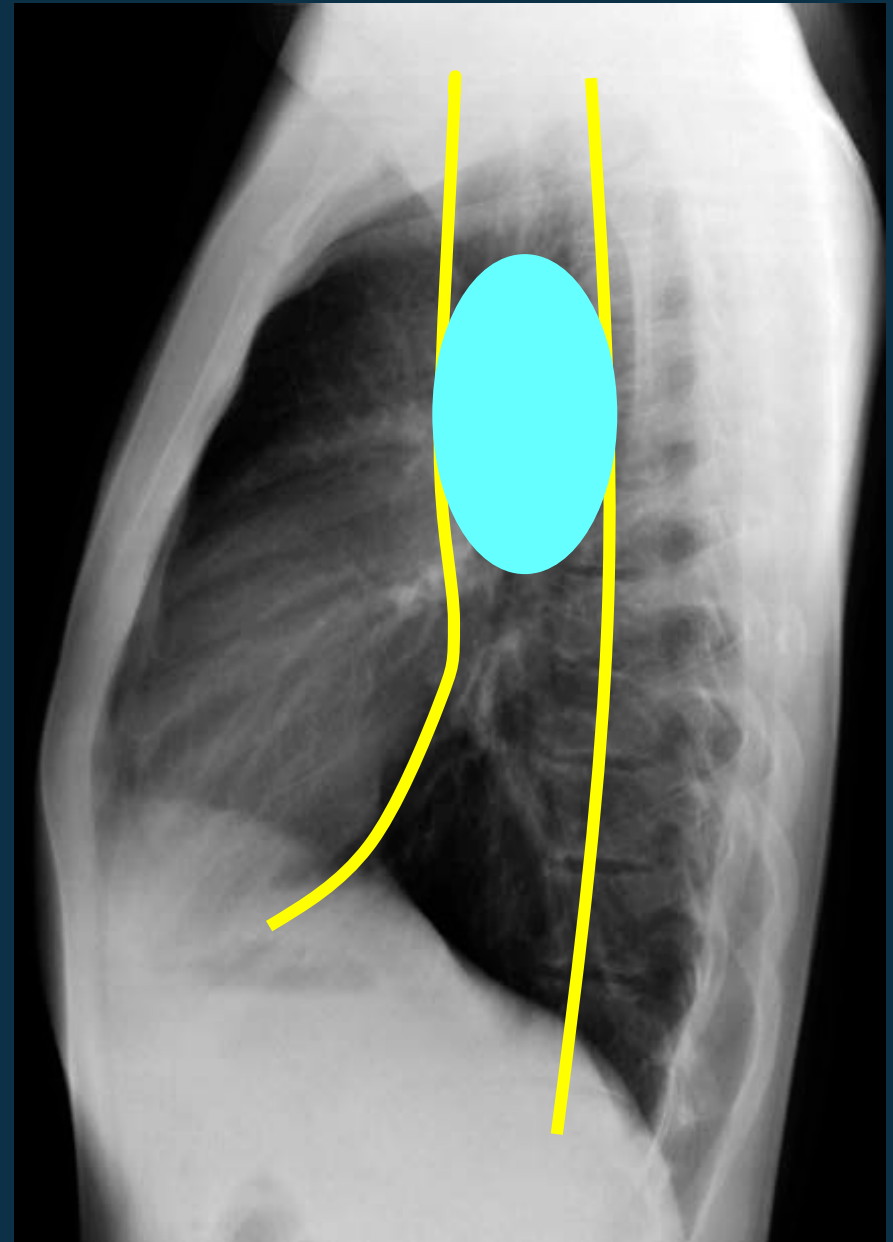
1. Thymus = a diagnosis of exclusion
2. Particularly visible before 2 years of age
3. Never compressive
4. Mobile with change of position
5. Change in size if inspiration or expiration
6. Various radiological appearances
7. Can cause confusion: can simulate cardiac enlargement, atelectasis, pulmonary infiltrates and mediastinal masses or enlarged lymph nodes

Middle mediastinal masses

Adenopathies

TB as first diagnosis

Lymphoma



What do you see on this X-ray ?

- . Widened mediastinum with convex bilateral opacities

Where is it located?

- . anterior mass

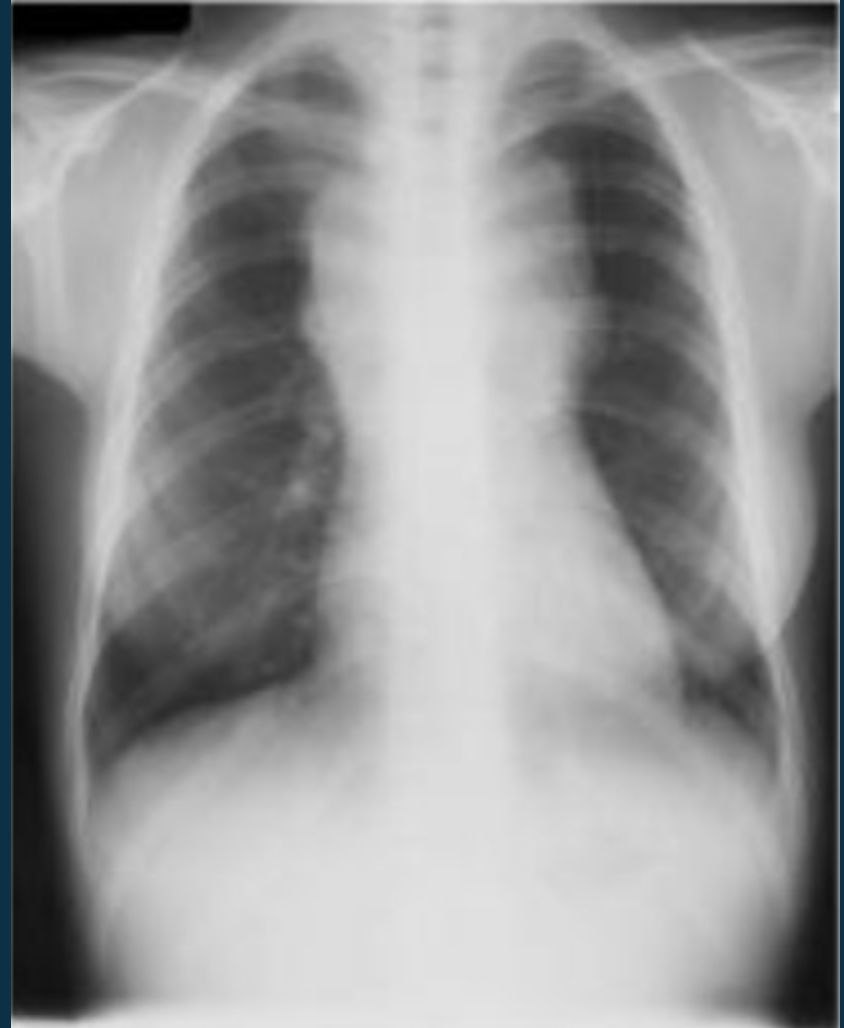Why ?

- . Obscures the heart borders

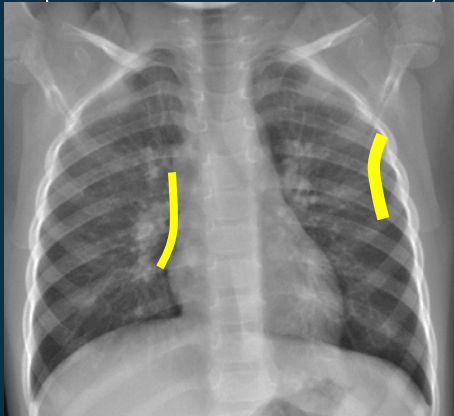
What is your diagnosis

Lymphoma

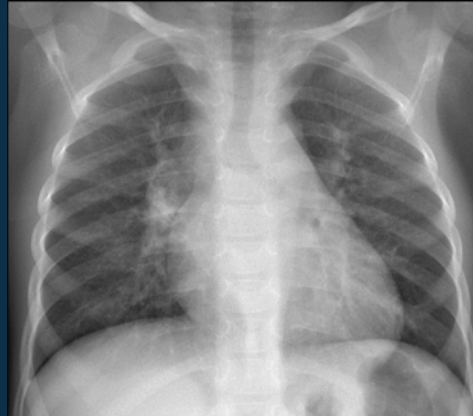16 year old girl with
cough and fever



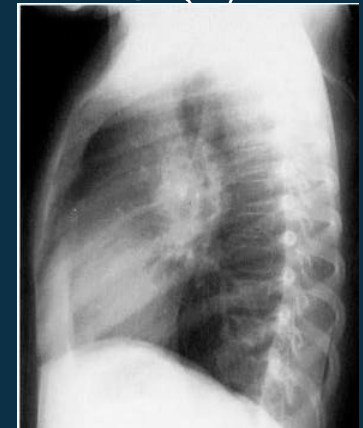Key points regarding enlarged lymph nodes



Normal

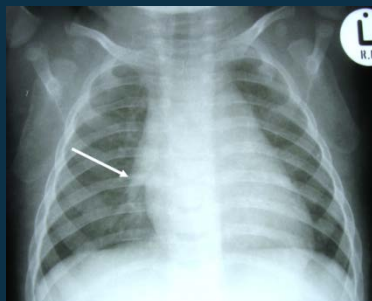

Suspected on front view

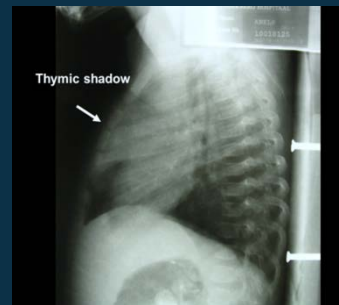

Confirmed on lateral view

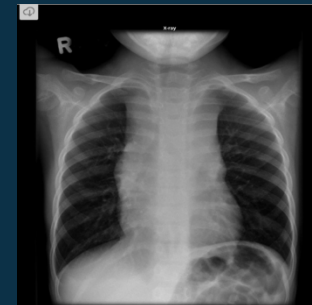
Beware of main differential diagnosis



Thymus



Lymphoma



Learning Objectives

Module 2: diagnose TB on a paediatric CXR using a simplified reading tool at PHC level

Chap1. Introduction

Chap2. Enlarged lymph nodes

Chap3. Alveolar opacity of the lung tissue

Chap4. Airways compression

Chap5. Cavitation

Chap6. Pleural or pericardial effusion

Chap7. Miliary

Chap8. Reading tool in a nutshell

What do you see on this CXR ?

- . First circle: normal
- . Second circle:
Lungs : What do you see ?
A right lung opacity
obscuring the right border
of the heart
- . Third circle : normal

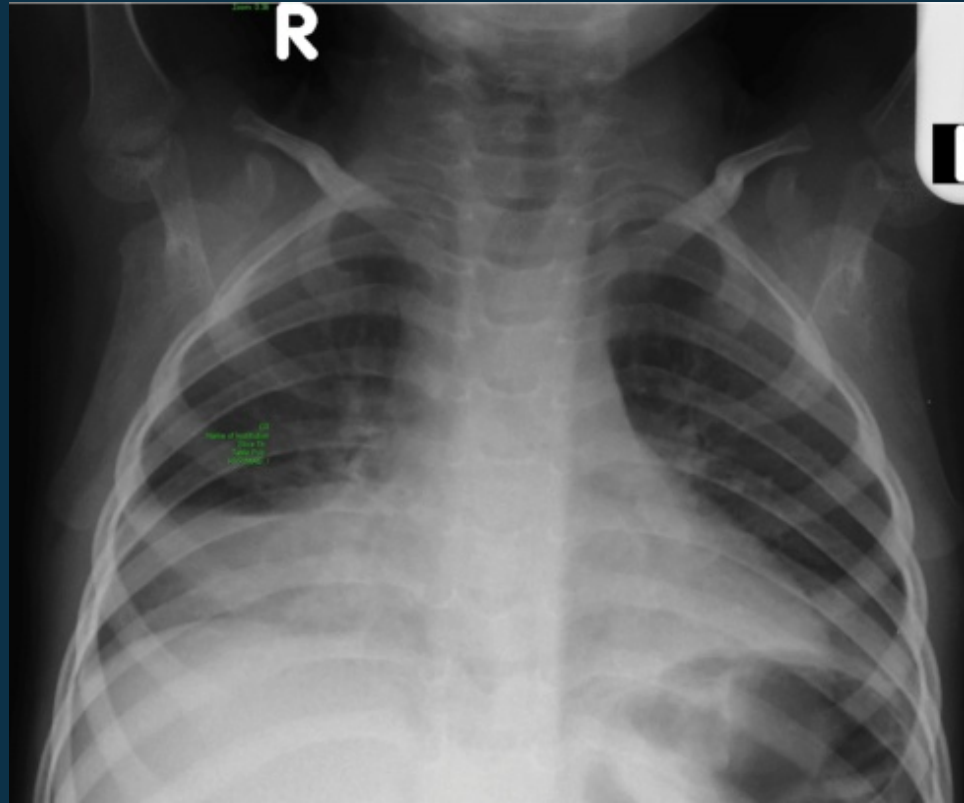
So it is

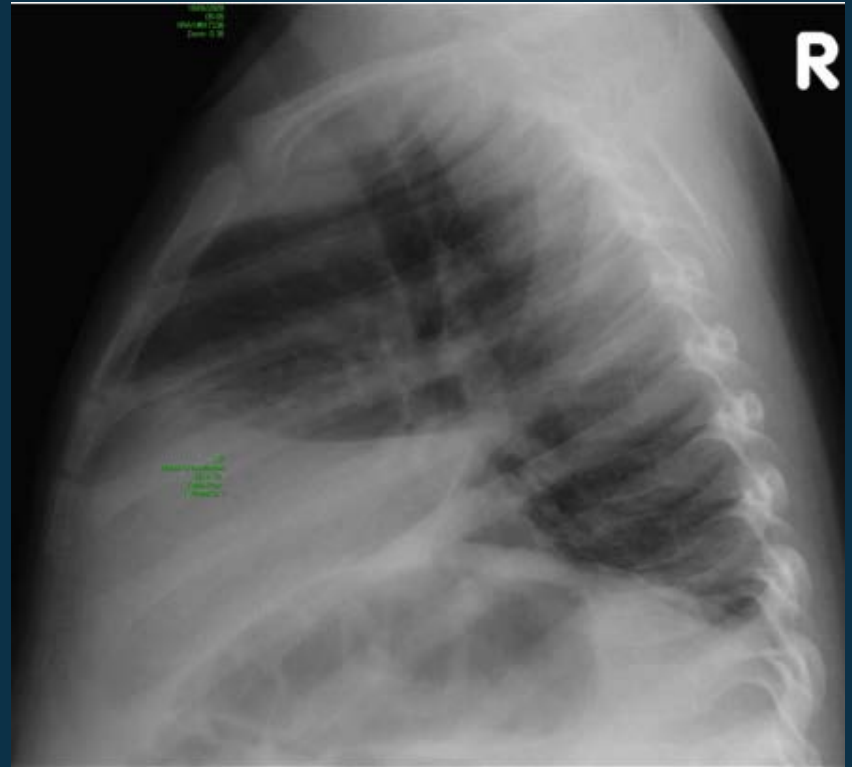
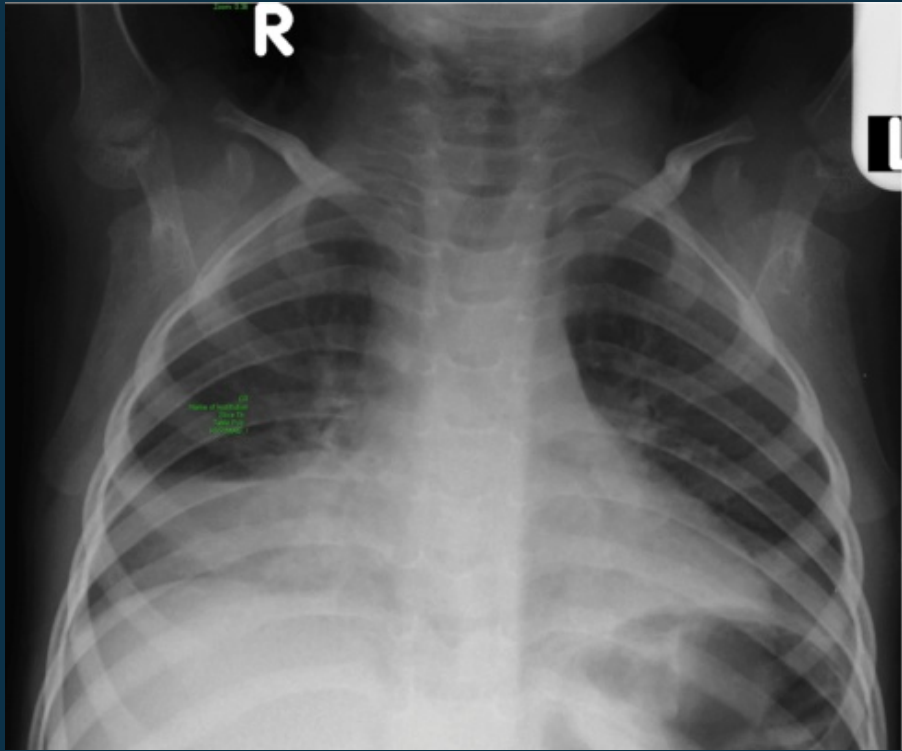
Pneumonia (middle lobe)

Is it TB ?

What should you request ?

- . a lateral view





Is it TB ?

- . Middle lobe pneumonia without lymphadenopathy:
Not Suggestive of TB
- . One should give a course of amoxicillin before considering TB treatment (if GeneXpert negative)

What do you see on this CXR ?

- . First circle: normal
- . Second circle:
Lungs :What do you see ?
A right lung opacity obscuring
the right border of the heart
(middle lobe)
- . Third circle : normal

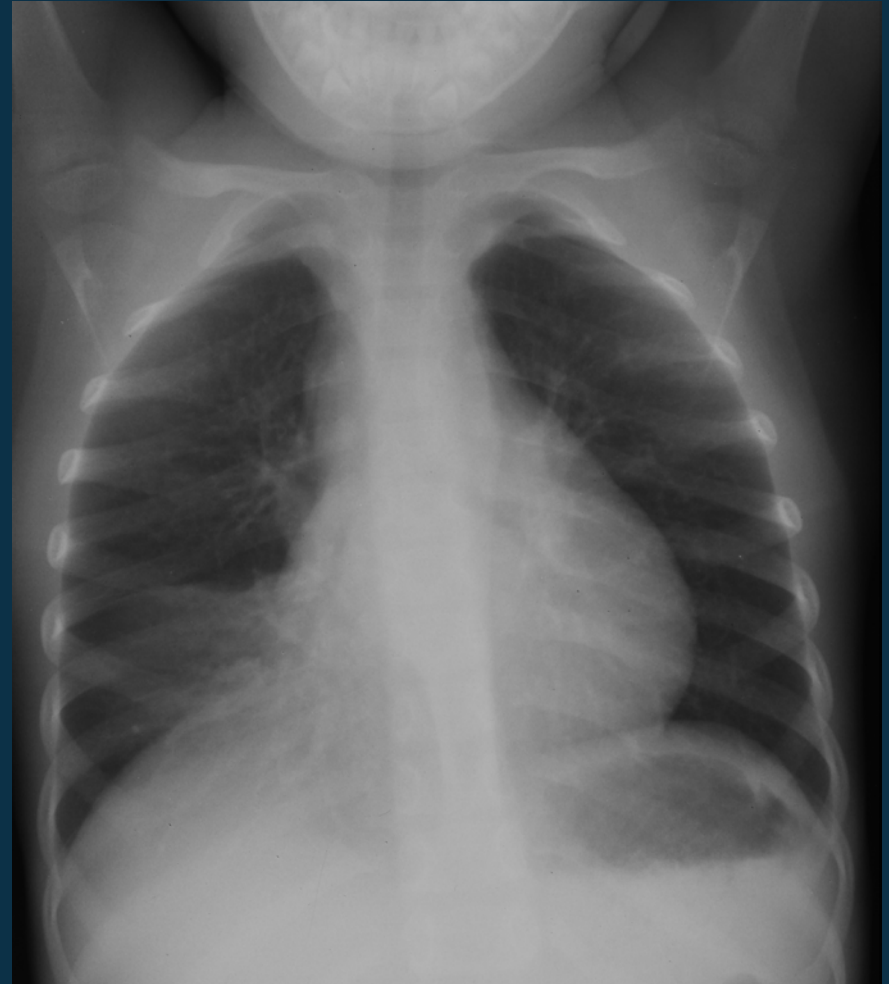So it is

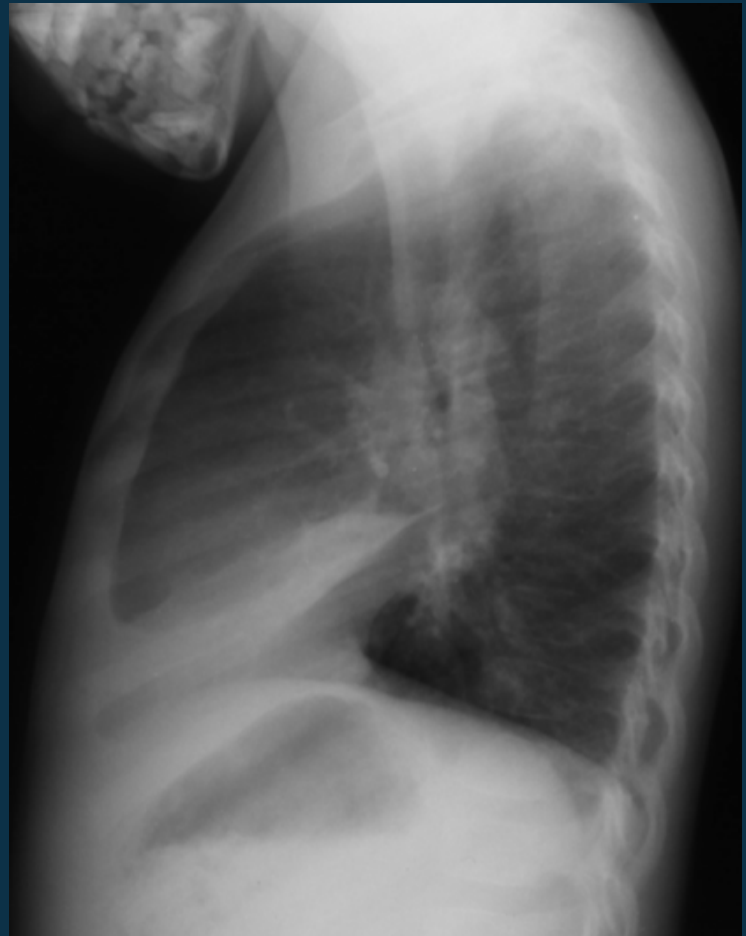
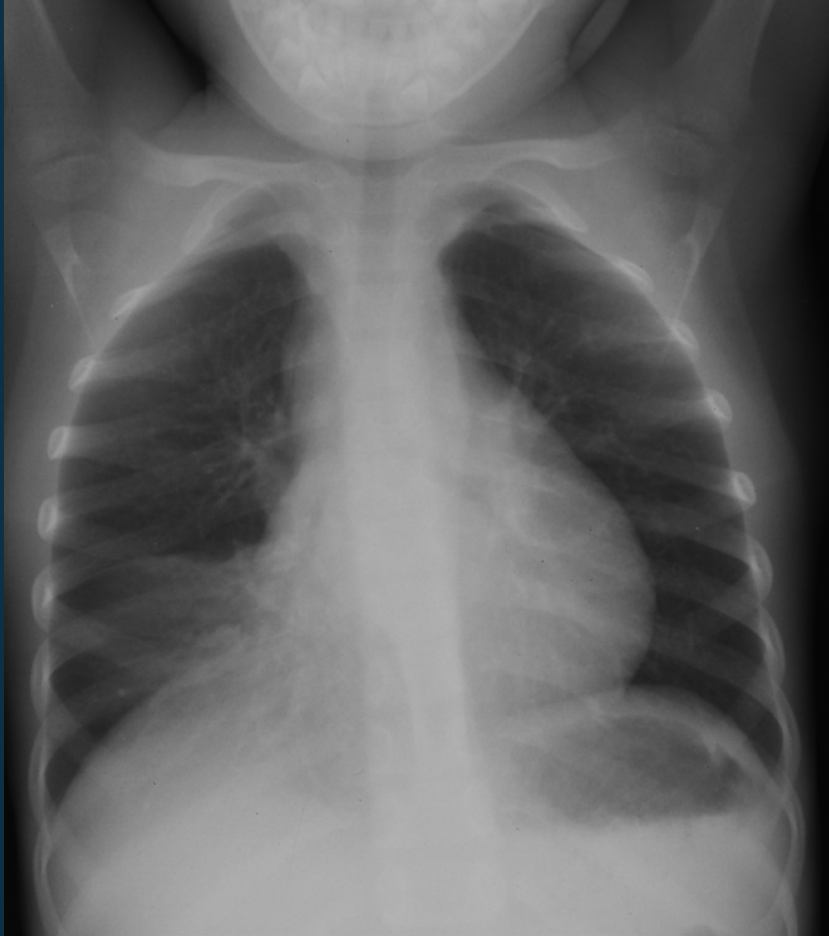Middle lobe pneumonia

Is it TB ?

What should you request ?

- . a lateral view





Is it TB ?

Middle lobe pneumonia associated with lymphadenopathy
= Suggestive of TB

What do you see on this CXR ?

- . First circle: normal
- . Second circle:
Lungs :What do you see ?
Right lung opacity in the upper zone
- . Third circle : normal

20 month old child
with fever, cough
and dyspnoea

Any tracheal deviation ?

- . No

Any airway compression ?

- . No

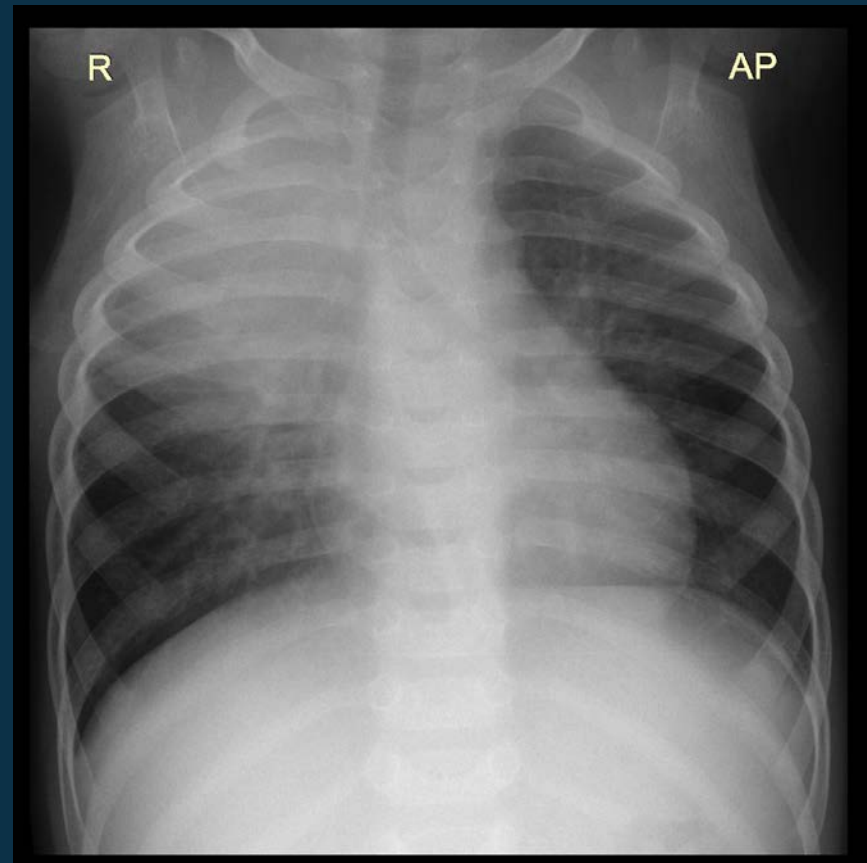
So it is

Alveolar opacity

Is it TB ?

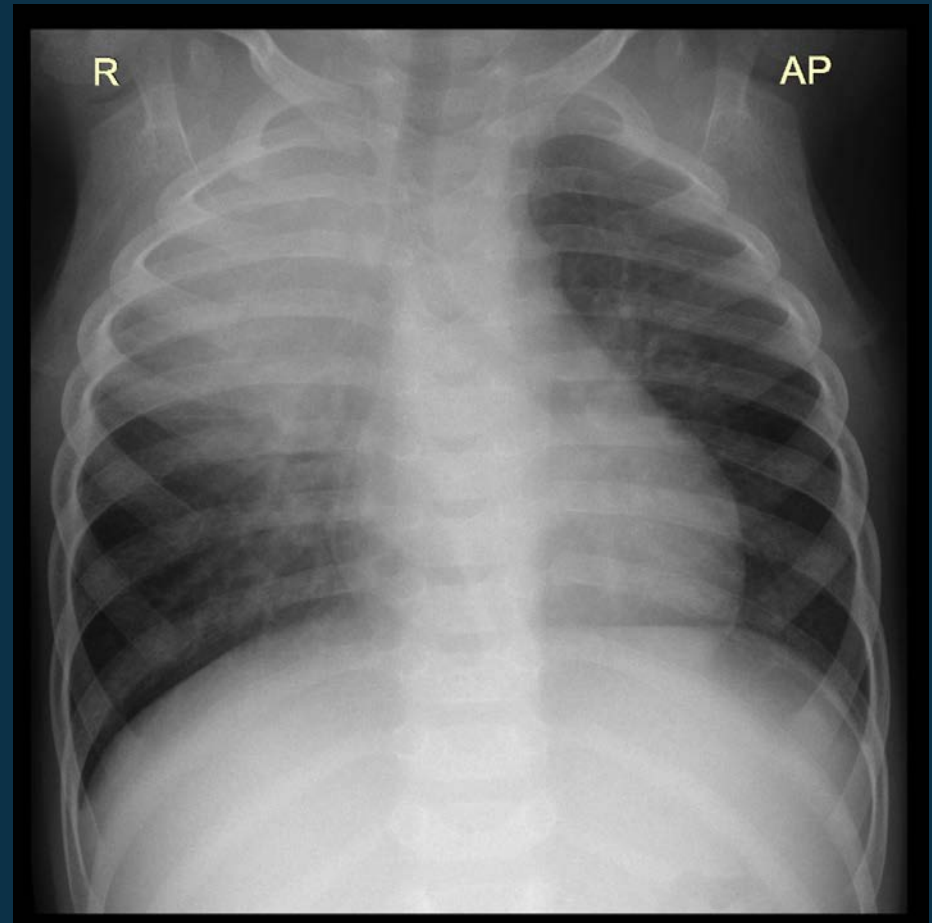
What should you request?

- . a lateral view



We have no lateral view
for this child so....

TB is possible but one should give
a course of amoxicillin before
considering TB treatment
(if GeneXpert negative)



Right upper alveolar opacity
in a 20 month old.

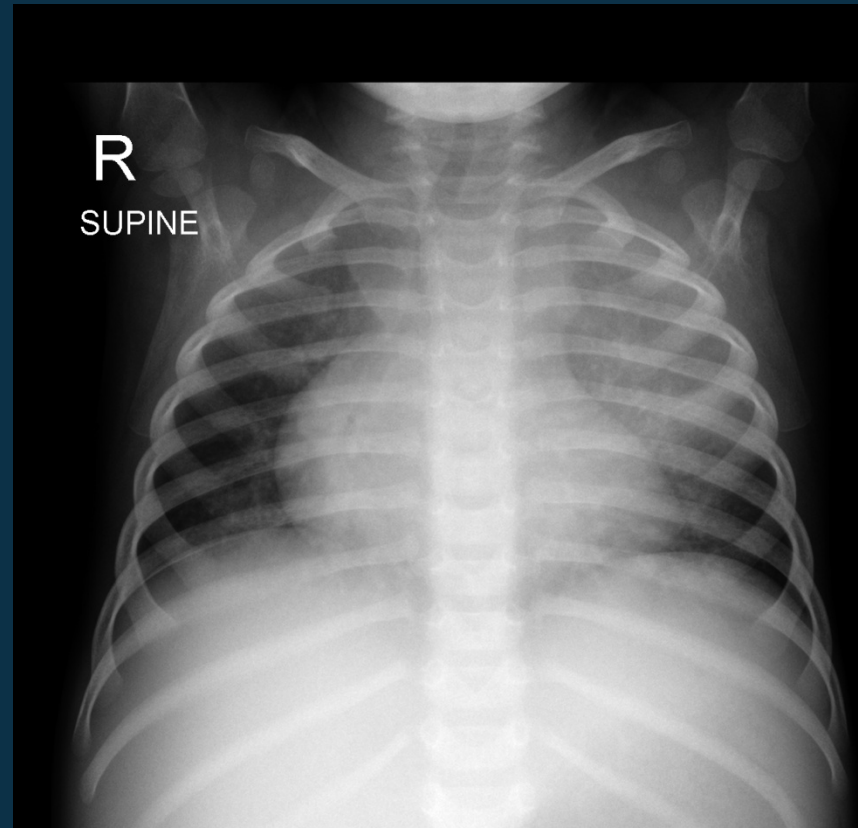
What do you see on this CXR ?

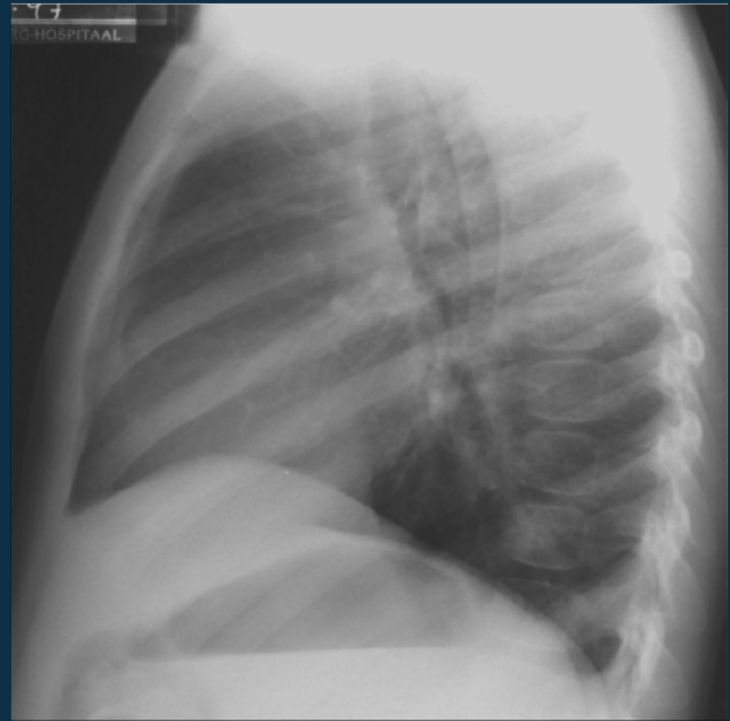
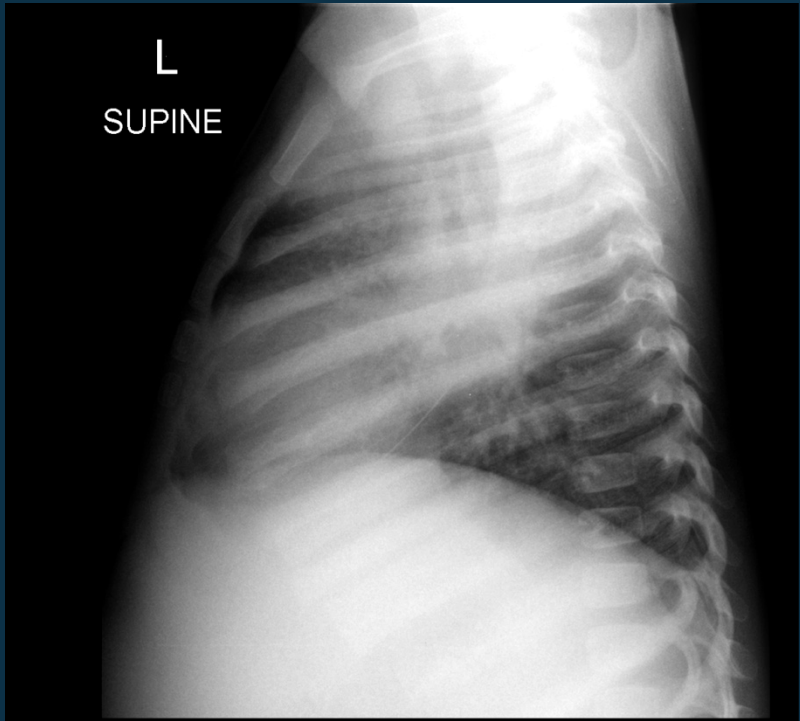
- . First circle: normal
- . Second circle:
Lungs :What do you see ?
opacity in the upper zone
of left lung
- . Third circle : normal

So it is

**Left upper zone alveolar
opacity (consolidation)**

Is it TB ?

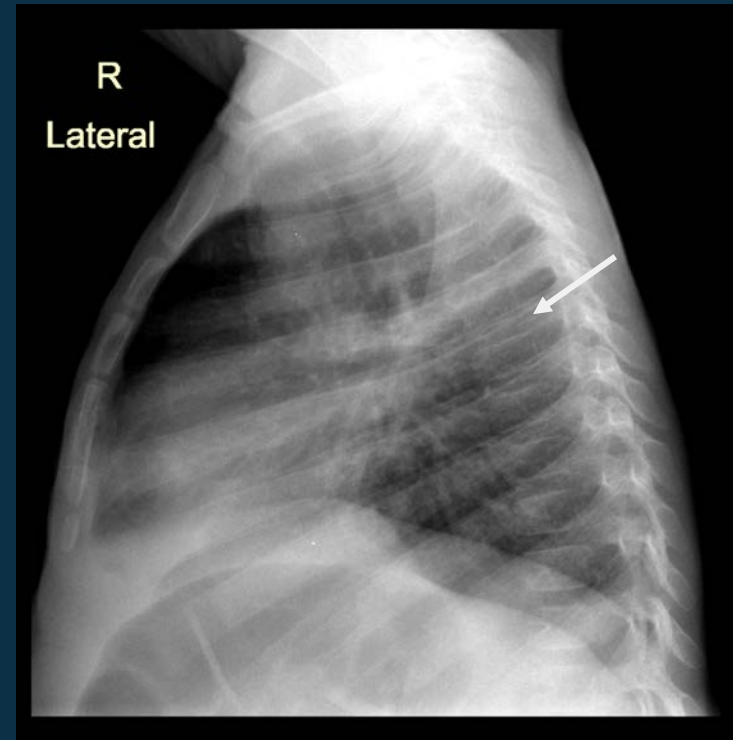
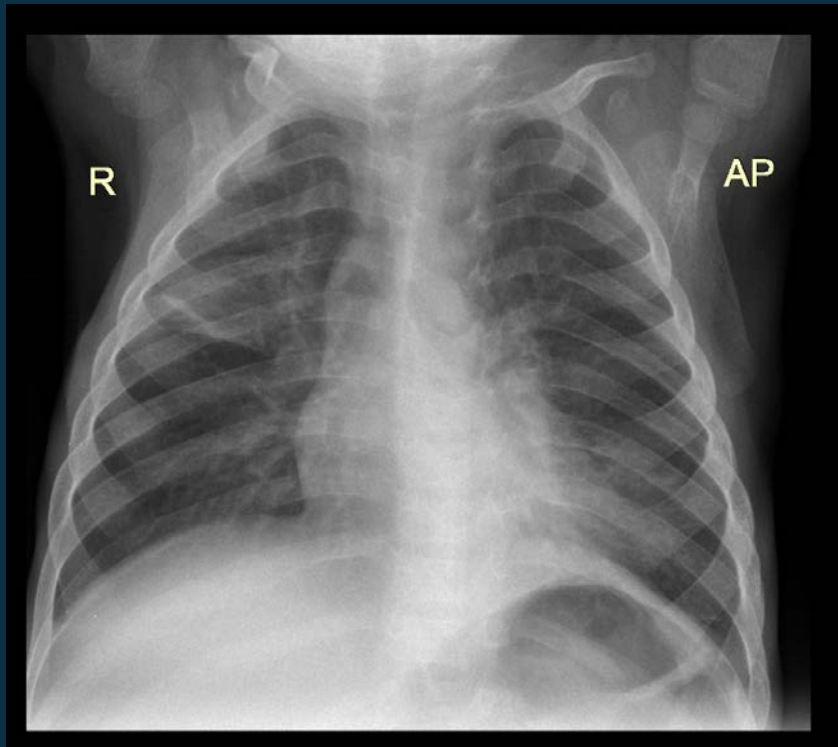




Is it TB ?

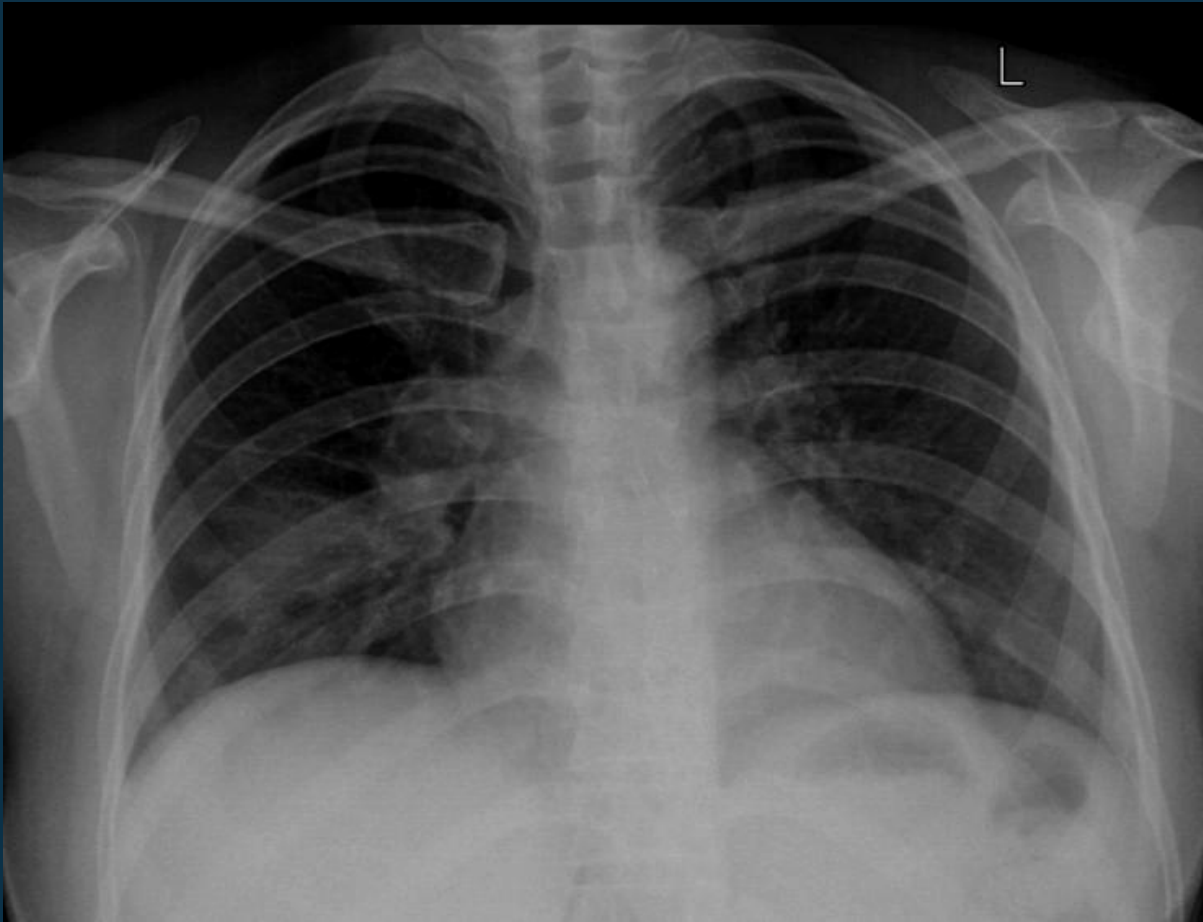
Yes , perihilar nodes
and lobar consolidation:
It is TB

Normal CXR



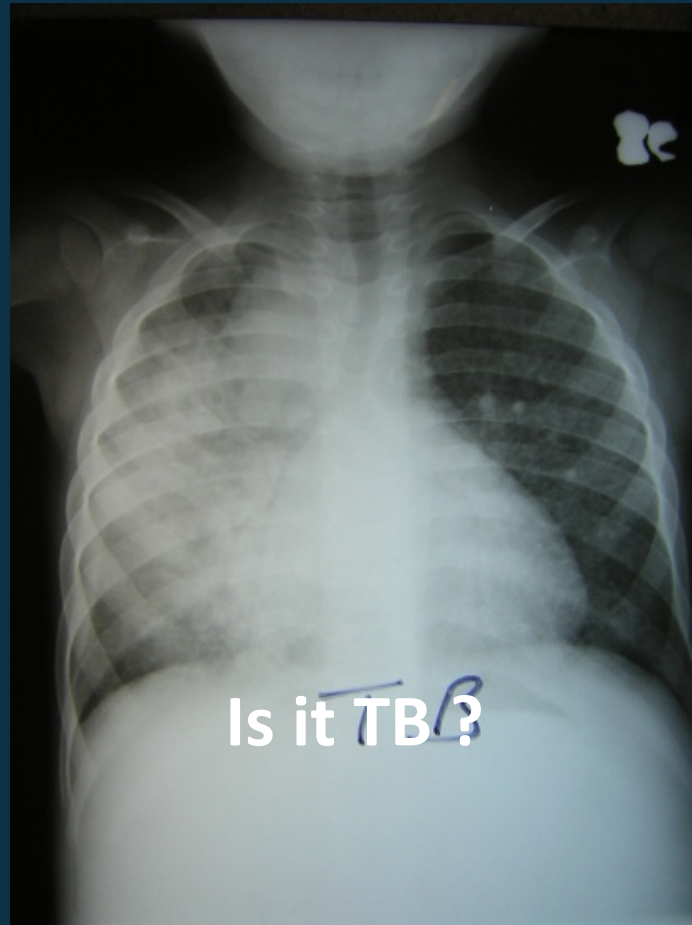
Is it TB ?

Bilateral bronchopneumonia with perihilar lymph node enlargement (visible on lateral view) and possible left bronchus compression in a 5 month old HIV-infected child



Is it TB ?

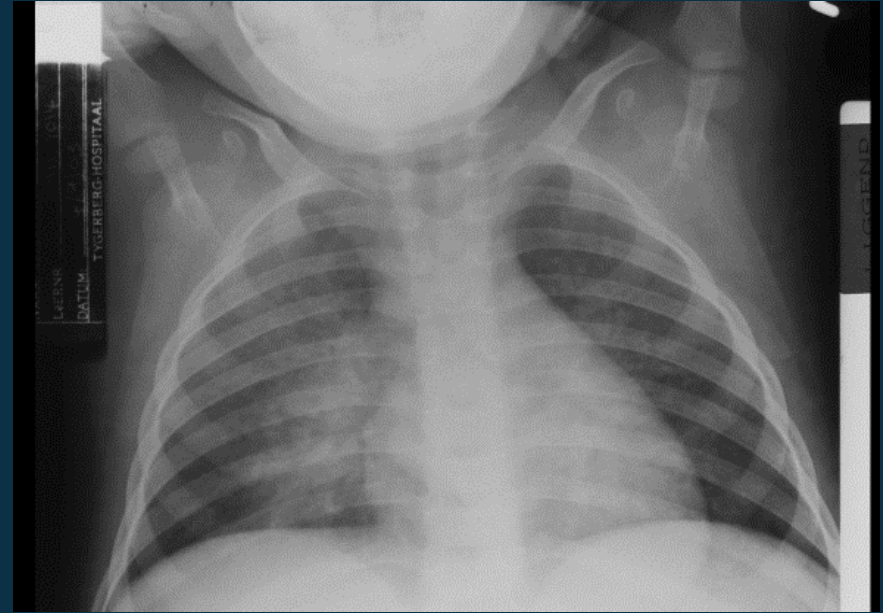
CXR suggestive of TB:
right perihilar lymph node enlargement with opacity
in the lower zone of the right lung



CXR suggestive of TB:
Right middle and upper lobe opacification and
tracheal deviation with lymph node compression
of the right main bronchus

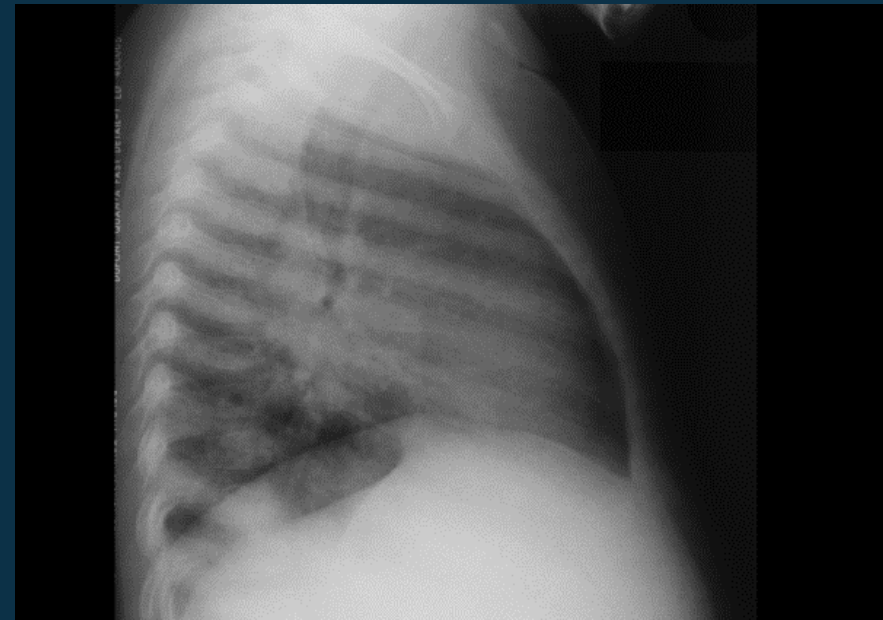
What do you see on these CXRs ?

- Right perihilar lymph node enlargement with surrounding opacities



What is your diagnosis ?

**TB Lymphadenopathy
with parenchymal
involvement**

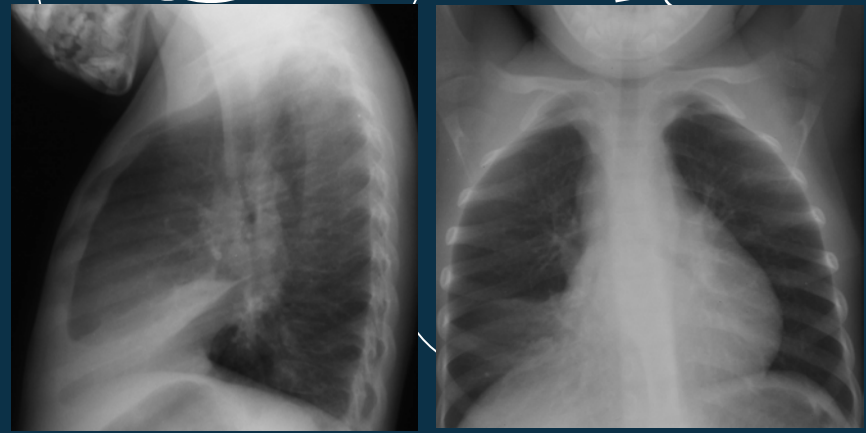
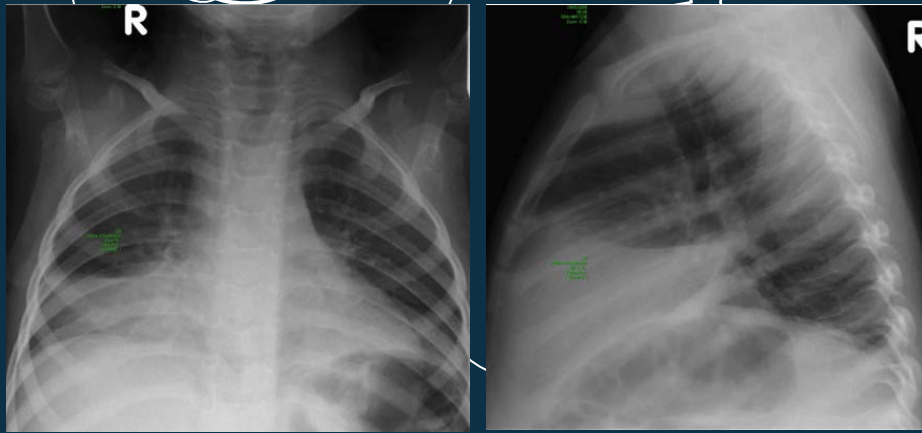


About alveolar opacity

1. The most common parenchymal involvement
2. It can mimic bacterial pneumonia
3. Strongly suggestive of TB if associated with ipsilateral hilar or para-tracheal lymph node enlargement
4. **Usually smear and xpert positive**
(especially in older children), if gastric lavage, induced sputum or NPA were collected

Key points: alveolar opacities

Is it TB ?



No hilar lymph nodes
 If GeneXpert negative then
 treat with antibiotics
 according to
 guidelines (amoxicillin or other)
 and review the child

Associated with hilar lymph
 nodes Suggestive of TB
 Begin TB treatment (With or
 without positive GeneXpert
 result)

Learning Objectives

Module 2: diagnose TB on a paediatric CXR using a simplified reading tool at PHC level

Chap1. Introduction

Chap2. Enlarged lymph nodes

Chap3. Alveolar opacity of the lung tissue

Chap4. Airways compression

Chap5. Cavitation

Chap6. Pleural or pericardial effusion

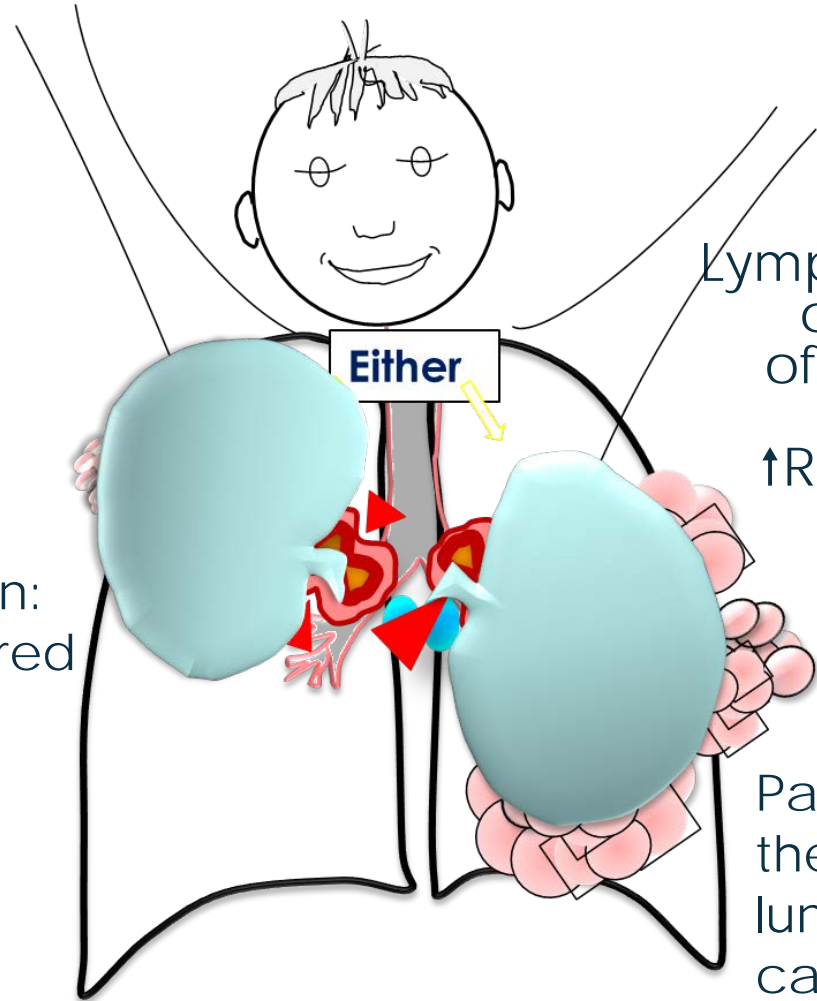
Chap7. Miliary

Chap8. Reading tool in a nutshell

Airway compression by TB lymph node in progressive TB

1. Lymph node compression can cause narrowing or obstruction of airways or can ulcerate into the airways
2. Look at airway position, and for narrowing or deviation
3. Look for:
 - . Airway narrowing
 - . Airway deviation
 - . Splaying of the carina

Specific anatomical considerations in infants and children



Lymph node compression causes narrowing of peripheral airways
 ↓
 ↑Resistance to airflow

Complete obstruction: the air has disappeared causing collapsed alveoli and loss of volume (atelectasis)

Partial obstruction: the air is trapped in the lung and accumulates causing check-valve / ball-valve phenomenon (air trapping)

Airway compression by TB lymph node

The enlarged nodes compress the adjacent trachea or bronchi causing luminal narrowing with either partial or complete obstruction

Partial obstruction

← either →

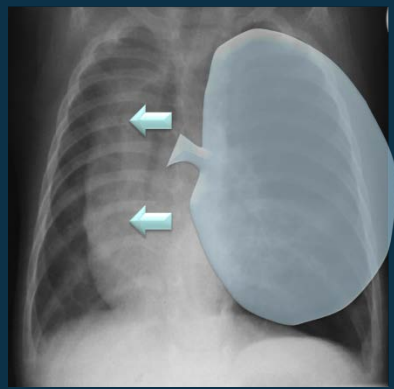
Complete obstruction

Air-trapping

Lung hyperinflation with check-valve effect and asymmetry between right and left lung

Responsible for radiographic hyperlucency (lung appears blacker)

Shift of surrounding structures: 'pushes'

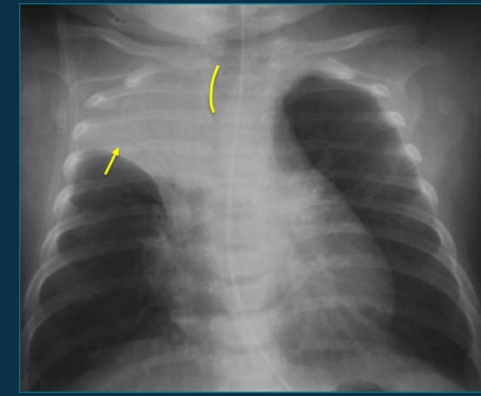


Atelectasis

alveolar collapse

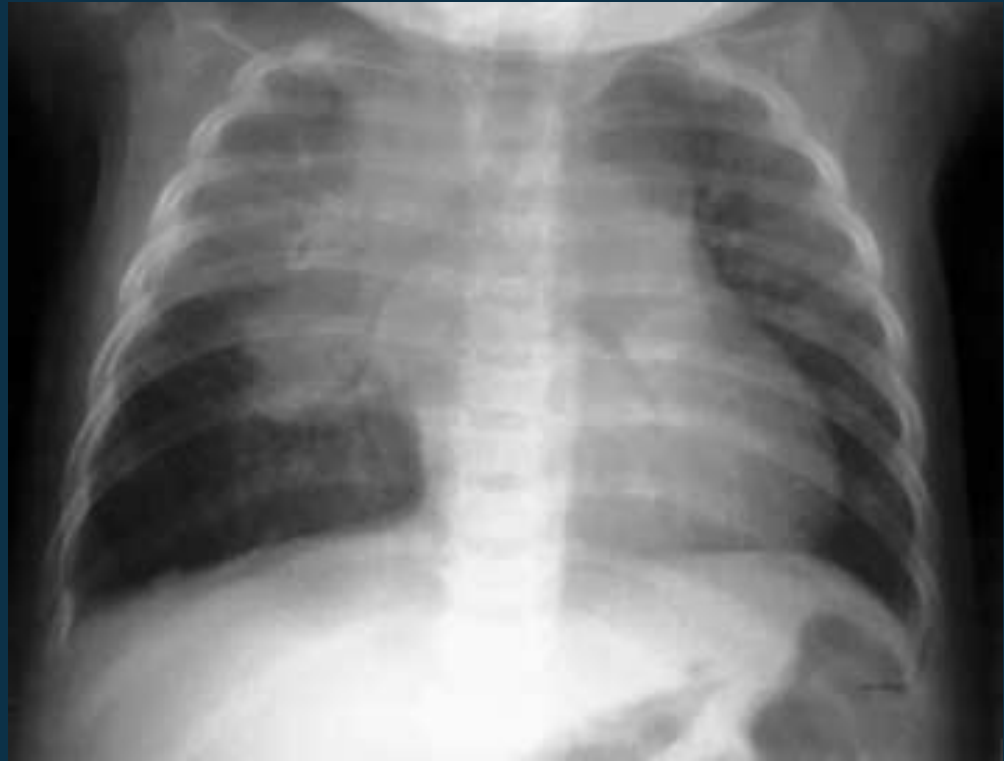Responsible for radiographic alveolar opacity (lung appears whiter) with loss of volume

Shift of surrounding structures: 'pulls'



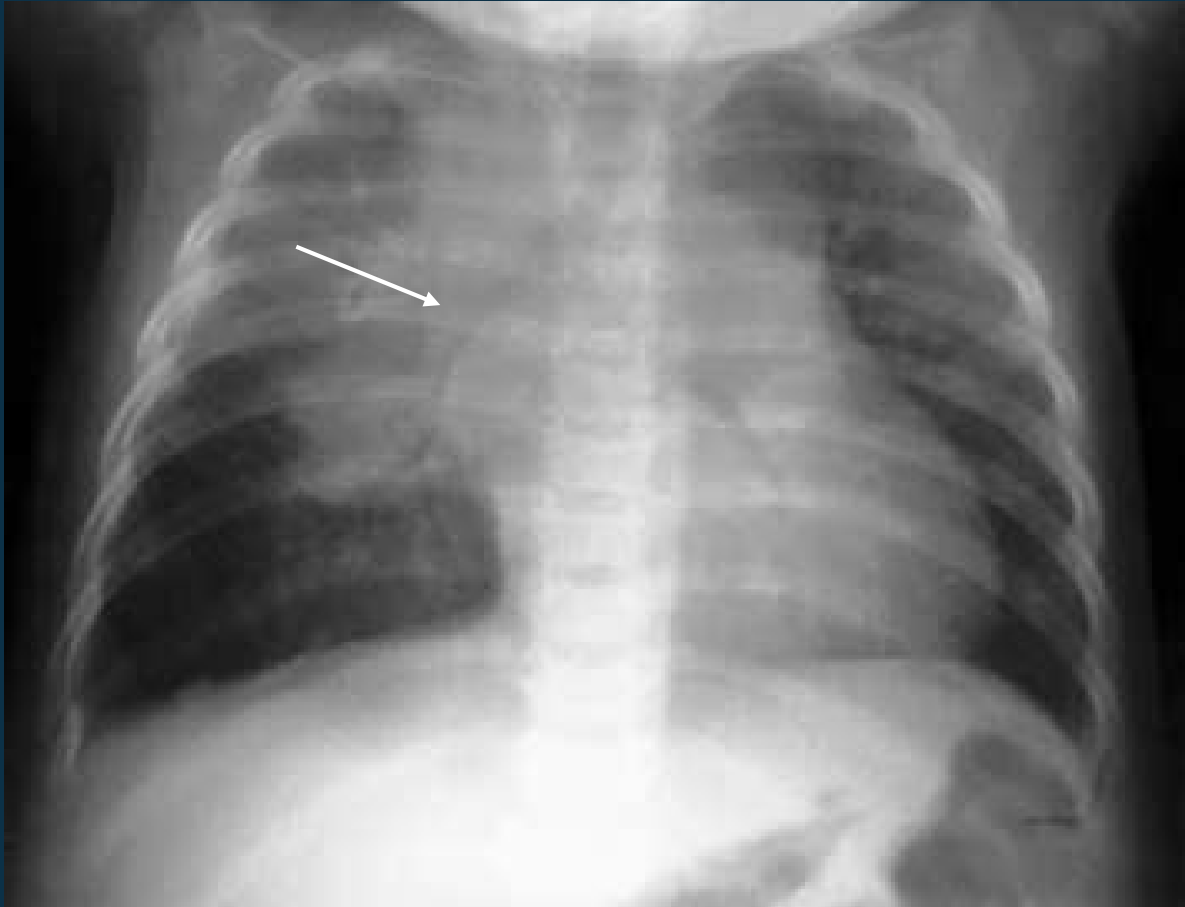
What do you see on this CXR ?

- . First circle: normal
- . Second and third circle:
How are the lungs ?
Asymmetry in lucency :
Upper lobe opacity and
hyperlucency in the right
lower lobe.
The right hemidiaphragm
is flattened



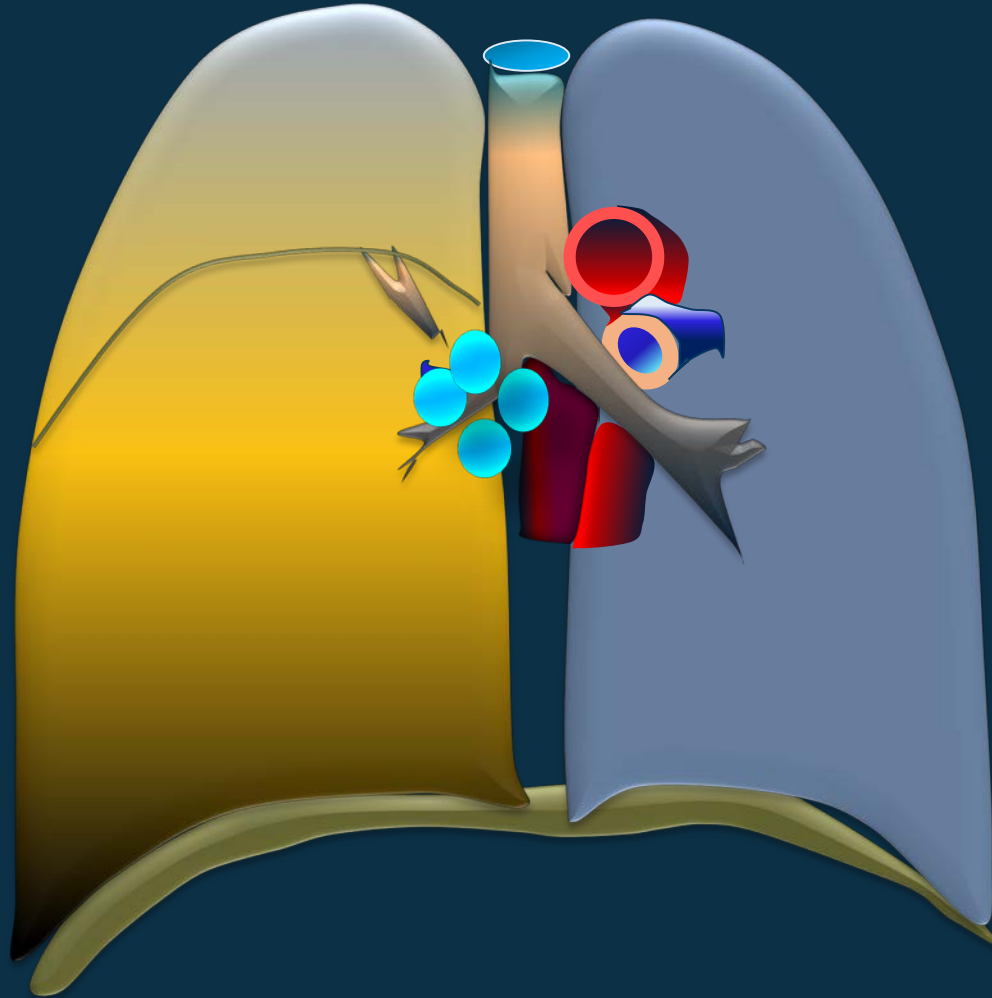
How are the airways ?

- . Narrowing of the right main bronchus
- . Mediastinum shifted to the right
- . Splaying of the carina



What is your diagnosis?

Airway compression caused by lymph node enlargement causing check-valve effect (right main bronchus partially obstructed with hyperinflation of the right lower lobe)



Lymphobronchial tuberculosis with partial obstruction of the right lower lobe bronchus by enlarged lymph nodes and secondary lobar hyperinflation

What do you see on this CXR ?

- . First circle: normal
- . Second and third circle:
How are the lungs ?
 - . Asymmetry in lucency:
left hyperlucent lung
 - . Alveolar opacity of the left
lower lobe

How are the airways ?

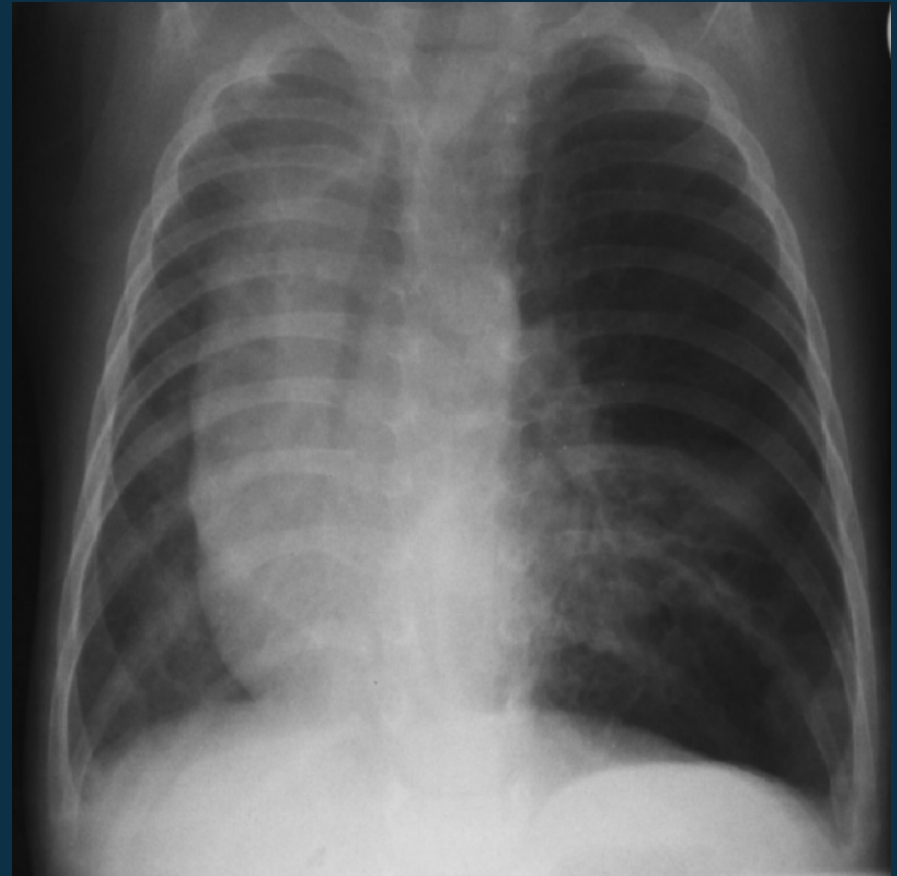- . Tracheal shift to the right

How is the mediastinum ?

- . Mediastinal shift

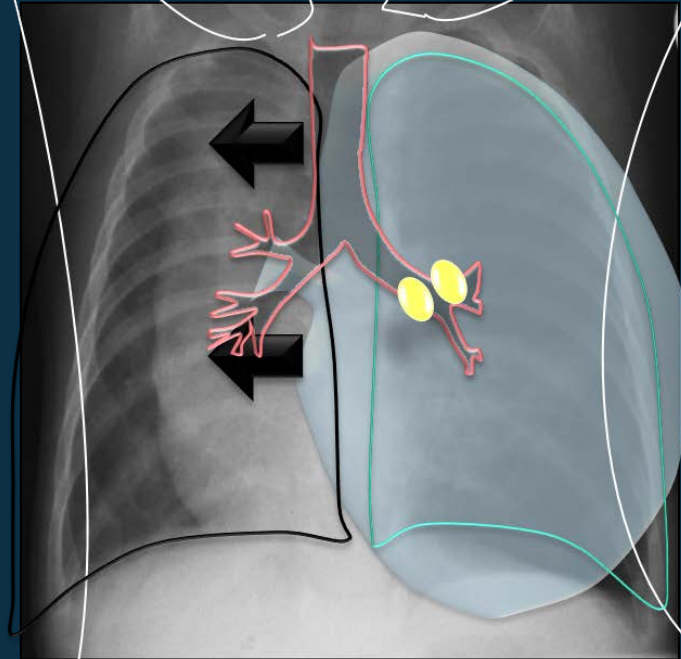
What is your diagnosis ?

**Airway compression by lymph nodes: check-valve effect
(left main bronchus is partially obstructed with hyperinflation)**



Complicated TB :

Check valve - the main left bronchus is partially obstructed



What do you see on this CXR ?

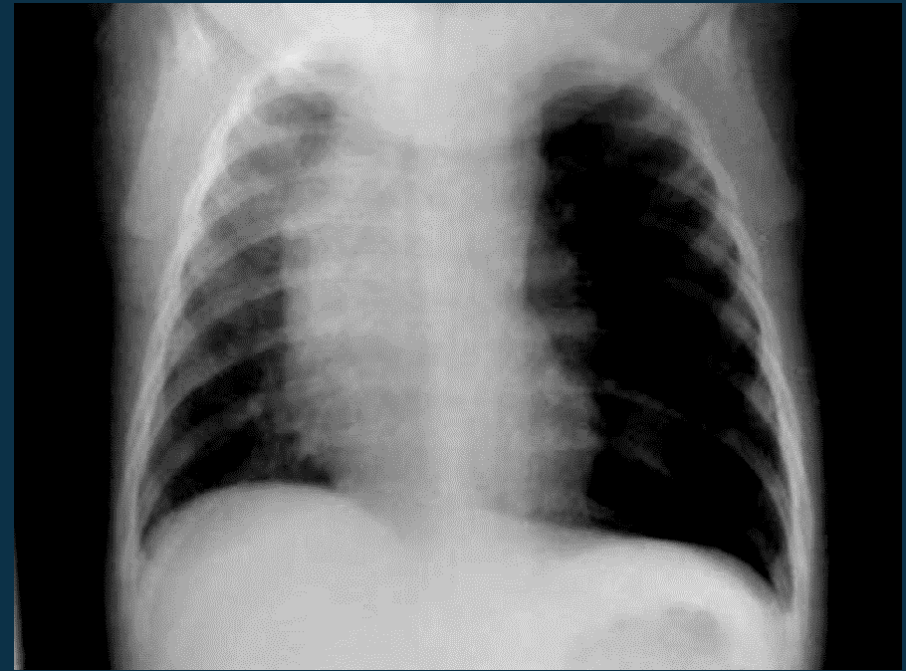
- . First circle: normal
- . Second and third circle:
How are the lungs ?
Asymmetry in lucency :
Left hyperlucent lung,
flattened hemidiaphragm
and hyperinflation

How are the airways ?

- . Tracheal shift to the right
- . Left main bronchus partially
obstructed (but not well visible)

How is the mediastinum ?

- . Mediastinal shift to the right
- . Left lymph node enlargement



What is your diagnosis ?

**Lymph node disease
with airway compression:
check-valve effect (the left
main bronchus is partially
obstructed with air trapping
and hyperinflation)**

What do you see on this CXR ?

How are the airways ?

- . Compression of both left and right main bronchi

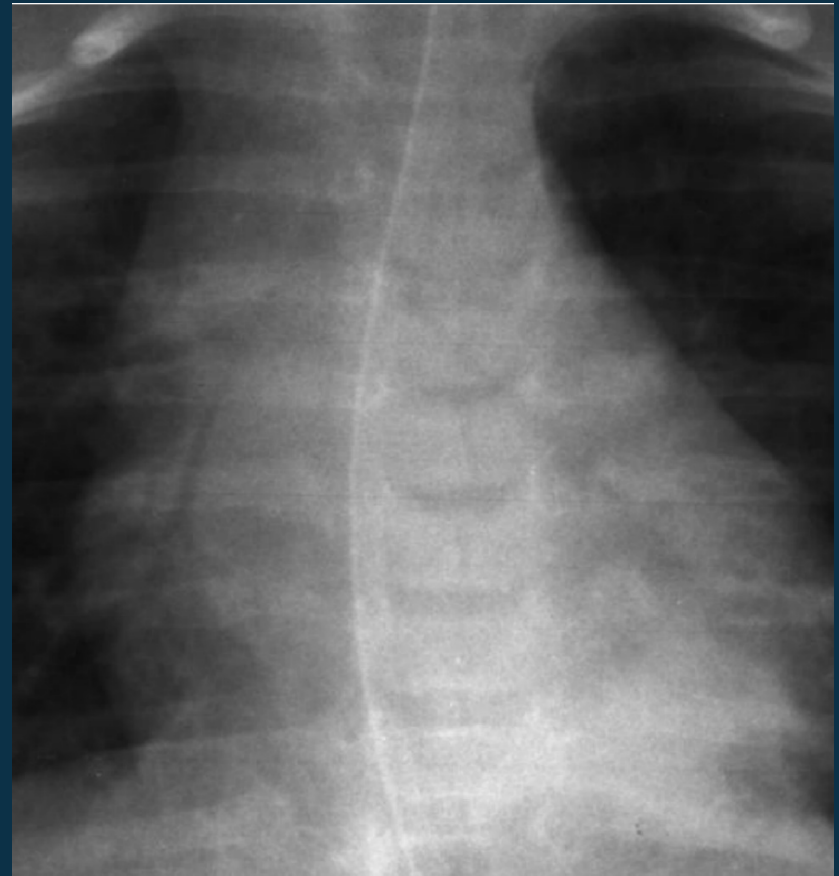
How is the mediastinum ?

- . Widened due to enlarged mediastinal lymph nodes

What is your diagnosis ?

Bronchial obstruction due to enlarged lymph nodes

This child has clinical signs of asthma (wheeze) but has no response to bronchodilators



Wheeze

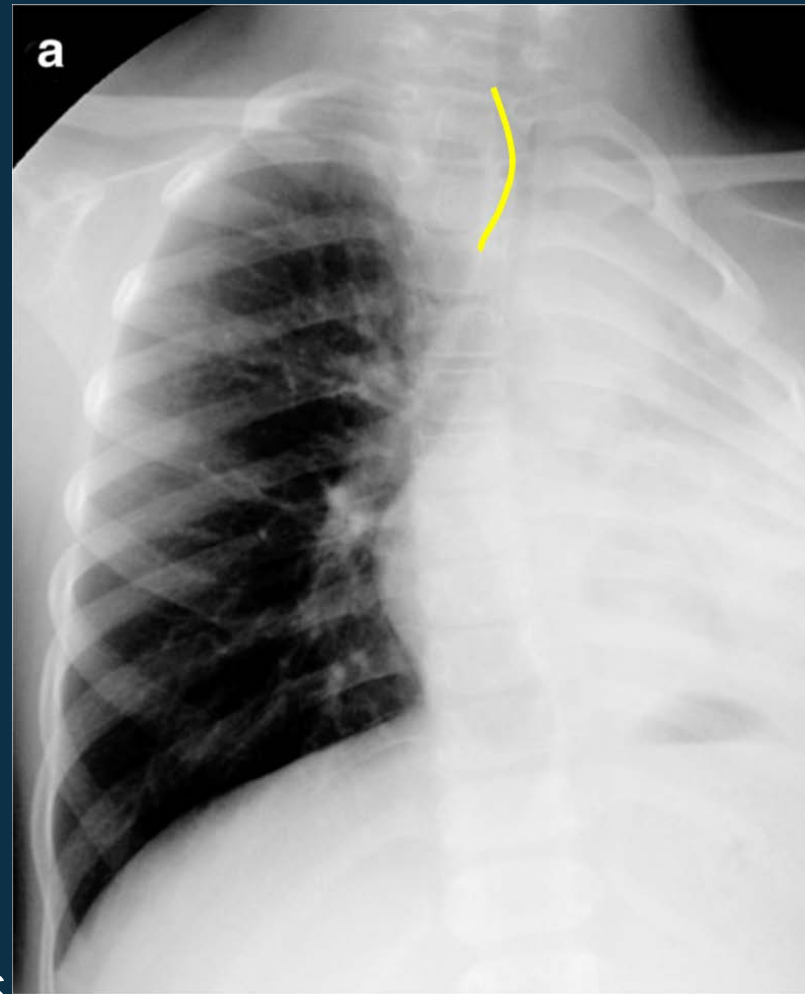
- . Asymmetrical and persistent wheeze can be caused by airway compression secondary to enlarged tuberculous hilar lymph nodes
- . Suspect TB when wheeze is asymmetrical, persistent or not responsive to bronchodilator therapy and/or associated with other typical features of TB

What do you see on this CXR ?

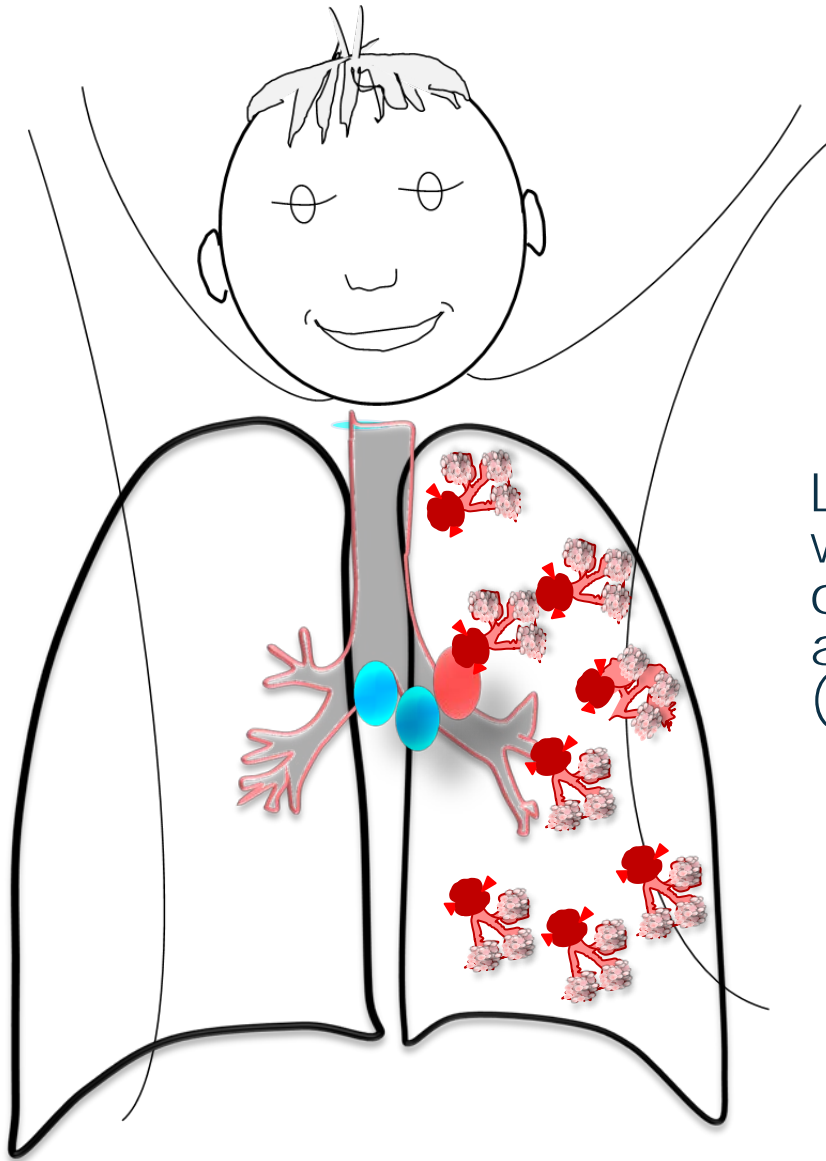
- . First circle :
We've lost the left hemi-diaphragm
- . Second circle :
Complete opacity of the left hemithorax
- . Third circle :
Tracheal shift towards the opacity

What is your diagnosis ?

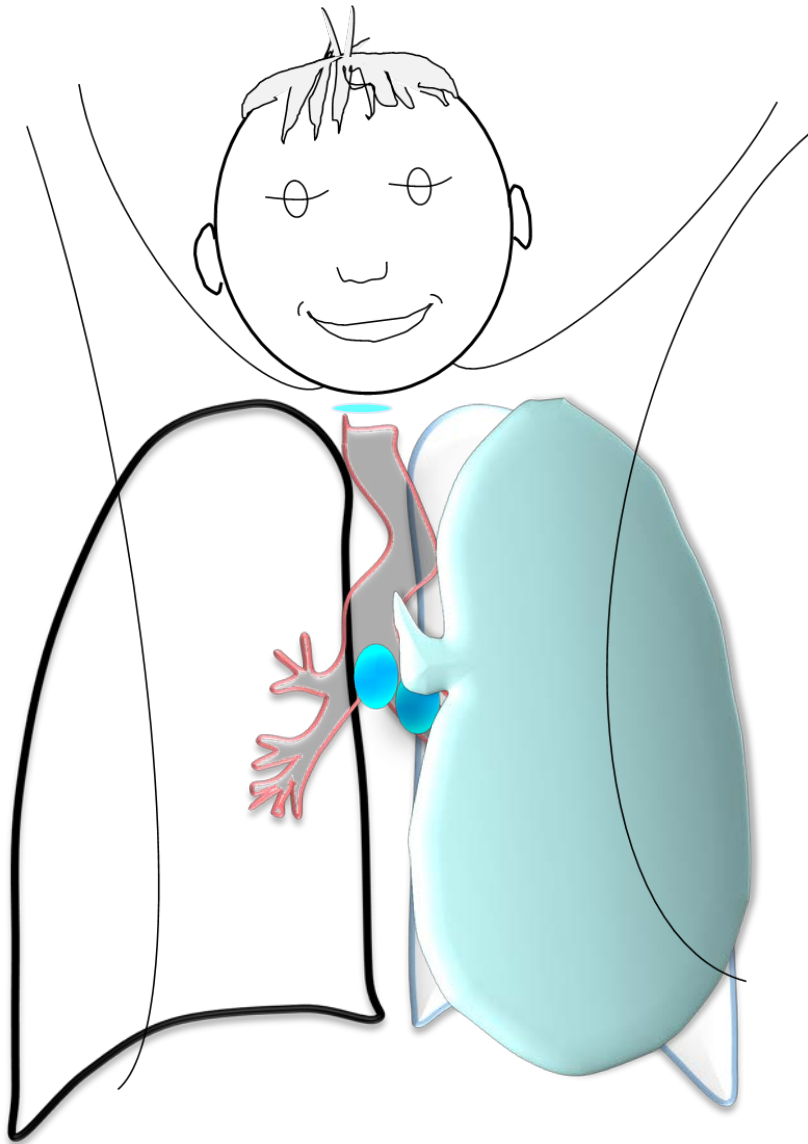
Left lung collapse: 6-year old boy with primary progressive lymphobronchial tuberculous disease.



AP chest radiograph



Lymph node compression
with complete obstruction
of the airway causing
alveolar collapse
(lung collapse)

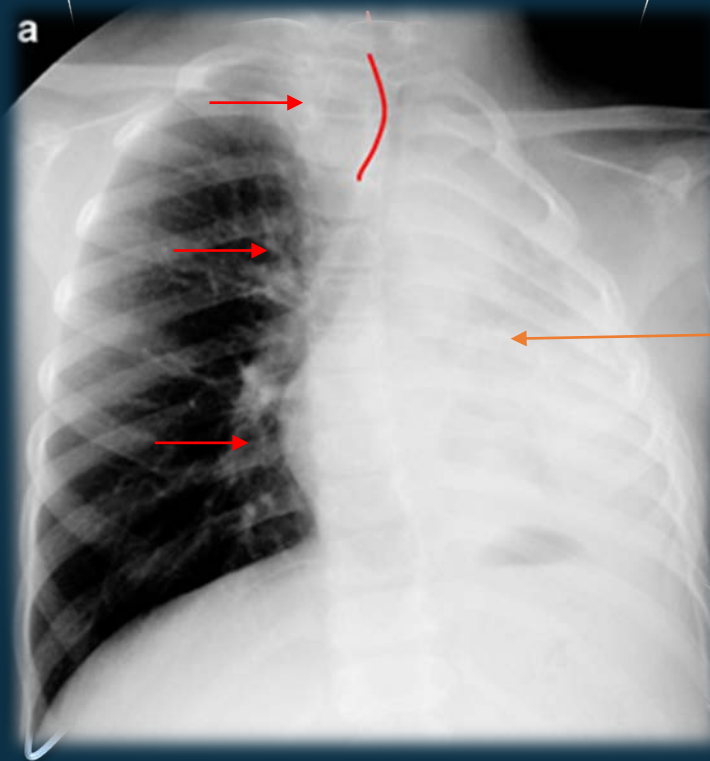


Lymph node compression with complete obstruction of the airway causing alveolar collapse.

The alveolar air gradually disappears and this is seen radiographically as an opacity with loss of volume.



Shift of trachea and mediastinal structures towards the side of the atelectasis



Complete opacification of left hemithorax (collapsed lung)

No more air !

What do you see on this CXR ?

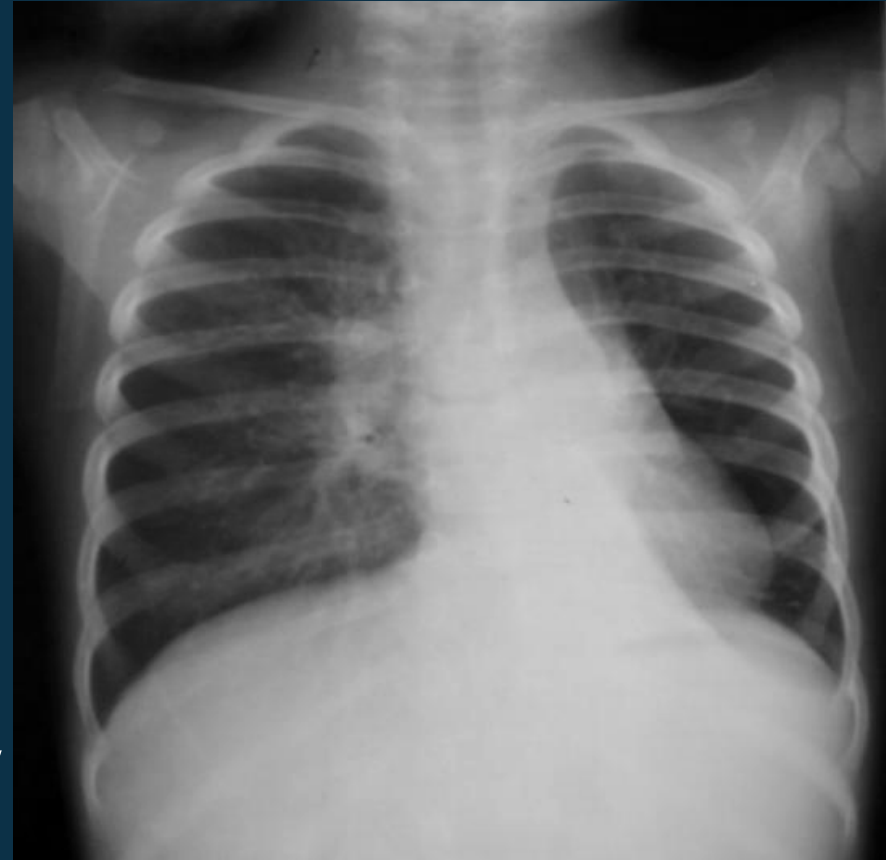- . In the right hemithorax ?
soft tissue density mass
with convex edge

Where?

- . hilar region with infiltration
into the surrounding tissue, and
hyperinflation

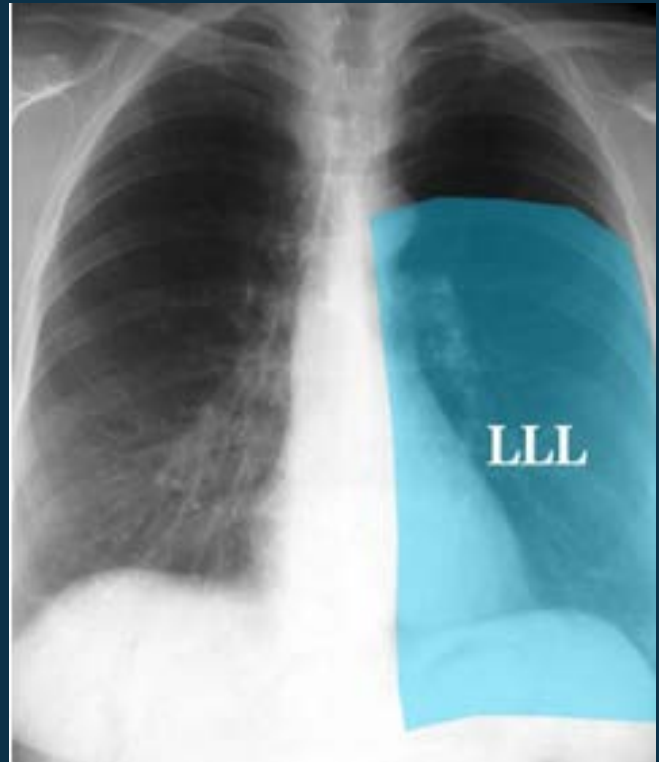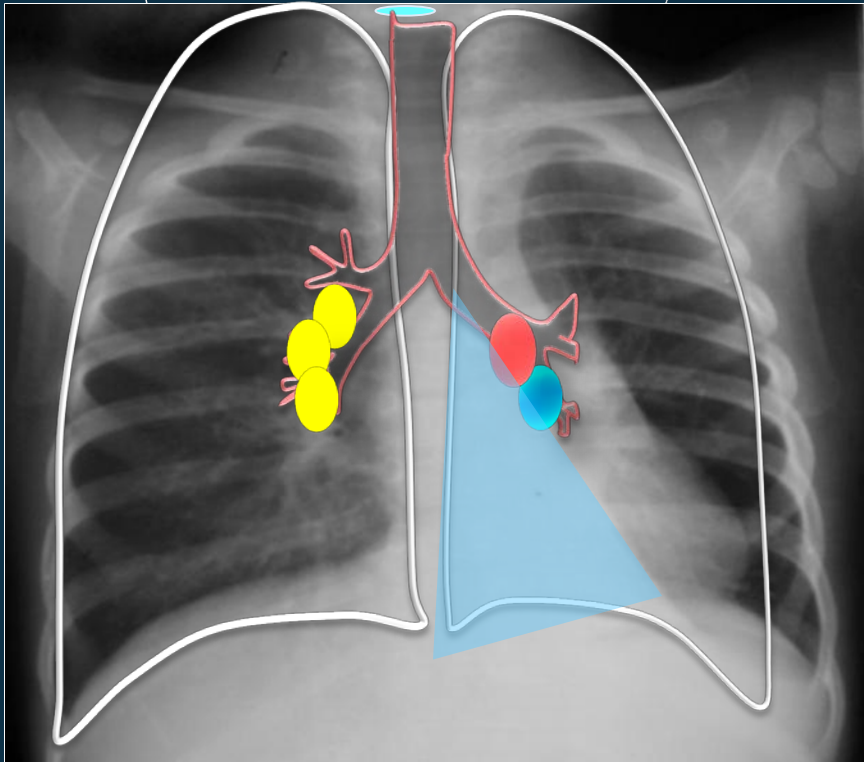
How about the left lung ?

- . Double shadow through
the cardiac shadow:
left inferior bronchus is completely
obstructed with volume loss



What is your diagnosis ?

Left lower lobe atelectasis caused by complete obstruction of left inferior bronchus by enlarged right hilar lymph nodes, with infiltration and hyperinflation



Normal left lower lobe

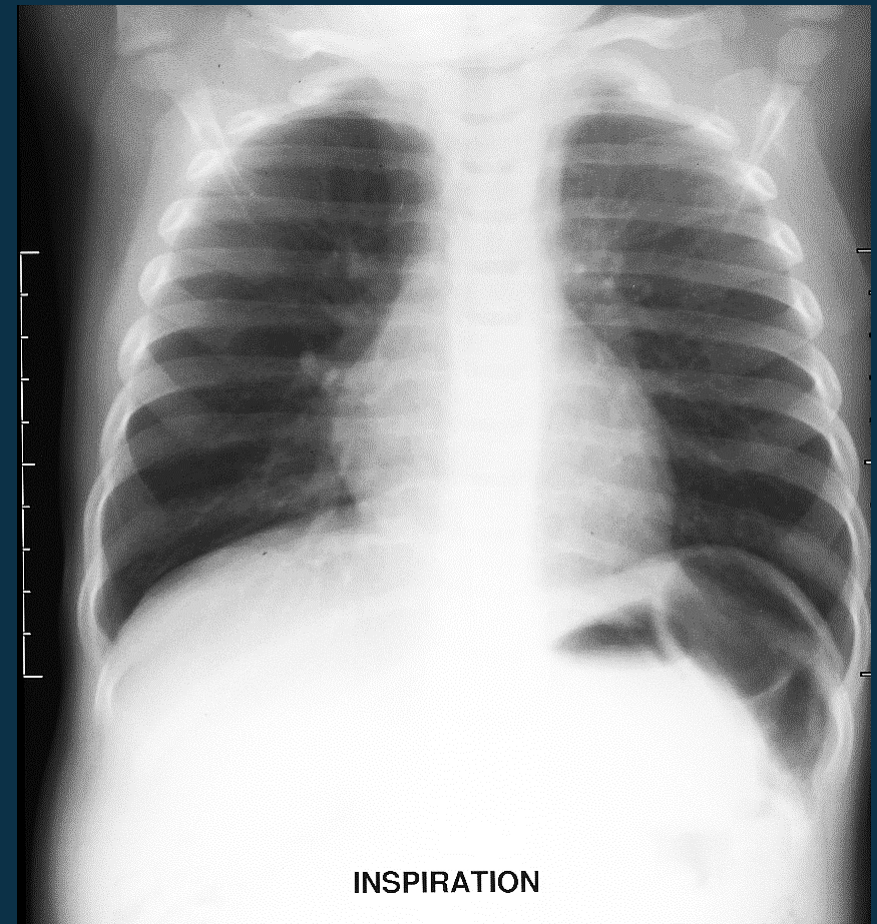
Airway compression by TB lymph node: differential diagnosis

Infant with cough and
dyspnoea of sudden onset

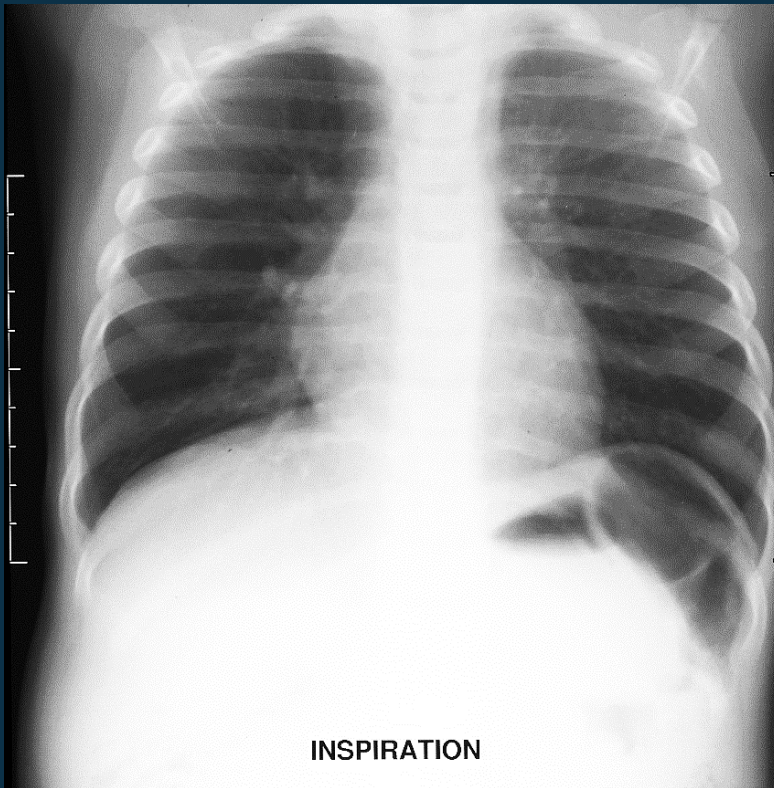What do you see on this CXR ?

- . There seems to be an asymmetry in lucency (hyperlucency of the right hemithorax)

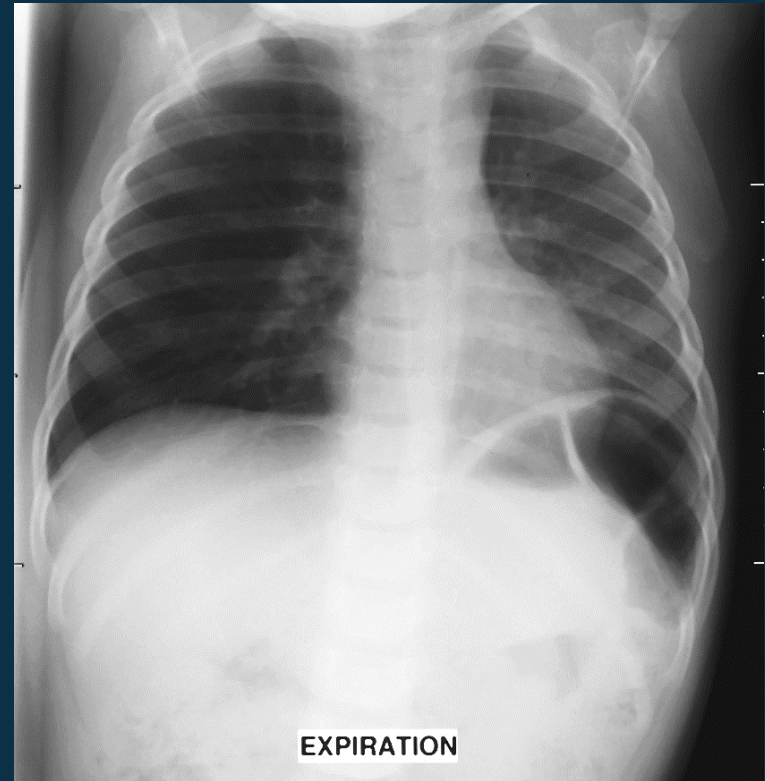What do you request?



Infant with cough and dyspnoea of sudden onset.



Inspiration



expiration

What is your diagnosis ?

The air is trapped in expiration in the right lung with mediastinal shift towards the normal contralateral side : Foreign body in the main right bronchus

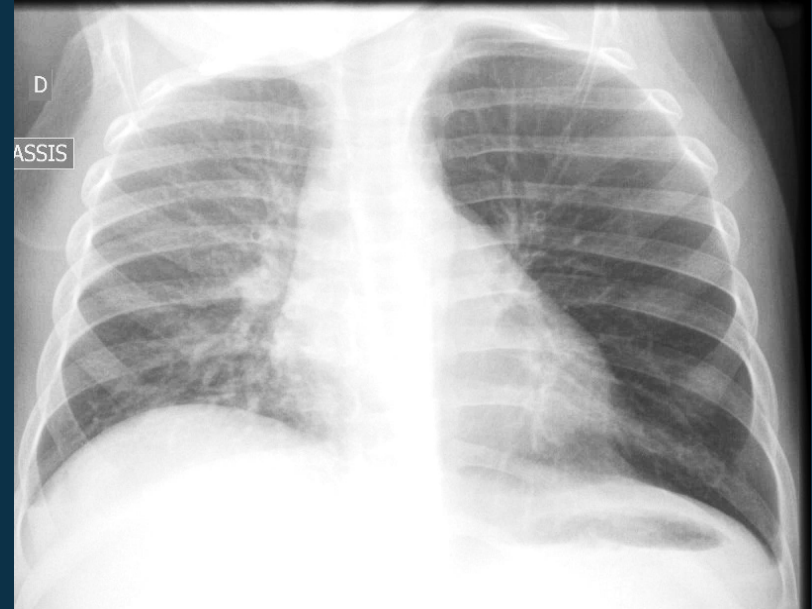
If you suspect foreign body aspiration always ask for an expiratory view

2 year old child with cough and dyspnoea of sudden onset.

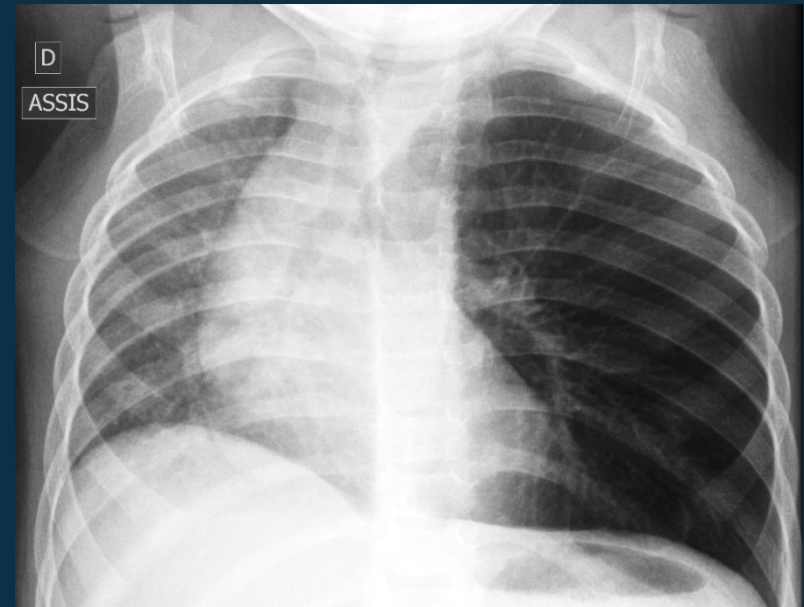
What do you see on this CXR ?

What is your diagnosis ?

The air is trapped in expiration in the left lung with mediastinal shift towards the normal contralateral side: Foreign body in the main left bronchus



Inspiration

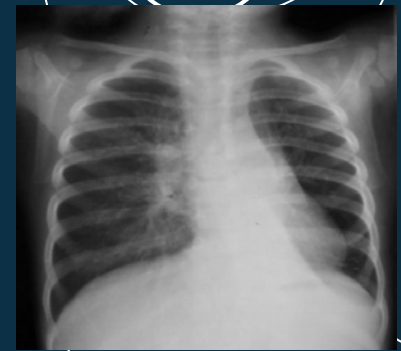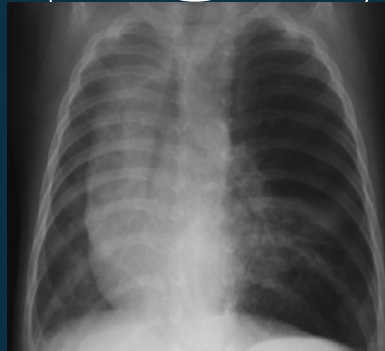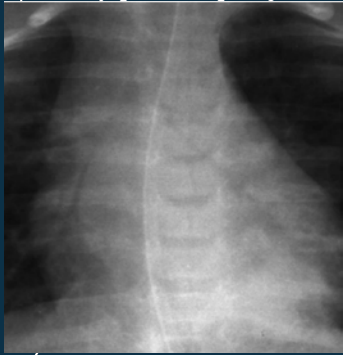


expiration

Key points: airway compression

Partial obstruction

Complete obstruction

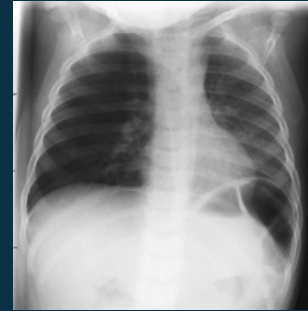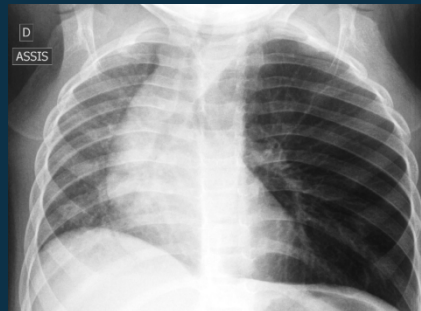


Large bronchial obstruction

Check-valve: hyperinflation, left main bronchus obstruction

Left lower lobe atelectasis

Beware of differential diagnosis



Foreign body aspiration: expiratory view

Learning Objectives

Module 2: diagnose TB on a paediatric CXR using a simplified reading tool at PHC level

Chap1. Introduction

Chap2. Enlarged lymph nodes

Chap3. Alveolar opacity of the lung tissue

Chap4. Airways compression

Chap5. Cavitation

Chap6. Pleural or pericardial effusion

Chap7. Miliary

Chap8. Reading tool in a nutshell

TB cavities

They are uncommon in young children

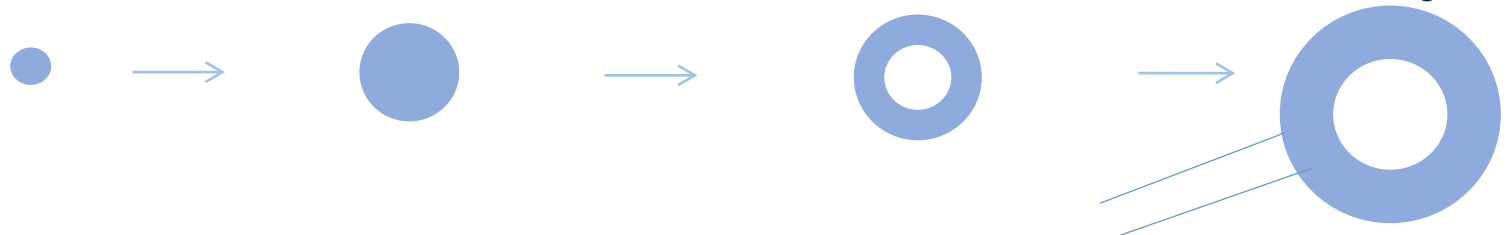
More frequent in children >10 years old

**More likely to be smear and GeneXpert
positive with a high risk of transmission**

About Cavities in childhood TB

1. More frequent in children >10 years old with 'adult-like' post primary TB. Usually involve the upper lobes, usually single and unilateral
2. As the alveolar lesion enlarges this leads to central necrosis and cavitation
3. The walls of the cavities are rich with bacilli and represent a risk of relapse and MDR strain development
4. **GeneXpert pos with a high risk of transmission**
5. These images can progress over time :

nodule → macronodule → excavated nodule → cavity

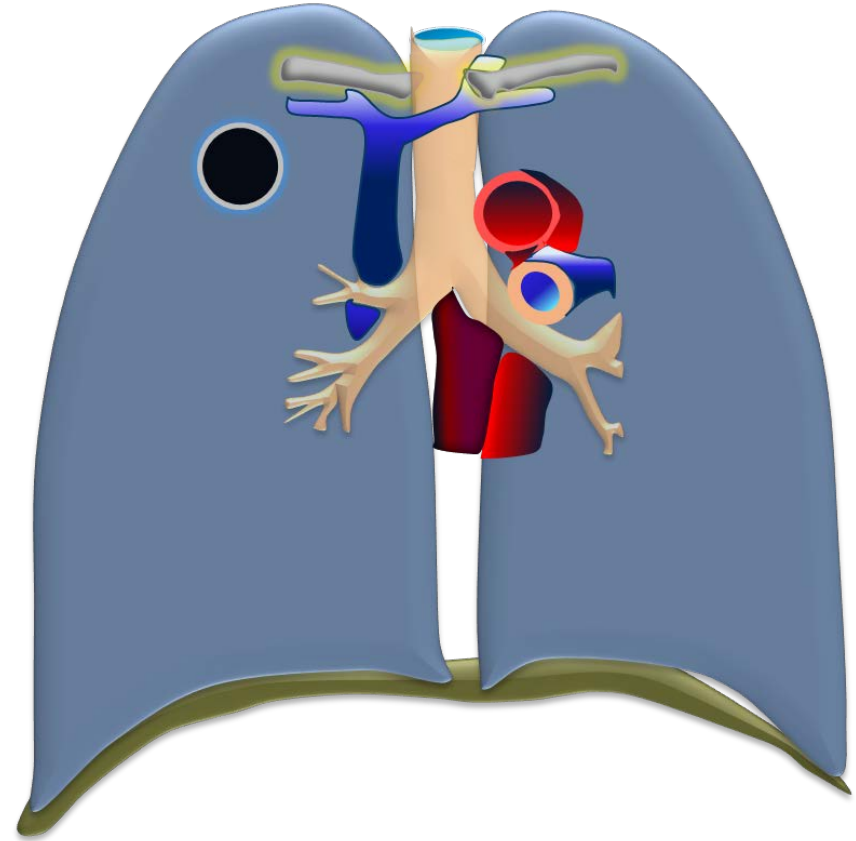


Older child >10 years old

A cavity is defined as any radiographic opacity with an internal area of lucency

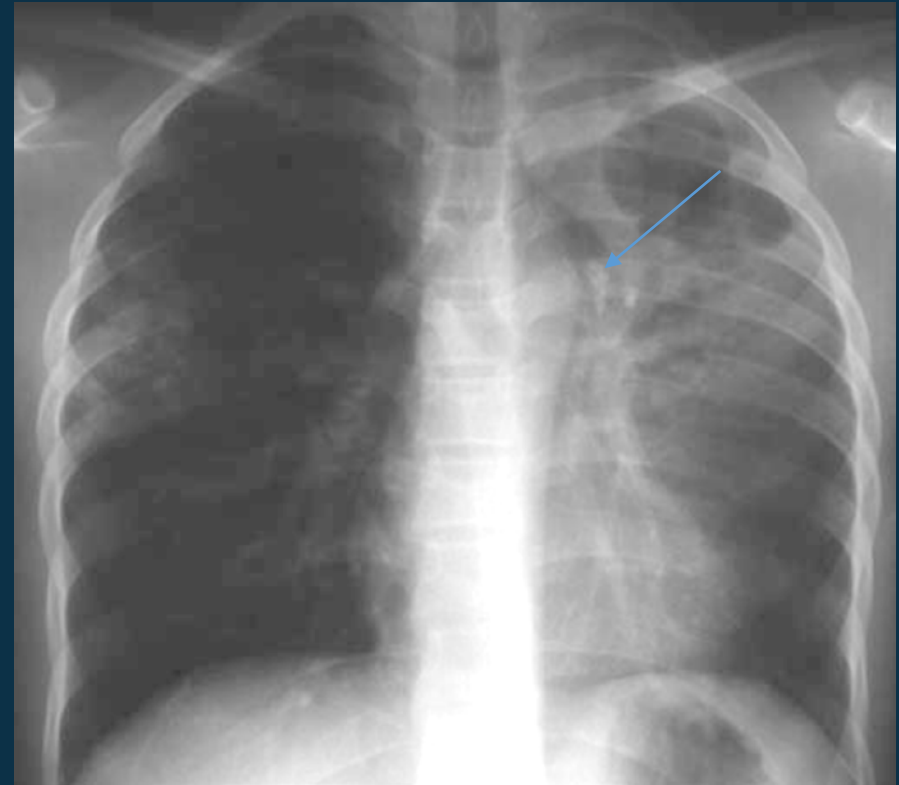
They are usually found in:

- . the apical and posterior segments of the upper lobes
- . the apical segment of the lower lobes (areas with higher oxygen tension)



What do you see on this CXR ?

- . First circle: normal
- . Second circle
 - . Left lung : alveolar consolidation and multiple cavities in LUL leading to intrabronchial spread
 - . Right lung : segmental bronchopneumonia
- . Third circle
Calcified mediastinal lymph nodes on the left suggest previous primary infection

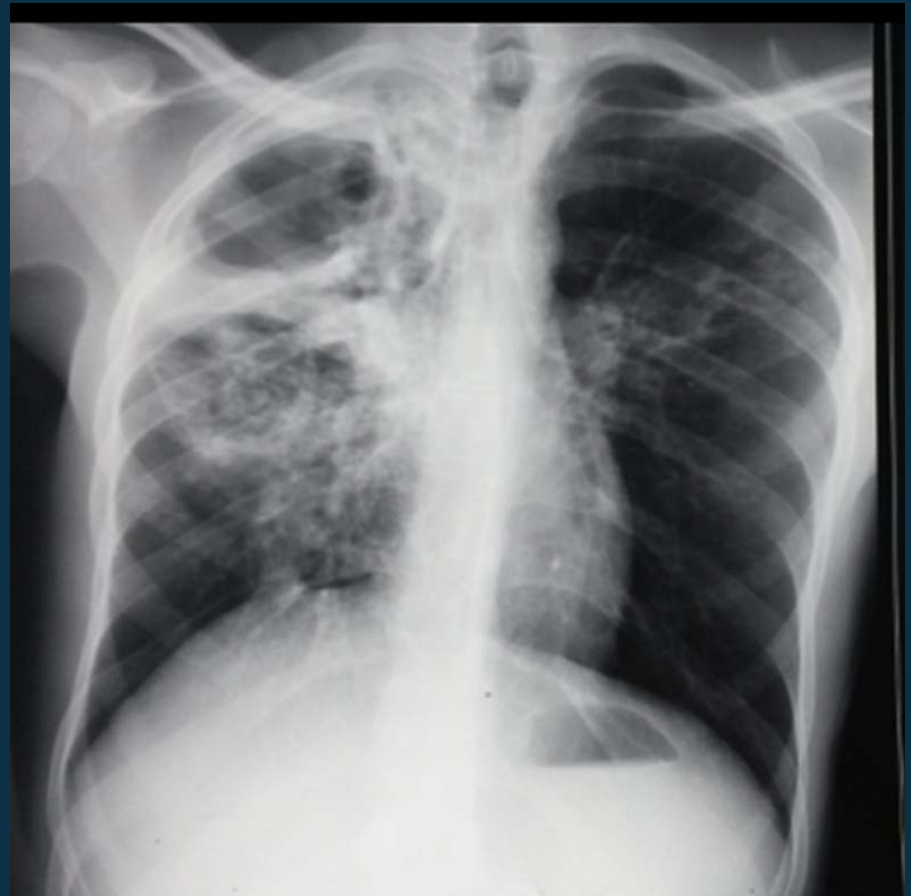

What is your diagnosis ?

'Adult-type' TB disease with alveolar consolidation and multiple cavities in the left upper lobe, and right bronchopneumonic consolidation

What do you see on this CXR ?

- . First circle: normal
- . Second circle
 - . Some degree of retraction of the right hemidiaphragm
 - . Large TB cavities and
 - . Multiple micro-nodules



What is your diagnosis ?

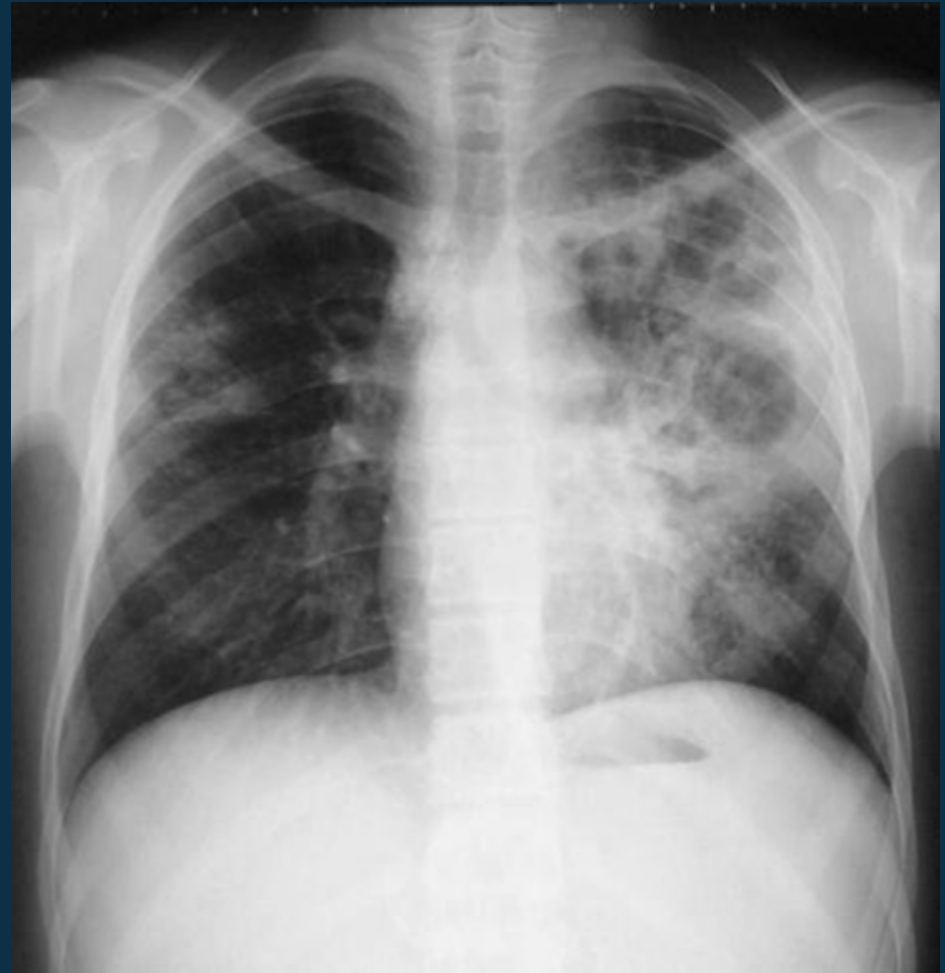**Large TB cavities in an adolescent with fever,
2 month cough, night sweats, AFB+**

What do you see on this CXR ?

- . First circle: normal
- . Second circle:
Lungs: left upper lobe
shows excavated
pneumonia

What is your diagnosis ?

Sputum Smear positive

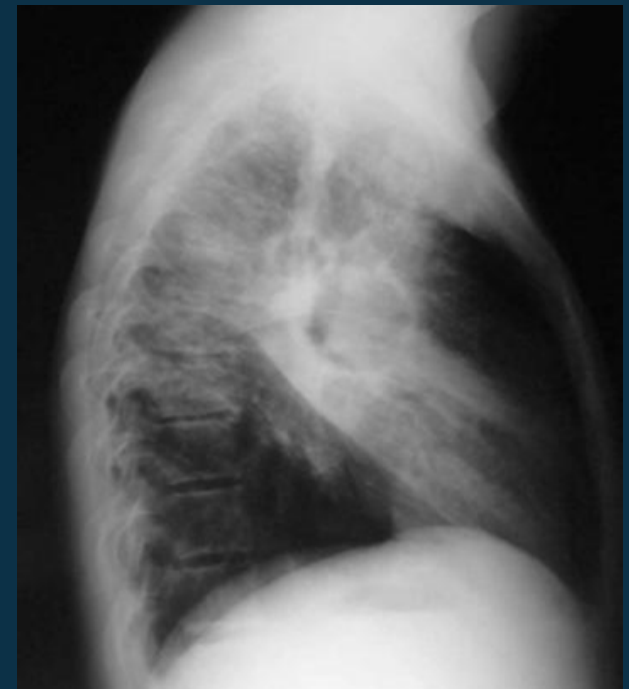
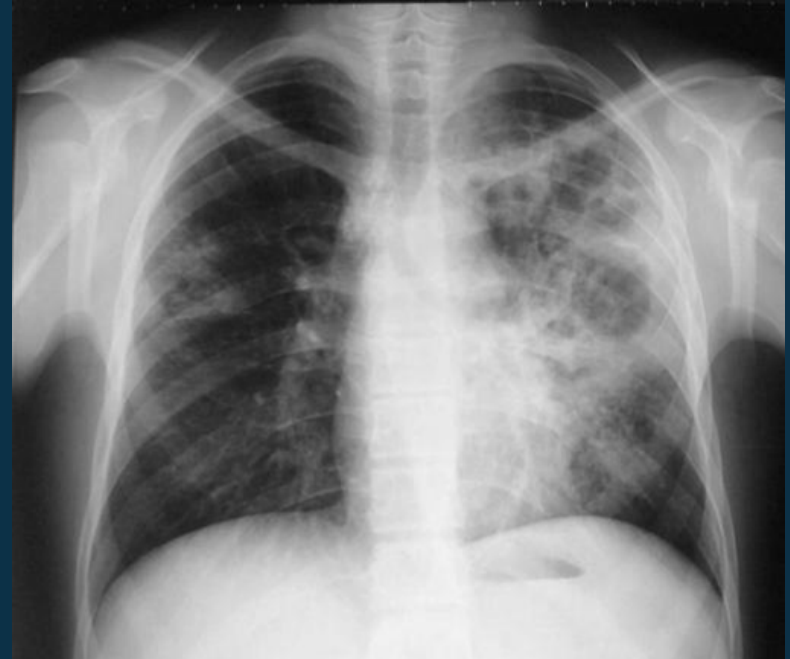

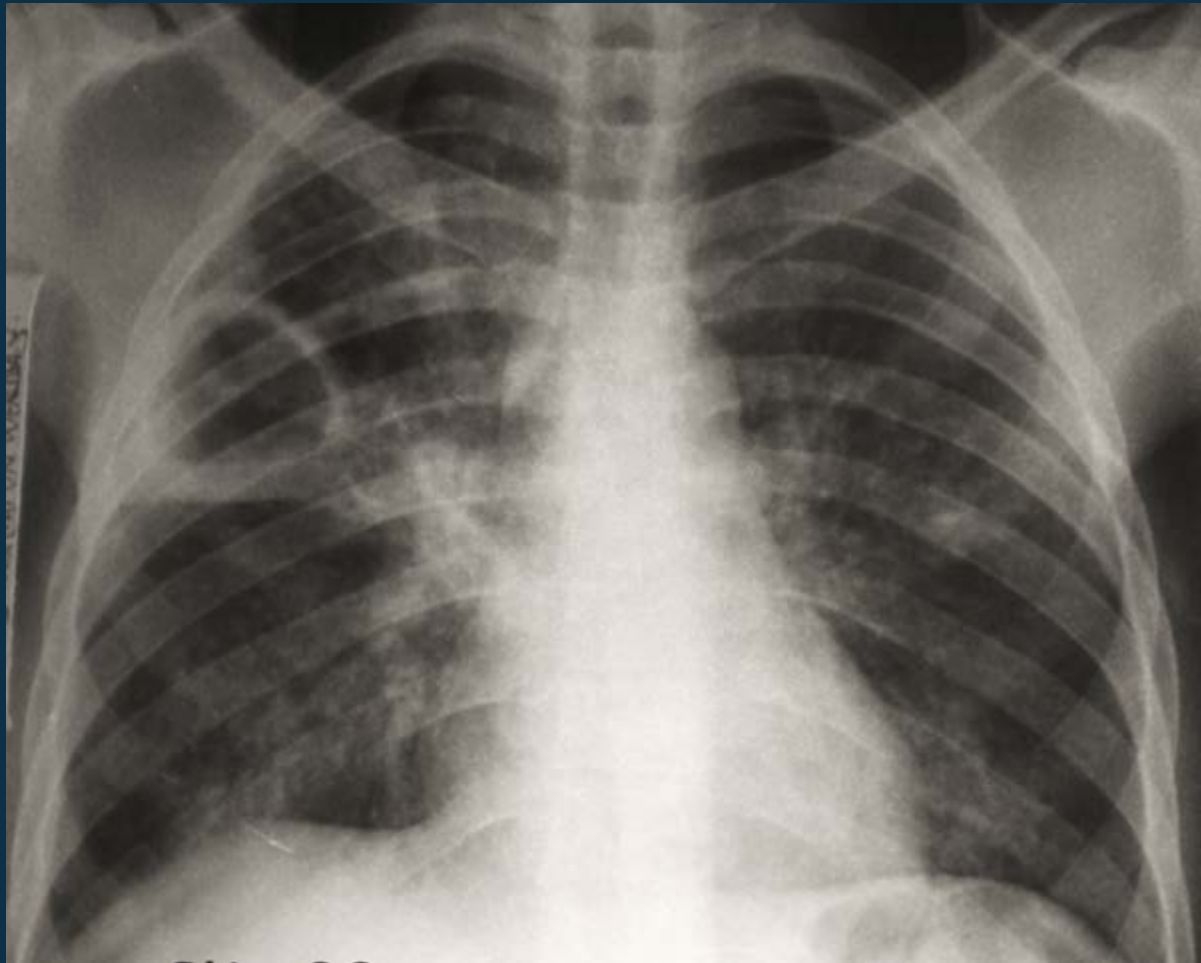
What do you see on this CXR ?

What is your diagnosis ?

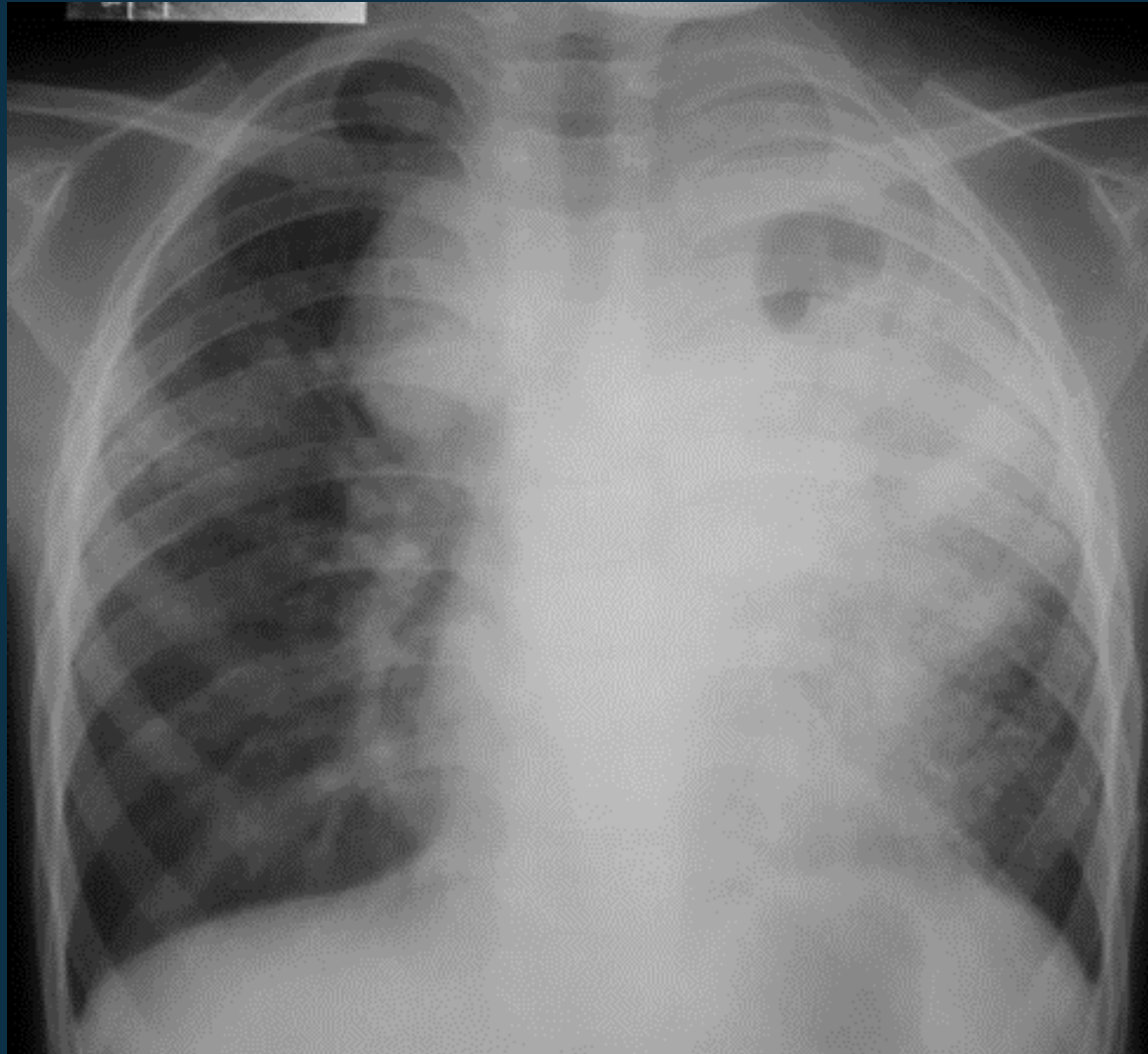
'Adult-type' TB disease :
alveolar consolidation with
multiple cavities
in the left upper lobe, and right
axillary nodular infiltrates

Note : association of 2 lesions of different ages is very typical of TB





Association of right cavitation
and left nodular infiltrates



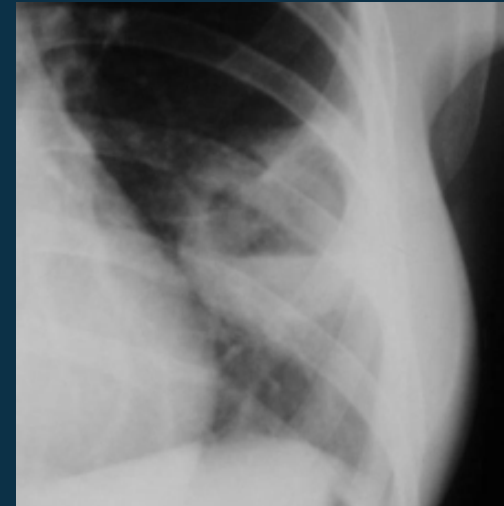
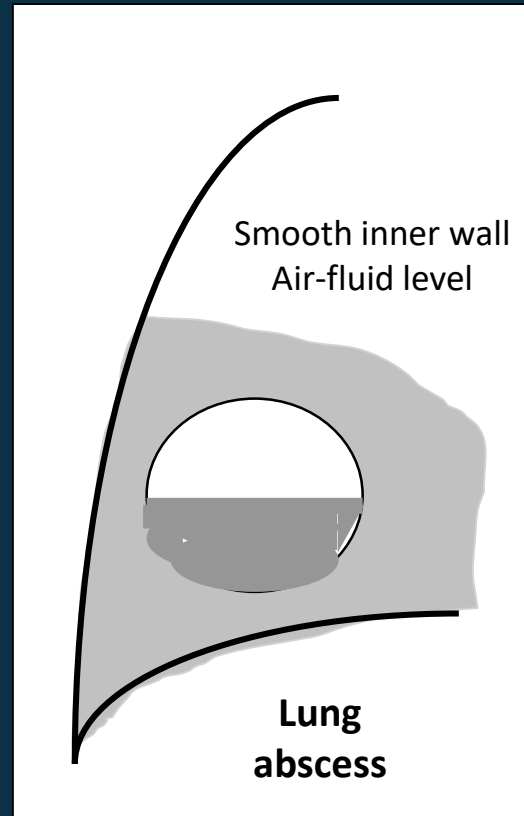
Left cavitary lung disease and right paratracheal lymph node enlargement

Cavities: differential diagnosis

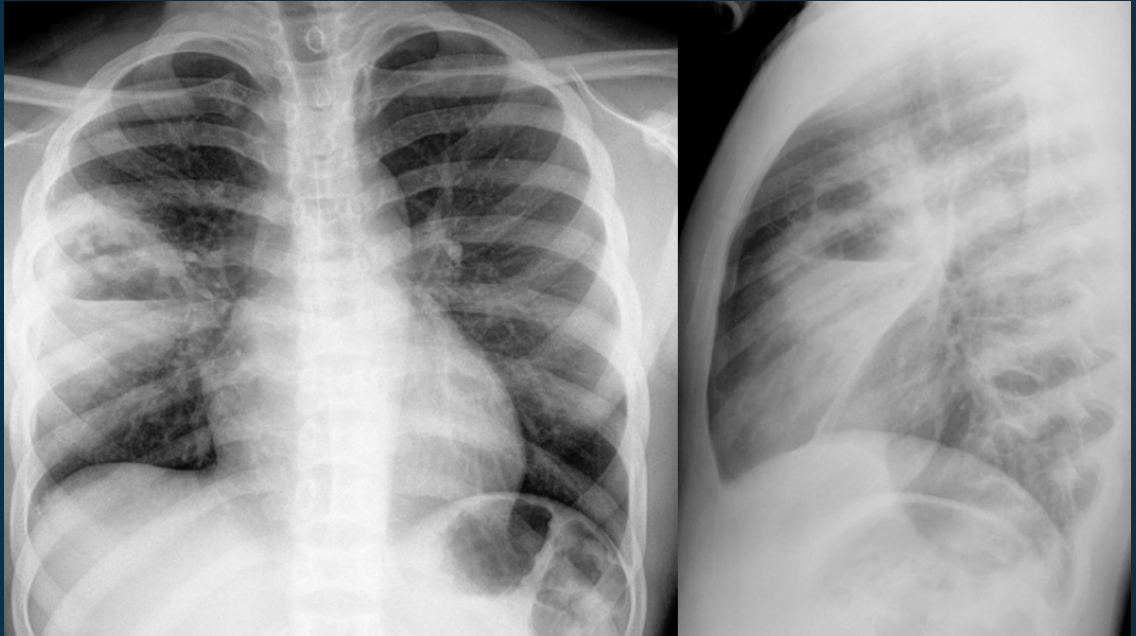
Differential diagnosis

Main aetiologies

1. Lung abscess (bacterial infection)
2. Pneumatocele (post staphylococcal or streptococcal pneumonia)



14 year old girl with sickle cell disease presenting with high fever and cough

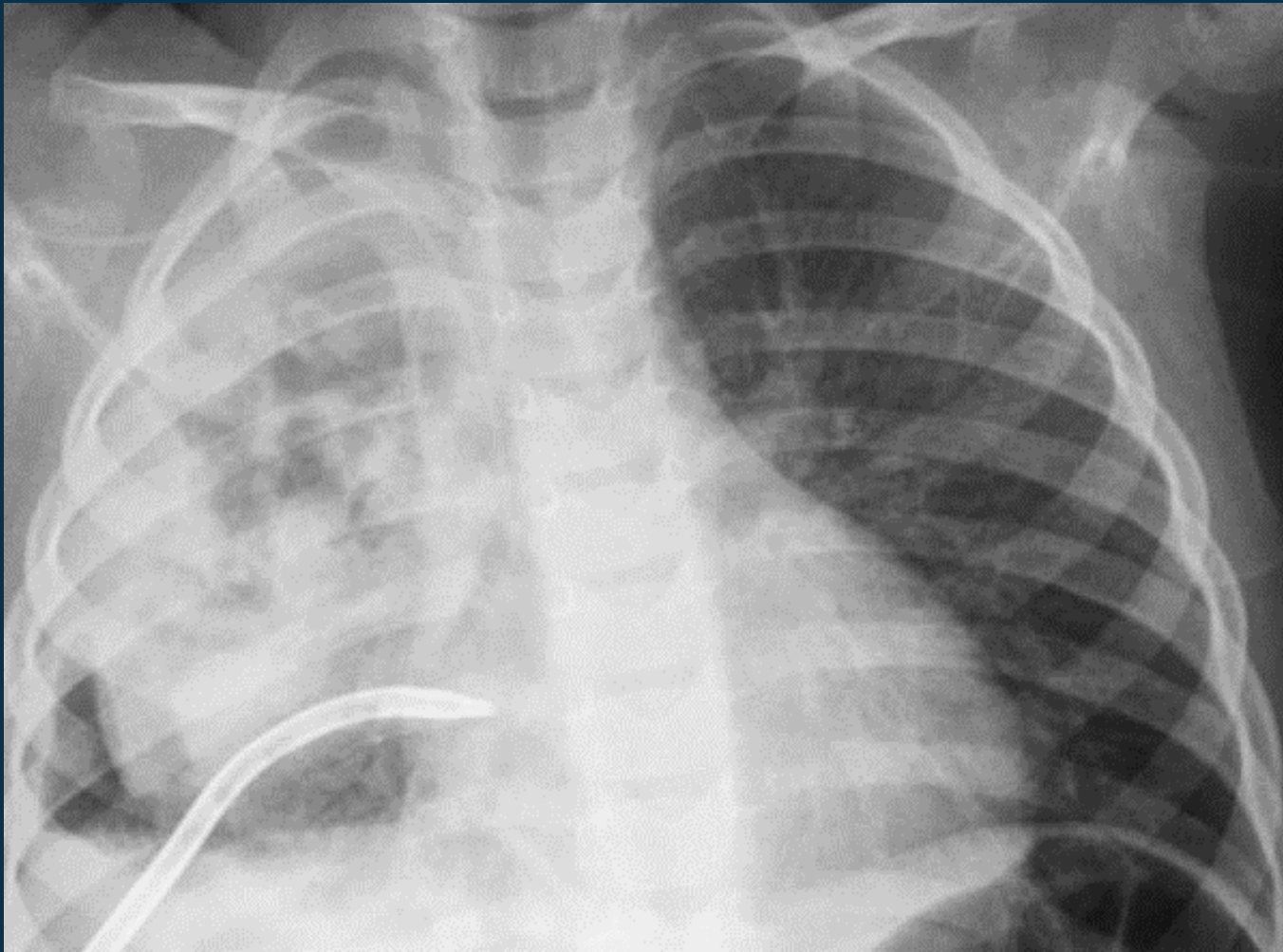


What do you see on these CXR ?

Parenchymal Abscess

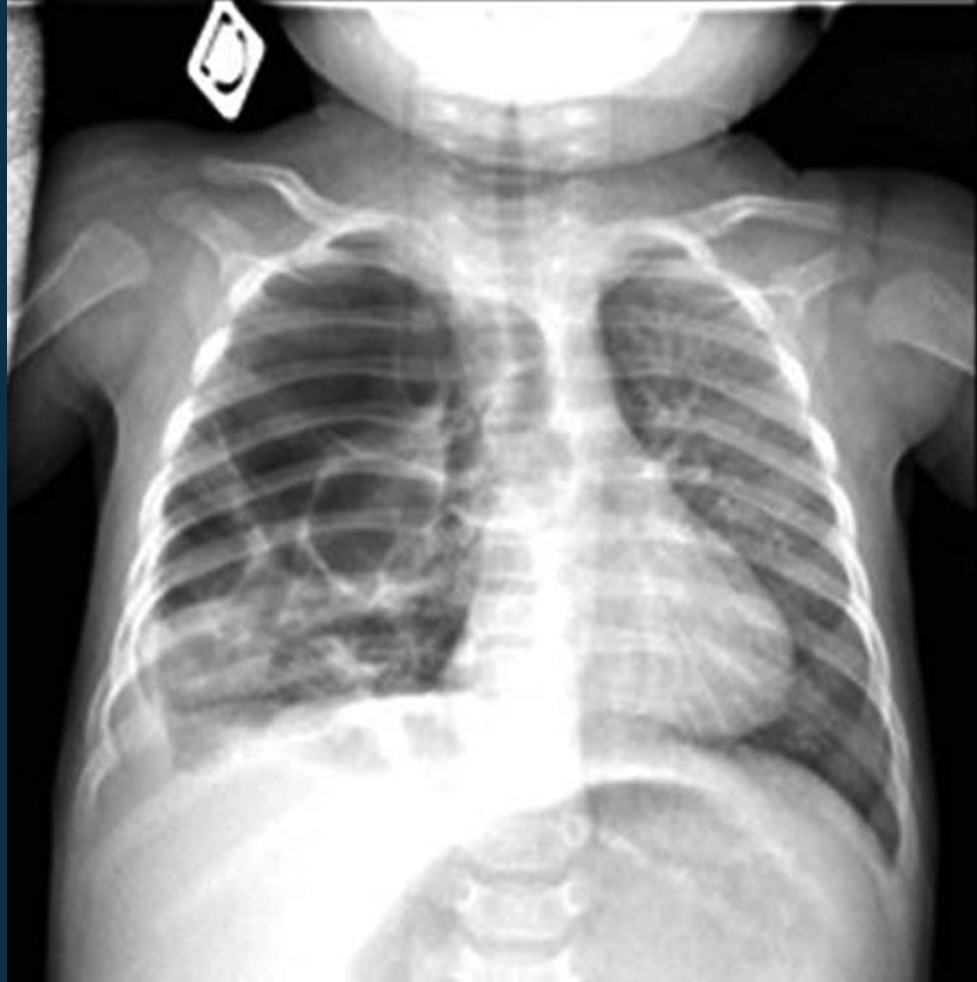- Parenchymal mass forming an acute angle with the chest wall
- Irregular wall thickening
- Air fluid level, similar length between frontal and lateral view
- Smear negative or GeneXpert negative

Cavities - differential diagnosis



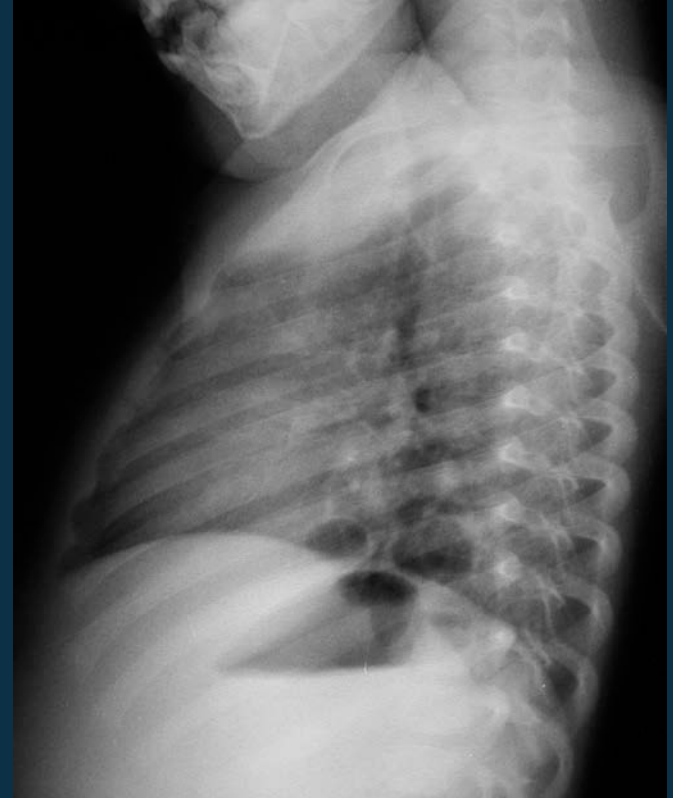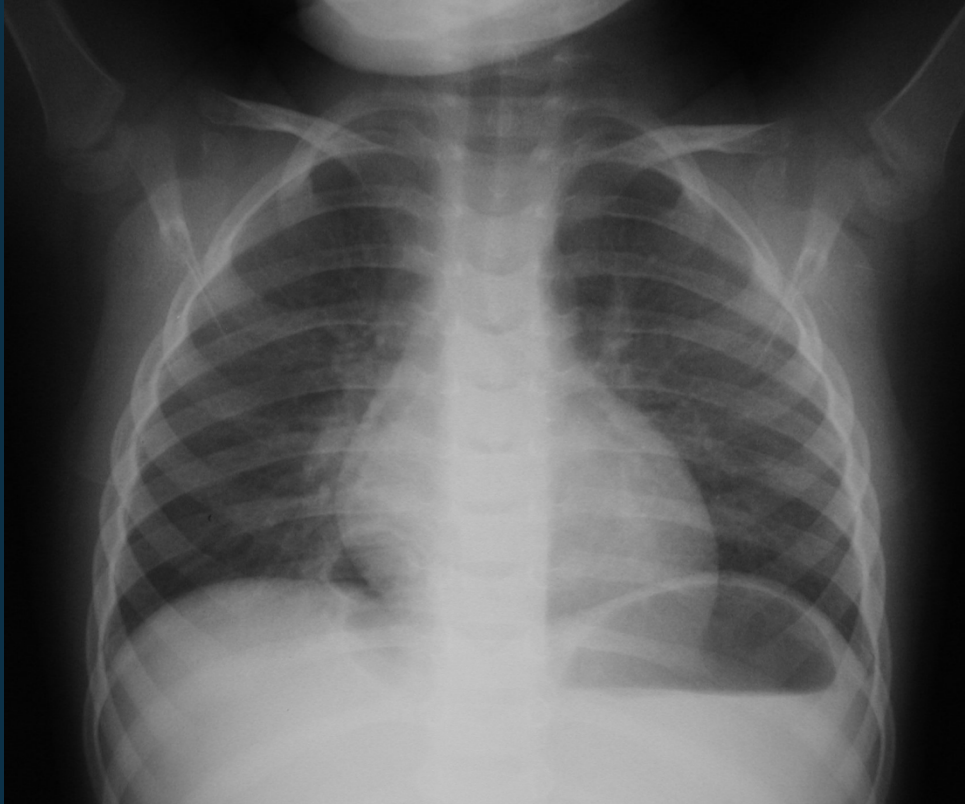
Cavity in the right lung,
necrotizing pneumonia and hydro-pneumothorax

Cavities - differential diagnosis



staphylococcal infection

Cavities - differential diagnosis

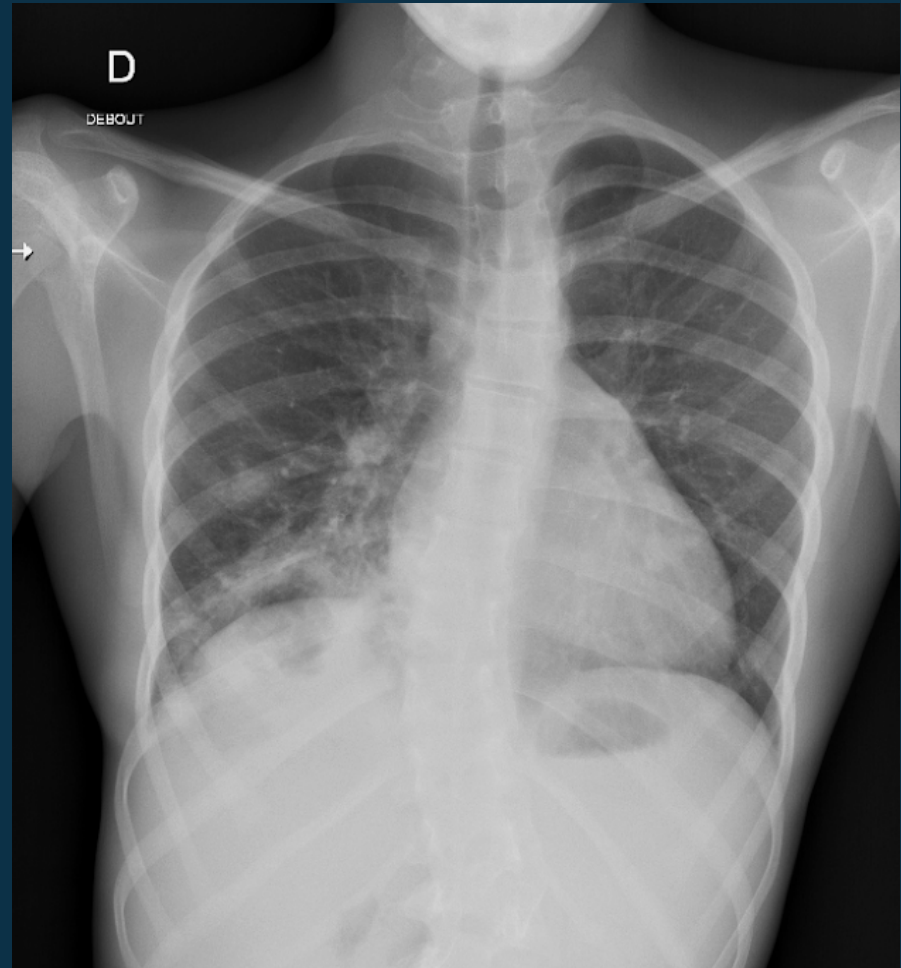


Pneumatocele:
thin walled air filled intraparenchymal cysts
(post staphylococcal or streptococcal pneumonia)

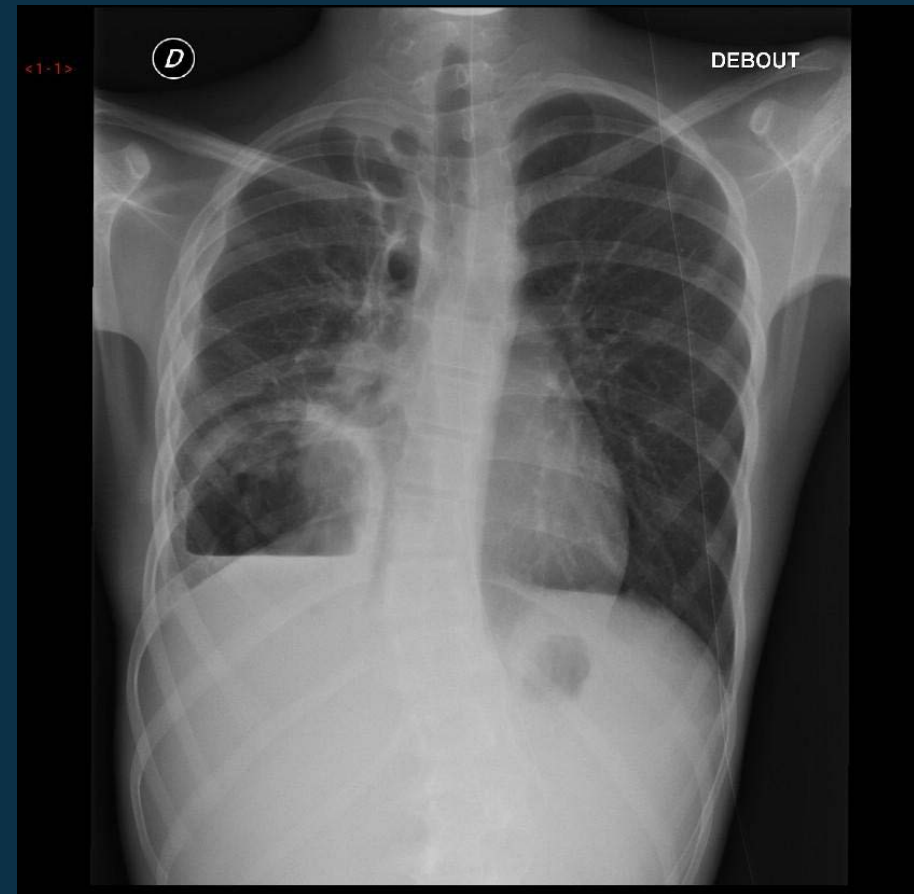
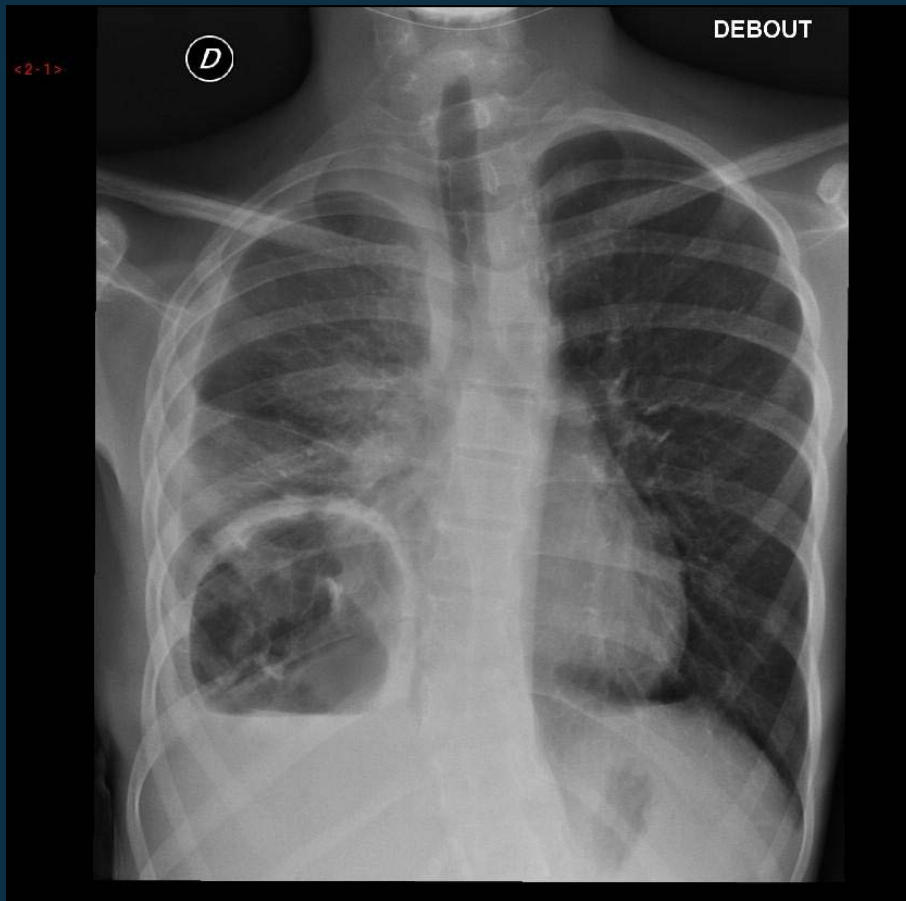
15 year old boy with fever,
cough, right thoracic pain
and diminished vesicular
breath sounds and crackles
inferior right lung

The right hemidiaphragm
is obscured, left lower
lobe opacity

A cavity is seen in this
opacity



....same boy a few days later

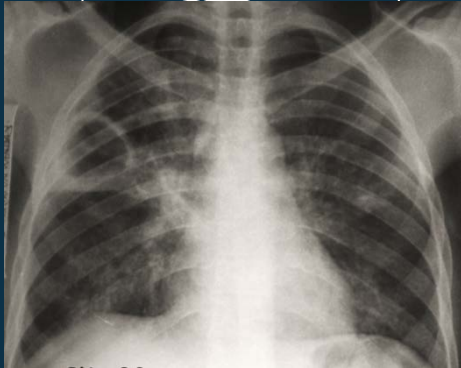

Excavated right inferior hemithorax opacity with air-fluid level and thick wall, suggesting a right inferior lobe abscess

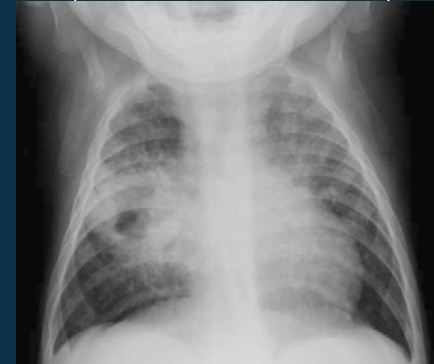Multiples images: hyperlucencies right apex

Key points TB cavities

Mainly older child >10 years
Post primary TB

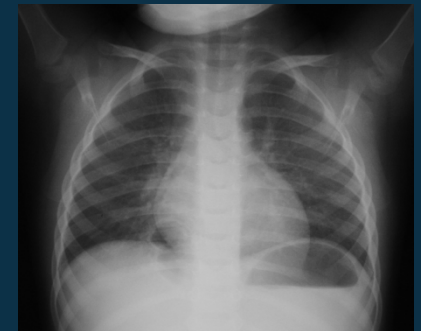
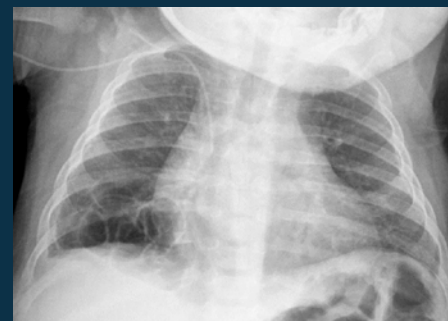
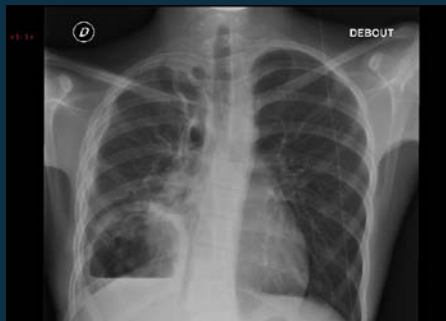

Less common under 5 years old
Progressive primary TB



Smear and GeneXpert usually positive if sputum available

Beware of many differential diagnoses



Lung abscess Pneumatocele

Staphylococcal infection

Learning Objectives

Module 2: diagnose TB on a paediatric CXR using a simplified reading tool at PHC level

Chap1. Introduction

Chap2. Enlarged lymph nodes

Chap3. Alveolar opacity of the lung tissue

Chap4. Airways compression

Chap5. Cavitation

Chap6. Pleural or pericardial effusion

Chap7. Miliary

Chap8. Reading tool in a nutshell

Pleural TB

1. Frequency increases with age: more frequent in children >10 years old and adolescents
 - . Commonly isolated pleural effusion
 - . TB is the most frequent cause of large pleural effusion in adolescence
2. Very uncommon in children under 5 years old
 - . Usually associated with parenchymal lesions or hilar adenopathy
3. Clinically: insidious onset of fever and shortness of breath

Smear neg in pleural fluid

What do you see on this CXR ?

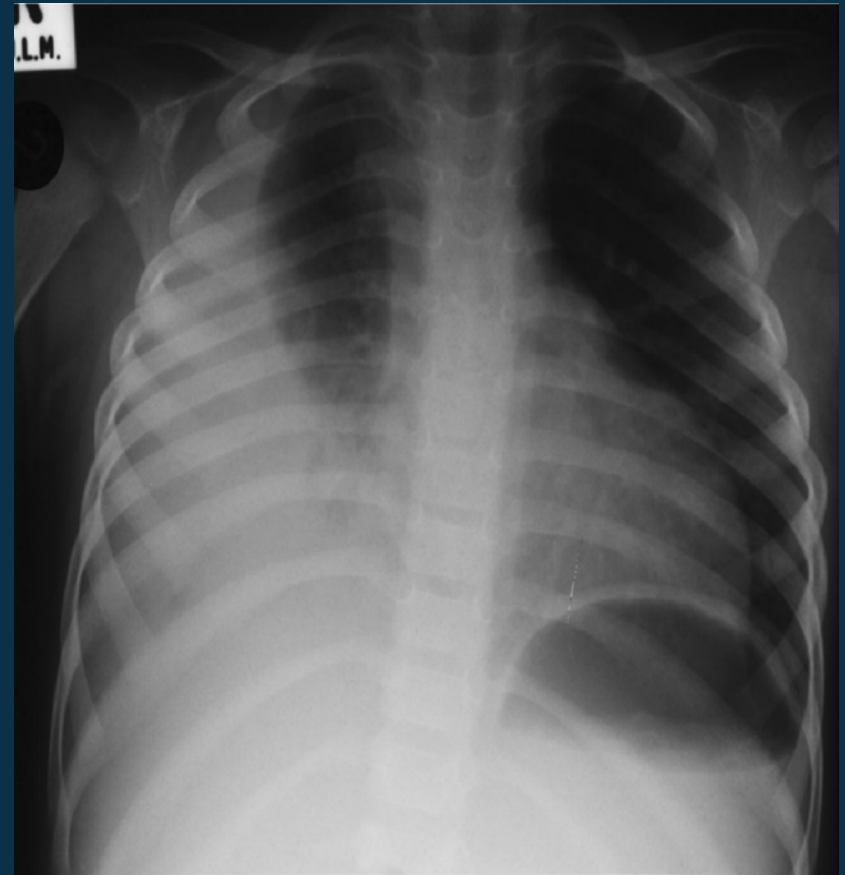
- . Circle 1: normal
- . Circle 2:
How are the lungs ?
 - . Large right pleural opacity.
 - . Homogeneous picture well defined, with concavity of the upper edge

How are the airways ?

- . No signs of compression

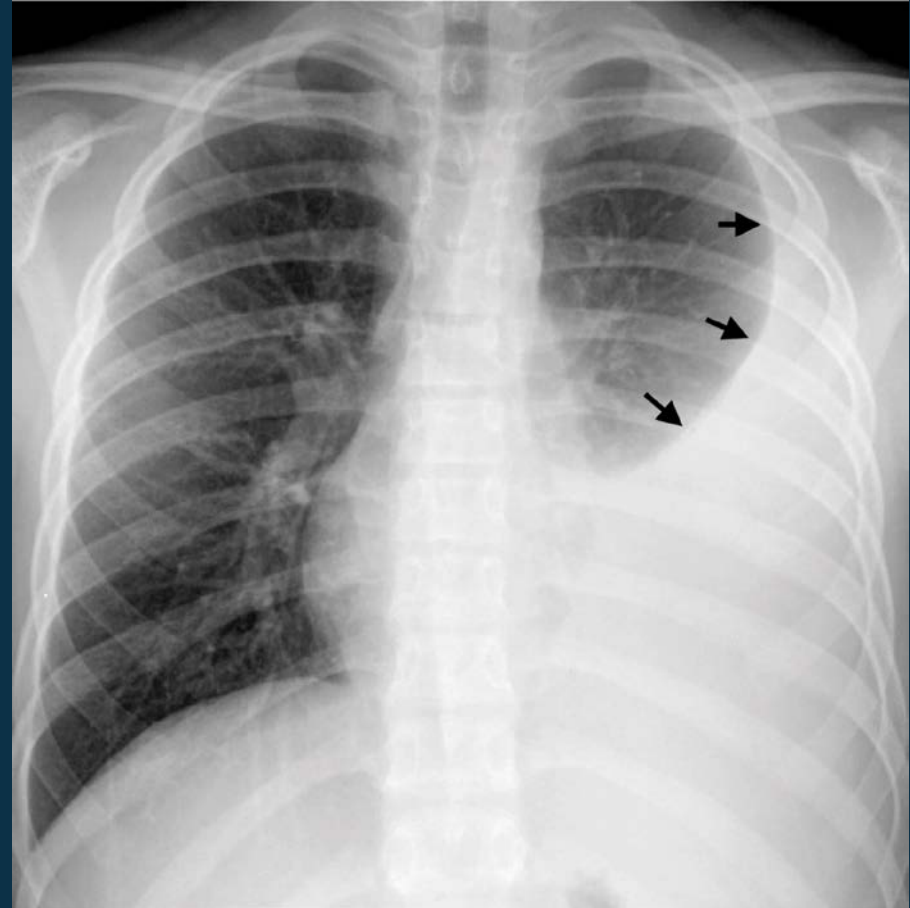What is your diagnosis ?

Uncomplicated right pleural TB



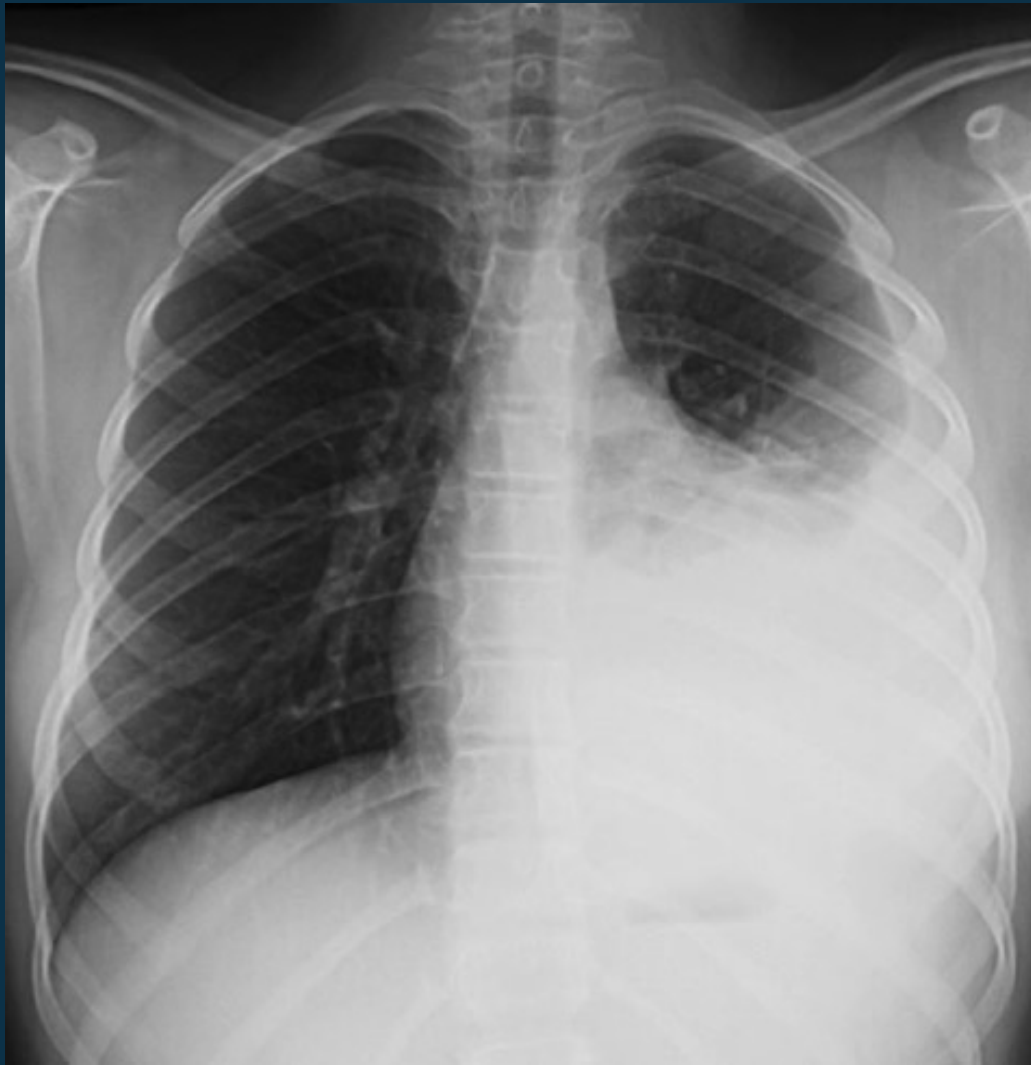What do you see on this CXR ?

- . First circle : disappearance of hemi-left diaphragm
- . Second circle:
How are the lungs ?
Large left pleural opacity



What is your diagnosis ?

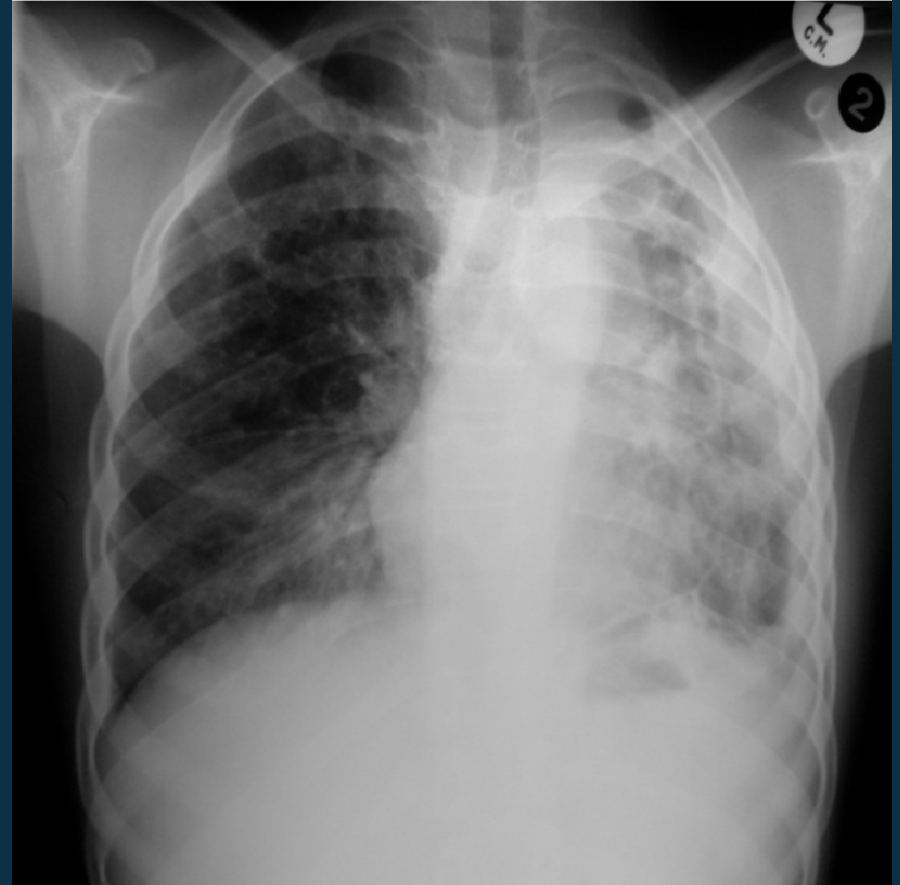
Uncomplicated left pleural TB



Left pneumonia with large pleural effusion

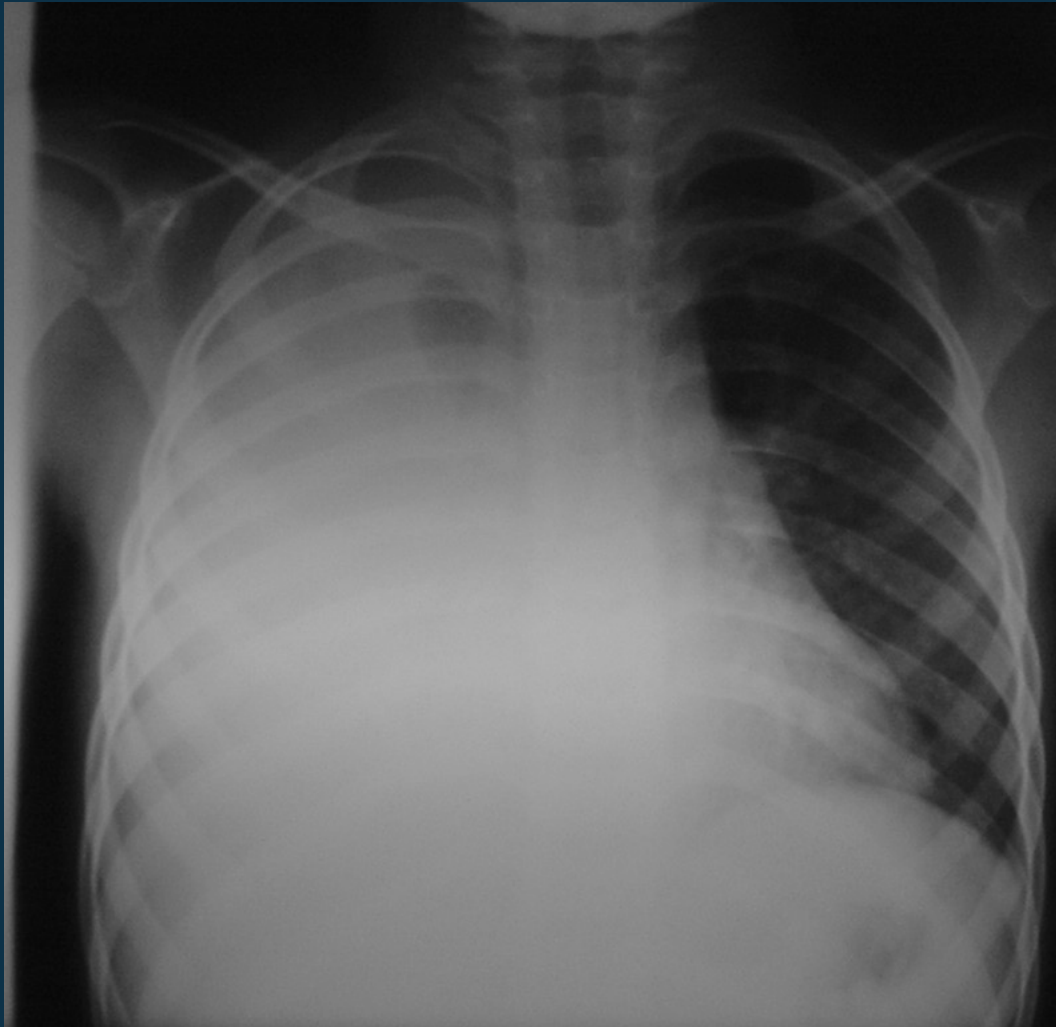
What do you see on this CXR ?

- . First circle: disappearance of left hemidiaphragm
 - . Second circle
- How are the lungs ?
Left pleural opacity and pleural thickening

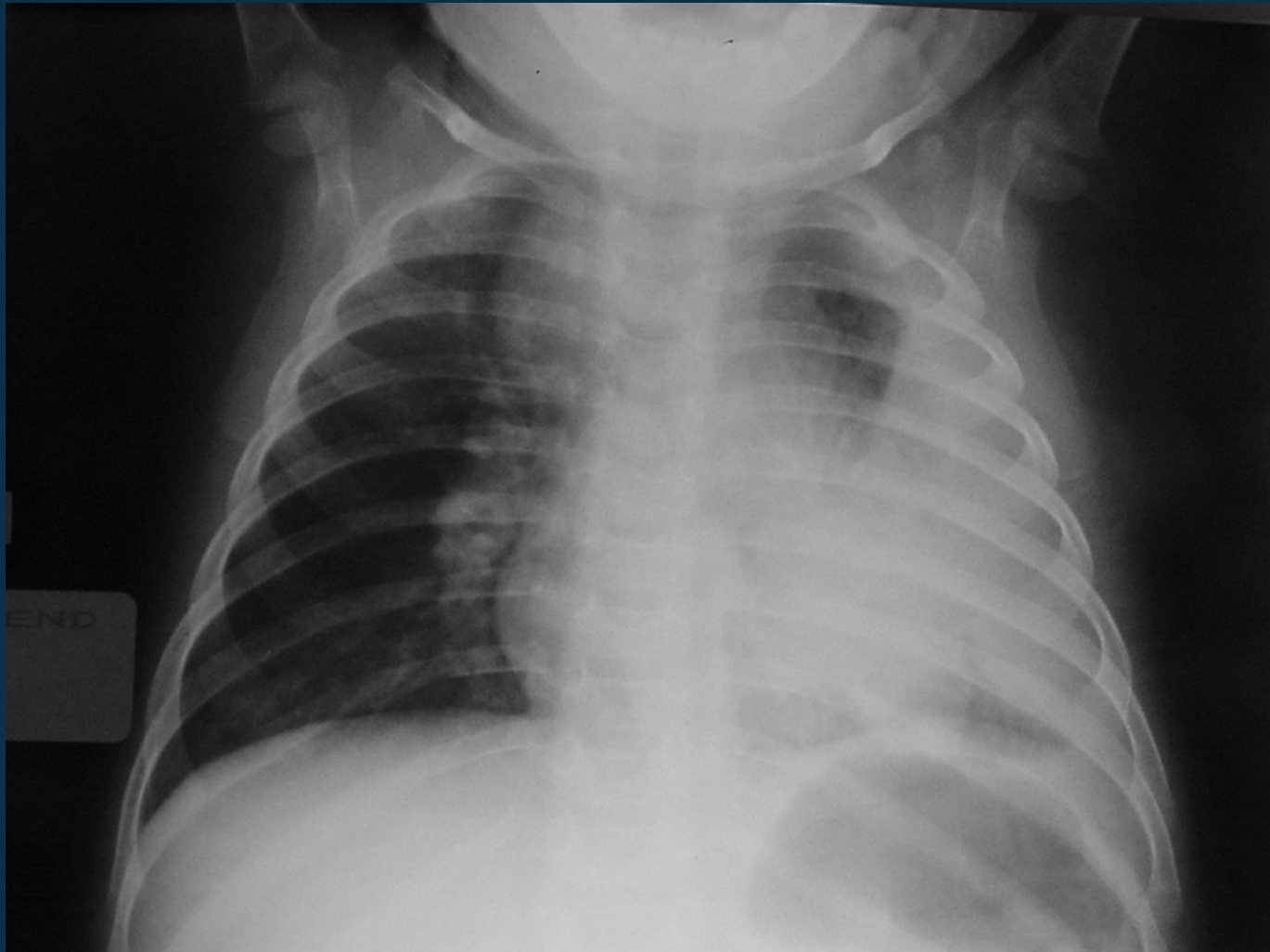


What is your diagnosis ?

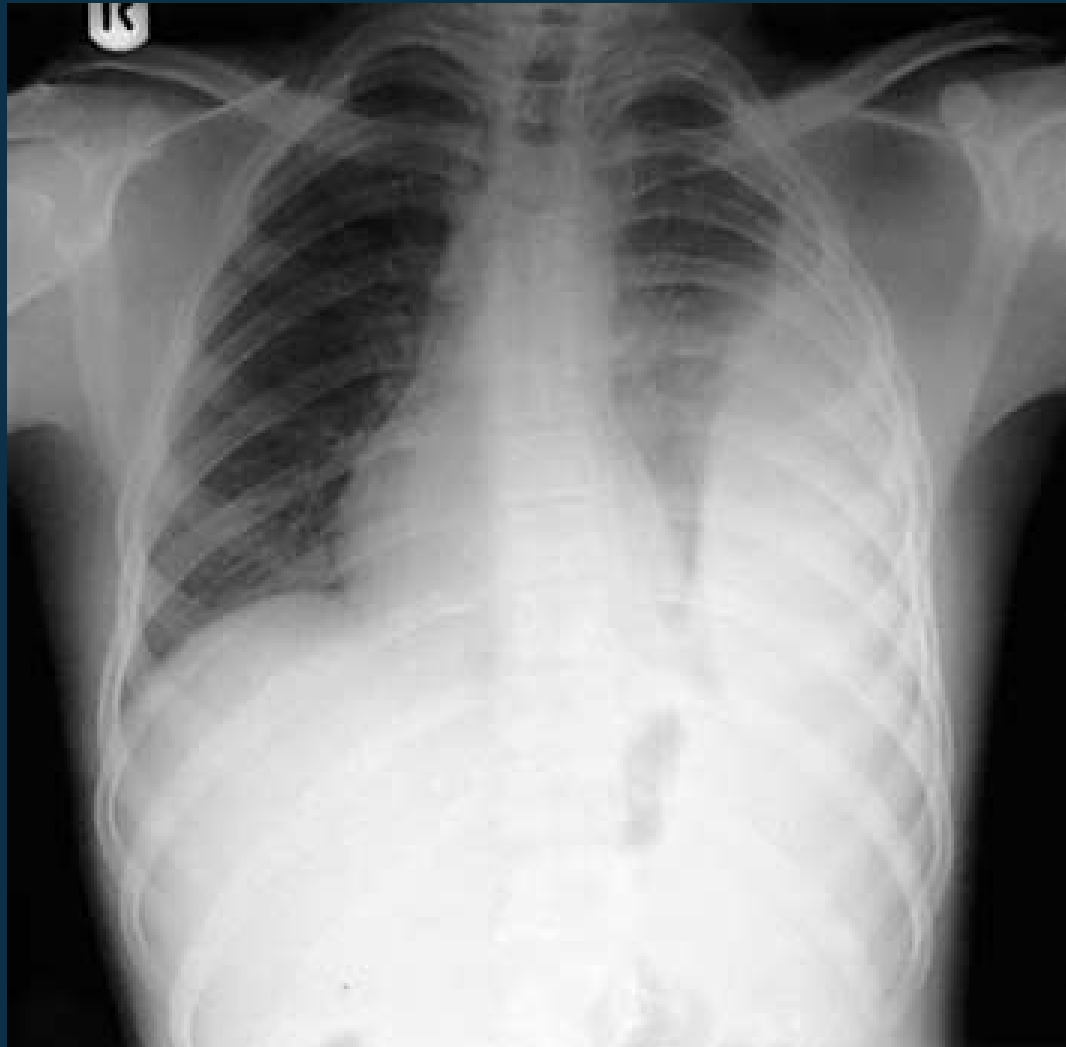Small left pleural effusion with complicated underlying TB: retraction , fibrosis, pleural thickness (probable important sequelae)



Large right pleural effusion with tracheal deviation



Paratracheal and hilar lymph nodes, left effusion



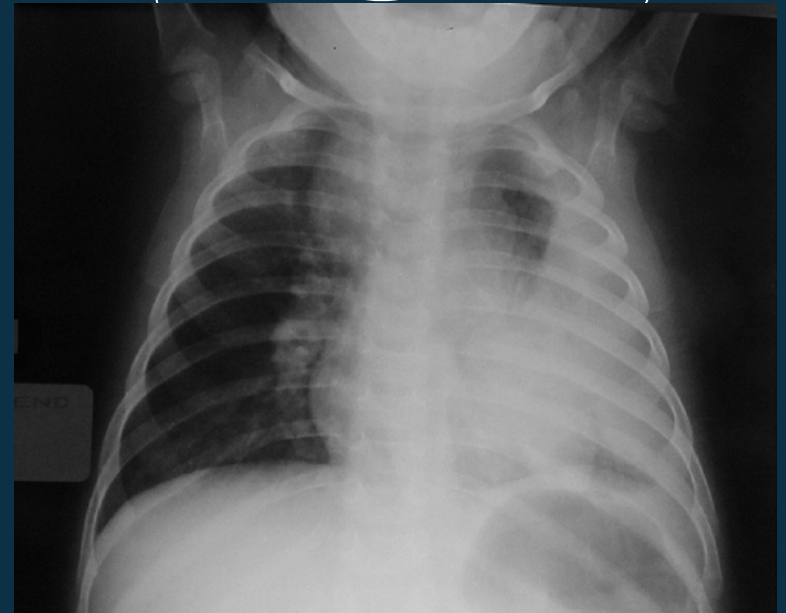
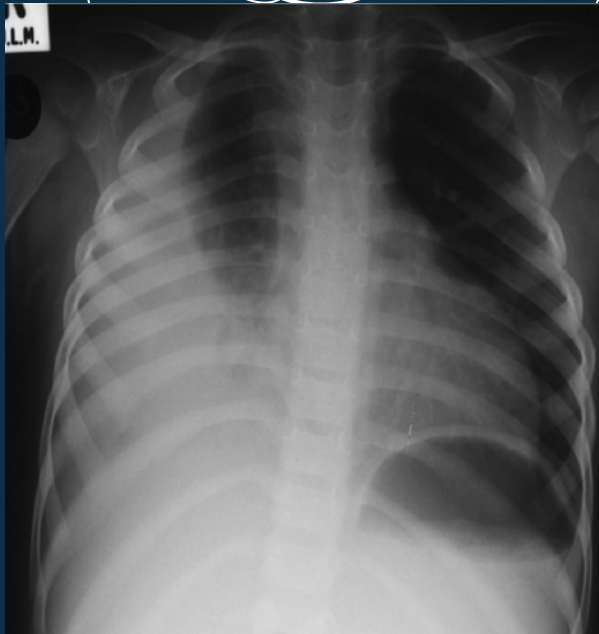
Pleural tuberculosis: there is a large left pleural effusion with some mediastinal shift.

Key points: pleural TB

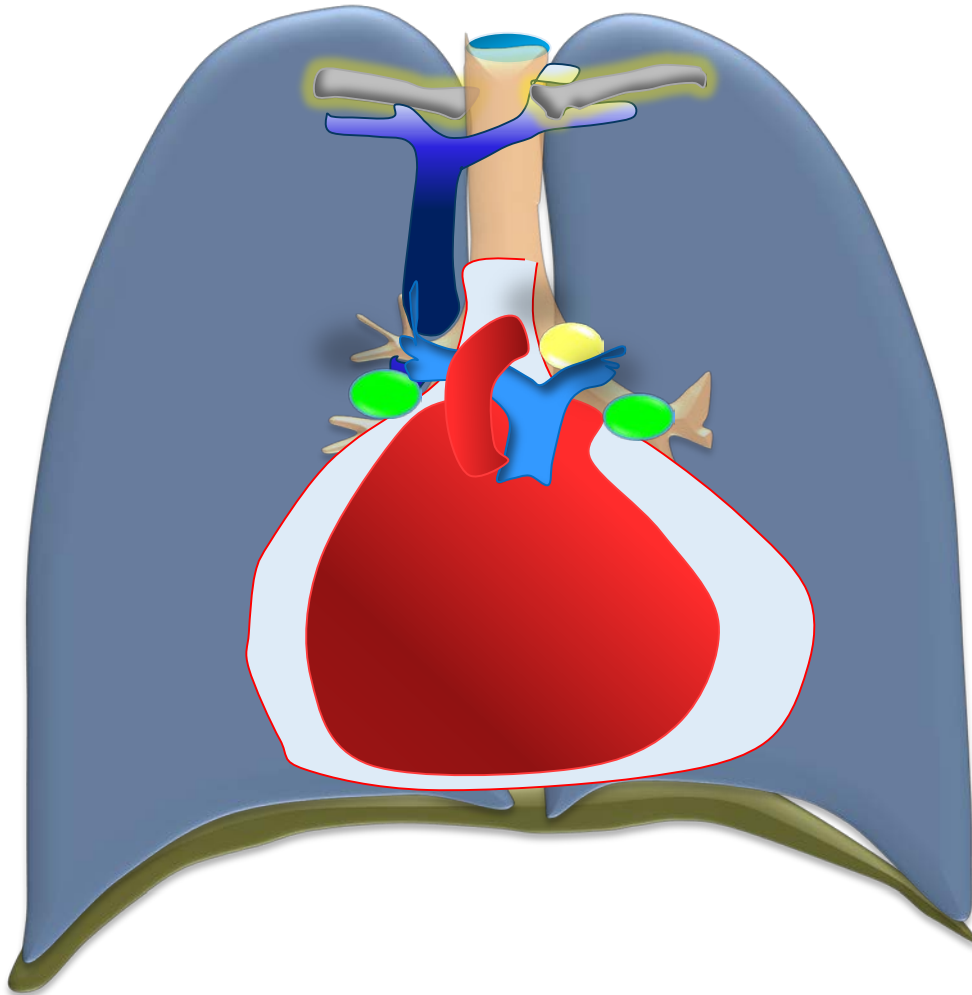
Smear neg in pleural fluid

Frequent in children >10 years old Isolated

less common under 5 years old



Pericardial TB



1. Not very common (less than 1% of the cases)
2. Caused by direct extension of subcarinal lymph nodes into the posterior pericardial sac
3. Can come from miliary spread
4. CXR: large 'water bottle' shape heart

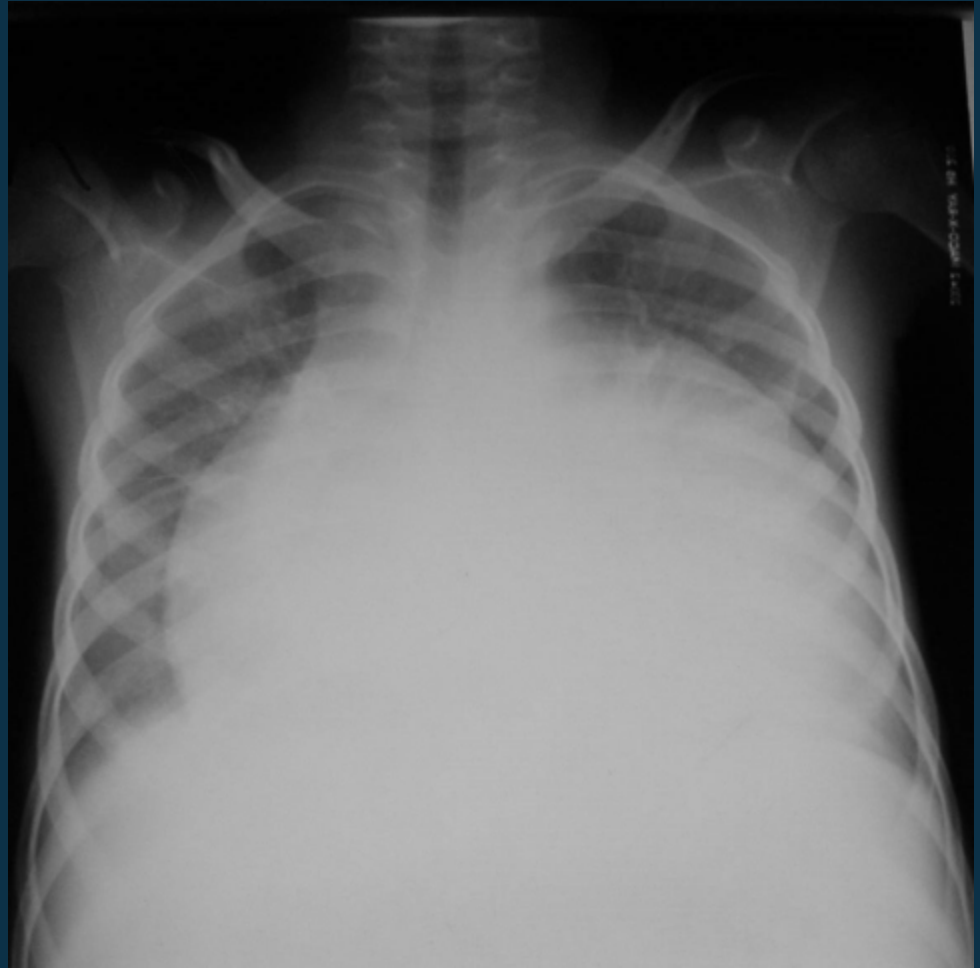
What do you see on this CXR ?

How is the heart ?

- . Cardiomegaly
- . Large 'water bottle' shaped heart

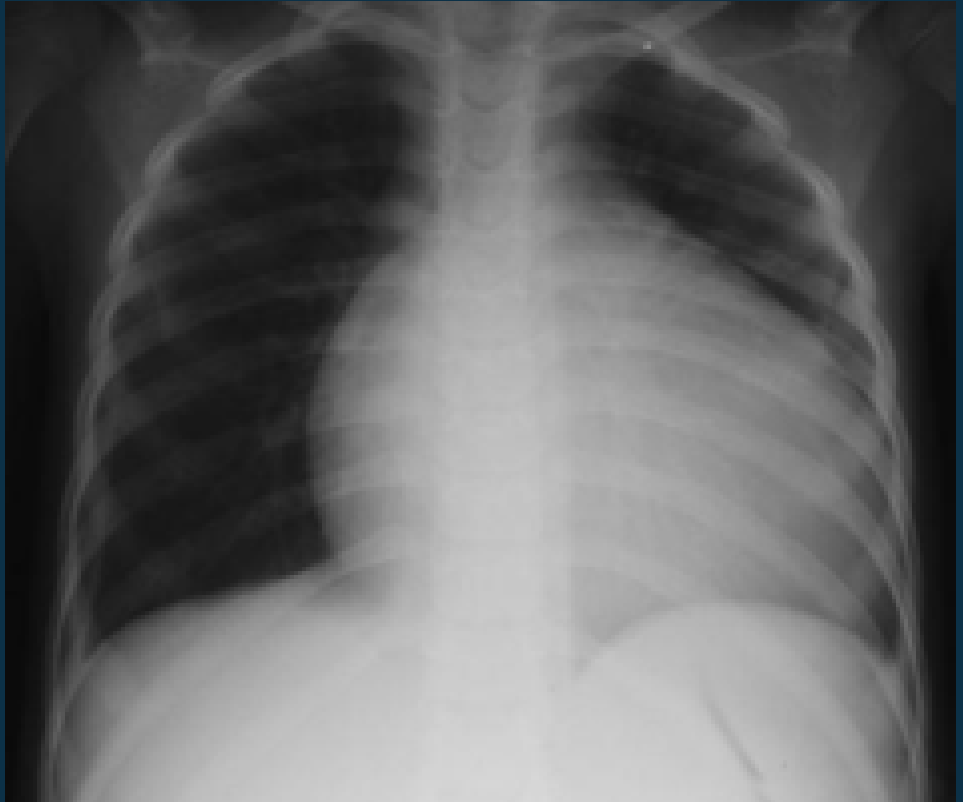What is your diagnosis ?

Pericardial effusion



What do you see on this CXR ?

- . Large 'water bottle' shaped heart (cardiomegaly)



What is your diagnosis ?

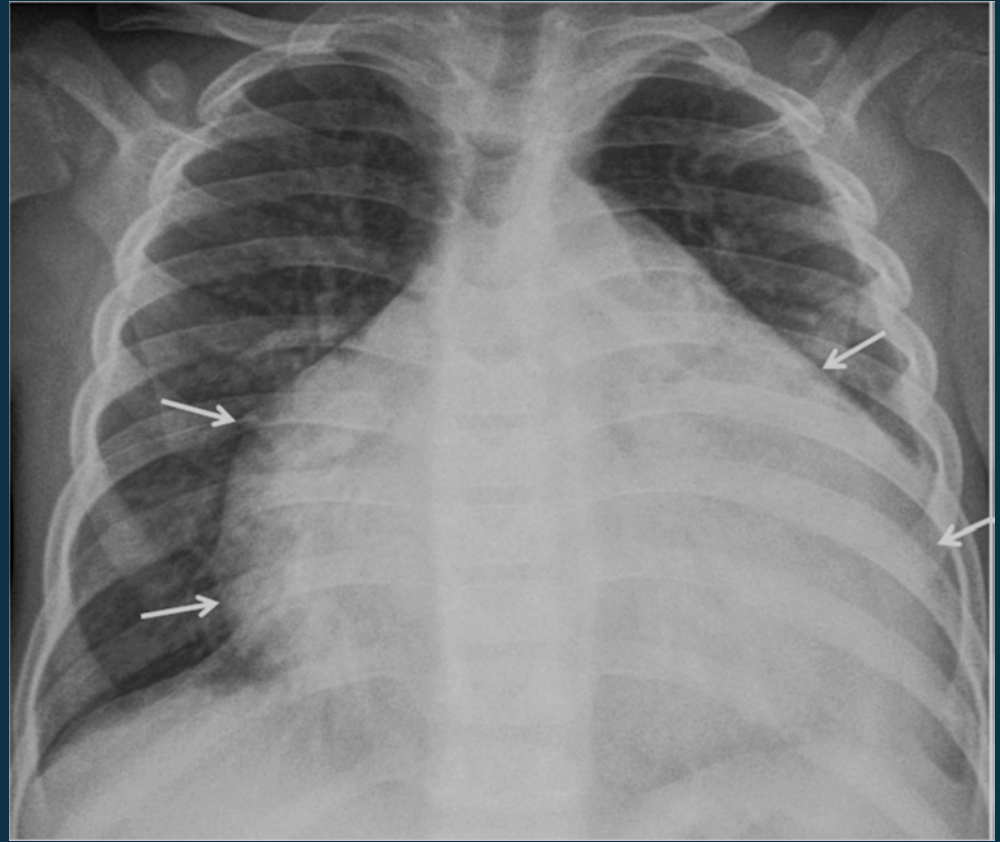
Pericardial effusion

What do you see on this CXR ?

- Globular enlargement of the cardiac silhouette
- Large 'water bottle' shaped heart

What is your diagnosis ?

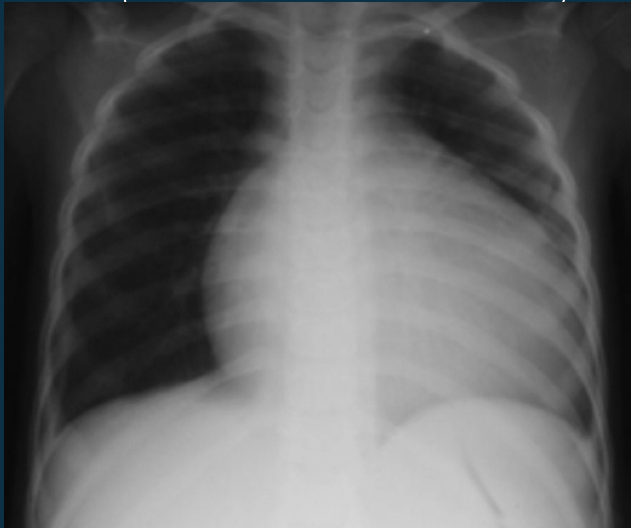**Pericardial effusion
in a 6 year-old boy**



Anteroposterior chest radiograph

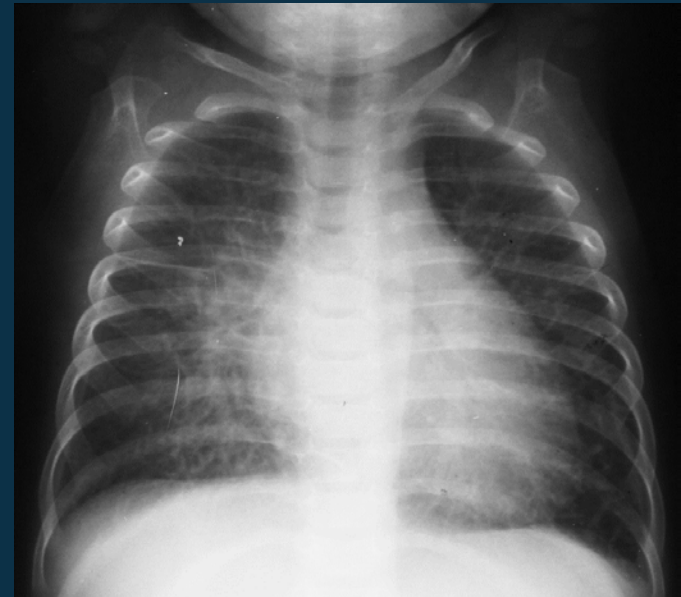
Key points: pericardial effusion

More frequent under 5 years old



A large 'water bottle'
shaped heart

Beware of differential diagnosis:
Many other causes of
cardiomegaly



Congestive heart failure with
pulmonary oedema (as in
myocarditis)

Learning Objectives

Module 2: diagnose TB on a paediatric CXR using a simplified reading tool at PHC level

Chap1. Introduction

Chap2. Enlarged lymph nodes

Chap3. Alveolar opacity of the lung tissue

Chap4. Airways compression

Chap5. Cavitation

Chap6. Pleural or pericardial effusion

Chap7. Miliary

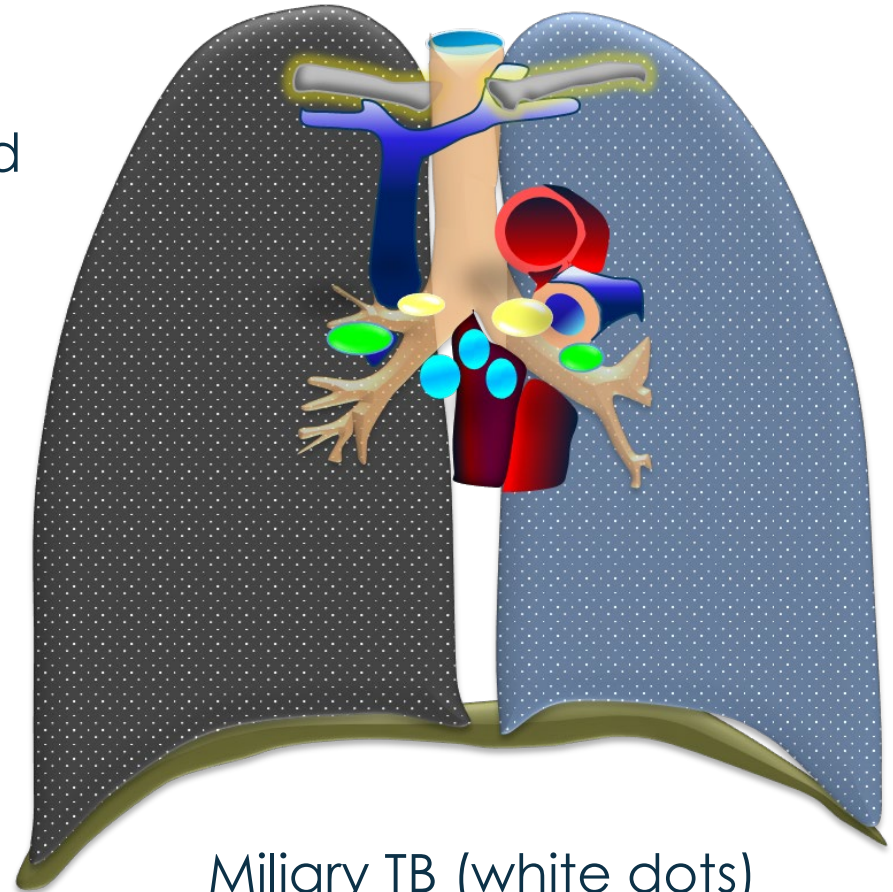
Chap8. Reading tool in a nutshell

Miliary TB

1. Haematogenous dissemination : complication of another pre-existing disease entity (or it may occur in isolation)
2. Development of granulomas in all the involved organs (lungs, liver, spleen, bones, meninges...)
3. Miliary infiltrates are the only pathognomonic finding for TB on CXR
 - . usually in the younger age group (immature immunity)
 - Bilateral and evenly distributed millet seed $\leq 2\text{mm}$
 - non-calcified nodules
4. Clinically : Severe dyspnoea, worsening condition, often with TB meningitis
5. Smear neg often GeneXpert neg

Typical innumerable even-sized miliary lesions (millet seed $\leq 2\text{mm}$ non-calcified nodules), scattered in both lungs

The lesions are bilateral and evenly distributed into the periphery of the lung



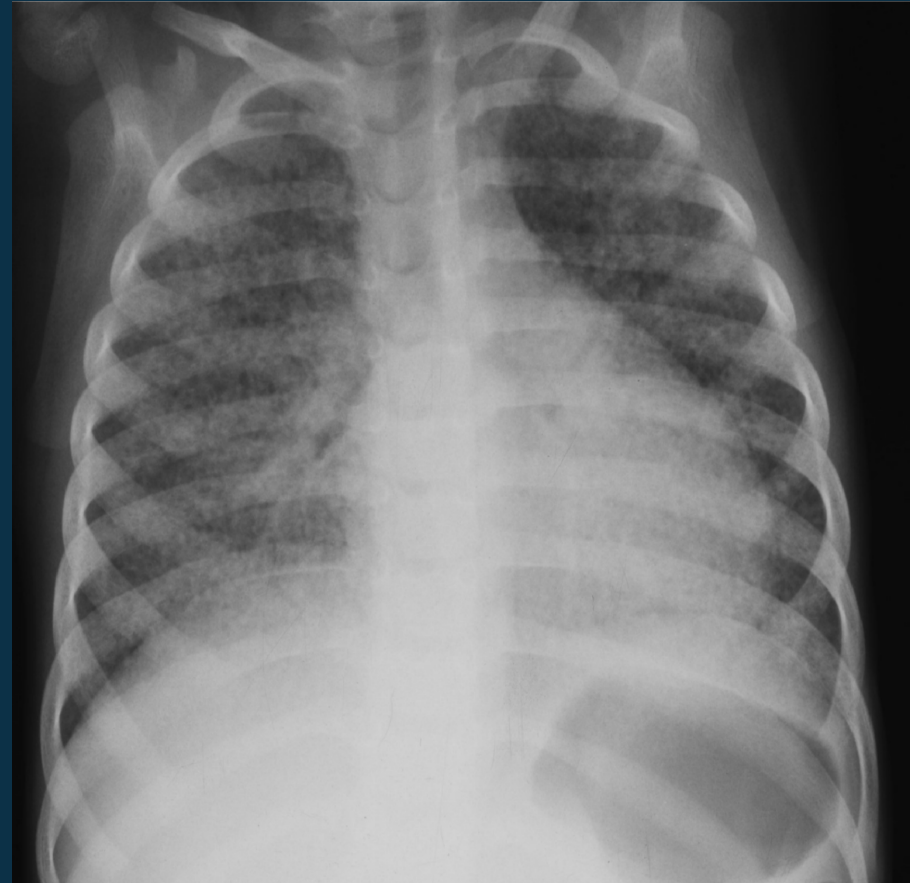
Miliary TB (white dots)
with lymphadenopathy

What do you see on this CXR ?

- . First circle: normal
 - . Second circle
- Lungs :
Bilateral micronodular opacities
All of equal size
In all the lobes of the lung

What is your diagnosis?

**Classic bilateral diffuse
micro nodulapattern
consistent with miliary TB.
These children often have
accompanying meningitis**



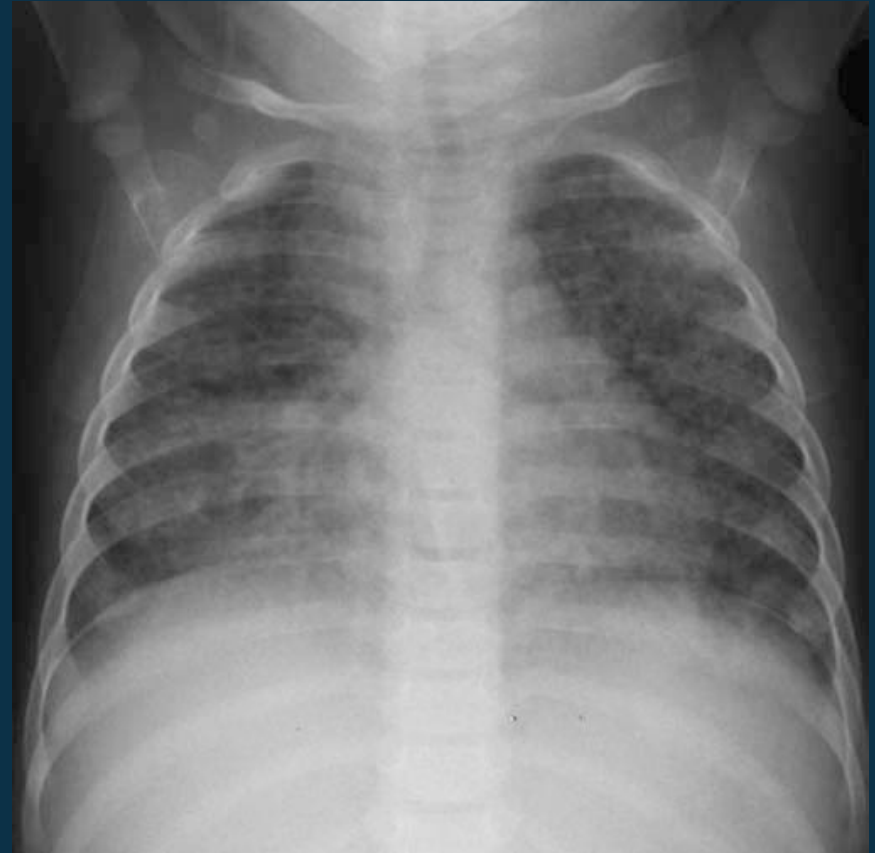Intrathoracic childhood TB : miliary TB

In countries with high incidence of TB and HIV,
if CXR shows miliary pattern

Most likely diagnosis is TB

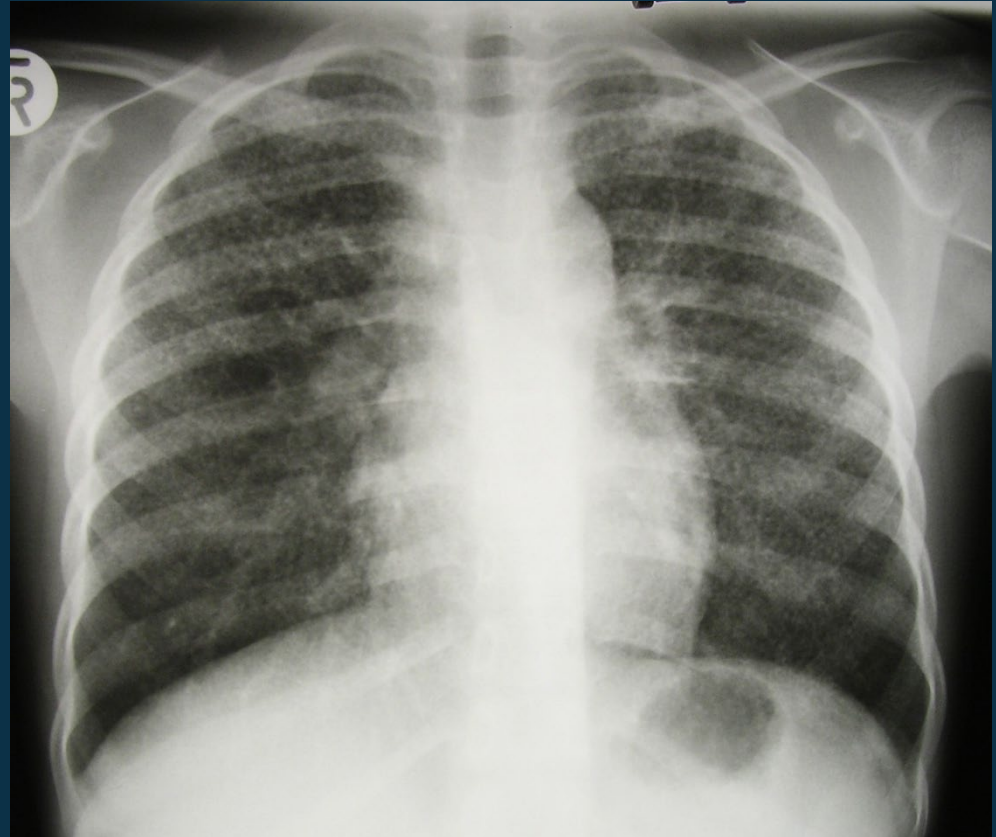
Lymph node disease plus
disseminated disease: military

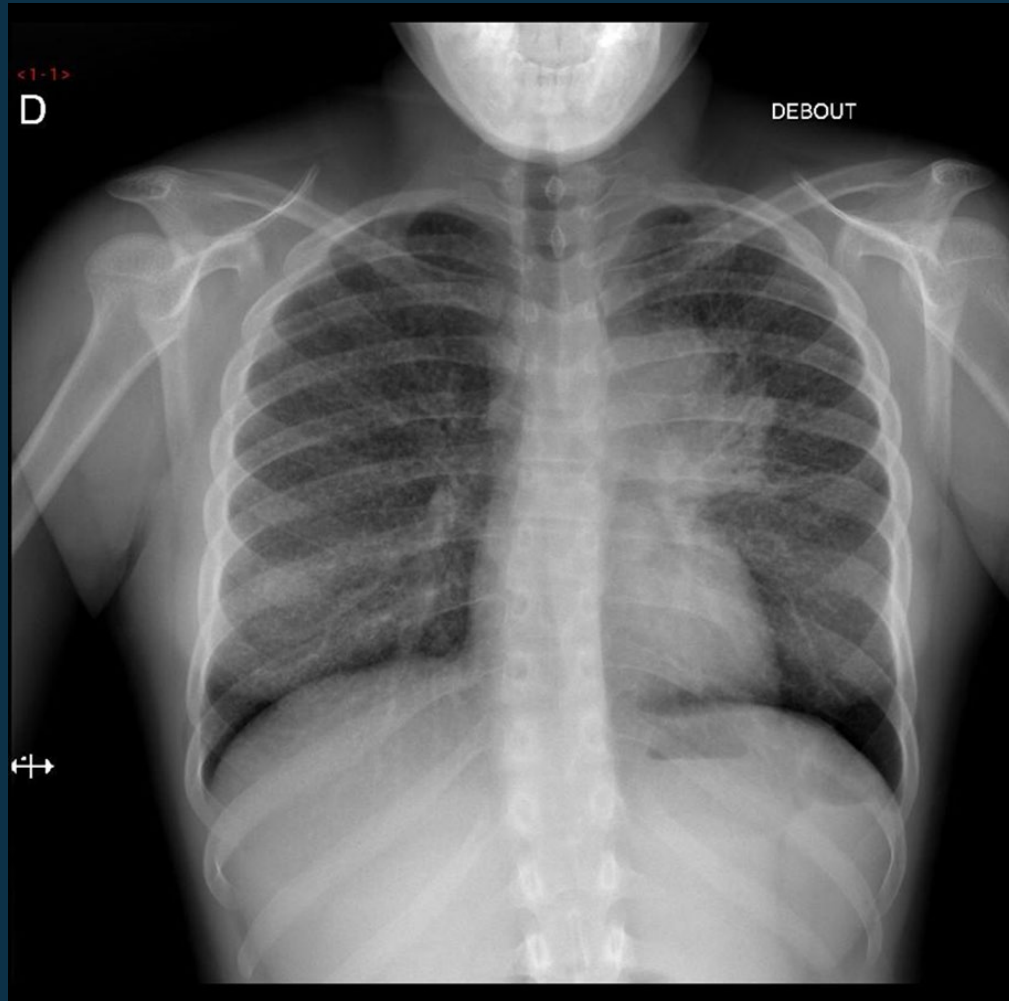
large right-sided paratracheal
glands shifting the trachea to
the left with haematogenous
disease spread (millet seed
nodular opacities)



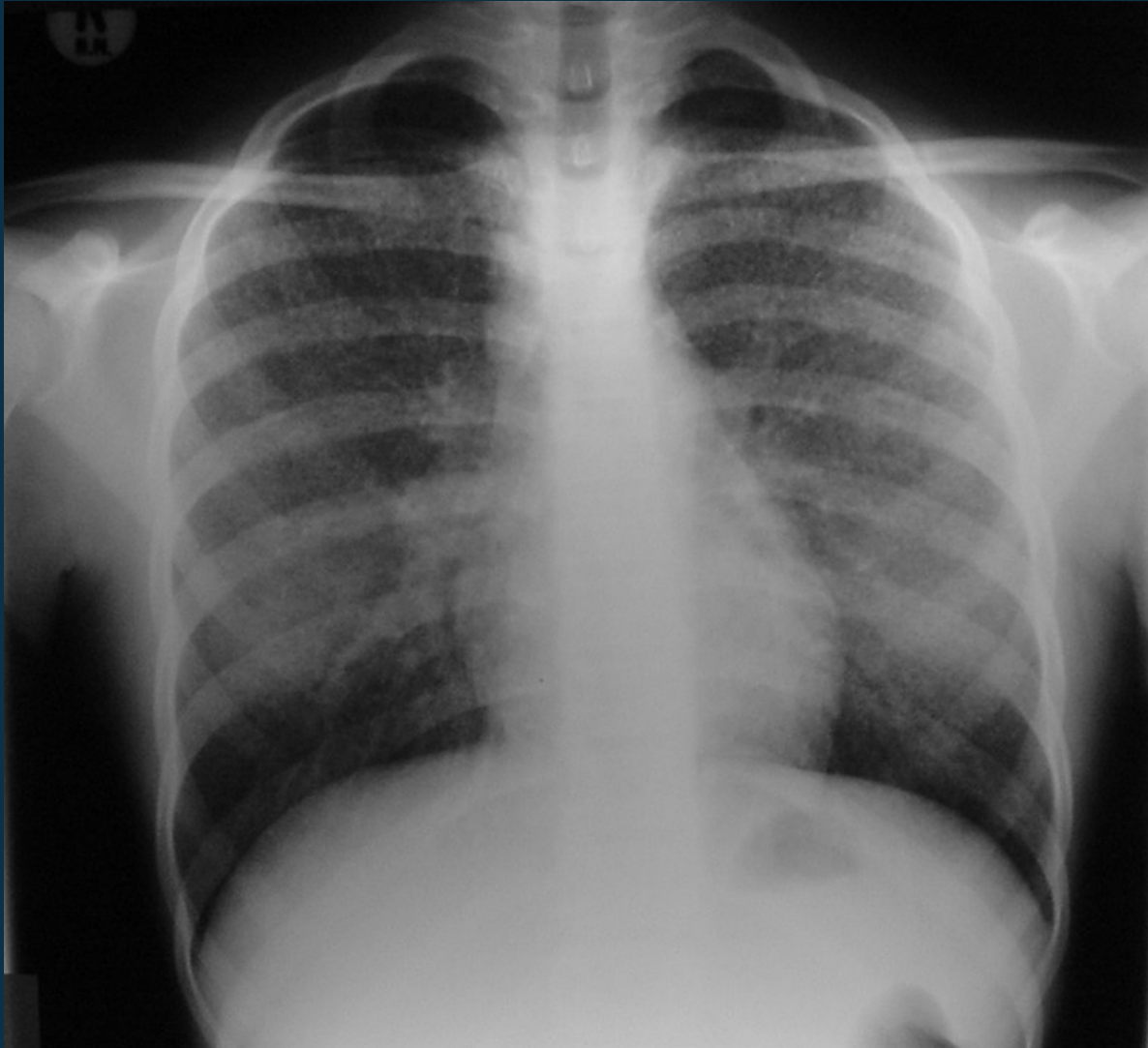
Lymph node disease plus
disseminated disease: military

Hilar lymph node enlargement
with haematogenous disease
dissemination (millet seed
nodular opacities)





Miliary TB : micronodular opacities disseminated in both lungs
Left opacity erasing the upper right heart border and the aortopulmonary window
Infiltration in the surrounding tissue



Miliary TB

Miliary Differential diagnosis

Learning Objectives

Module 2: diagnose TB on a paediatric CXR using a simplified reading tool at PHC level

Chapter 1: Introduction

Chapter 2: Enlarged lymph nodes

Chapter 3: Alveolar opacity of the lung tissue

Chapter 4: Airways compression

Chapter 5: Cavitation

Chapter 6: Pleural or pericardial effusion

Chapter 7: Miliary

Chapter 8: Reading tool in a nutshell

Learning Objectives

Module 2: diagnose TB on a paediatric CXR using a simplified reading tool at PHC level

Chap1. Introduction

Chap2. Enlarged lymph nodes

Chap3. Alveolar opacity of the lung tissue

Chap4. Airways compression

Chap5. Cavitation

Chap6. Pleural or pericardial effusion

Chap7. Miliary

Chap8. Reading tool in a nutshell

Key points - How to diagnose TB on a paediatric CXR using a simplified reading tool that identifies 6 suggestive CXR patterns

CXR remains the first imaging tool for primary screening of TB in children because respiratory samples are more difficult to obtain and are usually smear-negative. CXR can be highly suggestive.

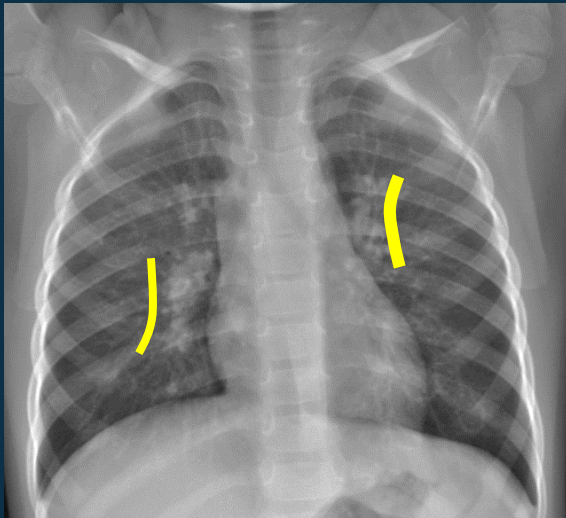
Key points : how to diagnose TB on a paediatric CX using a simplified reading tool that identifies 6 suggestive CXR patterns

6 abnormalities on a paediatric CXR that are highly suggestive of TB: always look for them using a systematic approach

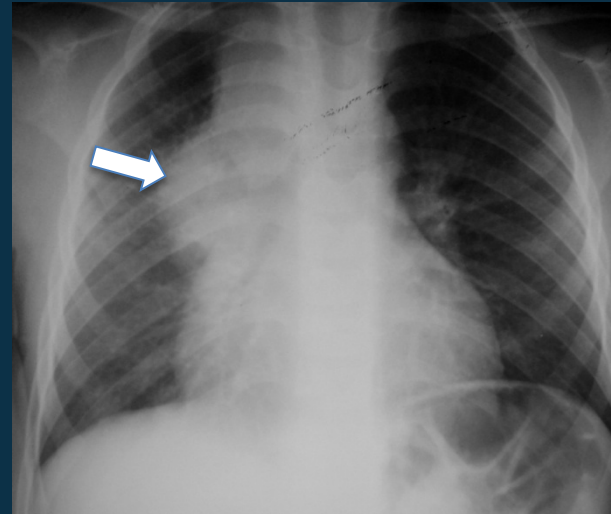
1. Enlarged lymph nodes (lateral view required) :
CXR can detect mediastinal and hilar lymph node enlargement.

The most common CXR appearance in young children with intrathoracic TB = lymphadenopathy

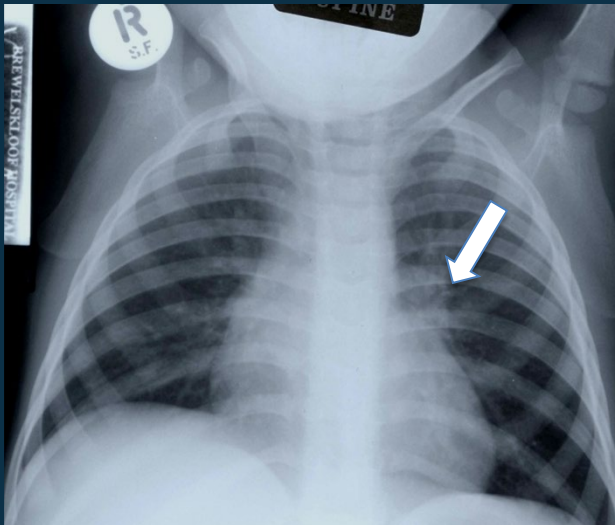
CXR can detect mediastinal lymph node enlargement



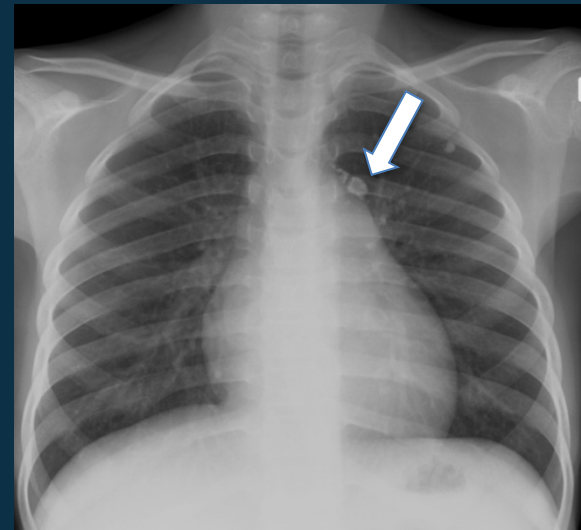
Normal



Right hilar lymphadenopathy

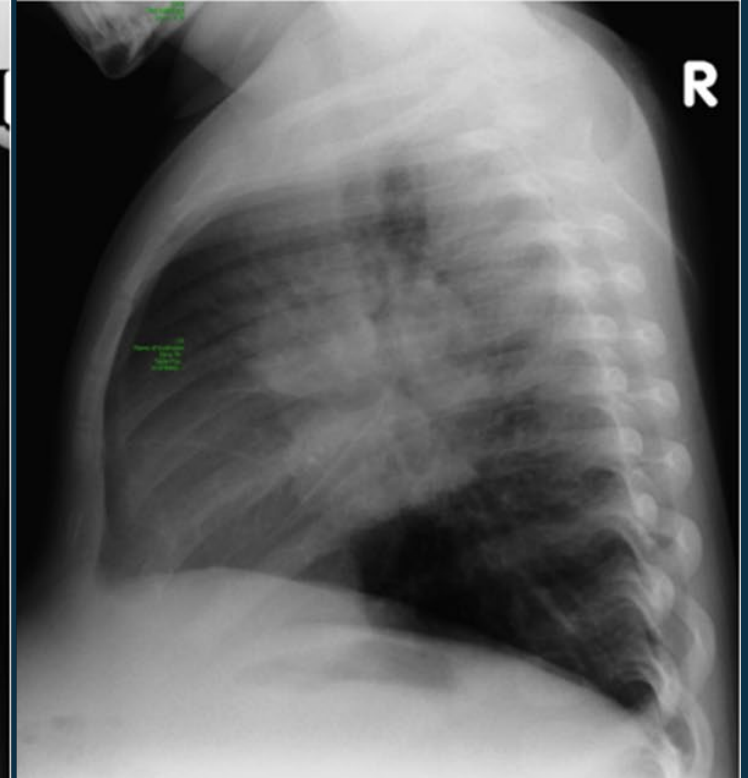
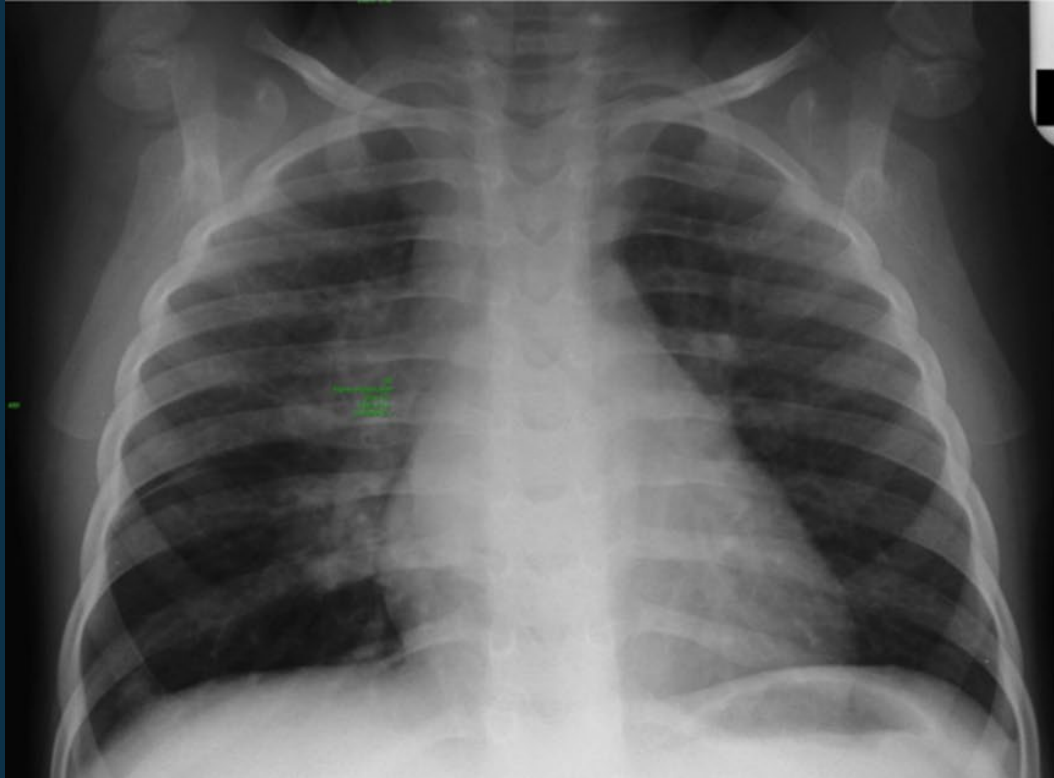


Left hilar lymphadenopathy

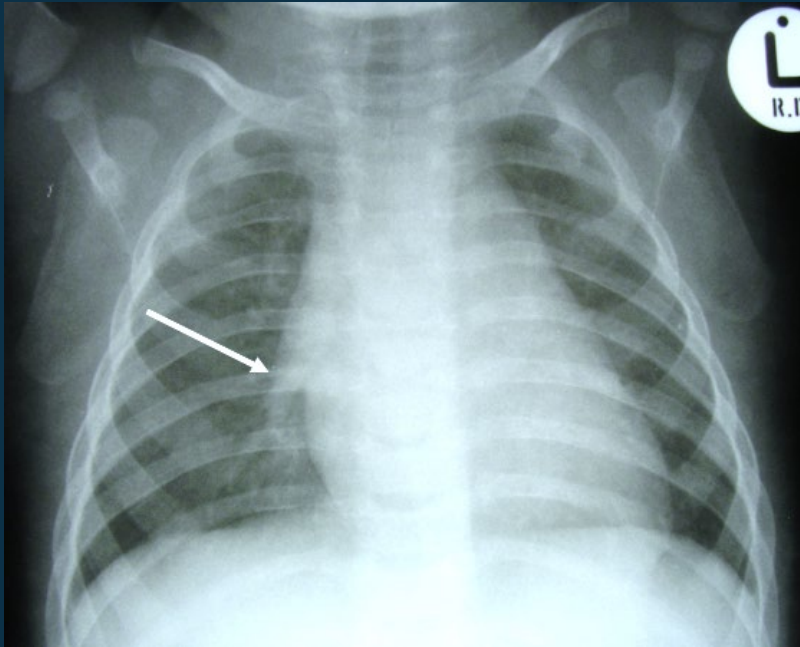


Calcified lymphadenopathy

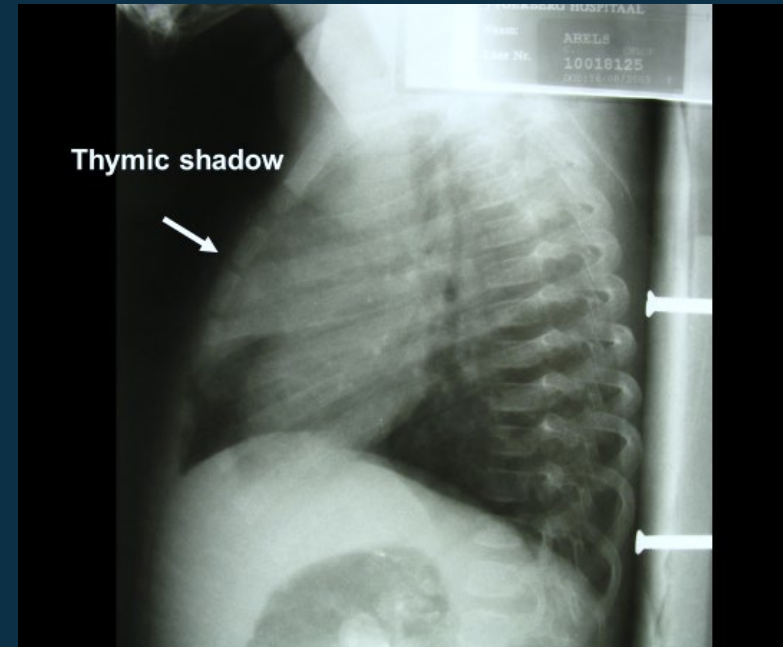
Importance of the lateral view



TB lymph node enlargement can be confused with other mediastinal masses



Thymus



Key points : how to diagnose TB on a paediatric CX using a simplified reading tool that identifies 6 suggestive CXR patterns

6 abnormalities on a paediatric CXR that are highly suggestive of TB: always look for them using a systematic approach

1. Enlarged lymph nodes (lateral view required) :
CXR can detect mediastinal and hilar lymph node enlargement.

The most common CXR appearance in young children with intrathoracic TB = lymphadenopathy

2. Alveolar opacity of the lung tissue: CXR can detect alveolar opacities. If associated with hilar nodes.
This is highly suggestive of TB

Key points : how to diagnose TB on a paediatric CX using a simplified reading tool that identifies 6 suggestive CXR patterns

6 abnormalities on a paediatric CXR that are highly suggestive of TB: always look for them using a systematic approach

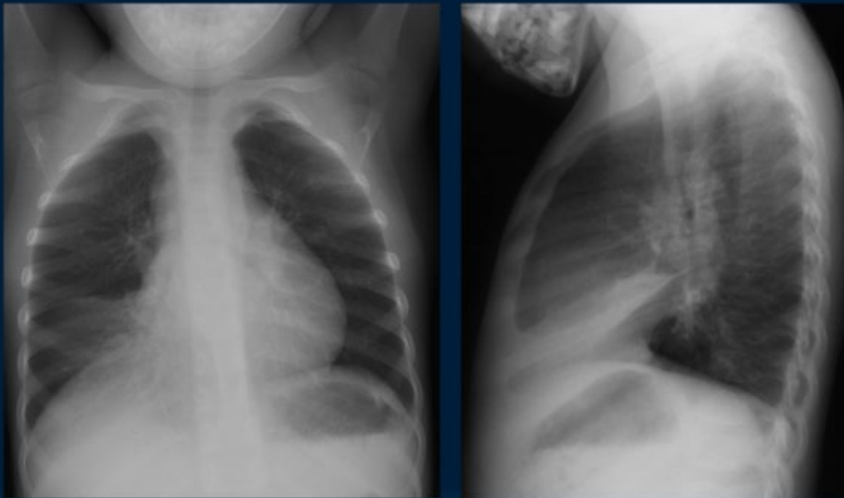
1. Enlarged lymph nodes (lateral view required) :
CXR can detect mediastinal and hilar lymph node enlargement.

The most common CXR appearance in young children with intrathoracic TB = lymphadenopathy

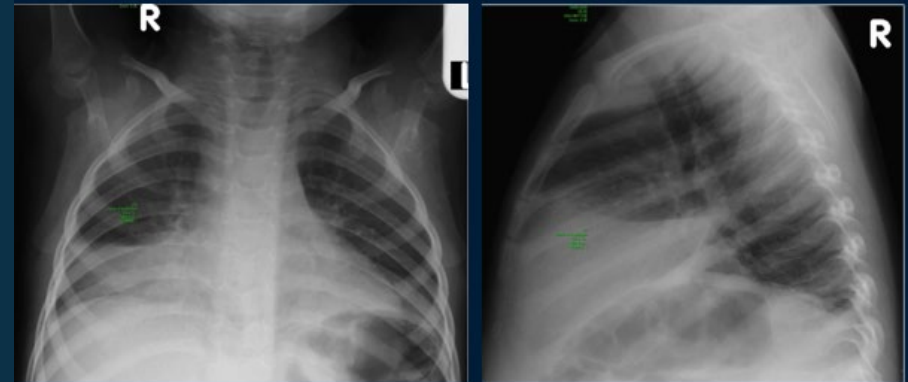
2. Alveolar opacity of the lung tissue: CXR can detect alveolar opacities. If associated with hilar nodes.
This is highly suggestive of TB

3. Airway compression (which may lead to asymmetry between left and right lung)

CXR can detect alveolar opacities. If associated with hilar nodes this is highly suggestive of TB.

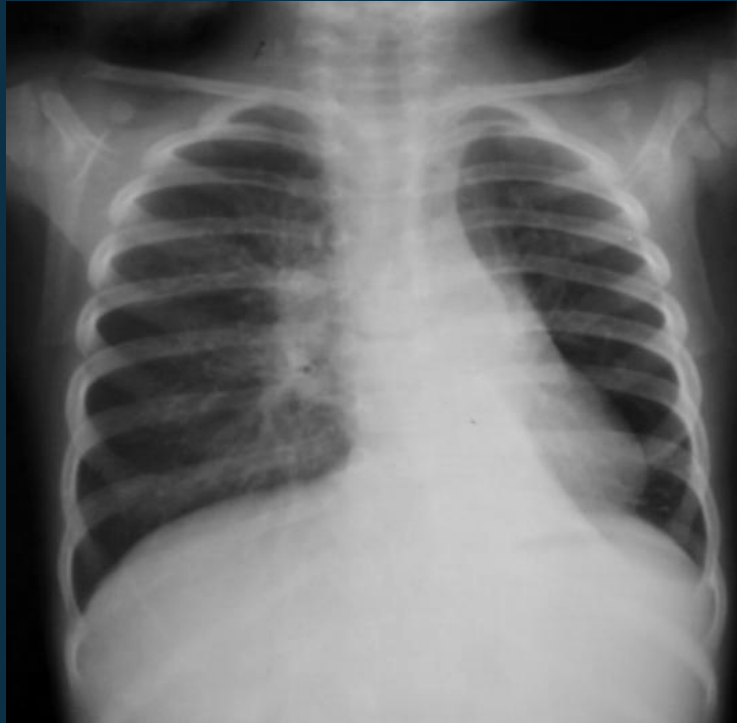

Middle lobe pneumonia associated with adenopathies = TB

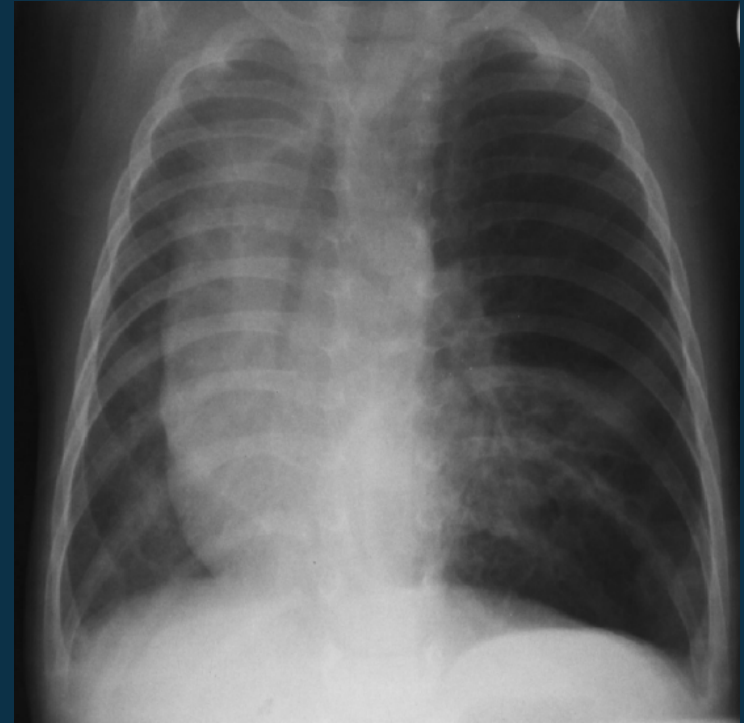

Same middle lobe pneumonia
but **without adenopathy**: non conclusive ;
One must begin amoxicillin before considering TB treatment

**CXR can be useful for detecting airway compression:
complications of primary infection are a result of lymph
nodes narrowing, obstructing, or ulcerating into airways**



Left lower lobe
atelectasis right hilar
lymph nodes



'Check-valve': left
main bronchus
obstruction with
hyperinflation

Key points : how to diagnose TB on a paediatric CX using a simplified reading tool that identifies 6 suggestive CXR patterns

6 abnormalities on a paediatric CXR that are highly suggestive of TB: always look for them using a systematic approach

1. Enlarged lymph nodes (lateral view required) : CXR can detect mediastinal and hilar lymph node enlargement.

The most common CXR appearance in young children with intrathoracic TB = lymphadenopathy

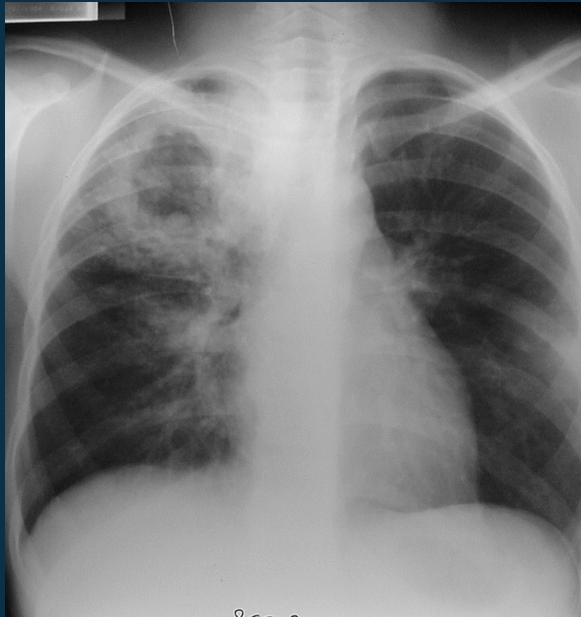2. Alveolar opacity of the lung tissue: CXR can detect alveolar opacities. If associated with hilar nodes. This is highly suggestive of TB

3. Airway compression (which may lead to asymmetry between left and right lung)

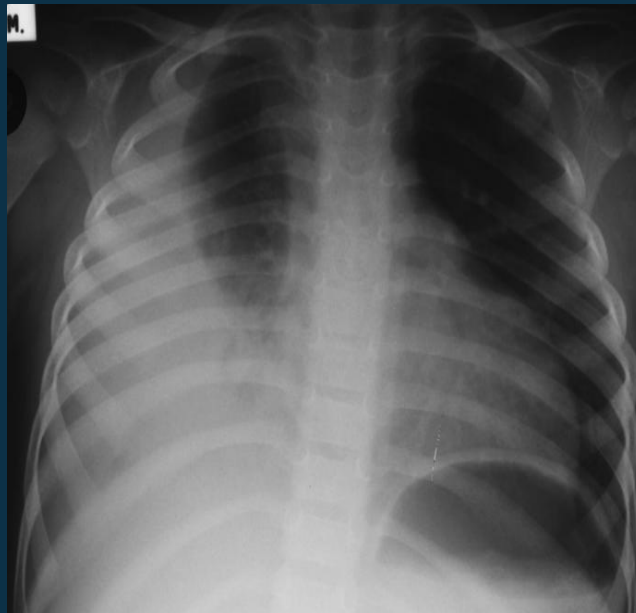
4. Cavitation

5. Pleural or pericardial effusion (especially in older children who develop pathology similar to adults with TB)

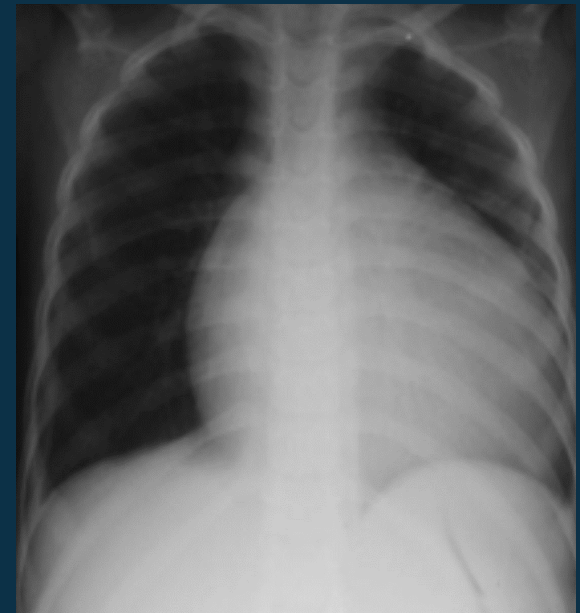CXR can reveal cavitations and pleural and pericardial effusion (usually in older children who develop 'adult-like' TB)



Cavitation



Pleural effusion



Pericardial effusion

Key points : how to diagnose TB on a paediatric CXR using a simplified reading tool that identifies 6 suggestive CXR patterns

6 abnormalities on a paediatric CXR that are highly suggestive of TB: always look for them using a systematic approach

1. Enlarged lymph nodes (lateral view required) :
CXR can detect mediastinal and hilar lymph node enlargement.

The most common CXR appearance in young children with intrathoracic TB = lymphadenopathy

2. Alveolar opacity of the lung tissue: CXR can detect alveolar opacities. If associated with hilar nodes.
This is highly suggestive of TB

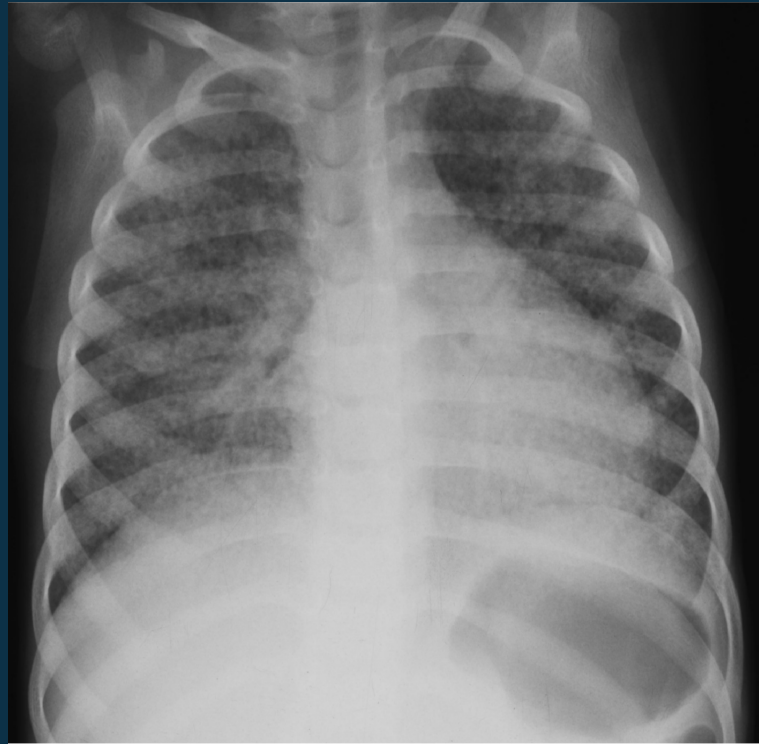
3. Airway compression (which may lead to assymetry between left and right lung)

4. Cavitation

5. Pleural or pericardial effusion (especially in older children who develop pathology similar to adults with TB)

6. Miliary: most pathognomonic CXR pattern of TB

CXR can be useful for detecting miliary infiltrates




Miliary

Key points - CXR for the diagnosis of intrathoracic TB in children

1. CXR remains a useful tool for diagnosis of TB in children.
2. CXR can detect mediastinal lymph node enlargement which is the most common appearance of intrathoracic TB on CXR in young children.
3. CXR can be useful for detecting complications: complications of primary infection are a result of lymph nodes compressing, obstructing, or ulcerating into airways
4. CXR can reveal cavitations and pleural and pericardial effusion in older children who develop pathology similar to adults with TB

CXR is useful in the diagnostic evaluation of TB in children and should be part of a comprehensive diagnostic pathway



The End



Thank You

TB-Speed



TAM Technical Assistance
for Management



université
de BORDEAUX

 **Inserm**

**BORDEAUX
POPULATION
HEALTH**
Centre de
Recherche - U1219

 IDLIC / Infectious diseases
in lower-income countries

anRS France
REcherche
Nord & sud
Sida hiv
Hépatites
Agence autonome de l'Inserm

 **L'INITIATIVE**
sida, tuberculose, paludisme

 **Unitaid**
Innovation in Global Health



© 2021. This work is licensed under a [CC BY 4.0 license](https://creativecommons.org/licenses/by-nc-sa/4.0/).