

Enameloplasty and Esthetic Finishing in Orthodontics—Differential Diagnosis of Incisor Proclination—The Importance of Appropriate Visualization and Records Part 2

DAVID M. SARVER, DMD, MS*†

ABSTRACT

The purpose of this paper is to briefly review some of the principals of ideal tooth shape and morphology and demonstrate how to use tooth reshaping through enameloplasty to treat and finish orthodontic cases to much more esthetic conclusions. This paper demonstrates the significant improvement to a smile orthodontists can achieve if they understand the principles of dental esthetics. In assessing smile design, the patient must be evaluated in three dimensions, and both dental and skeletal components must be considered. Expanded documentation in the form of frontal, profile, and oblique images taken both at rest and on dynamic smile permits the dentist to evaluate these elements without cephalometric radiography.

CLINICAL SIGNIFICANCE

Interdisciplinary treatment has expanded to include not only soft tissue assessment of the periodontal components of the dentition and smile, but also of the face as well. The next level of esthetic enhancement certainly will include facial proportionality as a key component in our patient evaluation. This paper expands the diagnostic vision of the dentist to include facial proportions and interrelationships of hard and soft tissues to improve diagnosis and treatment of the dental and facial esthetics.

(J Esthet Restor Dent 23:303–314, 2011)

The patient in this paper represents a different type of problem from the patient in Part 1 but also required esthetic finishing with tooth reshaping, which is why it has been selected. There is an interesting story in the management of her treatment. The patient in Figure 1 had her first treatment finished by the author 10 years previously. I remember that at the time I was not particularly pleased with the outcome both from the occlusal or smile esthetics standpoints, and admittedly was unsure of what to do about it at the time. Ten years later, I recalled the patient for further evaluation because I had gained a better understanding

of the esthetic and functional issues with implications in her case. Her smile was unesthetic because the anterior teeth were noticeably flared along with other issues we will describe in more detail. Her profile (Figure 2) was characterized by unbalanced upper lip support (less prominence than the lower lip), a high nasal tip, and nice skeletal balance. This is an important observation since we felt that extraction and retraction of teeth to upright them might result in accentuating the lack of support of the upper lip and an unappealing nasolabial angle. Because of these profile reasons, I felt that extraction treatment was not indicated.

*Department of Orthodontics, University of North Carolina, Chapel Hill, NC, USA

†Department of Orthodontics, University of Alabama, Birmingham, AL, USA



FIGURE 1. Although already treated orthodontically, this patient's smile was unesthetic because the anterior teeth were noticeably flared along with other issue.

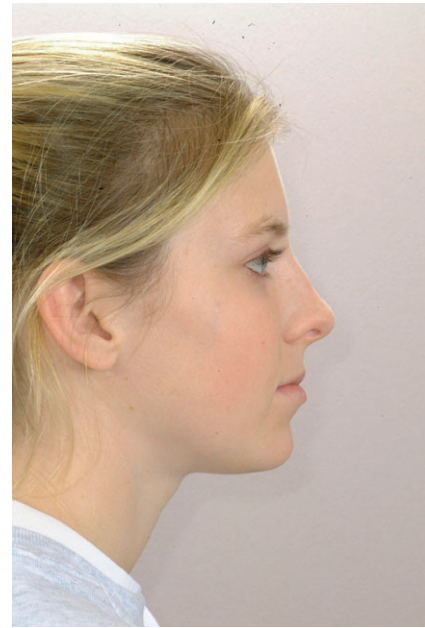

FIGURE 2. Her profile had nice skeletal balance but unbalanced upper lip support (less prominence than the lower lip), and a high nasal tip.

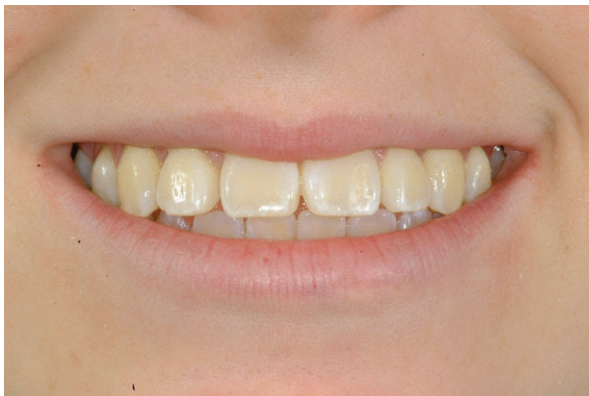

FIGURE 3. The close-up smile evaluation demonstrated proclined (flared) maxillary incisors, incomplete incisor display on smile, and a flat smile arc.

The close-up smile evaluation (Figure 3) demonstrated proclined (flared) maxillary incisors, incomplete incisor display on smile, and a flat smile arc. In general, incisor flare can be a result of many factors including (1) maxillary tooth size excess, (2) a skeletal pattern with flat maxillary and palatal planes relative to the mandibular plane and the face, and (3) orthodontic proclination of anterior teeth to accommodate crowding without tooth extraction. How can the clinician discern what is the etiology of flared incisors,



FIGURE 4. The oblique smile picture clearly shows the flare and angulation of the maxillary incisors better than any cephalogram or other clinical image.

and thus the appropriate treatment? This is an orthodontic paper, so the reader would suspect some cephalometric description, but that is not the case. Careful observation and examination of the patient provides the answer.¹

Figure 4 represents the patient's oblique smile, an image we routinely recommend for reasons well illustrated by this case.² The oblique smile picture clearly shows the flare and angulation of the maxillary incisors better

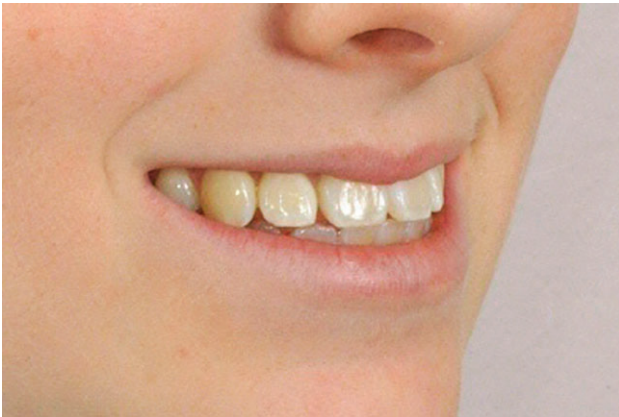

FIGURE 5. Her posterior occlusion was acceptable, but posterior interdigitation was not as detailed as we would have liked.

than any cephalogram or other clinical image. The close-up frontal smile image and close-up oblique smile image are also images that we routinely acquire. While the frontal close-up images are commonly taken in dental and orthodontic practice, the oblique smile is rarely taken. The close-up frontal and oblique smile picture permits scrutiny of incisor angulation, incisor display and smile arc characteristics (Figure 5).

TOOTH SIZE ISSUES

In this patient, overjet was 4 mm, while the posterior occlusion was Class I. Her anterior alignment was good, but the maxillary incisor flare resulted in excessive overjet (Figure 6). The posterior occlusion was acceptable (Figure 7), but the posterior interdigitation was not as detailed as we would have liked. We were puzzled as to why the cuspids were in a solid Class I relationship, but the molars were in a Class III relationship with slight crossbite was present.

Our diagnostic methodology includes evaluation of each aspect of the described occlusal and esthetic problems. Let us illustrate this principle by addressing the problem of overjet and its potential etiologies. We describe overjet as being a function of³:

- 1 Mandibular deficiency
- 2 Maxillary dental alveolar protrusion

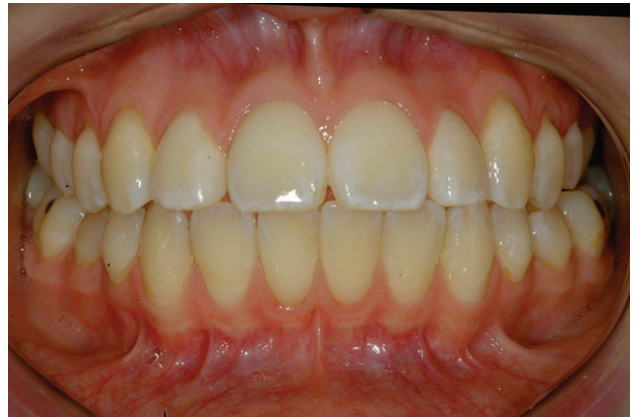

FIGURE 6. 4 mm of overjet was present, but the occlusion and the facial profile contraindicated extraction and retraction of incisors.

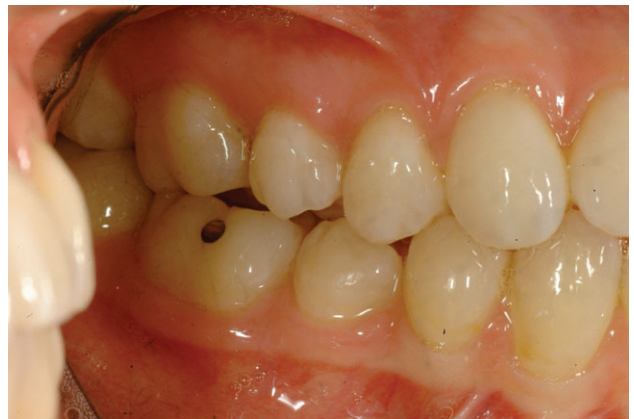

FIGURE 7. Both maxillary tooth size discrepancy and mandibular tooth mass excess was present, resulting in proclination and flare of both maxillary and mandibular incisors.

- 3 Mandibular dental retrusion
- 4 Incisor proclination
- 5 Tooth size excess (which includes either excess maxillary tooth mass, or insufficient mandibular tooth mass)

Cephalometrics is not critical for making a judgment on the etiology of the overjet. The patient's profile does not reflect either mandibular deficiency or maxillary dental alveolar protrusion. Incisor proclination was the cause of the overjet created by the disproportionate and excessive maxillary tooth size.

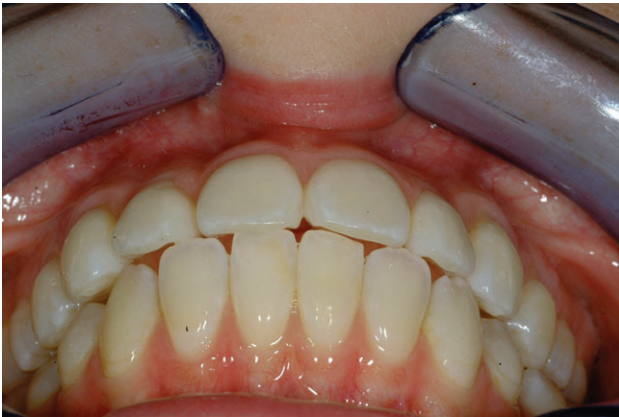

FIGURE 8. 4 mm of overjet was present. The lower incisors were actually in contact with the gingulae and marginal ridges of the maxillary incisors, an obstacle to orthodontic retraction.

It is important to note in Figure 8 that while 4 mm of overjet was present, the lower incisors were actually in contact with the gingulae and marginal ridges of the maxillary incisors, which would prevent orthodontic retraction without premolar extraction; but extraction and retraction of incisors was contraindicated because of the occlusion and the facial profile.

One of the downsides of the extraction choice is that we do not get to choose the exact amount of tooth mass removal needed to match the specific problem. In other words, if we have 5 mm of crowding, two premolar extractions create approximately 15 mL of space. The 5 mm is used to address the crowding, and the remaining space must be closed but is not critical to the crowding issue. We realized that this patient has both maxillary tooth size discrepancy and mandibular tooth mass excess resulting in proclination and flare of both maxillary and mandibular incisors.

Microesthetic evaluation revealed:

- 1 Maxillary central incisor width of 9.0 mm and height 9.5 mm. The contact was superiorly placed, resulting in a large incisal embrasure. Because of the high contact, the connector represented only 30% in length, while 50% is the generally accepted value.

This case differs from the case in Part 1 of this series because while most of us are intimately familiar with

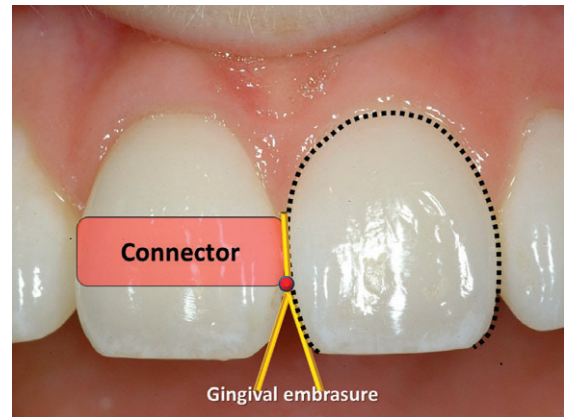


FIGURE 9. The anatomy of her maxillary central incisors was esthetically compromised by the width of the tooth between contacts being wider than the incisal edge, resulting in excessive incisal embrasures and short connectors.

the “black triangular hole” or excessive gingival embrasure, this case has an incisal embrasure problem. What I did not recognize in treatment of this case was the width of the teeth, their shape, and their cumulative contribution to the inadequate outcome. To the patient, the large incisal embrasure represents a space, when in reality the teeth are actually in contact with each other with no space. Treatment in this case no longer requires only a quantitative assessment of the embrasures, contacts, and connectors, but also an appreciation of the shape and form of the incisors. The anatomy of her maxillary central incisors was esthetically compromised by the width of the tooth between contacts being wider than the incisal edge, resulting in excessive incisal embrasures and short connectors (Figure 9). To attain a better shape, either restorative material had to be added to eliminate the incisal embrasures, or reshape the width of the teeth at the contact level, narrowing it to more closely approximate the incisor width. This will be illustrated clearly in the stepwise progression of this case.

TREATMENT SEQUENCE

Step 1: We aligned the teeth so that root divergence was as ideal as possible before any decisions were made as to what teeth need reshaping, and how much.

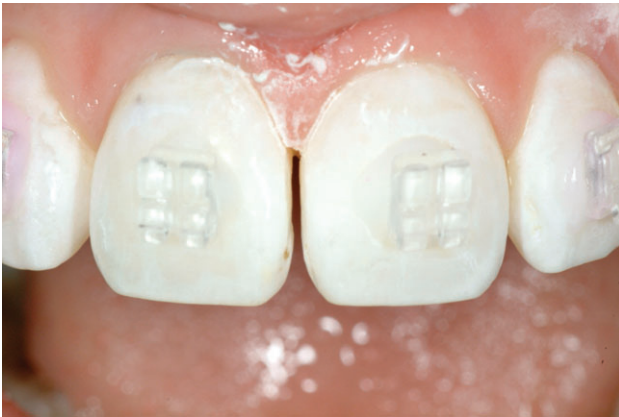

FIGURE 10. Addressing the contacts and incisal embrasures, we utilized the fine needle carbide to lengthen the connector and lower the contact.

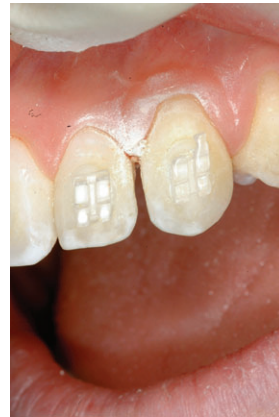

FIGURE 11. Because the maxillary central and laterals were similarly shaped, the lateral incisors were reshaped.

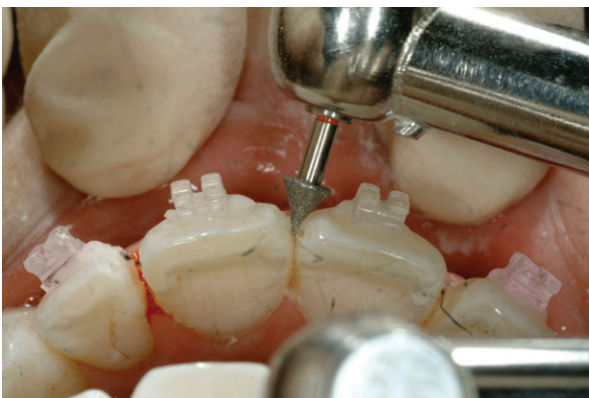

FIGURE 12. Once the connector lengths were established, rounding of the line angles was performed.

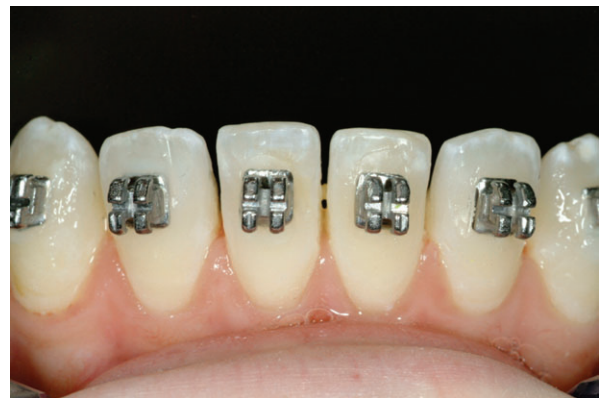

FIGURE 13. Tooth size reduction in the lower arch was also required to retract the lower incisors in concert with the uprighting of the maxillary incisors.

Step 2: Addressing the contacts and incisal embrasures, we utilized the fine needle carbide to lengthen the connector and in this case, lower the contact (Figure 10). Because the maxillary central and laterals were similarly shaped, the lateral incisors were reshaped (Figure 11).

Step 3: Once the connector lengths were established, rounding of the line angles was performed (Figure 12).

Step 4: Orthodontic appliances with elastomeric chain closed the space created by the tooth reshaping. Because the lower incisors were in close proximity to the cingulae of the upper incisors, overjet reduction was going to be limited by how much space was available for retraction. Therefore, tooth size reduction in the lower arch was also required (Figure 13). We want to point out

that the orthodontic space closure was performed on round wire which allowed the bracket to rotate around the round wire, uprighting and extruding them to increase incisor display and attain a more consonant smile arc while reducing incisor flare (Figure 14).

After the maxillary and mandibular space was closed, the overjet was resolved and more desirable tooth proportionality achieved (Figure 15). The patient's final smile (Figure 16) reflected great improvement with greater incisor show on smile and the severely flared teeth now uprighted. The close-up smile (Figure 17) and oblique smile (Figure 18) also demonstrated this improvement, and the intraoral pictures reflected an improved occlusion because of our ability to normalize the tooth size discrepancy in both arches (Figure 19).

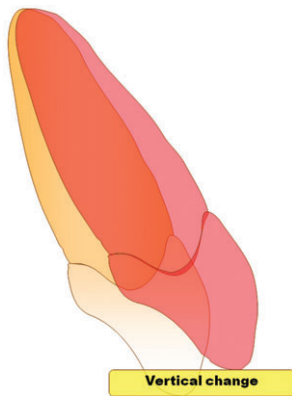


FIGURE 14. Orthodontic space closure was performed on round wire which allowed the bracket to rotate around the round wire, uprighting and extruding them to increase incisor display and attain a more consonant smile arc while reducing incisor flare.

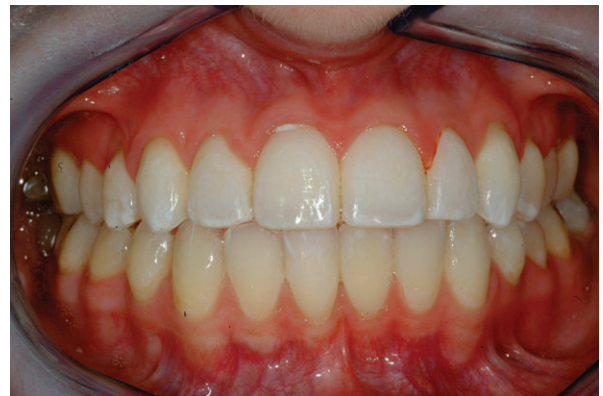

FIGURE 15. At the completion of treatment, more desirable tooth proportionality was achieved.



FIGURE 16. The patient's final smile with increased incisor show on smile and uprighted incisors.

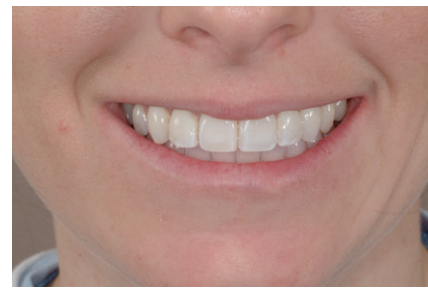

FIGURE 17. The close-up smile also reflected an improved smile arc.

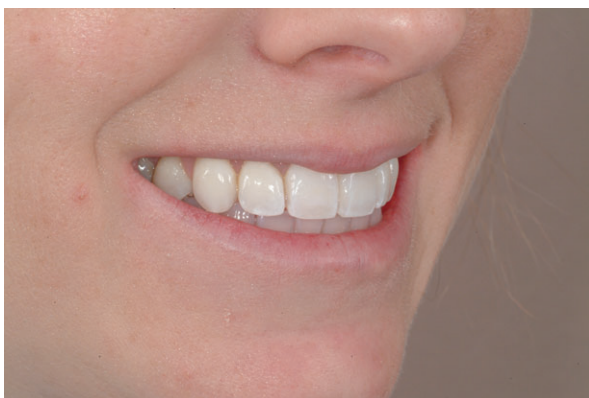

FIGURE 18. The oblique smile demonstrates the uprighted incisors and reduction in proclination.

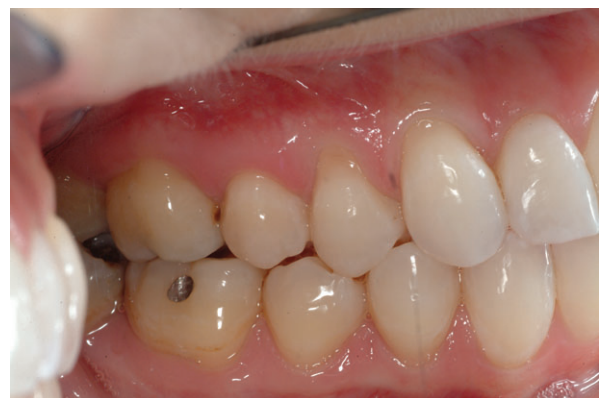

FIGURE 19. The final occlusion was improved as the tooth sizes were more proportionate.




FIGURE 20. This 19-year-old patient had concerns about her overall appearance.




FIGURE 21. Spacing was present in addition to a lack of tooth display on smile.




FIGURE 22. The profile was concave, and in terms of the Angle classification, we tend to call it a “Class III” profile. The Angle classification is a dental system of classification, never intended to describe skeletal relations.

INCISOR FLARE OF SKELETAL ETIOLOGY

Proclined appearing incisors can be dental in origin and skeletal, which makes the correct diagnosis and




FIGURE 23. Lower facial rotational characteristics are best visualized on the oblique facial view.

appropriate treatment even more challenging. How do we make the determination as to the underlying etiology of the incisor proclination? For example, the 19-year-old patient in Figure 20 had concerns about her

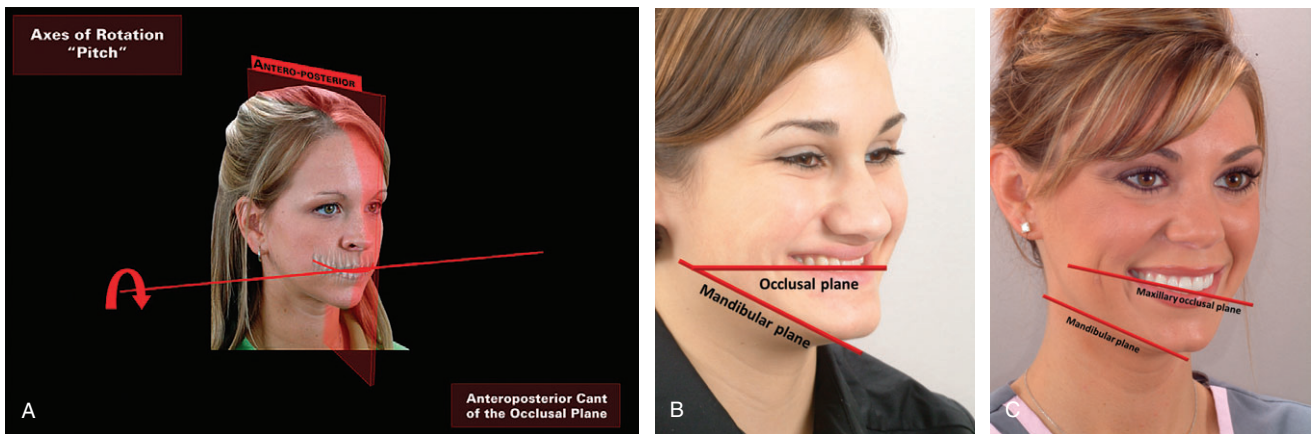


FIGURE 24. A, This schematic demonstrates the visualization of the face and skeleton in terms of pitch, roll, and yaw (from Ackerman JL, Proffit WR, Sarver DM, Ackerman MB, Keane MR. Pitch, Roll, and Yaw: Describing the Spatial Orientation of Dentofacial Traits. *Am J Orthod Dentofacial Orthop.* 2007 Mar; 131(3):305–10). B, The patient’s maxillary occlusal plane is flatter than the mandibular plane, a view we can realize without cephalometric radiography. C, In a patient with ideal facial and smile esthetics, the maxillary occlusal plane and mandibular plane are closer to ideal.

appearance. The macroesthetic evaluation is important in leading us to the correct diagnosis. Our patient’s facial proportions were characterized by a short lower face (often associated with vertical maxillary deficiency) with inadequate lip support for a 19-year-old. She was referred by her dentist for evaluation of her smile esthetic presentation (Figure 21) with spacing present and lack of tooth display on smile. The profile (Figure 22) provided an important clue: it was concave with a Class III appearance. The Angle classification was inadequate since it describes only the anteroposterior position of the teeth and was never intended to define jaw relationships. In this case, using the Angle classification we tend to think in terms of the mandible being too large or the maxilla too small. Therefore, our plan most likely would involve movement of the maxilla forward or the mandible back. An article by Ackerman et al.⁴ was intended to define skeletal relations in a more comprehensive way than a profile approach. While her midface was deficient relative to the mandible, the overall skeletal pattern really represented a counterclockwise pitch of the lower face. This is best visualized on the oblique view (Figure 23). By facilitating our visual evaluation of the spatial orientation of the maxillary and palatal occlusal planes (Figure 24 a–c), the oblique view is important in distinguishing the skeletal incisor flare problem from the dental one. As a result of the vertical and rotational

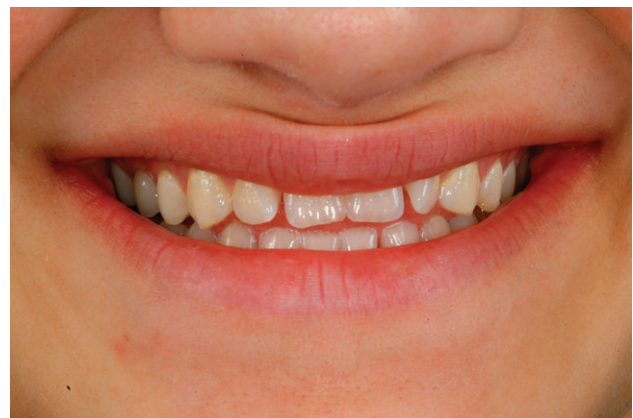

FIGURE 25. Anterior tooth display on smile was only 4 mm, central incisor crown height 10 mm and a flat, or nonconsonant smile arc.

skeletal pattern, her anterior tooth display on smile (Figure 25) was only 4 mm, with the crown height measured at 10 mm. Her smile arc was also nonconsonant or flat.^{5–9} The oblique smile images (Figure 26) reflect the flare of the maxillary incisors as a result of the counterclockwise positioning of the maxillary occlusal and palatal planes.

Our treatment started with orthodontic preparation for a surgical plan of maxillomandibular occlusal plane rotation in a clockwise direction.^{10–12} A Lefort I osteotomy of the maxilla was performed with anterior

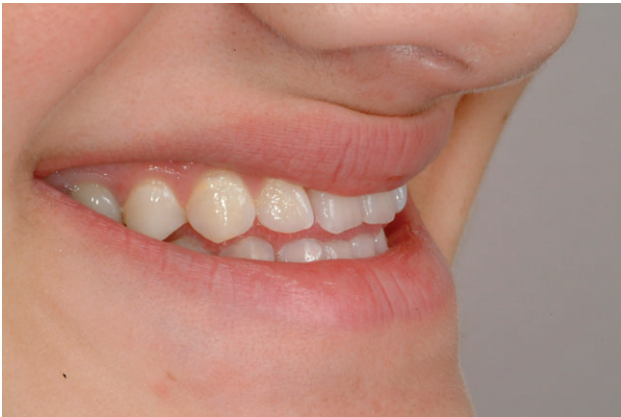

FIGURE 26. The oblique smile image reflects the flare of the maxillary incisors as a result of the counterclockwise positioning of the maxillary occlusal and palatal planes.



FIGURE 27. The final facial appearance was much more youthful and appealing since the facial dimensions were more appropriate.



FIGURE 28. A, The pretreatment oblique image reflects to aging effect of inadequate lip support. B, In the final outcome, the advancement of both jaws greatly enhanced resting lip support.



FIGURE 29. 5 mm anterior downgraft of the maxilla resulted in full incisor display on smile.

downgraft, thus changing the pitch of the maxilla. The amount of anterior downgraft was determined as follows:

- 1 Only 5 mm of maxillary incisor was displayed on smile
- 2 The incisor crown height was 10 mm
- 3 Therefore, the anterior maxilla was downgrafted 5 mm to attain full incisor display on smile

Surgery on the mandible was also performed to achieve clockwise rotation in concert with the maxillary movement. Both jaws were advanced to increase the lip support, and a rhinoplasty performed simultaneously with the osteotomies.^{13–23} The purpose of the rhinoplasty was twofold: (1) her nose was already wide and maxillary advancement results in further widening of the nasal base. Rhinoplasty was indicated so the esthetics of the midface was not compromised by the orthognathic surgery, and (2) the rhinoplasty would

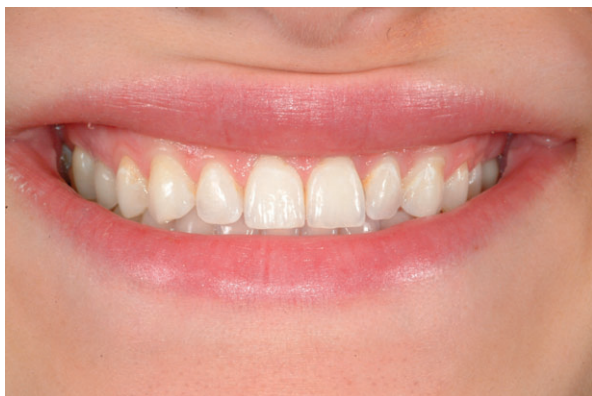

FIGURE 30. The smile arc was enhanced by tipping the curvature of the anterior sweep of the maxillary teeth to better match the curvature of the lower lip.

improve the esthetics of the face whether she was having orthognathic surgery or not. Think about it for a minute, the biggest risk for the patient in jaw surgery is the anesthesia. So our philosophy is to maximize the risk/benefit ratio of the procedure rather than to do the least.

The final facial appearance was much more youthful and appealing since the facial dimensions were more appropriate (Figure 27). The advancement of both jaws greatly enhanced resting lip support (Figure 28 a, b) and anterior downgraft of the maxilla resulted in full incisor display on smile (Figure 29). The smile arc was enhanced by tipping the curvature of the anterior sweep of the maxillary teeth to better match the curvature of the lower lip (Figure 30). The final profile was much more esthetic with anteroposterior balance of the maxilla and mandible along with improved facial proportions (Figure 31).

CONCLUSION

In assessing a patient's smile, the patient must be evaluated in three dimensions, and both dental and skeletal components must be considered. The simple recognition of unesthetically flared anterior teeth may have more than simple etiologies, and differential diagnosis and careful examination are required for any treatment decision. Expanded documentation in the

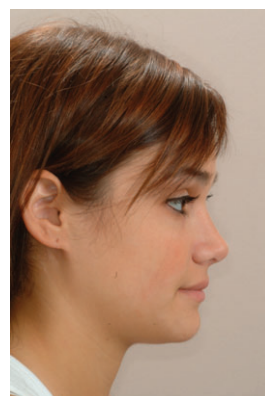


FIGURE 31. The final profile was much more esthetic with anteroposterior balance of the maxilla and mandible along with improved facial proportions.

form of frontal, profile, and oblique images taken both at rest and on dynamic smile permits the dentist to evaluate these elements without cephalometric radiography.

Interdisciplinary treatment also has expanded to include not only soft tissue assessment of the periodontal components of the dentition and smile, but of the face as well. The next level of esthetic enhancement certainly will include facial proportionality as a key component in our patient evaluation.

DISCLOSURE

The author does not have any financial interest in the companies whose materials are included in this article.

REFERENCES

1. Sarver DM, Ackerman JL. About face—the re-emerging soft tissue paradigm. *Am J Orthod Dentofacial Orthop* 2000;117:575–6.
2. Sarver DM, Ackerman MB. Dynamic smile visualization and quantification and its impact on orthodontic diagnosis and treatment planning. In: Romano R, editor. *The art of the smile-integrating prosthodontics, orthodontics periodontics, dental technology, and plastic surgery*. Chicago (IL): Quintessence Publishing Co.; 2005, pp. 99–139.

3. Sarver DM. Esthetic orthodontics and orthognathic surgery. St. Louis (MO): C.V. Mosby Co.; September 1997.
4. Ackerman JL, Proffit WR, Sarver DM, et al. Pitch, roll, and yaw: describing the spatial orientation of dentofacial traits. *Am J Orthod Dentofacial Orthop* 2007;131(3):305–10.
5. Frush JO, Fisher RD. The dynesthetic interpretation of the dentogenic concept. *J Prosthet Dent* 1958;8:558–81.
6. Hulsey CM. An esthetic evaluation of lip-teeth relationships present in the smile. *Am J Orthod* 1970;57:132–44.
7. Ackerman JL, Ackerman MB, Brensinger CM, Landis JR. A morphometric analysis of the posed smile. *Clin Orthod Res* 1998;1:2–11.
8. Ackerman MB, Ackerman JL. Smile analysis and design in the digital era. *J Clin Orthod* 2002;36:221–36.
9. Sarver DM. The smile arc—the importance of incisor position in the dynamic smile. *Am J Orthod Dentofacial Orthop* 2001;120:98–111.
10. Reyneke JP, Evans WG. Surgical manipulation of the occlusal plane. *Int J Adult Orthodon Orthognath Surg* 1990;5(2):99–110.
11. Sarver DM. Diagnosis and treatment planning of hypodivergent skeletal pattern with clockwise occlusal plane rotation. *Int J Adult Orthodon Orthognath Surg* 1993;8(2):113–21.
12. Reyneke JP. Surgical manipulation of the occlusal plane: new concepts in geometry. *Int J Adult Orthodon Orthognath Surg* 1998;13(4):307–16.
13. Kinnebrew MC, Emison JW. Simultaneous maxillary and nasal reconstruction. *J Craniomaxillofac Surg* 1987;15(6):312–25.
14. Waite PM, Matukas VJ, Sarver DM. Simultaneous rhinoplasty in orthognathic surgery. *Int J Adult Orthodon Orthognath Surg* 1988;17:298–302.
15. Guthrie PB, Ann R. Rhinoplasty—the other facial osteotomy. *Australas Coll Dent Surg* 1991;11:266–72, Review.
16. Waite PD, Matukas VJ. Indications for simultaneous orthognathic and septorhinoplastic surgery. *J Oral Maxillofac Surg* 1991;49(2):133–40.
17. Schendel SA, Carlotti AE Jr. Nasal considerations in orthognathic surgery. *Am J Orthod Dentofacial Orthop* 1991;100(3):197–208.
18. Sarver DM, Weissman SM, Matukas VJ. Incorporation of facial plastic surgery in the planning and treatment of orthognathic surgical cases. *Int J Adult Orthodon Orthognath Surg* 1991;6(4):113–21.
19. Sarver DM, Johnston MJ. Orthognathic surgery and esthetics: planning treatment to achieve functional and aesthetic goals. *Br J Orthod* 1993;20(2):93–100.
20. Ronchi P, Chiapasco M. Simultaneous rhinoplasty and maxillomandibular osteotomies. *Int J Adult Orthodon Orthognath Surg* 1998;13(2):153–61.
21. Sarver DM, Rousso DR. Facial plastic surgical procedures combined with orthodontic/orthognathic procedures. *Am J Orthod Dentofacial Orthop* 2004;126:305–7.
22. Sarver D, Yanosky M. Combined orthodontic, orthognathic, and plastic surgical treatment of an adult Class II malocclusion. *J Clin Orthod* 2005;39(4):209–13.
23. Fattahi T. Aesthetic surgery to augment orthognathic surgery. *Oral Maxillofac Surg Clin North Am* 2007;19(3):435–47, vii.

Reprint requests: David M. Sarver, DMD, MS, 1705 Vestavia Parkway, Vestavia Hills, AL 35216, USA; Tel.: 205-979-7072; Fax: 205-979-7140; email: sarverd@sarverortho.com

This article is accompanied by commentary, Enameloplasty and Esthetic Finishing in Orthodontics Part I and Part 2, Dan Grauer, DDS, PhD, Gavin Heymann, DDS, MS

DOI 10.1111/j.1708-8240.2011.00448.x