

Review article

CORDOCENTESIS; INDICATIONS, TECHNIQUES, COMPLICATIONS AND A TRAINING COURSE

Fuenglada Tongprasert, M.D.

Department of Obstetrics and Gynecology, Faculty of Medicine, Chiang Mai University

Abstract Cordocentesis is a procedure to sample fetal blood from the umbilical cord by a needle that is inserted through the maternal abdominal wall under continuous ultrasonographic monitoring. Typical indications for cordocentesis are the fetal risk of thalassemia and rapid daryotyping. Fetal intravascular accessibility allows the possibility of proceeding to more difficult invasive procedures of performing intrauterine blood transfusions or other intrauterine fetal therapies. At least cordocentesis should be performed at 18 weeks of gestation, with no more fetal loss rate. The procedure-related fetal loss risk is 1.4% which is mainly associated with the surgeon's skill and experience. Therefore, it is necessary for the surgeon to practice increasingly to develop their skill and lower associated complications. The author here also presents a cordocentesis training course for early practitioners to develop their skill in cordocentesis, without any fetal and maternal jeopardy. **Chiang Mai Med J 2007;46(3):119-127.**

Keywords: cordocentesis, fetal blood sampling, prenatal diagnosis, fetal loss, training course

Cordocentesis (i.e. fetal blood sampling, percutaneous umbilical blood sampling, funipuncture) is a procedure for sampling fetal blood from the umbilical cord by a needle that is inserted through the maternal abdominal wall under continuous ultrasonographic monitoring. The overall objective of cordocentesis is for prenatal diagnosis and the secondary aim is for fetal therapy. Cordocentesis was first performed by Fernand Daffos in the 1980s.⁽¹⁾ Direct access to the fetal vascular circulation allows improvement of prenatal

diagnosis and therapy. Despite its advantages and high acceptance, fetal blood sampling is relatively invasive and limited to the skilled perinatologist. The procedure-related fetal loss is dependent directly upon the skill and experience of the surgeon.⁽²⁾ The aim of this article is to briefly review the indications, techniques and complications of cordocentesis. The author here also presents a cordocentesis training course to effectively develop skill in cordocentesis.

Indications

Typical indications for cordocentesis are listed in Table 1.⁽³⁾ Although rapid karyotyping and hemolytic disease are the common indications for cordocentesis in western countries, cordocenteses are more commonly used in Asian countries for diagnosis of hemoglobinopathies disease.⁽⁴⁾ In Maharaj Nakorn Chiang Mai Hospital, Tongsong *et al.* published that 1,320 cordocenteses were performed between 1989 and 1999.⁽⁵⁾ The most common indication in that study was the fetal risk of thalassemia (61.1%) followed by rapid karyotyping (27.1%). Another application of cordocentesis is fetal therapy. Access to the fetal circulation offers the possibility of infusing biologic (e.g. blood transfusion) or pharmacologic agents for therapeutic purposes. In multiple gestations, in which one of the fetuses is abnormal, cordocentesis is also applied for selective termination by potassium chloride injection, which causes cardiac arrest.⁽⁶⁾

Techniques

Cordocentesis can be performed as early as 16 weeks of gestational, though it is technically more difficult prior to 18 weeks of gestation. In general, cordocentesis is commonly performed between 18-22 weeks of gestation for prenatal diagnosis. The target portions of umbilical cord location are classified in 3 subgroups, which are 1) placental origin of umbilical cord, 2) free loop of umbilical cord and 3) fetal origin of umbilical cord. Before the procedure, detailed ultrasound examination is performed using the convex transducer of 3.5-5 MHz to determine the number of fetuses, fetal viability, fetal biometry, fetal normality, placenta and umbilical cord locations. The preferred umbilical cord location for some surgeons is the placental origin of the umbili-

Table 1. Indications for cordocentesis

Indication	%
Rapid karyotype	50.70
Hemolytic disease	33.70
Severe, early onset growth restriction	21.70
Congenital infection	
Miscellaneous	16.90
Nonimmune hydrops fetalis	4.20
Stuck twin syndrome	
Fetal drug therapy	
Maternal thyroid stimulation antibody	
Alloimmune thrombocytopenia	

(from Weiner CP. Cordocentesis In: Evans MI, Johnson MP, Yaron Y, Drugan A, editors. Prenatal diagnosis. New York: McGraw-Hill; 2006. p. 443-447.)

cal cord, where it is relatively fixed. Cordocentesis is easiest when the placenta is anterior because access to the target portion of the cord with a posterior placenta may be hampered by the fetus. The fetal origin of umbilical cord puncture causes pain and should be avoided because of the innervations in the first few centimeters. The author prefers to target the easiest location for a direct approach rather than be confined to the placental cord origin. In fact, a free loop is the preferred target in nearly 100% of the procedures.⁽⁷⁾ Based on personal experience, it seems that the puncture site does not affect the difficulty if it is chosen on the basis of accessibility and quality of visualization. The major difficulties were apparently related to maternal obesity, resulting in poor sonographic images; the active fetal movement, and the presence of polyhydramnios, making the puncture site more difficult to access.

There are 2 standard methods for cordocentesis; free hand and the use of a fixed needle guide.⁽³⁾ In the free hand technique,

the needle course is tracked by imaging the tip and shaft with a high-resolution ultrasound transducer held either in the free hand of the surgeon or by their assistant. Since the needle is not fixed, the tip can move several centimeters in all axes should either the site of insertion be suboptimal or the fetus move during the procedure. Most experienced surgeons, including the author here, prefer a free-hand technique because of its flexibility in the adjustment of the needle path. An alternative approach is to employ a needle guiding device, which is attached to the base of the ultrasound transducer. Typically, the transducer is held by the surgeon's assistant. The predicted course of the needle, which can travel only in the vertical plane, is displayed on the ultrasound screen. This allows the surgeon to select a precise target in advance for puncture. It has been suggested that needle guidance may decrease the risk of cord laceration or needle displacement when the tip is properly placed.⁽⁸⁾ The needle guiding device restricts the lateral motion of the needle, which may hamper the procedure if the needle needs repositioning. This problem can be solved by removing the guiding device during the procedure, if necessary.⁽²⁾

With the aseptic technique, the abdomen is cleaned with an antiseptic solution and draped. The use of local anesthesia for diagnostic procedures is a matter of choice, and it can ease the patient's discomfort in cases of prolonged procedures. Maternal sedation and prophylactic antibiotics are not necessary. A regular 21- to 23-gauge spinal needle is used for cordocentesis. The standard length of the needle is 8.89 cm excluding the hub. The length of the needle should be in accordance to the thickness of maternal panniculus and the location of the target segment of the cord,

within the uterus. Within the umbilical cord, it is easier and safer to sample the vein rather than an artery. Puncture of the artery has been associated with a greater incidence of bradycardia and longer postprocedural bleeding.⁽⁸⁾ Fetal movement can either prevent a successful puncture or prolong the duration of the procedure. The use of paralytic agents to decrease fetal movement is left to the discretion of the surgeon. When indicated, atracurium (0.4 mg/kg fetal weight intravenously) or pancuronium (0.1 mg/kg fetal weight) can be used.⁽²⁾

Upon entering the umbilical cord, the stylet is removed and fetal blood is withdrawn into a 1-2 mL syringe attached to the hub of the needle. The syringe may be primed upon the indications with a small amount of anticoagulant, such as heparin or citrate. The volume of blood removed differs with the number of tests required and the gestational age (maximum of 6-7% of the fetoplacental blood volume for that gestational age) should be taken into account.⁽²⁾ The needle is withdrawn, then the puncture site is monitored for bleeding, and the fetal heart rate is assessed. After this procedure, the fetal heart rate and uterine contraction are monitored for 1-2 hours. In the case of a viable fetus, the patients are allowed to go home without prophylactic antibiotics or tocolysis. Rh-negative women are given an anti-D immunoglobulin prophylaxis and, if needed, the Kleihauer-Betke test is used to differentiate fetal and maternal blood before fetal blood analysis.

Complications

The major complication of cordocentesis is the procedure-related pregnancy loss. A review of the published series of low-risk cases reported an overall fetal loss risk of 1.40%

before 28 weeks, and an additional 1.40% risk of perinatal death after 28 weeks.⁽⁹⁾ However, most of the larger reports concerning cordocentesis-related fetal losses were undertaken at advanced gestational ages (mean 28-30 weeks of gestation) and lacked control populations.⁽¹⁰⁻¹⁴⁾ In Maharaj Nakorn Chiang Mai Hospital, Tongsong *et al.* compared 1,020 women undergoing midgestation cordocentesis with 1,020 control subjects.⁽¹⁵⁾ The reported fetal loss rate associated with cordocentesis was 3.20%, versus a background loss rate of 1.80% among matched control patients. The calculated fetal loss rate of 1.40% thus represents a true procedure-related loss rate.

Transient fetal bradycardia has been reported with rates ranging between 3-12%.⁽⁹⁻¹¹⁾ It is usually a self limited phenomenon. In most cases, bradycardias are thought to be manifestations of a vasovagal response caused by local vasospasm; this hypothesis is supported by a higher incidence of bradycardia in cases of umbilical artery puncture.⁽⁸⁾

Bleeding from the puncture site was reported to occur in 20-53% of cases, with a mean duration of 35 seconds.⁽⁹⁻¹¹⁾ In a pathologic study of 50 umbilical cords collected between 1 and 20 hours after cordocentesis, hematomas were noted in as many as 17% of cases.⁽¹⁶⁾ A hematoma is generally asymptomatic, but it can be associated with prolonged bradycardia and rapid fetal deterioration.

Fetomaternal hemorrhage occurred in about 40% of cases in a study of consecutive diagnostic cordocentesis, with an anterior rather than posterior placenta.⁽¹⁷⁾ The mean estimated volume of hemorrhage was 2.40 mL (3.10% of the total fetoplacental blood volume). In this author's experience, cordocentesis can cause fetomaternal hemorrhage in more than half of the cases, but nearly all cases had only

minimal hemorrhage.⁽¹⁸⁾

The most important risk factors implicated in the occurrence of complications are the surgeons experience, techniques and gestational age at the time of procedure. In inexperienced hands, cordocentesis is a difficult and potentially life threatening procedure. The author here presents a cordocentesis training course to develop effective skill in cordocentesis.

A cordocentesis training course at the Maternal-Fetal-Medicine (MFM) Unit, Chiang Mai University

Cordocentesis is a surgical procedure. Training is difficult to obtain due to the limited number of cases available at any given institution, and because of the risks associated with the procedure. Ideally, the surgeon should have a strong background in obstetric ultrasonography and experience with other invasive procedures of prenatal diagnosis. Training can be provided at first with in vitro models.⁽¹⁹⁾ Once proficiency is acquired with those models, the procedure can be performed in patients who have elective midtrimester termination of pregnancy.⁽²⁰⁾

This skill is earned almost entirely by experience, which in turn, increases proportionately with the growing number of procedures performed. Therefore, it is necessary for trainees to practice increasingly to develop their skill and lower associated complications. In many centers, there may not be a large enough number of pregnant patients requiring cordocentesis, thereby making it difficult to acquire skill and experience. Although the models for training cordocentesis have been developed previously in other centers,⁽¹⁹⁻²¹⁾ they are too expensive and impractical for training in developing countries. Above all, the efficacy of practicing with those models has never been

well evaluated. In considering these problems, the MFM Unit, Department of Obstetrics and Gynecology, Faculty of Medicine, Chiang Mai University has developed its own cordocentesis model in order to achieve the highest success rate and lowest complications in real practice, especially at the beginning of the learning curve.

Materials and method (Fig. 1)

1. An 18 x 35 x 15 cm rectangular transparent glass box, sealed at each corner with water resistant glue, is used to simulate the uterine environment. To prevent a reverberation effect from an ultrasonic signal, a rubber latex sheet is placed at the bottom of the glass box.

2. A 30-cm umbilical cord is filled with red mercurochrome solution after complete

blood clot evacuation. Both its ends are tied with cord tape and then hung inside the glass box, which is filled with water and used as the target for the puncture. It is important to adjust the level of umbilical cord to just 5 cm below the upper surface.

3. A nylon net cover consisting of 2 parts is attached to a plastic frame. There are 12 tiny holes around the edge of the plastic frame for tying string to fix a rubber latex sheet or pork skin. To make an artificial anterior abdominal wall, the nylon net cover is placed on the top of the glass box, then a rubber latex sheet or a piece of pork skin (skin, muscle and subcutaneous fatty layers) is fixed over the cover. For the first half of the practice period with the model, the rubber latex sheet is used because it has less sound wave absorption, and




Figure 1. A cordocentesis training model (A) materials of the model (water container, umbilical cord and pork skin cover) (B) a model after the combination (C) a water-filled model ready for practice.

provides a brighter and clearer image. During the latter half, more experience is gained by practicing with the pork skin cover, which is used to make a better sensation like the real anterior abdominal wall of a pregnant woman, and this will improve the skill.

How to practice (Fig. 2)

The necessary instruments for training are composed of a cordocentesis model as described above, an ultrasound machine, a 21- to 23- gauge spinal needle and a 1-2 mL plastic disposable syringe for aspiration. As in real practice, the surgeon has to search for the optimal puncture site of the umbilical cord under transabdominal ultrasound guidance in both the cross sectional and sagittal plane. Then, the trainee has to punch the needle into the rubber or pork skin cover as close as possible to the probe and try to point it towards the umbilical cord. It is very important to pass the needle along the ultrasound beam by following the sparkling sign of the needle's tip. As soon as it reaches the umbilical cord, the tip is adjusted and its puncture is directed through the middle of the cord caliber. Then the needle is penetrated speedily by a wrist jerking movement into the umbilical vessel. Finally, aspiration of the mercurochrome is attempted with a disposable syringe, as performed in real cordocentesis.

Training course

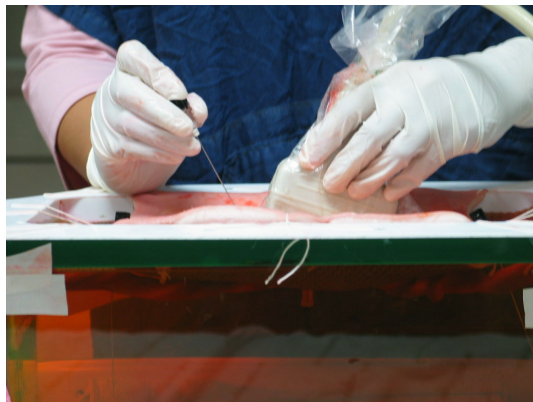The cordocentesis training program has been developed for cordocentesis training within a 15-day period. The trainee has to successfully aspirate mercurochrome 20 times per day. At the end of the training, it is expected that the trainee will have performed a total of 300 procedures on the model, is able to orientate transabdominal ultrasonographic

probe, and can control the needle confidently. After completing the training course with the model, the trainee is allowed to perform cordocentesis under expert supervision, with a time limit of 30 minutes. If the procedure has not been successful in 30 minutes it is considered a failure and the supervisor, who is always readily available, will take over to complete the operation.

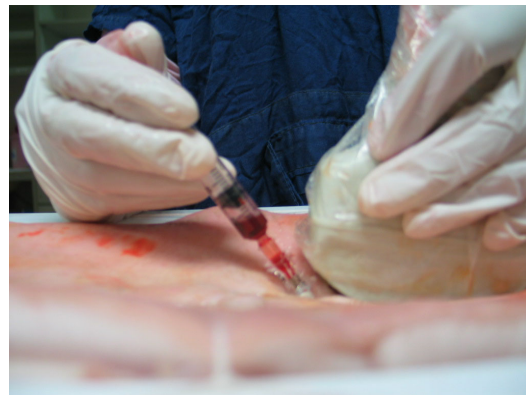To develop skills for cordocentesis, a model allows the surgeon to become familiar with the orientation of the umbilical cord and sampling needle. This author's experience with the model has been very favorable. The surgeon can confidently approach as in the real situation, and successfully perform the procedures without more immediate complications.⁽⁷⁾ The author believes that preclinical training is essential before starting real ultrasound-guided invasive procedures in fetal medicine, and that the cordocentesis model can help the inexperienced surgeon in their first steps to develop a skill with no patient risk. Furthermore, the model consists of inexpensive simple material that can be easily prepared in any health care center. This model practice is probably helpful in adjusting the probe and umbilical cord, leading to an improvement in needle control under an ultrasound guide.

Conclusion

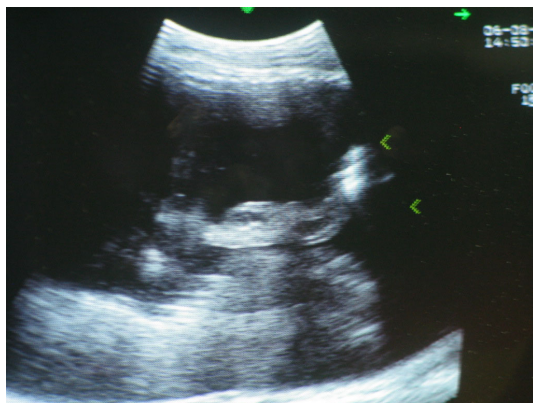
Cordocentesis has been recognized as a relatively safe and widely-used method for prenatal diagnosis. The procedure-related fetal loss risk is 1.40%, which is mainly associated with the surgeon's experience. Therefore, it is necessary for the surgeon to practice increasingly to develop their skill and lower associated complications. Training with a cordocentesis model can also be effective for early practitioners to develop their experience



A



B



C

Figure 2. Practice with a cordocentesis training model; free hand technique
(A) a needle is inserted through the pork skin cover
(B) mercurochrome is aspirated with a disposable syringe
(C) ultrasonographic picture of the umbilical cord in the model.

and skill in cordocentesis without any fetal and maternal jeopardy. Besides, the surgeon can repeatedly practice with the model to gain confidence in approaching the real situation, especially if there is a limited number of cases available.

References

1. Daffos F, Capella-Pavlovsky M, Forestier F. Fetal blood sampling via the umbilical cord using a needle guided by ultrasound. Report of 66 cases. *Prenat Diagn* 1983;3:271-7.
2. Ghezzi F, Maymon E, Redman M, Blackwell S, Berry SM, Romero R. Fetal blood sampling. In: Fleischer AC, editor. *Sonography in obstetrics and gynecology: principle and practice*. New York: McGraw-Hill; 2001. p. 775-804.
3. Weiner CP. Cordocentesis In: Evans MI, Johnson MP, Yaron Y, Drugan A, editors. *Prenatal diagnosis*. New York: McGraw-Hill; 2006. p. 443-7.
4. Liao C, Wei J, Li Q, Li L, Li J, Li D. Efficacy and safety of cordocentesis for prenatal diagnosis. *Int J Gynaecol Obstet* 2006;93:13-7.
5. Tongsong T, Wanapirak C, Kunavatikul C, Sirirchotiyakul S, Piyamongkol W, Chanprapaph P. Cordocentesis at 16-24 weeks of gestation: experience of 1,320 cases. *Prenat Diagn* 2000;20:224-8.
6. Evans MI, Goldberg JD, Dommergues M, et al. Efficacy of second-trimester selective termination for fetal abnormalities: international collaborative experience among the world's largest centers. *Am J Obstet Gynecol* 1994;171:90-4.
7. Tongprasert F, Tongsong T, Wanapirak C, Sirirchotiyakul S, Piyamongkol W, Chanprapaph P. Experience of the first 50 cases of cordocentesis after training with model. *J Med Assoc Thai* 2005; 88:728-33.
8. Weiner CP, Wenstrom KD, Sipes SL, Williamson RA. Risk factors for cordocentesis and fetal intra-

- vascular transfusion. *Am J Obstet Gynecol* 1991; 165:1020-5.
9. Ghidini A, Sepulveda W, Lockwood CJ, Romero R. Complications of fetal blood sampling. *Am J Obstet Gynecol* 1993;168:1339-44.
 10. Boulot P, Deschamps F, Lefort G, et al. Pure fetal blood samples obtained by cordocentesis: technical aspects of 322 cases. *Prenat Diagn* 1990;10:93-100.
 11. Daffos F, Capella-Pavlovsky M, Forestier F. Fetal blood sampling during pregnancy with use of a needle guided by ultrasound: a study of 606 consecutive cases. *Am J Obstet Gynecol* 1985;153:655-60.
 12. Donner C, Rypens F, Paquet V, et al. Cordocentesis for rapid karyotype: 421 consecutive cases. *Fetal Diagn Ther* 1995;10:192-9.
 13. Donner C, Simon P, Karioun A, Avni F, Rodesch F. Experience of a single team of operators in 891 diagnostic funipunctures. *Obstet Gynecol* 1994;84: 827-31.
 14. Weiner CP, Okamura K. Diagnostic fetal blood sampling-technique related losses. *Fetal Diagn Ther* 1996;11:169-75.
 15. Tongsong T, Wanapirak C, Kunavikatikul C, Sirirchotiyakul S, Piyamongkol W, Chanprapaph P. Fetal loss rate associated with cordocentesis at midgestation. *Am J Obstet Gynecol* 2001;184:719-23.
 16. Jauniaux E, Donner C, Simon P, Vanesse M, Hustin J, Rodesch F. Pathologic aspects of the umbilical cord after percutaneous umbilical blood sampling. *Obstet Gynecol* 1989;73:215-8.
 17. Nicolini U, Kochenour NK, Greco P, et al. Consequences of fetomaternal haemorrhage after intrauterine transfusion. *Bmj* 1988;297:1379-81.
 18. Rujiwetpongstorn J, Tongsong T, Wanapirak C, et al. Feto-maternal hemorrhage after cordocentesis at Maharaj Nakorn Chiang Mai Hospital. *J Med Assoc Thai* 2005;88:145-9.
 19. Timor-Tritsch IE, Yeh MN. In vitro training model for diagnostic and therapeutic fetal intravascular needle puncture. *Am J Obstet Gynecol* 1987;157: 858-9.
 20. Angel JL, O'Brien WF, Michelson JA, Knuppel RA, Morales WJ. Instructional model for percutaneous fetal umbilical blood sampling. *Obstet Gynecol* 1989;73:669-71.
 21. Ville Y, Cooper M, Revel A, Frydman R, Nicolaides KH. Development of a training model for ultrasound-guided invasive procedures in fetal medicine. *Ultrasound Obstet Gynecol* 1995;5:180-3.

การเจาะเลือดสายสะดือทารกในครรภ์: ข้อบ่งชี้ เทคนิค ภาวะแทรกซ้อน และการฝึกปฏิบัติ

เฟื่องลดา ทองประเสริฐ, พ.บ.

ภาควิชาสูติศาสตร์และนรีเวชวิทยา คณะแพทยศาสตร์ มหาวิทยาลัยเชียงใหม่

บทคัดย่อ การเจาะเลือดสายสะดือทารกในครรภ์คือการดูเก็บตัวอย่างเลือดจากสายสะดือทารก โดยการเจาะเข็มเจาะผ่านผนังหน้าท้องมารดาโดยอาศัยภาพคลื่นเสียงความถี่สูงซึ่งใช้ในการทำหัตถการ ข้อบ่งชี้ส่วนใหญ่ใช้ในการตรวจวินิจฉัยทารกในครรภ์ก่อนคลอด เช่น โรคธาลัสซีเมียชนิดรุนแรง และภาวะโครโมโซมผิดปกติ นอกจากนี้สามารถใช้รักษาทารกในครรภ์โดยการให้เลือด ส่วนประกอบของเลือด หรือให้ยาบางชนิดผ่านทางเส้นเลือดทารกได้ โดยทั่วไปมักทำเมื่ออายุครรภ์ 18 สัปดาห์ขึ้นไป อัตราการสูญเสียทารกจากการทำหัตถการประมาณร้อยละ 1.40 โดยพบว่าสัมพันธ์กับประสบการณ์ของผู้ทำหัตถการ ในบทความนี้จะทบทวนข้อบ่งชี้ เทคนิค ภาวะแทรกซ้อนของการเจาะเลือดสายสะดือทารกในครรภ์ และผู้เขียนได้เสนอการฝึกปฏิบัติการเจาะเลือดสายสะดือทารกในครรภ์อย่างเป็นระบบเพื่อเพิ่มทักษะในการทำหัตถการให้ได้ผลยิ่งขึ้น **เชียงใหม่เวชสาร 2550; 46(3):119-127.**

คำสำคัญ: การเจาะเลือดสายสะดือทารกในครรภ์ การวินิจฉัยก่อนคลอด การสูญเสียทารก การฝึกปฏิบัติการเจาะเลือดสายสะดือทารกในครรภ์
