

Pediatric Facial Gunshot injuries

Abdulrahman Alamri (R4)

Trauma rounds (22 Feb 2016)

Disclosure

- I have no conflict of interest to declare; I have no affiliation, honoraria or monetary support from an industry source.

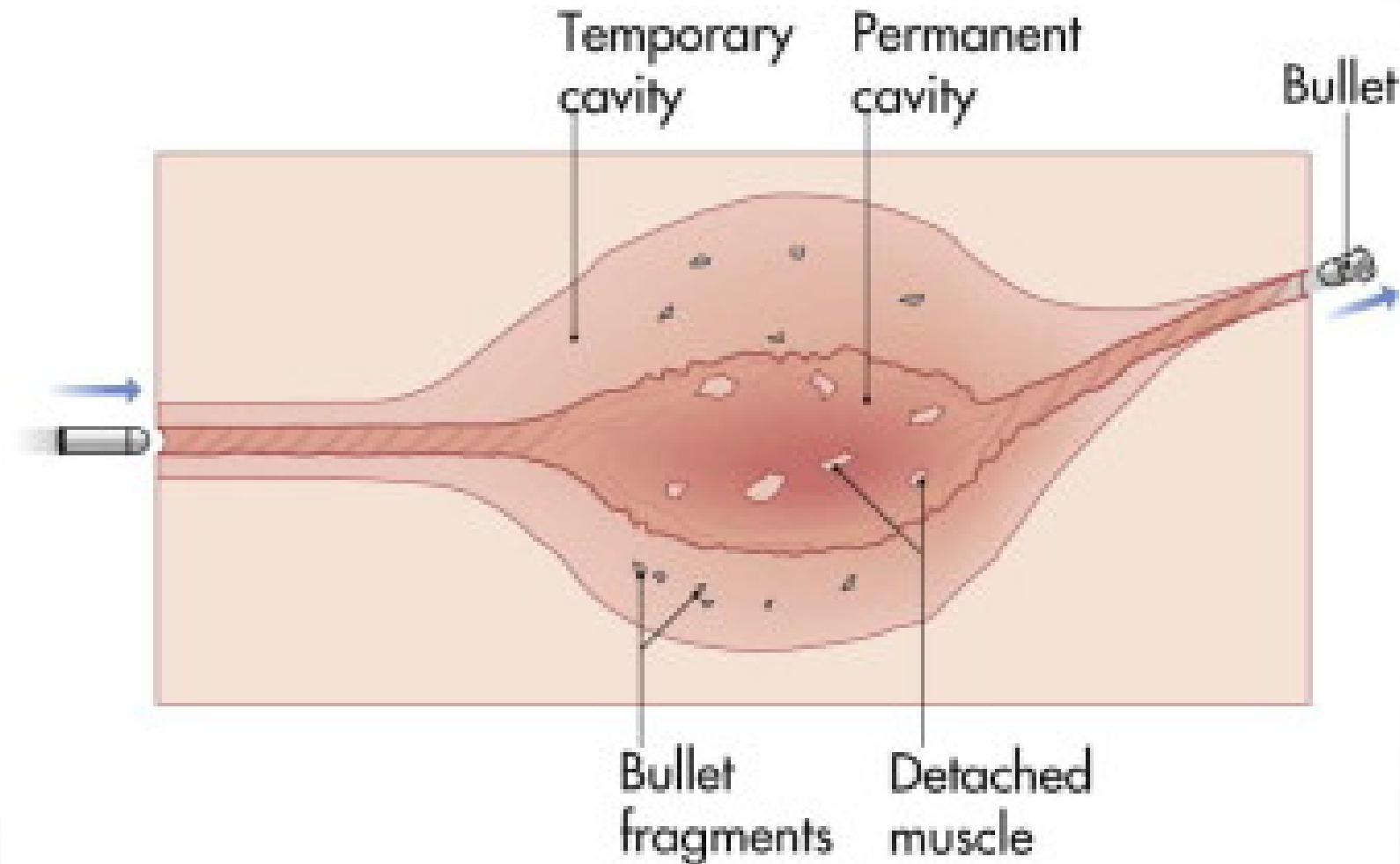
Introduction

- Recently ballistic weapons have added new dimensions to the complexity of facial injuries.
- The goal of management of these complex injuries is to restore function as well as preserve the appearance of facial structures.

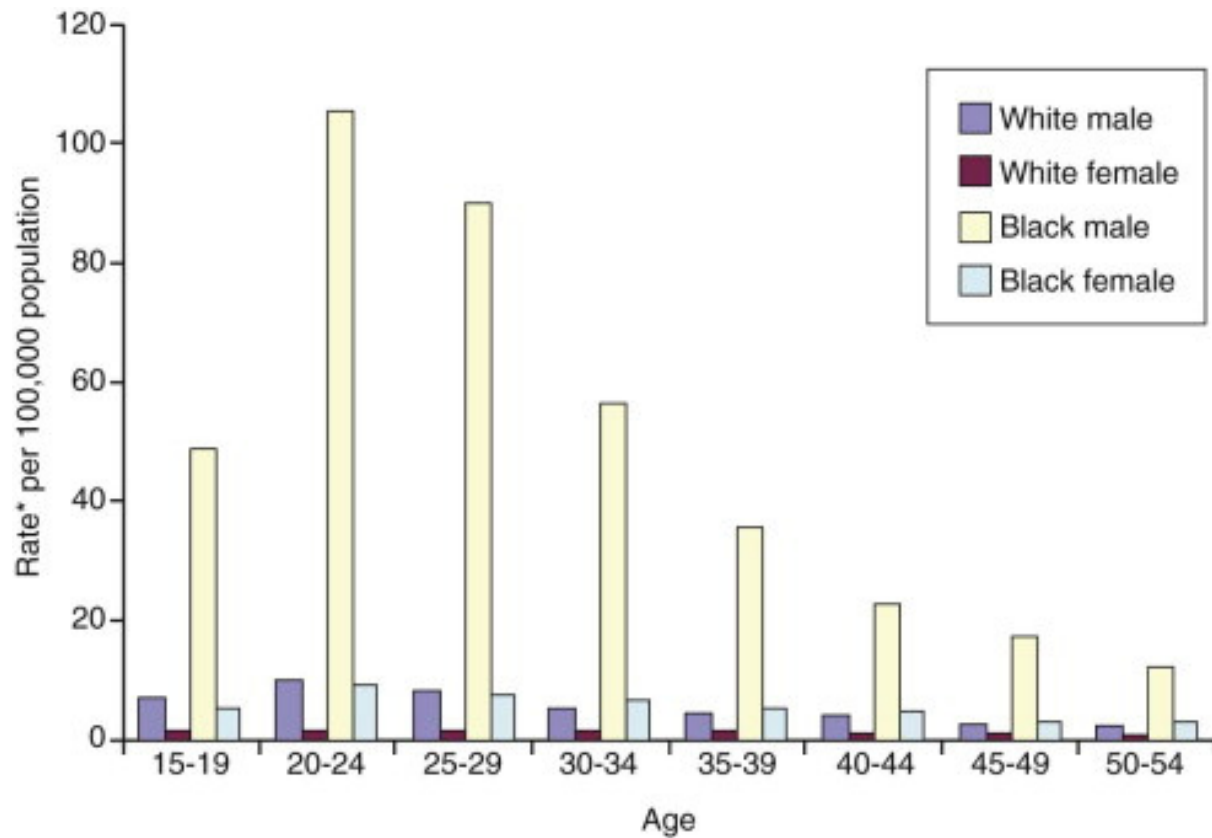
Introduction

- The principles of management of ballistic injuries (aggressive debridement, wound excision and drainage, serial dressings and healing by secondary intention, and late secondary reconstruction) were formulated in early 1700s.
- Since then advances in open reduction techniques and complex reconstruction procedures were improved dramatically in order to enhance the management principles.

Pathophysiology



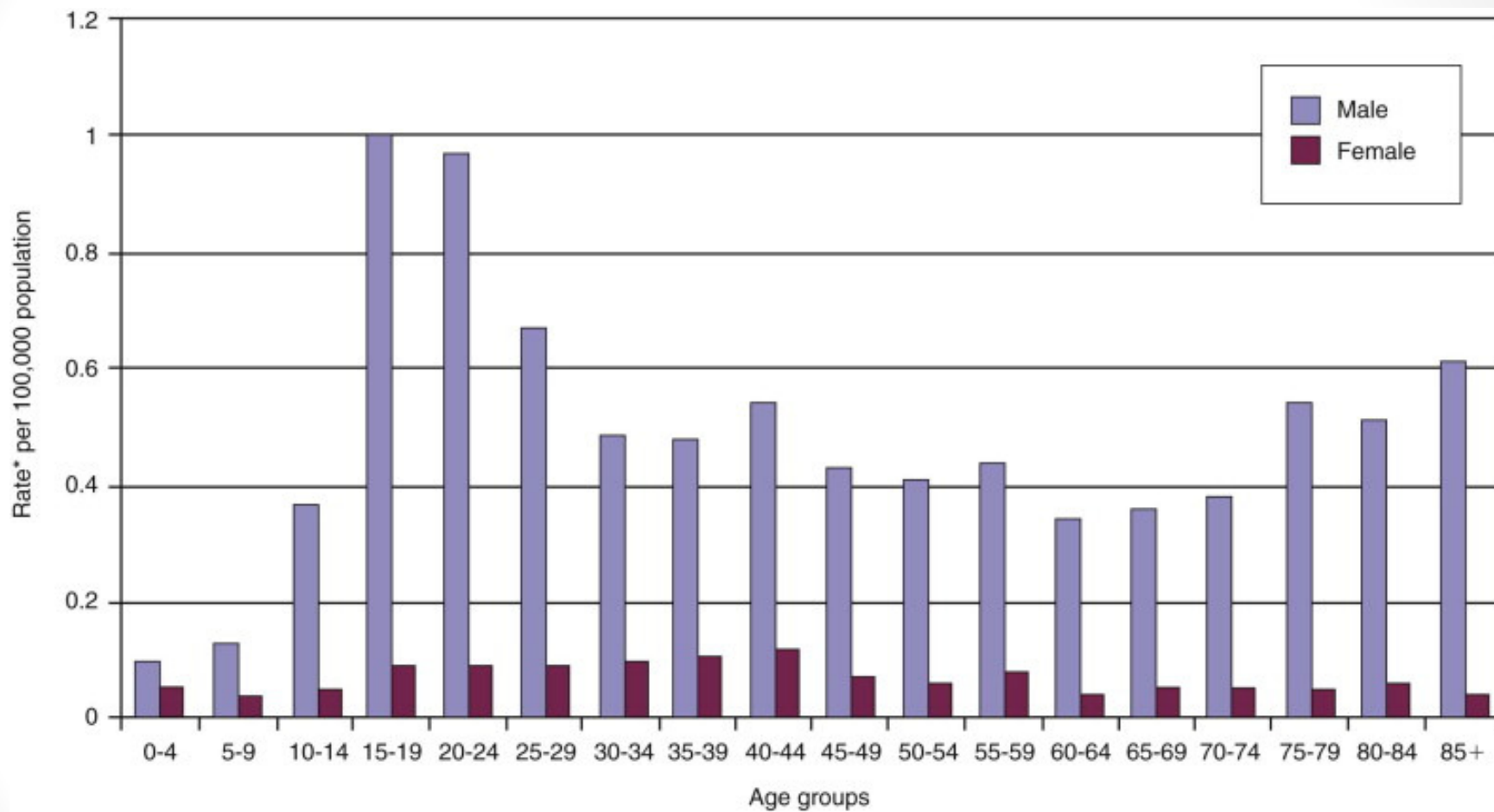
Prevalence



* Age-adjusted rate per 100,000 U.S. Standard population based on year 2000 standard

Pediatric Firearm injuries risk factors

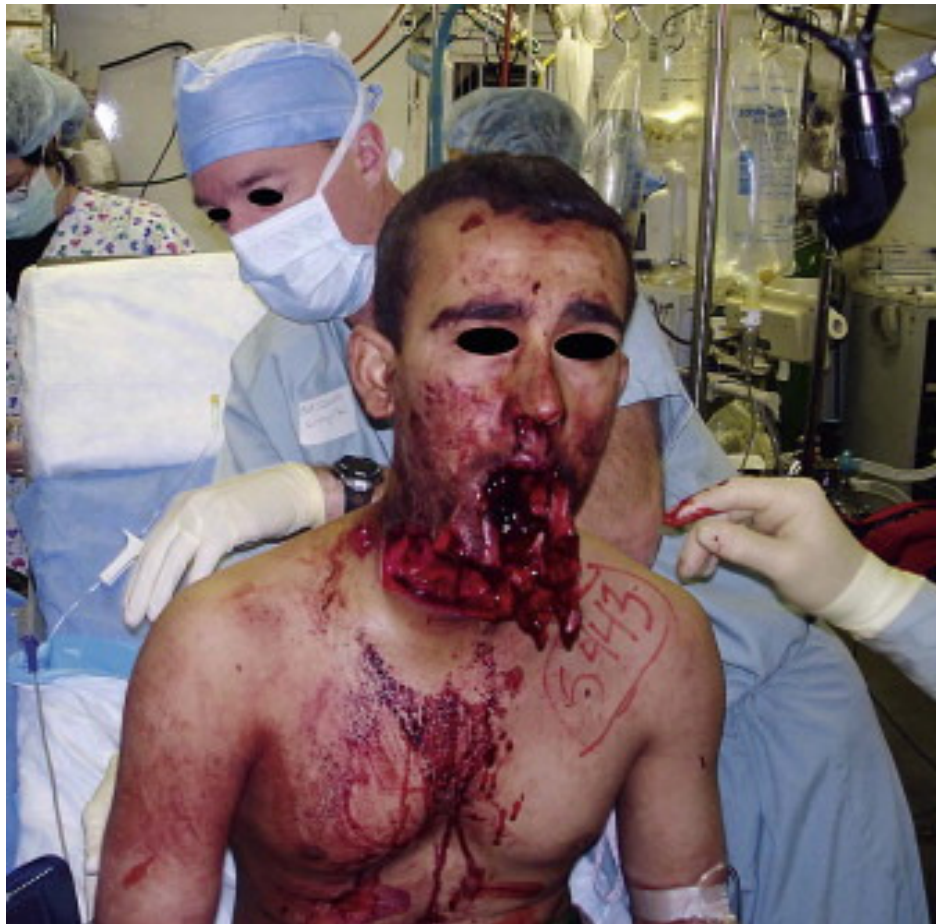- Paris et al have evaluated risk factors associated with nonfatal firearm injuries among inner city adolescents in the United States
- living with less than two parents
- frequent school absences
- previous arrest history
- Being african-american
- 10 times higher in urban areas than in rural areas (Nance et al)



* Age-adjusted rate per 100,000 U.S. Standard population based on year 2000 standard.

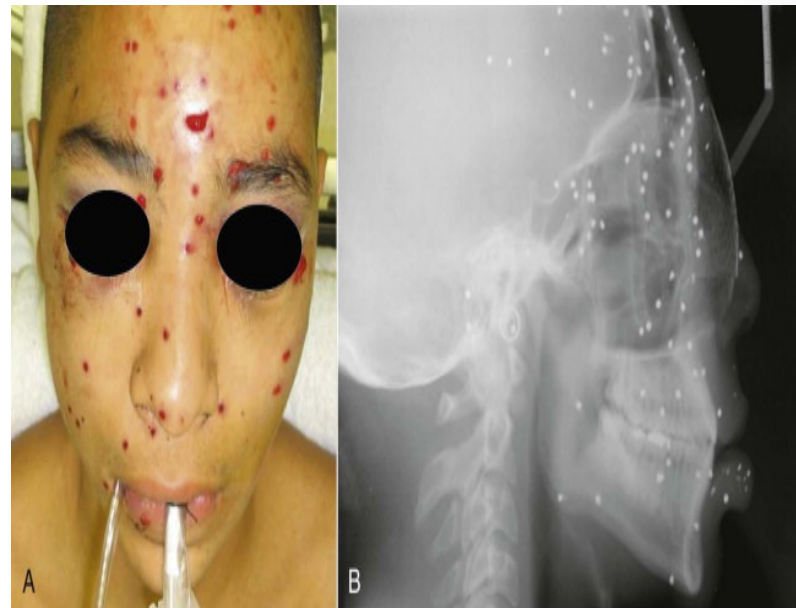Initial management

- management of the airway is of supreme importance. Intubation or tracheostomy (Hollier et al 21%) should be liberally done especially in cases of transfer.
- Initial ATLS protocol (C-spine precaution, other injuries)
- In addition to routine imaging studies in trauma patients, CT Facial bones/head/neck CTA.



Initial management

- The presence of catastrophic wounds to the craniomaxillofacial complex may serve as a distraction to emergency medical service personnel, focusing their attention away from potentially life-threatening injuries and wasting valuable time that could be better used for treatment of potentially lethal injuries, stabilization, and preparation for transport

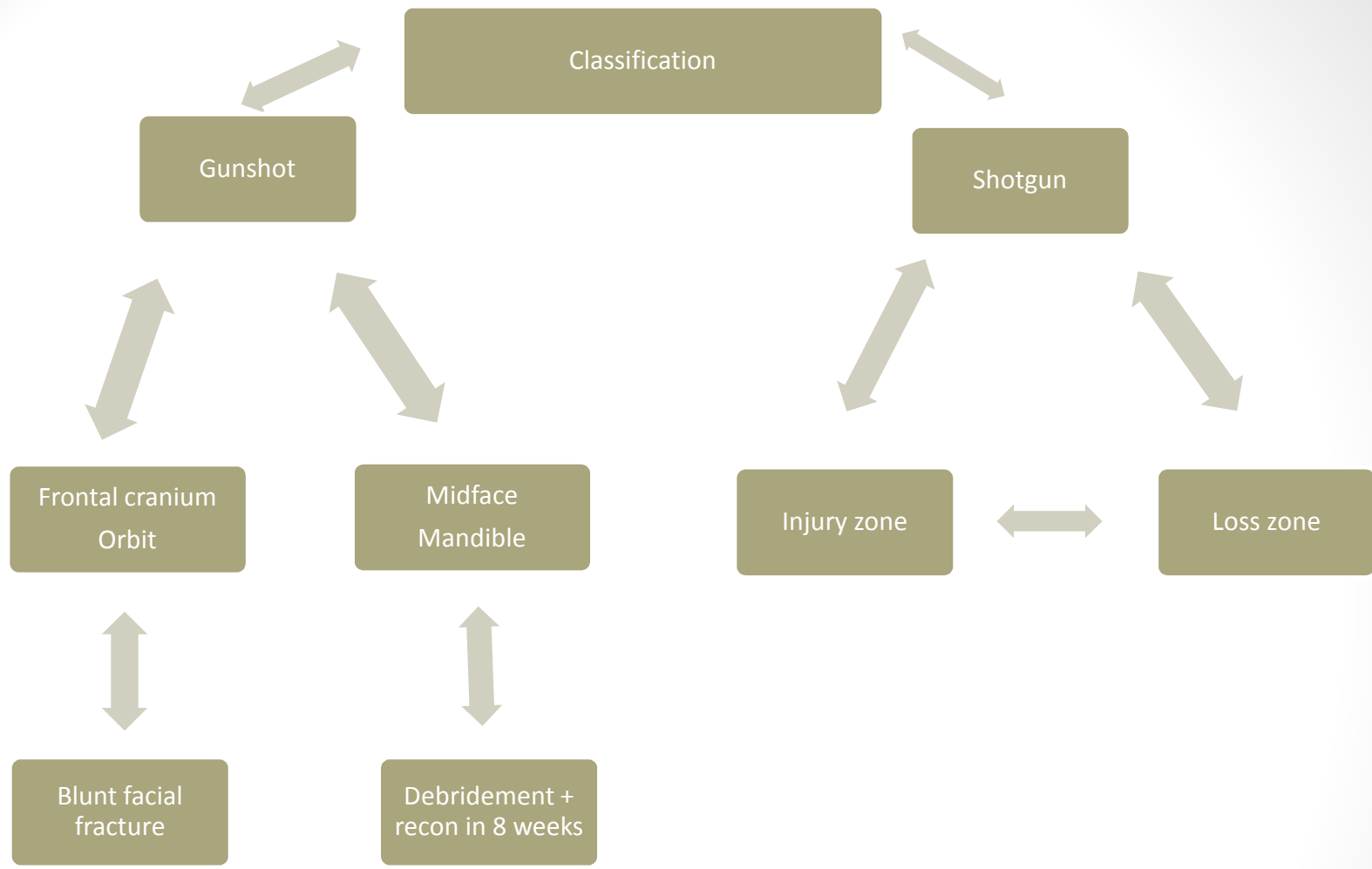


Classification

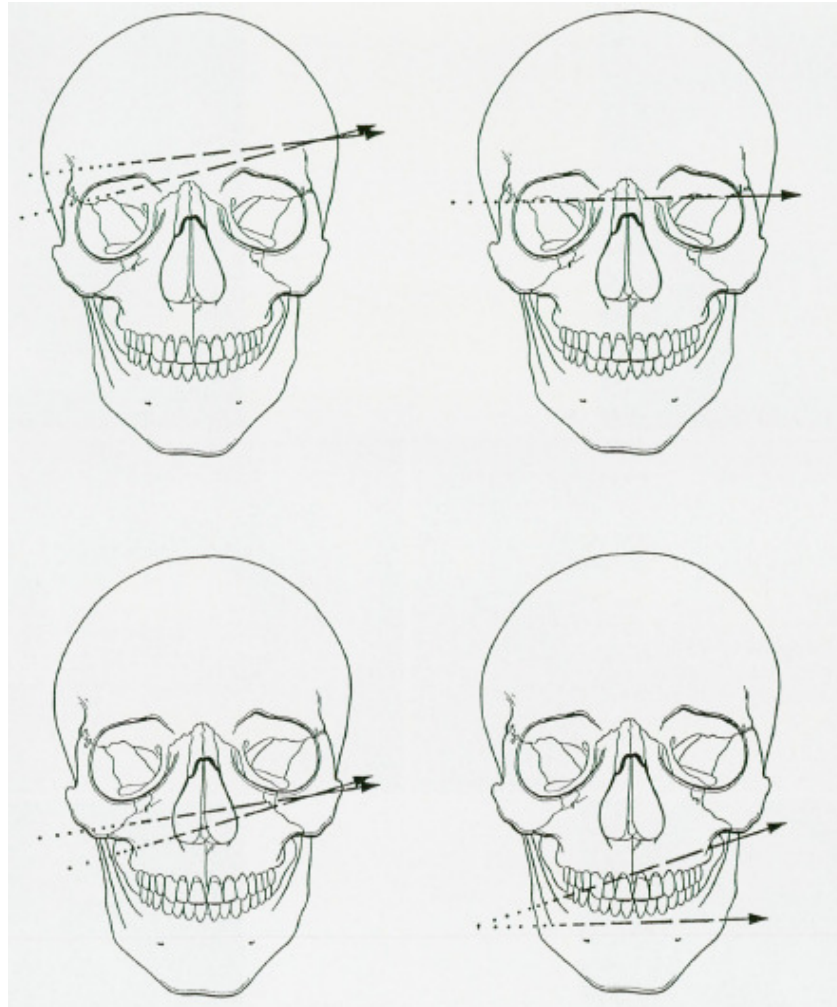
- Based on velocity:
 - Low velocity < 1000 feet per sec
 - Medium velocity >1000 <1200 feet per sec
 - High velocity = 1200 feet per sec or more
-
- This classification is particularly important to identify the status of soft tissue viability as it is expected to have necrosis and devitalized soft tissue with medium & high velocity GSW.

Classification

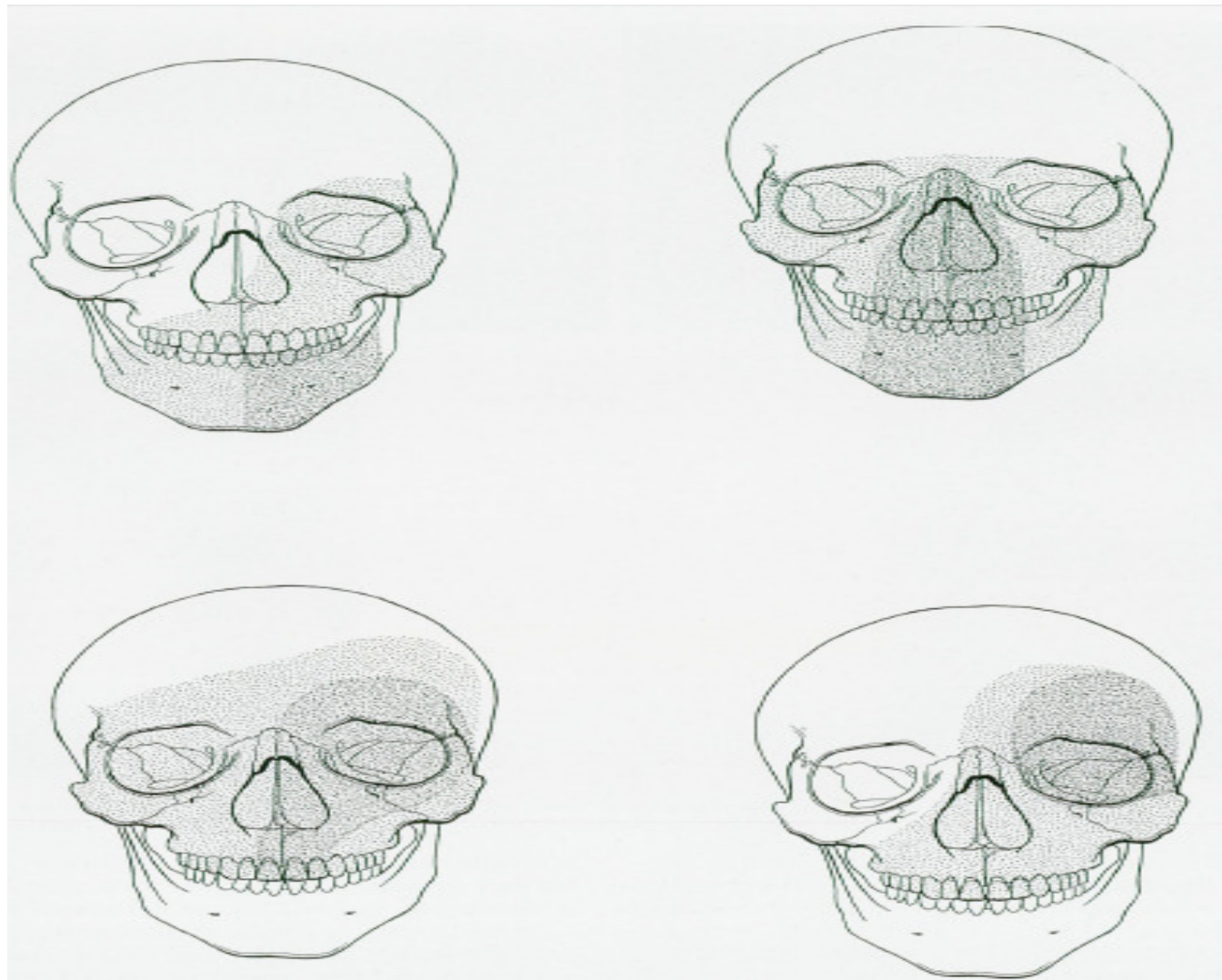
- Soft tissue & bone zone of injury
- Soft tissue & bone zone of loss
- This classification was implemented on 1982 were the distinction between both zones was the mainstay of the emerging principle of primary early fixation and coverage with conservative debridement, with management of the zone of loss early by bridging of the bone loss and tissue advancement for coverage.
- Serial conservative debridement (Q24-48hr) can be done if necessary.
- Once all necrotic tissue is excised definitive bone & soft reconstruction is performed.



Gunshots



Shotguns



Lateral Cranio-orbital

- Primary bone grafting except for the orbit.
 - Free tissue transfer to obliterate the orbital cavity.
 - Scalp loss is reconstructed by advancement or rotation flaps.
-
- Primary early approach of this type of injuries is successful and accepted modality of treatment.

Lateral Midface

- Minimal zone of loss & injury: Advancement flaps with primary bone grafting & fixation.
- Major zone of loss & injury: free vascularized tissue transfer with skin paddle + later excision of the paddle as a secondary procedure combined with advancement flaps to improve aesthetic outcome.

Lateral Mandible

- No intraoral involvement: Advancement flaps with Primary bone fixation + delayed bone grafting as a secondary procedure.
- Intraoral involvement: vascularized free tissue transfer + delayed bone grafting & fixation as a secondary procedure.

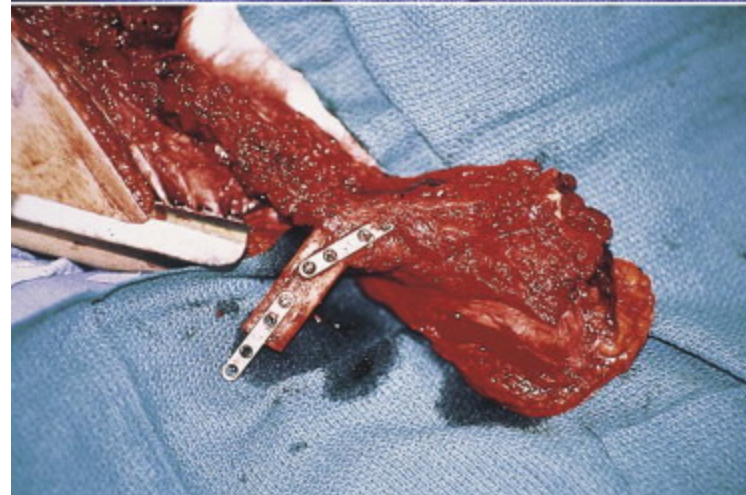
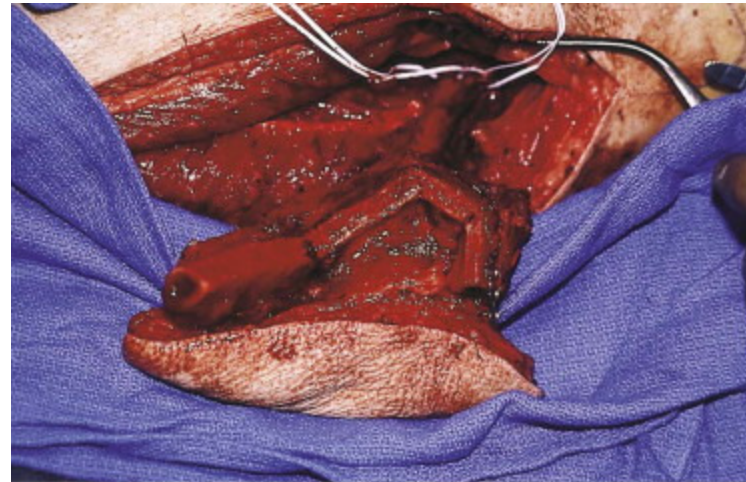
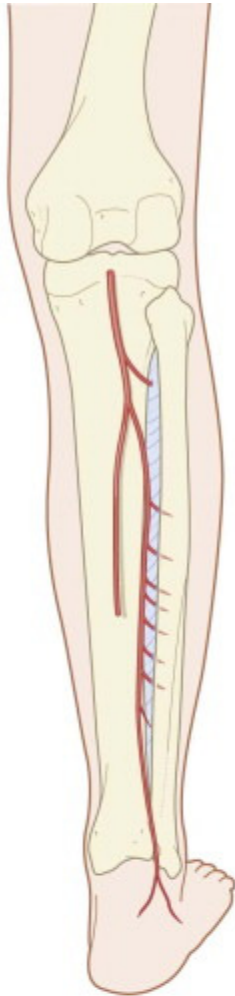
Central

- Very challenging, usually involve cutaneous and mucosal lining defects.
- Approach is highly dependent in identifying the zone of loss.
- Most often require multiple procedures and staging.
- Multiple free flaps are usually needed for complete reconstruction.

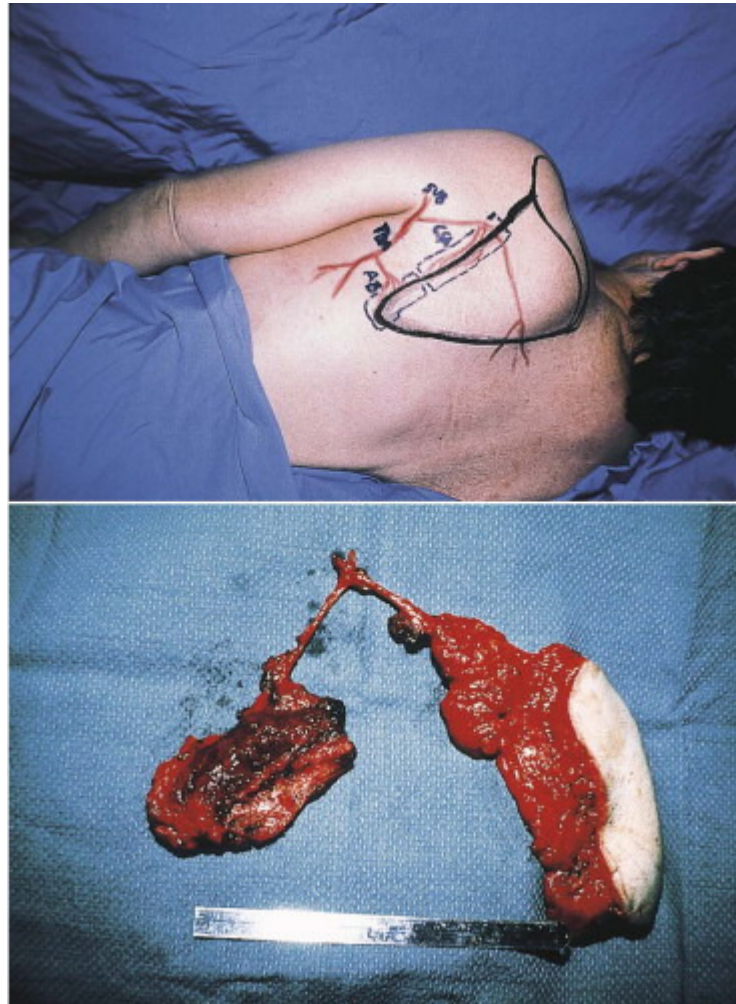
Central

- Moderate: vascularized free tissue transfer for lining reconstruction + advancement flaps for cutaneous coverage (may need multiple procedures or staging)
- Extensive: multiple vascularized free tissue transfer +/- Regional flaps

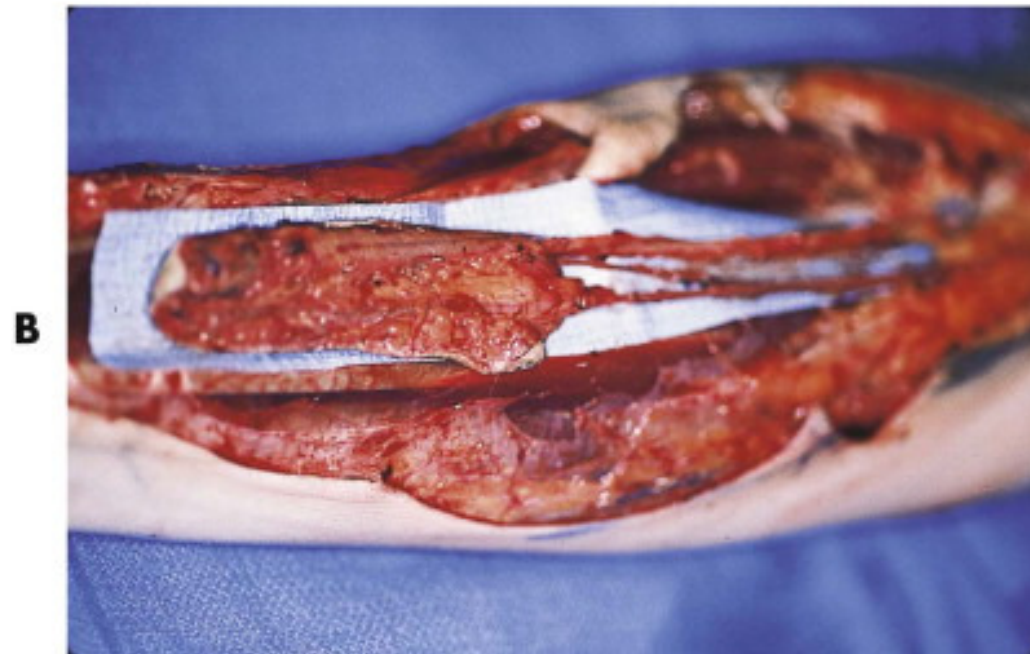
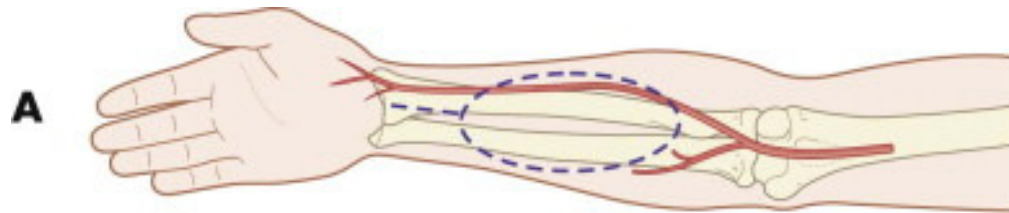
Free tissue transfer



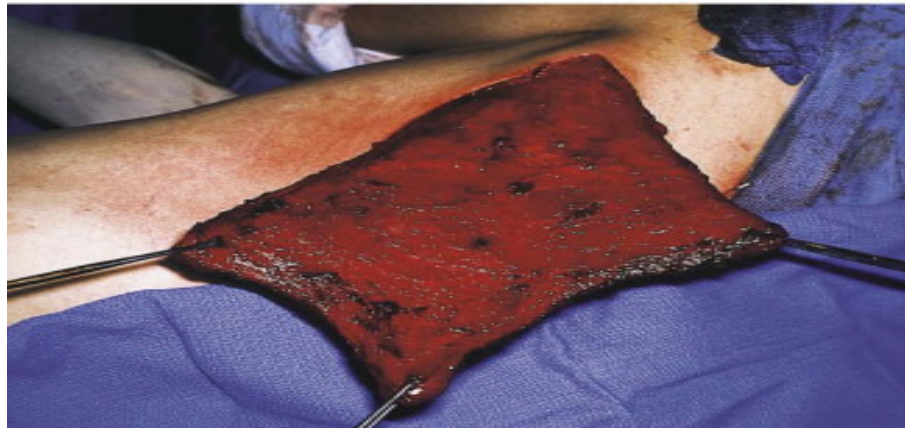
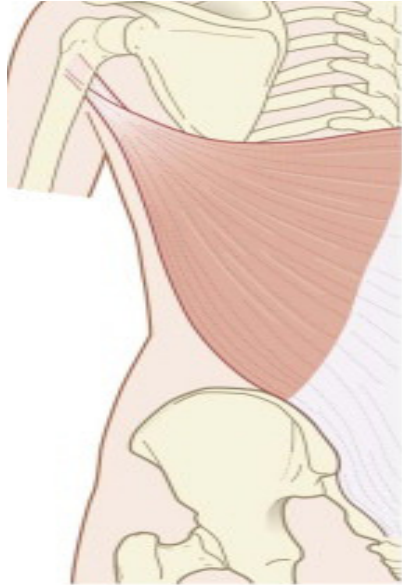
Free tissue transfer



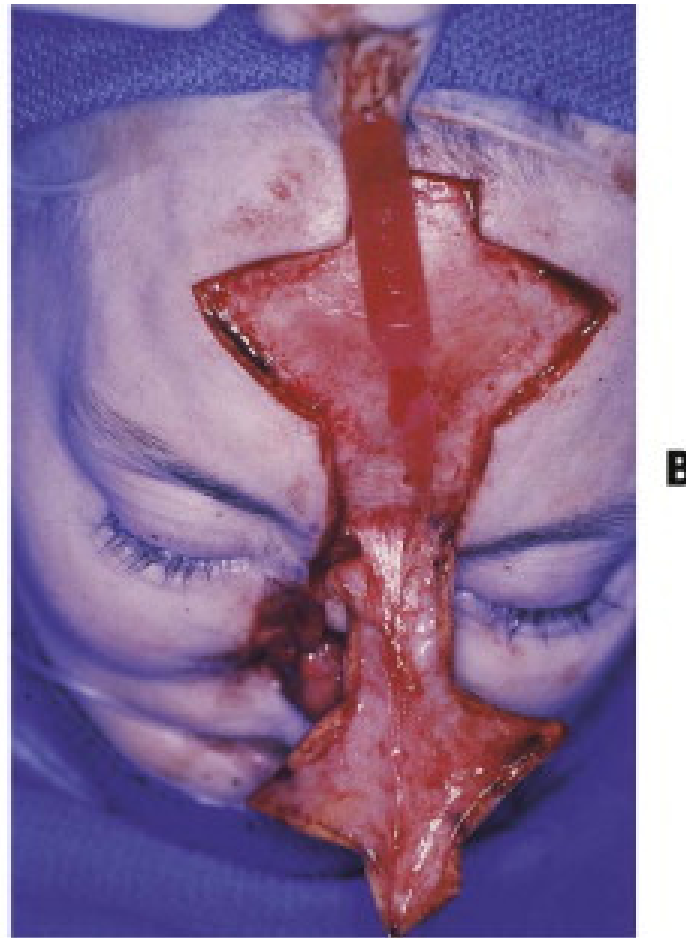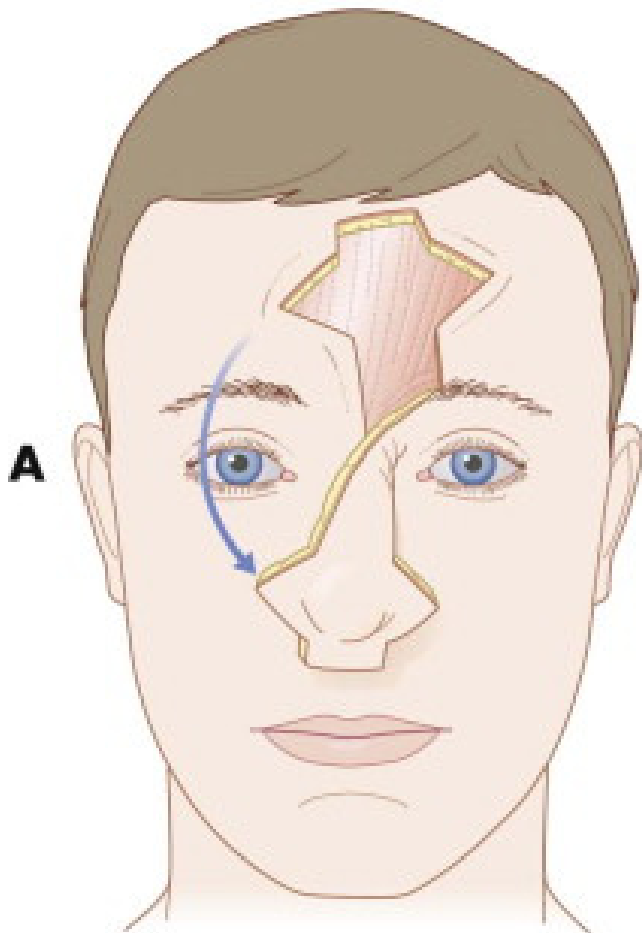
Free tissue transfer



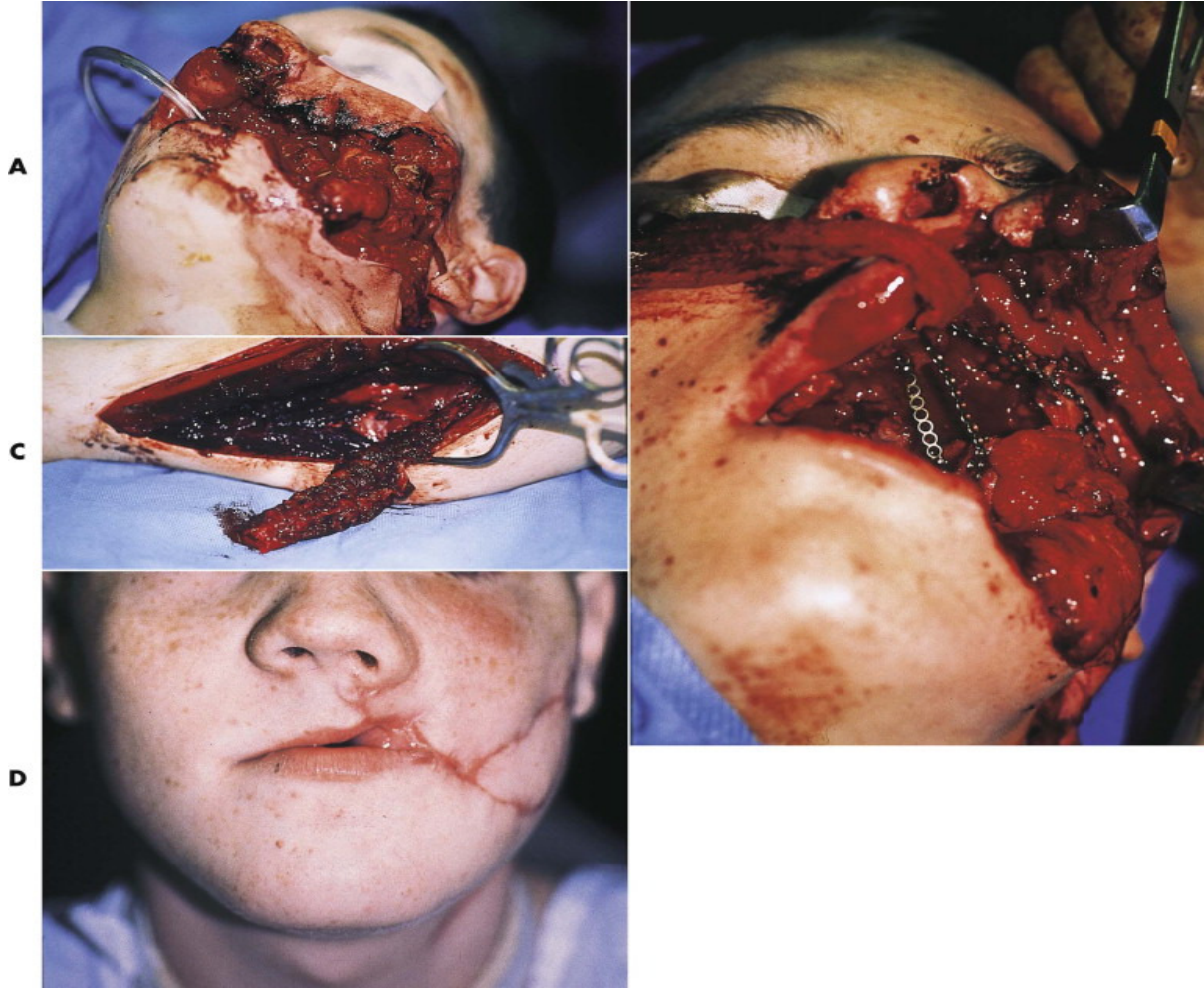
Free tissue transfer



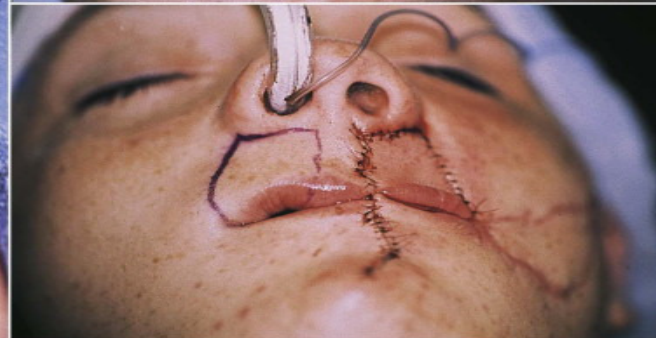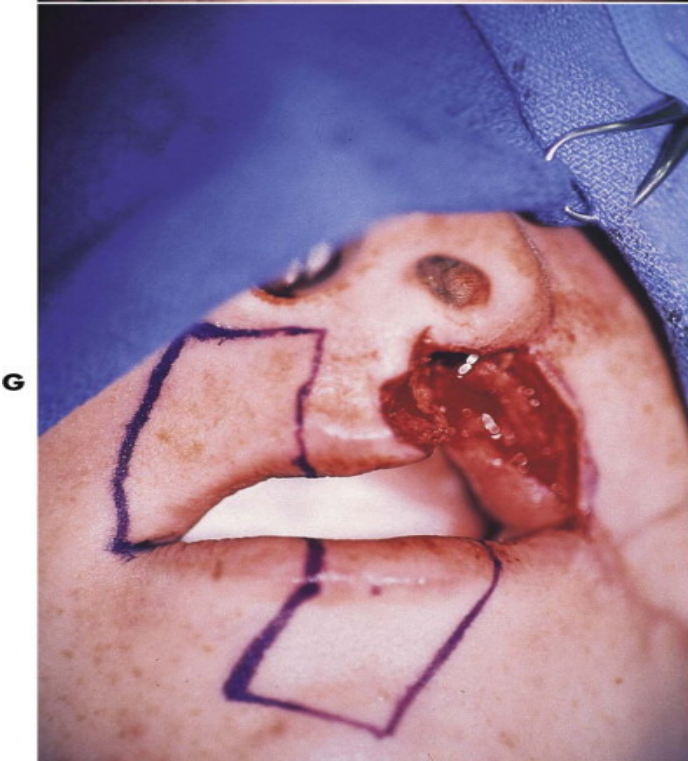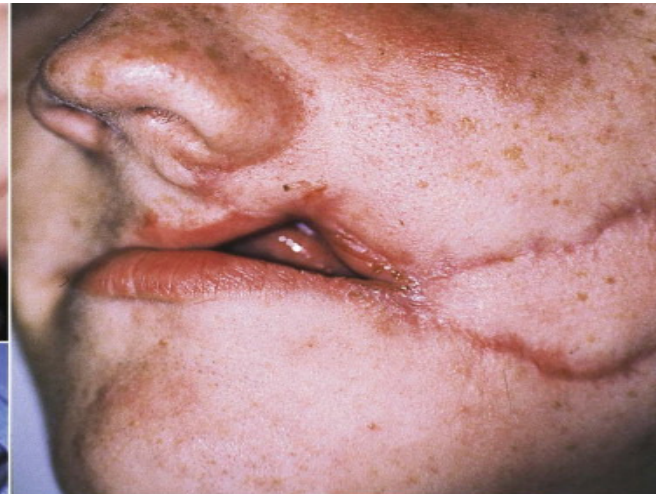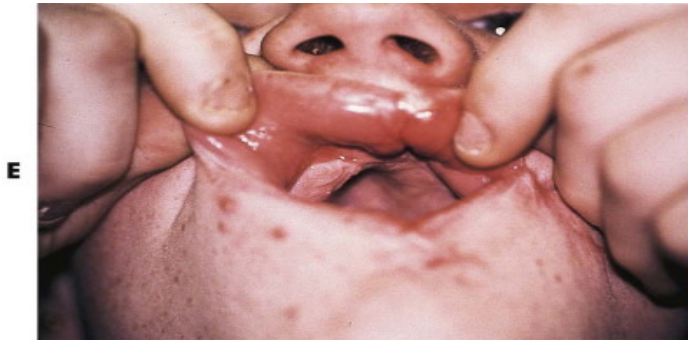Loco-regional transfer



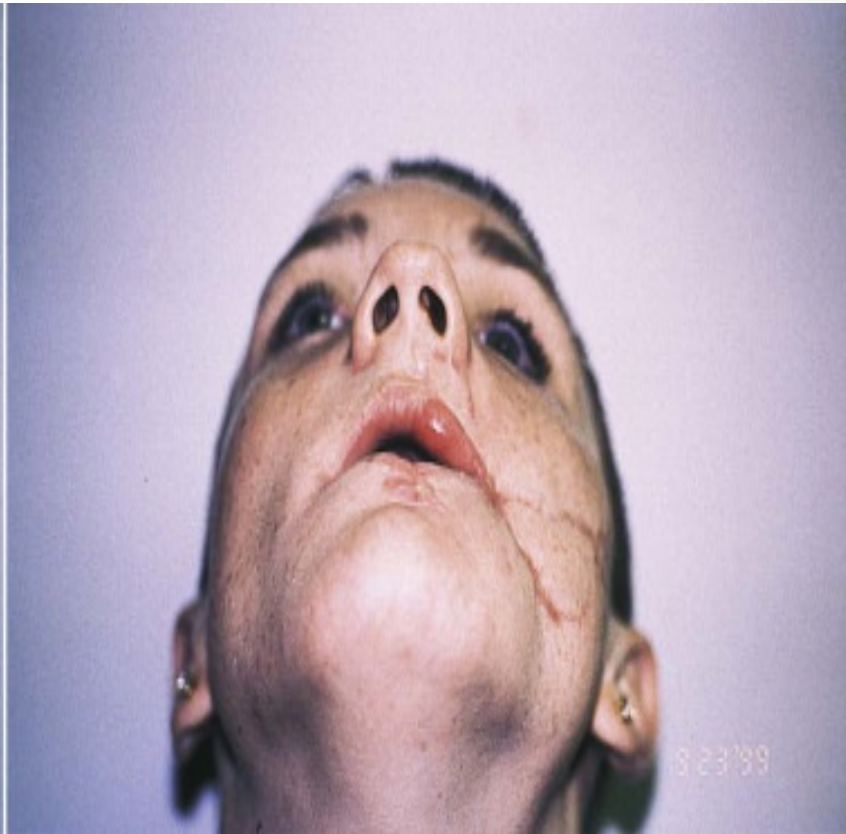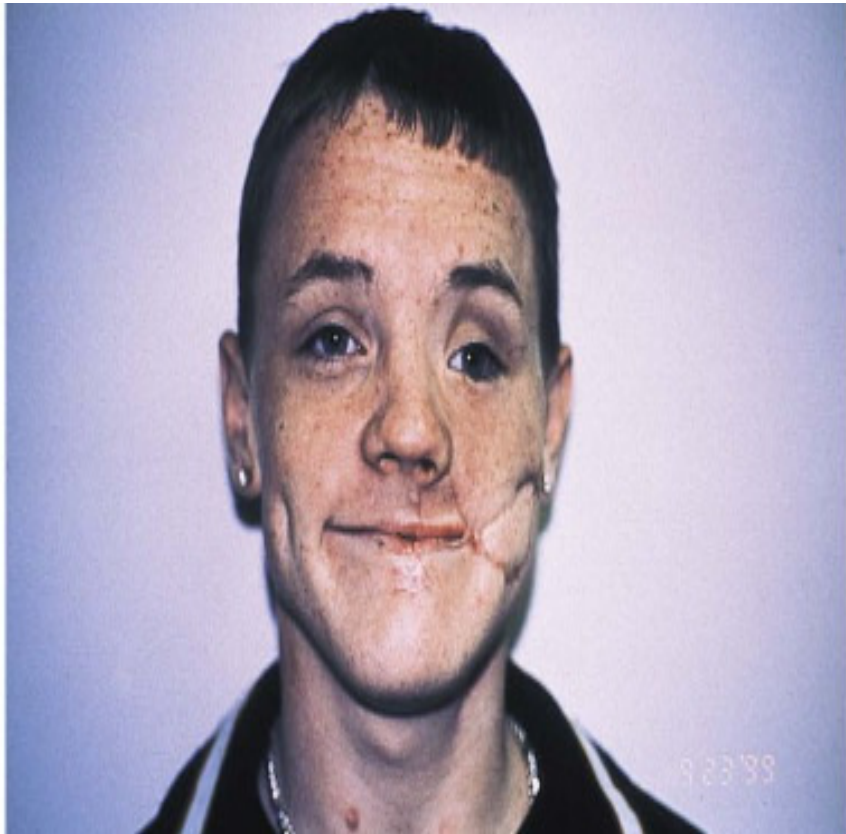Loco-regional transfer



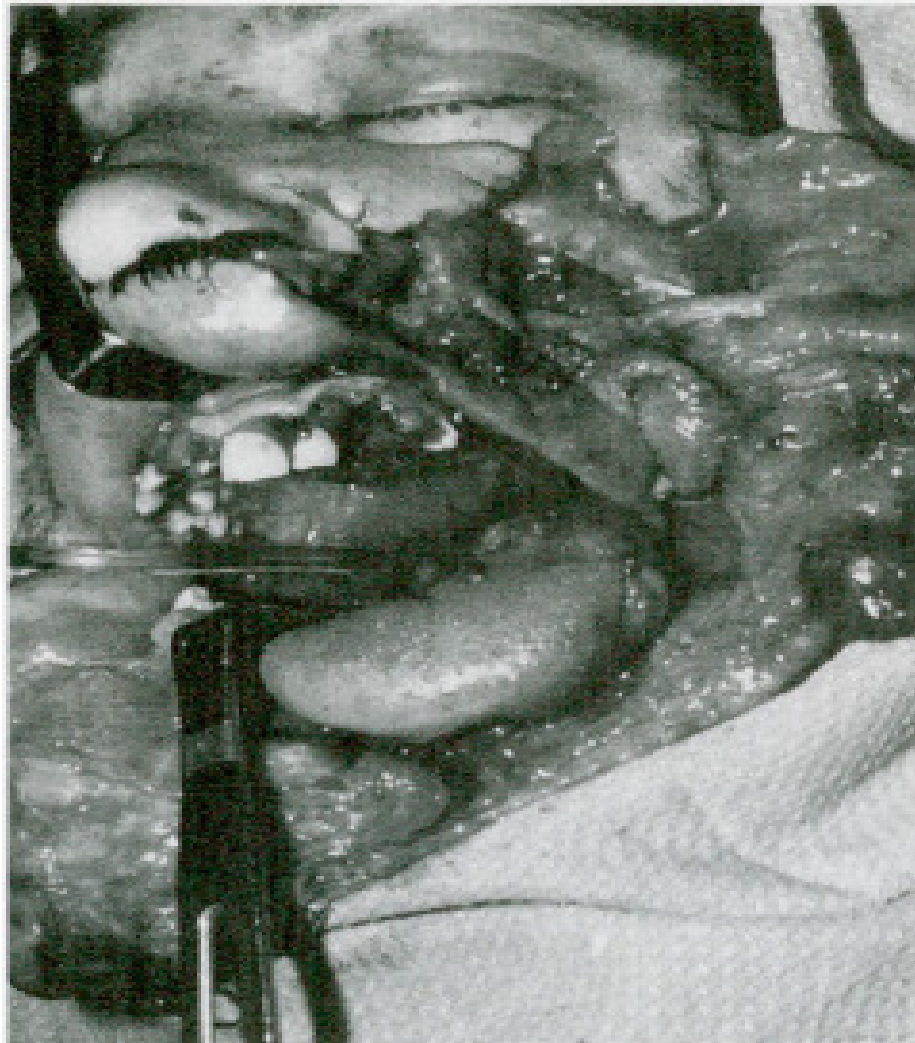Loco-regional transfer



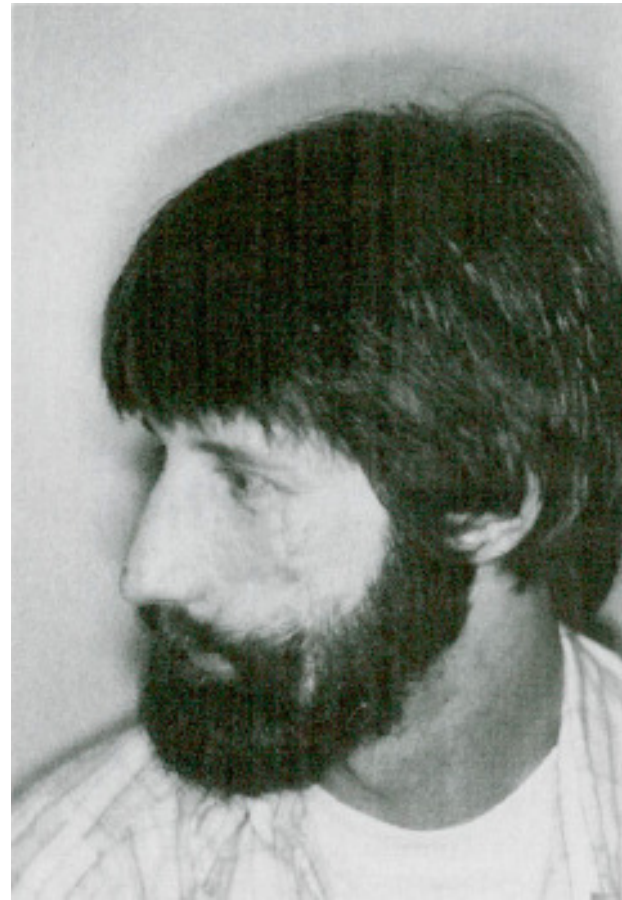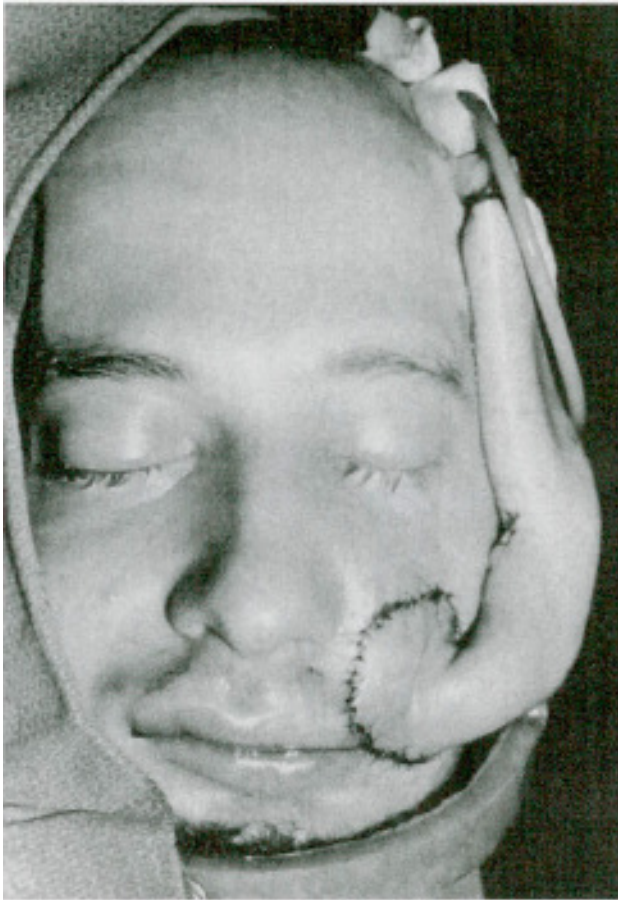Loco-regional transfer



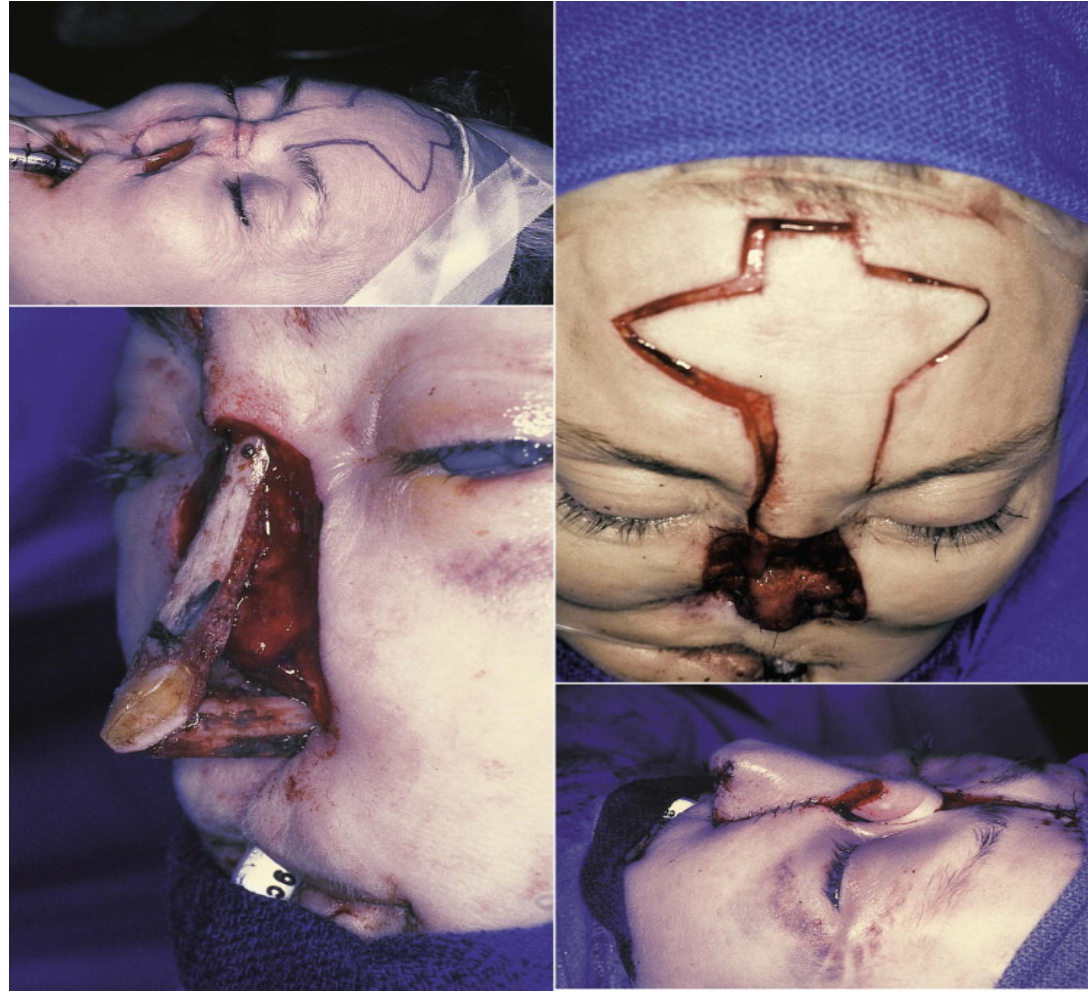
Loco-regional transfer



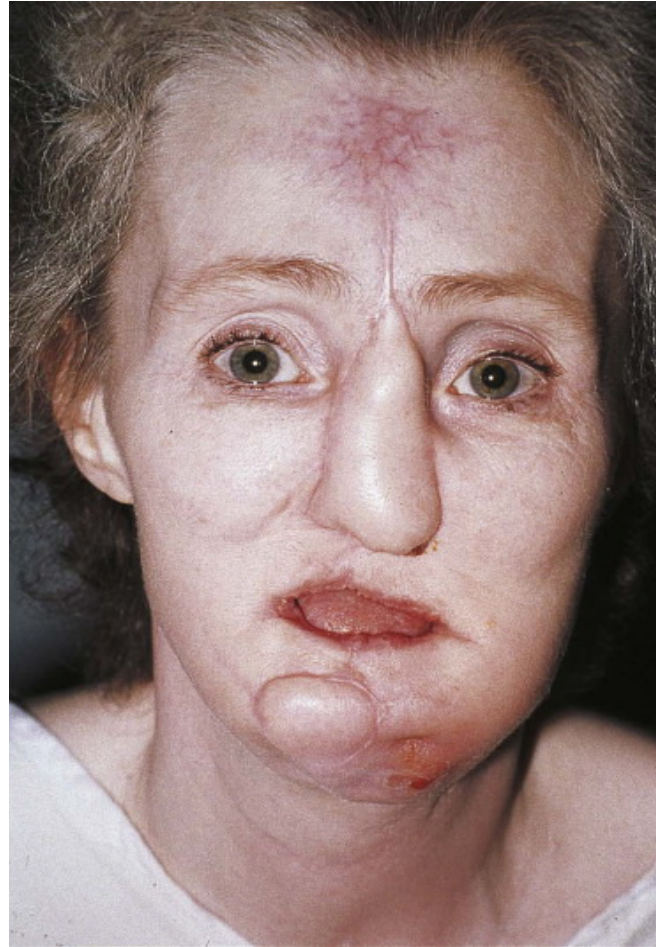
Loco-regional transfer



Loco-regional transfer



Loco-regional transfer



References

- Neligan Pediatric Plastic Textbook volume 3
- Maxillofacial Trauma and Esthetic Facial Reconstruction, Second Edition
- Oral and Maxillofacial Trauma, Forth Edition
- Pediatric Facial Fractures as a Result of Gunshot Injuries: An Examination of Associated Injuries and Trends in Management. Ian C. Hoppe et al
- High energy ballistic and avulsive facial injuries: classification, patterns, and algorithm for primary recnstruction. Norman Clark et al
- Early definitive bone and soft tissue reconstruction of major gunshot wounds of the face. Joseph S. Gruss et al
- Immediate and long-term management of gunshot wounds to the lower face. Carl N. Williams et al.
- Primary treatment of shotgun injuries to the face. Wallace A. Goodstein et al.
- High energy ballistic and avulsive injuries: a management protocol for the next millennium. Bradley et al.

Thank You