



ISSN (E): 2277- 7695

ISSN (P): 2349-8242

NAAS Rating: 5.03

TPI 2020; SP-9(10): 195-197

© 2020 TPI

[www.thepharmajournal.com](http://www.thepharmajournal.com)

Received: 22-08-2020

Accepted: 29-09-2020

#### Dhruba Das

M.V.S.c Scholar, Department of Veterinary Medicine, College of Veterinary Sciences and Animal Husbandry, Central Agricultural University, Selesih, Aizawl, Mizoram, India

#### Nikitasha Bora

M.V.S.c Scholar, Department of Veterinary Medicine, College of Veterinary Sciences and Animal Husbandry, Central Agricultural University, Selesih, Aizawl, Mizoram, India

#### Champak Deka

M.V.S.c Scholar, Department of Veterinary Medicine, College of Veterinary Sciences and Animal Husbandry, Central Agricultural University, Selesih, Aizawl, Mizoram, India

#### Elone Lucy

M.V.S.c Scholar, Department of Veterinary Medicine, College of Veterinary Sciences and Animal Husbandry, Central Agricultural University, Selesih, Aizawl, Mizoram, India

#### Kaushik Poran Bordoloi

M.V.S.c Scholar, Department of Veterinary Medicine, College of Veterinary Sciences and Animal Husbandry, Central Agricultural University, Selesih, Aizawl, Mizoram, India

#### Ankita Debnath

M.V.S.c Scholar, Department of Veterinary Medicine, College of Veterinary Sciences and Animal Husbandry, Central Agricultural University, Selesih, Aizawl, Mizoram, India

#### Dilip Nama

M.V.S.c Scholar, Department of Veterinary Medicine, College of Veterinary Sciences and Animal Husbandry, Central Agricultural University, Selesih, Aizawl, Mizoram, India

#### Chethan GE

Assistant Professor, Department of Veterinary Medicine, College of Veterinary Sciences and Animal Husbandry, Central Agricultural University, Selesih, Aizawl, Mizoram, India

#### Devajani Deka

Assistant Professor, Department of Veterinary Public Health and Epidemiology, College of Veterinary Sciences and Animal Husbandry, Central Agricultural University, Selesih, Aizawl, Mizoram, India

#### Parimal Roychoudhury

Associate Professor, Department of Veterinary Microbiology, College of Veterinary Sciences and Animal Husbandry, Central Agricultural University, Selesih, Aizawl, Mizoram, India

#### Kalyan Sarma

Associate Professor, Department of Veterinary Medicine, College of Veterinary Sciences and Animal Husbandry, Central Agricultural University, Selesih, Aizawl, Mizoram, India

#### Corresponding Author:

##### Kalyan Sarma

Associate Professor, Department of Veterinary Medicine, College of Veterinary Sciences and Animal Husbandry, Central Agricultural University, Selesih, Aizawl, Mizoram, India

## Diagnosis and clinical management of haemagalactia in a Holstein Friesian crossbred cow

**Dhruba Das, Nikitasha Bora, Champak Deka, Elone Lucy, Kaushik Poran Bordoloi, Ankita Debnath, Dilip Nama, Chethan GE, Devajani Deka, Parimal Roychoudhury and Kalyan Sarma**

### Abstract

A five-year-old Holstein Friesian crossbred cow was presented to the Teaching Veterinary Clinical Complex, College of Veterinary Sciences and Animal Husbandry, Selesih with a history of haemagalactia for one month. The animal was treated in a local veterinary dispensary but no improvement was noticed. As per owner, there was no abnormality in appetite, urination and defecation. Clinical examination revealed that all the vital parameters were within the normal range. The udder was found to be in normal size and consistency. California mastitis test (CMT) was found to be negative and culture of milk did not yield any bacterial growth. Centrifugation of milk sample revealed the presence of intact red blood cells. Haemato-biochemical parameters were within the normal range and peripheral blood smear was negative for haemoprotozoan and rickettsial diseases. Based on the history, clinical examination and laboratory findings, the condition was diagnosed as haemagalactia. The cow was treated with Inj. Tranexamic acid @ 5 mg/kg BW, IV, SID along with adrenaline (intramammary) and serratiopeptidase (PO) for 5 days. Improvement in condition was noticed on the fourth day and complete recovery was noticed after five days.

**Keywords:** Cow, Haemagalactia, CMT, tranexamic acid, adrenaline

### Introduction

Dairy farmers commonly encounter the presence of “rose milk” issue in cows or buffaloes, two to three days post-calving. Farmers suffer from economic loss as blood mixed milk is unfit for consumption. Bloody milk or haemagalactia in lactating dairy cattle is comparatively common in both heifers and multiparous cows (Radostits *et al.*, 2007; George *et al.*, 2008) [8, 3]. Blood tinge or haemagalactia in milk might be attributed to injury in capillaries of mammary glands. Any other haemorrhage by the movement or passage of blood cells, especially white blood cells, through intact capillary walls into surrounding body tissue, is considered to be pathological and it generally results from damage to the epithelial lining of the teat cistern, owing to harsh milking by hand or machine (Heidrich and Renk, 1967) [4]. Leptospirosis is one of the common causes of blood in milk in dairy animals. In leptospirosis, the milk from all four quarters would be red in colour, thick in consistency and usually contains blood clots and milk clots (Champawat *et al.*, 1984) [2]. Some viruses and red yeast (*Monascus purpureus*) may also responsible to cause intravascular hemolysis and capillary damage in udder leading to reddish or pinkish discoloration of milk (Rana *et al.*, 2009) [1]. Reddish or pinkish discoloration of milk in cattle observed due to thrombocytopenia that may cause leakage of blood into milk (George *et al.*, 2008) [3]. Blood in milk after parturition is common in cows but the successful treatment is reported. The present case report documents haemagalactia in a Holstein Friesian crossbred cow and its successful clinical management.

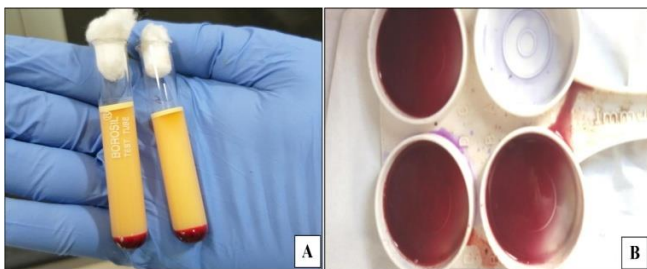
### Case history

A five-year-old Holstein Friesian crossbred cow was presented to Teaching Veterinary Clinical Complex, College of Veterinary Sciences and Animal Husbandry, Central Agricultural University, Selesih, Aizawl, Mizoram with a history of haemagalactia (from three quarters) since one month. The animal was in the third lactation and had calved three months ago. There was no history of any trauma to the udder or teat. The animal was treated with Pendistrin-SH™ (Procaine Penicillin G, streptomycin sulphate, sulphamerazine and hydrocortisone) in a local veterinary dispensary but no improvement was noticed.

### Clinical and laboratory examination

The vital parameters were within the normal range (temperature: 102.1°F; pulse rate: 56 per minute; respiration rate: 20 per minute). On palpation of the udder and teats, no abnormality (heat, pain, firmness, squelching, etc.) could be detected. The colour of the milk was dark pinkish. Milk samples from all the four quarters were collected in a sterile container for laboratory investigation of mastitis. To assess the nature of milk, centrifugation of fresh milk was done at a speed of 2500 rpm for 10 minutes to determine whether the reddish discolouration of milk was due to intact red blood cells (haemorrhage) or due to lysis of red blood cells (haemolysis) as per the method described earlier (George *et al.*, 2008) [3]. Whole blood and serum samples were taken for haematology and serum biochemistry. A peripheral blood smear was prepared to rule out haemoprotozoan and rickettsial diseases.

There was visible sedimentation of a bead of intact red blood cells at the bottom of the centrifugation tube indicating that red colour could be due to haemorrhage (Fig. 1A). Milk samples from all the quarters were found to be negative for mastitis as there was no gel formation in California mastitis test (CMT) (Fig. 1B). Culture of milk did not yield any bacterial growth. Haemato-biochemical parameters were within the normal range (Table 1) and a peripheral blood smear was negative for haemoprotozoan and rickettsial diseases. Based on the history, clinical examination and laboratory findings, the condition was diagnosed as haemagalactia. The absence of any systemic signs ruled out the possibility of any other infection.



**Fig 1:** Laboratory investigation of milk samples A. Sedimentation of a bead of RBCs at the bottom of the Centrifugation tube B. Negative result of CMT

**Table 1:** Haemato-biochemical parameters of animal

Sl. No.	Parameters	Value	Normal range (Kahn <i>et al.</i> , 2010)
1	RBC ( $\times 10^6$ cells/ $\mu$ L)	5.12	5- 10
2	Hb (g/dL)	10.20	8- 15
3	PCV%	31.34	24 – 46
4	MCV (fL)	47.0	40- 80
5	MCH(pg)	16.0	11- 17
6	MCHC (g/dL)	32.0	30- 36
7	WBC ( $\times 10^3$ cells/ $\mu$ L)	10.80	4- 12
8	Granulocytes (%)	29.0	17-67
9	Lymphocytes (%)	65.0	45-75
10	Monocytes (%)	6.0	2-7
11	Platelet count ( $\times 10^3$ cells/ $\mu$ L)	265.0	100- 800
12	AST (U/L)	57.0	43-127
13	Total protein (g/dL)	7.25	6.2- 8.2
14	Calcium (mg/dL)	9.89	8.4-11
15	Phosphorus (mg/dL)	7.12	4.3-7.8

### Treatment

The cow was treated with Inj. Tranexamic acid (Texableed™)

@ 5 mg/kg BW, IV, SID, Inj. Adrenaline (5 mL mixed with 20 mL of normal saline), intramammary, SID and Bol. Serratiopeptidase @ 2 boluses, PO, BID for five days. No tangible improvement in the colour of the milk was noticed until 72 hours after initiation of therapy (Fig. 2A and B). Improvement in condition was noticed on the fourth day (Fig. 2C) and complete recovery was noticed after five days (Fig. 2D).



**Fig 2:** Changes in the colour of the milk in response to treatment A. Before treatment B. 3<sup>rd</sup> day of treatment C. 4<sup>th</sup> day of treatment D. 5<sup>th</sup> day of treatment

### Discussion

There are several causes for haemagalactia condition in cattle. Previous researchers have suggested that local or systemic infections such as mastitis or leptospirosis could be the cause of bloody milk in some herds (Radostits *et al.*, 2007; George *et al.*, 2008) [8, 3]. The affected udders are usually flaccid and affected cows commonly experience other clinical signs such as fever, hemoglobinuria, abortion, and decrease in appetite and milk yield (Radostits *et al.*, 2007; George *et al.*, 2008) [8, 3]. The bloody milk is usually thick with blood and milk clots are present. None of these signs was noticed in the present study. The milk samples from all the quarters were found to be negative for mastitis. Haemagalactia noticed, in this case, might be due to rupture of capillary blood of the mammary gland. Hungerford (1990) [5] also stated that the traumatic rupture of some varicose blood vessel within the lactiferous sinus of the mammary gland is the most frequent cause of reddish discolouration of milk.

In the present study, the cow was treated with parenteral tranexamic acid along with local adrenaline. Different treatment strategies are available for the treatment of haemagalactia which includes parenteral calcium, parenteral and local coagulants, local and parenteral vasoconstrictors, antioxidants, antibiotics, blood transfusion, homeopathic and ethnoveterinary treatment practices (Muhammad and Rashid, 2015) [7]. Tranexamic acid is in a class of medications called antifibrinolytics. It works by blocking the breakdown of blood clots, which prevents bleeding. Parenteral injections of coagulants such as tranexamic acid and adrenochrome are likely to give better cure rates than calcium borogluconate (Radostits *et al.*, 2007; Muhammad and Rashid, 2015) [8, 7]. The circulatory system of the udder is very sensitive to the vasoconstrictor action of adrenaline (Heidrich and Renk, 1967; Muhammad and Rashid, 2015) [4, 7]. Therapeutic efficacy of intramammary adrenaline in the management of haemagalactia has been described earlier (Venkatesan *et al.*, 2017) [9].

### Conclusion

The present case report describes haemagalactia in Holstein Friesian crossbred cow and its successful management with parenteral tranexamic acid and intramammary adrenaline.

**Conflict of Interests:** There is no conflict of interest

**References**

1. Rana N, Phulia SK, Balhara AK. Blood in Milk: Causes and control. *Indian Buffalo Journal*. 2009;7(1):45-46.
2. Champawat SS, Dholakia PM, Jhala VM, Rajput HA. Blood in milk. *Indian Veterinary Journal*. 1984;61:421-423.
3. George LW, Divers TJ, Ducharme N, Welcome FL. Diseases of the teats and udder. In: *Rebhun's Diseases of Dairy Cattle*. 2nd Ed. Divers, T.J., and S.F. Peek (eds.). Saunders-Elsevier Publishers, St. Louis, USA, 2008,335.
4. Heidric HJ, Renk W. Diseases of the Mammary Glands of Domestic Animals. W.B. Saunders, Co. Philadelphia, USA. 1967,99-100.
5. Hungerford TG. *Hungerford's Diseases of Livestock*. McGraw-Hill Book Co., Sydney,1990.
6. Kahn CM, Line S. and Merck & Co. *The Merck veterinary manual*. Whitehouse Station, N.J.: Merck & Co, 2010.
7. Muhammad G, Rashid I. Causes, diagnosis and treatment of blood in milk (hemolactia) in cows and buffaloes. *Scholar's Advances in Animal and Veterinary Research*. 2015;2(1):1-6.
8. Radostits OM, Gay CC, Hinchcliff KW, Constable PD. Diseases of the mammary glands. In: *Veterinary Medicine*. 10th ed, Saunders Elsevier, Philadelphia, Pennsylvania, 2007,673-762.
9. Venkatesan M, Selvaraj P, Sivakumar M, Manickam R, Saravanan M, Veeraselvam M *et al*. Intramammary adrenaline in the management of hemolactia and coliform mastitis in a transition cow. *Journal of Entomology and Zoology Studies*, 2017;5:1882-1883.