



Fetal Congenital Mesoblastic Nephroma: Case Report

Prajakta Aloorkar Patil¹ · Gayatri Vemarapu¹

Received: 6 June 2021 / Accepted: 9 September 2021 / Published online: 16 October 2021
© Society of Fetal Medicine 2021

Abstract Congenital mesoblastic nephroma (CMN) is a rare renal tumor, but the commonest tumor of early infancy. It can be detected prenatally as a renal mass and is associated with prematurity, polyhydramnios, and neonatal hypertension. We report a case of congenital mesoblastic nephroma which presented as a large unilateral solid renal mass detected at 33 weeks of gestation associated with oligohydramnios and small for gestational age (SGA) fetus. Ultrasound features were a large hypoechoic mass arising from the upper pole of the Left kidney measuring 52 × 43 × 32 mm. Inside the mass there were incomplete septae and a few cystic areas, likely hemorrhagic areas, with minimal peripheral vascularity. The mass was surrounded by a hyperechoic capsule. The left adrenal gland could be imaged separately. The baby was delivered by a lower segment cesarean section (LSCS) at 38 weeks of gestation. After birth, the baby presented with a mass per abdomen with no other symptoms and no hypertension. CT scan and ultrasound guided biopsy confirmed the finding of the cellular variant of congenital mesoblastic nephroma. Left radical nephrectomy with adrenal gland conservation was performed on day 8 of life. Postoperative adjuvant chemotherapy was administered. On follow-up, the baby is asymptomatic with no relapse or metastasis. Fetal CMN and Wilms tumor have overlapping ultrasound features and are difficult to differentiate on prenatal ultrasound. Prenatal

detection of fetal renal tumors and timely neonatal management improve perinatal outcome.

Keywords Congenital mesoblastic nephroma (CMN) · Wilms tumor · Ultrasonography · Prenatal detection · Fetal tumors

Abbreviations

CMN	Congenital Mesoblastic Nephroma
MRI	Magnetic Resonance Imaging
CT	Computed Tomography
LSCS	Lower segment caesarean section
USG	Ultrasonography

Introduction

Neonatal renal tumors account for up to 7% of all neonatal tumors [1]. Though fetal renal tumors are rare Congenital Mesoblastic Nephroma (CMN) is the commonest benign renal stromal tumor under the age of 6 months [1, 2]. It is associated with perinatal complications such as polyhydramnios, prematurity, and paraneoplastic syndrome. CMN has a benign clinical course if diagnosed under three months of age and if surgically excised, independent of histological type. Antenatal detection of a fetal mass helps in planning and treatment of CMN. Though it is difficult to differentiate CMN and Wilms tumor on prenatal ultrasound findings due to overlapping feature [4], a high index of suspicion with prenatal ultrasound features may lead to an appropriate diagnosis of CMN. Fetal MRI may resolve the diagnostic dilemma, but histopathology is definitive.

✉ Prajakta Aloorkar Patil
drprajakta1985@gmail.com

Gayatri Vemarapu
drgayatriv@gmail.com

¹ Consultant Fetal Medicine, Rainbow Children Hospital & Birthright By Rainbow, Hydernagar, Hyderabad Telangana 500072 India

We report a case of CMN which was detected at 32–33 weeks of gestation.

Case Report

A 34 yrs old woman, G2P1L1 with a previous lower segment cesarean section with spontaneous conception was referred to our center at 33 weeks with a label of Unilateral MCDK (Multicystic dysplastic kidney). All her previous scans were reported normal. The first trimester combined screening was reported as low risk for common aneuploidies. Her antenatal period was uneventful until 32 weeks.

Ultrasound examination at 33 plus weeks showed small for gestational age (SGA) fetus with the fetal growth at the 9th centile and AFI of 6.6 cms. Fetal Dopplers were normal. There was a solitary, solid, globular mass arising from the upper pole of the left kidney measuring 52 × 43x32 mm, reaching up to the hilum. It was a hypoechoic mass with a hyperechoic capsule with incomplete septae and few cystic cavitory areas likely hemorrhagic areas. Upper pole corticomedullary differentiation was lost. (Figs. 1 and 2). Synchronous movement of the mass was seen along with fetal breathing movement. On colour Doppler examination, a single prominent feeding vessel entering the kidney was seen and very minimal colour flow signals were seen at the periphery of the mass (Figs. 3 and 4).

The left adrenal gland was imaged separately and was mildly displaced by the mass (Fig. 5). The right kidney was normal (Fig. 6). No other extra-renal structural abnormalities were noted on the scan.

After a detailed assessment, the ultrasound-based diagnosis was given as fetal left renal tumor/mass, with a possibility and differential diagnosis of likely CMN and a rare possibility of Wilms tumor.

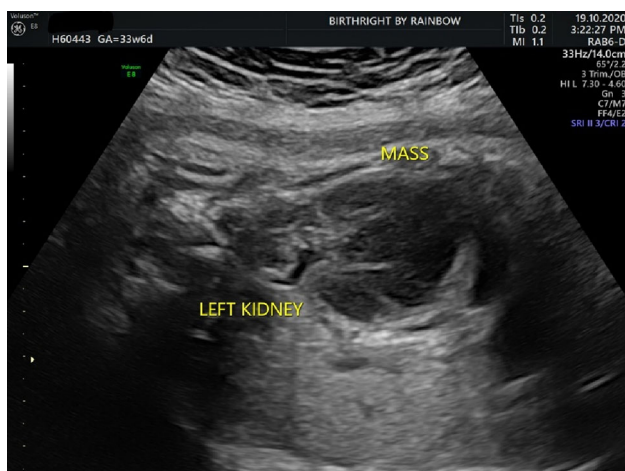


Fig. 1 Ultrasound picture of fetal renal mass

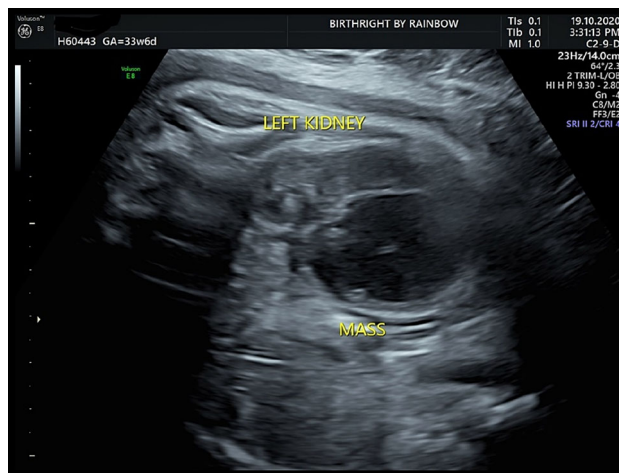

Fig. 2 Ultrasound image of the fetal renal mass

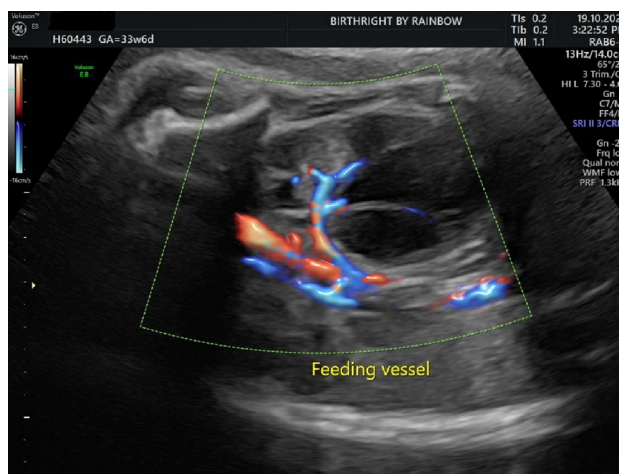


Fig. 3 Colour Doppler interrogation

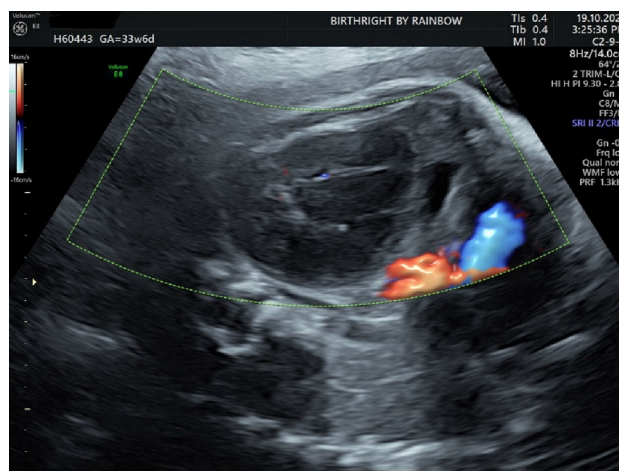


Fig. 4 Colour Doppler interrogation

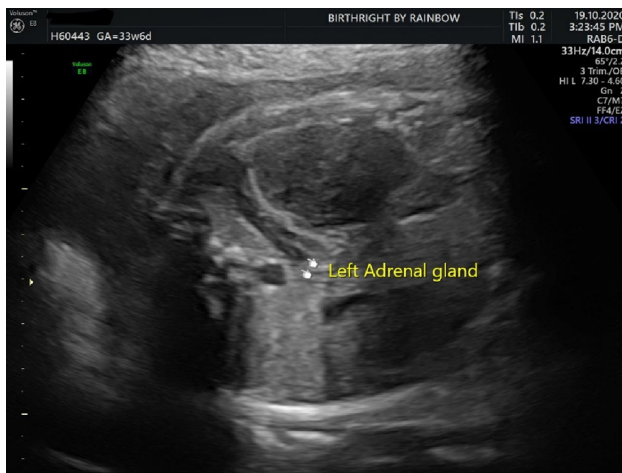


Fig. 5 Image of the left adrenal gland separate from the mass

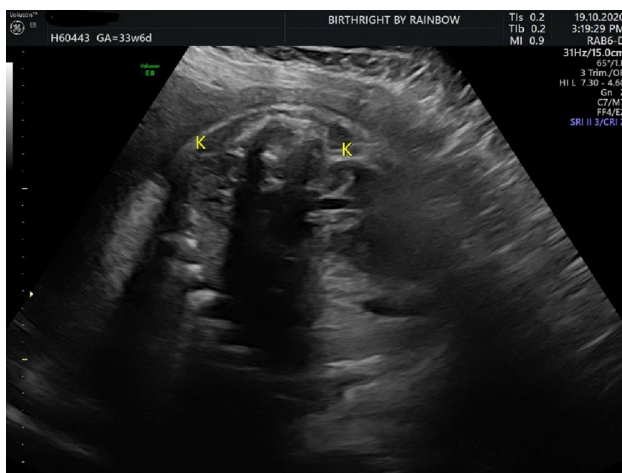


Fig. 6 Image of the Right Kidney

Parents were counseled about fetal MRI to delineate the exact type. The couple opted against MRI and further evaluation. She was monitored with serial ultrasound monitoring because of SGA fetus. The mass size remained the same throughout pregnancy. We had explained that obstetric management will not change because of the renal mass unless there were associated complications. Ultrasound at 36 weeks showed fetus growth on the 5th centile (EFW: 2100 gms), AFI 9 cm and normal Dopplers. The renal mass measured 51 × 42x31 mm and there was no increase in size or change in features.

Perinatal counseling was done by a pediatric surgeon explaining the need for postnatal evaluation and need for surgical management. Repeat cesarean section was performed at 38 + 4 weeks due to previous LSCS with SGA with oligohydramnios. A male baby was delivered with a birth weight of 2.3 kg and Apgar scores were 7 at 1 minute and 9 at 5 minutes.

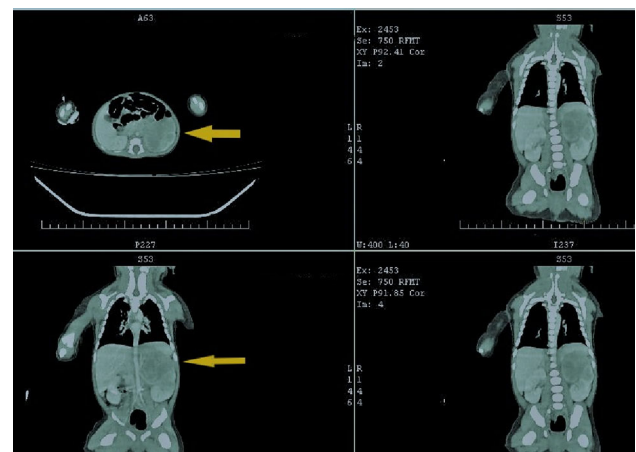


Fig. 7 CECT showed mixed dense mass lesion (more of hypodense) from the left renal upper pole

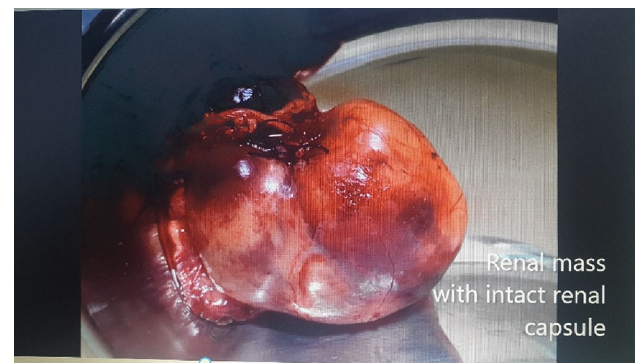
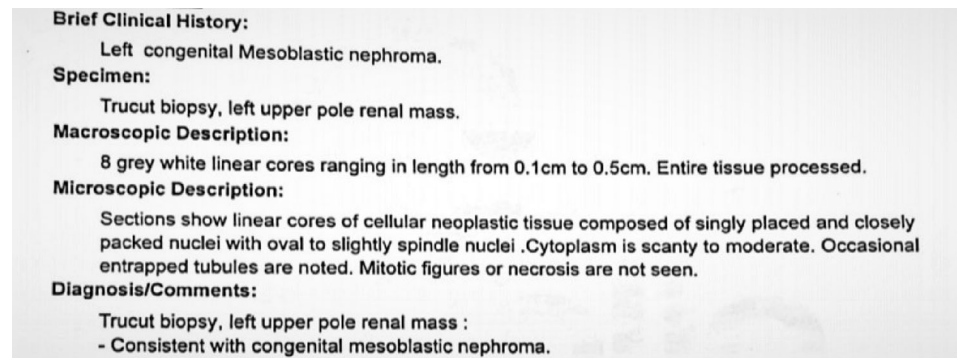


Fig. 8 Gross appearance of the mass

Postnatal ultrasound showed an enlarged left kidney with large solid mass at the upper pole of the kidney measuring 52 × 36x29mm with hypoechoic intraparenchymal cortical focal lesion likely CMN.

A neonatal endocrine panel was sent suspecting adrenal involvement. DHEAS was raised more than 1500 mcg/dl; testosterone, androstenedione, aldosterone,17OHP were in the normal range. On day 6 of life a CECT and US guided trucut biopsy was performed. CECT showed mixed dense mass lesion involving the left renal upper pole extending into the interpolar region, likely mesoblastic nephroma (Fig. 7). Histopathology was suggestive of cellular type congenital mesoblastic nephroma(CMN).

Left radical nephrectomy (surgical excision of the left kidney and perirenal fat) and adrenal gland conservation was performed on day 8 of life. On gross examination, the upper pole of the kidney was irregular due to a bulging globular mass. Tumor dimensions were 45 × 41x33 mms. It was reaching up to the renal hilum. There was no evidence of tumor rupture or renal capsule rupture (Fig. 8). No enlarged lymph nodes were seen around the kidney.

Fig. 9 Histopathology report

Surgical Staging showed it was stage 2 CMN as there was involvement of renal sinus. Histopathology was s/o cellular mesoblastic nephroma (Fig. 9). The baby has been started on prophylactic chemotherapy due to the aggressive nature of cellular type and stage 2. The baby was discharged in good condition. On follow-up, the baby was asymptomatic with no relapse.

Discussion

Though fetal renal tumors are rare, CMN is the most common benign tumor during fetal life and in infants [6]. The majority of CMN can be detected in the third trimester due to a rapid increase in size due to hemorrhages [7]. As per the few reported cases, CMN is more likely to occur in males and the right kidney [8].

The most common presentation of CMN is a unilateral homogeneous solid mass with hyperechoic echogenicity within the mass and involvement of the renal sinus and preserved contour of the involved kidney. The tumor lacks a well-defined capsule and moves with the renal parenchyma when fetal breathing movements are present. Occasionally CMN appears as a hypoechoic tumor with a concentric echogenic rim (Ring sign). Spectral Doppler demonstrates arterio-venous waveforms [6]. The atypical mesoblastic nephroma and cellular type show a more heterogeneous complex pattern due to necrosis, hemorrhage and cyst formation.

The differential diagnosis of a fetal abdominal solid tumor includes CMN, Wilms tumor, renal Rhabdoid tumor, compensatory hypertrophy with the absence of the contralateral kidney, crossed-fused ectopia, congenital adrenal neuroblastoma, adrenal hemorrhage, retroperitoneal teratoma and extra lobar pulmonary sequestration. Rarely, a multicystic dysplastic kidney (MCDK), severe hydronephrosis may mimic CMN.

In this case only after exclusion of other mass lesion differential diagnosis remained was Wilms tumor because:

1. Mass was arising from kidney and synchronous movement of mass was seen along with fetal breathing,
2. The adrenal gland was imaged separately, excluding the adrenal as a site of origin and the possibility of suprarenal neuroblastoma was ruled out,
3. The contralateral kidney was normal, with no evidence of fused renal ectopia,
4. No features were suggestive of severe hydronephrosis and Multicystic dysplastic kidney was ruled out,
5. Renal Rhabdoid tumor is rare in fetal life and the mean age of presentation is 12 months [16]. It has irregular margins, with significant vascularity. Rapid tumor growth is the main characteristic.

It is difficult to differentiate CMN from Wilms tumor as it shares phenotypic features. CMN is more common than Wilms tumor in the fetus and neonate. CMN present before one year of age with a mean age of 6 months [8]. In contrast, the mean age of presentation of Wilms Tumor is 3.5 years. As a part of a syndrome, Wilms tumor occurs even earlier, between 2 and 24 months of age [2].

Wilms tumor presents as an encapsulated solid heterogeneous tumor invading the normal renal parenchyma. It can be unilateral or bilateral. Areas of hemorrhage and necrosis may be detected within the mass, quite a similar feature of cellular CMN. Few studies have mentioned that solid renal masses which were considered as Wilms' tumors were diagnosed as CMN in the postnatal period [8].

Considering the rare presentation of Wilms in fetal life, a solid renal mass should be considered as CMN.

Fetal magnetic resonance imaging (MRI) is helpful in the diagnostic dilemma of fetal renal masses [15]. Prenatal ultrasonography combined with MRI identifies the site of origin and distinguishes the tumor from adjacent structures, providing valuable information for postnatal surgery. [5, 9, 14, 15]. On Fetal MRI, CMN is well defined, homogeneously solid, iso to hypointense to normal renal parenchyma and may show hyperintense foci related to hemorrhage. In the cellular subtype DWI shows restricted diffusion in the solid portion of the tumor, due to increase

cellularity [5]. In our case the couple did not opt for fetal MRI and further evaluation.

CMN is commonly associated with polyhydramnios, hydrops, fetal distress and prematurity. The reason for polyhydramnios is not clear but it may occur due to arteriovenous shunting, mass effect on the stomach, small bowel, particularly in left-sided masses and increased renal perfusion. In our case, it was associated with oligohydramnios.

Rarely, these tumors may be large, leading to abdominal dystocia, necessitating a cesarean section. In the neonatal period, CMN may present only as an asymptomatic abdominal mass. Sometimes it may be present with a paraneoplastic syndrome such as hypercalcemia and hypertension. Hypertension can occur in neonatal life due to increased renin levels as a result of trapped glomeruli in the tumor [8]. Additional congenital anomalies are rare but a few cases of associated gastrointestinal malformations, limb abnormalities and association with Beckwith-Weidman syndrome have also been reported [12].

CMN has three histological types classical, cellular, and mixed type. The classical type presents before 3 months of age but the cellular type usually presents after 3 months of age [3]. Cellular type is potentially malignant and capable of recurrence and metastasis [10]. Recurrence and metastasis are exclusively seen in babies older than three months of age.

CMN has a benign course, and radical nephrectomy is curative in the majority of cases. Additional chemotherapy should be started for those cases in which surgical margins are involved histologically [4, 7]. Both classic and cellular tumors have an excellent prognosis in babies presenting before 3 months [11]. In a few cases, there is local recurrence or distant metastases in the first year of life. The overall survival rate in CMN cases is 95% [7]. The cellular variant has an overall survival rate of 90% [7, 13].

Prenatal detection provides the opportunity for optimal management of antenatal complications like polyhydramnios, preterm labor and optimization of delivery planning in cases with suspected dystocia. Prenatal detection is also important in parental counseling and makes them prepared for postnatal management.

In our case, the baby was asymptomatic. Calcium levels were normal. Blood pressure was around 30th percentile. After left radical nephrectomy and chemotherapy, the baby was asymptomatic, and on follow-up, there is no evidence of relapse or metastasis.

Antenatal detection, followed by radical nephrectomy before 3 months of age with the initiation of chemotherapy improved the prognosis in this case.

Uncommon Features in the Present Case

- Cellular type CMN presents usually after 3 months of age but in this case, it was detected in the prenatal period,
- CMN during pregnancy is associated with polyhydramnios but in this case amniotic fluid was low,
- As per literature, CMN is a highly vascular tumor but vascularity was very minimal in the present case.

Overlapping Features of CMN and Wilms tumor

- Both tumors present as a solid mass,
- Classic CMN is a hypoechoic homogeneous mass; Cellular CMN is a more heterogeneous and large size in appearance due to intra-tumor hemorrhage,
- Wilms Tumor can present as a heterogeneous mass with multiple cystic areas due to hemorrhage.

Conclusion

Though Wilms tumor and CMN are difficult to differentiate on prenatal ultrasound, a high index of suspicion on ultrasound complemented with MRI findings helps us in reaching a diagnosis.

A solid vascular renal mass detected in the third trimester should be considered as a Congenital Mesoblastic Nephroma because Wilms tumor is rare during fetal life.

Accurate prenatal diagnosis or suspicion may improve the outcome of affected pregnancies by appropriately planned strategy and timely management with a multidisciplinary approach.

Acknowledgements Dr.Lavanya Kannaiyan (Paediatric Surgeon), Dr.Vamsi Kiran Rayadu(Consultant paediatrician & Neonatologist.), Dr.Kalyan Chakravarthy(Consultant paediatrician & Neonatologist)

Declarations

Conflicts of interests The authors declare there are no conflicts of interests.

References

1. Powis M. Neonatal renal tumours. *Early Hum Dev.* 2010;86:607–12.
2. Jeong Yeon Cho et al. Fetal tumours: prenatal ultra-sonographic finding and clinical characteristics. 2014. 33(4): 240–251.
3. Prasanta Kumar Tripathy, Susmita Behera, Hiranya K. Mohanty. Cellular Congenital Mesoblastic Nephroma in a Newborn. *Journal of Neonatal Surgery* 2017; 6:45

4. Celik H, Kefeli M, Tosun M, Cetinkaya MB, Alper T, Yildiz L. Congenital mesoblastic nephroma: prenatal diagnosis by sonography. *J Diagnostic Medical Sonography*. 2009;25(2):112–5.
5. Ko SM, Kim MJ, Im YJ, et al. Cellular mesoblastic nephroma with liver metastasis in a neonate: prenatal and postnatal diffusion-weighted MR imaging. *Korean J Radiol*. 2013;14:361–5.
6. Deborah Levine, MD et al. Fetal abdomen: Differential diagnosis of abnormal echogenicity and calcification-UpToDate
7. Young Do A, Jung-Sun Kim, Suk-Joo Choi. Prenatal diagnosis of congenital mesoblastic nephroma. *Obstet Gynecol Sci* 2015;58:405–8.
8. Wang ZP, Li K, Dong KR, et al. Congenital mesoblastic nephroma: clinical analysis of eight cases and a review of the literature. *Oncol Lett*. 2014;8:2007–11.
9. Chen WY, Lin CN, Chao CS, et al. Prenatal diagnosis of congenital mesoblastic nephroma in mid-second trimester by sonography and magnetic resonance imaging. *Prenat Diagn* 2003; 23:927. Pubmed
10. Broecker B: Non-Wilms' renal tumours in children. *Urol Clin North Am* 2000; 27:463–469. Pubmed
11. Bisceglia M, Carosi I, Vairo M, Zaffarano L, Bisceglia M, Creti G: Congenital mesoblastic nephroma: report of a case with review of the most significant literature. *Pathol Res Pract* 2000; 196:199–204. Pubmed
12. Gooskens SL, Houwing ME, Vujanic GM, et al. Congenital mesoblastic nephroma 50 years after its recognition: A narrative review. *Pediatr Blood Cancer* 2017. Pubmed
13. Shapiro E. Upper urinary tract anomalies and perinatal renal tumors. *Clin Perinatol*. 2014;41:679–94.
14. Che M, Yang F, Huang H, Zhang H, Han C, Sun N. Prenatal diagnosis of fetal congenital mesoblastic nephroma by ultrasonography combined with MR imaging: A case report and literature review. *Medicine*. 2021;100:3.
15. Irsutti M, Puget C, Baunin C, Duga I, Sarramon MF, Guitard J. Mesoblastic nephroma: prenatal ultrasonographic and MRI features. *Pediatr Radiol*. 2000;30:147–50.
16. Fuchs IB, Henrich W, Kalache KD, Lippek F, Dudenhausen JW. Prenatal sonographic features of a rhabdoid tumor of the kidney. *Ultrasound Obstet Gynecol*. 2004;23(4):407–10.

Publisher's Note Springer Nature remains neutral with regard to jurisdictional claims in published maps and institutional affiliations.