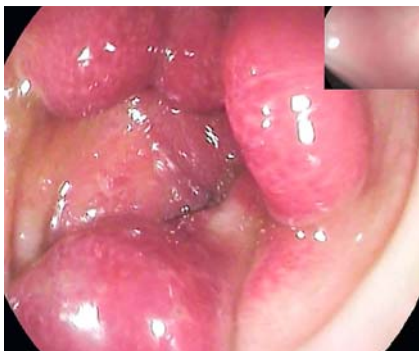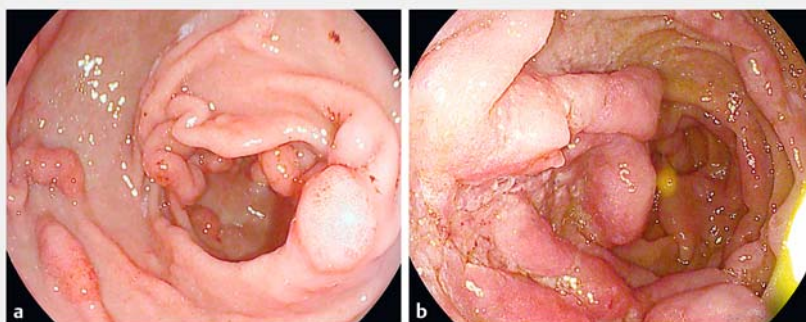


## Major duodenal papilla prolapse in Cronkhite–Canada syndrome



► **Fig. 1** Cronkhite–Canada colonic polyposis in a 59-year-old Japanese woman with recurrent proctorrhagia and recently presenting alopecia, dysgeusia, and onychodystrophy.



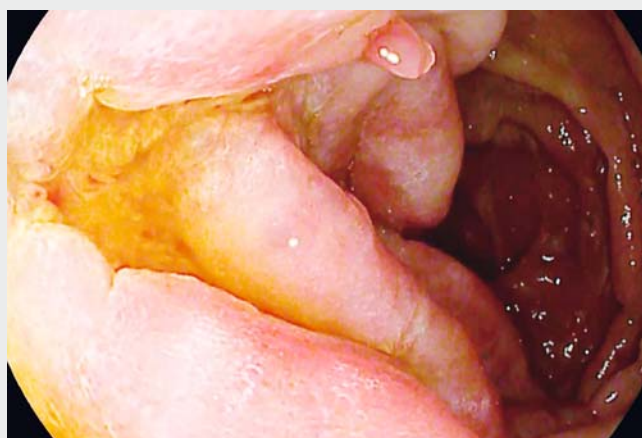► **Fig. 2** Cronkhite–Canada endoscopic appearances: **a** Hyperplastic plicae and polyposis of the stomach; **b** duodenal polyposis.

We describe the case of a 59-year-old Japanese woman presenting with recurrent proctorrhagia. Her clinical history was unremarkable except for recently presenting alopecia, dysgeusia, and onychodystrophy.

Ileocolonoscopy showed multiple strawberry-like sessile polyps ranging from 5 to 20 mm in size in the rectosigmoid (► **Fig. 1**).

Upper endoscopy demonstrated hypertrophic gastric plicae and many sessile polyps of 5–15 mm in size spreading from the stomach to the distal duodenum (► **Fig. 2 a, b**). i-SCAN digital contrast (I-SCAN) and optical enhancement virtual chromoendoscopy (Optivista EPK-i7010 video processor; Pentax, Tokyo, Japan) were activated to increase the detection of subtle mucosal changes, revealing several erosion-like mucosal defects within the surface of the polyps (► **Video 1**). During withdrawal, the dynamics of a major duodenal papillary prolapse were clearly observed within the context of a large, laterally spreading, superficial, and elevated polypoid projection (► **Video 1**).

Targeted biopsy samples showed histological features consistent with a diagnosis of Cronkhite–Canada syndrome (► **Fig. 3 a, b**). A capsule endoscopy ex-

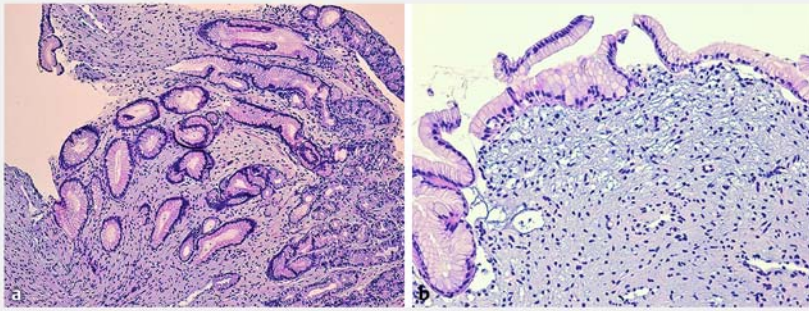


► **Video 1** Cronkhite–Canada syndrome. Enteroscopy conducted to the proximal jejunum, using high definition and optical enhancement virtual chromoendoscopy. A prolapsing major papilla is seen in duodenal polyposis.

cluded additional polyp locations and systemic steroid treatment was introduced to reduce both polyp formation and bleeding.

Cronkhite–Canada syndrome is an extremely rare nonhereditary gastrointestinal polyposis, with 450 cases reported in the literature, mainly in the Japanese population [1]. The syndrome usually presents with a triad of dermatologic disorders, including alopecia, onychodystrophy, and hyperpigmentation, associated

with a variable degree of gastrointestinal symptoms including diarrhea, malabsorption, and hemorrhage [2]. Cronkhite–Canada polyps are usually sessile, with abundant stromal edema, hyperplastic glands, and cystic mucous retention, plus mild inflammation with predominant eosinophilic infiltrate within the surrounding mucosa [3]. The prognosis for Cronkhite–Canada syndrome is often unfavorable, because of complications (malabsorption, gastrointestinal



► **Fig. 3** Histological appearances in Cronkhite–Canada syndrome: **a** gastric mucosa with hyperplastic glands without atypia (hematoxylin and eosin [H&E], ×100); **b** myxoid-edematous stroma with very scanty inflammatory infiltrates (H&E, ×400).

syndrome: a Japanese nationwide survey. *J Gastroenterol* 2016; 51: 327–336

- [3] Zhao R, Huang M, Banafea O et al. Cronkhite-Canada syndrome: a rare case report and literature review. *BMC Gastroenterology* 2016; 16: 23
- [4] Yun SH, Cho JW, Kim JW et al. Cronkhite-Canada syndrome associated with serrated adenoma and malignant polyp: a case report and a literature review of 13 Cronkhite-Canada syndrome cases in Korea *Clin Endosc* 2013; 46: 301–305
- [5] Tontini GE, Rimondi A, Neumann H et al. Usefulness of virtual chromoendoscopy with optical enhancement in everyday clinical practice. *Adv Res Gastroenterol Hepatol* 2017. doi:10.19080/ARGH.2017.07.555719

hemorrhage, or intussusception) and the lack of standardized treatments [4]. The malignant transformation of polyps is still a matter of debate and no validated protocols for endoscopic surveillance are available [5].

Endoscopy\_UCTN\_Code\_TTT\_1AO\_2AC

### Competing interests

None

### The authors

**Beatrice Marinoni<sup>1</sup>, Gian E. Tontini<sup>1</sup>, Luca Elli<sup>1</sup>, Barbara Bruni<sup>2</sup>, Marco Maggioni<sup>3</sup>, Luca Pastorelli<sup>4,5</sup>, Maurizio Vecchi<sup>1,6</sup>**

- 1 Gastroenterology and Endoscopy Unit, Fondazione IRCCS Ca' Granda Ospedale Maggiore Policlinico, Milan, Italy
- 2 Pathology and Cytodiagnostic Unit, IRCCS Policlinico San Donato, San Donato Milanese, Italy
- 3 Pathology Unit, Fondazione IRCCS Ca' Granda Ospedale Maggiore Policlinico, Milan, Italy

- 4 Gastroenterology and Digestive Endoscopy Unit, IRCCS Policlinico San Donato, San Donato Milanese, Italy
- 5 Department of Biomedical Sciences for Health, University of Milan, Milan, Italy
- 6 Department of Pathophysiology and Transplantation, University of Milan, Milan, Italy

### Corresponding author

**B. Marinoni, MD**

Ospedale Maggiore Policlinico, Gastroenterology and Endoscopy Unit, Via commenda 12 milano, Milano Lombardia 20122, Italy  
Fax: +39-2-55033414  
bea\_marinoni@hotmail.it

### References

- [1] Cronkhite LW Jr, Canada WJ. Generalized gastrointestinal polyposis; an unusual syndrome of polyposis, pigmentation, alopecia and onychotrophy. *N Engl J Med* 1955; 252: 1011–1015
- [2] Watanabe C, Komoto S, Tomita K et al. Endoscopic and clinical evaluation of treatment and prognosis of Cronkhite-Canada

### Bibliography

DOI <https://doi.org/10.1055/a-0800-8148>

Published online: 7.2.2019

*Endoscopy* 2019; 51: E81–E82

© Georg Thieme Verlag KG

Stuttgart · New York

ISSN 0013-726X

### ENDOSCOPY E-VIDEOS

<https://eref.thieme.de/e-videos>



*Endoscopy E-Videos* is a free access online section, reporting on interesting cases and new techniques in gastroenterological endoscopy. All papers include a high quality video and all contributions are freely accessible online.

This section has its own submission website at

<https://mc.manuscriptcentral.com/e-videos>