

Esophageal involvement by pemphigus vulgaris resulting in dysphagia

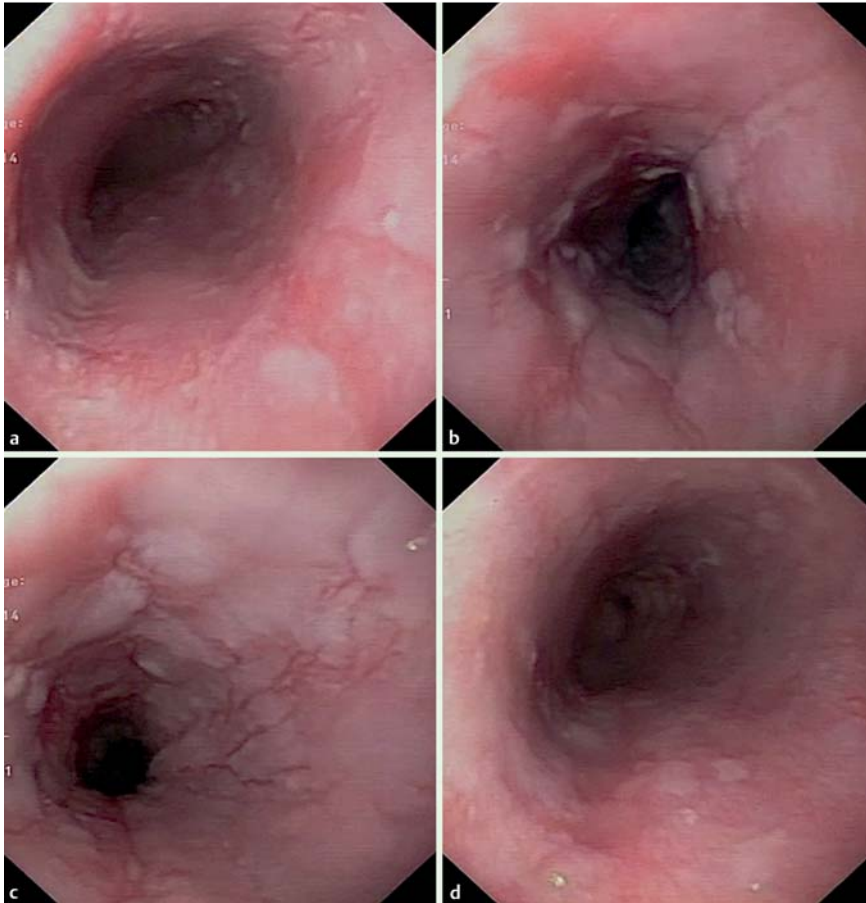


Fig. 1 In a 44-year-old patient with dysphagia because of pemphigus vulgaris that involved the esophagus, endoscopic esophageal views show mucosal exfoliation and confluent linear erosions that become less severe distally: **a, b** upper esophagus; **c** mid esophagus; **d** lower esophagus.

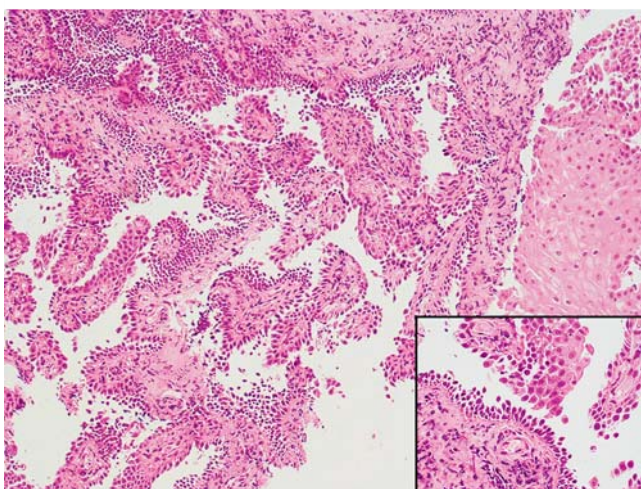


Fig. 2 Histologic examination of the esophageal specimen reveals suprabasal clefting, cells with a tombstone appearance, and prominent acantholysis.

A 44-year-old man was admitted to our institution because of the appearance of painful cutaneous, oral, and genital vesicles. His previous medical history was unremarkable. He had had pharyngitis treated with amoxicillin 1 month before the hospitalization. On physical examination, symmetrically erythematous plaques, covered with vesicles, were seen. Because of subsequent dysphagia for solid food, he underwent esophagogastroduodenoscopy.

The endoscopic examination revealed esophageal mucosal exfoliation with multiple linear and confluent furrows in the upper and middle esophagus (Fig. 1) that were less severe in the lower esophagus. The gastric and duodenal mucosa was preserved, without mucosal breakage. Biopsy specimens were taken from lesions in the upper and middle esophagus, with stripping of the mucosa on withdrawal of the biopsy forceps (Video 1). The histologic examination showed suprabasal clefting, cells with a tombstone appearance, and prominent acantholysis, suggestive of pemphigus vulgaris (Fig. 2). At the same time, a skin lesion biopsy was performed, which confirmed the diagnosis (Fig. 3).

Systemic corticosteroid treatment was started but was unsuccessful; during subsequent immunotherapy and the intravenous administration of monoclonal antibodies, the symptoms and signs decreased.

Pemphigus vulgaris is a rare autoimmune disease in which bullae of the skin and oral mucosa form as a result of acantholysis mediated by circulating immunoglobulin G autoantibodies against intercellular antigens of stratified epithelia. Pemphigus vulgaris can involve other mucosal surfaces that have squamous epithelium, such as those of the esophagus, nasopharynx, conjunctivae, cervix, and anus [1]. The prevalence of esophageal involvement in autoimmune bullous skin disease is 67.8% [2], but esophageal involvement may be underrecognized or misdiagnosed without a proper endoscopic evaluation

Video 1

Biopsy specimens are taken from lesions in the upper and middle esophagus, with stripping of the mucosa on withdrawal of the biopsy forceps.

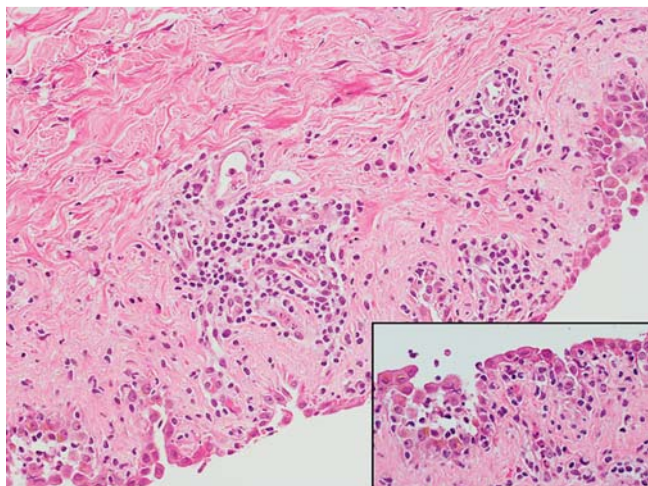


Fig. 3 Histologic examination of the skin specimen shows marked acantholysis and a linear palisade of intact basal keratinocytes, the so-called tombstone appearance; examination with immunofluorescent techniques reveals immunoglobulin G and complement C3 at the level of the basal keratinocytes.

[3]. Commonly, it is characterized by vesicles, superficial erosions, red and erythematous longitudinal lines, a circumferential crack with peeling, and a whitish mucosa with extensive bleeding along the entire organ. Pemphigus vulgaris may also be induced by drugs, including d-penicillamine and angiotensin-converting enzyme inhibitors [4,5]. Corticosteroids and immunosuppressive agents are considered the first-line treatment. If untreated, pemphigus vulgaris can be fatal.

Endoscopy_UCTN_Code_CCL_1AB_2AC_3AH

Competing interests: None

Paolo Cecinato¹, Liboria Laterza², Loredana De Marco³, Annamaria Casali⁴, Magda Zanelli³, Romano Sassatelli¹

¹ Unit of Gastroenterology and Digestive Endoscopy, Arcispedale Santa Maria Nuova-IRCCS, Reggio Emilia, Italy

² Unit of Digestive Endoscopy, Ospedale Cesare Magati, Reggio Emilia, Italy

³ Unit of Pathology, Arcispedale Santa Maria Nuova-IRCCS, Reggio Emilia, Italy

⁴ Center of Hemostasis and Thrombosis, Arcispedale Santa Maria Nuova-IRCCS, Reggio Emilia, Italy

References

- 1 Bystryn JC, Rudolph JL. Pemphigus. *Lancet* 2005; 366: 61–73
- 2 Galloro G, Mignogna M, de Werra C et al. The role of upper endoscopy in identifying oesophageal involvement in patients with oral pemphigus vulgaris. *Dig Liv Dis* 2005; 37: 195–199
- 3 Hokama A, Yamamoto Y, Taira K et al. Esophagitis dissecans superficialis and autoimmune bullous dermatoses: a review. *World J Gastrointest Endosc* 2010; 2: 252–256
- 4 Duhra P, Foulds I. Penicillin-induced pemphigus vulgaris. *Br J Dermatol* 1988; 118: 307
- 5 Ruocco V, Satriano R, Guerrero V. “Two step” pemphigus induction by ACE-inhibitors. *Int J Dermatol* 1992; 31: 33–36

Bibliography

DOI <http://dx.doi.org/10.1055/s-0034-1391905>
Endoscopy 2015; 47: E271–E272
 © Georg Thieme Verlag KG
 Stuttgart · New York
 ISSN 0013-726X

Corresponding author

Paolo Cecinato, MD

Unit of Gastroenterology and Digestive Endoscopy
 Arcispedale Santa Maria Nuova-IRCCS
 Reggio Emilia 42123
 Italy
 Fax: +39-0522-295941
 paolocecinato@libero.it