

# Anatomy of the superficial venous system of the leg

E. Brenner

Division of Clinical and Functional Anatomy, Medical University of Innsbruck, Austria

## Keywords

Great saphenous vein, small saphenous vein, accessory saphenous veins, superficial circumflex iliac vein, superficial epigastric vein, external pudendal vein, perforating veins

## Summary

The superficial venous system of the leg starts with the epifascial veins, i.e. the various subcutaneous venous networks, the accessory saphenous veins, superficial epigastric vein, the superficial iliac circumflex vein, and the external pudendal veins. These flow into the two intrafascial veins, the great and the small saphenous veins. These, in turn, enter the deep venous system, the great saphenous vein constantly in the saphenous hiatus, the small saphenous vein in just over two thirds of cases in the popliteal fossa. In addition, numerous connections exist between the superficial and the deep venous system by the perforating veins. The superficial veins communicate with each other by communicating veins. Within the superficial veins numerous parietal valves exist, mostly with two, in smaller and smallest veins also with only one valve leaflet. At the entrance of the great saphenous vein into the femoral vein, there may also be an ostial valve. The wall of the superficial veins has the typical three-layered structure with a tunica intima, a tunica media and a tunica externa. The tunica intima comprises, at least in the great saphenous vein, an internal elastic membrane. In the tunica media, longitudinally arranged bundles of smooth

musculature are found inside, followed by dense bundles of circularly arranged smooth musculature. In the tunica externa longitudinal muscle fiber bundles can also be found. Both the great and the small saphenous vein lie in their own fascial sheath, the floor of which is formed by the crural fascia or the fascia lata and their superficial leaf by the respective saphenous fascia. Within these „saphenous compartments“ the respective veins are laterally anchored by saphenous ligaments. About 60 large-volume, clinically significant perforating veins connect the superficial with the deep venous system. At least one flap in each perforating vein prevents backflow from the deep venous system.

## Schlüsselwörter

V. saphena magna, V. saphena parva, Vv. saphenae accessoriae, V. circumflexa ilium superficialis, V. epigastrica superficialis, V. pudenda externa, Vv. perforantes

## Zusammenfassung

Das oberflächliche Venensystem des Beines beginnt mit den epifaszialen Venen, das sind die diversen Venennetze der Subkutis, die Vv. saphenae accessoriae, die V. epigastrica superficialis, die V. circumflexa ilium superficialis und die Vv. pudendae externae. Diese münden in die beiden intrafaszialen Venen, die V. saphena magna und die V. saphena parva ein. Diese wiederum münden in das tiefe Ve-

nensystem ein, die V. saphena magna konstant im Hiatus saphenus, die V. saphena parva in etwas mehr als zwei Dritteln der Fälle in der Fossa poplitea. Zudem bestehen zahlreiche Verbindungen zwischen oberflächlichem und tiefem Venensystem über die Vv. perforantes. Die oberflächlichen Venen stehen untereinander über Vv. communicantes in Verbindung. In den oberflächlichen Venen finden sich zahlreiche parietale Klappen, zumeist mit zwei, in kleineren und kleinsten Venen auch mit nur einem Klappensegel. An der Mündung der V. saphena magna kann sich zudem eine ostiale Klappe, Astklappe, befinden. Die Wand der oberflächlichen Venen besitzt den typischen dreischichtigen Aufbau mit einer Tunica intima, einer Tunica media und einer Tunica externa. Die Tunica intima besitzt, zumindest in der V. saphena magna nachgewiesen, eine Membrana elastica interna. In der Tunica media finden sich innen longitudinal angeordnete Bündel glatter Muskulatur, nach außen gefolgt von dichten Bündeln zirkulär angeordneter glatter Muskulatur. In der Tunica externa können ebenfalls noch längsgerichtete Muskelfaserbündel zu finden sein. Sowohl die V. saphena magna als auch die V. saphena parva liegen in einer eigenen Faszienhülle, deren Boden von der Fascia cruris bzw. der Fascia lata und deren oberflächliches Blatt von der jeweiligen Fascia saphena gebildet wird. Innerhalb dieser „Saphenous Compartments“ werden die jeweiligen Venen durch Ligamenta saphena seitlich verankert. Etwa 60 großvolumige, klinisch bedeutende Vv. perforantes verbinden das oberflächliche mit dem tiefen Venensystem. Zumindest eine Klappe in einer V. perforans verhindert dabei einen Rückstrom aus dem tiefen Venensystem.

## Correspondence to:

Ao.Univ.Prof. Dr.med.univ. Erich Brenner, MME(Bern)  
Sektion für klinisch-funktionelle Anatomie, Medizinische Universität Innsbruck  
Müllerstrasse 59, 6020 Innsbruck, Österreich  
Tel: +43-512-9003-71121,  
E-Mail: Erich.Brenner@i-med.ac.at

## Anatomie des oberflächlichen Venensystems des Beines

Phlebologie 2018; 47: 352–362  
<https://doi.org/10.1055/s-0038-1675460>

Received: 03. September 2018

Accepted: 26. September 2018

## Introduction

The superficial venous system is basically different from the deep venous system. Superficial veins run independently of the arteries. They can be divided into two groups: the epifascial veins and the intrafascial veins.

- The epifascial veins lie within the subcutaneous tissue and flow into the intrafascial veins, i.e. they are usually tributaries to the intrafascial veins.
- The intrafascial veins lie on the superficial fascia and are partially separated from the rest of the subcutaneous connective tissue by their own distinct fascia.

The superficial venous system includes all the veins that lie above the fascia that covers the entire body – the ‘superficial fascia’ running beneath the skin. These veins differ from the deep veins in several ways:

- Superficial veins basically run independently of the arteries; they therefore lack any arterio-venous coupling that acts as a mechanism to propel blood flow along the veins.
- Superficial veins lie more or less directly on the superficial fascia, i.e. in the deep or deepest layers of the subcutaneous tissue. Some of these veins, in particular the great and small saphenous veins, have their own distinct fascia separating them from the rest of the subcutaneous tissue, and are known as intrafascial veins.
- Superficial veins connect to the deep veins at their inherent junctions but also to varying extents through the anastomoses formed by perforating veins. The superficial veins also form interconnecting networks through communicating veins.

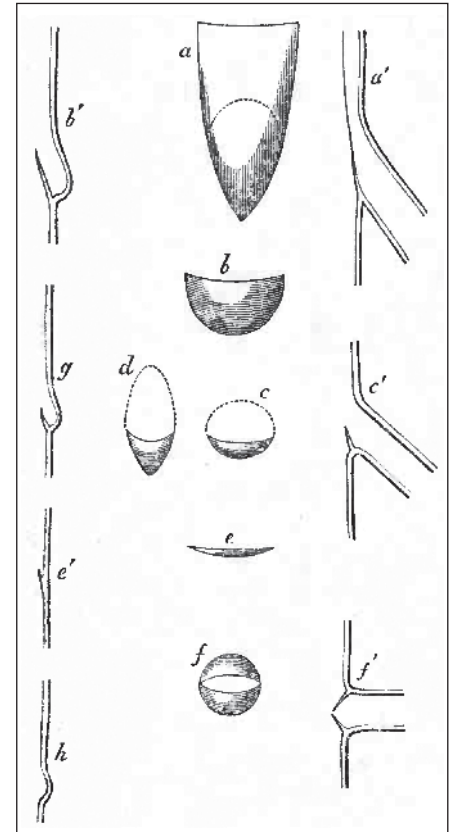
## Venous valves

The direction of blood flow in the superficial veins is determined by the venous valves. These valves are specialised structures formed from the intima (28). Two types of valve can be distinguished: ostial valves, also called branch valves, and parietal valves (22).

Ostial valves lie at the confluence of two veins, anchored in the wall of the larger vein immediately below the orifice of the lesser vein where it enters the trunk (22, 41). They consist of one or two valve cusps or leaflets (41); in the case of only a single valve leaflet, the free border is typically directed towards the heart, while the distal edge attached to the vein wall surrounds the opening of the smaller vein. Ostial valves are found mainly in the deep venous system (coronary sinus (35), great cardiac vein (35), mesenteric veins (13), renal veins (15), gonadal veins (50), vertebral veins (40), inferior thyroid vein (40), superior phrenic vein (40), posterior intercostal veins (31), hepatic veins (31), azygos vein (44), and the deep veins of the leg (34)); however, ostial valves are also an – albeit inconsistent – finding at the saphenofemoral junction (49). Ostial valves do not have an agger (thickened area at the base of the valve) (22).

The parietal valves within the lumen of the vein have to be distinguished from the ostial valves. Franklin KJ (22) cited Sappey PC (42), saying “A valve which is not inserted into the circumference of the actual entry is not an ostial, but a parietal valve, no matter how near it is to the entry”. Parietal valves are classic pocket valves and usually have two valve cusps, single-leaflet parietal valves are rare and are found only in small veins and venules (3; 17). It is of particular note that the number of valves in these very small vessels is highest in regions overlying bones and tendons, that is to say, in areas where venous ulcers are most likely to occur (3) (► Fig. 1).

As a rule, the cusps of these parietal valves are about twice as long as the diameter of the vein in which they are situated (22). On their luminal aspect, they contain an internal elastic membrane (51). They consist of thin, half-moon-shaped folds of intima, extending from the vein wall into the lumen. Neither nerves nor blood vessels are present in the cusps (9; 14). The thickened tissue where the valve cusps attach to the vein wall is known as the agger or limbus; the area where the two leaflets abut at their insertion into the vein wall is the commissure. The agger is roughly horseshoe-shaped with the convex side lying distally.



**Fig. 1** Ostial and parietal valves: a, valve placed at the orifice of the renal vein in the sheep; seen in face [luminal view]; a', the same in ideal section; b, the ordinary semilunar [parietal] valve from the tube of a vein; b', the same in section; c, imperfect [ostial] valve at orifice of intercostal vein; c', section of imperfect [ostial] valve at orifice of hepatic vein; d, the same in face (the dotted lines in a, c and d correspond to the orifices of the respective veins); e, very imperfect [parietal] valve; e', the same in section; f, plan of double valve at orifice of vein; f', the same in section; g, ideal section of small valve and sinus; h, section of a sinus without a valve. Source: Salter SJH (41).

In cross-section, the agger is a triangular fibromuscular structure, whose base is located within the circular muscle of the vein wall and whose tip forms the base of the valve cusp (19). It contains smooth muscle in a specific arrangement, following the agger's line of anchorage to the vein wall.

Taken in the normal direction of flow, the parietal valve that lies between the orifice of the most proximal tributary vein and the opening of the vein itself into the next venous trunk is called the terminal valve (15; 24; 34). In addition, there is usually a preterminal valve. This valve lies

distally, i.e. before the opening of the important tributaries into the respective saphenous vein, looking in the direction of flow.

## Wall structure

Although all the veins in the human body have basically the same function, namely to store and return blood to the heart, the structure of the vein wall varies considerably between various sections of the body. In general, the vein wall possesses a tunica intima (interna), a tunica media, and a tunica adventitia (externa). The tunica intima consists of at least a continuous endothelium and subendothelial connective tissue. The intima is also responsible for the formation of venous valves (see above). There is no blanket description of the further structures, divided into the layers previously mentioned, which fits all the venous vessels. While arteries by definition have smooth muscle in the tunica media, veins may have smooth muscle in all three layers (e.g. the iliac and femoral veins), may contain very few muscle fibres, or even none at all (e.g. veins in the brain and meninges) (4) (► Fig. 2).

Two factors are decisive in the morphology of the vein wall: first, the level of the hydrostatic pressure of the column of blood pressing on the vein wall and secondly, the mechanical demands made on the vein wall by the surrounding tissue (32).

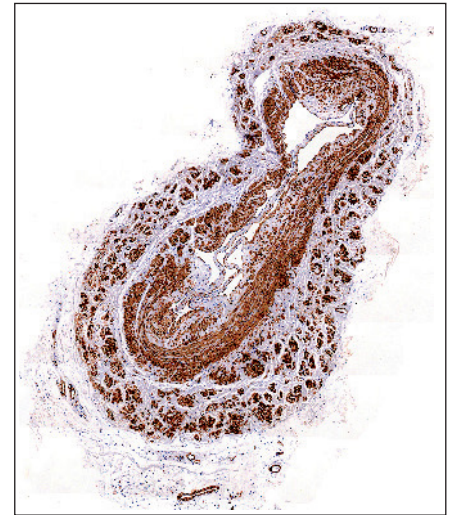
The structure of the wall of the superficial veins in the leg has to cope with the high hydrostatic pressure in the vessel and the low external pressure from the surrounding loose connective tissue. All the superficial veins therefore have a high proportion of circular smooth muscle fibres (21).

Beneath the layer of endothelium, the tunica intima consists of a loose extracellular matrix with collagen and elastic fibres, but also smooth muscle cells (53). Most of the muscle fibres run longitudinally and strengthen the vein wall (4). Middle-sized and large veins also have a more-or-less complete internal elastic membrane (the internal elastic lamina). It is found mainly in the segments between the valves. At the level of the valves, the internal elastic lamina

leaves the vein wall and switches to the luminal side of the valve cusp at the agger; although the vein wall itself contains elastic fibres around the valve sinus, they are not contiguous with the internal elastic lamina (51) (► Fig. 3).

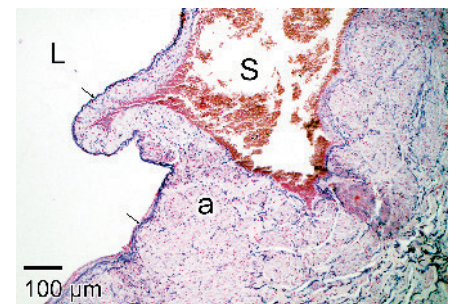A smooth transition to the tunica media occurs through the increase of smooth muscle cells. Their arrangement here is altogether denser, so that little room remains for collagen fibrils and elastic fibres. In addition, there are blood vessels and nerve plexuses (*vasa and nervi vasorum*) (53). The muscle fibres have a circular arrangement in the tunica media (*media circularis*). Smaller veins have a loose circular muscle layer with fine elastic fibres lying in between the muscle cells; the thickness of the circular muscle layer increases with the diameter of the vessel and appears dominant in the large epifascial venous trunks (28). After the age of 20, longitudinal muscle fibre bundles develop inside the circular media. These may disappear again with advancing age (4). Elastic fibre networks lie on the surface of the muscle layer, with the fibres predominantly running longitudinally (28). Adjacent to the tunica intima in the great saphenous vein (GSV), there is a section of variable width with longitudinal smooth muscle cells (51). In between the individual muscle cells or bundles are tightly packed undirected collagen fibres and moderately thick elastic fibres arranged longitudinally (51). A layer of circular muscle consisting of 5–8 overlying layers of smooth muscle cells is found to the outside (51).

Descriptions of the structure of the tunica adventitia are contradictory: the transition to the tunica adventitia has been described as the region where there are no longer any muscle cells (53) but other sources declare that spiral or longitudinal bundles of muscle fibres are still to be found in the adventitia (4; 51). Rieger and co-workers also report that these longitudinal muscle fibre bundles develop over the course of a lifetime into the most important component of the vessel wall (38). The adventitia consists of loose connective tissue and contains *vasa vasorum*, which are found in larger numbers in the epifascial veins than in the deep veins, plus bundles of nerve fibres and lymphatic vessels (28).



**Fig. 2** Histological cross-section of the great saphenous vein at the level of a parietal valve: the tunica media consists of circular smooth muscle (*media circularis*) and partially developed longitudinal muscle (*media longitudinalis*). The tunica adventitia also contains numerous longitudinal muscle fibre bundles.

$\alpha$ -SMA/haematoxylin/lithium carbonate. Own image. Source: Division of Clinical and Functional Anatomy, Medical University of Innsbruck



**Fig. 3** Histological longitudinal section of the great saphenous vein at the level of a parietal valve cusp: the internal elastic lamina extends from the valve cusp; there is no clearly structured continuous internal elastic lamina around the sinus. L: lumen; S: sinus; a: agger. Weigert's elastic stain. Own image. Source: Division of Clinical and Functional Anatomy, Medical University of Innsbruck

The subcutaneous tissue is divided into a true subcutaneous layer and an epifascial layer by a stratified wide-meshed lamellar system (29). The larger subcutaneous veins are suspended in the epifascial layer by a three-dimensional network of tensioning lamellae (28) that safeguards against strain and overstretching given the great flexibility (23).

## Superficial veins of the leg

Clinical focus on the superficial veins of the leg lies firstly on the epifascial manifestations of chronic venous insufficiency, varicose veins, and – as a complication – venous leg ulcers, and secondly on the possibility of harvesting these veins, especially the great saphenous vein, for the purpose of bypass grafting (► Fig. 4).

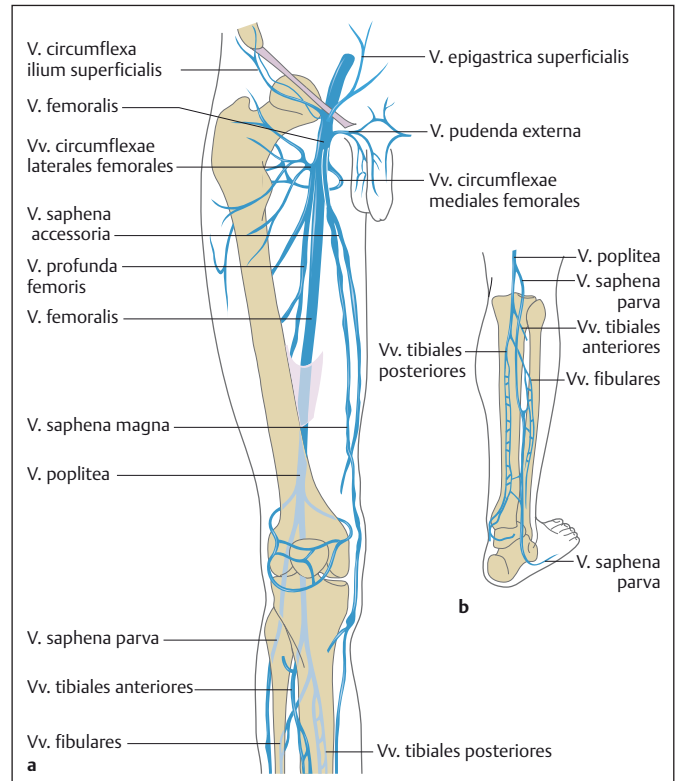
The two large intrafascial veins of the leg are the great saphenous vein (GSV) and the small saphenous vein (SSV). These terms are thought to come from the Greek meaning ‘clearly evident, albeit badly developed’, because these vessels are easily seen due to their superficial position. The Greek term is *σφυριτικ φλεψ* (37). The two systems are connected by communicating veins that differ greatly from person to person. In addition to the junctions of the superficial veins with the deep venous system, they are also connected by perforating veins. The direction of the valves in these veins allows the additional flow of blood from the superficial to the deep system. The groups of perforators are designated according to their topographical position and further divided into subgroups (16).

### The great saphenous vein (vena saphena magna)

The great saphenous vein (GSV) has its origin in the medial marginal vein at the medial border of the foot. It becomes the GSV proper when it enters its own fascial compartment in front of the medial malleolus. It runs up the medial aspect of the calf, crosses the knee joint just behind the medial femoral condyle in most cases, and enters the femoral triangle at the medial border of the sartorius muscle. The GSV passes through the saphenous opening in the fascia lata to open into the common femoral vein.

In the lower leg the GSV has two main tributaries. The leg portion of the posterior accessory of the GSV (vena saphena accessoria posterior distalis (sive cruris)) was formerly known as the posterior arch vein (vena arcuata cruris posterior); it originates behind the medial malleolus and runs upwards in a posteromedial position about 3 cm from the great saphenous vein in the

**Fig. 4** Venous flow in the right leg. a) Anterior thigh; b) Posterior calf (Source: Teubner P. Der venöse Blutabfluss. In: Bommas-Ebert U, Teubner P, Voss R, Editors. *Kurzlehrbuch Anatomie und Embryologie*. 3rd edition. Thieme; 2011. doi:10.1055/b-002-21536)



calf. It usually opens into the great saphenous vein just below the knee. The distal (or crural) anterior accessory of the GSV (vena saphena accessoria anterior distalis (sive cruris), formerly the anterior arch vein (vena arcuata cruris anterior) runs almost parallel to the infrapatellar branch of the saphenous nerve.

The GSV has numerous tributaries in the thigh, which mostly open in the region of the saphenofemoral junction (SFJ); this anatomical region was referred to as the ‘crosse’ in earlier times. Even though the term saphenofemoral junction has been commonly used in the English literature, discrepancies remain as to whether the term covers only the actual opening of the GSV into the common femoral vein or, as recommended by the International Union of Phlebology (UIP), the entire area from the preterminal valve to the orifice (15; 16). The saphenofemoral junction also includes the relevant portions of the common femoral vein between the supra- and infrasaphenic valves.

The suprasaphenic valve is the first parietal valve in the common femoral vein located immediately above (proximal to) the orifice of the great saphenous. In our own

investigations, we found that this valve was present in about 70% of cases; the average distance from the opening was 39 mm. In rare cases, further parietal valves can be found proximally in the common femoral vein (33). An infrasaphenic valve, i.e. the first parietal valve distal to the orifice of the GSV, was relatively common, being present in 87% of cases; the average distance from the orifice was about 50 mm. In about half of the cases we found a second distal parietal valve and, rarely, even a third (33).

Well-known large named veins open at the SFJ but there are also small unnamed tributaries. These small tributaries mostly originate around the superficial inguinal lymph nodes; there may also be veins accompanying the vessels and nerves (venae comitantes, venae vasorum, venae nervorum) and small cutaneous veins. The major superficial inguinal tributary veins or [major] saphenous junctional tributaries form the confluence of the superficial inguinal veins, sometimes also known as the Venenstern (venous star) from the German. This term, however, does not indicate any uniform vascular pattern: any of these veins may open independently into the great saphenous vein or form trunks with

one or more of the other large tributaries, or even, if only rarely, open into the common femoral vein. Usually three or four large tributaries open into the saphenofemoral junction. Given the large number of theoretically possible patterns, many of which have already been demonstrated, it does not really seem worthwhile to classify the SFJ variants, as many authors have tried to do.

- Superficial circumflex iliac vein (*vena circumflexa ilium superficialis*): In 83% of cases, it enters the GSV, on average about 11 mm (maximum 2 cm) before the GSV opens into the common femoral vein. It is therefore usually the most proximal of the tributaries emptying into the SFJ. This tributary forms a common trunk with the superficial epigastric vein in 30% of cases, and occasionally also includes the external pudendal vein (*vena pudenda externa*). The superficial circumflex iliac vein drains the lateral lower abdomen as well as the hip region and the lateral aspect of the upper thigh.
- Superficial epigastric vein (*vena epigastrica superficialis*): In just about 80% of cases, this large tributary opens into the SFJ about 12 mm from the saphenofemoral orifice. It may form a trunk with the superficial circumflex iliac vein alone (32%) or also include the (proximal) anterior accessory of the GSV (18%). The superficial epigastric vein drains the lower and medial part of the anterior abdominal wall from about the level of the umbilicus. Superiorly it anastomoses with the thoracoepigastric vein, which in turn opens into the axillary vein in the axilla. Around the umbilicus, this venous system connects with the paraumbilical veins, constituting an important portacaval anastomosis. The paraumbilical veins may distend to become a *caput medusae* when the flow in the portal vein is obstructed.
- External pudendal vein(s) (*vena(e) pudenda(e) externa(e)*): There are usually two external pudendal veins that unite into one large tributary before opening into the GSV about 17 mm (maximum 5 cm) from the saphenofemoral orifice in 90% of cases. They form trunks, especially with the superficial epigastric

vein (12%). They drain the external genitalia (scrotum or labium majus) and may anastomose with the dorsal vein of the penis or clitoris, respectively.

- Anterior accessory of the GSV (*vena saphena accessoria anterior* (proximalis sive femoris)): The proximal (femoral) anterior accessory of the GSV has its own fascial sheath, similar to that of the great saphenous vein with its saphenous fascia. However, in only 50% of cases does it open into the saphenofemoral junction, at an average distance of 20 mm from the saphenofemoral orifice. It forms trunk veins with the superficial circumflex iliac vein and/or the superficial epigastric vein. It drains the anterior and lateral thigh. Its main branch runs superficially following the course of the deep vessel/nerve pathway with the femoral artery and vein (alignment sign) and can be clearly distinguished from the great saphenous vein, which lies correspondingly medially.

From our own investigations, the (proximal) posterior accessory of the GSV (*vena saphena accessoria posterior* [proximalis sive femoris]) does not count as a large tributary of the saphenofemoral junction, even though it is sometimes still included in the confluence of superficial inguinal veins in the anatomical literature, a circumstance that can be attributed to it occasionally opening into one of the other large tributaries (34). Even though it frequently (85%) opens into the great saphenous vein, it does so at an average distance of more than seven centimetres (74 mm) from the saphenofemoral orifice. It therefore lies distal to the preterminal valve. In addition, it ultimately represents the actual outlet of the long dorsal vein(s), the small saphenous vein and its proximal extension, the femoropopliteal vein.

### Fascial relations of the great saphenous vein (8)

The superficial compartment of the thigh, the subcutaneous tissue, is bordered by skin on the outside and the fascia lata on the inside. Within this subcutaneous compartment lie all the superficial veins, but also (cutaneous) nerves and lymphatic

channels that drain into the superficial inguinal lymph nodes (*nodi lymphatici inguinales superficiales, tractus horizontalis et verticalis*).

The fascia lata is the fascial sheath surrounding the entire thigh. It has various openings for nerves and vessels to pass through. The largest opening allows the great saphenous vein to enter the subfascial compartment and is called the saphenous opening. The proximal, lateral and distal margins form the falciform margin, while the medial margin does not have a sharp border. Here the fascia curves more deeply and, as a relatively thin sheet of connective tissue, separates the distal extension of the vascular lacuna (containing the femoral artery and common femoral vein) from the distal extension of the femoral canal (with the lymph vessels and nodes of the deep inguinal group). The main branches of the nerves (femoral branch of the genitofemoral nerve, anterior cutaneous branches of the femoral nerve) do not usually pass through the saphenous opening, but mostly through the fascia lata laterally to it.

The subcutaneous tissue is divided by septa running in both the vertical plane from superficial to deep, and in the horizontal plane parallel to the fascia lata. Just below the surface, the septal separation is mostly incomplete. Somewhat deeper these connective tissue membranes form the cribriform fascia (*fascia subcutanea cribrosa*), in particular over the saphenous opening similarly to the abdomen, which was formerly referred to as the superficial femoral fascia or the fascia of Scarpa.

The saphenous fascia (10; 11). The GSV is fixed in its intrafascial position by its own fascia. The saphenous fascia is formed from a semi-transparent fibroelastic membrane in the lower thigh, reinforced by transverse strands of connective tissue. It is considerably thinner in the subinguinal region, over the saphenous opening, where the connective tissue strands are arranged radially or irregularly. Proximally, the saphenous fascia attaches to the inguinal ligament.

This fascia creates an isolated great saphenous compartment. In the upper thigh it contains the GSV and its *vasa vasorum*, the superficial inguinal lymph nodes, and the openings of the tributaries that have

previously pierced the saphenous fascia. The saphenous nerve still lies beneath the fascia lata in the upper thigh, not piercing the vastoadductor membrane (subsartorial fascia) and subsequently the fascia lata until the lower thigh; it comes to lie adjacent to the GSV, which it accompanies through the rest of the lower leg. The GSV is anchored to the fascial walls of the saphenous compartment by lateral connective tissue laminae (the 'saphenous ligament'). This configuration gives rise to the ultrasound image of the 'saphenous eye'.

Double great saphenous veins can be diagnosed only when two veins lie within the great saphenous compartment; if the second vein lies superficially to the saphenous fascia and runs parallel to the GSV, this is designated as a superficial accessory to the GSV.

### Small saphenous vein (vena saphena parva) (8)

The small saphenous vein (SSV) originates behind the lateral malleolus as the continuation of the lateral marginal vein, where it also receives its main afferent veins. The SSV is the long posterolateral vein of the lower leg, where it receives the lateral accessory saphenous vein of the leg, and continues as the proximal extension of the small saphenous vein, also known as the femoropopliteal vein, on the posterior aspect of the calf. This proximal extension moves around the upper thigh medially and ultimately opens into the GSV as the posterior accessory vein. In the vicinity of the popliteal fossa, this long posterior intrafascial vein relatively often anastomoses with the popliteal vein to a varying extent. This anastomosis is actually a saphenopopliteal perforating vein but is referred to in general clinical terms as the saphenopopliteal junction (the 'crosse' in European countries). The outflow of the saphenopopliteal junction forms the boundary between the SSV itself and its proximal extension. Anglo-American literature does not recognise the term 'crosse' and uses the term saphenopopliteal junction.

The proximal extension of the small saphenous vein continues proximally into the thigh: it usually lies in its own fascial compartment and finally opens into the great saphenous vein as the posterior accessory

of the GSV. In our investigations, we found a proximal extension of the SSV in 84% of cases; this frequency correlates well with the number of posterior accessory veins opening into the GSV (85%) (► Fig. 5).

However, there is a wide range of variants depending on how well the individual components are developed, especially the saphenopopliteal junction and the proximal extension of the SSV. In the course of our investigations, we identified a 'normal' saphenopopliteal junction in 56% of cases, sometimes with a very fine vessel or a double SSV, while a regular network of fine veins was present in 15% of cases.

The saphenopopliteal junction was completely absent in the remaining cases (29%), with only a fine proximal extension to be found (43). The saphenopopliteal junction usually opens into the popliteal vein from the (postero)lateral direction. Its position in relation to the two large nerve trunks in the popliteal fossa, the tibial nerve and the common fibular nerve, is important. We found that the tibial nerve lies laterally to the saphenopopliteal junction in about two-thirds of cases and medially in the other third. Particular attention needs to be paid to the common fibular nerve as it sometimes, although rarely (2.5% of cases), lies medial to the saphenopopliteal junction and then crosses the popliteal fossa relatively obliquely.

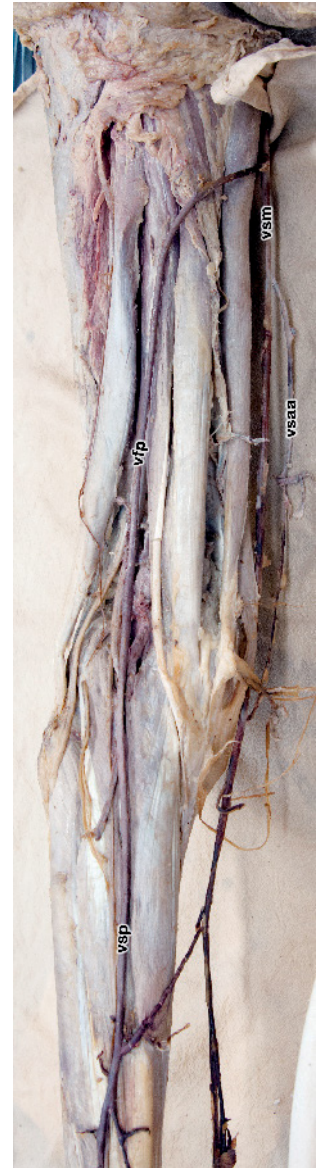### Fascial relations of the small saphenous vein (8)

Like the great saphenous vein, the SSV and its proximal extension also have their own (small) saphenous fascia (11; 12). Our investigations showed that this fascia begins near the lateral malleolus and extends upwards along the whole lower leg (43). Only the saphenopopliteal junction ultimately pierces the popliteal fascia to reach the popliteal vein.

The situation may also arise here that an accessory vein lies superficially outside this fascia, which is then called the superficial accessory vein.

### Perforating veins

The superficial venous system and the deep venous system are connected by up to 150



**Fig. 5** Proximal extension of the small saphenous vein (vein of Giacomini): The small saphenous vein continues into the thigh as its proximal extension as a vessel of almost the same diameter; it winds around the upper thigh and opens into the great saphenous vein. There is a robust perforator to the popliteal vein in the vicinity of the popliteal fossa (the saphenopopliteal junction). Left leg. Own image, prepreparation for dissection course. Source: Division of Clinical and Functional Anatomy, Medical University of Innsbruck

perforating veins in each leg. About 60 of these are key perforating veins, accompanied by cutaneous arteries in the thigh and lower leg, as direct outflows of the saphenous system. Another approximately 90 clinically less relevant perforating veins

pierce the fascia via intermuscular septa, sometimes paired with the cutaneous arteries. They drain mainly the subcutaneous tissue and are accompanied by subcutaneous nerves, lymph vessels, and the vasa vasorum of the saphenous system. Anastomoses in the subcutaneous tissue, at the fascial openings, and in the subfascial tissue connect the two venous outflow systems. The blood flow is directed from superficial to deep by means of one to three parietal valves; if there is only one valve, it is always located shortly before the vein opens into the deep system. These valves protect the superficial venous system against reflux from the deep venous system, for example by appropriate muscle contractions. The wall structure of the perforating veins is approximately the same as that of the superficial veins. Neither systematic and topographic anatomical parameters, nor the nature, number or structure of their valves or even special features of their wall structure explain why some perforating veins tend to become incompetent while others do not.

Perforating veins are very numerous and very variable with respect to arrangement, connection, size, and distribution. Most anatomical investigations have not found any consistency in the number and position of these connecting pathways. On the other hand, clinical authors emphasise that the regularity that can be seen in this respect is relatively high. Apparently even the smallest perforating veins can be demonstrated radiologically or surgically exposed in living patients, especially when the venous flow is obstructed for some reason, although they cannot always be seen in anatomical preparations.

The course of the perforating veins passes two topographic regions: the superficial or subcutaneous part and the deep or subfascial part. The subcutaneous part is short and frequently uniform. The subfascial part is much longer and often shows morphological variation. The perforating veins change their morphological appearance most often in the subfascial section: there may be double veins, branched, arboreal, or complex vessels. The subcutaneous part often crosses the superficial nerves, while the subfascial part lies close to a small, thin artery.

In clinical practice, the perforating veins were often given eponymous names that still appear, even though they were often inaccurate from a historical point of view and sometimes confusing. In the more recent literature therefore, thoroughly descriptive topographical terms are preferred. Perforators are grouped on the basis of their topography (► Table 1).

The perforating veins of the foot (*venae perforantes pedis*) are divided into dorsal (intercapitular), medial, lateral, and plantar foot perforators. A consistent large perforating vein connects the dorsal venous arch of the foot with the deep veins of the foot in the first intermetatarsal space.

The perforating veins of the ankle (*venae perforantes tarsalis*) are divided into medial, anterior, and lateral groups and usually lack valves.

The perforators of the leg (*venae perforantes cruris*) are divided into four main groups. The perforators of the medial leg are designated as paratibial and posterior tibial perforating veins. Paratibial perforators connect the main trunk or tributaries of the GSV with the posterior tibial veins and run close to the medial surface of the tibia. They correspond to the so-called Sherman PV (at the lower and mid leg) and Boyd PV (at the upper leg). Posterior tibial perforating veins (Cockett perforators) connect the posterior accessory great saphenous vein with the posterior tibial veins (*venae tibiales posteriores*). There are usually three perforating veins (lower, middle, and upper) which lie at a distance of 6 cm, 13.5 cm, and 18.5 cm proximal to the sole of the foot along 'Linton's line'; this is an imaginary vertical line along the calf starting about a fingerbreadth behind the medial malleolus. The point where the upper posterior tibial perforator pierces the fascia is known in clinical terms as the soleus point. In addition, there may be a further perforating vein higher up on Linton's line, at a distance of approximately 24 cm from the sole of the foot, known as the 24-cm PV.

The perforating veins of the anterior leg connect the anterior tributaries of the GSV to the anterior tibial veins (*venae tibiales anteriores*). They consistently lie some 2 cm to 5 cm lateral to the anterior border of the tibia.

The perforating veins of the lateral leg connect veins of the lateral superficial venous plexus with the fibular veins (*venae fibulares*).

The perforating veins of the posterior leg are divided into medial gastrocnemius perforators (in the medial calf), lateral gastrocnemius perforators (in the lateral calf), intergemellar perforators that connect the SSV to the deep calf veins (also called the mid-calf perforator of May), and para-Achillean perforators that connect the SSV with the fibular veins (also called the perforator of Bassi) some 5 cm proximal to the calcaneus.

The perforating veins of the knee (*venae perforantes genus*) are designated as medial knee perforators, suprapatellar or infrapatellar perforators, lateral knee perforators, and popliteal fossa perforators, according to their location. These perforating veins, too, usually lack valves.

The perforating veins of the thigh (*venae perforantes femoris*) are also grouped on the basis of their topography. On the medial thigh are the perforators of the femoral canal (Dodds) and the inguinal perforators, which connect the GSV or its tributaries with the femoral vein at the groin. The anterior thigh perforating veins pierce the quadriceps femoris. The lateral thigh perforating veins pierce the lateral muscles of the thigh. On the posterior thigh, the perforating veins are designated as posteromedial thigh perforators piercing the adductor muscles, sciatic perforators lying along the midline of the posterior thigh, posterolateral thigh perforators piercing the biceps femoris and semitendinosus muscles (also called the 'perforator of Hach'), and pudendal perforators.

The perforating veins of the gluteal region (*venae perforantes glutealis*) are divided into superior, mid, and lower perforators.

## Fascial openings

The perforating veins pierce the fascia through oval apertures whose long axis lies in the same direction as the fascial fibres and whose edges are reminiscent of the fal-ciform margin of the saphenous opening. These margins are formed by thickened bundles of fibres that intersect at the

**Tab. 1** Overview of the perforating veins. Sources: Caggiati A, Bergan JJ, Gloviczki P, Jantet G, Wendell-Smith CP, Partsch H and the International Interdisciplinary Consensus Committee on Venous Anatomical Terminology (16), Ströbel P (48)

Location	Subgroup (eponym)	Average number	Connecting between ...
<b>Gluteal</b>	Superior gluteal PV	4 – 6	subcutaneous veins and superior gluteal veins
	Inferior gluteal PV	4 – 7	subcutaneous veins and inferior gluteal veins
<b>Thigh</b>	Medial thigh PV:		
	PV of the femoral canal (Dodd)	3 – 5	great saphenous vein (small saphenous vein) and femoral vein
	Inguinal PV	1	superficial and deep circumflex iliac veins
	Anterior thigh PV	6 – 12	branches of the great saphenous vein and muscle veins
	Lateral thigh PV	3 – 9	
	Posterior thigh PV:		
	Posteromedial PV	1 – 5	great saphenous vein and femoral vein
	Sciatic PV	2 – 3	cranial extension of small saphenous vein and femoral vein
	Posterolateral PV (Hach)	3 – 9	subcutaneous venous plexus and muscle veins
	Pudendal PV	2	subcutaneous venous plexus and pudendal vein
<b>Knee</b>	Medial knee PV	3 – 5	small saphenous vein and popliteal vein
	Anterior knee PV:		
	Suprapatellar PV	1 – 2	
	Infrapatellar PV		
	Lateral PV	4	lateral venous plexus and popliteal vein
	Posterior or popliteal fossa PV	4	small saphenous vein and popliteal vein
<b>Lower leg</b>	Medial leg PV:		
	Paratibial PV (Sherman's or Boyd's)	4	great saphenous vein and posterior tibial vein
	Posterior tibial PV (Cockett)	3 (- 5)	posterior accessory great saphenous vein and anterior tibial vein
	Anterior leg PV	3	anterior tributaries of the great saphenous vein and anterior tibial vein
	Lateral leg PV	3 – 5	lateral branches of the small saphenous vein and fibular vein
	Posterior leg PV:		
	Medial gastrocnemius PV		posterior branch of the great saphenous vein and gastrocnemius veins
	Lateral gastrocnemius PV		small saphenous vein and gastrocnemius veins
	Intergemellar PV (May)	1	
Para-Achillean PV (Bassi)		small saphenous vein and fibular vein	
<b>Ankle</b>	Medial ankle PV (May/Kuster)	3	dorsalis pedis vein and great saphenous vein
	Anterior ankle PV	2	origin of fibular vein and small saphenous vein
	Lateral ankle PV	2 – 3	
<b>Foot</b>	Dorsal foot PV	10 – 14	plantar vein and great or small saphenous vein
	Medial foot PV	6	dorsalis pedis vein and great or small saphenous vein
	Lateral foot PV	6	fibular vein and small saphenous vein
	Plantar foot PV	13 – 16	deep plantar veins and the venous network of the sole of the foot (rete venosum plantare)

angles. Tent-like sheaths are formed from the loose fine-fibred superficial layer of the fascia together with the fibrous system of the vascular sheaths of the perforating veins. The perforators are also equipped

with a similar, although not so strongly developed, supporting matrix on the inside of the fascia. The openings are usually located in the intermuscular septa, especially in the lower leg. The perforating veins usually

penetrate the fascia in a downwards direction, rarely also running upwards. They firstly run for some distance between two fascial sheets, sometimes with an intrafascial sheath, e.g. along the medial tibial mar-



gin. It is often the case that several perforating veins open into the deep veins through a common trunk segment.

Based on macroscopic preparations, Sander (1959) distinguished three types of fascial opening for perforating veins – apparently irrespective of the local fascial texture:

- The most commonly occurring type of fascial opening is the ‘hole’. Tensioning fibres in the intersecting fibre bundles form a rounded opening through which the perforators usually pass steeply. These fascial holes are so firm due to their intersecting and interwoven fibres that no alteration in shape is possible on tension, i.e. the aperture does not widen or narrow (an example of this type is seen in the caval opening in the central tendon of the diaphragm).
- The ‘funnel’ is to be found as the construction where the superficial fascia is associated with a muscle septum. The opening in the fascia is funnel-shaped, running along the septum into the deeper layers; the funnel thus formed does not merge with the vascular sheath of the penetrating vessels (perforating vein with accompanying artery and lymph vessels) but also ends with a sharp margin. Sander asserted that it stands to reason that tension on the fascia would not cause this type of opening to change shape, either.
- The rarest type of fascial opening is the ‘slit’, which is found only where the fascial fibres are running in the same direction and the veins pass through entirely. This is particularly the case over the robust bellies of the calf muscles. The veins pass straight through a slit-like opening in the parallel fibre bundles, whose edges diverge perpendicularly to the fascial plane. If the fascia is slack, the filled vein widens the slit, but when the fascia is tensed, the slit narrows, thus compromising the perforator.

The perforating veins are nearly always accompanied by small arteries and lymph vessels; deep anastomoses where the vein passes through the fascia alone could be demonstrated only in the foot. If incompetent varicose perforating veins trap the accompanying arteries and lymphatics be-

tween the free margin of the fascial opening and the widened vein wall, trophic disorders in the vascular territory may ensue.

## Functional aspects (1, 2)

The venous system as a whole makes only a small contribution to the overall peripheral resistance (venules and veins together account for about 7% [27]), yet it contains three-quarters of the blood volume. The most important parameters of the venous system are therefore volume and compliance of the vein wall. These parameters can be measured easily and reliably in routine clinical practice by means of venous occlusion (photo) plethysmography. Apart from factors of age and body position, the venous tone itself depends greatly upon temperature, so that corresponding investigations should be carried out only at constant (and recorded) ambient temperatures after adequate acclimatisation.

Pharmacological venous vasoconstriction can be achieved by the local administration of  $\alpha$ -adrenergic agonists, 5-HT receptor agonists, ergot alkaloids, angiotensinogen, and angiotensin I and II, as well as various prostaglandins. Applying cold is also well-known to cause vasoconstriction (45). Vasodilatation of previously constricted veins can be seen with the use of  $\beta$ -adrenergic agonists, muscarinic cholinergic receptor agonists, nitrates, calcium antagonists, bradykinin, substance P, and some prostaglandins. It seems that veins are also basically able to accomplish spontaneous peristaltic contraction (5; 6).

The full mechanism that drives the blood in the veins towards the heart remains conspicuously unexplained. Rather, a whole bunch of factors combine to enable the venous blood flow. These include the oft-mentioned ‘vis a tergo’ (force acting from behind), the ‘vis a fronte’ (force acting from in front), the muscle pump, and the mechanics of respiration (52). The pressure gradient from the postcapillary area to the heart is a sufficient ‘vis a tergo’ to maintain a slow blood flow, at least with the body lying horizontally (25). This volume transport, which is ‘pushed’ by the systolic ejection from the left ventricle, cannot, however, represent the sole origin of the ‘vis a

tergo’; for instance, a pressure increase in the vena cava also occurs with a sudden cardiac arrest (39). The ‘vis a fronte’ of the right atrial diastolic suction also has an effect on the filling of the heart; however its effects on the peripheral venous system have not yet been investigated. However, the heart rate does not correlate with the frequency of the valve closure cycles in the GSV (46; 47). The mechanics of respiration act in the same direction, i.e. ‘vis a fronte’ (25), but once again there is no correlation between the respiratory rate and the valve closure cycles (46; 47). The muscle and joint pumps have been described as an important drive mechanism (18; 25), although there are dissenting voices on this issue (26), especially as their function depends on active movement. When the muscles are active, these pumps certainly contribute to the venous return; when the body is completely at rest, asleep for instance, this mechanism stops working.

It is understandable that disorders of the connections between the superficial and deep venous systems lead to serious problems. This involves not only the saphenofemoral and saphenopopliteal junctions but also the perforating veins.

A vicious circle ensues: instead of blood flowing into the deep system, there is backflow (reflux) from the deep veins. This in turn increases the superficial blood volume. The superficial veins dilate as a result, causing more venous valves to stretch and become incompetent. Conversely, (pathological) changes in the vein wall, such as thickening of the intima and media or an increase in collagen and a decrease in the elastic fibres, can disrupt the normal functioning of the veins and give rise to venous insufficiency (20).

The endothelial cells of the veins contain numerous Weibel-Palade bodies (WPBs). The WPBs store von Willebrand Factor (vWF), an adhesive glycoprotein essential to haemostasis. If the endothelium is damaged, vWF binds platelets that coat the defect immediately and allow it to be covered with new epithelial cells later.

## Conflict of interest

The author declares that he has no conflicts of interest.

## Ethical guidelines

No studies on humans or animals were conducted in the preparation of this paper.

## References

- Aellig WH. Clinical pharmacology, physiology and pathophysiology of superficial veins--1. *Br J Clin Pharmacol* 1994; 38(3): 181–196.
- Aellig WH. Clinical pharmacology, physiology and pathophysiology of superficial veins--2. *Br J Clin Pharmacol* 1994; 38(4): 289–305.
- Aharinejad S, Nedwed S, Michlits W, Dunn R, Abraham D, Vernadakis A, Marks SC, Jr. Valvular density alone cannot account for sites of chronic venous insufficiency and ulceration in the lower extremity. *Microcirculation* 2001; 8(5): 347–354.
- Altenkämper H, Eldenburg M. *Farbatlas der Phlebologie*, 1st ed. Hannover: Schlüter 1993.
- Attardi G. Demonstration in vivo and in vitro of Peristaltic Contractions in the Portal Vein of Adult Mammals (Rodents). *Nature* 1955; 176(4471): 76–77.
- Attardi G, Attardi-Gandini D. Spontaneous peristaltic activity of veins of chick embryos and newly hatched chickens explanted in vitro. *Experientia* 1955; 11(1): 37–38.
- Bommas-Ebert U, Teubner P, Voß R. *Kurzlehrbuch Anatomie: und Embryologie*, 3rd ed. Stuttgart, New York: Thieme 2011.
- Brenner E. Spezielle Anatomie der Crossextremitäten. In: Noppeney T, Nüllen H, (Hrsg.) *Varikose: Diagnostik – Therapie – Begutachtung*. Berlin, Heidelberg: Springer 2010; 18–24.
- Butterworth DM, Rose SS, Clark P, Rowland P, Knight S, Haboubi NY. Light-Microscopy, Immunohistochemistry and Electron-Microscopy of the Valves of the Lower-Limb Veins and Jugular Veins. *Phlebology* 1992; 7(1): 27–30.
- Caggiati A. Fascial relationships of the long saphenous vein. *Circulation* 1999; 100(25): 2547–2549.
- Caggiati A. Fascial relations and structure of the tributaries of the saphenous veins. *Surg Radiol Anat* 2000; 22(3–4): 191–196.
- Caggiati A. Fascial relationships of the short saphenous vein. *J Vasc Surg* 2001; 34(2): 241–246.
- Caggiati A. The nomenclature of the veins of the lower limbs, based on their planar anatomy and fascial relationships. *Acta Chir Belg* 2004; 104(3): 272–275.
- Caggiati A. The venous valves of the lower limbs. *Phlebology* 2013; 20(2): 87–95.
- Caggiati A, Bergan JJ, Gloviczki P, Eklof B, Allegra C, Partsch H, International Interdisciplinary Consensus Committee on Venous Anatomical Terminology. Nomenclature of the veins of the lower limb: extensions, refinements, and clinical application. *J Vasc Surg* 2005; 41(4): 719–724.
- Caggiati A, Bergan JJ, Gloviczki P, Jantet G, Wendell-Smith CP, Partsch H, International Interdisciplinary Consensus Committee on Venous Anatomical Terminology. Nomenclature of the veins of the lower limbs: an international interdisciplinary consensus statement. *J Vasc Surg* 2002; 36(2): 416–422.
- Caggiati A, Phillips M, Lametschwandner A, Allegra C. Valves in small veins and venules. *Eur J Vasc Endovasc Surg* 2006; 32(4): 447–452.
- Corley GJ, Broderick BJ, Nestor SM, Breen PP, Grace PA, Quondamatte F, O'Leighin G. The anatomy and physiology of the venous foot pump. *Anat Rec (Hoboken)* 2010; 293(3): 370–378.
- Crotty TP. The venous valve afferent and plasma noradrenaline-mediated venodilator feedback. *Phlebology* 2007; 22(3): 116–130.
- Elsharawy MA, Naim MM, Abdelmaguid EM, Al-Mulhim AA. Role of saphenous vein wall in the pathogenesis of primary varicose veins. *Interact Cardiovasc Thorac Surg* 2007; 6(2): 219–224.
- Fischer H. Der lichtmikroskopische Bau der Venenwand mit besonderer Berücksichtigung der Einwirkung des hydrostatischen Druckes. *Zentralbl Phlebol* 1967; 6(2): 209–220.
- Franklin KJ. Valves in Veins: An Historical Survey. *Proc R Soc Med* 1927; 21(1): 1–33.
- Freerksen E. Die Venen des menschlichen Handrückens. *Z Anat Entw Gesch* 1937; 108(1): 82–111.
- Hach W, Gruß JD, Hach-Wunderle V, Jünger M. *VenenChirurgie*. Stuttgart, New York: Schattauer 2006.
- Hach W, Hach-Wunderle V. Die retrograde und die antegrade Strömungsinsuffizienz der tiefen Beinvenen als Grundlage für chirurgische Überlegungen. *Gefäßchirurgie* 1998; 3(2): 110–116.
- Hamann JJ, Valic Z, Buckwalter JB, Clifford PS. Muscle pump does not enhance blood flow in exercising skeletal muscle. *J Appl Physiol* (1985) 2003; 94(1): 6–10.
- Hammersen F, Fischer H, Bräuer H. Blutfluß, Venen und Oedeme: zur Pathophysiologie des Niederdrucksystems. München: Müller & Steinicke 1985.
- Hochauf S, Sternitzky R, Schellong SM. Struktur und Funktion des venösen Systems. *Herz* 2007; 32(1): 3–9.
- Kubik S, May R. Das Verspannungssystem der Venen in der Subinguinalregion. *Aktuelle Probleme Angiologie* 1979; 38: 51–65.
- Leonhardt H, Tillmann B, Zilles K (Hrsg.) *Topographie der Organsysteme, Systematik der peripheren Leitungsbahnen*. 4. Stuttgart, New York: Thieme 1988.
- Ludbrook J. Valvular Defect in Primary Varicose Veins: Cause or Effect? *Lancet* 1963; 2(7321): 1289–1292.
- May R. *Chirurgie der Bein- und Beckenvenen*. Stuttgart: Thieme 1974.
- Mühlberger D, Morandini L, Brenner E. An anatomical study of femoral vein valves near the saphenofemoral junction. *J Vasc Surg* 2008; 48(4): 994–999.
- Mühlberger D, Morandini L, Brenner E. Venous valves and major superficial tributary veins near the saphenofemoral junction. *J Vasc Surg* 2009; 49(6): 1562–1569.
- Myers KA, Ziegenbein RW, Zeng GH, Matthews PG. Duplex ultrasonography scanning for chronic venous disease: patterns of venous reflux. *J Vasc Surg* 1995; 21(4): 605–612.
- Noppeney T, Nüllen H (Hrsg.) *Varikose. Diagnostik – Therapie – Begutachtung*. Berlin, Heidelberg: Springer 2010.
- Pierer JF, Choulant L (Hrsg.) *Medizinisches Realwörterbuch zum Handgebrauch practischer Aerzte und Wundärzte und zu belehrender Nachweisung für gebildete Personen aller Stände. Erste Abtheilung: Anatomie und Physiologie. Siebenter Band. Rh-Syz. Altenburg: Literatur=Comptoir 1827.*
- Rieger H, Strauss AL, Schoop W. *Klinische Angiologie*. Berlin: Springer 1998.
- Riml O. Über das Verhalten des Blutdruckes in der Vena cava bei plötzlichem Zirkulationsstillstande. *Naunyn-Schmiedeberg's Archives of Pharmacology* 1929; 139(3): 231–239.
- Rudofsky G. *Epidemiologie und Pathophysiologie der primären Varikosis*. Langenbecks Arch Chir 1988; Suppl 2: 139–144.
- Salter SJH. *Vein*. In: Todd RB, (Hrsg.) *Cyclopaedia of anatomy and physiology*. London: Longman, Brown, Green, Longmans, & Roberts 1849–1852; 1367–1403.
- Sappey PC. *Traité d'anatomie*. Paris 1869.
- Schweighofer G, Mühlberger D, Brenner E. The anatomy of the small saphenous vein: fascial and neural relations, saphenofemoral junction, and valves. *J Vasc Surg* 2010; 51(4): 982–989.
- Scultetus AH, Villavicencio JL, Rich NM. Facts and fiction surrounding the discovery of the venous valves. *J Vasc Surg* 2001; 33(2): 435–441.
- Shepherd JT, Rusch NJ, Vanhoutte PM. Effect of cold on the blood vessel wall. *Gen Pharmacol* 1983; 14(1): 61–64.
- Strauß A. Klappenschlussfrequenzen der oberen und unteren Extremität (am Beispiel der terminalen Klappe der V. saphena magna und der terminalen Klappe der V. cephalica) im direkten Vergleich und im Zusammenhang mit anderen Messgrößen. Thesis: Sektion für klinisch-funktionelle Anatomie, Dept. für Anatomie, Histologie und Embryologie. Innsbruck: Medizinische Universität Innsbruck 2010.
- Strauß A, Glodny B, Brenner E. Klappenschlussfrequenzen der oberen und unteren Extremität im direkten Vergleich und im Zusammenhang mit anderen Messgrößen – Am Beispiel der terminalen Klappe der Vena saphena magna und der terminalen Klappe der Vena cephalica *VasoMed* 2010; 22(5): 127–128.
- Ströbel P. Anatomie des epifaszialen Venensystems. In: Noppeney T, Nüllen H, (Hrsg.) *Varikose. Diagnostik – Therapie – Begutachtung*. Berlin, Heidelberg: Springer 2010; 10–18.
- Tasch C, Brenner E. The ostial valve of the great saphenous vein. *Phlebology* 2012; 27(4): 179–183.
- Tessari L, Capelli M. The study of the saphenofemoral junction to understand the distribution of refluxes in chronic venous disease. *Medicographia* 2008; 30(2): 112–115.
- Tsantilas P. Aufbau der Venenwand der gesunden V. saphena magna. Thesis: Sektion für klinisch-funktionelle Anatomie. Innsbruck: Medizinische Universität Innsbruck 2012; 64.
- Wagner AH. Physiologie und Pathophysiologie der venösen Hämodynamik. In: Noppeney T, Nüllen H, (Hrsg.) *Varikose. Diagnostik – Therapie – Begutachtung*. Berlin, Heidelberg: Springer 2010; 51–60.
- Zwillenberg LO, Laszt L, Zwillenberg H. Die Feinstruktur der Venenwand bei Varikose. *Angiologica* 1971; 8(6): 318–346.