



Imaging of Gastric Carcinoma. Part Two: Lymph node mapping in Gastric Carcinoma

Pulkit Maru¹ Bipradas Roy² Saugata Sen¹ Argha Chatterjee¹

¹Department of Radiology, Tata Medical Center, Kolkata, West Bengal, India

²Department of Surgical Oncology, Tata Medical Center, Kolkata, West Bengal, India

Address for correspondence Argha Chatterjee, MD, Department of Radiology, Tata Medical Center, Kolkata, West Bengal, India (e-mail: arghachat84@gmail.com).

J Gastrointestinal Abdominal Radiol ISGAR 2021;4:206–213.

Abstract

Accurate preoperative nodal staging is critical in determining the appropriate therapy and prognosis for stomach cancer. A staging computed tomography should inform the treating surgeon about the nodal burden to decide the appropriate surgical plan or perioperative chemotherapy. Nodal staging is also a powerful predictor of the outcome of surgery and overall survival. Imaging of nodes is also important in the assessment of response following the chemotherapy. In this article, we will discuss lymphatic drainage of stomach and different nodal stations, identification of nodal stations on cross sectional imaging, and different types of surgical nodal clearance for gastric cancer.

Keywords

- ▶ nodal staging
- ▶ stomach
- ▶ cancer
- ▶ computed tomography

Introduction

Lymphatic spread is found in 74 to 88% of gastric cancers at diagnosis.¹ Nodal stage is an important determinant of the overall stage and treatment of gastric cancer. Hence, radiological nodal staging (cN) and mapping of nodal stations is an important part of gastric cancer management. In this article, we will discuss lymphatic drainage of stomach, tumor node metastasis (TNM) and Japanese Gastric Cancer Association (JGCA) nomenclature of regional and distant nodal stations, identification of each station on cross sectional imaging, and different types of surgical nodal clearance for gastric cancer.

Clinical Significance of Nodal Staging

- Gastrectomy surgeries such as total gastrectomy and sub-total distal gastrectomy are further subdivided into D1, D1+, D2, and rarely D2+ based on the extent of dissection of distant nodal stations. Extent of nodal dissection is further determined by radiological staging. Station 10 nodes may sometimes require splenectomy, and hence, preoperative vaccination against encapsulated bacteria and a prior consent for organ removal is essential.²

- Nodal status is the most powerful predictors of outcome in the first 5 years after curative surgery.³ There is a significant difference in the recurrence rate and 5-year survival rate between lymph node-negative and lymph node-positive patients.^{3,4} It has been shown that the presence of four or more involved nodes predicts worse survival outcome.^{5,6} Therefore, the American Joint Committee on Cancer (AJCC) 8th edition has emphasized this relationship between the number of involved nodes and the prognosis of gastric cancer (▶ **Table 1**).⁷
- Evidence from studies of early gastric cancers from Japan suggest that well-differentiated cancers may metastasize more frequently to the liver and poorly differentiated tumors to lymph nodes.⁸ This may explain the high rate of local recurrence with the poorly differentiated tumors.
- For early gastric cancer (tumor limited to mucosa, less than 2 cm without ulceration) minimally invasive endoscopic procedure like endoscopic mucosal resection or endoscopic submucosal dissection is feasible in selected group of patients. But 2.3 to 5% patients of early gastric cancer may harbor nodal metastases.⁹ In those patients, proper gastrectomy with lymph node clearance is recommended.

published online
March 2, 2021

DOI <https://doi.org/10.1055/s-0040-1722795>
ISSN 2581-9933.

© 2021. Indian Society of Gastrointestinal and Abdominal Radiology. This is an open access article published by Thieme under the terms of the Creative Commons Attribution-NonDerivative-NonCommercial-License, permitting copying and reproduction so long as the original work is given appropriate credit. Contents may not be used for commercial purposes, or adapted, remixed, transformed or built upon. (<https://creativecommons.org/licenses/by-nc-nd/4.0/>).
Thieme Medical and Scientific Publishers Pvt. Ltd. A-12, 2nd Floor, Sector 2, Noida-201301 UP, India

Table 1 American Joint Committee on Cancer 8th Edition (tumor node metastasis) staging, N staging

NX	Regional lymph node(s) cannot be assessed
N0	No regional lymph node metastasis
N1	Metastasis in 1 to 2 regional lymph nodes
N2	Metastasis in 3 to 6 regional lymph nodes
N3	Metastasis in 7 or more regional lymph nodes
	N3a Metastasis in 7 to 15 regional lymph nodes
	N3b Metastasis in 16 or more regional lymph nodes

- Finally, perioperative chemotherapy with (fluorouracil-leucovorin-oxaliplatin-docetaxel) regime is now considered standard of care for locally advanced and node-positive resectable gastric and gastroesophageal cancer in many centers, including ours.¹⁰ So understaging due to inadequate information on nodal burden may lead to futile surgeries. On the other hand, overstaging may lead to unnecessary perioperative chemotherapy. Patients with heavy locoregional nodal burden (stations 1–12) should be considered for perioperative chemotherapy followed by surgery. If there are enlarged nodes at the para-aortic, aorto-caval, or mediastinal area, then the patient should be categorized as having metastatic disease and treated with palliative intent.

Anatomy

Stomach is drained by an extensive lymphatic network. Lymph nodes are named after either the organ of drainage or the accompanying vessels. The lymphatic vessels originate in the gastric mucosa and form a submucosal and a subserosal plexus. The subserosal plexus drains into the perigastric nodes. The perigastric nodes are the sentinel group of nodes draining the stomach. The perigastric nodes ultimately drain into the retroperitoneal nodes by four lymphatic axes.

- Nodes along left inferior phrenic artery (left subdiaphragmatic pedicle)
- Nodes along left gastric, splenic, and common hepatic arteries (celiac pedicle)
- Infrapyloric nodes and nodes along root of superior mesenteric artery (superior mesenteric pedicle)
- Nodes along the hepatoduodenal ligament and posterior aspect of pancreatic head (retro-pancreatic pedicle)

Due to the presence of extensive perigastric lymphatic networks, even early mucosa-confined tumors can have lymphatic spread at diagnosis.¹¹

Gastric Nodal Stations

Gastric nodes are described in 23 nodal stations, stations 1 to 20, and stations 110 to 112 (►Table 2). Generally, stations 1 to 12 are considered regional nodes both by AJCC and the JGCA. However, JGCA considers the superior mesenteric vein lymph node (station 14v) to be regional, but the AJCC considers it as a distal node. Also, if the tumor of the proximal third of stomach involves the esophagus, then the infradiaphragmatic, paraesophageal, and supradiaphragmatic lymph nodes (stations 19, 20, 110 and 111) are also considered

regional nodes.¹² All of these stations are considered distant nodal stations by the AJCC. For carcinomas arising in the remnant stomach with a gastrojejunostomy, jejunal lymph nodes adjacent to the anastomosis are included in regional lymph nodes as well.

There are some specific distal nodal sites that are typical for gastric carcinoma and some other upper abdominal malignancies. Metastasis can manifest as an enlarged supraclavicular node (Virchow node), periumbilical node (Sister Mary-Joseph node), or left axillary node (Irish node). The Virchow node is one of the left supraclavicular lymph nodes that is adjacent to the junction of the thoracic duct and left subclavian vein. Gastric and other upper abdominal malignancies have a propensity to metastasize to these nodes. Presence of hard and enlarged nodes in the left supraclavicular fossa is historically described as Troisier sign and is suggestive of abdominal malignancy¹³ (►Fig. 1).

Radiological Anatomic Mapping

On cross-sectional imaging, most nodal stations can be identified by accompanying vascular pedicles. ►Fig. 2 shows the locations of the nodal stations on diagrams and ►Figs. 3–18 demonstrated the nodal stations on contrast-enhanced CT (►Figs. 2–18).

Lymph Node Morphology

Lymph nodes are considered pathological when

- Perigastric nodes (stations 1–6) with short axis diameter >6 mm
- Extra-perigastric nodes (stations 7, 8, 9, and 11) with short axis diameter >8 mm
- Lymph nodes with rounded or irregular shape
- Absent fatty hilum
- Heterogeneous enhancement

Types of Surgery and Nodal Resection

Complete surgical resection of the tumor and draining nodes with a negative resection margin is the only curative treatment for gastric carcinoma. The primary objective of surgery is to excise the primary tumor with clear longitudinal and circumferential resection margin of at least 5 cm (R0 resection), adjacent organ resection as required, resection of associated lymph nodes, and then safely restoring intestinal and biliary continuity. Various types of surgical resection are performed based on the size and location of the primary tumor.

Types of Gastrectomy

- Total gastrectomy, for diffuse tumors, large distal tumors, and the tumor involving body or lesser curvature of stomach
- Esophagogastrectomy for tumors involving cardia and gastroesophageal junction (with epicenter located greater than 2 cm into the proximal stomach)
- Distal subtotal gastrectomy for tumors limited to distal stomach
- Proximal gastrectomy with transhiatal excision of lower mediastinal lymph node (below the level of inferior

Table 2 Gastric nodal stations (Japanese Gastric Cancer Association)

Station	Lymph nodes	Location	
1	Right paracardial nodes	Along the first branch of the ascending limb of the left gastric artery	
2	Left paracardial nodes	Along the esophagocardiac branch of the left subphrenic artery	
3	Nodes along lesser curvature	3a	Along the branches of the left gastric artery
		3b	Along second branch and distal part of the right gastric artery
4	Nodes along the greater curvature	4sa	Along short gastric arteries in perigastric region
		4sb	Left greater curvature LNs along the left gastroepiploic artery (perigastric area)
		4d	Right greater curvature LNs along the second branch and distal part of the right gastroepiploic artery
5	Suprapyloric nodes	Along the first branch and proximal part of the right gastric artery	
6	Infrapyloric nodes	Along the first branch and proximal part of the right gastroepiploic artery down to the confluence of the right gastroepiploic vein and the anterior superior pancreaticoduodenal vein	
7	Nodes along the left gastric artery	LNs along the trunk of left gastric artery between its root and the origin of its ascending branch	
8	Nodes along the common hepatic artery	8a	Anterosuperior nodes along the common hepatic artery
		8p	Posterior nodes along common hepatic artery
9	Nodes around celiac axis	Along the celiac trunk	
10	Splenic hilar nodes	Nodes in splenic hilum along the splenic artery, distal to the pancreatic tail, nodes on the roots of short gastric arteries, and nodes along the left gastroepiploic artery proximal to first gastric branch	
11	Nodes along the splenic artery	11p	Proximal splenic artery LNs from its origin to halfway between its origin and the pancreatic tail end
		11d	Distal splenic artery LNs from halfway between its origin and the pancreatic tail end to the end of the pancreatic tail
12	Nodes in the hepatoduodenal ligament	12a	The proper hepatic artery, in the caudal half between the confluence of the right and left hepatic ducts and the upper border of the pancreas
		12b	Along the bile duct, in the caudal half between the confluence of the right and left hepatic ducts and the upper border of the pancreas
		12p	Along the portal vein in the caudal half between the confluence of the right and left hepatic ducts and the upper border of the pancreas
13	Nodes at posterior aspect of head of pancreas	Nodes on posterior surface of the pancreatic head cranial to the duodenal papilla	
14	Nodes at the root of mesentery	14v	Nodes along superior mesenteric vein
		14a	Nodes along superior mesenteric artery
15	Nodes in the mesocolon of the transverse colon	Nodes along the middle colic vessels	
16	Para-aortic lymph nodes	16a1	Nodes in the diaphragmatic aortic hiatus
		16a2	Between upper margin celiac artery origin and the lower border of left renal vein
		16b1	Between lower border of left renal vein and upper border of the inferior mesenteric artery origin
		16b2	Between upper border of the origin of inferior mesenteric artery and aortic bifurcation
17	LNs on the anterior surface of the pancreatic head beneath the pancreatic sheath		
18	LNs along the inferior border of the pancreatic body		
19	Infradiaphragmatic LNs predominantly along the subphrenic artery		
20	Paraesophageal LNs in the diaphragmatic esophageal hiatus		
110	Paraesophageal LNs in the lower thorax		
111	Supradiaphragmatic LNs separate from the esophagus		
112	Posterior mediastinal LNs separate from the esophagus and the esophageal hiatus		

Abbreviation: LN, lymph node.

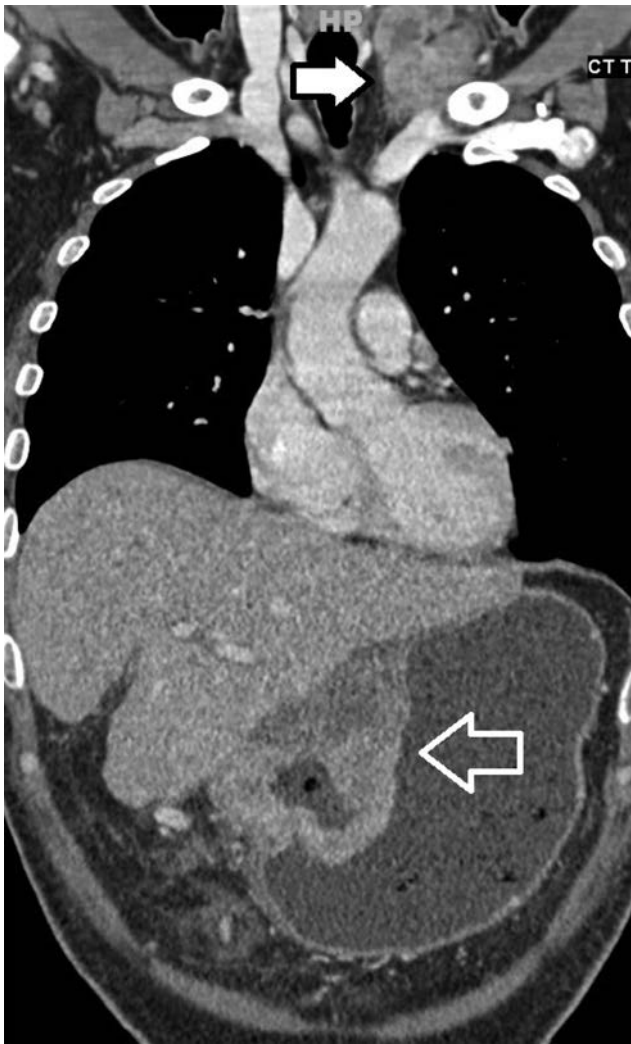


Fig. 1 Virchow node. Coronal reformatted contrast enhanced computed tomography of thorax and upper abdomen showing large tumor in the lesser curvature of stomach (open arrow). Left supraclavicular fossa shows a lobulated heterogeneously enhancing nodal mass (solid arrow).

pulmonary vein) for gastroesophageal junction tumor infiltrating less than 3 cm into the lower esophagus.¹⁴

Types of Lymphadenectomy

D1 lymphadenectomy is when all N1 nodes (perigastric nodes closest to the primary tumor) are removed en bloc with the stomach and D2 lymphadenectomy is when all N1 and N2 (distant perigastric nodes and nodes along main arteries supplying stomach) are systematically removed en bloc with stomach. Since gastric cancer commonly remains localized to stomach and adjacent lymph nodes, D2 lymphadenectomy has a survival benefit. Overall, D2 has lower locoregional recurrence and gastric cancer-related death rates, but it has higher postoperative mortality, morbidity, and reoperation rates compared with D1 surgeries.¹⁵ Originally, to ensure full nodal clearance along the splenic artery, a routine en bloc resection of spleen and distal pancreas used to be performed. But spleen preserving D2 resection technique is currently performed in most higher centers as it can reduce morbidity significantly. According to Sano et al total gastrectomy for proximal tumors which has not involved greater curvature of stomach, splenectomy should be avoided.² The extent of D1 and D2 resection is given below.

(A) Total gastrectomy

D0: Any lymphadenectomy less than D1

D1: Stations 1–7

D1+: D1 + stations 8a, 9, 11p

D2: D1 + Stations 8a, 9, 10, 11p, 11d, 12a

For tumors invading the esophagus: D1+ includes 110 and D2 includes 19, 20, 110, and 111.

(B) Distal gastrectomy

D0: Any lymphadenectomy less than D1

D1: Stations 1, 3, 4sb, 4d, 5, 6, 7

D1+: D1 + stations 8a, 9

D2: D1 + stations 8a, 9, 11p, 12a

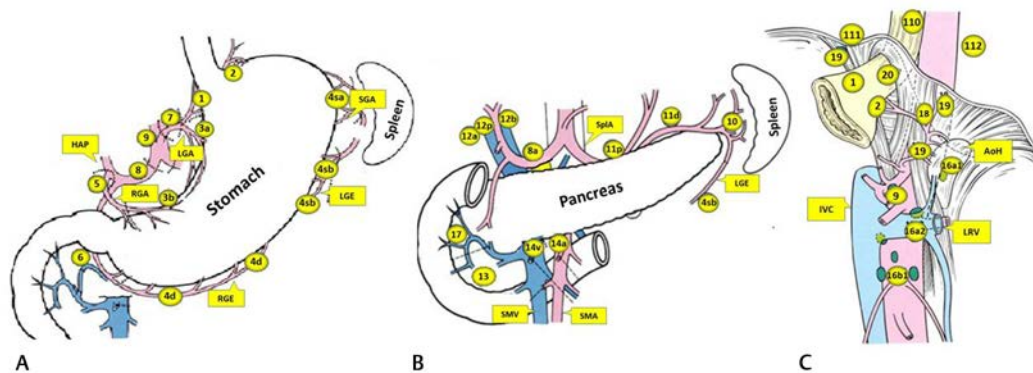


Fig. 2 Line diagram showing gastric nodal stations. (A) Perigastric nodes. (B) Perigastric and regional nodes with the stomach removed to reveal the pancreas. (C) Nodes along the G-E junction, aorta and diaphragmatic hiatus. See ►Table 2 for number keys. AoH, aortic hiatus of diaphragm; HAP, hepatic artery proper; LGA, left gastric artery; LGE, left gastroepiploic artery; LRV, left renal vein; RGA, right gastric artery; RGE, right gastroepiploic artery; SMA, superior mesenteric artery; SMV, superior mesenteric vein; SplA, splenic artery.

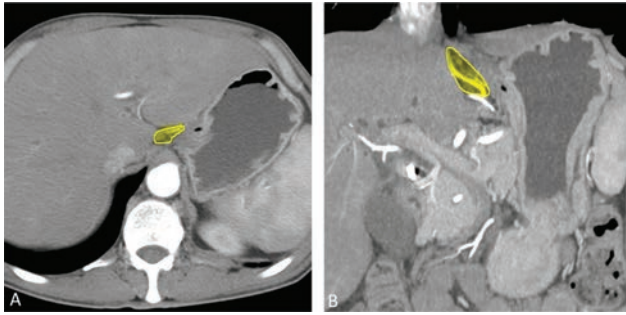


Fig. 3 Station 1. Axial (A) and coronal (B) reformatted contrast enhanced computed tomography images in arterial phase showing first branch of ascending limb of left gastric artery (yellow area) along which station 1 nodes are expected in right paracardial location.

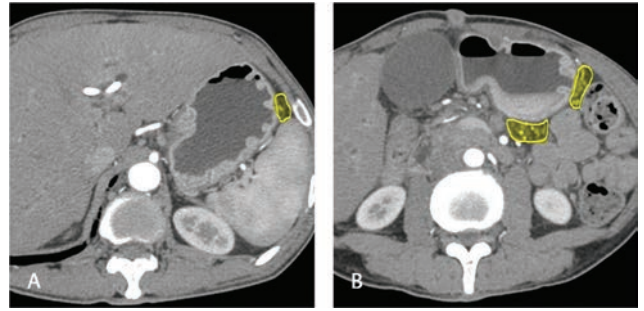


Fig. 6 Station 4. Axial computed tomography images in arterial phase depict short gastric arteries (yellow area in A), left and right gastroepiploic arteries along the greater curvature of stomach (yellow area in B) which is the location for station 4 gastric nodes.

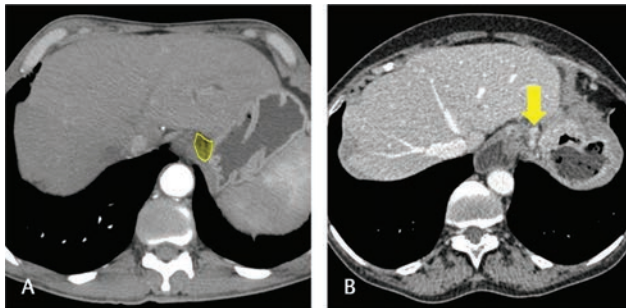


Fig. 4 Station 2. Axial computed tomography images in arterial (A) and venous (B) phase. The esophagogastric branch of left subphrenic artery (yellow area) is seen in (A) along which lie the left paracardial nodes (yellow arrow in B). Gastric wall thickening can also be seen in (B).

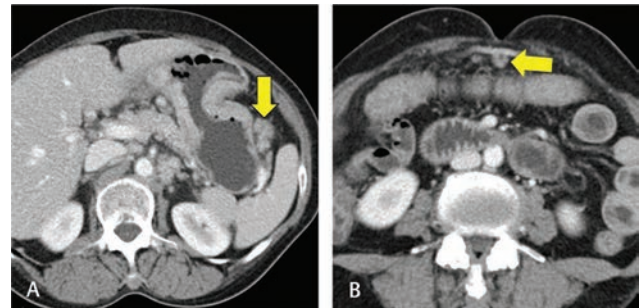


Fig. 7 Station 4d/4sa. Axial computed tomography images in venous phase (A) and (B) show enlarged lymph nodes along short gastric arteries (station 4sa, arrow in A) and right gastroepiploic artery (station 4d, arrow in B).

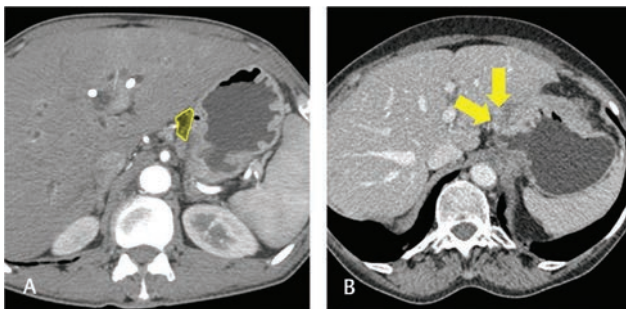


Fig. 5 Station 3. Axial computed tomography images in arterial (A) and venous (B) phase. Station 3 location (yellow area) is depicted in figure (A) along the left gastric artery branches and distal part of right gastric artery and its second branch, along the lesser curvature of stomach. Figure (B) shows few lesser curvature nodes (arrows). Gastric wall thickening can also be seen in (B).

Nodal mapping in CT – What the Surgeon Wants to Know

- T-status of the tumor; location, relation with the surrounding structures
- Presence of enlarged or suspicious lymph node in perigastric area
- Presence of enlarged or suspicious lymph nodes in para-aortic, aortocaval, mediastinal, and left supraclavicular nodes
- Comparison of pre- and postchemotherapy nodal burden before surgery

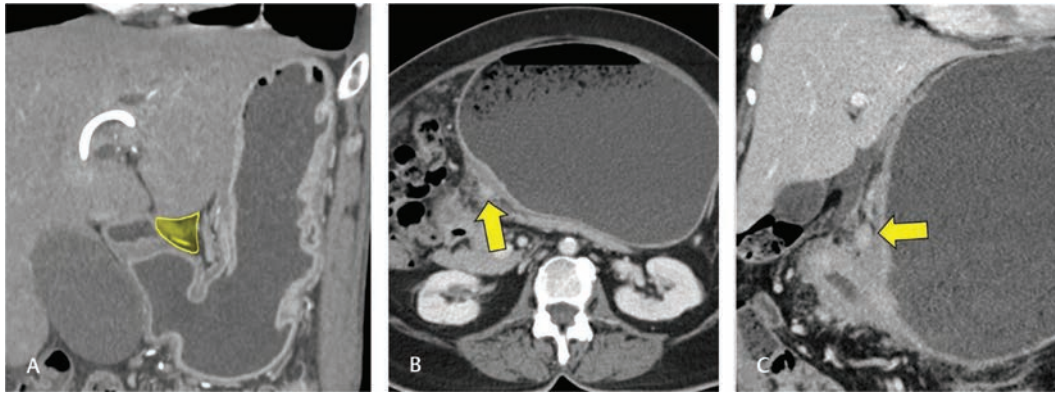


Fig. 8 Station 5. Coronal reformatted CT in arterial phase (A) depicts the suprapyloric region (yellow area in A) with proximal part of right gastric artery along which lie the station 5. Axial and coronal reformatted CT (B) and (C) in venous phase shows suprapyloric nodes (arrow) and pyloric wall thickening. CT, computed tomography.

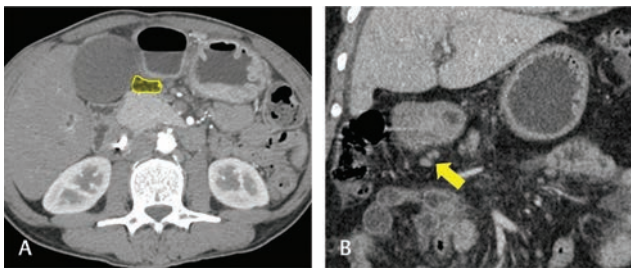


Fig. 9 Station 6. Axial CT (A) shows the region of station 6 nodes along first branch and proximal part of right gastroepiploic artery (yellow area in A). Coronal reformatted CT (B) in venous phase shows few prominent infrapyloric nodes (arrow in B). CT, computed tomography.

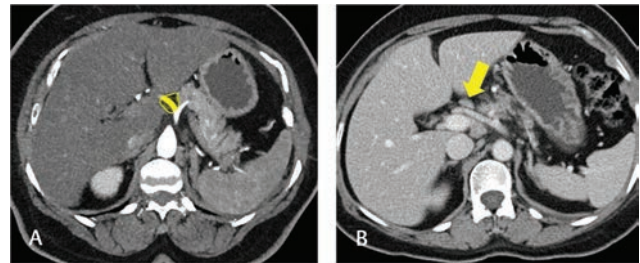


Fig. 11 Station 8. Axial CT (A) in arterial phase depicts the station 8 location along the common hepatic artery (yellow area in A). Axial CT (B) in venous phase show station 8 nodes (arrow in B). CT, computed tomography.

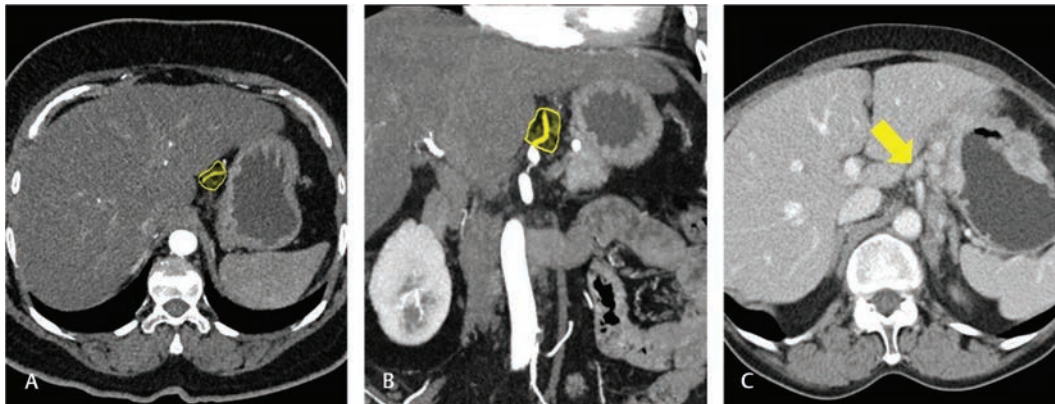


Fig. 10 Station 7. Axial and coronal reformatted CT (A) and (B) in arterial phase showing origin and proximal left gastric artery along which lie station 7 nodes (yellow area in A and B). Axial CT in venous phase show multiple left gastric nodes (arrow in C). CT, computed tomography.

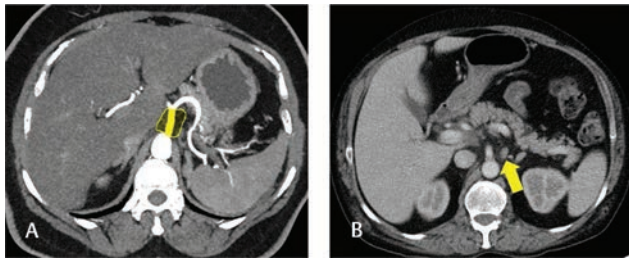


Fig. 12 Station 9. Axial CT (A) in arterial phase shows the celiac trunk along which lie the station 9 (yellow area in A). Axial CT (B) in venous phase shows a small celiac node in a patient with known gastric carcinoma (arrow in B). CT, computed tomography.

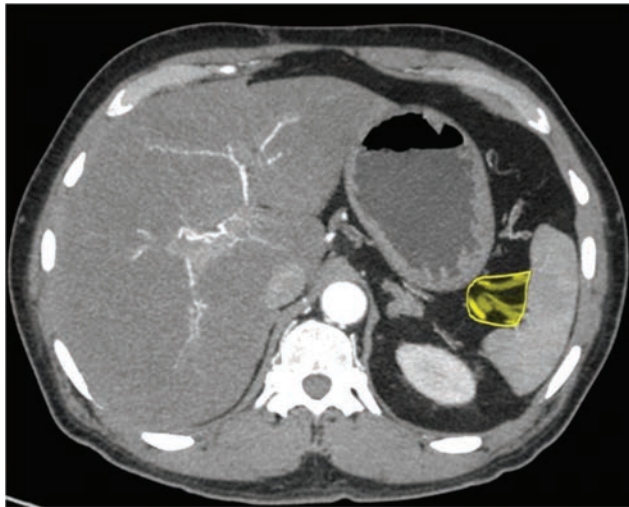


Fig. 13 Station 10. Axial computed tomography in arterial phase depicts the station 10 location at splenic hilum (yellow area). When involved, it may require splenectomy.

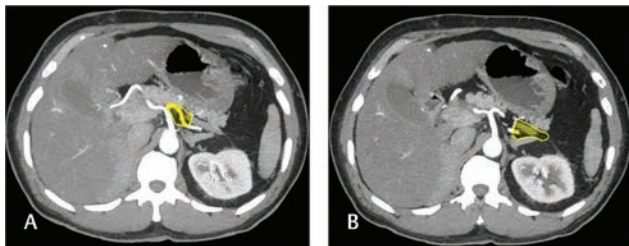


Fig. 14 Station 11. Axial computed tomography (A) and (B) in arterial phase show station 11 location along proximal (A) and distal (B) splenic artery, that is, station 11p and 11d, respectively.

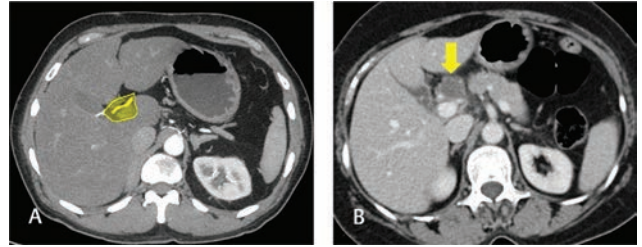


Fig. 15 Station 12. Axial CT (A) in arterial phase demarcates station 12: the hepatoduodenal ligament nodes along proper hepatic artery (12a), bile duct (12b), and portal vein (12p) (yellow area in A). Axial CT (B) in venous phase shows a necrotic station 12 node (arrow in B), likely involving the hepatic artery proper, hence unresectable. CT, computed tomography.

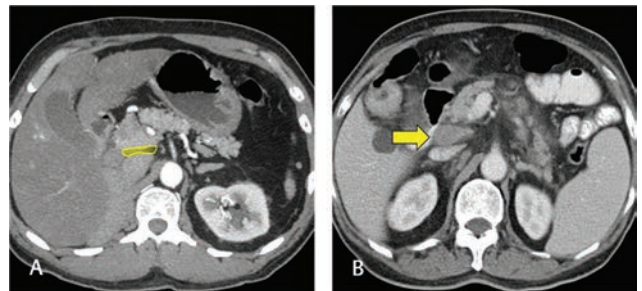


Fig. 16 Station 13. Axial CT (A) in arterial phase depicts the station 13 location, the retropancreatic nodes, on posterior surface of pancreatic head cranial to duodenal papilla (yellow area in A). Axial CT (B) in venous phase shows an enlarged station 13 node, sometimes also referred to as posterosuperior pancreaticoduodenal node. If surgery is planned, it requires kocherization of duodenum for its resection. CT, computed tomography.

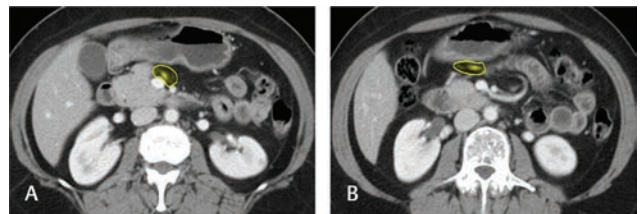


Fig. 17 Stations 14 to 15. Axial computed tomography depicts the location of station 14v (A) along superior mesenteric vein and station 15 (B) along middle colic vessels.

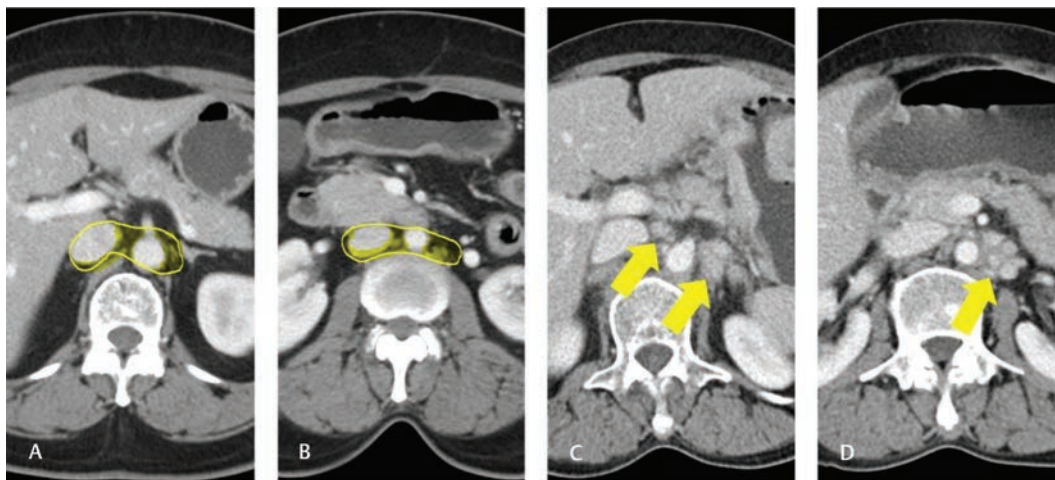


Fig. 18 Station 16. Axial CT images (A) and (B) depicts station 16 location which encompass the retroperitoneal nodes in gastric cancer (yellow area in A and B). Axial CT image (C) shows enlarged retroperitoneal nodes and (D) shows small but multiple retroperitoneal nodes raising suspicion for metastatic involvement. CT, computed tomography.

Funding

None.

Conflict of Interest

None declared.

References

- 1 Ferlay J, Soerjomataram I, Dikshit R, et al. Cancer incidence and mortality worldwide: sources, methods and major patterns in GLOBOCAN 2012. *Int J Cancer* 2015;136(5):E359–E386
- 2 Sano T, Sasako M, Mizusawa J, et al; Stomach Cancer Study Group of the Japan Clinical Oncology Group. Randomized controlled trial to evaluate splenectomy in total gastrectomy for proximal gastric carcinoma. *Ann Surg* 2017;265(2):277–283
- 3 Hochwald SN, Kim S, Klimstra DS, Brennan MF, Karpeh MS. Analysis of 154 actual five-year survivors of gastric cancer. *J Gastrointest Surg* 2000;4(5):520–525
- 4 Kim DY, Seo KW, Joo JK, et al. Prognostic factors in patients with node-negative gastric carcinoma: a comparison with node-positive gastric carcinoma. *World J Gastroenterol* 2006;12(8):1182–1186
- 5 Gunji Y, Suzuki T, Hori S, et al. Prognostic significance of the number of metastatic lymph nodes in early gastric cancer. *Dig Surg* 2003;20(2):148–153
- 6 Ichikura T, Tomimatsu S, Okusa Y, Uefuji K, Tamakuma S. Comparison of the prognostic significance between the number of metastatic lymph nodes and nodal stage based on their location in patients with gastric cancer. *J Clin Oncol* 1993;11(10):1894–1900
- 7 Amin MB, Edge S, Greene F, et al, eds. *AJCC Cancer Staging Manual*. 8th ed. New York: Springer; 2017
- 8 Roukos DH, Kappas AM. Perspectives in the treatment of gastric cancer. *Nat Clin Pract Oncol* 2005;2(2):98–107
- 9 Sasako M, McCulloch P, Kinoshita T, Maruyama K. New method to evaluate the therapeutic value of lymph node dissection for gastric cancer. *Br J Surg* 1995;82(3):346–351
- 10 Al-Batran S-E, Homann N, Pauligk C, et al; FLOT4-AIO Investigators. Perioperative chemotherapy with fluorouracil plus leucovorin, oxaliplatin, and docetaxel versus fluorouracil or capecitabine plus cisplatin and epirubicin for locally advanced, resectable gastric or gastro-oesophageal junction adenocarcinoma (FLOT4): a randomised, phase 2/3 trial. *Lancet* 2019;393(10184):1948–1957
- 11 Roviello F, Rossi S, Marrelli D, et al. Number of lymph node metastases and its prognostic significance in early gastric cancer: a multicenter Italian study. *J Surg Oncol* 2006;94(4):275–280, discussion 274
- 12 Japanese Gastric Cancer Association. *Japanese classification of gastric carcinoma: 3rd English edition*. *Gastric Cancer* 2011;14(2):101–112
- 13 Som PM, Curtin HD, Mancuso AA. Imaging-based nodal classification for evaluation of neck metastatic adenopathy. *AJR Am J Roentgenol* 2000;174(3):837–844
- 14 Kumamoto T, Kurahashi Y, Niwa H, et al. True esophagogastric junction adenocarcinoma: background of its definition and current surgical trends. *Surg Today* 2020;50(8):809–814
- 15 Songun I, Putter H, Kranenbarg EM-K, Sasako M, van de Velde CJH. Surgical treatment of gastric cancer: 15-year follow-up results of the randomised nationwide Dutch D1D2 trial. *Lancet Oncol* 2010;11(5):439–449