



Symbrachydactyly

Govindasamy Balakrishnan¹ S. Vijayaragavan² Balakrishnan Somesh²

¹The Tamilnadu Dr. MGR Medical University, Chennai, India

²Department of Plastic, Hand and Microsurgery, Right Hospitals, Kilpauk, Chennai, India

Address for correspondence Balakrishnan Govindasamy, MS, MCh, FRCS, DSc (Hon), Department of Plastic, Hand & Microsurgery, Right Hospitals, Kilpauk, Chennai, India (e-mail: gbrighthospitals@gmail.com).

Indian J Plast Surg 2022;55:7–17.

Abstract

Keywords

- ▶ congenital hand
- ▶ symbrachydactyly
- ▶ free phalangeal transfer
- ▶ toe transfer
- ▶ Poland syndrome
- ▶ thumb web release
- ▶ square flap

Symbrachydactyly is a rare congenital hand malformation in which a child is born with abnormally short digits that may be webbed, misshaped, or missing, and it is usually a unilateral condition. There is no standardized treatment algorithm for the management of symbrachydactyly. The function of the hand is often not adequate and requires early surgical intervention to restore useful prehension and appearance. This CME article presents a brief review of the embryology, history, classification and clinical presentation, and author's experience of treating 19 children with symbrachydactyly over 10 years. Creation of thumb web, lengthening of thumb, and creating an opposition post results in prehension of hand with an improved quality of life.

Introduction

Symbrachydactyly is a rare congenital hand difference with an incidence of approximately 1 in 32,000 live births. It was once considered a form of a cleft hand and termed atypical cleft hand due to central ray deficiency, which is usually bilateral and often associated with cleft feet.¹

These hands do not represent a terminal failure of formation. It is usually a unilateral pathology, characterized by failure of complete formation of the fingers, and present as rudimentary “nubbins” containing elements of the nail plate, bone and cartilage. Typically, the central digits are absent, the border digits are relatively spared, and syndactyly may be present. The child often presents with short, webbed digits.

There is little evidence to show that symbrachydactyly is due to a genetic defect or passed from one generation to another. It is caused by vascular dysgenesis during fetal development, with interruption of the subclavian artery distal to the internal thoracic artery and a decrease in blood flow in the affected limb before the gestational age of 42 days.

Presentation

Symbrachydactyly usually occurs as an isolated hand difference. Clinical presentations are varied but always include short fingers. The underlying defect is believed to be mesodermal, which explains the presence of remnants of the distal part of the fingers, namely, ectodermal tissue, pulp, nail folds, and nails. Symbrachydactyly can be associated with Poland syndrome, which is characterized by hypoplasia, or absence, of the sternal head of pectoralis major (–Fig. 1).

Children with symbrachydactyly may have one, or more, of the following:

1. Short fingers in which some bones are smaller than normal or missing. Commonly, the middle phalanges are either hypoplastic or absent.
2. The fingers that are joined together or webbed—syndactyly.
3. Nubbins of skin and soft tissues where the fingers would be.

published online
November 2, 2021

DOI <https://doi.org/10.1055/s-0041-1734579>.
ISSN 0970-0358.

© 2021. Association of Plastic Surgeons of India. All rights reserved. This is an open access article published by Thieme under the terms of the Creative Commons Attribution-NonDerivative-NonCommercial-License, permitting copying and reproduction so long as the original work is given appropriate credit. Contents may not be used for commercial purposes, or adapted, remixed, transformed or built upon. (<https://creativecommons.org/licenses/by-nc-nd/4.0/>)
Thieme Medical and Scientific Publishers Pvt. Ltd., A-12, 2nd Floor, Sector 2, Noida-201301 UP, India

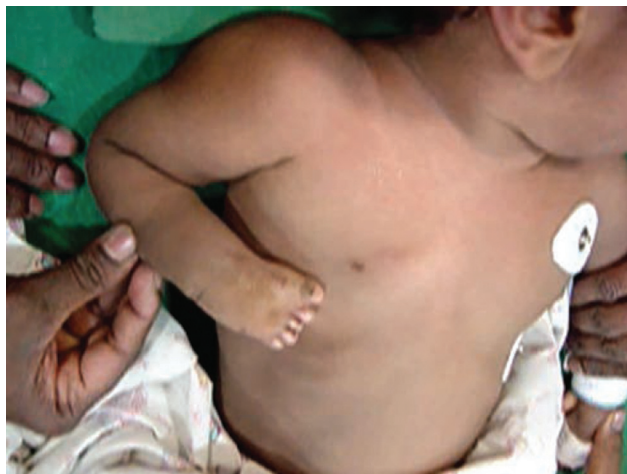

Fig. 1 Symbrachydactyly-associated Poland syndrome.

4. A short hand with gaps, that is, absence of central metacarpals.
5. A short forearm.

Most children with symbrachydactyly have a normal thumb, but the first web contracture is a constant. The hand may not function well, and the bones, muscles, ligaments, and nerves are also often affected.

Radiological Examination

1. Antenatal ultrasonogram—Congenital hand differences are diagnosed more effectively with high-frequency ultrasonogram antenatally.
2. Radiograph—Postnatal X-ray identifies the presence or absence of bones.
3. MRI—postnatal MRI of finger nubbins will identify the soft-tissue abnormalities.

Classification

The International Federation of Societies for Surgery of the Hand (IFSSH) has recently adopted the Oberg, Manske and Tonkin (OMT) classification system, which is based on embryology and molecular biology. Previously characterized as an undergrowth, in the OMT system, symbrachydactyly is characterized as the failure of formation of the proximal-distal axis, which can involve the entire upper limb or the hand plate only. Blauth classification system for symbrachydactyly includes four phenotypes.²

1. The short-finger type, characterized by the presence of a thumb and four coalesced stiff digits, which may have one or more missing phalanges within these digits.
2. The oligodactylic or “atypical cleft hand” type, characterized by a central aplasia of digits, with thumb and fifth digit present.
3. The monodactylic type, characterized by the presence of a thumb and four associated digital remnants.
4. The peromelic type, characterized by a complete absence of all digits at the metacarpal level.

Table 1 Symbrachydactyly types based on radiologic pattern on skeletal reduction

The triphalangia type, characterized by a hand with no missing bones, even though many phalanges (usually the middle phalanx) may be short
The biphalangia type, characterized by one or more missing phalanges in one or more digits
The monophalangia type, characterized by the presence of a thumb and one or more digits containing only one phalanx
The aphyalangia type, characterized by the presence of a thumb and digital nubbins with no phalanges
The ameta-carpia type, characterized by absence of the thumb and digits and absence of one or more metacarpals
The acarpia type, characterized by the absence of all digits and thumb and one or more carpal bones
The forearm amputation type, characterized by absence of the distal portion of the forearm with small rudimentary nubbins on the amputation stump

Yamauchi and Tanabu (► **Table 1**) described a classification that included seven types of symbrachydactyly, based on examination and imaging. This classification does not provide guidance for treatment.³ Foucher modified the Blauth classification to make it more useful in respect of treatment (► **Table 2**).⁴

Authors Series

Nineteen children with symbrachydactyly underwent surgical management in our institute over a period of 10 years. Eighteen were unilateral and one was bilateral. There were sixteen male and three female children. Of the unilateral cases, seven were on the right side and eleven on the left, indicating left-side dominance. These children usually underwent surgery between the ages of 1 and 3 years. The children were followed-up for a period of 8 to 10 years.

Treatment Goals

The goals of reconstruction are to improve the appearance and function of the hand. Selection of specific treatments for symbrachydactyly depends on the clinical presentation and radiological findings. The outcomes depend on the existing hand differences. The family must be counselled for accepting the outcome.

Nonoperative Management

1. Physiotherapy—performed till the child and the parents can understand the problem and give their consent for the surgery.
 - (a) Stretching of the thumb web.
 - (b) Mobilization of stiff fingers both active and passive.
2. Occupational therapy.

Provision of splints and prosthesis for opposition post. However, prosthesis cannot provide sensation; hence, it is of limited value in children.

Table 2 Foucher's classification

Type	Features	Thumb	Ulnar digit	Interventions
I	All bones and digits present, brachydactyly and syndactyly	Normal	Bones present, brachydactyly or syndactyly	Syndactyly release
II A	> 2 fingers. Normal thumb, hypoplastic fingers	Normal	Hypoplastic, syndactyly	Nonvascularized toe phalanx transfers, ablation or stabilization
II B	Functional border digits, variable central nubbins	Normal	Present, variable hypoplasia and stability	Surgery rarely indicated
II C	"Spoon hand" thumb conjoined with hypoplastic ulnar digits	Present ± stability	Hypoplastic, clinodactyly	Variable
III A	Monodactyly	Normal	Absent	Vascularized toe-to-hand transfer
III B	Monodactyly	Hypoplastic and/or unstable	Absent	Variable, vascularized toe-to-hand transfer, thumb stabilization, thumb lengthening
IV A	Peromelic, wrist mobility	Absent	Absent	Vascularized toe to hand transfer
IV B	Peromelic, no wrist mobility	Absent	Absent	Surgery not indicated

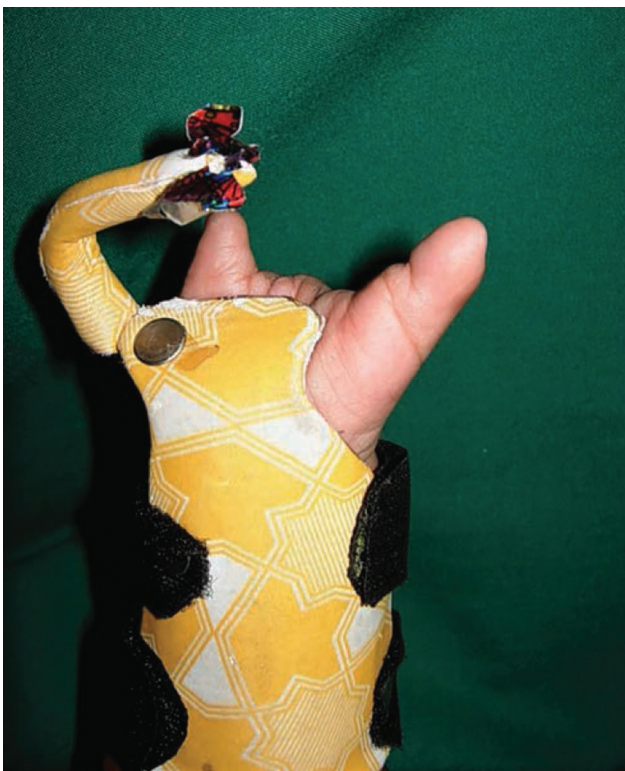

Fig. 2 An opposition paddle provided by the occupational therapist helps these children with monodactyly to practice opposition movement. A future toe transfer later will help this child to perform grasp and prehension.

Opposition paddles may be helpful in patients with monodactyly, because they provide a surface against which they can pinch (► **Fig. 2**). Targeted muscle reinnervation (TMR) and regenerative peripheral nerve interface (RPNI) may become useful to children with the pleomorphic type of

Table 3 Components of a symbrachydactyly reconstruction

Excision of rudimentary nubbins
Formation or preservation of a mobile, unscarred thumb with stable joints
Formation or preservation of a broad first web space
Maintenance of a thumb and at least one digit with sensation
Formation or preservation of an intact fifth ray with MCP joint motion and stability
Separation of digital syndactylies
Preservation of digital proximal interphalangeal joint motion in triphalangeal digits and MCP joint motion in biphalangeal digits

Abbreviations: MCP, metacarpophalangeal.

symbrachydactyly or transverse arrest at later stage of development.

3D printing of the hand may be useful in preparing light-weight hand prosthesis, which can be customized as the child grows.

Surgical Interventions

Symbrachydactyly is a spectrum of deficiencies from short, or absent, middle phalanges through absent metacarpals to absence of the entire hand. Treatment is variable and depends on the degree of digital suppression.

The aim of surgical treatment is toward improving function and aesthesis. The various surgical components are enlisted in ► **Table 3**. Reconstruction is oriented to achieve basic requirements for manipulation of objects such as creation of a radial post, an ulnar post, and an adequate web space.

Stability of the posts should be achieved and at least one of them should be mobile. Once this target is achieved, then further enhancement is planned by separating the digits, increasing length, and improving mobility.

It is not possible to draw a surgical algorithm for the management of symbrachydactyly, since planning has to be customized, according to availability of local tissues and the extent of deficiency. The presence of transverse bones and abnormal articulations also influence the planning. The types of presentations, surgical procedures, and the outcome obtained in our clinical experience has been tabulated in ► **Table 4**. It is also not possible to compare the functional outcome of various procedures, because of the absent phalanges, varying degree of hypoplasia, and limited mobility of existing digits.

Different surgical interventions planned in the management of symbrachydactyly are listed below. Planning and sequencing of surgeries have to be individualized, according to the need of the child.

1. Thumb web contracture release and lengthening of the thumb.
2. Creation of an opposition or ulnar post.
3. Release of syndactyly between the short fingers.
4. Lengthening of brachydactyly.
5. Free phalangeal transfer with digital augmentation manoplasty.
6. Microvascular toe transfer.

First Web Contracture Release and Lengthening of the Thumb

In symbrachydactyly, first web contractures are treated to improve the grasp span, appearance, and function of the thumb. When all the metacarpals are present and the phalanges are not present or replaced with nubbins, the simplest option is to deepen the first web and lengthen the thumb to create some form of crude pinch against the palm or an available phalanx or nubbins.

We have used various surgical procedures to release the first web.

1. Multiple Z-plasties.
2. Dorsal rotation flap.
3. Groin flap.
4. Square flap.
5. Omega flap.

Z-Plasties

Multiple Z-plasties in sequence will achieve the maximum release, but lengthening of the thumb is inadequate. It is often used to lengthen the short thumb by deepening the thumb web.

Dorsal Rotation Flaps

When there is tightness of the adductor pollicis muscle in addition to skin contracture, a dorsal rotation flap is planned. Through the same skin incision, the adductor pollicis insertion is released and the flap is rotated into the webspace. The donor defect can either be closed primarily or, occasionally, the skin is grafted (► **Fig. 3A-E**).

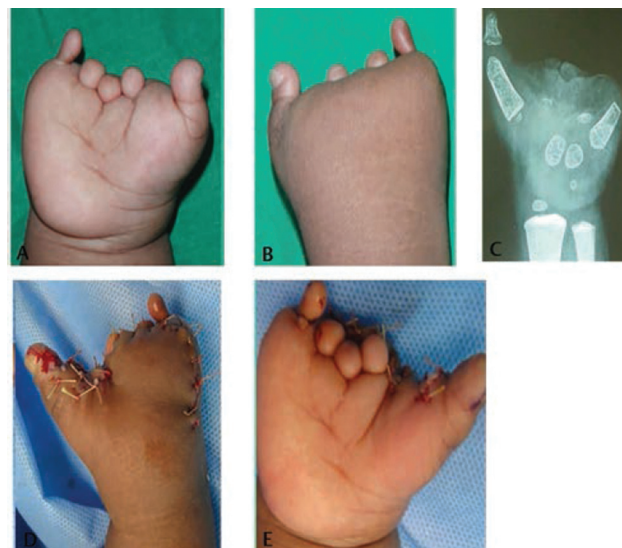

Fig. 3 A child with oligodactyly type of symbrachydactyly with a narrow thumb web. (A) Volar view. (B) Dorsal view. (C) X-ray. (D) Thumb web creation by dorsal transposition flap. (E) Adequate thumb web after surgery.

The dorsal rotation flap can only be planned when all the metacarpals are present, and the dorsum has adequate width. In the absence of few metacarpals, the dorsal width is narrowed, and a rotation flap cannot be performed.

Groin Flaps

Symbrachydactyly with a narrow first web and no available local tissue is reconstructed with a distant flap, such as groin flap, following web release. A vertical skin incision is used to separate the first and second metacarpals and release the insertion of the adductor pollicis muscle. The groin flap is an exceptionally effective procedure under these circumstances (► **Fig. 4A, B, C**). When there is a complex musculoskeletal contracture, such as present of transverse bone, abnormal articulations in carpometacarpal joint, or tight adductor muscles, release and groin flap will be the once choice. The disadvantage is the bulkiness of the flap.

Square Flaps

The square flap, introduced by Prof. Hiko Hyakusoku, is a better option for release of first web and simultaneous lengthening of the thumb (► **Fig. 5A, B**). The release of web contracture will be nearly twice that of a single Z-plasty, resulting in better widening of the thumb web and lengthening of the thumb. It incorporates an advancing square, which breaks the linear contracture band, with two triangle flaps rotating from the opposite side into the lateral defects (► **Video 1**).

Video 1

Square flap animation—video. Online content including video sequences viewable at: <https://www.thieme-connect.com/products/ejournals/html/10.1055/s-0041-1734579>.

Table 4 Clinical presentation and surgical management

PT. ID	Symbrachydactylsubtype	Sex and age at presentation	Surgical intervention	Outcome
A	Oligodactyly Right hand Narrow thumb web	F/1 year	Thumb web release by dorsal transposition flap	Adequate web release obtained
B	Short-finger type Left hand Thumb normal All fingers short with absent middle phalanges	M/10 years	Distraction Osteogenesis of proximal phalanges of all fingers	Lengthening of fingers was useful to improve function
C	Oligodactyly Left hand Thumb normal Index and mid absent	M/2 years	Syndactyly release—ring and little fingers—omega flap	Tripod pinch achieved
D	Peromelic Left hand Unstable thumb Absent fingers	M/1 year	Free phalangeal transfer to stabilize unstable thumb	Child uses the stable thumb to oppose palm to hold objects. Will require double toe transfer to enhance prehension
E	Oligodactyly type Narrow thumb web Right hand	F/1 year	Thumb web reconstruction with a dorsal transposition flap	Adequate thumb web release obtained
F	Symbrachydactyly Absent thumb web with transversely placed second metacarpal Absent index Left hand	M/2 years	Thumb web release Excision of transverse metacarpal Groin flap cover	Opposition achieved between released thumb and syndactylized ulnar post
G	Peromelic type Left hand Absent thumb Finger nubbins	M/1 year	1. Free phalangeal transfer for little finger nubbin—15 months 2. Toe-to-hand transfer for thumb reconstruction—4 years	Child can perform hook grip using the reconstructed digits and manipulate objects
H	Oligodactyly Narrow thumb web Left hand	M/2 years	Thumb web release by square flap technique	Adequate release of thumb web achieved
I	Oligodactyly Narrow thumb web Left hand	M/1 year	Thumb web reconstruction with omega flap technique	Adequate thumb web obtained. Child will need further procedures to release finger syndactyly
J	Oligodactyly type Inadequate thumb web Absent index Right hand	M/9 months	1. Syndactyly release little and ring using omega flap technique + square flap for thumb web deepening 2. Syndactyly release middle and ring fingers using omega flap	Adequate thumb web and three useful digits achieved after reconstruction. Able to use hand with tripod pinch
K	Oligodactyly Bilateral – Thumb and thumb web normal. Rest of the fingers syndactylized	F/3 months	1. Syndactyly release of marginal fingers—omega flap technique—9 months—both hands 2. Syndactyly release of index and mid—both hands—omega flap technique—2 years	Adequate release of all fingers achieved
L	Oligodactyly Right hand	M/1 year	1. Syndactyly release—ring and little—1 year—omega flap	Tripod pinch obtained

(Continued)

Table 4 (Continued)

PT. ID	Symbrachydactylsubtype	Sex and age at presentation	Surgical intervention	Outcome
	Short thumb Index absent		Thumb web deepening by Z-plasty 2. Syndactyly release middle and ring finger—2 years Omega flap	
M	Oligodactyly Narrow thumb web Left hand	M/1.5 years	Thumb web release by square flap technique	Thumb web release adequate
N	Short-finger type Left hand Thumb and little finger normal Rest of the fingers short and syndactylized	M/6 months	1. Syndactyly release between index and middle fingers—9 months 2. Syndactyly release between middle and ring fingers—12 months 3. Distraction osteogenesis of proximal phalanges of index, middle and ring fingers to lengthen the fingers	Achieved stable long fingers of equal length. Improvement in appearance and function achieved. Child is now able to use computer keyboard fluently
O	Oligodactyly Narrow thumb web left hand	M/2 years	Thumb web release by square flap	Adequate web release obtained
P	Hole type of Symbrachydactyly Absent thumb web Adductor pollicis contracture Right Hand	M/1.5 years	Thumb web release; adductor muscle release Groin flap cover	Child was able to oppose the released thumb and touch the remaining fingers. Able to hold objects and manipulate
Q	Peromelic type Right hand Unstable thumb Finger nubbins	M / 6 months	Free phalangeal transfers to stabilize thumb and to stabilize ring and little finger nubbins	Child was able to oppose the stable thumb to the stable digits and hold objects
R	Peromelic type Left hand Stable thumb Finger nubbins	M/9 months	Free phalangeal transfer to middle and ring finger nubbins	Child was able to use Stable fingers for manipulation of objects
S	Monodactyly Right hand Short thumb Narrow thumb web	M/1 year	1. Thumb web release and thumb lengthening by square flap method 2. Rotational osteotomy of 1st metacarpal to bring the thumb into opposition and pronation 3. Second toe transfer to reconstruct ulnar post	Child was able to manipulate objects using hook grip. Able to hold a pen and write

In some of these children, the thumb lays in the same plane as the rest of the fingers. These children will require rotational osteotomy of the first metacarpal to bring thumb into opposition and pronation.⁵ We have performed this procedure in one child with monodactylous form of symbrachydactyly with short thumb.

Omega Flaps

The omega flap is another useful tool for release of the first web and, also, other webbed fingers. It has two components.

1. A truncated dorsal flap with a triangular tip at the level of the proximal interphalangeal (PIP) joint.

2. An anchor incision on the volar side, raising two triangular palmar flaps to cover the lateral surfaces of the base of the finger.⁶ This technique avoids web creep (→ Fig. 6A, B, C). Omega flap is a useful tool when the thumb is syndactylized to index, but only at skin level.

Creation of an Opposition or Ulnar Post

The creation of an opposition post is particularly important. Usually, the little finger is short with the absence of the middle phalanx. To create an ulnar post, a free phalangeal bone transfer can be used to lengthen the existing little finger. When there is aplasia of the digit, the only possible surgical option is a free vascularized toe transfer. When the thumb is short, longer toe

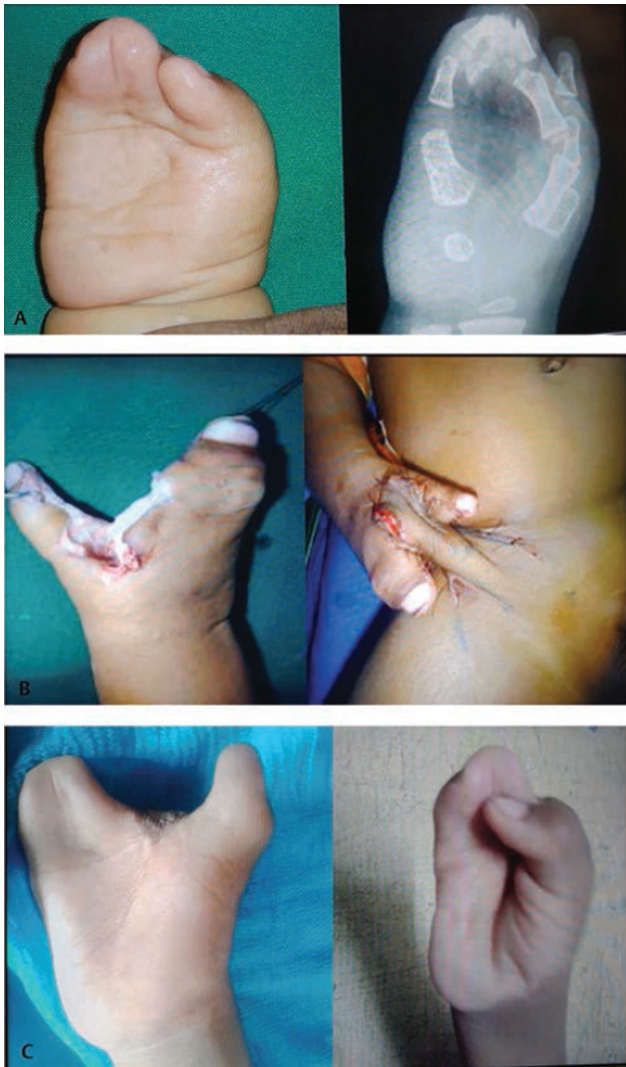

Fig. 4 (A) Child with symbrachydactyly along with a completely absent thumb web and no local tissue available in the hand for reconstruction. X-ray showing hole type of symbrachydactyly with absence of central metacarpals, (B) Thumb web released; adductor muscles released; adequate thumb web was created with a groin flap. (C) 5 years postoperative result showing good opposition; child is able to write holding a pen.

in place of the little finger will help with opposition. The ideal timing of surgery is at 2 to 3 years of age to allow for a reasonable size of vessel for microvascular anastomosis.

Syndactyly Release

Syndactyly release between the short digits is essential. It is done in stages. Index and little fingers need to be released early to avoid shortening of digits. Marginal fingers can be released as early as 6 months and the subsequent fingers released 6 months later.

When we have a child with first web contracture, syndactyly of the ulnar three fingers and an absent index finger at the metacarpophalangeal (MCP) joint level, staged reconstruction is planned. At the first stage, the first web is released along with the release of the syndactyly between the ring and little fingers. At the second procedure, 6 months

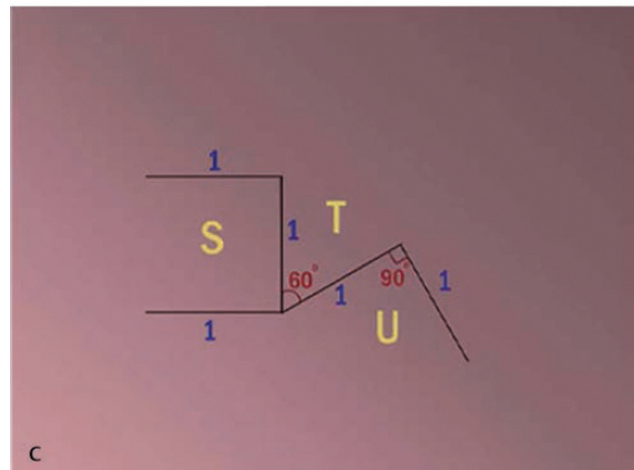
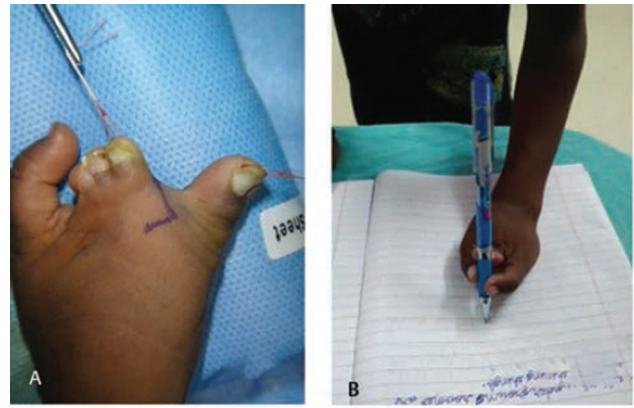


Fig. 5 (A) Child with oligodactyly along with a narrow thumb web— Illustration of the planning for a square flap to reconstruct the thumb web and lengthen the thumb. (B) Postoperative view result showing a longer thumb and ability to hold a pen using pincer grip between thumb and little finger. (C) Schematic representation of the square flap procedure. A square flap is planned on one side of the web and two triangular flaps are planned on the other side of the web. The first triangle has an angle of 60° and the second triangle has an angle of 90°.

later, the syndactyly between the middle and ring fingers is released (→Fig. 7A-D). In most of these cases, the middle phalanx is absent, or there is a very short middle finger with an intact terminal phalanx and nail complex. The postoperative video illustrates that good function has been achieved with the reconstructed hand (→Video 2).

Video 2

Postoperative functional status after syndactyly release. Online content including video sequences viewable at: <https://www.thieme-connect.com/products/ejournals/html/10.1055/s-0041-1734579>.

Lengthening of Brachydactyly

Distraction osteogenesis is useful to lengthen short digits.⁷ It can also be used at a second stage after a toe phalangeal transfer to lengthen the transferred toe phalangeal bone.

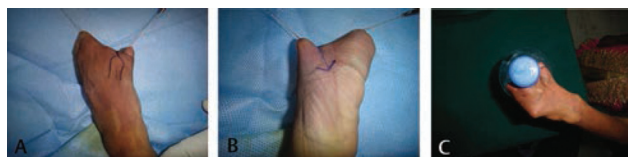

Fig. 6 A child with symbrachydactyly along with a narrow thumb web, illustrating the planning for release and reconstruction with an omega flap. (A) Volar view. (B) Dorsal view showing the truncated dorsal flap. (C) Postoperative view showing an adequate first web.

When the thumb is short, osteotomy of first metacarpal can be performed and lengthening can be achieved by distraction. Metacarpal lengthening can provide more reliable and stable bone formation than bone grafting.⁸ A web deepening procedure is often necessary after the distractor is removed and callus is consolidated.

When multiple fingers are short, distraction of proximal phalanges is performed to obtain finger length. A single distractor can be applied to multiple fingers, and simultaneous lengthening of all fingers can be achieved. Placement of pins should be done under C-arm guidance, and injury to epiphysis and articular surfaces should be avoided.

We had a child with symbrachydactyly of short-finger type. This child had a well-developed thumb and little finger. The middle three fingers were short and syndactylized. At the ages of 9 and 12 months, syndactylies of the middle three fingers were released in two stages, and the fingers allowed to grow individually. At the age of 6 years, the child had short and thin proximal phalanges and terminal phalanges, with intact nail complexes in the middle three fingers. The middle phalanges were absent. The child underwent distraction osteogenesis of the proximal phalanges of all three fingers, using a combined distraction device. Although the distraction takes longer, it is said to be more effective than bone grafting with respect of the bone lengthening achieved.⁹ We were able to create a gap in the proximal phalanx, which was replaced by auto-osteosynthesis. At the age of 11 years, the child had fingers of a uniform length (► Fig. 8A, B, C).

Because of reduced usage of hand, the phalanges are often osteopenic and hypoplastic. Distraction must be carried in a slow, careful, and supervised manner for a prolonged period to obtain a stable callus. Even after removal of distractor, intramedullary K wires may be required for keeping the callus in alignment for few weeks. Few children might require bone grafting for nonunion of the distracted callus.¹⁰

Free Nonvascularized Phalangeal Transfer

Single or double free nonvascularized toe phalangeal transfer is used in children with symbrachydactyly. To obtain normal growth of the phalanges, the procedure should be done before 18 months of age. The growth plates may remain open to the age of 7 years. This procedure is only appropriate when the soft-tissue envelope is sufficient. It is necessary to harvest the whole phalanx with an intact periosteal envelope to avoid resorption.¹¹

Free nonvascularized phalangeal transfer for symbrachydactyly will have a poor outcome if there is inadequate space

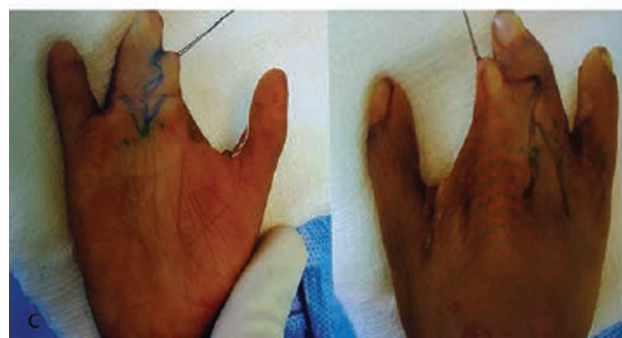
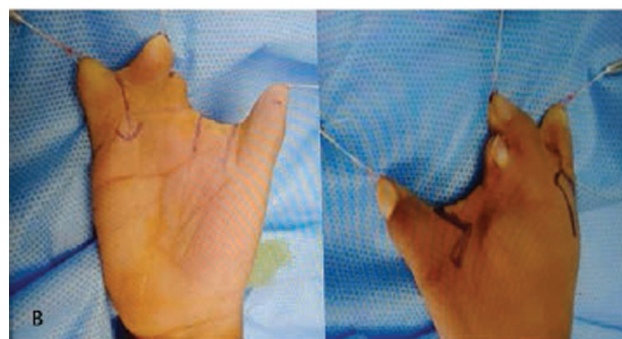
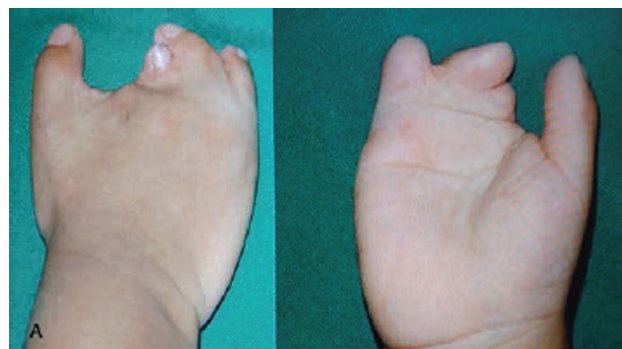
Fig. 7 (A) A child with symbrachydactyly along with fusion of all digits. The thumb is normal. The thumb web is contracted. (B) At the first procedure, the little finger was separated from the ring finger by the omega flap technique and the first web released using a square flap. (C) The markings for the second stage to release the syndactyly of the middle and ring fingers by the omega technique. (D) The result showing four independent useful fingers.

in the digital sac. If the transferred phalanx is shortened to fit into the digital sac, it will be reabsorbed, as the medullary cavity is exposed. If there is disruption of the periosteal covering, the phalangeal graft will not survive.¹² Donor digit

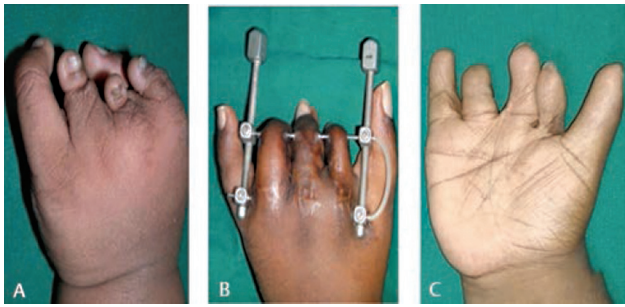


Fig. 8 (A) Child with short-finger type of symbbrachydactyly: first stage reconstruction done with syndactyly release. (B) Lengthening of the index, middle, and ring fingers done with distraction osteogenesis. (C) The postoperative appearance of the lengthened fingers.

shortening, instability, and deformity can occur after toe phalangeal harvest.¹³ To avoid donor site instability, the flexor and extensor tendons should be sutured together in the resultant gap. This avoids a floppy digit, prevents deformity after phalangeal harvest, and minimizes shortening.

When the metacarpals are of equal length with a good soft-tissue envelope, free phalangeal transfers remain quite stable and can achieve up to 90 degrees of motion at the new MCP joint. However, with metacarpals of uneven lengths, direct placement of the free phalangeal transfers onto the metacarpal heads will often lead to angulated deformity and subluxation.

Digital instability was not noticed in most of these patients, because the flexor and extensor tendons were fused by the palmar aponeurosis over the metacarpal heads. While reconstructing the digit, the tendons must be divided and sutured to the palmar and dorsal sides of the transferred phalanx to act as flexor and extensor. This will provide stability to the reconstructed finger. To avoid instability of the digit, the transverse metatarsal ligament should never be disturbed.

A combination of toe phalangeal transfer, web deepening, and distraction lengthening of the transferred phalanges enhance the hand function, provide stable digits, and enable wider grip span in oligodactylosis type of symbbrachydactyly.¹⁴

We had a child with peromelic type of symbbrachydactyly who presented at the age of 1 year with an unstable thumb at the MCP level. He had a remnant of the terminal phalanx with a nail complex. A free nonvascularized phalangeal transfer was performed to stabilize the thumb at the MCP joint level. Reviewing the patient after 8 years, we found that the patient had retained a stable thumb, but it was short. However, he could oppose to the palm with the short thumb and ride a bicycle to his satisfaction and that of his parents (—Fig. 9A, B and C).

Toe Transfer

Vascularized toe transfer is an ideal treatment for reconstruction of absent radial post or ulnar post. Toe transfer helps in restoration of pinch, grasp, and prehension in monodactylosis form of symbbrachydactyly. The success rate of microvascular toe-to-hand transfer by experienced microvascular surgeons is generally more than 95%.¹⁵ The

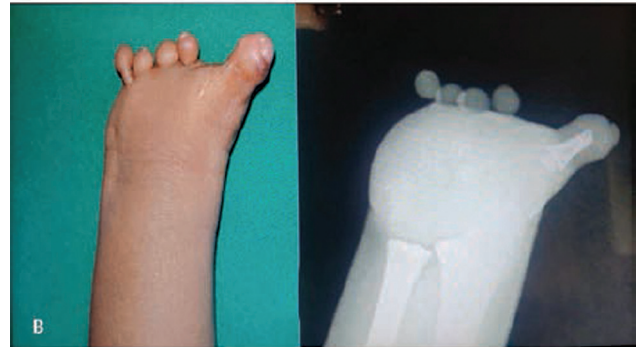
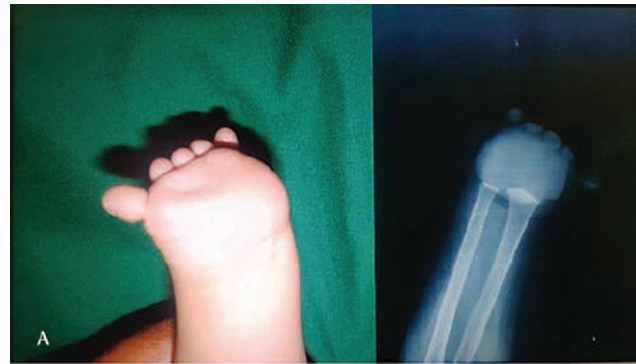
Fig. 9 (A) A child with peromelic type of symbbrachydactyly: The thumb was attached by a small pedicle but unstable; X-ray showing poor development of the phalanges. (B) Dorsal view of a free toe phalangeal transfer at 15 months, stabilizing the thumb. (C) X-ray at 3-year follow-up showing good survival of the transferred phalanx with no bony absorption. (D) At 8 years of age, although the boy has got no fingers in the opposing post, he opposes with the thumb to the palm and is able to hold the handlebar of a bicycle to ride to school.

transferred digit often regains adequate function and sensation and helps the hand perform self-care.¹⁶

Planning has to be done meticulously, since proximal abnormalities like absent or hypoplastic tendons, abnormal vascular pattern and branching and skeletal hypoplasia are more common in congenital hand differences.¹⁷ Proximal nerves can also be absent and may need nerve transfer from adjacent nerves to provide sensation to transferred digit.¹⁸

Our experience with second toe transfer to replace the little finger as an opposition post is limited. In children with

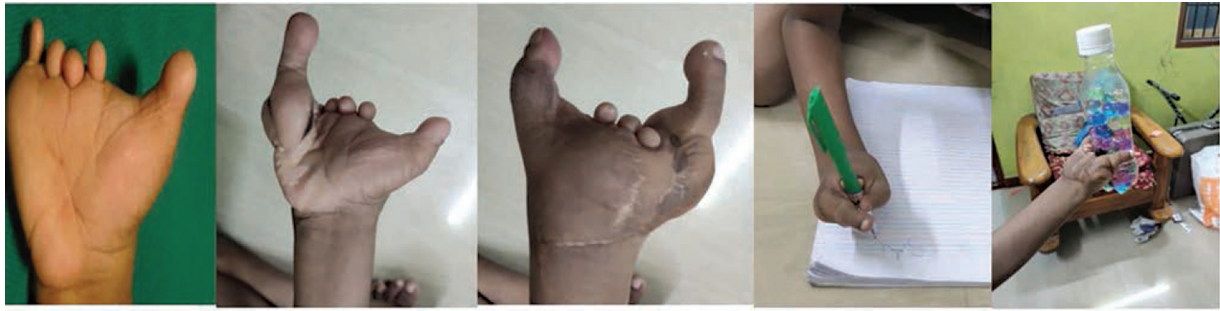

Fig. 10 A child with monodactylous type of symbrachydactyly. The child had a stable short radial post, but the remaining digits were hypoplastic. In the first stage, thumb web release, thumb lengthening, and rotation osteotomy of first metacarpal along with square flap cover was done. The child underwent microvascular reconstruction with second toe transfer to reconstruct an ulnar post in the second stage. Postoperatively, the child was able to use the reconstructed hand to hold a pen and write.

SYMBRACHYDACTYLY – MANAGEMENT PROTOCOL

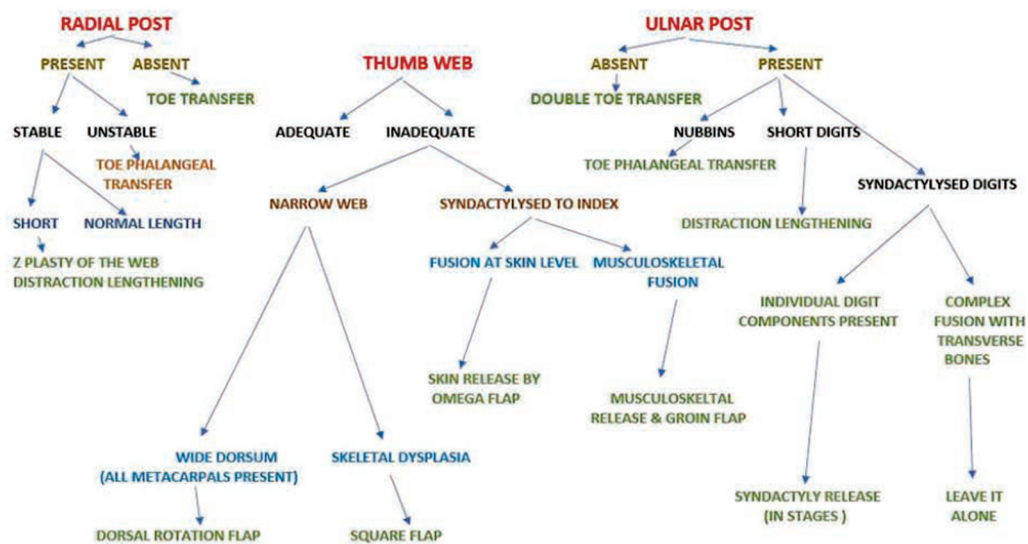


Fig. 11 Management protocol for symbrachydactyly.

the monodactylous form of symbrachydactyly, addition of digits by free vascularized double toe transfer, will achieve tripod grip, as opposed to the hook grip of a single toe transfer to the little finger (► Fig. 10).

Restoration of pinch in adactylous form of symbrachydactyly needs to be performed in two stages. In the first stage, radial postreconstruction is done by second toe transfer. In the second stage, ulnar postrecreation is done by double toe transfer. Growth rate, functional status, and sensory recovery are often satisfactory. Joint motion restoration will be limited and may require secondary surgeries. Extension deficit in PIP joint level and limited mobility of distal interphalangeal joint may be benefited by tenolysis or arthrolysis.¹⁹

Conclusions

Making the correct diagnosis is the essential first step of managing congenital hand differences.²⁰ This is especially

more appropriate in symbrachydactyly, because of its diverse morphologic presentations.

Surgical treatment of children with symbrachydactyly is challenging but can provide excellent functional outcomes if surgery is performed early. More severe forms are taxing to the ingenuity of the surgeon. Management has to be individualized in each and every child, depending upon the clinical presentations, availability of digits, stability and their mobility.

We have formulated a management protocol (► Fig. 11) for these children with symbrachydactyly. This is only a rough outline and guidance toward planning. Children often require a combination of these procedures or additional newer techniques designed, as per the vision and visualization of the reconstructive surgeon.

Sometimes, surgery has little to offer. Despite the adverse appearance of the hand, children will adapt and learn to use it in a way, which might have been considered impossible at

birth. In our experience, it is possible to satisfy parents with the functional outcome for their wards. The children, when they become adults, will be mature enough to use the corrected hand usefully.

Conflict of Interest

None declared.

Acknowledgment

We would like to acknowledge the contribution of Dr. Kavya Somesh in data acquisition, scientific analysis, preparation of the manuscript, and submission of the article. Without her sincere efforts, hard work, intelligent interventions, enthusiastic support, and exemplary motivation, preparation of this manuscript would have been impossible.

References

- Sandzén SC Jr. Classification and functional management of congenital central defect of the hand. *Hand Clin* 1985;1(03):483–498
- Blauth W, Gekeler J. [Morphology and classification of symbrachydactylia]. *Handchirurgie* 1971;3(04):123–128
- Yamauchi Y, Tanabu S. Symbrachydactyly. In: Buck-Gramcko E, ed. *Congenital malformations of the hand and forearm*. London: Churchill Livingstone; 1998:149
- Foucher G, Medina J, Pajardi G, Navarro R. [Classification and treatment of symbrachydactyly. A series of 117 cases]. *Chir Main* 2000;19(03):161–168
- Langer JS, Manske PR, Steffen JA, Hu C, Goldfarb C. Thumb in the plane of the hand: characterization and results of surgical treatment. *J Hand Surg Am* 2009;34(10):1795–1801
- Balakrishnan G, Vijayaragavan S, Balakrishnan S. Omega flap technique: revisiting conventional wisdom. *Hand (N Y)* 2021;1558944721990786
- Buck-Gramcko D. Symbrachydactyly: a clinical entity. *Tech Hand Up Extrem Surg* 1999;3(04):242–258
- Miyawaki T, Masuzawa G, Hirakawa M, Kurihara K. Bone-lengthening for symbrachydactyly of the hand with the technique of callus distraction. *J Bone Joint Surg Am* 2002;84(06):986–991
- Miyawaki T, Masuzawa G, Hirakawa M, Kurihara K. Bone-lengthening for symbrachydactyly of the hand with the technique of callus distraction. *J Bone Joint Surg Am* 2002;84(06):986–991
- Mann M, Hülsemann W, Winkler F, Habenicht R. [Distraction osteogenesis is an effective method to lengthen digits in congenital malformations]. *Handchir Mikrochir Plast Chir* 2016;48(01):48–52
- Goldberg NH, Watson HK. Composite toe (phalanx and epiphysis) transfers in the reconstruction of the aphalangic hand. *J Hand Surg Am* 1982;7(05):454–459
- Nguyen ML, Jones NF. Undergrowth: brachydactyly. *Hand Clin* 2009;25(02):247–255
- Garagnani L, Gibson M, Smith PJ, Smith GD. Long-term donor site morbidity after free nonvascularized toe phalangeal transfer. *J Hand Surg Am* 2012;37(04):764–774
- Netscher DT, Lewis EV. Technique of nonvascularized toe phalangeal transfer and distraction lengthening in the treatment of multiple digit symbrachydactyly. *Tech Hand Up Extrem Surg* 2008;12(02):114–120
- Jones NF, Hansen SL, Bates SJ. Toe-to-hand transfers for congenital anomalies of the hand. *Hand Clin* 2007;23(01):129–136
- Kaplan JD, Jones NF. Outcome measures of microsurgical toe transfers for reconstruction of congenital and traumatic hand anomalies. *J Pediatr Orthop* 2014;34(03):362–368
- Gilbert A. Toe transfers for congenital hand defects. *J Hand Surg Am* 1982;7(02):118–124
- Richardson PW, Johnstone BR, Coombs CJ. Toe-to-hand transfer in symbrachydactyly. *Hand Surg* 2004;9(01):11–18
- Eaton CJ, Lister GD. Toe transfer for congenital hand defects. *Microsurgery* 1991;12(03):186–195
- Koskimies E, Lindfors N, Gissler M, Peltonen J, Nietosvaara Y. Congenital upper limb deficiencies and associated malformations in Finland: a population-based study. *J Hand Surg Am* 2011;36(06):1058–1065