



# Penile Prosthesis in Transgender Men after Phalloplasty

Rajveer S. Purohit<sup>1</sup> Marissa Kent<sup>1</sup> Miroslav L. Djordjevic<sup>1</sup>

<sup>1</sup>Department of Urology, Icahn School of Medicine at Mount Sinai, New York, New York, United States

Address for correspondence Rajveer Purohit, MD, MPH, Department of Urology, Icahn School of Medicine at Mount Sinai, 445 East 77th Street, New York, NY 10075, United States (e-mail: Rajveer.purohit@mountsinai.org).

Indian J Plast Surg 2022;55:168–173.

## Abstract

A penile prosthesis can be successfully implanted after phalloplasty in transgender men to permit sexual intercourse. A prosthesis can be categorized as malleable or inflatable. The most common penile prosthesis implanted after masculinizing genital surgery is the inflatable prosthesis but this can be a challenging operation with high complication rates. Penile prosthesis in transgender patients differs from cis-patients in many respects but one critical difference is the absence of the tough, protective tunica of the corporal body to contain the prosthesis. This causes greater mobility of the prosthesis under the skin and increases the risk of migration and erosion of the device through the skin. In addition, to overcome the absence of a corpora cavernosa, the proximal portion of the prosthesis must be anchored to bone. Complications include injury to the urethra, vascular injury, skin breakdown, infection, device migration, device failure, extrusion, and erosion. There is no robust data on the use of penile prosthesis in transgender men with only multiple reports of small numbers of patients. While successful implantation can improve patients' quality of life, surgeons should counsel patients about the relatively high risk of the need for revision surgery.

## Keywords

- ▶ transgender
- ▶ phalloplasty
- ▶ penile implant
- ▶ testicular prosthesis
- ▶ surgery

## Introduction

There is an increasing number of transgender and non-binary men presenting for medical and surgical treatment.<sup>1,2</sup> In addition to metoidioplasty, common masculinizing genital surgery includes the radial forearm free flap, anterior lateral thigh flap, abdominal flap, and latissimus dorsi free flap phalloplasty. Penile prosthesis use was first described after phalloplasty in 1977.<sup>3</sup> Functionally, the final stage of masculinizing genital surgery is the placement of a penile prosthesis to permit penetrative intercourse. This surgery often completes a surgical journey that involves multiple stages and is fraught with challenges.

Various other techniques have been described over the years to provide rigidity, permitting penetrative intercourse

including fibular bone and rib cartilage grafts.<sup>4</sup> However, these techniques tended to have poor results. Patients would have a persistent, uncomfortable erection and often suffer from gradual reabsorption of the bone and fracture. Most surgeons have now abandoned cartilage and bone techniques in favor of prosthetic devices.

A prosthesis can be categorized into two groups, a malleable prosthesis, and an inflatable prosthesis. The stiffness of malleable prosthesis remains unchanged but patients can bend the prosthesis up for intercourse. Inflatable prostheses are firm when pumped and flaccid when patients are not sexually active. The most common penile prosthesis implanted after masculinizing genital surgery is the inflatable prosthesis but this can be a challenging operation with high complication rates. No major modifications have been

published online  
July 14, 2022

Issue Theme Gender  
Incongruence

DOI <https://doi.org/10.1055/s-0041-1740523>.  
ISSN 0970-0358.

© 2022. Association of Plastic Surgeons of India. All rights reserved. This is an open access article published by Thieme under the terms of the Creative Commons Attribution-NonDerivative-NonCommercial-License, permitting copying and reproduction so long as the original work is given appropriate credit. Contents may not be used for commercial purposes, or adapted, remixed, transformed or built upon. (<https://creativecommons.org/licenses/by-nc-nd/4.0/>)  
Thieme Medical and Scientific Publishers Pvt. Ltd., A-12, 2nd Floor, Sector 2, Noida-201301 UP, India

made over time until the recent advent of a transgender-specific penile prosthesis but this is new and still not widely used. Although widely used, it should be noted that the penile prosthesis has not been approved in the United States specifically for use in transgender men.

The utilization of a prosthesis is limited in many non-western countries because of the high cost. Generally, the malleable prosthesis is cheaper than the inflatable prosthesis and may be an option for those who cannot afford an inflatable prosthesis.

This article provides a comprehensive discussion on what prosthetic options are available for transgender individuals and delves into surgical technique considerations and peri-operative management for the benefit of both the learner as well as fellow transgender surgeons.

## Prosthesis Options

There have been attempts to place a prosthesis in patients after metoidioplasty to improve the phallic length and the ability to stand to urinate but these should be considered experimental with safety and efficacy not yet demonstrated.<sup>5</sup>

With one exception, transgender men have similar prosthetic options after phalloplasty as cis-men. These include the malleable prosthesis, the two-piece inflatable, and the three-piece inflatable prosthesis. In addition, there is a unique prosthesis that is available only for trans-men after phalloplasty, Zephyr's ZSI 475 FtM. Significant differences from the other inflatable penile prostheses include the presence of only one cylinder rather than two, a glans shaped tip to shape the overlying skin and prevent rolling of the glans over the prosthesis, and a flat base designed to be tacked into the periosteum of the pubic bone to increase the stability of the prosthesis. In addition, the pump is designed to mimic a testicular prosthesis appearance more so than the standard penile prosthesis pump. Long-term data are limited but in a small series of 20 patients and 21 implants, there was a 19% revision rate with a mean follow-up of 8.9 months with acceptable satisfaction rates reported using a non-validated questionnaire.<sup>6</sup>

Two companies, Boston Scientific and Coloplast, produce the most commonly used prostheses in the United States and India. Both companies have advantageous properties to their products. The AMS has an antibiotic coating that theoretically may reduce the risk of infection. Coloplast produces a prosthesis that expands both girth and length with inflation. Ultimately the choice of the prosthesis in trans-men is usually based on the surgeon's familiarity as there are little data to guide otherwise.

The malleable prosthesis is generally composed of a distal rigid core and a softer silicone proximal end which can be trimmed. Additionally, rear tip extenders can be added to the prosthesis to gain additional length. Inflatable prostheses are most commonly composed of three segments, a reservoir, a pump, and 1 or 2 cylinders. When the pump is pressed fluid is transferred from the reservoir to the prosthesis which then becomes stiff. The pump also permits deflation and fluid

returns to the reservoir. There is an alternative inflatable prosthesis that is composed of 2 pieces and does not contain a reservoir (Boston Scientific, Ambicor). The device is partially inflated at all times and becomes more rigid with pumping. This prosthesis avoids the second incision usually required for implantation of the reservoir in a 3-piece prosthesis. However, the need to deflate the prosthesis by bending the penis at a 55–65 degree angle for 6–12 seconds may increase the risk of tissue injury to the neophallus and migration of the device, particularly given the absence of corpora cavernosa in the neophallus. In addition, inflation of the device requires higher pressures to pump which theoretically may increase the risk of damage to the overlying scrotal skin and subcutaneous tissues which is often not as thick as cis-gender scrotal skin.

The 3-piece inflatable penile prosthesis is considered the "gold standard" device in the neophallus for a variety of reasons. For one, it more naturally mimics the appearance of the natal phallus with deflation and inflation. In addition, by being deflated most of the time, there is, theoretically, a lower risk of erosion into the overlying skin. The cylinders are composed of either inorganic Dacron (AMS) or Bioflex (Coloplast) to provide stiffness with fluid inflation. Particularly with Bioflex, when the phallus is flaccid it may have a palpable "dog-ear" redundancy which may put pressure on the overlying skin in the neo-phallus and over time increase the risk of erosion at this site.

## Choice of Prosthesis

Generally, we often use a malleable prosthesis when the device is first implanted as a staged operation. Use of the malleable prosthesis first allows a capsule to form around the prosthesis which serves as a placeholder and allows for the easier subsequent placement of a 3-piece prosthesis. Ultimately, the choice of prosthesis is up to the patient and the surgeon's comfort and experience with the implantation of devices.

## Surgical Technique

Penile prosthesis in transgender patients differs from cis-patients in many respects but one critical difference is the absence of the tough, protective tunica of the corporal body to contain the prosthesis. This lack of a tunica causes greater mobility of the prosthesis under the skin and increases the risks of migration and erosion of the device through the skin. Because of this, it is especially important to ensure when placing the device that there is adequate tissue coverage overlying the prosthesis. If tension does exist it is better to downsize the cylinder or use only one cylinder for the prosthesis.

## Timing of Surgery

Typically, surgery should be performed after glansplasty has been completed to minimize the chance of wound infection impacting the prosthesis. Ideally, in patients who have had a nerve-hookup at the time of their phalloplasty, enough time should lapse to allow for the establishment of sensation prior

to prosthesis implantation. This allows patients to receive feedback and minimize activity that might increase the risk of erosion of the device or injury to the phallus. We generally wait at least 6 months prior to implant placement but others have advocated an even longer wait of up to 12–16 months to allow sensitivity to occur which can protect the phallus from injury.<sup>7</sup>

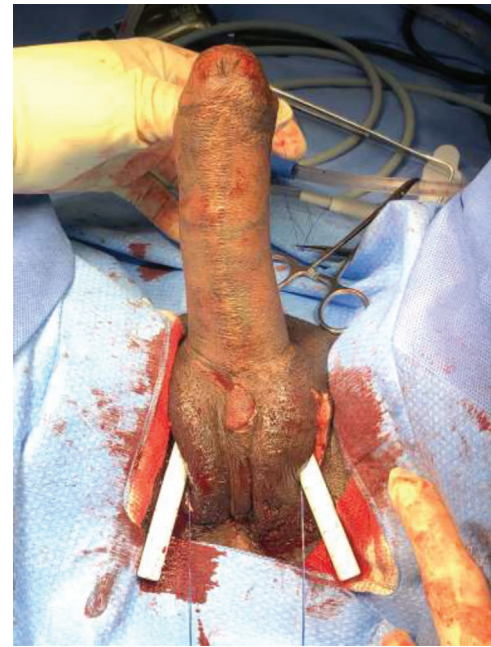In fact, one large series has found a higher rate of revisions for a 3-piece penile prosthesis placed after abdominal phalloplasty compared with radial forearm flaps. The authors hypothesized that this may have been in part related to a higher incidence of placement of 2 cylinders in the abdominal phalloplasty group.<sup>8</sup> The thicker muscle layer and/or subcutaneous tissue in latissimus dorsi and anterior lateral thigh flap phalloplasties may also be protective from prosthesis erosion.

### Preoperative Planning

We ask patients to use an antibacterial soap wash the night before and the morning of surgery. Broad-spectrum intravenous antibiotics are begun 30 minutes prior to the procedure. We typically position the patient in a dorsal lithotomy position. The area is shaved at the time of surgery and a full 10-minute scrub followed by an alcohol-based sterilizing agent is used at the time of surgery.

### Incisions

Incisions to place the prosthesis can be made ventrally such as an infrapubic incision or dorso-inferiorly such as a parascrotal incision. Surgeons implanting a penile prosthesis after phalloplasty should be conscious of the vascularity of the flap and minimize compromise of this when deciding the location of the incision. For example, the MLD phalloplasty will utilize a flap that requires an anastomosis to the unilateral superficial femoral artery and saphenous vein.<sup>10</sup> Incisions on this side should be avoided when placing the prosthesis. Abdominal phalloplasty is usually based on the superior lateral blood supply to the neophallus. Consideration should be made for an inferior or inferior lateral incision.<sup>11</sup> If the vascularity cannot be determined preoperatively, a Doppler ultrasound can assess the location of the primary vessels. The neophallus may develop accessory

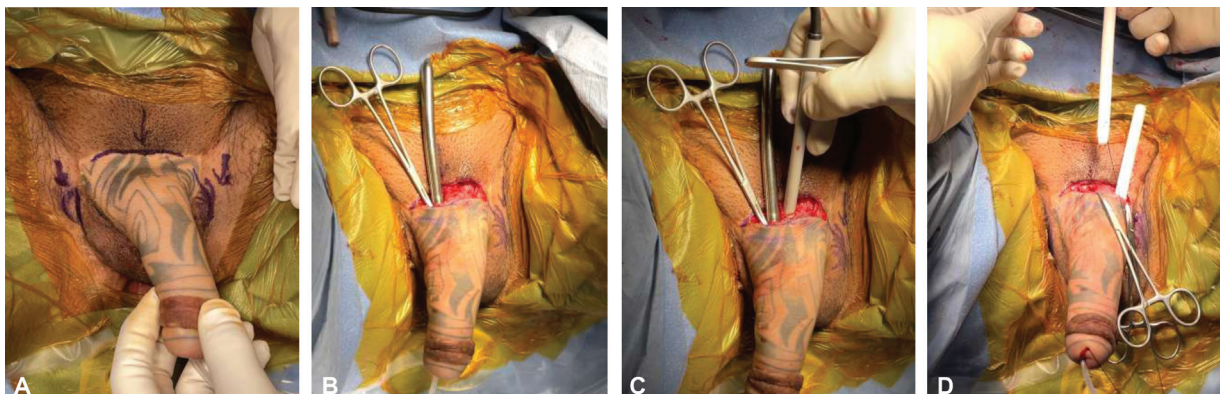


**Fig. 1** Malleable penile prosthesis in position prior to proximal ends being trimmed.

neovascularity which can serve a protective function should the primary artery be compromised during prosthesis placement.

### Malleable Penile Prosthesis

A 14 French urethral catheter is placed to begin the case. This often requires cystoscopic guidance to avoid injury to the neourethra. When utilizing a groin approach, the incision is made lateral to the scrotum over the inferior aspect of the pubic bone. The scrotum is retracted medially. Dissection is performed through the soft tissues until the periosteum of the bone is exposed (→**Fig. 1**). A single, non-absorbable suture is placed as an anchoring stitch through the periosteum. In cases in which there is concern about the vascular supply for phallus may be lateral, an infrapubic incision can be made (→**Fig. 2A**). A straight metal sound is then introduced through the incision and advanced into the neophallus with careful attention as to not injure the urethra and to



**Fig. 2** (A) Markings depicting possible incision sites. (B) Hegar dilator in position. (C) Doppler is used to check for vascular pedicle. (D) Second cylinder being placed.

maintain an adequate thickness of overlying skin. A Doppler ultrasound can be used to determine the location of the blood supply if this is uncertain prior to or doing dilation. (► **Fig. 2B**) The dilator should be stopped once the tip of the penis is reached while still leaving ample tissue coverage. (► **Fig. 2C**). Serial dilation is then performed. The distance from the furthest dilation point to the anchoring suture is measured. If the neophallus appears to be able to accommodate a second cylinder then the same procedure is performed on the opposite side with a dilator left in place. A suture can be tied to the tip of the prosthesis and pulled through the phallus to help bring the prosthesis to the tip of the neophallus. (► **Fig. 2D**) The first malleable cylinder is then placed along the previously dilated tract. Once in position, the bottom is trimmed with a scalpel. The anchoring stitch previously placed is then put through the bottom of the cylinder and tied down. The second cylinder is then placed in the same manner. The neophallus should be maintained in an upward direction in the midline during initial healing.

### Inflatable Penile Prosthesis

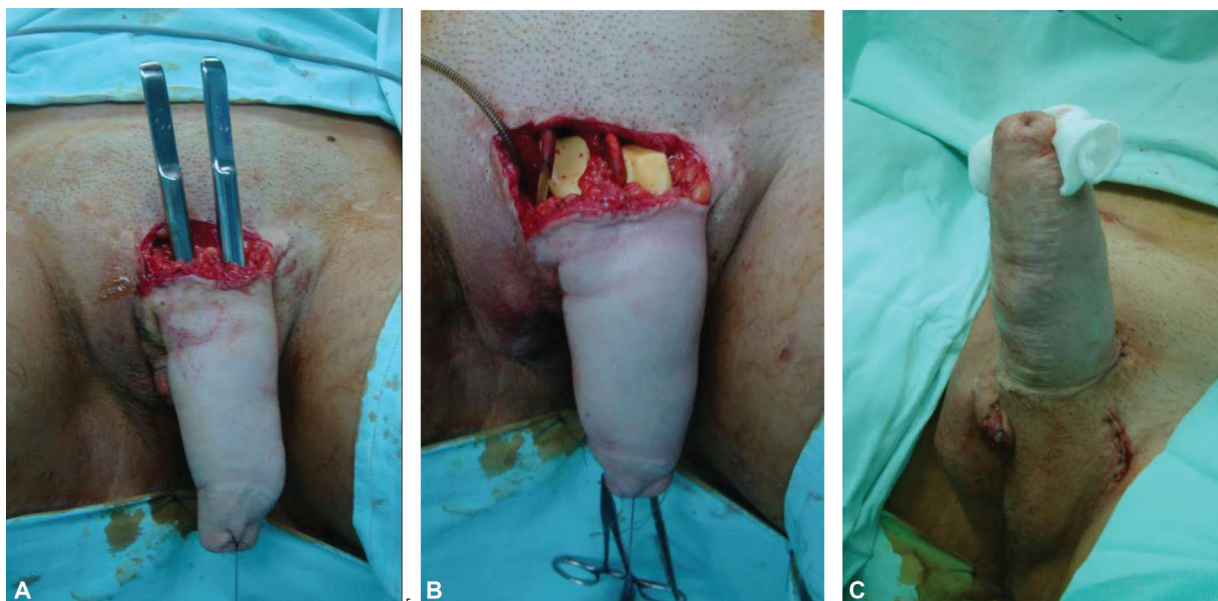
The inflatable prosthesis (► **Fig. 3**) can be placed in one stage or two stages. Falcone, et al<sup>8</sup> described a two-stage operation where the first stage consists of placement of one single testicular implant along with reservoir placement. The reservoir is left inflated with the tubing capped off and left in the vicinity of the testicular implant. In the second stage, the same lateral groin incision is made as described above to place an inflatable prosthesis. We generally place all components of the inflatable prosthesis in one stage and make a separate secondary incision for placement of the reservoir. The second incision is typically a transverse lower abdominal incision made on the same side as the scrotal pump. The reservoir is then placed submuscular with it resting posterior to the rectus muscle but anterior to the

transversalis fascia. This space may also be developed without a second incision by going through the external inguinal ring then developing the space medially between the transversalis fascia and rectus. The reservoir may also be placed in the space of retzius by piercing through the floor of the inguinal canal.

When placing the cylinders, a similar surgical incision can be made as the malleable prosthesis and dilation proceed with Hegar dilators as they would with the malleable prosthesis. If the phallus permits, two cylinders are placed but we err on the side of caution and will place just one cylinder if any tension on the skin is suspected. The space is then measured to determine which implant size to use. If two cylinders are to be used the same procedure is performed on the contralateral side. Falcone et al<sup>8</sup> have recommended that the distal tip of the implant is covered with a polyethylene terephthalate (Dacron) cap and coverage of the rear tip of the cylinder is then covered by a Dacron sock which is in turn anchored to the bone using the previously place stay sutures. The pump can be implanted on one side as a testicle and a contralateral testicular prosthesis implanted if it has not previously been placed. The implant is left partially inflated for 1 week.

### Anchoring the Prosthesis

To overcome the absence of a corpora cavernosa to contain the prosthesis, the proximal portion of the prosthesis must be anchored to bone. The two common sites of anchoring are the pubic symphysis<sup>8,11-13</sup> and the inferior pubic rami.<sup>14</sup> Multiple methods of anchoring have been described. The non-absorbable suture should be used for the anchor which may include merseline 1,<sup>11</sup> 3-0 gor-tex,<sup>14</sup> or 0 ethibond.<sup>8,15</sup> This suture may be placed directly through the base of a malleable prosthesis. In a 3 piece prosthesis the suture may be placed through a rear tip extender or through an alternatively fashioned rear sheath. Materials



**Fig. 3** (A) Two dilators in place. (B) Inflatable prosthesis in position. (C) Final appearance after wound closure.

used to form this sheath or “sock” include Dacron,<sup>8,11,12</sup> Gor-tex,<sup>14</sup> or polyester vascular graft.<sup>12,13</sup> Some surgeons cover just the rear tip of the prosthesis with this sheath<sup>8,11</sup> while others cover the whole prosthesis.<sup>14</sup> Despite these maneuvers, migration of the prosthesis remains a persistent problem.

## Postoperative Management

Antibiotics are continued for 7 days after surgery. For patients who get a malleable penis prosthesis they are asked to refrain from sex for 6 weeks. For the 3-piece penile prosthesis patients, the device is left partially inflated for 7 days. Patients are encouraged to keep the pump in the scrotum periodically to prevent migration of the pump in a cephalad direction. Patients may begin to have sex after 6 weeks.

## Complications

### Intraoperative Complications

Intraoperative complications include injury to the urethra at the time of device implantation. Urethral injury can occur more easily than in cis-gendered males because of the absence of a corpora and often poorly defined margins with the urethra. If possible, placement of a urethral catheter prior to dilation can help minimize this complication. One feared complication is an injury to the vascular bundle that supplies the neophallus. Fortunately, this complication is rare, and often times the neophallus has developed collateral circulation. When a vascular injury does occur urgent revascularization and repair of the injury may be necessary to prevent phallic necrosis.

### Postoperative Complications

Post-operative complications include skin breakdown, infection, device migration, device failure, extrusion, and erosion. Infections can be acute or chronic and although techniques have been described to salvage the prosthesis in infected cases of cis men there is no data to suggest that this technique is viable in transgender men. Our preferred method is to remove the infected prosthesis and wait until the infection has cleared prior to attempting a replacement of the prosthesis. One difficulty with this approach is that significant scarring can occur at the site the prosthesis is removed which can make implantation of a second prosthesis difficult. In addition, for patients who may have had a Dacron sheath placed distally or proximally, removal of the Dacron portion in the setting of infection can be difficult because of significant scarring. Glandular hypermobility,<sup>17</sup> device migration, and skin erosion can occur. The addition of a Dacron cap may help prevent this erosion. In addition, although a single cylinder may not give the same girth and rigidity as two cylinders, it may decrease the incidence of skin erosion. Phallic reconstruction that includes a muscular component may also decrease the risk of skin erosion.

## Outcomes and Data

There is no robust data on the use of penile prosthesis in transgender men with multiple reports of small numbers of patients. The largest series published to date by Falcone et al was of 247 patients who received an inflatable penile prosthesis and had either a radial forearm flap or an abdominal phalloplasty. They used a Dacron envelope fitted around the proximal and distal aspect of the cylinder and anchored the proximal Dacron sheath to the pubic bone. They found a 43% complication rate including 8.5% infections, 15.4% mechanical failure (including cylinder rupture and aneurysm, and rupture of the connecting tubing), and 19.4% of patients dissatisfied with the prosthesis. The overall 5-year survival rate of the implants was 78%. There was no significant difference between the type of prosthesis used and the likelihood of prosthesis survival.<sup>8</sup> The second largest series published to date is of 129 patients (and 185 prostheses) and a similarly high need for removal or revision of the prosthesis (41.1%) was reported. Complications included infections in 11.9%, protrusion in 8.1%, 9.2% with a prosthesis leak, and a migration rate of 14.6%. Other smaller series have confirmed a high rate of need for revisions and replacement.<sup>17</sup>

## Conclusion

A penile prosthesis can be successfully implanted after phalloplasty in transgender men to permit sexual intercourse. There are a variety of techniques and devices available and the choice depends both on the surgeon and patient preferences as well as the type of phalloplasty that was utilized initially. While successful implantation can improve patients' quality of life, surgeons should counsel patients about the relatively high risk of the need for revision surgery.

### Conflict of Interest

None declared.

## References

- Spizzirri G, Eufrazio R, Lima MCP, et al. Proportion of people identified as transgender and non-binary gender in Brazil. *Sci Rep* 2021;11(01):2240
- Wiepjes CM, Nota NM, de Blok CJM, et al. The Amsterdam Cohort of Gender Dysphoria Study (1972-2015): trends in prevalence, treatment, and regrets. *J Sex Med* 2018;15(04):582-590
- Puckett CL, Montie JE. Construction of male genitalia in the transsexual, using a tubed groin flap for the penis and a hydraulic inflation device. *Plast Reconstr Surg* 1978;61(04):523-530
- Bogoras N. Uber die volle plastische Wiederherstellung eines zum Koitus fahigen Penis (Peni plastica totalis). *Zentralbl Chir* 1936; 22:1271-1276
- Neuville P, Carnicelli D, Paparel P, Ruffion A, Morel-Journal N. Metoidioplasty with implantation of a specific semirigid prosthesis. *J Sex Med* 2021;18(04):830-836
- Neuville P, Morel-Journal N, Cabelguenne D, Ruffion A, Paparel P, Terrier JE. First outcomes of the ZSI 475 FtM, a specific prosthesis designed for phalloplasty. *J Sex Med* 2019;16(02):316-322
- Blecher GA, Christopher N, Ralph DJ. Prosthetic placement after phalloplasty. *Urol Clin North Am* 2019;46(04):591-603

- 8 Falcone M, Garaffa G, Gillo A, Dente D, Christopher AN, Ralph DJ. Outcomes of inflatable penile prosthesis insertion in 247 patients completing female to male gender reassignment surgery. *BJU Int* 2018;121(01):139–144
- 9 Djordjevic ML, Bencic M, Kojovic V, et al. Musculocutaneous latissimus dorsi flap for phalloplasty in female to male gender affirmation surgery. *World J Urol* 2019;37(04):631–637
- 10 Kim S, Dennis M, Holland J, Terrell M, Loukas M, Schober J. The anatomy of forearm free flap phalloplasty for transgender surgery. *Clin Anat* 2018;31(02):145–151
- 11 Hage JJ. Dynaflex prosthesis in total phalloplasty. *Plast Reconstr Surg* 1997;99(02):479–485
- 12 Hoebeke PB, Decaestecker K, Beysens M, Opdenakker Y, Lumen N, Monstrey SM. Erectile implants in female-to-male transsexuals: our experience in 129 patients. *Eur Urol* 2010;57(02):334–340
- 13 Neuville P, Morel-Journel N, Maucourt-Boulch D, Ruffion A, Paparel P, Terrier JE. Surgical outcomes of erectile implants after phalloplasty: retrospective analysis of 95 procedures. *J Sex Med* 2016;13(11):1758–1764
- 14 Zuckerman JM, Smentkowski K, Gilbert D, et al. Penile prosthesis implantation in patients with a history of total phallic construction. *J Sex Med* 2015;12(12):2485–2491
- 15 Large MC, Gottlieb LJ, Wille MA, DeWolfe M, Bales GT. Novel technique for proximal anchoring of penile prostheses in female-to-male transsexual. *Urology* 2009;74(02):419–421
- 16 Salgado CJ, Fein LA, Williams EA, Sood R. Supersonic transporter deformity in transgender men following phalloplasty. *Plast Reconstr Surg* 2019;144(01):225–227
- 17 van der Sluis WB, Pigot GLS, Al-Tamimi M, et al. A retrospective cohort study on surgical outcomes of penile prosthesis implantation surgery in transgender men after phalloplasty. *Urology* 2019;132:195–201