

Pneumoscrotum after ERCP-related duodenal perforation

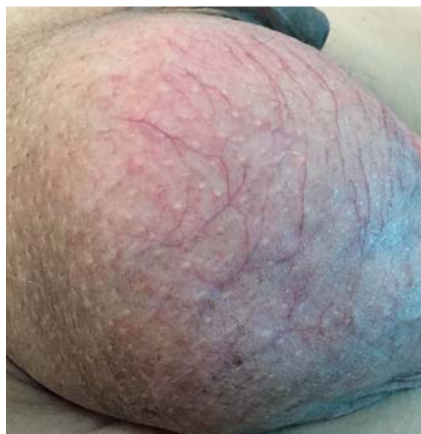

Fig. 1 Enlarged scrotum following endoscopic retrograde cholangiopancreatography.

The incidence of duodenal perforation after endoscopic retrograde cholangiopancreatography (ERCP) is lower than 1%. When it does occur, intestinal gas usually tracks upward through the retroperitoneal space and mediastinum to present as surgical emphysema in the neck [1]. We describe a rare case of a young man developing pneumoscrotum following an ERCP-related duodenal perforation.

A 29-year-old man underwent ERCP for investigation and treatment of jaundice due to choledocholithiasis. The papilla was difficult to cannulate. Endoscopic sphincterotomy was performed. Success-

ful biliary drainage was achieved. As stone clearance was incomplete, a temporary plastic stent was placed [2].

The patient immediately complained of a swollen scrotum; otherwise he was completely asymptomatic. There was no abdominal tenderness or guarding. His scrotum was enlarged 2–3 times the normal size (Fig. 1), and was tense and tympanic. Crepitus was elicited in the scrotum, but not in the abdomen, chest, or neck. Needle aspiration of the scrotum produced gas but no fluid. Abdominal computed tomography scan (Fig. 2) confirmed the diagnosis of pneumoscrotum related to retroperitoneal perforation. Type IV perforation was identified and was treated successfully with conservative management.

Few cases of pneumoscrotum have been reported. A systematic review by Cochetti et al. [3] identified 59 cases of pneumoscrotum. Although the endoscopic procedures accounted for 32% of all iatrogenic cases, only three cases of pneumoscrotum after ERCP have been described previously [3–5]. In cases of pneumoscrotum, the gas could reach the scrotum by tracking along the transversalis fascia, which forms the innermost covering layer of the spermatic cord. This would account for the lack of palpable subcutaneous emphysema over the abdominal wall. Consequently, pneumoscrotum could be the first

manifestation of a duodenal perforation, as was the case in our patient. As duodenal perforation is a potentially life-threatening condition, clinicians involved in ERCP management must be aware of this clinical manifestation in order to establish prompt diagnosis and treatment.

Endoscopy_UCTN_Code_CPL_1AK_2AC

Competing interests: None

Marco Milone¹, Michele Manigrasso¹, Katia Di Lauro¹, Benedetta Manzo², Francesco Maione², Francesco Milone¹, Giovanni D. De Palma²

¹ Department of Surgical Specialities and Nephrology, University of Naples “Federico II,” Naples, Italy

² Department of Surgery and Advanced Technologies, University of Naples “Federico II,” Naples, Italy

References

- 1 Cho KB. The management of endoscopic retrograde cholangiopancreatography-related duodenal perforation. *Clin Endosc* 2014; 47: 341–345
- 2 De Palma GD, Catanzano C. Stenting or surgery for treatment of irretrievable common bile duct calculi in elderly patients? *Am J Surg* 1999; 178: 390–393
- 3 Cochetti G, Barillaro F, Cottini E et al. Pneumoscrotum: report of two different cases and review of the literature. *Ther Clin Risk Manag* 2015; 11: 581–587
- 4 Klimach OE, Defriend DJ, Foster DN. Pneumoscrotum following endoscopic sphincterotomy. *Surg Endosc* 1990; 4: 230–231
- 5 Silák J, Nemeč L, Ondrák M et al. Pneumoscrotum: uncommon sign in duodenal perforation (a case review). *Rozhl Chir* 2011; 90: 237–239

Bibliography

DOI <http://dx.doi.org/10.1055/s-0042-116428>
 Endoscopy 2016; 48: E295
 © Georg Thieme Verlag KG
 Stuttgart · New York
 ISSN 0013-726X

Corresponding author

Marco Milone, MD
 Department of Surgical Specialities and Nephrology
 University of Naples “Federico II”
 Via Pansini 5
 80131 Naples
 Italy
 Fax: +39-081-7462896
 milone.marco.md@gmail.com

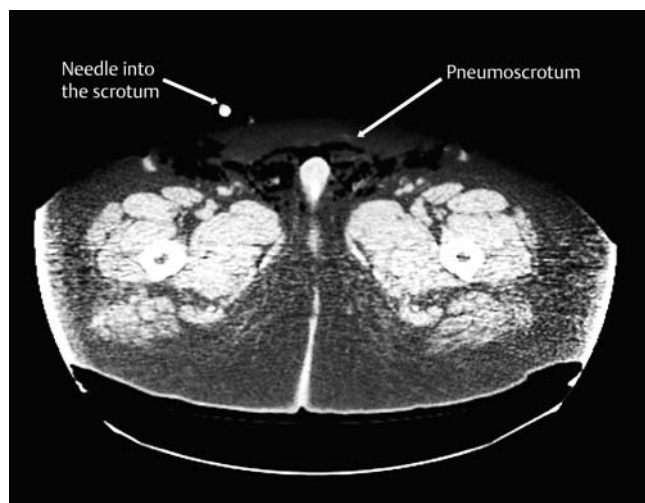


Fig. 2 Abdominal computed tomography imaging of scrotal emphysema (pneumoscrotum).