



# Hepatic Arterioportal Fistula in Patients with Cirrhosis with Endovascular Management—A Series of 4 Cases with Review of Literature

Karamvir Chandel<sup>1</sup> Ranjan Kumar Patel<sup>1</sup> Tara Prasad Tripathy<sup>1</sup> Amar Mukund<sup>1</sup> Rakhi Maiwall<sup>2</sup>  
Shiv Kumar Sarin<sup>2</sup>

<sup>1</sup>Department of Intervention Radiology, Institute of Liver and Biliary Sciences, New Delhi, India

<sup>2</sup>Department of Hepatology, Institute of Liver and Biliary Sciences, New Delhi, India

Address for correspondence Amar Mukund, MD, Department of Intervention Radiology, Institute of Liver and Biliary Sciences, Vasant Kunj, New Delhi, 110070, India (e-mail: Dramarmukund@gmail.com).

Indian J Radiol Imaging 2022;32:136–141.

## Abstract

Hepatic arterioportal fistula (APF) in the setting of cirrhosis may aggravate the preexisting portal hypertension and its complications. Cirrhotic patients undergo various percutaneous invasive procedures and are at risk of developing an APF. These should be diagnosed early and should be treated accordingly at the earliest when indicated. Presently embolization is the treatment of choice with coil embolization as the most commonly used method. We describe four cases from our institute with a history of liver parenchymal disease and were found to have acquired APF on imaging. These were successfully managed with transarterial embolization with resolution or improvement in their clinical symptoms on follow-up. The present case series and review emphasize the importance of APF in the setting of liver parenchymal disease and the role of early diagnosis and therapeutic intravascular interventions.

## Keywords

- ▶ arterioportal fistula
- ▶ cirrhosis
- ▶ portal hypertension
- ▶ embolization
- ▶ n-BCA glue

## Introduction

Hepatic arterioportal fistulae (APF) are abnormal communications between the hepatic artery (HA) and portal vein (PV). These may be congenital or more commonly secondary to iatrogenic causes like liver biopsy, transhepatic portal, and biliary interventions, ablation procedures, or following blunt or penetrating trauma.<sup>1–3</sup> The fistulous communication results in the direct flow of the arterial blood into the PV, bypassing the hepatic sinusoids, leading to presinusoidal type portal hypertension or worsening of the preexisting portal hypertension.<sup>1,2</sup> We describe a small series consisting of four cases of acquired hepatic APF in the setting of chronic liver parenchymal disease with variable presentation and endovascular management.

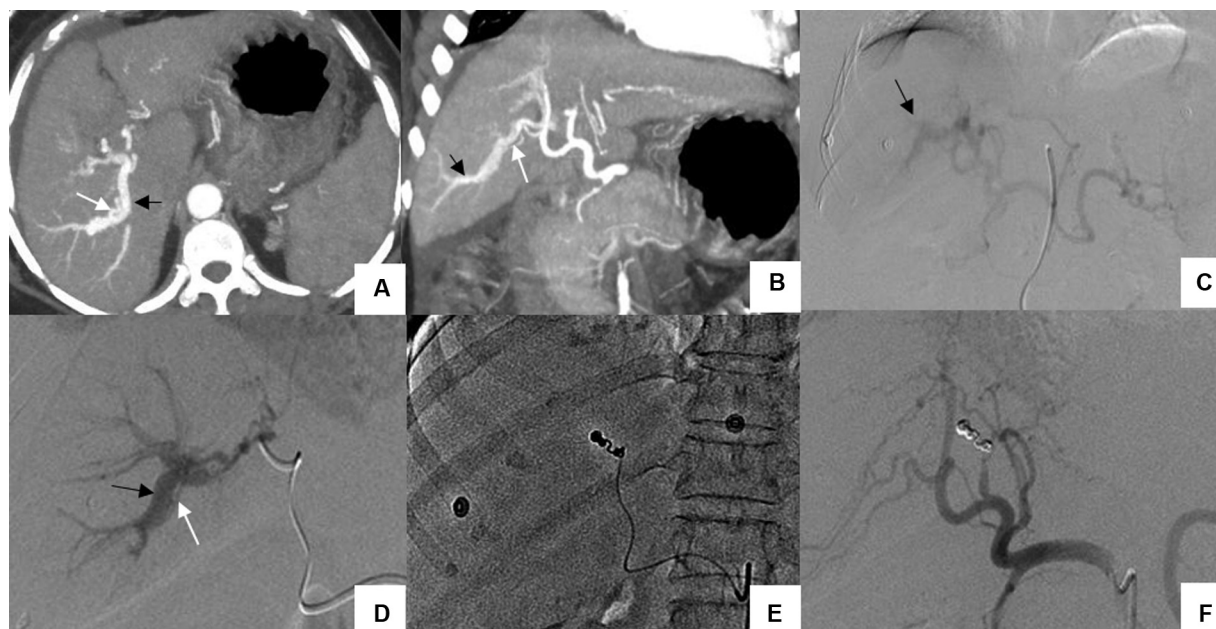## Case 1

A 56-year-old female, a case of decompensated chronic liver disease secondary to autoimmune hepatitis, presented with melena after 7 days of transjugular liver biopsy. The patient was hemodynamically stable. Laboratory evaluations showed a mild drop in hemoglobin (10.6–9.4 g/dL), an increase in total bilirubin (7.5–14.7 mg/dL; direct–8.8 and indirect–5.9), and elevated total leukocyte count (12,600/mm<sup>3</sup>). Her platelet count was low (46,000/mL) and international normalized ratio (INR) was 1.6. Child-Turcotte-Pugh (CTP) score (Child C) and MELD-Na score were 11 and 26, respectively. Upper gastrointestinal endoscopy revealed haemobilia. Multiphasic contrast-enhanced computed tomography (CECT) abdomen showed early peripheral portal

published online  
April 19, 2022

DOI <https://doi.org/10.1055/s-0042-1743112>.  
ISSN 0971-3026.

© 2022. Indian Radiological Association. All rights reserved.  
This is an open access article published by Thieme under the terms of the Creative Commons Attribution-NonDerivative-NonCommercial-License, permitting copying and reproduction so long as the original work is given appropriate credit. Contents may not be used for commercial purposes, or adapted, remixed, transformed or built upon. (<https://creativecommons.org/licenses/by-nc-nd/4.0/>)  
Thieme Medical and Scientific Publishers Pvt. Ltd., A-12, 2nd Floor, Sector 2, Noida-201301 UP, India



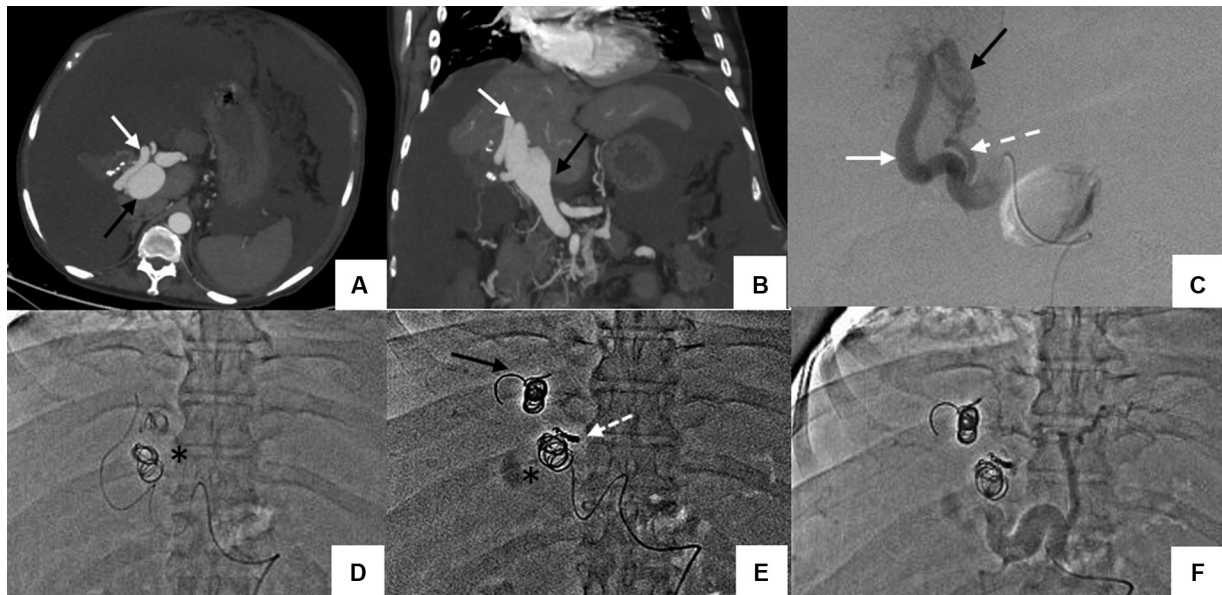**Fig. 1** Arteriportal fistula (APF) in a 56-year-old patient who presented with hemobilia. Computed tomography arterial phase images, (A, axial); (B, coronal), demonstrate an APF between the posterior segmental branch of the right hepatic artery (white arrow) and right branch of the portal vein (black arrow). Selective celiac artery angiogram (C) shows early peripheral opacification of portal vein branch (black arrow). A selective arterial angiogram (D) reveals an APF between the right hepatic artery branch (white arrow) and dilated branch of the right portal vein (black). Selective coil embolization of the arterial branch (E). Check angiogram (F) shows no opacification of the hepatic artery branch and APF.

venous opacification in the arterial phase suggesting an APF, without any obvious biliary communication, pseudoaneurysm, or hematoma (►Fig. 1A, B). Digital subtraction angiography confirmed fistulous communication between the posterior segmental branch of the right HA and PV (►Fig. 1C, D). The hepatic arterial branch supplying the fistula was super selectively cannulated using a microcatheter (PRO-GREAT, Terumo, Tokyo, Japan) and embolized using a pushable microcoil (18–14–4, MicroNester, Cook Medical) (►Fig. 1E). Thereafter, the coil scaffold was supported by *n*-butyl cyanoacrylate (*n*-BCA) glue–Lipiodol mixture (0.3 mL, 30%), resulting in complete occlusion of the fistulous communication (►Fig. 1F). She had mild sepsis for which she was managed in the intensive care unit. There was no further melena or drop in hemoglobin.

## Case 2

A 43-year-old male, biopsy-proven case of cryptogenic cirrhosis presented to emergency with complaints of hematemesis (3 episodes) and melena for 2 days. He had signs of hypovolemia in the form of hypotension (blood pressure = 96/62 mm Hg) and tachycardia (heart rate = 107 beats/min). Bleeding was managed with emergency variceal ligation along with ongoing resuscitative measures. The patient had undergone a liver biopsy 1 year ago to evaluate the cause of cirrhosis. During the past hospitalizations, he had undergone endoscopic variceal ligations twice for esophageal variceal bleeding and multiple sessions of therapeutic paracentesis for rapidly filling ascites. On evaluation, initial laboratory investigations were normal except for low hemoglobin (6.5 gm/dL) and albumin (2.6 g/dL). His CTP score was 9 (Child B) and MELD-Na was 16.

INR was 1.4 and platelet count was normal (1,06,000/mL). Transjugular portosystemic shunt (TIPSS) was planned for managing portal hypertension because of refractory ascites and repeated variceal bleeding. During pre-TIPSS workup, the multiphase CECT abdomen demonstrated a fistula between the right HA and posterior branch of the right PV with aneurysmal dilatation of the intrahepatic PV branches (►Fig. 2A, B). Catheter angiography (5F, C2 angiographic catheter, Cook Medical) showed a 6-mm APF between the posterior segmental branch of the right HA and the posterior branch of the right PV (RPV) with early opacification of the aneurysmally dilated RPV (►Fig. 2C). We considered using an Amplatzer vascular plug, but due to the vessel's tortuosity, getting close to the fistula would have been challenging. Therefore, we proceeded with superselective arterial branch cannulation using a microcatheter (PROGREAT, Terumo) and coil embolization. However, the first three coils (18–14–10, MicroNester, Cook Medical) deployed at the level of the fistula inadvertently migrated into the aneurysmally dilated right PV, possibly due to the high flow across the fistula and inappropriate coil size (even though 30% oversized) (►Fig. 2D). Subsequently, three larger coils (35–14–14 × 2 and 35–14–12 × 1, MReye, Cook Medical) were placed across the fistula by anchoring the initial coil in one of the arterial side branches. An additional small arterial feeder was also embolized using a microcoil (18–14–3, MicroNester, Cook Medical) (►Fig. 2E). The coil scaffolds were supported using a glue–Lipiodol mixture resulting in complete occlusion of the fistulous communication (►Fig. 2F). On follow-up ultrasonography (USG), the migrated coils were confined to the right PV with eccentric thrombus. Before discharge, a patient was put on anticoagulation for 1 month. There was no further progression of the PV



**Fig. 2** Arteriportal fistula (APF) in a 50-year-old with APF and coil migration during angioembolization. Computed tomography arterial phase images, (A, axial); (B, coronal), demonstrate hypertrophied right hepatic artery (HA; white arrow) and early aneurysmally dilated right branch of the portal vein (PV) (black arrow) suggestive of an APF. Selective right HA angiogram (C) shows two arterial feeders (solid and dashed white arrow) and early opacified dilated PV branch. During coil placement (D) initial three coils migrated into the portal vein (asterisk). Post coil embolization (E) spot shows embolized larger and smaller feeder with migrated coil mass in PV (asterisk). Check angiogram (F) reveals nonopacification of the APF.

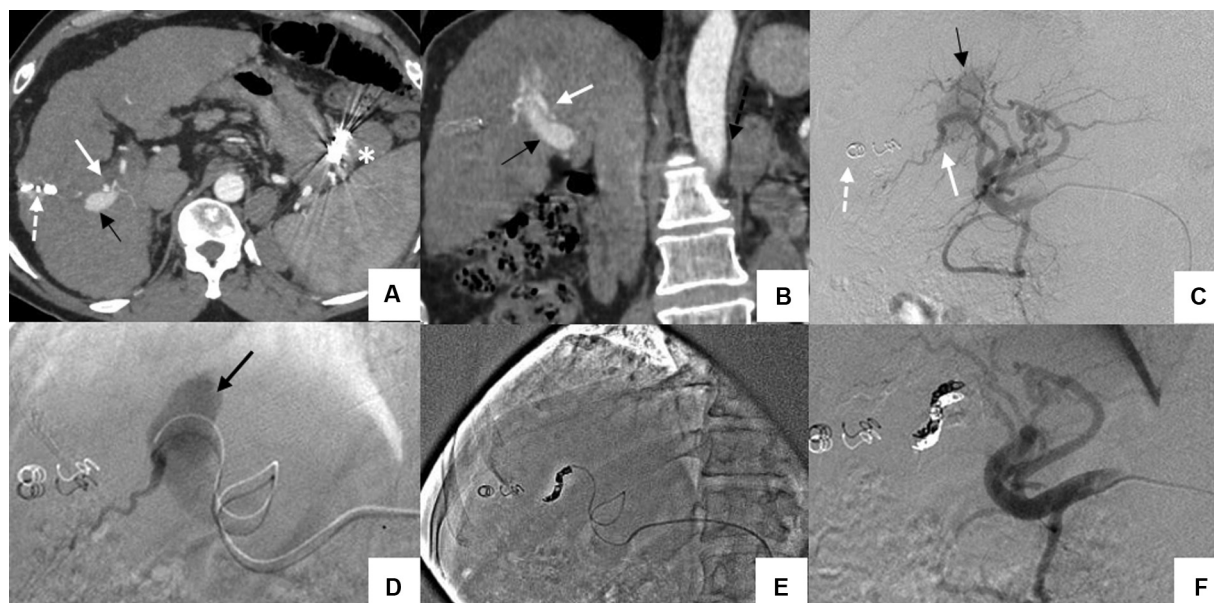
thrombus. During the 6-month follow-up, his abdominal distension has gradually resolved and there were no further episodes of hematemesis or melena. On follow-up imaging, the migrated coils were confined to the right PV with a non-occlusive eccentric thrombus of right PV.

### Case 3

A diagnosed case of an alcohol-related chronic liver parenchymal disease was admitted to our institute for further management of refractory ascites. On presentation, his CTP and MELD-Na scores were 10 (Child C) and 11, respectively. His platelet count was 91,000/mL and INR was 1.5. Two years ago, he had undergone plug-assisted transhepatic antegrade obliteration of the gastrosplenic shunt for recurrent hepatic encephalopathy. Further workup during the current admission revealed a large APF on the CECT abdomen (► Fig. 3A, B). There was fistulous communication between the right HA branch and the posterior branch of right PV with aneurysmal dilatation of the intrahepatic PV branches. The fistula was present along the puncture tract, possibly suggesting an iatrogenic injury from the prior transhepatic intervention for the gastrosplenic shunt. The selective hepatic angiogram showed an APF between right HA and post branch of RPV (► Fig. 3C, D). Superselective catheterization using a microcatheter (PROGREAT, Terumo) and coil embolization of the supplying arterial branch was done using three pushable microcoils (18–14–6 × 1, and 18–14–4 × 2, MicroNester, Cook Medical) and a glue–Lipiodol mixture (► Fig. 3E, F). On follow-up, the patient showed definite improvement in his abdominal distension with the decrease in the frequency of paracentesis.

### Case 4

A 59-year-old male patient labeled as end-stage chronic liver disease was referred to our institute for liver transplantation. The outside sonogram was suggestive of diffuse liver parenchymal disease with features of portal hypertension and ascites. He had undergone endoscopic variceal ligation for variceal bleeding in the past. Baseline CTP and MELD-Na score were 9 and 18, respectively. His platelet count was 1,45,000/mL and INR was 1.3. His cirrhosis workup was inconclusive and was labeled as cryptogenic cirrhosis. During pretransplant workup, an APF was found on CECT. There was a fistulous communication between the right HA and the anterior branch of the right PV with aneurysmal dilatation of the intrahepatic PV branches. CT also showed an atrophic right lobe of the liver, likely secondary to the arteriportal shunting with compensatory hypertrophy of the left hepatic lobe. Additional findings of pruning of the segmental PV branches, splenomegaly, portosystemic collaterals, moderate ascites, and pleural effusion were also noted. The CT scan findings helped us in attributing the entire disease process to the arteriportal shunt causing portal hypertension. Also, patient recalled an abdominal trauma, for which he was hospitalized in the past. The relatively high hepatic venous pressure gradient (10 mm Hg) in this case of presinusoidal portal hypertension is likely related to the right hepatic lobe parenchymal changes and atrophy, secondary to the fistula and shunting. The hepatic angiogram revealed a 6-mm fistula between the anterior segmental branch of the right HA and the anterior branch of the right PV with early opacification of the aneurysmally dilated PV. Superselective embolization of the fistula was performed with seven pushable microcoils. The first coil (18–14–8, MicroNester, Cook



**Fig. 3** Arteriportal fistula (APF) in a 50-year-old patient with a history of plug-assisted transhepatic antegrade obliteration of gastrosplenic shunt. Computed tomography arterial phase images, (A, axial); (B, coronal), demonstrate an APF between posterior segmental branch of the right hepatic artery (HA) (white arrow) and portal vein (PV) branch (black arrow). Selective right HA angiogram (C) shows hypertrophied right HA and early opacification of a dilated PV branch. Selective segmental HA branch angiogram (D) reveals the abnormal fistula with dilated PV (black arrow). Selective coil embolization of the arterial branch (E) was done. Check angiogram (F) reveals nonopacification of the HA branch and APF. Coil from previous percutaneous hepatic access noted (dashed arrow in A, C). Metallic artifact (asterisk in A) from vascular plug noted in the gastrosplenic region from previous shunt closure.

Medical) deployed at the level of the fistula migrated into the dilated right PV. Thus, larger diameters coils (18–14–10 × 4, and 18–14–12 × 2, MicroNester, Cook Medical) were deployed subsequently, and the feeding artery was tightly packed until the APF was completely occluded. On follow-up, the ascites resolved with the decrease in size of the PV with no thrombosis.

Femoral access was used in all the patients and puncture site hemostasis was achieved by arterial closure device (Perclose, ProGlide, Abbott) in all the patients.

## Discussion

Hepatic APFs are an important cause of presinusoidal portal venous hypertension occurring secondary to abnormal fistulous communication between the HA and the PV.<sup>2,3</sup> These may be congenital or acquired in nature, with abdominal trauma being the most common etiology followed by iatrogenic procedures (percutaneous as well as transjugular liver biopsies, surgeries, percutaneous transhepatic interventions, and tumor ablations), malignancy, and rarely HA aneurysm rupture.<sup>1–4</sup>

Patients with chronic liver parenchymal disease undergo various types of interventions that include parenchymal biopsies (percutaneous and transjugular) and ablative procedures. These patients already have portal hypertension and APF in these patients may worsen the preexisting portal hypertension, due to increased arterial flow into the PV. Increased flow into the PV may increase the pressure in preexisting varices, aggravating the chances of gastrointestinal bleeding and also refilling ascites.

During percutaneous procedures, USG guidance is recommended to limit the risk of inadvertent vascular injuries. The use of color Doppler to visualize major vessels and choosing a relatively avascular plane for hardware placement decreases the chance of major vessel injury. Smaller peripheral arteries that are not evident on USG may, however, be damaged and manifest as APF later, particularly in patients with chronic liver disease.

Iatrogenic hepatic APFs represent more than 50% of all published cases.<sup>1</sup> The postbiopsy APF was first described by Preger in 1967.<sup>4</sup> Hellekant showed that the incidence of arteriovenous fistula after a percutaneous liver biopsy was 50% during the first week and 10%, 2 weeks after the biopsy.<sup>5</sup> The majority of these acquired APF are small and peripheral with low shunt volume and are thought to resolve spontaneously. Persistent high-flow APFs causing portal hypertension are relatively rare.<sup>2,3</sup> Guzman et al proposed a simple classification system of APFs based on the location, etiology, and magnitude of arterioportal shunt and proposed the treatment to be adopted based on these.<sup>3</sup>

APF can have either an acute or delayed presentation. In acute type APF, one of the most common presentations is hemobilia.<sup>1</sup> The indication for active and urgent intervention includes the association of haemobilia, as in our first case.<sup>6</sup> This is due to injury to the portal triad, where portal venules, arterioles, and biliary tract lie nearby.<sup>1</sup> In the absence of haemobilia, the presentation is usually delayed with features of portal hypertension (gastrointestinal bleeding and ascites) or diarrhea (due to congestive vascular enteropathy).<sup>1,3</sup> The rationale behind the treatment is to prevent the grave consequences of portal hypertension as in our last case. APF

formation in patients with cirrhosis may worsen the pre-existing portal hypertension, due to increased arterial flow into the PV, thereby increasing the risk of variceal bleeding and aggravating cirrhotic ascites and hydrothorax, as seen in our second and third cases.

Endovascular interventional management is the first line and definitive treatment wherever feasible.<sup>1,2</sup> Embolization aims to selectively embolize the fistula site with preservation of the adjacent hepatic vasculature. Care should be taken to reach the fistula site as close as possible, to avoid nontarget embolization as well as to take care of any collateral circulation that may develop after HA embolization.<sup>1</sup> The various embolizing agents that have been described are microcoils, detachable balloons, liquid agents like onyx and cyanoacrylate glue, stent grafts, and vascular plugs.<sup>1,2,7-10</sup> The choice of embolization agents depends on the fistula size and flow dynamics across the fistula.<sup>2</sup> Coil embolization has been the preferred endovascular treatment in APF; however, new commercially available vascular plugs may offer added advantage.<sup>1,2</sup> Precise deployment, low risk of migration, and complete occlusion with a single device are the advantages of the vascular plug.<sup>9,11</sup> To avoid device migration oversizing of the plug is recommended. In cases two and four, plug deployment was our first choice, as it would have prevented the possibility of coil migration. However, the guiding catheter could not be placed across the tortuous artery, and the commercially available plugs that could have been placed using angiographic catheters were not available.

In the setting of chronic liver parenchymal disease where one expects deranged coagulation, embolization agents like *n*-BCA alone or in combination may be used, as these are not dependent on patient's coagulation profile. Glue was used in all the cases in our series. In the author's experience in cases with the underlying liver disease during coil embolization, the use of glue seems to provide additional support to the coil scaffold. However, *n*-BCA should be used cautiously as it is associated with a high risk of distal embolization that may be fatal.<sup>1,2,12</sup>

Stent grafts have been used to treat traumatic HA pseudoaneurysms with an APF.<sup>10,13</sup> In patients with liver transplants, stent grafts have been utilized to treat main HA injuries, which present the same difficulty of excluding an arterial damage while conserving flow. Stent grafts successfully cover the entry location of the fistula, resulting in total obliteration of the fistula and pseudoaneurysm thrombosis, with preserved flow.<sup>13</sup> To embolize the collaterals, more coils may be required.<sup>12</sup> They may have a role in managing APF in the straight segment of the arteries particularly the extrahepatic arterial segments; however, placing a stent graft in the intrahepatic tortuous arteries could be difficult.

Complications that may occur with embolization are coil migration, vascular injury, hepatic failure, abscess, PV thrombosis (PVT), and bile duct stricture.<sup>1,2</sup> In our second and fourth cases, we successfully embolized the fistula with multiple coils; however, initial coils migrated into the portal venous side and were confined to the right branch of the PV; fortunately, there was no PVT on follow-up imaging in case 4; however, mild eccentric thrombus was

noted in our second case. In the literature, there is no consensus on the need of regular anticoagulation after embolization to prevent thrombosis after coil migration. In case 2, because the patient acquired a nonocclusive eccentric right PV thrombus, we used anticoagulation in the immediate postintervention period. On USG follow-ups, case 4 did not develop PVT and was not administered anticoagulation. Sluggish blood flow in the PV after embolization, the PV's large diameter, and embolic agent migration to the PV may all influence PVT after transarterial embolisation.<sup>2,4</sup> Chen et al suggested that coil migration into the PV could cause thrombosis.<sup>14</sup> Hirakawa et al reported spontaneous PVT with no coil migration in a case series.<sup>2</sup> Three of the four patients with PVT as a result of trans arterial embolisation (TAE) were administered warfarin in their study; however, only one patient's PVT improved. The other three patients who were treated with or without anticoagulant medication had a persistently thrombosed native PV main trunk and a patent intrahepatic PV via cavernous transformation in the hepatic hilum on follow-up CT.

From our experience, we can share that in cases with large high-flow fistulas, few steps are important to follow. First, the initial coils should be oversized (15–30%). Second, the side branch technique should be deployed where the initial end of the coil should be placed in one of the side branches so that the coil does not migrate. Controlled-release detachable coils, such as the interlocking detachable coil or Guglielmi detachable coil, can be used to avoid the risk of coil migration.<sup>2,7</sup> The next-generation vascular plugs, which may be placed using angiographic catheters, appear to be a promising choice for fistula embolization and could be used as the first line of treatment.

## Conclusion

APF is not only a cause of presinusoidal portal hypertension but also aggravates the pre-existing portal hypertension in cirrhotic patients that may lead to increased symptoms and decompensation. Imaging helps in its early detection, and timely intervention is of paramount importance to avoid its consequences. Endovascular management is the treatment of choice with the coil being the most common embolizing material. The use of glue, particularly in cirrhotic patients additionally, provides support to the coil scaffold and fastens embolization. One should be very cautious to avoid the potential complication of coil migration, particularly in large fistulae.

**Conflict of Interest**  
None declared.

## References

- 1 Kumar A, Ahuja CK, Vyas S, et al. Hepatic arteriovenous fistulae: role of interventional radiology. *Dig Dis Sci* 2012;57(10): 2703–2712
- 2 Hirakawa M, Nishie A, Asayama Y, et al. Clinical outcomes of symptomatic arterioportal fistulas after transcatheter arterial embolization. *World J Radiol* 2013;5(02):33–40

- 3 Guzman EA, McCahill LE, Rogers FB. Arterioportal fistulas: introduction of a novel classification with therapeutic implications. *J Gastrointest Surg* 2006;10(04):543–550
- 4 Mukund A, Maiwall R, Kumar Condati N. Angioembolization of post-traumatic intrahepatic arterioportal fistula presenting with portal hypertension. *J Clin Exp Hepatol* 2019;9(04):541–545
- 5 Preger L. Hepatic arteriovenous fistula after percutaneous liver biopsy. *Am J Roentgenol Radium Ther Nucl Med* 1967;101(03):619–620
- 6 Hellekant C. Vascular complications following needle puncture of the liver. *Clinical angiography. Acta Radiol Diagn (Stockh)* 1976;17(02):209–222
- 7 Akpek S, Ilgit ET, Cekirge S, Yücel C. High-flow arterioportal fistula: treatment with detachable balloon occlusion. *Abdom Imaging* 2001;26(03):277–280
- 8 Srivastava DN, Sharma S, Pal S, et al. Transcatheter arterial embolization in the management of hemobilia. *Abdom Imaging* 2006;31(04):439–448
- 9 Roux P, Hébert T, Angheliescu D, Kerneis J, Nonent M. Endovascular treatment of arterioportal fistula with the Amplatzer occlusion device. *J Vasc Interv Radiol* 2009;20(05):685–687
- 10 Anand RR, Cherian PM, Mehta P, Gandhi JM, Elango S, Patil SB. Endovascular treatment of pseudoaneurysm arising from common hepatic artery bifurcation with complete disruption of gastroduodenal artery and high flow arterioportal fistula. *Ann Hepatobiliary Pancreat Surg* 2019;23(02):187–191
- 11 Ward TJ, Marin ML, Lookstein RA. Embolization of a giant arterioportal fistula requiring multiple Amplatzer vascular plugs. *J Vasc Surg* 2015;62(06):1636–1639
- 12 Oguslu U, Uyanik SA, Gümüş B. Endovascular treatment of hepatic arterioportal fistula complicated with giant portal vein aneurysm via percutaneous transhepatic US guided hepatic artery access: a case report and review of the literature. *CVIR Endovasc* 2019;2(01):39. Doi: 10.1186/s42155-019-0084-y
- 13 Flum AS, Geiger JD, Gemmete JJ, Williams DM, Teitelbaum DH. Management of a traumatic hepatic artery pseudoaneurysm and arterioportal fistula with a combination of a stent graft and coil embolization using flow control with balloon remodeling. *J Pediatr Surg* 2009;44(10):e31–e36
- 14 Chen Q, Tack C, Morcos M, et al. Embolotherapy of an arterioportal fistula. *Cardiovasc Intervent Radiol* 2007;30(05):1047–1051