





Nodular Hidradenoma of the Lower Limb Impersonating as Sebaceous Cyst in a Young Female

Archana Shetty¹  Praveen Gnanadev² Nidha Gaffoor¹  Nirupama Murali¹

¹Department of Pathology, Dr. Chandramma Dayananda Sagar Institute of Medical Education and Research, Ramanagara, Karnataka, India

²Department of Surgery, Dr. Chandramma Dayananda Sagar Institute of Medical Education and Research, Ramanagara, Karnataka, India

Address for correspondence Nidha Gaffoor, Department of Pathology, Dr. Chandramma Dayananda Sagar Institute of Medical Education and Research, Ramanagara, Karnataka, India (e-mail: nidha.gaffoor@gmail.com).

J Health Allied Sci^{NU} 2023;13:137–140.

Abstract

Adnexal tumors possess a remarkable capacity for morphological diversity and often present with nonspecific clinical presentations. Definitive diagnosis is made on histopathology with categorization based on the predominant morphological component. We present a case of a 31-year-old woman, with a swelling in the upper one-third of the right leg suspected clinically to be an infected sebaceous cyst. Histopathological examination clinched the diagnosis of a nodular hidradenoma. We wish to present this case not only for its uncommon clinical presentation but also for the diverse spectrum of histomorphological features that can be exhibited by this tumor. The case also emphasizes to surgeons the importance of complete surgical resection given the chances of recurrence and rare cases of malignant transformation associated with this entity.

Keywords

- ▶ adnexa
- ▶ hidradenoma
- ▶ sebaceous
- ▶ skin

Introduction

Adnexal tumors of skin include a wide array of neoplasms, with time and again new terminologies and subtypes being incorporated. These lesions predominantly present as nodules anywhere over the body and are last on the list of clinical differentials.^{1,2}

Often, histopathological examination is definitive with special stains and immunohistochemistry (IHC) being an adjunct.³ Though surgical management is limited to wide excision and follow-up, the pathologist often remains muddled when overlapping morphological features are present.

We present a case of nodular hidradenoma of the leg in an adult woman, suspected to be a sebaceous cyst. Histopathological examination clinched the diagnosis.

Case Report

A 31-year-old woman presented with a slowly growing swelling over anterior aspect of the left leg for the last 6 months, associated with itching. On examination, a solitary, firm, non-tender swelling of size 3 × 2 cm was noticed. Overlying skin had a bluish discoloration and a small ulcerated area. Scanty serous discharge was noted oozing out. X-ray, systemic examination, and routine blood investigations were normal. There was no history of trauma. With a clinical suspicion of an infected sebaceous cyst, an excision biopsy was done. Intraoperatively, the surgeon noticed a well-circumscribed swelling, with intact walls and absence of pus (▶ **Fig. 1a**).

The specimen was received in 10% formalin for histopathological examination. Grossly, a pearly white, firm, lobulated

article published online
June 22, 2022

DOI <https://doi.org/10.1055/s-0042-1746426>.
ISSN 2582-4287.

© 2022. Nitte (Deemed to be University). All rights reserved.
This is an open access article published by Thieme under the terms of the Creative Commons Attribution-NonDerivative-NonCommercial-License, permitting copying and reproduction so long as the original work is given appropriate credit. Contents may not be used for commercial purposes, or adapted, remixed, transformed or built upon. (<https://creativecommons.org/licenses/by-nc-nd/4.0/>)
Thieme Medical and Scientific Publishers Pvt. Ltd., A-12, 2nd Floor, Sector 2, Noida-201301 UP, India

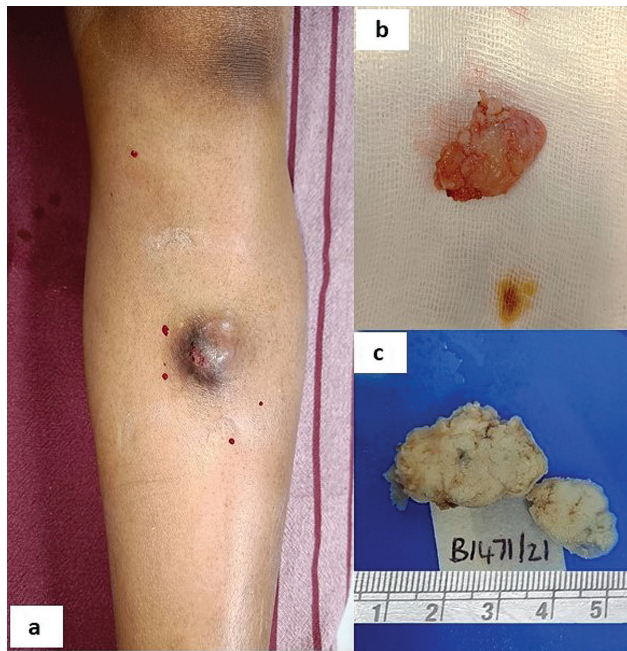


Fig. 1 (a) Nodular lesion over the upper one-third of the right leg. (b) Excised lesion. (c) Cut section showing a well-circumscribed gray-white solid-to-cystic lobular lesion.

mass measuring $2.8 \times 2.3 \times 2$ cm was noted with focal cystic areas (►Fig. 1b, c). Microscopy showed an unencapsulated solid and cystic tumor in the dermis with lobular architecture. Solid portion consisted of nests and lobules of cells

having finely granular, faintly eosinophilic cytoplasm with a dark-colored round-to-oval nucleus, showing nuclear grooves. Pale round cells with clear cytoplasm were seen along with few duct-like structures and interspersed clear cells. Mucin secretion was noted at places (►Fig. 2). Angio-lymphatic invasion, extension to deeper structures and necrosis were absent. Mitotic activity of less than 2 per 10 high-power fields was noted. The surgically resected tumor margins were free of tumor. A diagnosis of nodular hidradenoma was conferred. The patient was advised for regular follow-up at frequent intervals when she visited for suture removal. Till date, postexcision follow-up at 2, 4, and 6 months has shown no signs of recurrence.

Discussion

Adnexal tumors arise from hair follicles and sebaceous, apocrine, and eccrine glands. Some exhibit more than one line of appendageal differentiation, making their classification confusing. A less complicated approach to categorize is to assess structure of origin, look for signs of malignancy, and rule out metastasis or a part of syndrome.³

Nodular hidradenoma is a rare benign adnexal tumor with debatable tissue of origin between eccrine and apocrine frequently encountered in head and neck region, trunk, and extremities.⁴ The tumor affects all ages and is seen more commonly in females. Though limb as site of tumor has been reported in literature, incidence is sparse, comprising approximately 1% of all skin tumors.⁵ Clinically, it appears

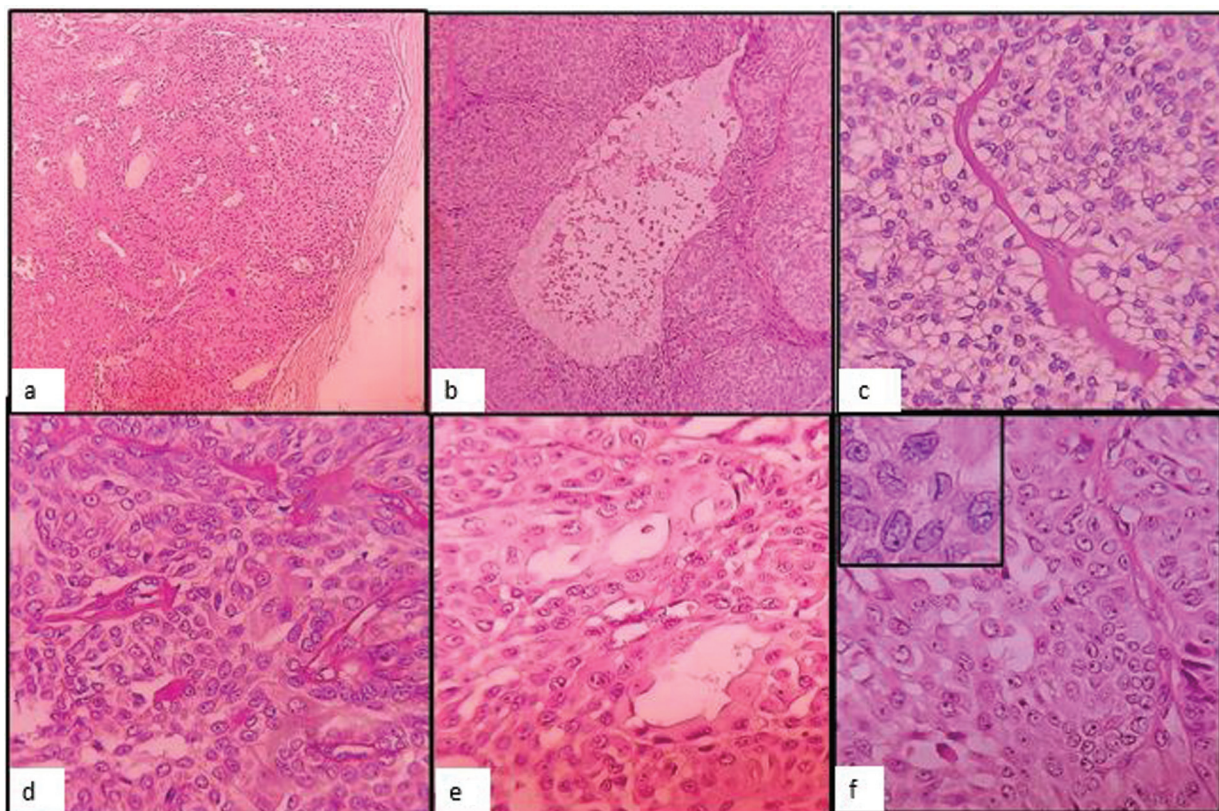


Fig. 2 (a) A well-circumscribed dermal tumor. (b) Cystic spaces. (c) Clear cells. (d) Hyalinized vascularized fibrous stroma. (e) Duct-like luminal structures by apocrine cells. (f) Nuclear grooves. H&E stain $\times 400$ (inset).

Table 1 Differences between atypical and malignant hidradenoma

Atypical hidradenoma (risk of recurrence and malignant transformation) ¹⁰	Malignant hidradenoma (risk of metastasis) ¹⁰
Focal/total loss of circumscription, increased cystic spaces Ki-67n and PHH3 expression: lower	Deep extension, infiltrative growth pattern, large zones of necrosis, nuclear pleomorphism and >4 mitoses per 10 HPFs Ki-67n and PHH3 expression: high

Note: Ki-67n- Ki-67 nuclear protein HPF- High Power Field PHH3- Phosphohistone H3.

as a small, solitary, slow-growing nodule with intact skin. Some exhibit surface ulceration or serous fluid leakage. Clinical differentials include lipoma, epidermal inclusion cyst (as in our case), basal cell carcinoma, and pyogenic granuloma.⁶

Microscopically, it is well-circumscribed but not encapsulated and is located in the dermis. It is known to exhibit a wide array of histological patterns as evidenced by its synonyms: nodular hidradenoma, eccrine acrospiroma, solid-cystic hidradenoma, clear cell acrospiroma, clear cell myoepithelioma, and eccrine sweat gland adenoma.⁷ Clear cell change and/or squamous metaplasia may be prominent when metastatic clear cell tumor (positive for PAX8 and CD10, negative for p63) needs to be considered. Cystic spaces are formed due to dilated eccrine ducts.⁸ Nuclear grooving has been described as a useful morphological feature to aid diagnosis.⁹ The differential of eccrine poroma was ruled out as there was absence of poroid cells, which are small, cuboidal cells with round-to-oval nuclei. Trichilemmoma was ruled out as broad connection with the epidermis and peripheral cell palisading were not noted.

Majority of the histological features were present in varying proportions in our case that favored hidradenoma in including features of apocrine differentiation such as decapitation secretion, mucinous secretion, and sebaceous metaplasia.

Classification

Recent literature has categorized hidradenomas into those with apocrine differentiation (known as clear cell hidradenoma) and those with eccrine differentiation (known as poroid hidradenoma). The apocrine type accounts for 95% of all hidradenomas and is composed of clear, polygonal, and mucinous cells with apocrine differentiation. The eccrine or poroid type, which constitutes 5% of hidradenomas, is characterized by a single or multilobulated dermal nodule with no connection to the epidermis, is solid to cystic, and consists of two cell types, poroid and cuticular.^{4,5} An alternative system classifies hidradenomas as: clear cell, solid-cystic, mucinous and poroid, and pigmented nodular hidradenomas depending on the predominant component.

It is important to look for indicators that stratify them as atypical or malignant (→ **Table 1**). A study by Nazarian et al⁹ has shown duct formation, hyalinized stroma, clear cell change, epidermoid morphology, pseudoinclusions, and

nuclear grooving in both atypical and malignant hidradenomas. Importance of recognizing and reporting the atypical type implies risk of recurrence and possible malignant potential, unlike the malignant countertype, which has risk of metastasis.¹⁰ IHC demonstrates positive staining with antibodies against CK-CAM 5.2, BER-EP4, p63, epithelial membrane antigen, S-100 protein, smooth muscle actin, and vimentin in tumor cells. However, the role of IHC in hidradenoma is more of an adjunct than diagnostic and is not routinely indicated.⁵ Genetically, t(11;19) translocation has been reported in a few cases of hidradenoma.^{4,5}

Recurrence is common, up to 10%, mostly due to inadequate excision and sprouts of tumor tissue located between dermis and subcutaneous tissue, with possibility of malignant transformation being reported in up to 7% of all cases.¹⁰ These factors highlight the need for complete surgical excision with wide surgical margins and clinical follow-up. However, there is no consensus regarding criteria for optimal surgical margins of excision in literature.⁴

Conclusion

Nodular hidradenoma is a clinical masquerade. It is noteworthy for pathologists to be aware of its diverse histological components and look for morphological features that aid in differentiating this tumor as benign, atypical, or malignant as each has different clinical implications for the treating surgeon.

Details of Earlier Presentation

None.

Statement of Institutional Review Board Approval and/or Statement of Conforming to the Declaration of Helsinki
Not applicable.

Brief Background

We wish to present this case as it is of academic interest and intrigue to practising pathologists. The case highlights the importance of close observation of varied histopathological features that can be seen in this tumor.

We would also want to impress on the fact that the use of IHC can be restricted in cases like these where a routine H&E by itself can be diagnostic.

Source of Support

None.

Conflict of Interest

None declared.

References

- 1 Fulton EH, Kaley JR, Gardner JM. Skin adnexal tumors in plain language: a practical approach for the general surgical pathologist. *Arch Pathol Lab Med* 2019;143(07):832–851
- 2 El Ochi MR, Boudhas A, Allaoui M, et al. Skin adnexal tumors: histological study about 96 cases [in French]. *Pan Afr Med J* 2015; 20:389
- 3 Agarwal A, Agarwal P, Anand A, et al. Nodular hidradenocarcinoma, tricholemmal carcinoma and squamous cell carcinoma with clear cell changes: pitfalls of biopsy diagnosis of skin and adnexal tumours. *Clin Pathol* 2021;14;. Doi: 2632010X211033840
- 4 Bijou W, Laababsi R, Oukessou Y, et al. An unusual presentation of a nodular hidradenoma: a case report and review of the literature. *Ann Med Surg (Lond)* 2020;61:61–63
- 5 Das A, Gayen T, Podder I, Shome K, Bandyopadhyay D. A weeping tumor in a young girl: an unusual presentation of nodular hidradenoma. *Indian J Dermatol* 2016;61(03):321–323
- 6 Kumar P, Das A, Savant SS. Poroid hidradenoma: an uncommon cutaneous adnexal neoplasm. *Indian J Dermatol* 2017;62(01): 105–107
- 7 Yao C, Swaby MG, Migden MR, Silapunt S. A nodular hidradenoma of atypical location in pregnancy. *Acta Derm Venereol* 2018;98 (09):908–909
- 8 Nandeesh BN, Rajalakshmi T. A study of histopathologic spectrum of nodular hidradenoma. *Am J Dermatopathol* 2012;34(05): 461–470
- 9 Nazarian RM, Kapur P, Rakheja D, et al. Atypical and malignant hidradenomas: a histological and immunohistochemical study. *Mod Pathol* 2009;22(04):600–610
- 10 Ngo N, Susa M, Nakagawa T, et al. Malignant transformation of nodular hidradenoma in the lower leg. *Case Rep Oncol* 2018;11 (02):298–304