



# Thyroid Storm Presenting with Isolated Acute Bulbar Myopathy: A Case Report and Literature Review

Asma AlNeyadi<sup>1</sup> Manal AlKhanbashi<sup>1</sup> Fatima AlKaabi<sup>2</sup> Mohamed Ismail<sup>2</sup>

<sup>1</sup> Internal Medicine Department, Tawam Hospital, Al Ain, United Arab Emirates

<sup>2</sup> Department of Endocrinology, Tawam Hospital, Al Ain, United Arab Emirates

**Address for correspondence** Fatima AlKaabi, MD, Department of Endocrinology, Tawam Hospital, 132 Mohammed Bin Khalifa Street, Al Ain, 15258, United Arab Emirates (e-mail: drfmkaabi@gmail.com).

J Diabetes Endocrine Practice 2022;5:83–86.

## Abstract

While proximal skeletal muscle myopathy is a frequently reported complication of thyrotoxicosis, acute bulbar thyrotoxic myopathy is rare especially in absence of other forms of myopathy. In this report, we present a case of 31 years old male presenting with thyrotoxicosis and aspiration pneumonia following weeks of experiencing dysphagia and hoarseness of voice. Labs confirmed Graves' disease and other causes of bulbar myopathy like Myasthenia gravis was ruled out. He was started on thyroid treatment and showed remarkable improvement of dysphagia over 15 days. Based on this, we conclude that isolated bulbar myopathy in hyperthyroidism should be considered in patients presenting with dysphagia and dysphonia in absence of other possible neurological causes.

## Keywords

- ▶ bulbar myopathy
- ▶ Graves' disease
- ▶ thyrotoxic myopathy

## Introduction

Hyperthyroidism is well recognized cause of myopathy. Acute bulbar myopathy is rare and rapidly progressive complications of thyrotoxic myopathy. It has been reported in 16.4% of patients with chronic thyrotoxic myopathy.<sup>1</sup> We present the case of a young male who presented with thyrotoxic crises and aspiration pneumonia caused by acute bulbar myopathy in absence of other features of thyrotoxic myopathy.

## Case Presentation

A 31-year-old male previously healthy presented to our emergency department with days' history of high-grade

fever, cough productive of whitish sputum, dysphagia, and watery nonbloody diarrhea.

He described gradual weight loss of approximating to 14 kg over the preceding 12 months, heat intolerance, tremors, palpitations, increase in appetite, intermittent diarrhea, and gradual hoarseness of his voice that has developed over the last 2 months. He also described few episodes of choking while drinking or eating that started 2 weeks prior to his presentation.

Physical examination revealed sick cachectic young man with body mass index of 15.05 kg/m<sup>2</sup>. He was looking anxious, sweaty, and agitated. His tympanic membrane temperature was 37.6°C, heart rate was 125 beats per minute (bpm), respiratory rate of 17 bpm, blood pressure 124/86 mm Hg, and SpO<sub>2</sub> 98% on room air.

DOI <https://doi.org/10.1055/s-0042-1749074>.  
ISSN 2772-7653.

© 2022. Gulf Association of Endocrinology and Diabetes (GAED). All rights reserved.

This is an open access article published by Thieme under the terms of the Creative Commons Attribution-NonDerivative-NonCommercial-License, permitting copying and reproduction so long as the original work is given appropriate credit. Contents may not be used for commercial purposes, or adapted, remixed, transformed or built upon. (<https://creativecommons.org/licenses/by-nc-nd/4.0/>)

Thieme Medical and Scientific Publishers Pvt. Ltd., A-12, 2nd Floor, Sector 2, Noida-201301 UP, India

Eye examination revealed normal conjunctiva, lid lag, but no proptosis. His thyroid gland was diffusely enlarged with grade III soft vascular nontender goiter that did not extend retrosternally.

Precordial examination was normal apart from tachycardia.

There were coarse crackles at left lung base, and there were no abnormal abdominal findings. Neurological examination revealed hoarse soft voice. The uvula was central but there was no palatal movement noted on gag reflex.

The patient was looking emaciated with obvious loss of muscle mass and there was no evidence of upper or lower muscle weakness with normal power in all muscle groups. All deep tendon reflexes were symmetrical and brisk. There was no sensory loss, no cerebellar signs, and his gait was normal.

His initial investigations revealed normal sodium and potassium level, hyperchloremic normal anion gap acidosis, and normal renal function. His thyroid panel confirmed severe hyperthyroidism with suppressed thyroid-stimulating hormone (TSH) < 0.005 mIU/L, elevated free T4 > 100 pmol/L, normal aspartate transaminase and alanine aminotransferase, but his C-reactive protein was significantly elevated.

An electrocardiography showed sinus rhythm tachycardia with heart rate of 110 bpm.

Chest X-ray showed opacity in left lower zone consistent with pneumonia (► **Table 1**).

We admitted the patient as a case of thyroid storm with Burch and Wartofsky Point Scale score of 50 points precipitated by bacterial acquired pneumonia.

He was started on intravenous fluid hydration, antipyretics, intravenous hydrocortisone 50 mg every 8 hours, and intravenous ceftriaxone and azithromycin. We also started him on propylthiouracil 200 mg every 8 hours along with propranolol 40 mg three times daily.

Hydrocortisone was later converted to dexamethasone 2 mg three times daily, and we added 2% Lugol's iodine solution 10 drops three times daily and cholestyramine 4 g three times daily.

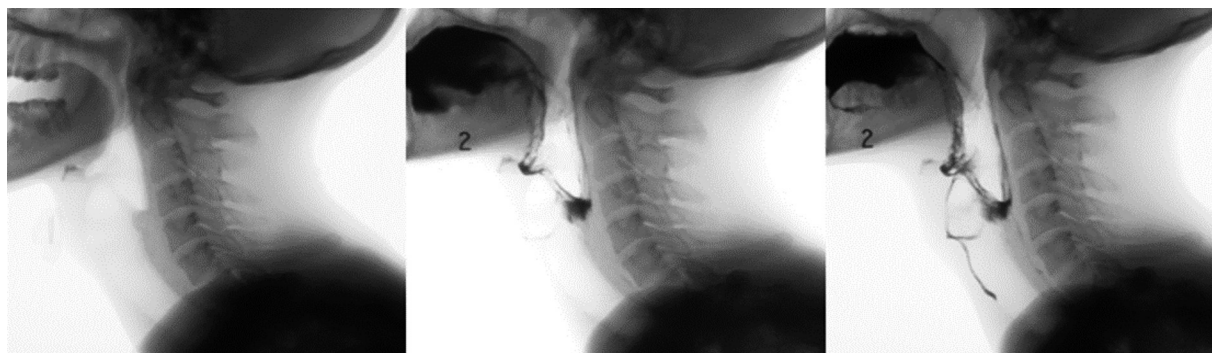
Thyroid receptor antibody returned markedly elevated (> 40 IU/L [reference range ≤ 1.75]) and antithyroid peroxidase antibodies were moderately elevated as well 201 IU/mL (reference range ≤ 34).

Creatinine kinase was not elevated 27 IU/L (39–308 IU/L), and syphilis screening was negative.

**Table 1** Laboratory data

Variable	Reference range	During admission	On discharge
Hemoglobin (g/dL)	11.6–14.8	11.1	14.4
Hematocrit (%)	35.1–44.4	32	43
White blood cell count (per $\mu$ L)	4.5–11.0	19.1	14.9
Neutrophils (%)	0.0–2.5	77.30	12.29
Lymphocytes (%)	16.5–49.5	14.20	2.02
Monocytes (%)	2.0–10.0	8.30	0.55
Eosinophil (%)	0.0–8.5	0.10	0.03
Platelet count (per $\mu$ L)	158,000–348,000	248,000	244,000
Sodium (mmol/L)	135–145	138	134
Potassium (mmol/L)	3.6–4.8	4.0	4.5
Chloride (mmol/L)	101–108	106	99
Creatinine ( $\mu$ mol/L)	61–106	34	38
Urea nitrogen (mmol/L)	2.80–8.10	4.0	5.30
Alanine aminotransferase (IU/L)	Normal high ≤ 41	34	22
Aspartate aminotransferase (IU/L)	Normal high ≤ 40	34	96
Alkaline phosphatase (IU/L)	40–129	215	146
C-reactive protein (mg/dL)	Normal high ≤ 5	30.0	3
FT4 (pmol/L)	12.0–22.0	> 100	24.4
TSH ( $\mu$ LU/mL)	0.400–4.200	< 0.005	0.005
Thyroid receptor antibodies	Normal high ≤ 1.75	> 40	NA
TPO antibodies	Normal high ≤ 34	201	NA
Ach R binding antibodies	Normal high ≤ 0.02	< 0.02	NA

Abbreviations: Ach R, acetylcholine receptor; TPO, thyroid peroxidase; TSH, thyroid-stimulating hormone.



**Fig. 1** X-ray of swallowing function.

Thyroid ultrasound showed diffusely enlarged hypoechoic thyroid gland with hypervascular gland consistent with Graves' disease.

A video fluoroscopic swallowing exam was arranged to evaluate the patient's dysphagia and it confirmed aspiration due to upper esophageal motility dysfunction as shown in **Fig. 1**.

Patient was reviewed by the speech and language therapy team and the dietician who recommended nasogastric tube feeding but the patient refused this procedure.

We consulted the neurology team to rule out Myasthenia gravis in view of the dysphagia in association with Graves' disease.

Following their assessment, repetitive nerve stimulation study was arranged but the result was inconclusive as the patient could not tolerate the procedure. Serum acetylcholine receptor antibodies was sent and returned negative. Computed tomography scan of the thorax revealed no evidence of thymoma, retrosternal goiter, or other masses causing compression on the esophagus.

The patient condition continued to improve with resolution of the symptoms of severe hyperthyroidism.

His thyroid function improved significantly, TSH 0.005 mIU/L, free T4 24.4 pmol/L, and free T3 6.20.

The patient also reported improvement in swallowing and hoarseness of voice back to his normal self.

A repeat video fluoroscopic swallowing exam was arranged on day 15 of admission and no evidence of aspiration was found, as shown in **Fig. 2**.

The patient was discharged home on propylthiouracil 100 mg three times daily and propranolol 20 mg three times daily, with follow-up arranged in the endocrinology outpatient clinic.

The improvement of patient's symptoms in parallel with the improvement of thyroid function is highly suggestive of thyroid storm being the cause of acute bulbar myopathy.

## Discussion

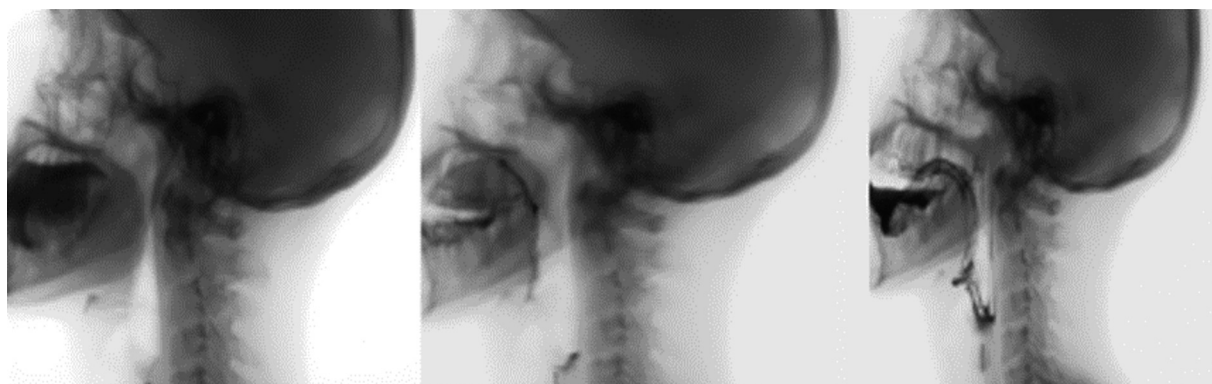Untreated hyperthyroidism is well known to affect muscle function and it results in chronic muscle weakness and wasting secondary myopathy.

The first case of thyrotoxic myopathy was described in 1885 by Du Caza<sup>2</sup> and the first documented detailed pathological description of chronic thyrotoxic myopathy was reported by Askanazy in 1898.<sup>3</sup>

Thyrotoxic myopathy is known to affect the skeletal muscles and isolated involvement of the esophageal muscles is unusual and quite rare.<sup>4,5</sup>

The esophagus wall is composed of striated muscle in the upper part, smooth muscle in the lower part, and a mixture of the two in the middle and it is this unique anatomical structure of the esophagus that makes the upper third the main site of involvement in cases of thyrotoxic myopathy.

The exact mechanism leading to thyrotoxic myopathy is not fully understood but it is likely that thyroid receptor antibodies play a role as well as direct action of increased levels of thyroid hormone on the muscle fiber's mitochondria



**Fig. 2** X-ray of swallowing function.

leading to increased oxidative stresses and depletion of adenosine triphosphate (ATP) in the muscle fibers which results into muscle fiber atrophy and muscle weakness.<sup>2</sup>

Riis et al showed that human muscle fibers obtained from hyperthyroid patients with muscle weakness contained unexpected elevated Na<sup>+</sup>-K<sup>+</sup>-ATPase content compared with euthyroid subjects.<sup>6</sup> This is an interesting observation as these hyperthyroid patients usually suffer from muscle weakness or frank myopathy despite having increased skeletal muscle K<sup>+</sup>-ATPase content which is contrary to the upregulation of K<sup>+</sup>-ATPase induced by physical training.

Korényi-Both et al developed experimental model of thyrotoxic myopathy that confirmed that the involved muscle fibers included type I (slow twitch) and type II (fast twitch) muscle fibers with muscle fiber atrophy in humans largely affecting type II muscle fibers.<sup>3</sup>

Miyashita et al demonstrated that elevated levels of T4 reduces the contractility of canine muscle diaphragm and they showed that the reduced contractility was the result of loss of muscle.<sup>7</sup>

Thyroid hormone exerts significant role on the function of neuromuscular system and the brain and in hyperthyroidism patients can present with variety of neuromuscular dysfunctions including thyrotoxic myopathy, thyrotoxic-associated periodic hypokalemic paralysis, and thyrotoxic-associated Myasthenia gravis. Some of the clinical manifestations can be caused by the associated neurological disorder such as Myasthenia gravis rather than by the hyperthyroidism.<sup>8</sup>

Our patient presented with thyrotoxic crisis and evidence of aspiration pneumonia with clinical examinations confirming isolated bulbar myopathy causing esophageal motility dysfunction leading to repeated aspiration. Myasthenia gravis and mechanical causes of dysphagia were both ruled out.

In our case, treatment of thyrotoxic crisis with combination of dexamethasone, Lugol's iodine, antithyroid medications, cholestyramine, and propranolol controlled the thyrotoxic state promptly and led to resolution of the patient's dysphagia over the course of 3 weeks.

We arrived at the diagnosis of isolated acute thyrotoxic bulbar myopathy in our patient in view of the confirmed upper esophageal swallowing abnormality confirmed on the video fluoroscopy exam which resolved with successful treatment of the severe hyperthyroidism.

The absence of acetyl choline receptor antibodies and the rapid improvement of the swallowing defect with the

treatment of severe hyperthyroidism argue against Myasthenia gravis as an alternative diagnosis.

The main limitation of our case is related to incomplete neuromuscular testing as the patient was not able to tolerate the repetitive nerve stimulation test.

## Conclusion

Acute bulbar thyrotoxic myopathy can be the cause of acute dysphagia or aspiration pneumonia in patients with hyperthyroidism in rare cases.

### Authors' Contribution

All authors critically revised the report, commented on the drafts of the manuscript, and approved the final report.

### Compliance with Ethical Principles

We have obtained informed consent from the patient for publication of this case report.

### Funding and Sponsorship

None.

### Conflict of Interest

None declared.

## References

- 1 Kammer GM, Hamilton CR Jr. Acute bulbar muscle dysfunction and hyperthyroidism. A study of four cases and review of the literature. *Am J Med* 1974;56(04):464-470
- 2 Ramsay I. Thyrotoxic muscle disease. *Postgrad Med J* 1968;44(511):385-397
- 3 Korényi-Both A, Korényi-Both I, Kayes BC. Thyrotoxic myopathy. Pathomorphological observations of human material and experimentally induced thyrotoxicosis in rats. *Acta Neuropathol* 1981; 53(03):237-248
- 4 Noto H, Mitsuhashi T, Ishibashi S, Kimura S. Hyperthyroidism presenting as dysphagia. *Intern Med* 2000;39(06):472-473
- 5 Mathew B, Devasia AJ, Ayyar V, Thyagaraj V, Francis GA. Thyrotoxicosis presenting as acute bulbar palsy. *J Assoc Physicians India* 2011;59(06):386-387
- 6 Riis ALD, Jørgensen JOL, Møller N, Weeke J, Clausen T. Hyperthyroidism and cation pumps in human skeletal muscle. *Am J Physiol Endocrinol Metab* 2005;288(06):E1265-E1269
- 7 Miyashita A, Suzuki S, Suzuki M, et al. Effect of thyroid hormone on in vivo contractility of the canine diaphragm. *Am Rev Respir Dis* 1992;145(06):1452-1462
- 8 Kung AWC. Neuromuscular complications of thyrotoxicosis. *Clin Endocrinol (Oxf)* 2007;67(05):645-650