



Prolapsing Left Atrial Mass Presenting as Syncope

Presheet Pathare, MBBS¹  Michael Weyand, MD¹ Christian Heim, MD¹ 

¹Department of Cardiac Surgery, Friedrich Alexander University of Erlangen-Nuremberg, Erlangen, Germany

Address for correspondence Presheet Pathare, Herzchirurgie, Universitätsklinikum Erlangen, Krankenhausstraße, 12, Erlangen 91054, Germany (e-mail: preshmew@hotmail.com).

Thorac Cardiovasc Surg Rep 2022;11:e44–e46.

Abstract

Keywords

- ▶ myxoma
- ▶ neurological symptom
- ▶ tumor, cardiac imaging

Background Myxomas are the most common primary cardiac tumor in adults and are most commonly found within the left atrium. These are usually asymptomatic, detected incidentally, or present gradually with symptoms typical of heart failure.

Case Description This case report is a description of a case of syncope caused by a large left atrial myxoma.

Conclusion Atrial myxomas may present with transient loss of consciousness, especially when they prolapse through the atrioventricular valves or when embolization occurs. Non-invasive diagnostic tools (e.g., echocardiogram, cardiac computed tomography) should be considered to thoroughly evaluate cardiogenic causes of syncope.

Introduction

Myxomas are the most common primary cardiac tumor in adults and are most commonly found within the left atrium¹ with an incidence of 0.5 to 1 cases per million in the general population, with females being affected three times more often as compared with males.² These benign tumors are usually asymptomatic, detected incidentally, or present gradually with symptoms typical of heart failure. Other symptoms may include constitutional symptoms—i.e., symptoms of autoimmune disease, vasculitis, and various other non-specific symptoms or embolic symptoms, most frequently cerebral emboli.³ Following is a description of a case of syncope caused by left atrial myxoma.

Case Description

A 46-year-old female patient presented to the emergency department with syncope and dyspnea. Using the ESC guidelines for the evaluation of transient loss of consciousness,² a

complete history was taken followed by thorough physical examination. Cardiovascular risk factors included adipositas (body mass index 41.5 kg/m²) and active smoking (30 pack years). No other significant diseases were known. There were no previous instances of similar episodes of unconsciousness. On presentation, the patient was conscious with stable vital parameters. The electrocardiography (ECG) revealed a right bundle branch block. Considering the clinical constellation presented above, an emergency cranial and thoracic CT with contrast was performed to rule out pulmonary embolism and intracerebral bleeding after syncope, in preparation of possible lysis. Here, a giant mass in the left atrium was discovered, which on further diagnosis via echocardiography was shown to occlude the mitral valve during atrial systole. Then the patient was referred to our Cardiac Surgery Department for urgent removal of the hemodynamically relevant tumor, which was performed within 12 hours of admission. Due to the urgent indication for surgery and lack of calcified coronary plaques on the CT, further invasive diagnosis for coronary artery disease was omitted in the

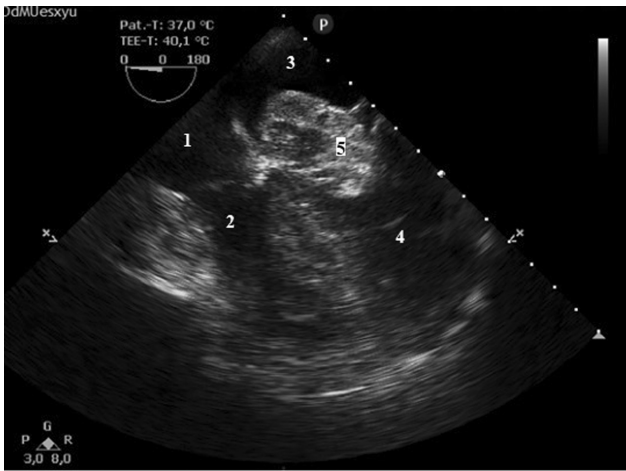
received
December 17, 2021
accepted
January 24, 2022

DOI <https://doi.org/10.1055/s-0042-1749140>.
ISSN 2194-7635.

© 2022. The Author(s).

This is an open access article published by Thieme under the terms of the Creative Commons Attribution-NonDerivative-NonCommercial-License, permitting copying and reproduction so long as the original work is given appropriate credit. Contents may not be used for commercial purposes, or adapted, remixed, transformed or built upon. (<https://creativecommons.org/licenses/by-nc-nd/4.0/>)

Georg Thieme Verlag KG, Rüdigerstraße 14, 70469 Stuttgart, Germany



Transesophageal echocardiography showing:
 1. Right atrium
 2. Right ventricle
 3. Left atrium
 4. Left ventricle
 5. Atrial myxom prolapsing through mitral valve

Fig. 1 Transesophageal echocardiography showing a mass arising from the left atrium, prolapsing into the left ventricle, occluding the area of the mitral valve.

46-year-old female patient. An intraoperative transesophageal echocardiogram confirmed the floating structure in the left atrium with recurring prolapse into the left ventricle through the mitral valve (► **Fig. 1, 4** ► **Videos 1 & 2**). In view of the size of the tumor a median sternotomy was preferred to ease access into the left atrium possibly via the atrial roof or transeptal approach. Total bicaval cardiopulmonary bypass was established to allow complete removal of tumor. Antegrade warm blood cardioplegia (Calafiore) was given once. After left atriotomy posterior to the interatrial sulcus, the myxoma was found attached to the middle of the interatrial septum. The septum was opened during the in toto resection of the myxoma along with its base (► **Fig. 2**). The incision in the septum was directly closed using 4-0 Prolene. Cardiopulmonary bypass time was 27 minutes and cross clamp time was 18 minutes, respectively. The patient

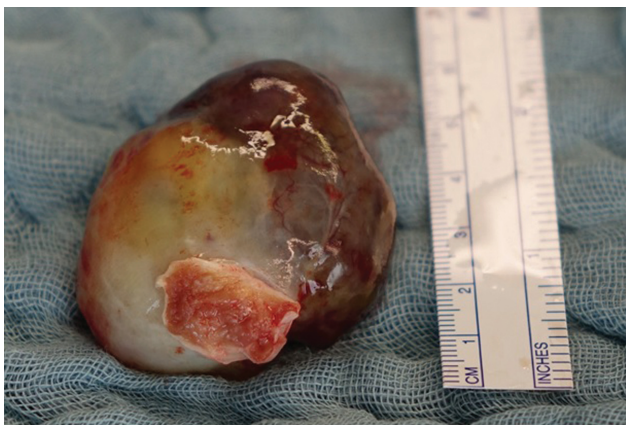

Fig. 2 Myxoma after in toto resection from the left atrium with myocardial stump. Note the large size responsible for symptoms (scale for comparison).

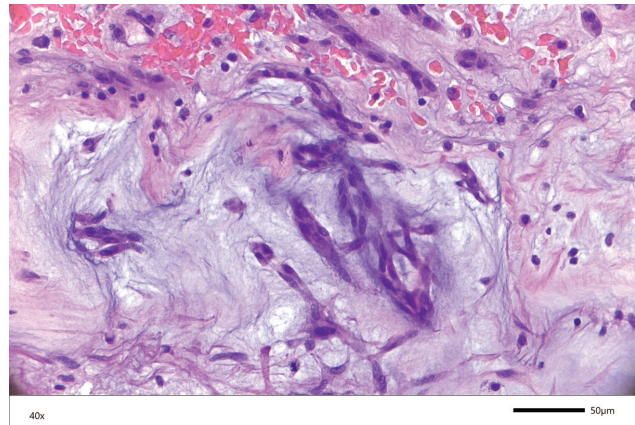
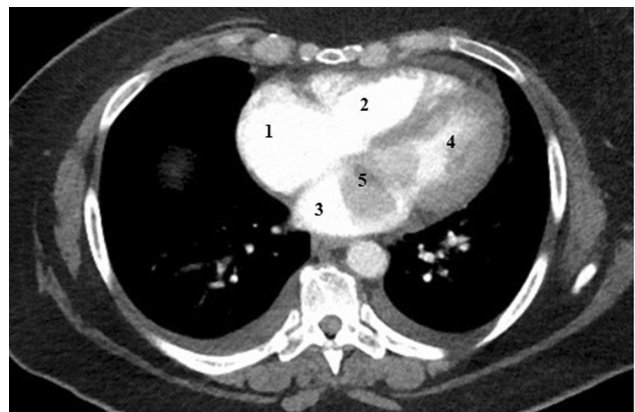


Fig. 3 Representative histology of a myxoma in 40x, Gryphax Subra Camera [Jenoptik, Jena] with Plan Fluotar Objektiv, Leica, DM 4000B Microscope [Leica, Wetzlar] showing the cellular structure and matrix of a myxoma.

did not require blood transfusion intraoperatively or post-operatively. The histopathological analysis confirmed the diagnosis of a giant left atrial myxoma (► **Fig. 3**, Histology in 5x and 40x, Gryphax Subra Camera [Jenoptik, Jena] with Plan Fluotar Objektiv, Leica, DM 4000B Microscope [Leica, Wetzlar]). The patient could be weaned from cardiopulmonary bypass, extubated on the fast track intensive care unit, and transferred to the cardiac ward. She made a full and uneventful recovery postoperatively and could be discharged for rehabilitation on postoperative day 6. As per standard, prophylactic anticoagulation preoperatively and postoperatively was prescribed. After mobilization of the patient and on discharge no further anticoagulation was deemed necessary. A routine follow-up after a 3 week rehabilitation period was performed. Furthermore, we recommended annual visits to a cardiologist. Local recurrence appears highly



1. Right atrium 2. Right ventricle
 3. Left atrium 4. Left ventricle
 5. Atrial myxom prolapsing through mitral valve

Fig. 4 Computer tomography with contrast showing a mass in the left atrium, prolapsing into the left ventricle. Note the reduced contrast material in the left ventricle due to obstruction of blood flow caused by the mass.

unlikely as the base of the myxoma was excised and should be noticed early in yearly follow-up.

Discussion

Syncope is defined as a transient loss of consciousness due to cerebral hypoperfusion, characterized by a rapid onset, short duration, and spontaneous complete recovery. Current guidelines recommend classifying every transient loss of consciousness as syncope until another cause can be found (e.g., epilepsy, metabolic causes, psychological causes).

The initial work-up of a patient with syncope should include a thorough history (including history from those present during the incident) and examination, ECG, and a Schellong test. With these examinations, a differential diagnosis can be made and further diagnostic tests and/or treatment can be performed depending on the probable cause (vasovagal, orthostatic, cardiogenic causes of syncope, postural tachycardia syndrome, or other causes of transient loss of syncope).³

Cardiogenic syncope caused by arrhythmias or ischemia can be ruled out on ECG, if apparent at presentation. However, other cardiac causes of syncope, especially those associated with structural changes in the heart (e.g., valvular pathologies, congenital heart diseases, intracardiac tumors) require further diagnosis. This includes, appropriate laboratory parameters, Holter monitoring, echocardiogram, and exercise stress test.⁴ An accurate diagnosis can usually be achieved using these non-invasive methods.

Depending on the underlying disease, further imaging may be required to confirm the diagnosis and plan further treatment. Cardiac CT can be used to observe intracardiac tumors or thrombus formation,⁵ though more invasive transesophageal echocardiogram provides a sensitive and specific modality for anatomical changes in the heart.

Atrial myxomas have a typical shape, origin, mobility and may show a tendency to prolapse, as seen in the above figures. Most are small tumors which are asymptomatic. With increasing size atrial myxomas may cause symptoms and most commonly present with dyspnea, signs of heart failure (left or right depending on the location), and embolization. A minority of patients present with neurological symptoms such as dizziness and syncope.⁶ The above modalities also help differentiate and diagnose other conditions that may present with similar symptoms (e.g., pulmonary embolism).

Atrial myxomas may present with transient loss of consciousness, especially when they prolapse through the atrioventricular valves or when embolization occurs. Non-invasive diagnostic tools (e.g., echocardiogram, cardiac computed tomography) should be considered to thoroughly evaluate cardiogenic causes of syncope.

List of Abbreviations

AV: atrioventricular
 BMI: body mass index
 CT: computer tomography
 ECG: electrocardiography
 ESC: European society of Cardiology
 POD: postoperative day
 TLOC: transient loss of consciousness
 CPB: cardiopulmonary bypass

Video 1

Online content including video sequences viewable at: <https://www.thieme-connect.com/products/ejournals/html/10.1055/s-0042-1749140>.

Video 2

Online content including video sequences viewable at: <https://www.thieme-connect.com/products/ejournals/html/10.1055/s-0042-1749140>.

Conflict of Interest

None declared.

Acknowledgments

We thank the Department of Pathology at Universitätsklinikum Erlangen, Dr. Geppert and Prof. Agaimy for providing the histopathology pictures.

References

- 1 Hecht SM. A review of: "Current Diagnosis & Treatment: Cardiology. 3rd ed. Crawford, Michael H., ed.". Quarterly 2009;28(04):401–402
- 2 Yoon DH, Roberts W. Sex distribution in cardiac myxomas. Am J Cardiol 2002;90(05):563–565
- 3 Biswas A, Thakur AK. An unusual presentation of atrial myxoma in an elderly patient: a case report. Cases J 2008;1(01):384
- 4 von Scheidt W, Bosch R, Klingenheben T, et al. Kardiologie Kommentar zu den Leitlinien (2018) der European Society of Cardiology (ESC) zur Diagnostik und Therapie von Synkopen. Der Kardiologe 2019;13:131–137
- 5 Guidelines for management of Syncope from the German Society of Neurology. Access 03 October 2021 at: https://www.awmf.org/uploads/tx_szleitlinien/030-0721_S1_Synkopen_2020-04.pdf
- 6 Brignole M, Moya A, de Lange FJ, et al; ESC Scientific Document Group. 2018 ESC Guidelines for the diagnosis and management of syncope. Eur Heart J 2018;39(21):1883–1948