



# Vancomycin-Induced Maturation Arrest with Reactive Promyelocyte Proliferation: A Diagnostic and Therapeutic Challenge

Iffat Jamal<sup>1</sup> Shuchismita<sup>1</sup> Vijayanand Choudhary<sup>1</sup>

<sup>1</sup> Department of Hematology, Indira Gandhi Institute of Medical Sciences, Patna, Bihar, India

Address for correspondence Shuchismita, MBBS, MD, Department of Hematology, Indira Gandhi Institute of Medical Sciences, Patna 800014, Bihar, India (e-mail: shuchi.smita123@gmail.com).

J Lab Physicians 2023;15:149–151.

## Abstract

### Keywords

- vancomycin
- maturation arrest
- promyelocyte
- proliferation
- bone marrow

Drug-induced leukopenia is a diagnostic and therapeutic challenge. A detailed clinical history is a must to come to a right diagnosis. Certain drugs are known to cause bone marrow suppression, leukopenia, myeloid maturation arrest, and reactive promyelocyte proliferation. Here, we report an unusual case of vancomycin-induced maturation arrest with marked promyelocyte proliferation in a 47-year-old male patient who was being treated for novel coronavirus disease 2019 (COVID-19) infection. Most times, this reactive promyelocyte proliferation is confused with neoplastic promyelocytes, leading to incorrect diagnosis and management.

## Introduction

Drug-induced leucopenia complicates any clinical situation especially when it is associated with novel coronavirus disease 2019 (COVID-19) infection.<sup>1</sup> It is essential to find out the cause of leucopenia for effective patient management. Certain drugs used in medical practice are like double edged sword having both benefits and risks. Therefore, it is mandatory on the clinicians' part to weigh the risk and benefit ratio before starting any treatment. Various drugs—like fluoroquinolones, like ciprofloxacin, levofloxacin, moxifloxacin, and newer entries like trovafloxacin—have known to cause pancytopenia along with isolated leukopenia in some cases. Antimalarials and antihelminthics are also well known for causing bone marrow suppression leading to leukopenia or more severe pancytopenia like blood picture.

Bone marrow suppression with marked leukopenia is a well-established and common side effect of chemotherapy and radiotherapy which are commonly given in cancer patients.

Here, we report a case of vancomycin-induced myeloid maturation arrest in a patient with COVID-19 infection where his condition reverted to normal after stopping the drug. It highlights the adverse effects of vancomycin, leading to promyelocyte proliferation posing a diagnostic challenge to differentiate it from neoplastic promyelocyte proliferation.<sup>2</sup> We searched literature for this uncommon side effect of vancomycin and to the best of our knowledge, very few cases have been described so far which makes our case worth reporting. Treating physicians must be aware of this side effect for effective management of patients.

## Case Report

A 47-year-old male presented with fever, dry cough, and difficulty in breathing for 12 days. He was COVID-19 positive with computed tomography (CT) lung showing bilateral pneumonic consolidations for which vancomycin was started. Hemogram showed pancytopenia with hemoglobin, 6.8 g/dL; total leucocyte count, 3,200/mm<sup>3</sup>; with a

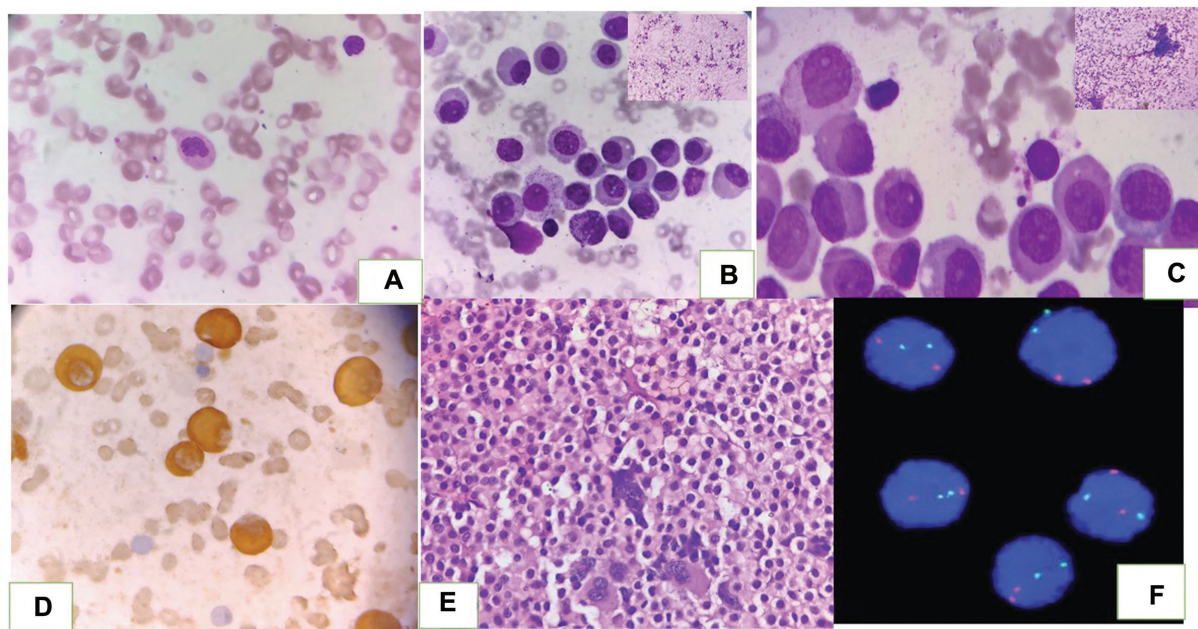
article published online  
July 26, 2022

DOI <https://doi.org/10.1055/s-0042-1750072>.  
ISSN 0974-2727.

© 2022. The Indian Association of Laboratory Physicians. All rights reserved.

This is an open access article published by Thieme under the terms of the Creative Commons Attribution-NonDerivative-NonCommercial-License, permitting copying and reproduction so long as the original work is given appropriate credit. Contents may not be used for commercial purposes, or adapted, remixed, transformed or built upon. (<https://creativecommons.org/licenses/by-nc-nd/4.0/>)

Thieme Medical and Scientific Publishers Pvt. Ltd., A-12, 2nd Floor, Sector 2, Noida-201301 UP, India



**Fig. 1** (A) Peripheral blood smear showing leucopenia with dyspoietic neutrophil (Leishman's stain;  $\times 100$ ). (B, C) bone marrow aspiration revealing marked promyelocyte proliferation and maturation arrest. Inset shows hypercellular marrow (Leishman's stain;  $\times 40$  and  $\times 100$ ). (D) MPO stain showing strong positivity (MPO;  $\times 100$ ). (E) Bone marrow biopsy showed promyelocyte proliferation (H&E;  $\times 40$ ). (F) FISH showing absence of fusion signals of PML/RARA. H&E, hematoxylin and eosin; MPO, myeloperoxidase stain.

differential count revealing neutrophil, 28% (with left shift and features of dyspoiesis); lymphocyte, 66%; monocyte, 4%; eosinophil, 2% (**Fig. 1A**); and platelets,  $90,000/\text{mm}^3$ . Bone marrow aspiration (BMA) and biopsy was advised. BMA was hypercellular for age with marked promyelocyte proliferation and maturation arrest with suppression of trilineage hematopoiesis (**Fig. 1B and C**). Myeloperoxidase stain (MPO) was strongly positive, confirming presence of promyelocyte proliferation (**Fig. 1D**). Bone marrow biopsy also reflected similar findings (**Fig. 1E**). As there was marked proliferation of promyelocyte in bone marrow with pancytopenia on peripheral blood smear, in order to rule out the possibility of acute promyelocyte leukemia, immunophenotyping and cytogenetics were done. Immunophenotyping revealed positivity for immaturity markers like HLADR and CD34 along with expression of MPO, CD11a, and CD11b with few cells showing CD15 positivity unlike that of acute promyelocytic leukemia where HLADR and CD34 are negative along with CD11a and CD11b favoring diagnosis of reactive promyelocytes over neoplastic ones.

Fluorescence in situ hybridization (FISH) for promyelocytic leukemia/retinoic acid receptor alpha (PML-RARA) translocation was also performed in order to completely negate any possibility of presence of neoplastic promyelocytes that turned out to be negative and confirmed that all these promyelocytes were reactive in nature (**Fig. 1F**).

A diagnosis of drug-induced leucopenia with reactive promyelocyte proliferation was made. Considering worsening of these hematological findings, vancomycin was stopped and patient's hematological findings improved drastically with stabilization of hematological parameters.

## Discussion

Drug-induced leukopenia occurs in a dose-dependent or dose-independent (idiosyncratic) reaction.<sup>3</sup>

Vancomycin-dependent antibodies against neutrophils lead to an autoimmune reaction directly affecting progenitor cell growth, especially of myeloid cell lineage leading to maturation arrest. Further, cytotoxic T-cell-mediated response also has damaging effects on hematopoietic cells. Infections like COVID-19 can also lead to suppression of normal myeloid maturation due to release of interleukins.<sup>4,5</sup>

Unlike drug-induced immune thrombocytopenia and anemia, laboratory testing for neutrophil drug-dependent antibodies is not productive as testing for neutrophil antibodies is not available widely. Moreover, it is technically more complex, labor intensive, and expensive.<sup>5</sup>

Myeloid maturation arrest with marked promyelocyte proliferation poses a diagnostic dilemma, especially in patients presenting with cytopenia, as they are confused with acute promyelocytic leukemia.<sup>6</sup> This case highlights the importance of detailed knowledge related to drug-induced myeloid maturation arrest which is reversible after stoppage of the offending drug.

Various drugs like fluoroquinolones group, such as ofloxacin, ciprofloxacin, levofloxacin, trovafloxacin and moxifloxacin, antimalarials, penicillins, sulfonamides, anti-thyroid medications, anticonvulsants, anticancer drugs, and vancomycin are implicated to cause neutropenia, pancytopenia, bone marrow suppression, and myeloid maturation arrest.<sup>7,8</sup>

Levamisole, another antihelminthic and immunomodulator, also suppresses bone marrow and induces neutropenia.<sup>9</sup>

Cyclic or periodic neutropenia may be related to congenital diseases or related to toxic exposure. Severe congenital neutropenia and cyclic neutropenia are autosomal dominant diseases caused by defects in neutrophil production leading to recurrent infections. There is a selective defect in neutrophil formation with a promyelocyte maturation arrest.<sup>10,11</sup>

In a retrospective study done by Pai et al in 2006, found out 12% cases to be affected by vancomycin-induced neutropenia and they concluded that patients undergoing prolonged vancomycin therapy should remain under close clinical care with regular laboratory testing for blood counts, at least once weekly.<sup>12</sup> In cases where there is high suspicion of neutropenia, alternative agents should be initiated.

Vancomycin-induced neutropenia, defined as an absolute neutrophil count (ANC) less than 1,000/ $\mu$ L, has been reported to occur at rates of 2 to 12%. The first two case reports were published by Dangerfield and colleagues in 1960, shortly after the introduction of the drug, and they assessed bone marrow in patients with vancomycin-induced neutropenia and reported maturation arrest in granulocytic series.<sup>13</sup> Since these initial cases, vancomycin-induced neutropenia has continued to be reported in the literature. Earlier formulations of vancomycin had impurities that may have contributed to higher incidences of adverse effects such as neutropenia.<sup>14,15</sup>

Kauffman and colleagues also in their study assessed bone marrow aspirate of a patient considered to have vancomycin-induced neutropenia and found hypercellularity of granulocytic cells but in their case, maturation was preserved.<sup>16</sup>

Despite increasing awareness of vancomycin-induced neutropenia, very few reviews and case reports are published, summarizing the characteristics of this reaction. To our knowledge, no systematic review has been published to address the question of whether vancomycin-induced neutropenia is dose or duration related. Thus, the objective of this case report was to highlight this side effect of vancomycin and to assess bone marrow findings which can be confused with hematological malignancy.

## Conclusion

A thorough history and clinical evaluation and laboratory testing is essential for delineating the cause of bone marrow suppression, promyelocyte proliferation, and maturation arrest. It can also be concluded that not every promyelocyte proliferation is neoplastic and extensive search should be

made to find out the cause of maturation arrest and promyelocyte proliferation through detailed clinical history and examination.

## Conflict of Interest

None declared.

## References

- 1 Arya TV, Prasad RN. Fatal pancytopenia in falciparum malaria. *J Assoc Physicians India* 1989;37(07):469–470
- 2 Zvulunov A, Tamary H, Gal N. Pancytopenia resulting from hemophagocytosis in malaria. *Pediatr Infect Dis J* 2002;21(11):1086–1087
- 3 Hattton CS, Peto TE, Bunch C, et al. Frequency of severe neutropenia associated with amodiaquine prophylaxis against malaria. *Lancet* 1986;1(8478):411–414
- 4 Pipek R, Vulfsons S, Wolfvitz E, Har-Shai Y, Taran A, Peled IJ. Case report: ofloxacin-induced hypersensitivity vasculitis. *Am J Med Sci* 1996;311(02):82–83
- 5 Nepali N, Kalam A, Subish P, et al. Hemoglobinuria due to ofloxacin in a 9 year old child - a case report. *Pharmacologyonline* 2007;1:1–5
- 6 Deng JY, Tovar JM. Pancytopenia with levofloxacin therapy for pelvic inflammatory disease in an otherwise healthy young patient. *Ann Pharmacother* 2006;40(09):1692–1693
- 7 Dutta TK, Badhe BA. Ciprofloxacin-induced bone marrow depression. *Postgrad Med J* 1999;75(887):571–573
- 8 Mitropoulos FA, Angood PB, Rabinovici R. Trovafloxacin-associated leukopenia. *Ann Pharmacother* 2001;35(01):41–44
- 9 Chang CM, Lee NY, Lee HC, et al. Moxifloxacin-associated neutropenia in a cirrhotic elderly woman with lower extremity cellulitis. *Ann Pharmacother* 2008;42(04):580–583
- 10 Naranjo CA, Busto U, Sellers EM, et al. A method for estimating the probability of adverse drug reactions. *Clin Pharmacol Ther* 1981;30(02):239–245
- 11 Cunha BA, Quintiliani R, Deglin JM, Izard MW, Nightingale CH. Pharmacokinetics of vancomycin in anuria. *Rev Infect Dis* 1981;3(suppl):S269–S272
- 12 Pai MP, Mercier RC, Koster SA. Epidemiology of vancomycin-induced neutropenia in patients receiving home intravenous infusion therapy. *Ann Pharmacother* 2006;40(02):224–228
- 13 Dangerfield HG, Hewitt WL, Monzon OT, et al. Clinical use of vancomycin. *Antimicrobial Agents Annual* 1960:26–28
- 14 Farber BF, Moellering RC Jr. Retrospective study of the toxicity of preparations of vancomycin from 1974 to 1981. *Antimicrob Agents Chemother* 1983;23(01):138–141
- 15 Black E, Lau TT, Ensom MH. Vancomycin-induced neutropenia: is it dose- or duration-related? *Ann Pharmacother* 2011;45(05):629–638
- 16 Kauffman CA, Severance PJ, Silva J Jr, Huard TK. Neutropenia associated with vancomycin therapy. *South Med J* 1982;75(09):1131–1133