



Cerebellar Tubers in Tuberous Sclerosis Complex Patients: New Imaging Characteristics and the Relationship with Cerebral Tubers

Akira Yogi^{1,2}  Yoko Hirata^{2,3} Michael Linetsky² Benjamin M. Ellingson² Noriko Salamon²

¹Department of Radiology, University of the Ryukyus Hospital, Okinawa, Japan

²Department of Radiological Science, David Geffen School of Medicine, University of California, Los Angeles, California, United States

³Department of Neurosurgery, Toho University Ohashi Medical Center, Tokyo, Japan

Address for correspondence Akira Yogi, MD, PhD, Department of Radiology, University of the Ryukyus Hospital, 207 Uehara, Nishihara-cho, Nakagami-gun, Okinawa, 903-0215, Japan (e-mail: ayogi@med.u-ryukyu.ac.jp).

J Pediatr Epilepsy 2023;12:76–83.

Abstract

Objective The imaging characteristics, evolution, and clinical features of cerebellar tubers in tuberous sclerosis complex (TSC) patients have not been well described. The purpose of this study is to investigate the imaging characteristics of cerebellar tubers, including their dynamic changes, and to evaluate the relationship with cerebral tubers in TSC patients.

Materials and Methods Two observers retrospectively reviewed 75 consecutive TSC patients to identify cerebellar tubers and to evaluate their imaging characteristics, including location, presence of retraction change, calcification, contrast enhancement, and the presence of an associated vascular anomaly, as well as dynamic changes in these characteristics. The number of cerebral tubers was compared between TSC patients with and without cerebellar tubers.

Results Twenty-five TSC patients with 28 cerebellar tubers were identified. All cerebellar tubers occurred within the lateral portions of the cerebellar hemispheres. Thirteen cerebellar tubers demonstrated calcification. Ten cerebellar tubers showed contrast enhancement, half of which demonstrated a zebra-like appearance. A vascular anomaly was associated with 12 tubers, one of which subsequently developed parenchymal hemorrhage. Fifteen cerebellar tubers demonstrated complex dynamic changes in size and contrast enhancement. Patients with cerebellar tubers had more cerebral tubers ($p = 0.001$).

Conclusion Cerebellar tubers demonstrate a specific distribution, suggesting a possible influence on higher brain function. The presence of an associated vascular anomaly may be an important imaging characteristic. Cerebellar tubers may be associated with a more severe manifestation of TSC, given their association with increased numbers of cerebral tubers. These findings may provide insights into the pathogenesis and clinical manifestations of cerebellar tubers in TSC patients.

Keywords

- ▶ cerebellar tuber
- ▶ tuberous sclerosis complex
- ▶ associated vascular anomaly
- ▶ dynamic change
- ▶ anatomical location

received

May 14, 2022

accepted

August 20, 2022

article published online

October 7, 2022

DOI <https://doi.org/>

10.1055/s-0042-1756717.

ISSN 2146-457X.

© 2022. The Author(s).

This is an open access article published by Thieme under the terms of the Creative Commons Attribution-NonDerivative-NonCommercial-License, permitting copying and reproduction so long as the original work is given appropriate credit. Contents may not be used for commercial purposes, or adapted, remixed, transformed or built upon. (<https://creativecommons.org/licenses/by-nc-nd/4.0/>)

Georg Thieme Verlag KG, Rüdigerstraße 14, 70469 Stuttgart, Germany

Introduction

Tuberous sclerosis complex (TSC) is a de novo genetic disorder that is often associated with seizures, infantile spasm, autistic spectrum disorder (ASD), and other developmental disabilities.^{1,2} While cerebral tubers are almost universally present and associated with seizures, *cerebellar* tubers occur in 10 to 44% of TSC patients and do not directly cause epilepsy.^{3–9}

Several studies have documented the imaging findings of cerebellar tubers, including contrast enhancement, which is rare in cerebral tubers.^{3–9} Recent studies have also revealed that cerebellar tubers demonstrate dynamic changes with increases or decreases in size, while cerebral tubers are usually static.^{4,7–10} Some studies have demonstrated the laterality of cerebellar tubers^{4,8,10–12}; however, only two studies have reported the anatomic locations of tubers in the cerebellar lobules.^{5,11} In addition, an abnormal flow void, considered as an associated vascular anomaly, is occasionally encountered in association with cerebellar tubers, which has not been previously reported, to the best of our knowledge. Furthermore, although it is known that cerebellar tubers are associated with increased number of cerebral tubers,^{4,5,13} the relationship between cerebral tubers presenting with the internal cystic degeneration, which is often encountered and considered a severe form of cerebral tubers,^{14–16} is unknown.

This study aims to review the imaging characteristics of cerebellar tubers, including the association with associated vascular anomalies and precise anatomical location, to track their dynamic changes, and to evaluate the correlation with cerebral tubers.

Materials and Methods

Patients

The Institutional Review Board at the University of California, Los Angeles (UCLA) approved the use of human subjects and waived the need for written informed consent and signed Patient Consent-to-Disclose Forms since all testing was deemed clinically relevant to patient care.

We retrospectively selected 75 consecutive TSC patients (2 months–26 years old, mean age 7.4; 43 female and 32 male) referred to the UCLA TSC Clinic between 2001 and 2014. All patients demonstrated cortical tubers and subependymal nodules, meeting the criteria of definitive TSC.¹⁷ Twenty-four of them demonstrated subependymal giant cell astrocytoma (SEGA). Seventeen patients had genetic test, including TSC1 and TSC2 genetic testing. Four and 12 patients had a mutation in TSC1 and TSC2, respectively.

Thirty-seven (49%) patients had a history of infantile spasms, and 17 (23%) had autism. Twenty-nine (39%) had a history of mammalian target of rapamycin (mTOR) inhibitor use. Thirty-seven (49%) had undergone epilepsy surgery, including a lobectomy or tuberectomy for the removal of an epileptogenic zone ($n = 34$), vagal nerve stimulator placement ($n = 14$), or corpus callosotomy ($n = 2$). Thirteen patients had a history of multiple types of epilepsy surgery.

Imaging Analysis

Two experienced neuroradiologists reviewed all magnetic resonance (MR) examinations to identify the cerebellar tubers and evaluate their imaging findings and dynamic changes, in consensus. We resolved any discrepancies through open discussion, adding another experienced neuroradiologist. Cerebellar tubers were defined as focal signal abnormalities, typically wedge- or band-like, on at least one of the T1-weighted (T1WI) or T2-weighted images (T2WI) (►Fig. 1).^{8,9} According to the imaging characteristics of cerebellar tubers, the anatomical location, signal characteristics on T1WI and T2WI, calcification, retraction change, contrast enhancement, and the presence of associated vascular anomaly were reviewed.

The anatomical locations were assessed according to cerebellar lobules, including the superior or inferior semilunar lobules, gracilis lobule, biventral lobule, posterior or anterior quadrangular lobule, flocculus, and cerebellar tonsil, using volumetric sequences, either three-dimension (3D) magnetization-prepared rapid gradient-echo or 3D spoiled gradient echo. A distribution map of the cerebellar tubers was also generated, using the postprocessing software Analysis of Functional Neuroimaging (<http://afni.nimh.nih.gov/afni/download>). Masks were generated by contouring the cerebellar tubers manually on T2WI and subsequently registered to the Montreal Neurological Institute standard space. The generated masks were extracted and combined to generate a four-dimensional mask of all cerebellar tubers, which was colored according to the number of overlapping tubers. The resultant distribution map was visualized in a 3D manner using 3D Slicer 4.4.0 (<http://www.slicer.org>).

Calcification was inferred from T2-shortened areas and/or susceptibility artifact on gradient-echo sequences within the tuber. Computed tomography (CT) was also used for this assessment, when available. A retraction change was defined as a focal contour abnormality at the periphery of the lesion with associated volume loss.⁸ We monitored contrast enhancement and also assessed whether the enhancement showed a striped pattern, known as a “zebra-like appearance,” which is characteristic of cerebellar tubers (►Fig. 1D).⁸ An associated vascular anomaly was defined as a dilated and prominent flow void coursing adjacent to the tuber which could be confirmed on consecutive slices (►Fig. 1A, B). In patients with an associated vascular anomaly, we also evaluated whether such prominent flow voids existed on the contralateral side of posterior fossa.

The presence of new lesions and dynamic changes of existing cerebellar tubers was visually evaluated over serial scans. We carefully compared the imaging findings of cerebellar tubers on each MR imaging (MRI) with those on the preceding MRI and defined the dynamic changes as an increase or decrease in the size, retraction change, and contrast enhancement, or the development or progression of calcification or an associated vascular anomaly. We carefully compared each MRI to account for slight technical differences in slice selection and orientation, taking care not to mistake these for actual dynamic changes.

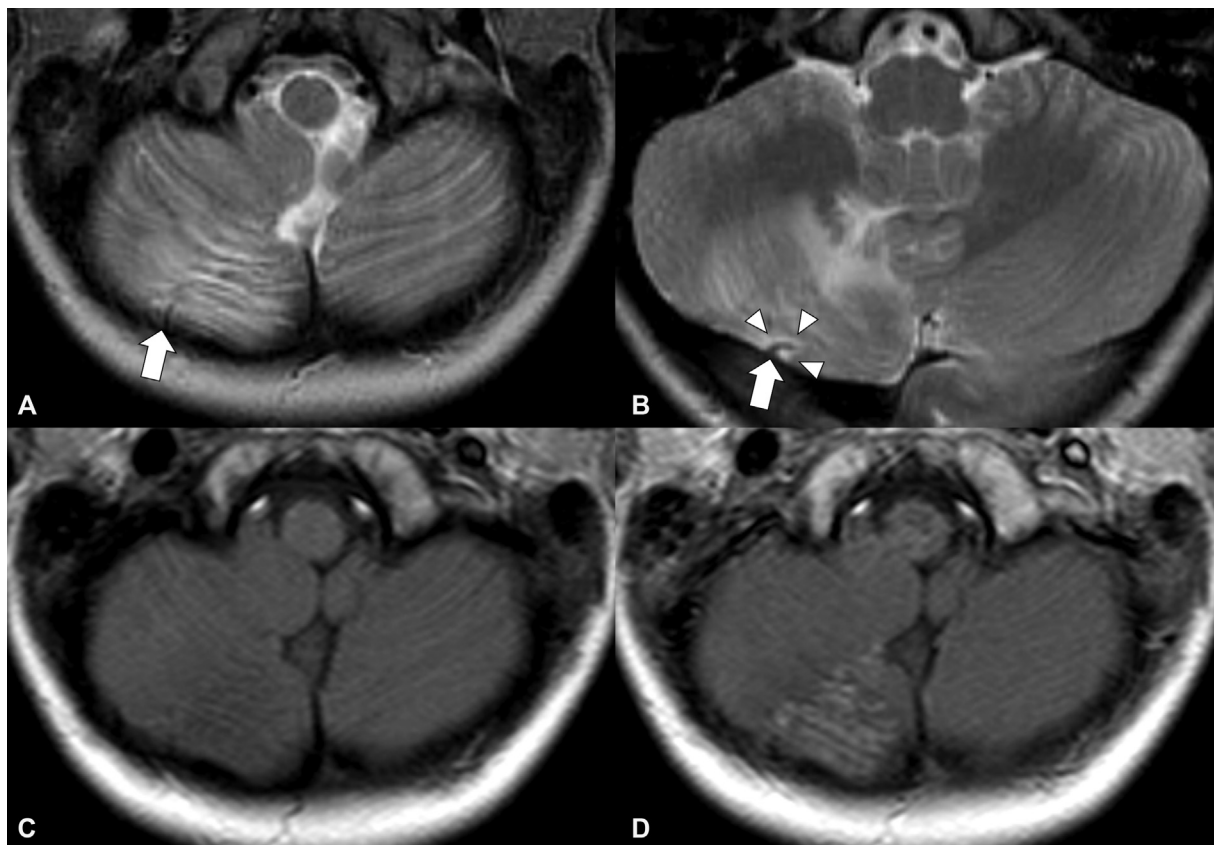


Fig. 1 A 7-year-old boy with a right cerebellar tuber. (A, B) Fan-shaped tuber shows hyperintensity on T2-weighted image (T2WI). Contour deformity due to retraction change is present (arrow heads). There is also a prominent flow void coursing adjacent to the tuber, defined as an associated vascular anomaly (arrow). (C) Tuber shows slight hypointensity on T1-weighted image (T1WI). (D) Contrast enhancement is present on contrast-enhanced T1WI, showing a striped pattern with a high and low intensity, “zebra-like appearance.”

Also, the same two observers manually counted all cerebral tubers and cerebral tubers with internal cystic degeneration. Cerebral tubers with internal cystic degenerations were defined as tubers demonstrating hypointensity on T1WI, hyperintensity on T2WI, and heterogeneous intensity mixed with central hypointensity and surrounding hyperintensity on fluid-attenuated inversion recovery, called type C tubers in Gallagher’s classification.¹⁰ Discrepancies were resolved through open discussion.

Statistical Analysis

TSC patients were divided into two groups according to the presence of cerebellar tubers. We compared the patients’ demographic data and the numbers of all cerebral tubers and type C cerebral tubers between the two groups, using the chi-square test and Mann–Whitney *U* test, respectively. A *p*-value of < 0.05 was considered statistically significant.

Table 1 Demographic data of TSC patients with or without cerebellar tubers

	Patients with cerebellar tubers (<i>n</i> = 25) ^a	Patients without cerebellar tubers (<i>n</i> = 50) ^a	<i>p</i> -Values
Age	Range 0.4–23.8; mean, 7.4	Range 0.2–26.4; mean, 7.3	0.93
Gender	Female 15, male 10	Female 31, male 19	0.87
Patients with a history of infantile spasms	16 (64)	21 (42)	0.07
Patients with autism	8 (32)	9 (18)	0.17
Patients with a history of mTOR inhibitor use	13 (52)	16 (32)	0.09
Patients with epilepsy surgery	13 (52)	24 (48)	0.74

Abbreviations: mTOR, mammalian target of rapamycin; TSC, tuberous sclerosis complex.

^aThe percentages of patients with each clinical manifestation to patients with cerebellar tubers (*n* = 25) or without tubers (*n* = 50) are in parentheses.

Results

A total of 28 cerebellar tubers were found in 25 TSC patients (0.4–23.8 years old, mean age 7.4; 15 female and 10 male). Twenty-two patients had one cerebellar tuber while three patients had two; all patients with two had bilateral cerebellar tubers. Patients' demographic data are summarized in ▶Table 1. There was no significant difference in each characteristic between TSC patients with and without cerebellar tubers ($p > 0.07$).

A total of 116 MR examinations and 39 CT examinations were performed in these 25 patients with cerebellar tubers. The number of MR examinations per patient ranged from 1 to 16 (median, 4). The imaging characteristics of the cerebellar tubers are summarized in ▶Table 2. Cerebellar tubers occurred in both hemispheres with equal frequency and were located only on the lateral portions of the cerebellar hemispheres (▶Fig. 2). The superior and inferior semilunar lobules were the most and the second most frequently affected. All cerebellar tubers (100%) were predominantly hyperintense on T2WI. Twenty-six (93%) were predominantly hypointense and two were isointense on T1WI. Calcification within 13 (46%) of the cerebellar tubers, however, caused focal heterogeneous signal changes, including low intensity on T2WI ($n = 13$) and/or high intensity on T1WI ($n = 3$). CT was performed for 6 of 13 calcified cerebellar tubers, all of which demonstrated high density. All cerebellar tubers (100%) exhibited retraction change. Ten (36%) cerebellar tubers showed contrast enhancement, half of which demonstrated a zebra-like appearance. Twelve (43%) cerebellar tubers demonstrated an associated vascular anomaly. There was no such prominent flow void at the contralateral side of the posterior fossa.

Twenty-two patients with 25 cerebellar tubers underwent follow-up studies (▶Table 3). The follow-up period ranged from 6.0 to 156.2 months, with a median of 95.6 months. Fifteen cerebellar tubers (60%) demonstrated dy-

Table 2 Imaging characteristics of cerebellar tubers at first presentation

Imaging findings	No. of cerebellar tubers ^a
Affected hemisphere ^b	
Right/left	14 (50)/14 (50)
Location by cerebellar lobules	
Superior semilunar lobule	25 (89%)
Inferior semilunar lobule	20 (71%)
Gracilis lobule	12 (43%)
Biventral lobule	4 (14%)
Posterior quadrangular lobule	4 (14%)
Hyperintense on T2WI	28 (100)
Hypointense on T1WI	26 (93)
Associated vascular anomaly	12 (43)
Calcification	13 (46)
Retraction change	28 (100)
Contrast enhancement	10 (36)
Zebra-like appearance	5 (18)

Abbreviations: T1WI, T1-weighted image; T2WI, T2-weighted image.

^aThe percentage of cerebellar tubers with the finding to all cerebellar tubers ($n = 28$) are in parentheses.

^bThree patients had cerebellar tubers bilaterally.

namic changes in at least one of the imaging characteristics surveyed (▶Figs. 3 and 4). Size increased in four (16%) cerebellar tubers and decreased in other four (16%). Five (20%) cerebellar tubers showed complicated size changes with increase and decrease. One cerebellar tuber increased at first and subsequently decreased, resulting in larger size than the initial one. Another decreased at first and subsequently increased, resulting in a smaller size than the initial one. The

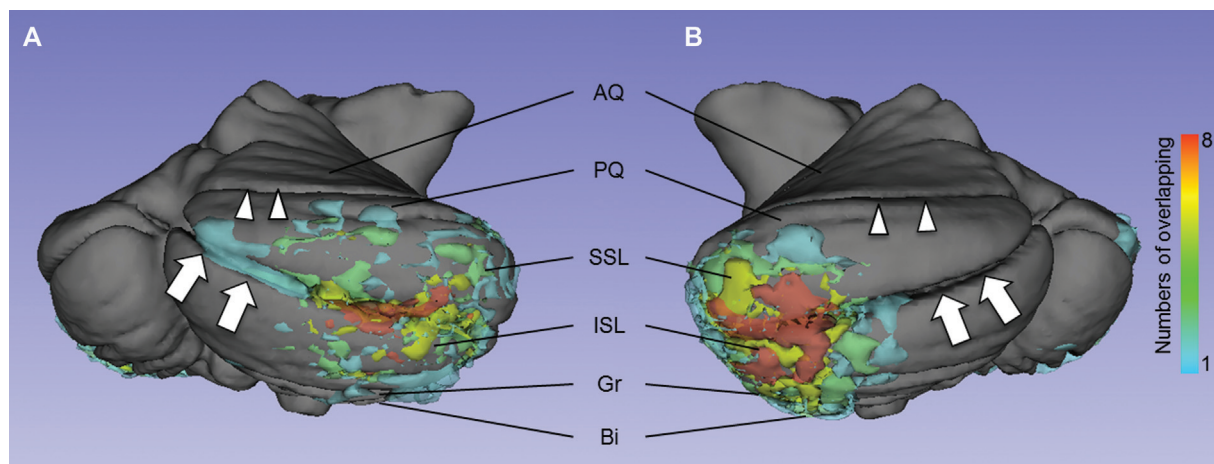


Fig. 2 Distribution map of cerebellar tubers on (A) right posterior view and (B) left posterior view. AQ, anterior quadrangular lobule; Bi, biventral lobule; Gr, gracilis lobule; ISL, inferior semilunar lobule; PQ, posterior quadrangular lobule; SSL, superior semilunar lobule. The horizontal fissure (arrows) divides SSL and ISL and the primary fissure (arrow heads) divides AQ and PQ. Twenty-five (89%) cerebellar tubers were in superior semilunar lobule, 20 (71%) were in inferior semilunar lobule, 12 (43%) were in gracilis lobule, 4 (14%) were in biventral lobule, and 4 (14%) were in posterior quadrangular lobule. The superior and inferior semilunar lobules, that were the most and the second most frequently affected, were involved simultaneously in 17 (61%) tubers.

Table 3 Dynamic change of cerebellar tubers

Imaging characteristics showing dynamic changes	Number of cerebellar tubers ^a
Size	
Increase	4 (16)
Decrease	4 (16)
Mixed with the increase and decrease	5 (20)
Retraction change	
Increase	9 (36)
Decrease	2 (8)
Calcification	
Progress	5 (20)
Stable	8 (80)
Contrast enhancement	
Decreased/loss	2 (8)
Mixed with the increase and decrease	8 (32)
Developed an associated vascular anomaly	4 (16)

^aThe percentage of tubers with the finding to all tubers ($n = 25$) are in parentheses.

other three cerebellar tubers alternated increase and decrease: two were larger and the other was smaller than their initial size on the latest MRI. Retraction change progressed in nine (36%) and decreased in two (8%). Calcification progressed in five (20%), and the other eight (80%) were stable. Two cerebellar tubers (8%) showed decrease or complete loss of contrast enhancement. Eight cerebellar tubers (32%) showed complicated changes in contrast enhancement with both increases and decreases. Contrast enhancement decreased at first and subsequently increased in one cerebellar tuber, while it increased at first and subsequently decreased in two. The other five cerebellar tubers showed alternating increase and decrease in contrast enhancement, with contrast enhancement on the latest MRI lower than that on the initial MRI. Among these eight cerebellar tubers with complicated changes in contrast enhancement, the latest contrast enhancement was lower than the initial one in

seven. Another cerebellar tuber on the latest MRI demonstrated contrast enhancement equal to that on the initial MRI. Among these eight cerebellar tubers with complicated change in contrast enhancement, the latest contrast enhancement was lower than the initial one in seven. Another cerebellar tuber on the latest MRI demonstrated equal contrast enhancement to that on the initial MRI.

Six (24%) developed an associated vascular anomaly, one of which kept progressing and resulted in parenchymal hemorrhage (–Fig. 4).

A total of 2,131 cerebral tubers (range 4–71; mean, 28.4) were identified in all 75 TSC patients, and a total of 217 type C tubers (range from 1 to 19; mean, 2.9) were found in 47 TSC patients. Patients with cerebellar tubers had more cerebral tubers and slightly more type C tubers than the patients without cerebellar tubers ($p = 0.001$ and < 0.02 , respectively).

Discussion

We found that cerebellar tubers were located exclusively within the lateral portions of the cerebellar hemispheres, with a predilection for the semilunar lobules. Our result is consistent with previous works reporting that the cerebellar tubers were predominantly located in the lateral hemispheres.^{11,13} Recent studies have suggested that the cerebello-cerebral neural network, involving lateral portions of the cerebellar hemispheres, the semilunar and posterior quadrangular lobules, is involved in higher brain functions.^{18–25} In addition, autism is also associated with focal abnormalities in the cerebellum, especially in the semilunar lobule,^{26–32} where cerebellar tubers occurred most commonly in this study. In patients with TSC, the strong correlation between cerebral tubers and ASD has been reported^{13,33–36}; however, the relationship between cerebellar tubers and autism has not been fully established. Though the correlation between ASD and cerebellar tubers was reported in one study,¹⁰ it did not consider other variables, including genetics and severity of neurological phenotypes. The other study reported that ASD did not correlate with cerebellar tubers and was mainly associated with genetic abnormality and the number of cerebral tubers through the multivariate analysis, concluding that cerebellar tubers were not the best predictor of ASD.¹³ In this study, we

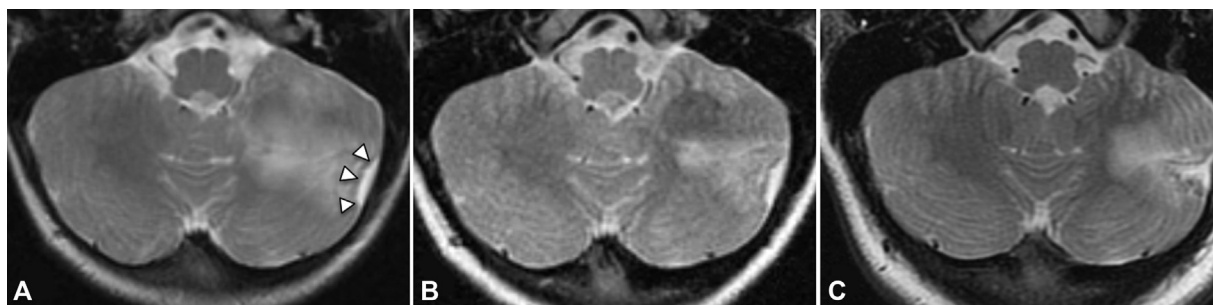


Fig. 3 Initial magnetic resonance imaging (MRI) (A) and follow-up MRIs performed 3 years (B) and 7 years later (C) for a left cerebellar tuber. (A) The tuber shows hyperintensity on T2-weighted image (T2WI). A retraction change is also present (arrowheads). The hyperintense area decreases 3 years later (B) and increases again 7 years later (C). The retraction change, on the other hand, keeps progressing.

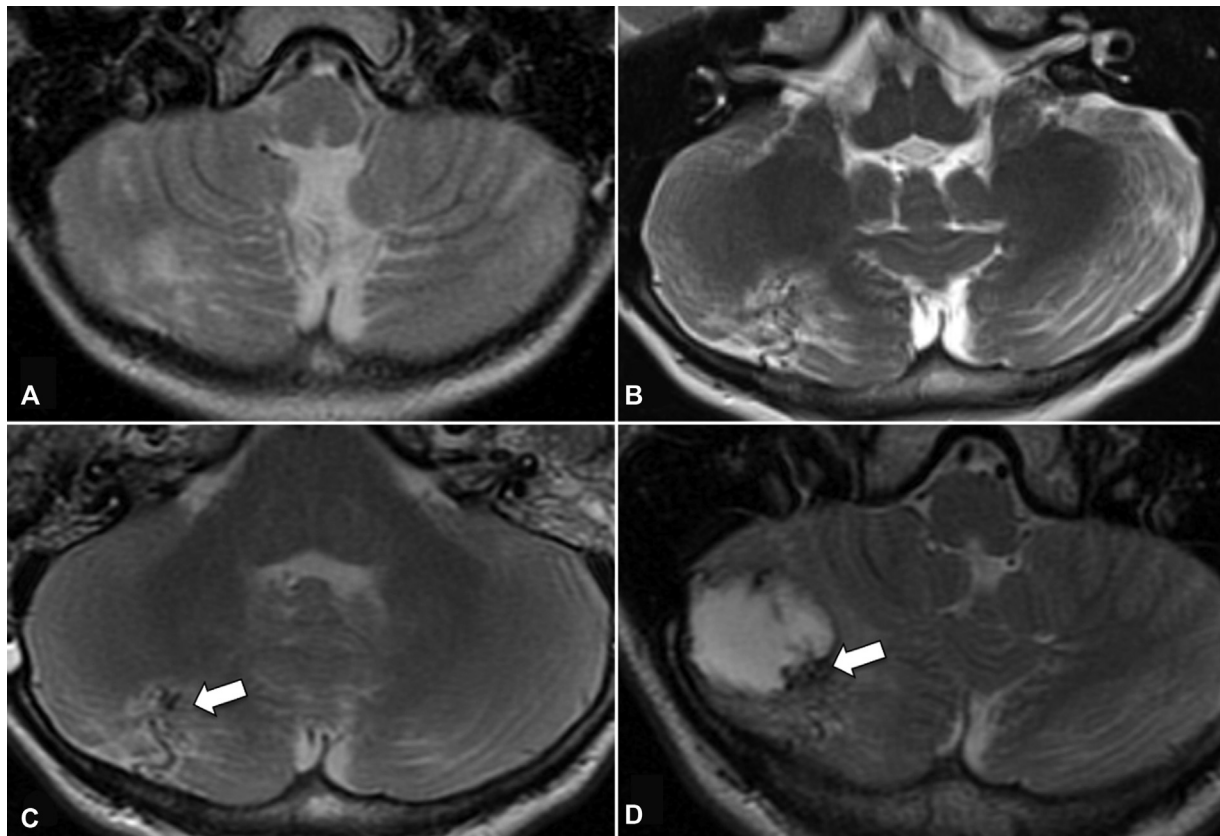


Fig. 4 A 2-year-old male with tuberous sclerosis complex. (A) T2-weighted image (T2WI) shows a right-cerebellar tuber. (B) Seven years later, a flow void indicating an associated vascular anomaly (AVA) appears. (C) Nine years later, a nodular T2-hypointense focus within the tuber develops (arrow). (D) Eleven years after the initial scan, T2WI and T1-weighted image (T1WI) (not shown) demonstrate parenchymal hemorrhage occurring adjacent to the region of the previously imaged associated vascular anomaly and the T2-hypointense focus (arrow)

also found no significant correlation between cerebellar tubers and autism. Because the pathogenesis of cerebellar tubers is not fully understood, it is unknown why cerebellar tubers occur in such an important area exclusively. It is also unknown whether cerebellar tubers affect higher brain functions in patients with TSC, including their correlation with autism. Further analyses including pathological and neuropsychiatric assessments may clarify these issues.

In this study, 43% of the cerebellar tubers demonstrated an associated vascular anomaly, suggesting that it may be an important imaging finding of cerebellar tubers. The pathogenesis and pathological features of the associated vascular anomalies are uncertain due to a lack of pathological studies; however, we can suggest that the associated vascular anomalies may be related to the cerebellar tubers as there were no such dilated and prominent flow voids on the contralateral side of the posterior fossa. Moreover, half of these anomalies developed on follow-up studies without appearing on the initial scan, and one associated vascular anomaly developed into a parenchymal hemorrhage. A recent study reported that epidermal growth factor, hepatocyte growth factor, and vascular endothelial growth factor, which regulate angiogenesis as well as cell growth in the developing brain, also regulate the mTOR pathway and were enhanced in tubers and SEGA.^{37,38} It is unknown whether these intrinsic factors initiate the associated vascular anomalies and their evolu-

tion. Further studies may elucidate the pathogenesis of these associated vascular anomalies.

Other imaging features in cerebellar tubers were consistent with those in previous reports.⁷⁻⁹ They exhibited T1 and T2 prolongation, retraction changes, calcification, and contrast enhancement. Retraction change was confirmed in all cerebellar tubers. Previous histopathological studies reported that cerebellar tubers demonstrated abnormal neuronal migration, gliosis, calcification, and folial atrophy.^{3,5,8,39} Folial atrophy causes volume loss of neuronal tissue within the cerebellar tuber and may result in retraction change as well as the “zebra-like” contrast-enhancement, which is thought to reflect cerebrospinal fluid-filled sulci interposed between atrophic neuronal elements.⁸

Although it is well known that cerebellar tubers show dynamic changes over time,^{7,8} it has not been reported previously that they show not only monotonic increase or decrease, but also both increase (progression) and decrease (improvement), as confirmed in this study. We cannot define the exact patterns of change in this study because the time intervals of the MR examinations were not uniform. However, the important finding is that cerebellar tubers have more complicated dynamic patterns than previously suspected.

Cerebral tubers with internal cystic degeneration, known as type C tubers, were more numerous in patients with cerebellar tubers, as well as whole cerebral tubers were. It

is well known that both cerebral and cerebellar tubers demonstrate similar pathological changes, suggesting that they may have a common pathway of generation.^{3,5,8,39} In addition, the number of cerebral tubers and the presence of type C tuber are associated with a more severe spectrum of TSC^{10,40}; therefore, the presence of cerebellar tubers may be associated with more severe TSC. However, there was no significant difference in TSC patients' demographic data (– **Table 1**). Though it is of interest whether cerebellar tubers are associated with the severity of TSC, further analyses with a larger sample size may reveal the correlation between the mechanisms of cerebellar tuber generations and TSC severity.

The limitations of this study include a relatively small number of cases, the retrospective approach, and the heterogeneous time intervals of the MR examinations. The patients' TSC gene mutations, detailed medication history, age of seizure onset, and presence of drug refractory epilepsy were not evaluated, so we could not precisely evaluate the relationship between cerebellar tubers and the clinical severity of TSC. The sample solely consisted of patients referred to the UCLA TSC Clinic; therefore, the patients likely represent a clinically severe phenotype of TSC. Finally, the severity of genetic defects was not correlated with cerebellar tubers.

Conclusion

Since cerebellar tubers are less common than cerebral tubers and do not directly cause epilepsy, they may, at first glance, seem less clinically relevant. However, this study has documented that cerebellar tuber occurs exclusively within the lateral portions of the cerebellar hemispheres, which are related to higher brain function. In addition, the associated vascular anomaly may be an important imaging finding in cerebellar tubers, as they may develop over time and progress to parenchymal hemorrhage. These findings suggest that cerebellar tubers may be clinically important. It is also of interest that cerebellar tubers may demonstrate complex dynamic patterns of change.

Further analyses incorporating neuropsychiatric and pathological data would strengthen these preliminary findings, which may provide insight into the pathogenesis and clinical manifestations of cerebellar tubers in TSC patients.

Authors' Contributions

1. Guarantor of integrity of the entire study: A.Y. and N.S.
2. Study concepts: A.Y. and N.S.
3. Study design: A.Y. and N.S.
4. Data acquisition: A.Y., Y.H., B.M.E., and N.S.
5. Data analysis: A.Y., Y.H., B.M.E., and N.S.
6. Statistical analysis: A.Y. and N.S.
7. Manuscript preparation: A.Y.
8. Manuscript editing: A.Y., Y.H., M.L., B.M.E., and N.S.
9. Manuscript review: A.Y., Y.H., M.L., B.M.E., and N.S.

Conflict of Interest

None declared.

References

- 1 Jones AC, Shyamsundar MM, Thomas MW, et al. Comprehensive mutation analysis of TSC1 and TSC2-and phenotypic correlations in 150 families with tuberous sclerosis. *Am J Hum Genet* 1999;64(05):1305–1315
- 2 Prather P, de Vries PJ. Behavioral and cognitive aspects of tuberous sclerosis complex. *J Child Neurol* 2004;19(09):666–674
- 3 Menor F, Martí-Bonmatí L, Mulas F, Poyatos C, Cortina H. Neuroimaging in tuberous sclerosis: a clinicoradiological evaluation in pediatric patients. *Pediatr Radiol* 1992;22(07):485–489
- 4 Eluvathingal TJ, Behen ME, Chugani HT, et al. Cerebellar lesions in tuberous sclerosis complex: neurobehavioral and neuroimaging correlates. *J Child Neurol* 2006;21(10):846–851
- 5 Martí-Bonmatí L, Menor F, Dosdá R. Tuberous sclerosis: differences between cerebral and cerebellar cortical tubers in a pediatric population. *AJNR Am J Neuroradiol* 2000;21(03):557–560
- 6 Braffman BH, Bilaniuk LT, Naidich TP, et al. MR imaging of tuberous sclerosis: pathogenesis of this phakomatosis, use of gadopentetate dimeglumine, and literature review. *Radiology* 1992;183(01):227–238
- 7 Daghistani R, Rutka J, Widjaja E. MRI characteristics of cerebellar tubers and their longitudinal changes in children with tuberous sclerosis complex. *Childs Nerv Syst* 2015;31(01):109–113
- 8 Vaughn J, Hagiwara M, Katz J, et al. MRI characterization and longitudinal study of focal cerebellar lesions in a young tuberous sclerosis cohort. *AJNR Am J Neuroradiol* 2013;34(03):655–659
- 9 Ertan G, Arulrajah S, Tekes A, Jordan L, Huisman TAGM. Cerebellar abnormality in children and young adults with tuberous sclerosis complex: MR and diffusion weighted imaging findings. *J Neuro-radiol* 2010;37(04):231–238
- 10 Weber AM, Egelhoff JC, McKellop JM, Franz DN. Autism and the cerebellum: evidence from tuberous sclerosis. *J Autism Dev Disord* 2000;30(06):511–517
- 11 Boronat S, Thiele EA, Caruso P. Cerebellar lesions are associated with TSC2 mutations in tuberous sclerosis complex: a retrospective record review study. *Dev Med Child Neurol* 2017;59(10):1071–1076
- 12 Manara R, Bugin S, Pelizza MF, et al. Genetic and imaging features of cerebellar abnormalities in tuberous sclerosis complex: more insights into their pathogenesis. *Dev Med Child Neurol* 2018;60(07):724–725
- 13 Toldo I, Bugin S, Perissinotto E, et al. Cerebellar lesions as potential predictors of neurobehavioural phenotype in tuberous sclerosis complex. *Dev Med Child Neurol* 2019;61(10):1221–1228
- 14 Gallagher A, Grant EP, Madan N, Jarrett DY, Lyczkowski DA, Thiele EA. MRI findings reveal three different types of tubers in patients with tuberous sclerosis complex. *J Neurol* 2010;257(08):1373–1381
- 15 Chu-Shore CJ, Frosch MP, Grant PE, Thiele EA. Progressive multifocal cystlike cortical tubers in tuberous sclerosis complex: clinical and neuropathologic findings. *Epilepsia* 2009;50(12):2648–2651
- 16 Chu-Shore CJ, Major P, Montenegro M, Thiele E. Cyst-like tubers are associated with TSC2 and epilepsy in tuberous sclerosis complex. *Neurology* 2009;72(13):1165–1169
- 17 Northrup H, Krueger DA, Roberds S, et al; International Tuberous Sclerosis Complex Consensus Group. Tuberous sclerosis complex diagnostic criteria update: recommendations of the 2012 International Tuberous Sclerosis Complex Consensus Conference. *Pediatr Neurol* 2013;49(04):243–254
- 18 Strick PL, Dum RP, Fiez JA. Cerebellum and nonmotor function. *Annu Rev Neurosci* 2009;32(01):413–434
- 19 Middleton FA, Strick PL. Cerebellar projections to the prefrontal cortex of the primate. *J Neurosci* 2001;21(02):700–712
- 20 Dum RP, Strick PL. An unfolded map of the cerebellar dentate nucleus and its projections to the cerebral cortex. *J Neurophysiol* 2003;89(01):634–639

- 21 Cho SS, Yoon EJ, Bang SA, et al. Metabolic changes of cerebrum by repetitive transcranial magnetic stimulation over lateral cerebellum: a study with FDG PET. *Cerebellum* 2012;11(03):739–748
- 22 Whiteside SP, Port JD, Abramowitz JS. A meta-analysis of functional neuroimaging in obsessive-compulsive disorder. *Psychiatry Res* 2004;132(01):69–79
- 23 Yan H, Zuo XN, Wang D, et al. Hemispheric asymmetry in cognitive division of anterior cingulate cortex: a resting-state functional connectivity study. *Neuroimage* 2009;47(04):1579–1589
- 24 Fulbright RK, Jenner AR, Mencl WE, et al. The cerebellum's role in reading: a functional MR imaging study. *AJNR Am J Neuroradiol* 1999;20(10):1925–1930
- 25 Tamada T, Miyauchi S, Imamizu H, Yoshioka T, Kawato M. Cerebro-cerebellar functional connectivity revealed by the laterality index in tool-use learning. *Neuroreport* 1999;10(02):325–331
- 26 Carper RA, Courchesne E. Inverse correlation between frontal lobe and cerebellum sizes in children with autism. *Brain* 2000;123(Pt 4):836–844
- 27 Olivito G, Clausi S, Laghi F, et al. Resting-state functional connectivity changes between dentate nucleus and cortical social brain regions in autism spectrum disorders. *Cerebellum* 2017;16(02):283–292
- 28 Igelström KM, Webb TW, Graziano MSA. Functional connectivity between the temporoparietal cortex and cerebellum in autism spectrum disorder. *Cereb Cortex* 2017;27(04):2617–2627
- 29 Scott JA, Schumann CM, Goodlin-Jones BL, Amaral DG. A comprehensive volumetric analysis of the cerebellum in children and adolescents with autism spectrum disorder. *Autism Res* 2009;2(05):246–257
- 30 D'Mello AM, Crocetti D, Mostofsky SH, Stoodley CJ. Cerebellar gray matter and lobular volumes correlate with core autism symptoms. *Neuroimage Clin* 2015;7:631–639
- 31 Khan AJ, Nair A, Keown CL, Datko MC, Lincoln AJ, Müller RA. Cerebro-cerebellar resting-state functional connectivity in children and adolescents with autism spectrum disorder. *Biol Psychiatry* 2015;78(09):625–634
- 32 Verly M, Verhoeven J, Zink I, et al. Altered functional connectivity of the language network in ASD: role of classical language areas and cerebellum. *Neuroimage Clin* 2014;4:374–382
- 33 Asano E, Chugani DC, Muzik O, et al. Autism in tuberous sclerosis complex is related to both cortical and subcortical dysfunction. *Neurology* 2001;57(07):1269–1277
- 34 Bolton PF, Griffiths PD. Association of tuberous sclerosis of temporal lobes with autism and atypical autism. *Lancet* 1997;349(9049):392–395
- 35 Bolton PF, Park RJ, Higgins JN, Griffiths PD, Pickles A. Neuroepileptic determinants of autism spectrum disorders in tuberous sclerosis complex. *Brain* 2002;125(Pt 6):1247–1255
- 36 Numis AL, Major P, Montenegro MA, Muzykewicz DA, Pulsifer MB, Thiele EA. Identification of risk factors for autism spectrum disorders in tuberous sclerosis complex. *Neurology* 2011;76(11):981–987
- 37 Brugarolas J, Kaelin WG Jr. Dysregulation of HIF and VEGF is a unifying feature of the familial hamartoma syndromes. *Cancer Cell* 2004;6(01):7–10
- 38 Parker WE, Orlova KA, Heuer GG, et al. Enhanced epidermal growth factor, hepatocyte growth factor, and vascular endothelial growth factor expression in tuberous sclerosis complex. *Am J Pathol* 2011;178(01):296–305
- 39 Jay V, Edwards V, Musharbash A, Rutka JT. Cerebellar pathology in tuberous sclerosis. *Ultrastruct Pathol* 1998;22(04):331–339
- 40 Hawkins CP, Mackenzie F, Tofts P, du Boulay EP, McDonald WI. Patterns of blood-brain barrier breakdown in inflammatory demyelination. *Brain* 1991;114(Pt 2):801–810