



ICRI White Paper: An Update on Role of Conventional Radiography in Imaging of Pediatric Gastrointestinal Tract

Sanjay N. Jain¹ Rushit S. Shah²  Tanvi Modi²  Ravi U. Varma²

¹Department of Radiology, Prince Aly Khan Hospital, Aga Hall, Nesbit Road, Mazagaon, Maharashtra, India

²Department of Radiology, TNMC and BYL Nair Hospital, Mumbai Central, Mumbai, Maharashtra, India

Address for correspondence Rushit S. Shah, MD, DNB, FRCR, Department of Radiology, TNMC and BYL Nair Hospital, Mumbai Central, Mumbai 400008, Maharashtra, India (e-mail: grey612@gmail.com).

Indian J Radiol Imaging 2023;33:218–229.

Abstract

Plain abdominal radiographs and gastrointestinal contrast studies remain the first line of investigation for the evaluation of several conditions due to their easy availability and ease of use in pediatric patients. A systematic approach to evaluating the plain radiograph for pediatric abdomen can lead the radiologist to a relevant differential diagnosis in most cases. In other cases, it leads the radiologist to the next line of investigation. The plain radiograph of the abdomen is requested for several conditions ranging from abdominal pain, vomiting, failure to pass meconium, abdominal distension, perforation, mass or for suspected obstruction. The radiation dose involved in abdominal radiography, although significant, the diagnostic information provided outweighs the risk. Dose reduction techniques should be employed to reduce the radiation dose to infants and children. Spectrum of atresias and stenosis from the esophagus up to the rectum, Hirschsprung disease, small left colon syndrome, and anorectal malformations can be identified with a detailed and systematic contrast study. They act as an adjunct in the diagnosis of conditions such as intussusception and hypertrophic pyloric stenosis. Inflammatory conditions such as acute appendicitis, necrotizing enterocolitis, and acute conditions such as pneumoperitoneum are also well appreciated on plain abdominal radiographs.

Keywords

- ▶ plain radiograph
- ▶ abdomen
- ▶ pediatric
- ▶ intestinal obstruction
- ▶ pneumoperitoneum

Introduction

Plain abdominal radiographs and gastrointestinal (GI) contrast studies remain the first line of investigation in most of the health care facilities due to its easy availability. Radiography and fluoroscopy are more useful in the pediatric age group due to the long examination time involved in magnetic resonance imaging (MRI) and a high dose of radiation in computed tomography (CT) examinations. For the uninitiated, reading a pediatric abdominal radiograph can be a daunting task.

However, a systematic approach with the identification of subtle signs can give a plethora of information about the underlying pathology and lead the radiologist to a relevant differential diagnosis.

Technique

Most commonly, the AP supine position is used for acute abdomen. Occasionally, special views are obtained for identifying conditions such as anorectal malformations. Additional

article published online
December 29, 2022

DOI [https://doi.org/
10.1055/s-0042-1759481](https://doi.org/10.1055/s-0042-1759481).
ISSN 0971-3026.

© 2022. Indian Radiological Association. All rights reserved.
This is an open access article published by Thieme under the terms of the Creative Commons Attribution-NonDerivative-NonCommercial-License, permitting copying and reproduction so long as the original work is given appropriate credit. Contents may not be used for commercial purposes, or adapted, remixed, transformed or built upon. (<https://creativecommons.org/licenses/by-nc-nd/4.0/>)
Thieme Medical and Scientific Publishers Pvt. Ltd., A-12, 2nd Floor, Sector 2, Noida-201301 UP, India

techniques such as automatic exposure control, beam collimation, and dose adjustment need to be employed to reduce the dose to the patient. Beam collimation should be judiciously used so as not to miss out on the area of interest. Radiation dose to children from a single AP abdomen radiograph varies by age from 0.077 mSv at birth to 0.509 mSv at the age of 10 years.^{1,2}

Indications

The plain abdominal radiograph is often the initial imaging modality ordered for abdominal pain, distension, constipation, vomiting, obstruction, perforation and occasionally for an abdominal mass or for ruling out gastrointestinal anomalies. A list of clinical indications for which an abdominal radiograph can be advised with the dosage information can be found on 'Refer: making the best use of clinical radiology guidelines, 8th edition' published by the Royal College of Radiologists.³ An upright or left lateral decubitus view may be obtained if there is a concern for intraperitoneal free air or air-fluid levels. However, in a majority of cases, a single supine radiograph will yield sufficient information and the absence of significant radiographic findings on a single radiograph may be all that is necessary to appropriately triage a pediatric patient with abdominal pain.

Indications for the use of oral or rectal contrast include evaluating many conditions including but not limited to gastroesophageal reflux, malrotation, and midgut volvulus, hiatus hernia, evaluation of strictures and aberrant anatomy, meconium ileus, small bowel obstruction, Hirschsprung's disease, functional immaturity of the large bowel, and large bowel atresia. The choice of contrast depends on the condition to be evaluated. In neonates, especially premature infants, and in circumstances where aspiration is a risk or a perforation of the GI tract is suspected, a low-osmolality water soluble non-ionic contrast media is ideally used. Also, for evaluating distal bowel obstruction, water-soluble contrast media are preferred as there may be potential for bowel perforation.⁴

Intussusception

Intussusception is an acquired invagination or 'telescoping' of the bowel into itself, usually involving both small and large bowels, which can lead to bowel edema and subsequent ischemia. Prolonged delay in diagnosis is not uncommon, resulting in an increased risk of obstruction, necrosis, and bowel perforation. In frequency, it is second only to pyloric stenosis as a cause of gastrointestinal tract obstruction in children, occurring more often in boys than in girls at a ratio of 3:2. Classic pediatric intussusception involves the invagination of the distal ileum into the colon, as ileocolic or ileoileocolic intussusception; however, intestinal intussusception may occur along the entire length of the bowel from the duodenum to the colon. Most cases of intussusception are idiopathic. Approximately 5 to 6% of cases have a pathological lead point such as the Meckel diverticulum, duplication cyst, polyp, and lymphoma. Idiopathic intussusception occurs most commonly in infants between 2 months and 3 years of age, with a peak at age 5 to 9 months. The classic

clinical presentation of the child with intussusception is colicky abdominal pain, vomiting, bloody stools (currant jelly stools) and a palpable abdominal mass.^{5,6}

The role of plain abdominal radiography in the diagnosis of intussusception is three-fold. (a) When the clinical suspicion is low, the role of plain radiograph is to allow the exclusion of intussusception and diagnosis of other pathologic processes. (b) When the clinical suspicion is high, to allow confirmation of intussusception. (c) If intussusception is present, the role of plain radiography is to allow exclusion of complications such as intestinal obstruction or perforation. Adding a left side down decubitus view has been shown to improve sensitivity.^{5,6}

Signs of intussusception on plain abdominal radiograph include—1: a non-specific soft tissue mass, most often seen in the right upper quadrant effacing the adjacent hepatic contour; 2: specific signs such as the target sign (circular mass with circular or nearly circular areas of lucency due to mesenteric fat within) and the meniscus sign (crescent of gas within the colonic lumen that outlines the apex of the intussusception); 3: the presence of a curvilinear mass within the course of the colon (the crescent sign), particularly in the transverse colon just beyond the hepatic flexure, is nearly pathognomonic of intussusception (→Fig. 1A); 4: other signs include reduced air in the small intestine or a gasless abdomen, air in a displaced appendix and obstruction of the small intestine. On barium enema, the signs of

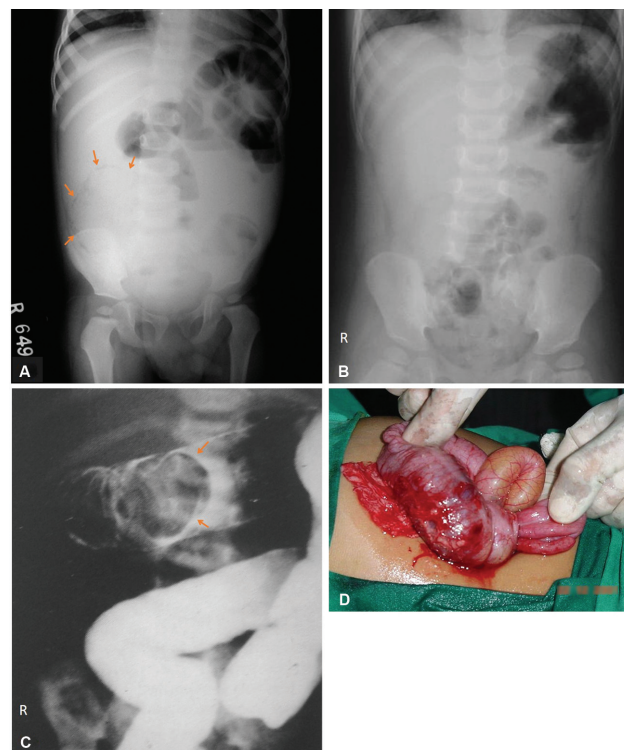


Fig. 1 Intussusception. (A) Plain radiograph of the abdomen showing a curvilinear soft tissue mass with crescentic lucency (arrows) representing the crescent sign in a case of intussusception. (B) Plain radiograph of another patient showing a soft tissue density in the left upper quadrant. (C) Barium enema of the same patient showing the pincer shaped filling defect (arrows) in the transverse colon representing the intussusceptum. (D) Intussusception was confirmed intraoperatively.

intussusception are the coiled spring sign and the meniscus sign.⁶ Some authors have also described it as claw sign or pincer sign representing the pincer shaped filling defect in the bowel (►Fig. 1B–D).

Ultrasound is highly sensitive in the detection of intussusception. Initial evaluation by ultrasound circumvents the more invasive enema in patients who do not have intussusception, and it allows diagnosis of other conditions, such as mesenteric adenitis or colitis, for which performance of an enema would not be the procedure of choice.⁶

Hypertrophic Pyloric Stenosis

Hypertrophic pyloric stenosis (HPS) is the most common surgical entity affecting infants during the first 6 months of life. Data indicate that HPS is not present at birth and its symptoms and characteristic anatomic changes typically present between 3 and 12 weeks of age. The pyloric antrum is no longer distensible and therefore is no longer clearly demarcated from the pyloric sphincter. The entire complex presents as one elongated canal with thickened muscular walls and filled with edematous mucosa. Babies with HPS typically present with a history of forceful nonbilious vomiting, often described as “projectile.” Physical examination through palpation reveals an “olive” or “pyloric tumor” shaped mass, which is diagnostic in experienced hands.⁷

Plain radiographs may reveal a markedly distended stomach, with little gas distally (►Fig. 2B). Gastric hyperperistalsis may be seen as the ‘caterpillar configuration’ of the stomach.⁸ On upper gastrointestinal (GI) series, it appears as a “beak” that evolves into a “string” (►Fig. 2C) or a “double track” sign. Other signs for hypertrophic pyloric stenosis have been historically described, such as the “shoulder sign,” “apple core lesion,” and “mushroom sign” or “umbrella sign.”^{7–9} A diagrammatic representation of various signs seen in HPS has been shown in ►Fig. 2A.

The most common antropyloric abnormality mimicking HPS on an upper GI series is pylorospasm. Although a spasm also may cause the pyloric muscle to appear thicker on ultrasound, a spasm is a transient phenomenon usually distinguishable from HPS and a follow-up examination would suffice to differentiate the two. Before the advent of ultrasound, the upper GI series was widely used for diagnosis of HPS, however currently with direct visualization of the antropyloric region by ultrasound, it is preferred for the diagnosis of HPS.⁷

Neonatal Obstructions

In neonates and young children, there is no radiographic “signature” of small bowel and large bowel and they cannot be differentiated well from one another. In a clinically obstructed newborn, the number of dilated loops (“dilated” meaning roughly wider than the vertebral interpedicular space) may be more helpful. Neonatal intestinal obstruction can be classified by location with respect to proximal jejunum as high and low.^{10,11}

The causes of neonatal intestinal obstruction are enlisted in ►Table 1.^{10,11}

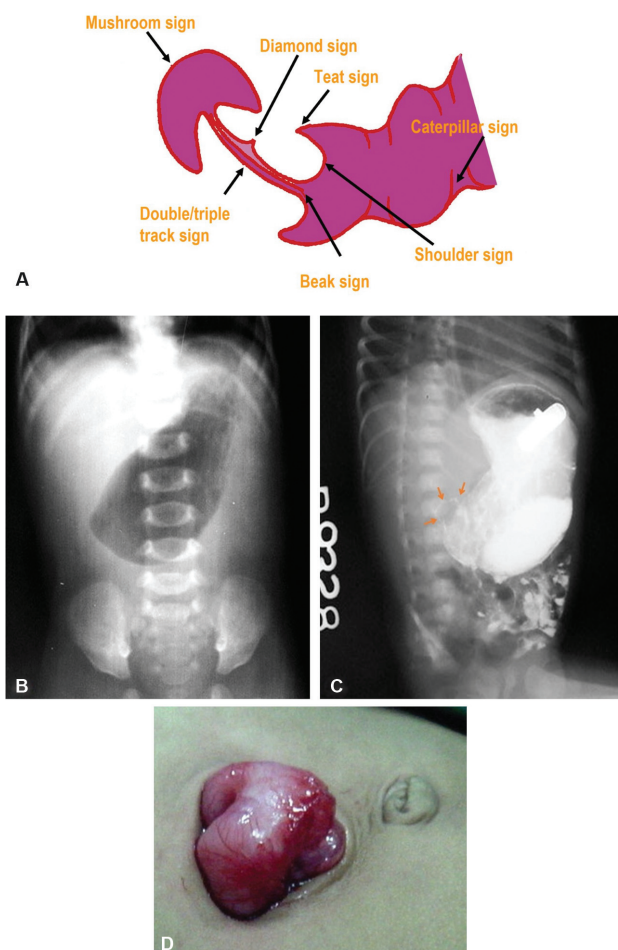


Fig. 2 Hypertrophic pyloric stenosis. (A) A diagrammatic representation of the components that form the various signs in hypertrophic pyloric stenosis. (B) Plain abdominal radiograph of an infant presenting with projectile bilious vomiting showing a markedly distended stomach with no gas distally and (C) upper GI series of the same child showing distended contrast-filled stomach and a linear “string” of contrast (arrows) seen in the pylorus. (D) Intraoperative picture of the same patient showing the thickened pylorus consistent with hypertrophic pyloric stenosis.

Table 1 Causes of neonatal intestinal obstruction

High intestinal obstruction	Low intestinal obstruction
Esophageal atresia	Small bowel involvement
Gastric atresia	Ileal atresia
Duodenal atresia	Meconium ileus
Duodenal stenosis (with annular pancreas)	Large bowel involvement
Duodenal web	Functional immaturity of the colon
Malrotation (may be complicated by volvulus)	Hirschsprung’s disease
Jejunal atresia and stenosis	Colonic atresia
	Anal atresia and anorectal malformations

Gastric Atresia

This rare entity is typically localized to the antrum or pyloric region. There is an association between pyloric atresia and epidermolysis bullosa.¹² The classical signs of pyloric atresia on plain abdominal radiograph are gas distended stomach with no air seen in the distal intestinal loops, classically described as the single bubble sign. This can be confirmed on upper GI study.¹¹

Duodenal Atresia and Stenosis

Complete duodenal obstruction in neonates is caused by duodenal atresia from failure of recanalization. Duodenal atresia is frequently associated with other congenital anomalies, such as additional intestinal atresias, congenital heart disease, or as a part of the VACTERL association. The abdominal plain radiograph is usually diagnostic and shows the classical “double-bubble sign,” with gas filling a distended stomach and proximal duodenum with no distal gas (►Fig. 3). If plain radiographs are not diagnostic, air, or barium can be injected through the nasogastric tube for confirmation. In incomplete duodenal obstructions, a double bubble is accompanied by the presence of gas in the distal bowel. Failure of the contrast material to pass beyond the atretic segment and duodenal bulb dilation out of proportion to the stomach are typical findings on upper gastrointestinal examination in atresia. In patients with duodenal stenosis, an upper GI series will confirm the partial obstruction with the presence of air in the distal bowel loops indicating partial obstruction. This may be associated with annular pancreas. When a web is present, the membrane may be seen as a thin linear filling defect.¹¹

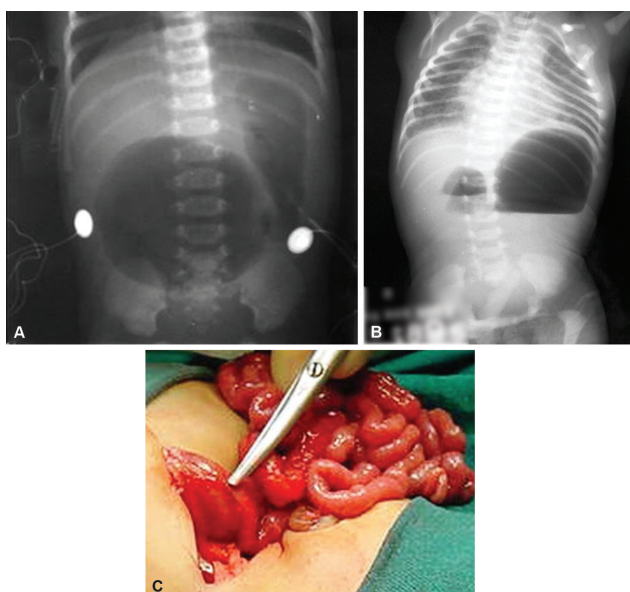


Fig. 3 Duodenal atresia. (A) Plain radiograph of the abdomen showing the classical “double bubble” sign with no gas distally in a case of duodenal atresia. (B) Plain abdominal radiograph of another newborn with duodenal atresia showing the distended stomach and duodenum with air-fluid levels and no distal gas consistent with the double bubble sign of duodenal atresia. (C) Findings were confirmed intraoperatively.

Malrotation

Normally, physiologic counter clockwise bowel rotation (270 degrees around the axis of the superior mesenteric artery) leads to duodenojejunal and ileocecal junctions that are appropriately situated in the left upper and right lower quadrants, respectively (►Fig. 4A). The term “malrotation” indicates that the normal rotation of the midgut was not completed, thus presenting a spectrum of abnormalities that affect both the duodenojejunal and ileocecal junction, singly or in unison. In malrotation, different degrees of abnormal location of these two key intestinal segments produce a narrower mesenteric attachment, which places the small bowel at risk for twisting around its pedicle, a condition known as “midgut volvulus.” Midgut volvulus causes both mechanical obstruction and arterial occlusion of the mesenteric vessels.^{10,11,13}

The abnormalities of rotation¹² can be described as:

1. Nonrotation
2. Reversed rotation
3. Incomplete rotation and malfixation.
4. Hyper-rotation.

Plain abdominal radiograph in patients with malrotation without obstruction or volvulus may show an abnormal distribution of stool, with the absence of stool pattern in the right lower quadrant, which has been termed the radiologic “Dance’s sign.” In patients with nonrotation, all colonic stool may be seen as confined to the left half of the abdomen.⁷

An upper GI series is at present considered the standard examination to evaluate for malrotation and for its complications, particularly volvulus (►Fig. 4B–D), which classically appears as an abnormal course of the duodenum that fails to cross the midline combined with a circular duodenal configuration (corkscrew appearance) (►Fig. 4E–H).¹¹ Ultrasound is however useful in demonstrating the relationship of the superior mesenteric artery and vein in the diagnosis of malrotation.

Jejunal Atresia and Stenosis

Atresia and stenosis affect the jejunum and ileum more commonly (approximately 51% incidence) than any other portion of the abdominal gastrointestinal tract.¹⁰ Newborns with jejunal atresia usually present with bilious emesis and abdominal distention. Plain abdominal radiography typically shows several dilated bowel loops, more than the double bubble of duodenal atresia but fewer than the low obstruction pattern. Characteristic dilatation of the stomach, duodenum, and proximal jejunum is known as the “triple-bubble sign.” The loop of the jejunum immediately proximal to the atresia is frequently disproportionately dilated and has a bulbous end. No gas is seen distal to the atresia and there is the absence of gas in the rectum. In most instances, an upper gastrointestinal study is not necessary before surgical repair. However, if obtained, an upper gastrointestinal study usually shows a dilated duodenum and proximal jejunum, both of which are filled with contrast material. A contrast enema study also is often performed to evaluate for possible concomitant distal bowel atresias before surgical repair.¹¹

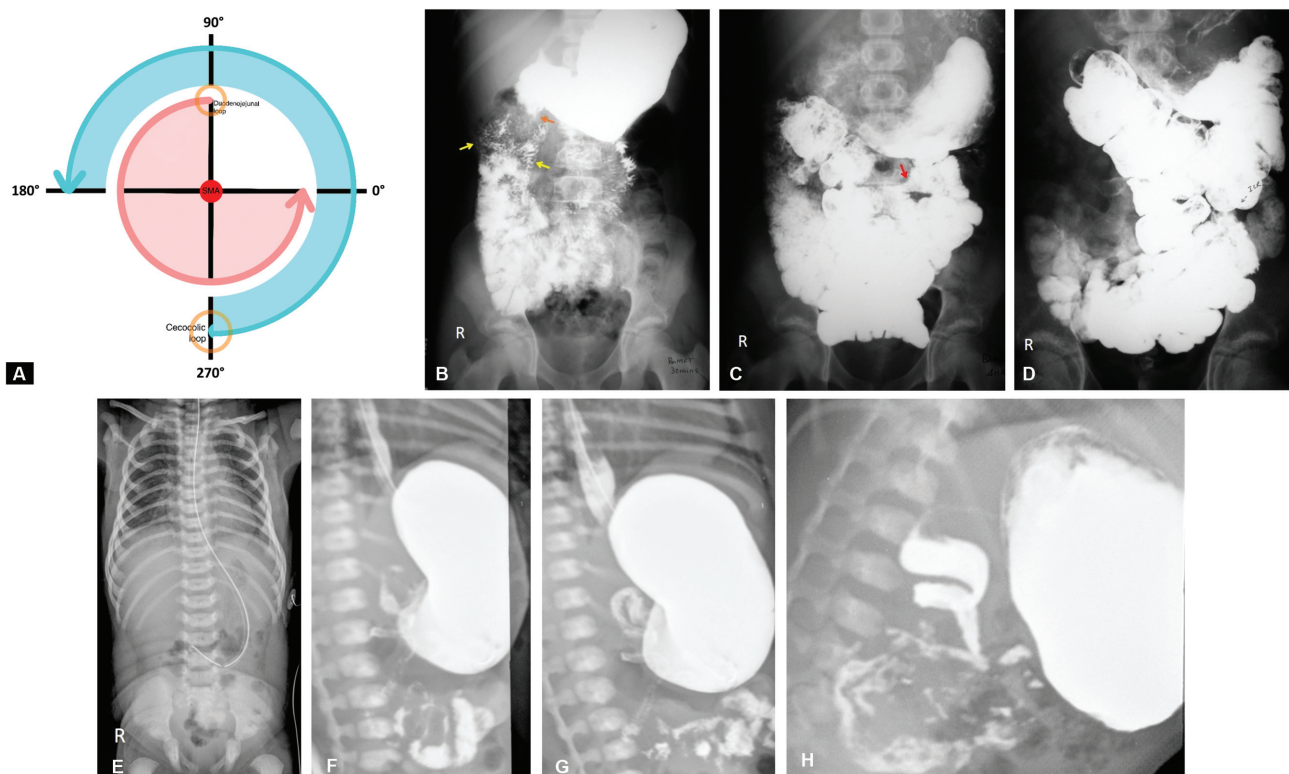


Fig. 4 (A) Normal physiologic rotation of the intestines during development. (B) Barium meal follow through of a child with malrotation shows the duodenojejunal flexure to the right side of the midline (orange arrow) and jejunal loops in the right upper quadrant of the abdomen (yellow arrows). (C) (D) The ileo-cecal junction (red arrow) is seen in the left mid abdomen. (E) Plain radiograph of another patient with malrotation shows paucity of bowel loops in the upper abdomen. (F–H) Barium meal follow through of different patients showing the classical cock screw appearance of the duodenal C-loop in case of malrotation.

Ileal Atresia

Ileal atresia is a common cause of low intestinal obstruction in neonates, with the distal portion of the ileum being most commonly involved. Plain abdominal radiography shows numerous dilated bowel loops with air fluid levels (→Fig. 5A). Peritoneal calcifications indicate that the atresia is complicated by meconium peritonitis. A contrast enema study shows termination of the contrast filled colon up to the terminal ileum if the atresia is in the terminal ileum. The contrast enema will reveal a very small, unused colon, known

as a microcolon, whose lumen has not been distended by swallowed material or succus entericus (→Fig. 5B). The differential diagnoses of microcolon are distal small bowel obstruction, ileal atresia, or meconium ileus.^{10,11} Other rarer causes of small intestinal obstruction may be seen such as jejunal diaphragm and intestinal bands. These usually show the presence of multiple air fluid levels on abdominal radiographs (→Fig. 6).

Meconium Ileus

Meconium ileus accounts for approximately 20% of cases of neonatal intestinal obstruction and denotes an obstruction in the terminal ileum secondary to inspissated meconium. Meconium ileus is the initial presentation in approximately 15% to 20% of patients with cystic fibrosis. Occlusion of the distal small bowel results in mechanical obstruction with subsequent distention of the more proximal bowel loops. Neonates with meconium ileus usually show a pattern of low intestinal obstruction that is characterized by multiple proximal bowel loop dilatations (→Fig. 7A). Despite the marked intestinal dilatations, there is often a relative lack of air-fluid levels within the dilated bowel loops because of the abnormally thick intraluminal meconium.¹¹

A contrast enema study typically shows an unused colon (microcolon), within which are multiple small filling defects representing meconium concretions (→Fig. 7B). If there is reflux of contrast material beyond the ileocecal valve, these concretions may also be seen in the terminal ileum, rendering a

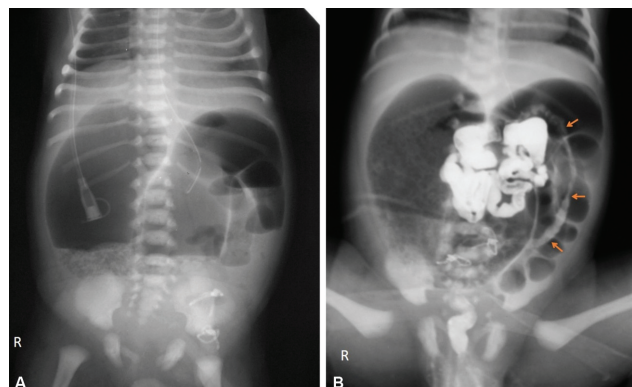


Fig. 5 Ileal atresia with microcolon and malrotation. (A) Plain radiograph of the neonate with ileal atresia showing multiple dilated small bowel loops in the abdomen up to the distal ileum. (B) Water-soluble contrast enema shows a microcolon (orange arrows) with ileo-cecal junction in the left upper quadrant of the abdomen.

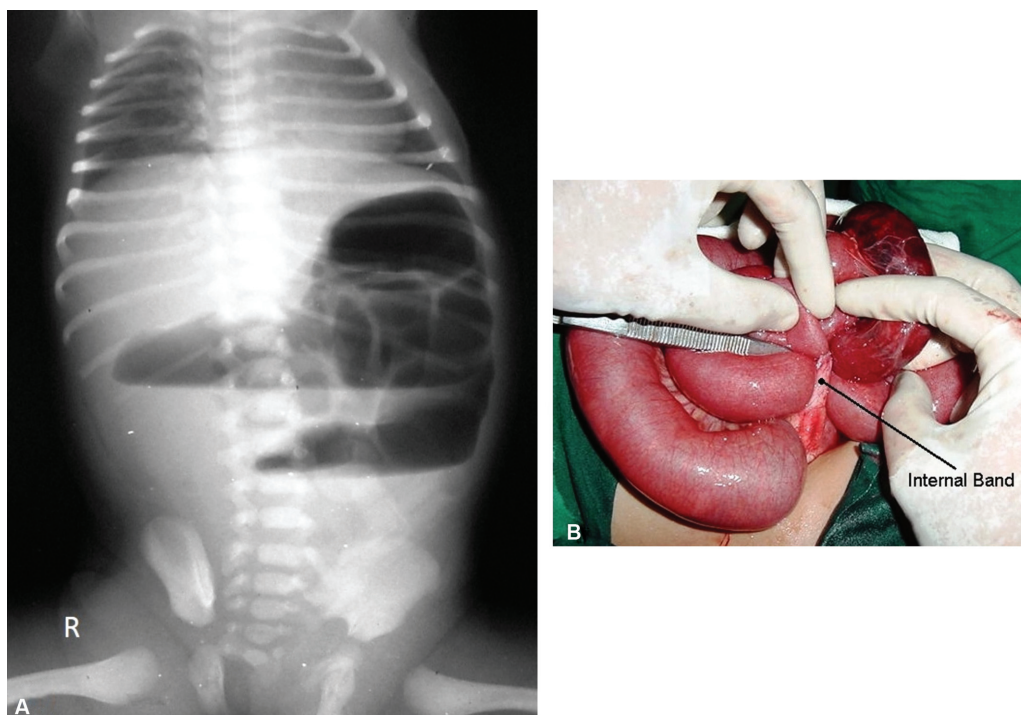


Fig. 6 (A) Plain radiograph of a child presenting with vomiting showing grossly dilated bowel loops with multiple air fluid levels indicating small bowel obstruction. (B) Intraoperatively, an intestinal band was found which was the cause of obstruction.

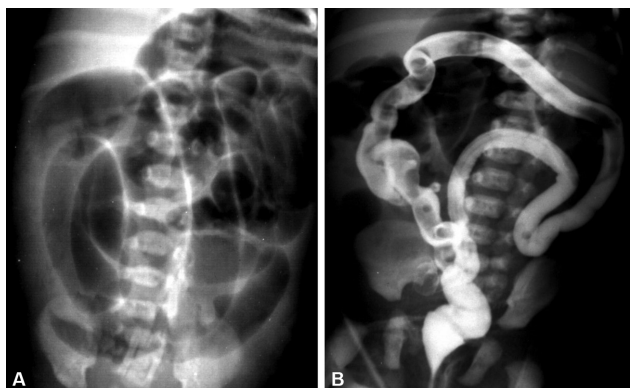


Fig. 7 (A) Plain radiograph of a newborn with meconium ileus shows multiple dilated bowel loops with absence of air fluid levels suggestive of a distal small bowel obstruction. (B) Barium enema of the same patient shows the small caliber of the colon (microlon) with rounded filling defects due to meconium pellets. This gives the soap bubble appearance.

characteristic “soap bubble” appearance. Meconium ileus may be complicated by volvulus, perforation. Intrauterine perforation may lead to meconium peritonitis (chemical peritonitis) and peritoneal calcifications, which may be seen postnatally on abdominal radiographs (–Fig. 8A). Meconium peritonitis sometimes has been categorized as several distinct forms: fibroadhesive, cystic (–Fig. 8B–E) and generalized.^{10,14}

Colonic Atresia

Colonic atresia is exceedingly rare and the diagnosis is often made clinically (vomiting and failure to pass meconium). Abdominal radiographs typically show multiple dilated bowel loops, multiple air–fluid levels and absence of air in

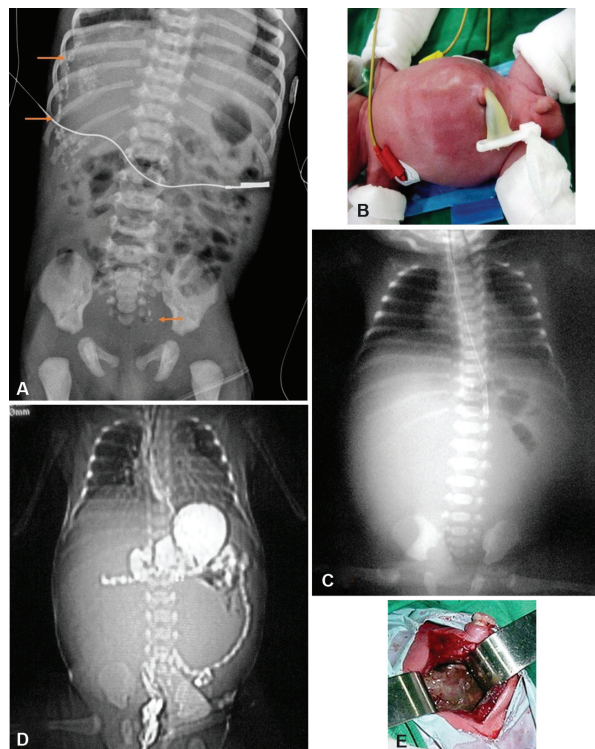


Fig. 8 (A) Plain radiograph of a newborn showing calcifications (solid arrows) along the peritoneal lining in the right upper quadrant. A few calcifications are also seen in the pelvis. These findings are suggestive of meconium peritonitis. (B) New born presenting with abdominal distension. (C) Plain radiograph of the abdomen showing a homogeneous opacity in the central abdomen displacing the bowel loops peripherally. (D) CT scanogram of the same patient showing peripherally displaced bowel loops. (E) Intraoperatively, the findings were confirmed and a diagnosis of cystic meconium peritonitis was made.

the rectum. Contrast enema reveals failed passage of contrast proximal to the level of the colonic atresia.¹⁵

Hirschsprung Disease

Hirschsprung disease is characterized by the failure of normal bowel innervation (absence of ganglion cells) as a result of the arrest of the proximal to distal migration of vagal neural crest cells and is therefore considered a neurocristopathy. A variable length of the distal bowel lacks parasympathetic Auerbach (intermuscular) and Meissner (submucosal) plexuses and is unable to participate in normal peristalsis, resulting in the failure of relaxation and functional obstruction. The presence of the transition point at the rectosigmoid is termed short-segment aganglionosis and occurs in approximately 80% to 90% of cases. Hirschsprung's disease is most commonly associated with Down's syndrome, which is present in approximately 2 to 10% of patients with Hirschsprung's disease.^{10,15}

In neonates, the abdominal radiograph demonstrates distal bowel obstruction. On prone cross table lateral radiograph, gas is usually seen in the rectum, unlike small bowel obstruction or colonic atresias. In older children, there may be no signs of small bowel obstruction and the radiograph may just show signs of constipation such as marked dilatation of the colon.

Contrast enema identifies the zone of transition, i.e., the region in which there is a perceptible change in caliber, with the dilated normal colon above and the narrowed aganglionic colon below (►Fig. 9A–C). The study is done with a small catheter, which should be placed as close to the external sphincter as possible in neonates (►Fig. 9D–F). Water-soluble iso-osmolar agents are preferred in neonates. The enema is terminated when the zone of transition is identified.^{10,11,15}

A rectosigmoid ratio < 0.9 is typical. On fluoroscopy, irregular saw-toothed mucosal pattern or changing serrated pattern may be seen due to disordered contractions in the aganglionic segment. Another radiographic appearance is the presence of straight transverse bands in the involved segment of the colon, which are thought to represent areas of persistent spasm.¹⁶ Colonic evacuation is impaired in patients with Hirschsprung's disease, which can be evaluated by a comparison of pre-evacuation and delayed post-evacuation images.^{10,11,15}

Meconium Plug, Small Left Colon, and Dysmotility of Prematurity

In patients with meconium plug syndrome, a plug of meconium is identified within the colon, which, when evacuated, has a characteristic "white head." The etiology of these

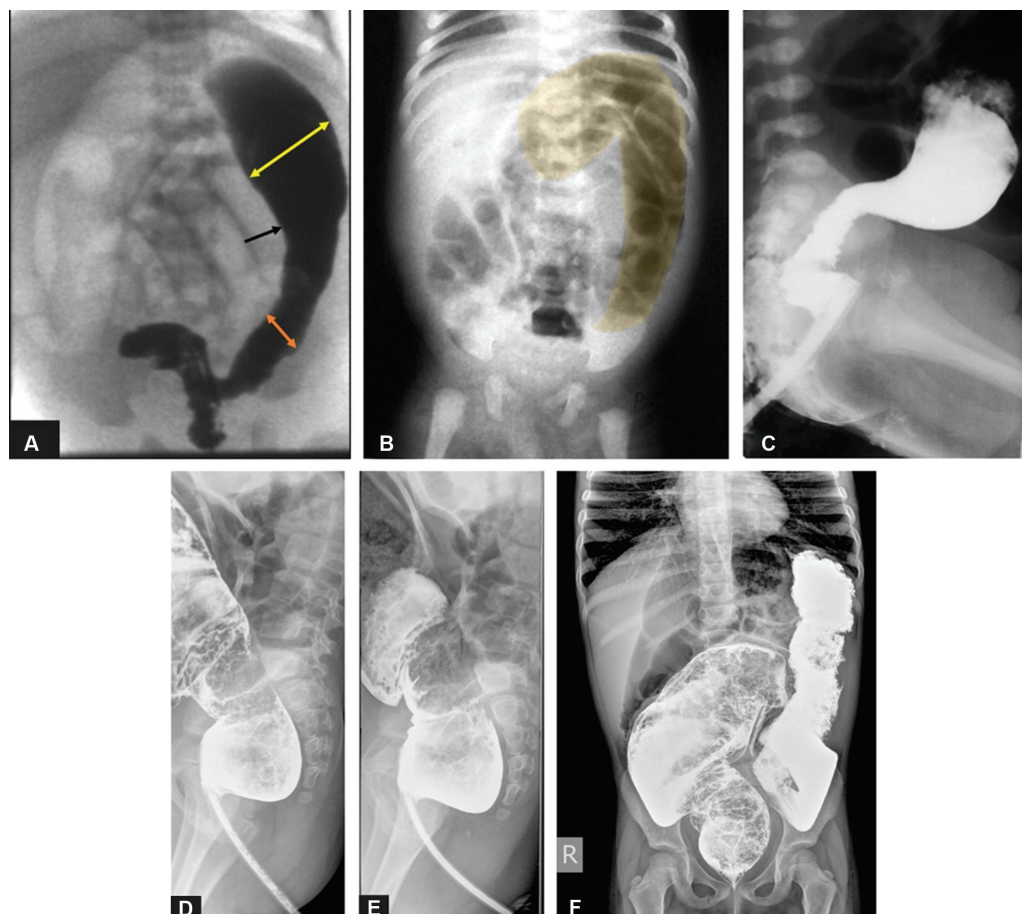


Fig. 9 Hirschsprung's disease. (A) Barium enema showing an abrupt change in caliber of colon (black arrow marks 'transition zone.' Orange double headed arrow shows the smaller caliber of the aganglionic segment. Yellow double-headed arrow shows the larger caliber innervated segment). (B) Plain radiograph of another child shows a grossly dilated air filled colon (Shaded yellow) with little or no gas in the rectum. (C) Contrast enema of the same patient showing the small caliber of the rectum and dilated sigmoid colon suggestive of classic Hirschsprung's disease (D–F) Contrast enema of another patient showing long-segment dilatation of the sigmoid and descending colon.

conditions is believed to be delayed maturation of effective peristalsis and/or abnormally increased water absorption by the colon, leading to a more tenacious meconium.^{10,14}

Abdominal radiographs show typical findings of distal obstruction with multiple dilated loops of bowel, but the degree of dilatation tends to be lesser as compared to atresias. A diagnostic enema should be performed with water-soluble contrast material with a near iso-osmolal concentration. The enema demonstrates a colon of normal caliber, typically with a long-filling defect caused by the meconium plug, in cases of meconium plug syndrome. The patient may evacuate this at the conclusion of enema examination. In small left colon syndrome, the examination will reveal a small-caliber colon involving a variable length of sigmoid and descending colon, with a typically normal caliber rectum (►Fig. 10).^{10,11,14}

In low intestinal obstruction, it is important to differentiate different entities that present with microcolon. The two most common causes of high-grade distal ileal obstruction leading to this pattern are meconium ileus and ileal atresia. The two can be distinguished by the contrast enema. If refluxed contrast reaches ileal loops containing multiple filling defects, a diagnosis of meconium ileus can be made. If no reflux can be achieved, then ileal atresia is the presumptive diagnosis. Total colonic Hirschsprung's disease can also produce a microcolon appearance; however, this is uncommon. A short or incomplete microcolon

allows a diagnosis of colonic atresia. A demonstrable transition from small- or normal-caliber colon distally to more dilated colon proximally narrows the differential diagnosis to two entities: Hirschsprung's disease and small left colon syndrome. Small left colon syndrome is the presumptive diagnosis when the caliber transition is at the splenic flexure, assuming that meconium evacuation and decompression follow the contrast enema within 24 to 48 h. Hirschsprung's disease is the likely diagnosis if the transition is elsewhere in the colon. Although the transition point may be found at splenic flexure even in case of Hirschsprung's disease.

Anorectal Malformations

Anorectal malformations encompasses the spectrum of anal atresia and stenosis. Anal atresia, also known as "imperforate anus," is a condition of unknown cause in which there is the absence of a normal anal opening. With an estimated incidence of 1 in 5000 live births, they are slightly more common in boys.⁴ Anal atresia is associated with other congenital anomalies, including vertebral, cardiac, renal and limb anomalies. Although there are currently numerous classification schemes for anal atresia, it is traditionally divided into high and low lesions, depending on whether the rectum ends above or below the puborectalis sling. In a low anal atresia, the rectum remains close to the skin in a blind pouch. In a high anal atresia, the rectum is located high in the pelvis and there may be a fistulous connection between it and the bladder, urethra, or vagina. Although the diagnosis can be made on the basis of physical examination alone, abdominal radiography can be useful for determining whether the atresia is of high or low type, which helps in surgical planning (►Fig. 11).

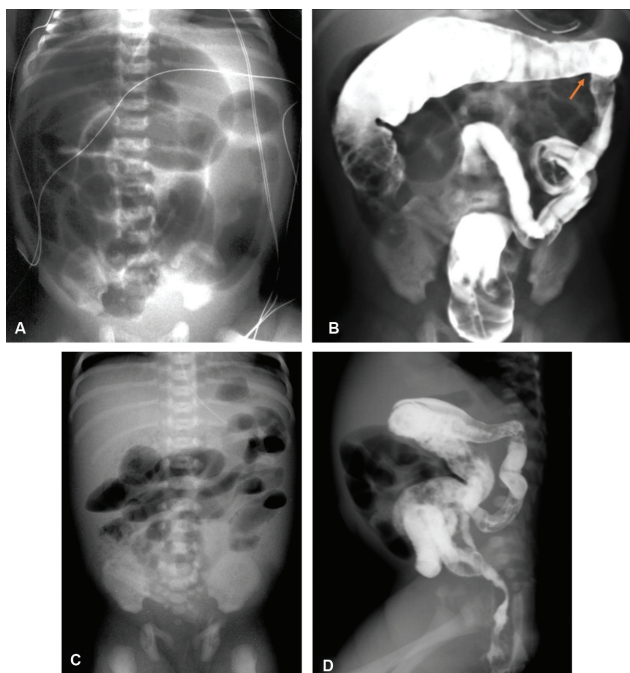


Fig. 10 Small left colon syndrome. (A) Plain abdominal radiograph of a newborn with small left colon syndrome shows air filled dilated bowel loops representing distal small bowel obstruction. (B) Contrast enema of the same patient showing a small caliber descending colon. The point of transition was seen at the splenic flexure (arrow). (C) Plain abdominal radiograph of another premature infant with small left colon syndrome shows air filled dilated bowel loops. (D) Contrast enema of the same patient showing a small caliber of the descending colon.

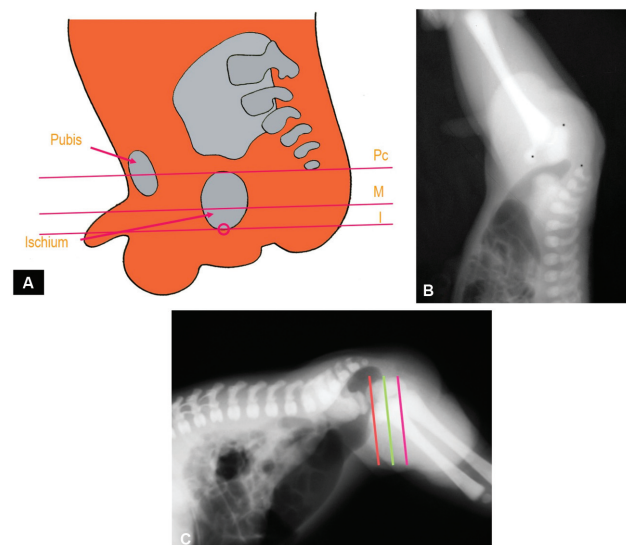


Fig. 11 Anorectal malformation. (A) Diagrammatic representation of lines drawn on invertogram and classification of anorectal malformations based on these lines. (B) The invertogram shows the absence of gas extending up to the anal pit. (C) Prone cross table radiograph shows the gas bubble above the 'M' line (green line) indicating a high anorectal malformation. (PC-pubococcygeal line, M-M line, I-I line).

Table 2 Bell's stage and corresponding radiographic finding in necrotizing enterocolitis

Stage	Radiographic finding
I	Normal bowel gas pattern or mild ileus
IIA	Ileus pattern and focal pneumatosis
IIB	Extensive pneumatosis ± portal venous gas and ascites
IIIA	Prominent ascites and persistent bowel loops
IIIB	Pneumoperitoneum

Abdominal radiographs usually show a low intestinal obstruction pattern. The invertogram though a past practice is still obtained at a few centers due to the confidence level of pediatric surgeons. A lateral view obtained in the prone position is valuable for showing the level of rectal descent. Fistulous tracts between the rectum and urinary bladder, vagina or skin can be demonstrated in contrast studies.¹¹

Infectious, Ischemic, and Inflammatory Intestinal Pathology

Necrotizing Enterocolitis

Necrotizing enterocolitis is a term coined in 1953 to describe an inflammatory condition affecting the gastroin-

testinal tract of neonates, most commonly premature infants who survive the first few days of life and are receiving enteral nutrition. A classification of enterocolitis-based on clinical severity was suggested by Bell et al. The Bell criteria have corresponding radiographic findings as described in ►Table 2 and ►Fig. 12.^{10,17}

Acute Appendicitis

Plain radiographs show ileus locating to the right lower quadrant, scoliosis from the splinting, appendicolith and apparent small bowel obstruction may be seen. Abscess with mass effect and/or atypical air collection may also be seen on radiographs.¹⁷ Ultrasound may demonstrate the inflamed appendix with high sensitivity and specificity.

Pneumoperitoneum

The term pneumoperitoneum refers to the presence of air within the peritoneal cavity. Free intraperitoneal air is most commonly a consequence of gastrointestinal tract perforation. In the neonate, this usually results from intestinal obstruction, necrotizing enterocolitis, or spontaneous gastric or bowel perforation, usually at the ileocecal region. In children beyond the neonatal period, perforated peptic ulcers and inflammatory bowel disease are other causes of pneumoperitoneum. Trauma, both accidental and nonaccidental, may also result in pneumoperitoneum.^{18,19}

Once pneumoperitoneum is suspected on supine abdominal radiograph, the diagnosis can be confirmed on horizontal-beam erect radiographs. The decubitus view should be obtained with the right side up in young children and patients who are too ill and cannot sit or stand. If decubitus or upright imaging is difficult to obtain, a supine view using a horizontal-beam technique can be utilized.

On upright radiographs, air can be seen collecting under the diaphragm and the liver on the right and between the diaphragm and the liver, spleen, stomach, or colon on the left. Multiple signs related to pneumoperitoneum are described on plain radiographs based on the location and volume of air and its relationship to adjacent structures as described in ►Table 3, ►Fig. 13.^{18–21}

Conclusion

The abdominal radiograph is the first investigation to be ordered in cases of suspected abdominal pathology. It is useful as the sole imaging modality for establishing a diagnosis in certain conditions and as a guide for further investigations in other conditions. A checklist and approach to interpreting the abdominal radiograph is shown in ►Fig. 14. Fluoroscopic contrast studies are helpful in confirming the diagnosis. Interpretation of the abdominal radiograph is a challenging task and thus requires a systematic approach, rapid and precise identification of subtle signs and sound knowledge of underlying pathology to reach a relevant differential diagnosis.

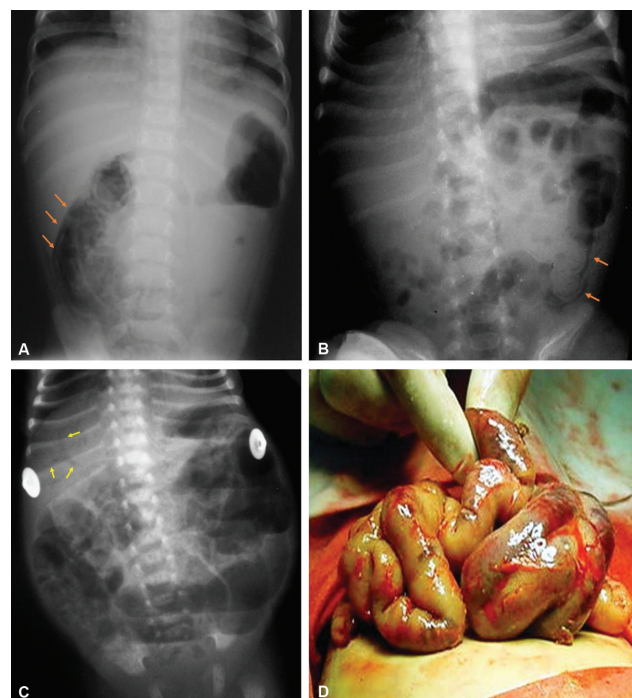


Fig. 12 Necrotizing enterocolitis. (A) Plain radiograph of a child showing air in small bowel wall (arrows) representing pneumatosis intestinalis. (B) Another radiograph showing air in the bowel wall as linear lucency along the bowel wall representing pneumatosis intestinalis (orange arrows). (C) Plain radiograph of another infant showing dilated bowel loops and linear branching lucency over the liver shadow (yellow arrows) representing air in the portal veins consistent with necrotizing enterocolitis. (D) Intraoperative image showing pale dilated bowel loops.

Table 3 Signs of pneumoperitoneum and their descriptors

Sign	Description
Right upper quadrant signs	
Hyperlucent liver sign	Air overlying the liver on a supine radiograph decreases the radiodensity of that portion of the liver over which it lies.
Anterior superior oval sign	single or multiple oval, round, or pear-shaped gas bubbles projected over the liver shadow
Fissure for ligamentum teres sign	Linear collection of air in the fissure of the ligamentum teres
Doge cap sign (Morison pouch sign)	Triangular collections of air in the Morrison's pouch (resembles the cap worn by the Venetian Doge)
Hepatic edge sign	Linear collections of air in the right subhepatic space
(Leaping) dolphin sign ²²	intra-peritoneal gas highlights different slips of muscle in the diaphragm giving arcuate lucencies which converge superomedially and resemble leaping dolphins. Some authors have also described it as muscle slip sign.
Bowel-related signs	
Rigler's sign/ghost sign/ double wall sign/bas-relief sign	both sides of the bowel wall can be visualized due to the presence of air on both sides of the bowel wall
Telltale triangle sign	Free intraperitoneal air accumulating among three adjoining bowel loops or two bowel loops and the parietal peritoneum appearing as a triangular radiolucency
Peritoneal ligament related signs	
Falciform ligament sign (Silver sign)	Intra-peritoneal free air outlining the falciform ligament, seen as a linear density situated longitudinally within the right upper abdomen
Inverted V sign	Air is seen outlining the medial umbilical folds in the pelvis.
Urachus sign	Air outlining the urachus seen as a thin midline linear structure in the lower abdomen from the umbilicus to the dome of the urinary bladder
Miscellaneous signs	
Football sign	Distension of the flanks caused by the free intraperitoneal air and the outline of the falciform ligament centrally form the elements of the well-known football sign
Cupola sign (Lord Nelson's hat sign)/ saddlebag or moustache sign	Air in the central subphrenic space beneath the central tendon of the diaphragm seen as an arcuate lucency overlying the lower thoracic spine and projecting caudad to the heart.
Left-sided anterior-superior oval sign	Multiple oval, round, or pear-shaped free air projected over left upper quadrant abdomen.
Gall bladder sign	Presence of air in the gallbladder fossa outlining the gallbladder.
Subphrenic radiolucency	Radiolucency beneath the diaphragm, either right or left side on the supine radiograph
Continuous diaphragm sign	Diaphragm appears to be continuous due to accumulation of a large amount of air below the diaphragm and there is visibility of inferior heart border due to air outlining the inferior border of the heart
Flying bird sign/eagle sign ²³	Seen in massive pneumoperitoneum when air collects under both domes of diaphragm but unlike continuous diaphragm sign it is not continuous in the centre.
Decubitus abdomen sign	Free air seen between abdominal wall and liver seen on left lateral decubitus radiograph
Pneumosrotum	presence of air in the scrotum
Presence of air in the lesser sac is seen medial to the lesser curvature of stomach	
Air may be seen along the transverse mesocolon and root of the mesentery.	
Focal radiolucency is the abnormal gas pattern presenting on the supine films without fitting any sign.	

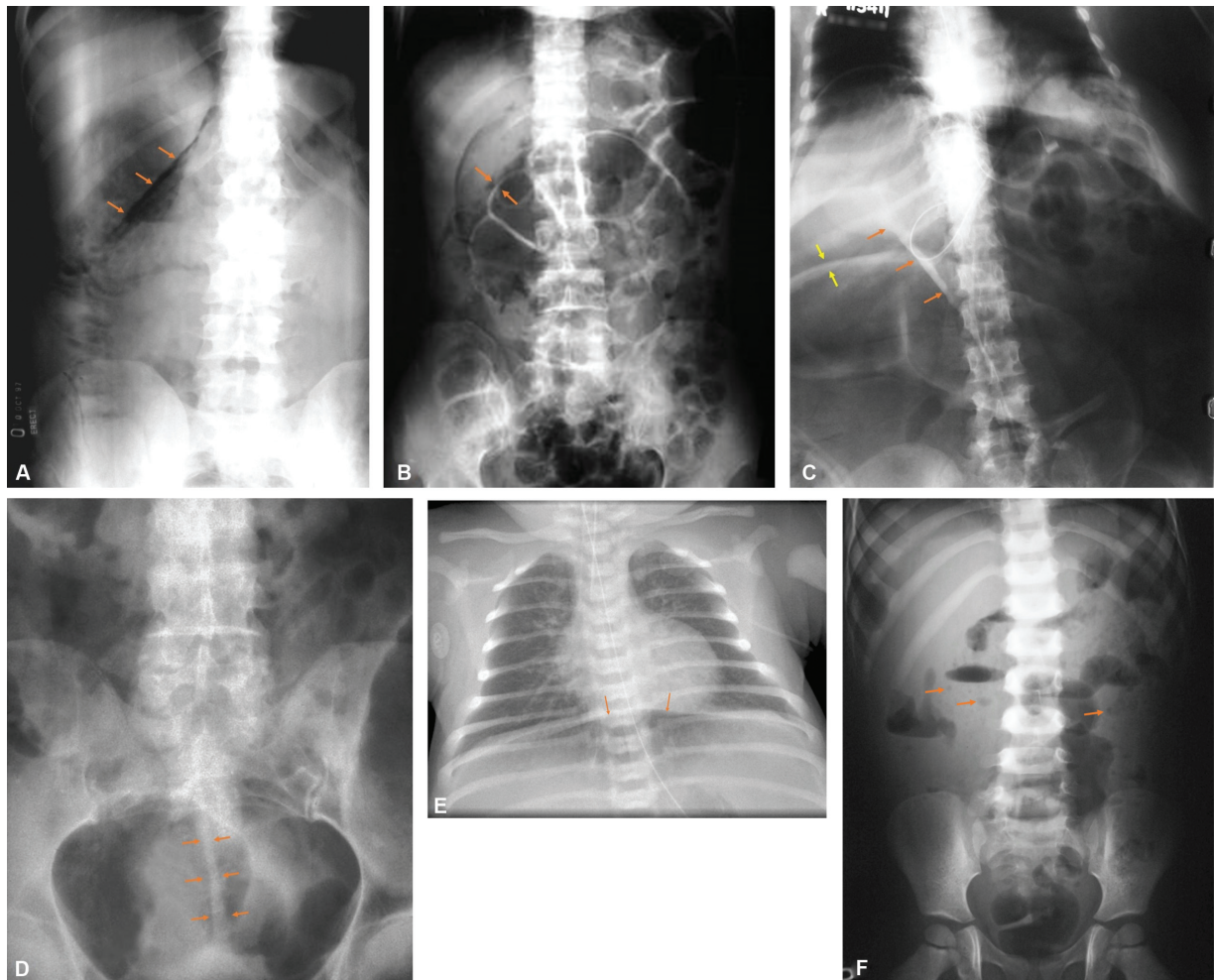


Fig. 13 Signs of pneumoperitoneum on plain radiographs. (A) increased radiolucency over the liver with air outlining the inferior hepatic edge (solid arrows) representing pneumoperitoneum. (B) Rigler’s sign is seen as air is out lining both sides of bowel loops (solid arrows). (C) A large pneumoperitoneum with air outlining the falciform ligament, which is seen as a linear opacity (orange arrows). Air is also seen outlining both sides of the bowel, forming the Rigler’s sign (yellow arrows). (D) Pneumoperitoneum with air outlining the urachus (solid arrows). (E) Pneumoperitoneum in a child seen as air outlining the inferior aspect of the diaphragm (orange arrows). (F) Plain radiograph showing no direct signs of pneumoperitoneum. However multiple small radiolucencies (orange arrows) are seen in the abdomen representing pockets of air.

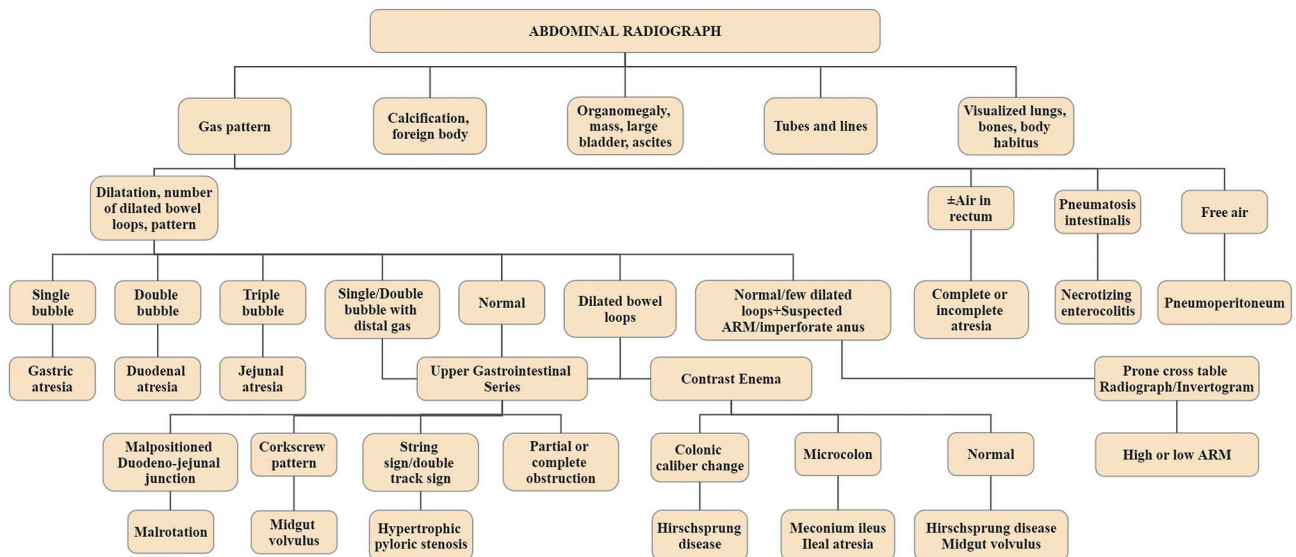


Fig. 14 Flowchart describing the approach to interpretation of a plain abdominal radiograph and contrast studies in a pediatric patient (ARM-anorectal malformation).

Conflict of Interest

None declared.

References

- 1 Frush DP, Slovis TL. Radiation bioeffects, risks, and radiation protection in medical imaging in children. In: Coley BD, ed. *Caffey's pediatric diagnostic imaging*. 12th ed. Philadelphia, PA: Elsevier/Saunders; 2013:3–11
- 2 Whitley AS, Clark KC. Clark's positioning in radiography. 12th ed. London, New York, NY: Hodder Arnold; 2005:xiv, 398–401
- 3 IRefer Guidelines: Making the Best Use of Clinical Radiology. 8th ed. The Royal College of Radiologists (RCR); 2017 Accessed October 21, 2022 at: www.irefer.org.uk
- 4 Hiorns MP. Gastrointestinal tract imaging in children: current techniques. *Pediatr Radiol* 2011;41(01):42–54
- 5 del-Pozo G, Albillos JC, Tejedor D, et al. Intussusception in children: current concepts in diagnosis and enema reduction. *Radiographics* 1999;19(02):299–319
- 6 Applegate KE. Intussusception. In: Coley BD, ed. *Caffey's pediatric diagnostic imaging*. 12th ed. Philadelphia, PA: Elsevier/Saunders; 2013:1135–1143
- 7 Hernanz-Schulman M. Hypertrophic pyloric stenosis. In: Coley BD, ed. *Caffey's pediatric diagnostic imaging*. 12th ed. Philadelphia, PA: Elsevier/Saunders; 2013:1039–1047
- 8 Blickman JG, Parker BR. Gastrointestinal Tract. In: Blickman JG, Parker BR, Barnes PD, eds. *Pediatric radiology: the requisites*. 3rd ed. Philadelphia, PA: Mosby/Elsevier; 2009; ix, 63–102
- 9 Currarino G. The value of double-contrast examination of the stomach with pressure "spots" in the diagnosis of infantile hypertrophic pyloric stenosis. *Radiology* 1964;83:873–878
- 10 Hernanz-Schulman M. Congenital and neonatal disorders. In: Coley BD, ed. *Caffey's pediatric diagnostic imaging*. 12th ed. Philadelphia, PA: Elsevier/Saunders; 2013:1057–1080
- 11 Vinocur DN, Lee EY, Eisenberg RL. Neonatal intestinal obstruction. *Am J Roentgenol* 2012;198(01):W1–10
- 12 Lin AN. Pyloric atresia and epidermolysis bullosa. *Pediatr Dermatol* 1997;14(05):406–408
- 13 Javors BR, Bittane RM. Applied embryology of the gastrointestinal tract. In: Gore RM, Levine MS, eds. *Textbook of gastrointestinal radiology*. 4th ed. Philadelphia, PA: Elsevier/Saunders; 2015: 2079–2094
- 14 Feinstein KA, Fernbach SK. Neonatal gastrointestinal radiology. In: Gore RM, Levine MS, eds. *Textbook of gastrointestinal radiology*. 4th ed. Philadelphia, PA: Elsevier/Saunders; 2015: 2095–2124
- 15 Feinstein KA, Fernbach SK. Diseases of the pediatric colon. In: Gore RM, Levine MS, eds. *Textbook of gastrointestinal radiology*. 4th ed. Philadelphia, PA: Elsevier/Saunders; 2015: 2164–2179
- 16 Swischurk LE. Alimentary tract. In: Swischurk LE, ed. *Imaging of the Newborn, Infant and Young Child*. 5th ed. Lippincott Williams and Wilkins; 2004:341–482
- 17 Dunn EA, Olsen ØE, Huisman TAGM. The pediatric gastrointestinal tract: what every radiologist needs to know. In: Hodler Jr, Kubik-Huch RA, Schulthess GKV, eds. *Diseases of the Abdomen and Pelvis 2018–2021: diagnostic imaging - IDKD book*. Cham, Switzerland: Springer; 2018 (viii):157–66
- 18 Pruthi S, Singh SP, Hilmes MA. The abdominal wall and peritoneal cavity. In: Coley BD, ed. *Caffey's pediatric diagnostic imaging*. 12th ed. Philadelphia, PA: Elsevier/Saunders; 2013: 1157–1180
- 19 Messmer JM, Levine MS. Gas and soft tissue abnormalities. In: Gore RM, Levine MS, eds. *Textbook of gastrointestinal radiology*. 4th ed. Philadelphia, PA: Elsevier/Saunders; 2015:178–196
- 20 Raturi S, Chandran S, James TE, Rajadurai VS. Radiological signs of pneumoperitoneum in an extremely low birthweight infant. *BMJ Case Rep* 2014;2014:bcr2014205510
- 21 Chiu YH, Chen JD, Tiu CM, et al. Reappraisal of radiographic signs of pneumoperitoneum at emergency department. *Am J Emerg Med* 2009;27(03):320–327
- 22 Xiang H, Han J, Ridley WE, Ridley LJ. Leaping dolphin sign: pneumoperitoneum. *J Med Imaging Radiat Oncol* 2018;62 (Suppl 1):87–87
- 23 Rajkumar T. Flying bird sign or eagle sign in pneumoperitoneum. *WJPMR* 2017;3(04):78–82