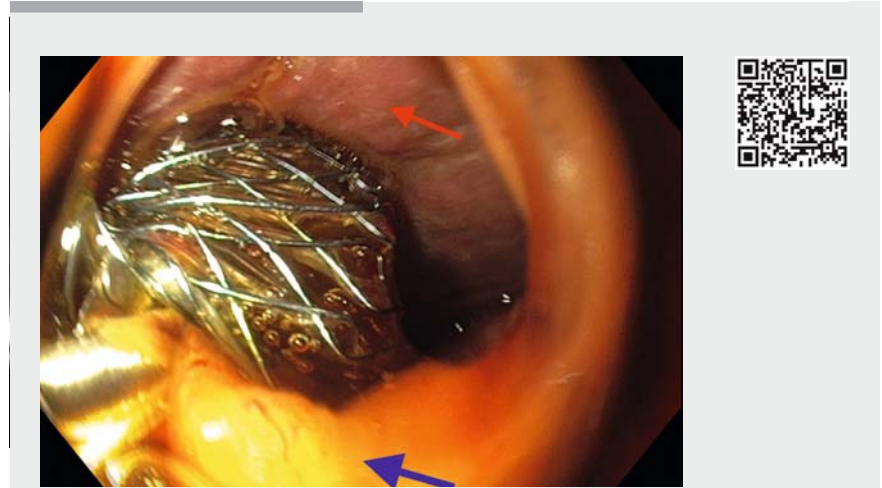


Salvage of a dislodged hepaticogastrostomy stent in the peritoneum with NOTES

Endoscopic ultrasound-guided hepaticogastrostomy (EUS-HGS) is a technique to create a fistula between the stomach and the left intrahepatic bile duct. The technical success rate is high, reported to be 87%–89.5% in expert hands, but the drawback is the procedure-related adverse event rate of 27% [1, 2], with possible events including pneumoperitoneum, choleperitoneum, infection, stent dysfunction, and death [3]. In natural orifice transluminal endoscopic surgery (NOTES), an intentional perforation in the bowel is created to access the peritoneal cavity with an endoscope. We describe here a novel NOTES technique to salvage a misplaced HGS stent from the peritoneal cavity.

The patient was a 68-year-old man with lung cancer that had metastasized to the liver hilum causing compression and stenosis of the duodenum and common bile duct (CBD). He was initially treated with a duodenal stent and a stent in the CBD; however, because of tumor expansion, he redeveloped cholestasis with intrahepatic bile duct dilation, and tumor overgrowth causing stenosis of the duo-

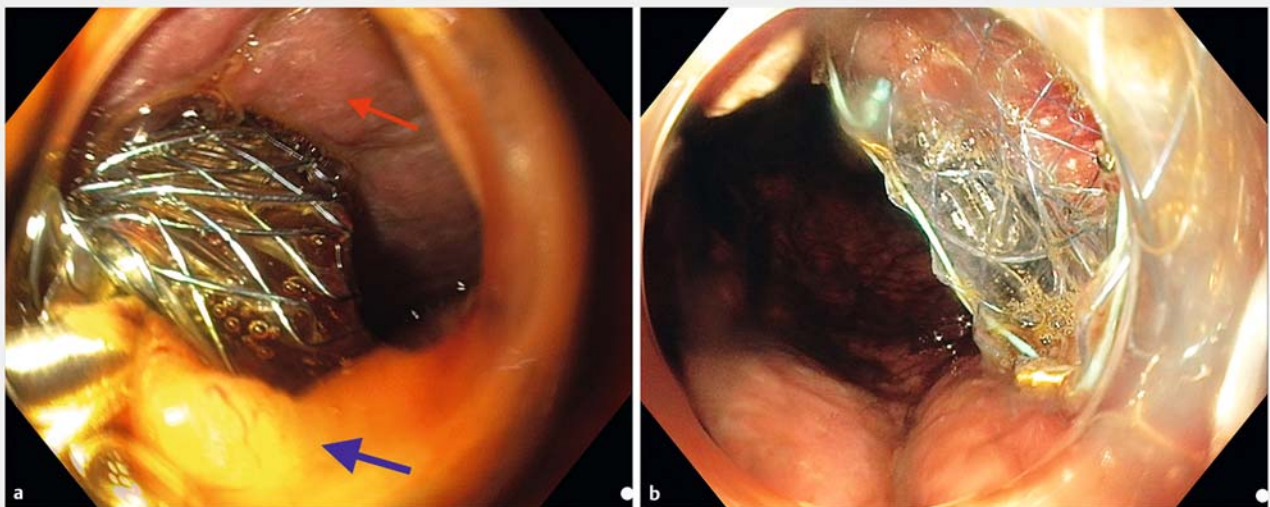


▶ Video 1 A natural orifice transluminal endoscopic surgery (NOTES) procedure is performed to rescue a misplaced hepaticogastrostomy stent. The stent is used to fill the NOTES entry site.

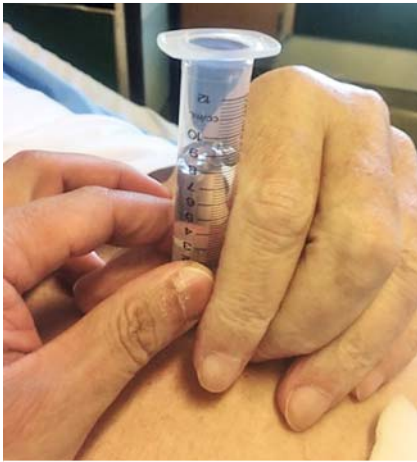denum meant that endoscopic retrograde cholangiopancreatography (ERCP) was not possible. After the patient had given informed consent, we therefore attempted an EUS-HGS.

The procedure was performed with the patient under conscious sedation. Under

EUS guidance, the left intrahepatic bile duct was punctured with a 19G needle, and a cholangiogram was obtained following contrast injection. A guidewire was passed through the needle and the needle was exchanged with a 6-Fr cystogastrotome to create a tract in the liver



▶ Fig. 1 Endoscopic images showing: **a** the hepaticogastrostomy stent coming out from the liver (red arrow), with the gastric flange embedded in omental fat (blue arrow); **b** the stent positioned via the natural orifice transluminal endoscopic surgery (NOTES) opening.



► **Fig. 2** Photograph showing decompression of the air with a water lock.

parenchyma. A 10-cm partially covered dedicated HGS stent (Biliary Flange Lasso; M.I. Tech, Seoul, South Korea) was placed into the liver hilum; however, the stent was released erroneously into the peritoneum (► **Fig. 1 a**), causing bile leakage.

An intentional perforation in the stomach wall was then created near the original site of the HGS to pass a gastroscope with a 12.4-mm cap through. The stent was retrieved and passed through the

new orifice into the stomach (► **Fig. 1 b**; ► **Video 1**). The pneumoperitoneum was treated with acute and delayed decompression (► **Fig. 2**). The patient was placed on antibiotics and octreotide. The stent position was checked by a computed tomography (CT) scan on the second day (► **Fig. 3**), before the patient commenced liquid feeding. Clinically the patient recovered rapidly and was discharged after 1 week.

Endoscopy_UCTN_Code_CPL_1AL_2AD

Competing interests

None

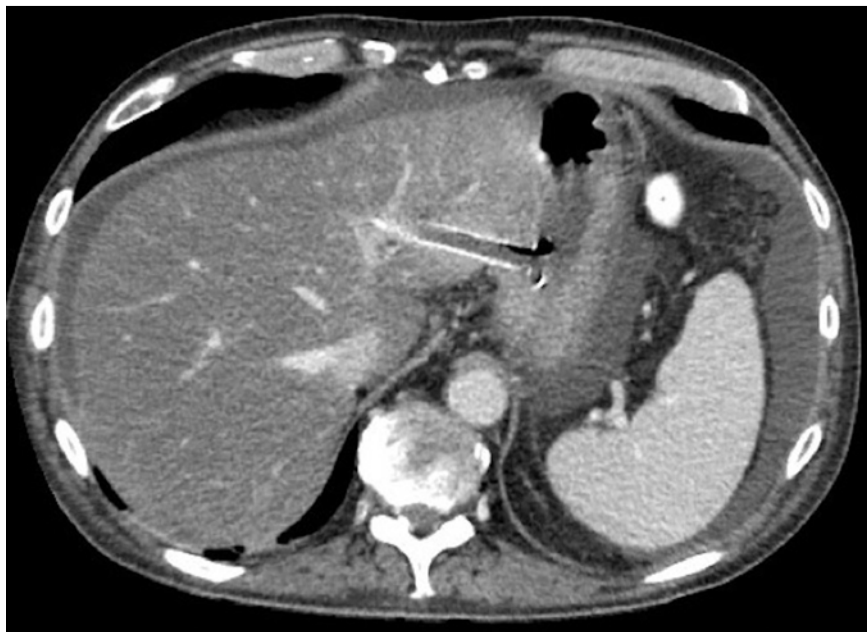The Authors

Khanh Do-Cong Pham^{1,2}, **Dag Hoem**³, **Arild Horn**³, **Georg G. Dimcevski**^{1,2}

1 Department of Medicine, Haukeland University Hospital, Bergen, Norway

2 Department of Clinical Medicine, K1, University of Bergen, Norway

3 Department of gastro and acute surgery, Haukeland University Hospital, Bergen, Norway



► **Fig. 3** Computed tomography (CT) scan performed to confirm correct positioning of the stent.

Corresponding author

Khanh Do-Cong Pham, MD

Section of Gastroenterology, Department of Medicine, Haukeland University Hospital, Jonas Lies vei 65, 5051 Bergen, Norway
pham@helse-bergen.no

References

- [1] Khashab MA, van der Merwe S, Kunda R et al. Prospective international multicenter study on endoscopic ultrasound-guided biliary drainage for patients with malignant distal biliary obstruction after failed endoscopic retrograde cholangiopancreatography. *Endosc Int Open* 2016; 4: 1–2
- [2] Iwashita T, Doi S, Yasuda I. Endoscopic ultrasound-guided biliary drainage: A review. *Clin J Gastroenterol* 2014; 7: 94–102
- [3] Ogura T, Higuchi K. Technical tips for endoscopic ultrasound-guided hepaticogastrostomy. *World J Gastroenterol* 2016; 22: 3945–3951

Bibliography

DOI <https://doi.org/10.1055/s-0043-109426>

Published online: 29.6.2017

Endoscopy 2017; 49: 919–920

© Georg Thieme Verlag KG

Stuttgart · New York

ISSN 0013-726X

ENDOSCOPY E-VIDEOS

<https://eref.thieme.de/e-videos>



Endoscopy E-Videos is a free access online section, reporting on interesting cases and new techniques in gastroenterological endoscopy. All papers include a high quality video and all contributions are freely accessible online.

This section has its own submission website at

<https://mc.manuscriptcentral.com/e-videos>