



Endoscopically-Assisted Percutaneous Trigeminal Rhizotomy for Trigeminal Neuralgia: A Cadaveric Feasibility Study

Mansour Mathkour^{1,2,3} Cassidy D. Werner⁴ Robert F. Dallapiazza¹ Marios Loukas⁵ Joe Iwanaga^{1,6}
Aaron S. Dumont¹ R Shane Tubbs^{1,2,5,6,7}

¹Department of Neurosurgery, Tulane Center for Clinical Neurosciences, Tulane University School of Medicine, New Orleans, Louisiana, United States

²Department of Neurosurgery, Ochsner Neuroscience Institute, Ochsner Health System, New Orleans, Louisiana, United States

³Division of Neurosurgery, Department of Surgery, Jazan University School of Medicine, Jazan, Kingdom of Saudi Arabia

⁴Tulane University School of Medicine, New Orleans, Louisiana, United States

⁵Department of Anatomical Sciences, St. George's University, St. George's, Grenada

Address for correspondence Joe Iwanaga, DDS, PhD, Department of Neurosurgery, Tulane Center for Clinical Neurosciences, 131 S. Robertson St., Suite 1300, New Orleans, LA 70112, United States (e-mail: iwanagajoeca@gmail.com).

⁶Department of Neurology, Tulane Center for Clinical Neurosciences, Tulane University School of Medicine, New Orleans, Louisiana, United States

⁷Department of Structural and Cellular Biology, Tulane University School of Medicine, New Orleans, Louisiana, United States

AJNS 2023;18:40–44.

Abstract

Objective Trigeminal neuralgia (TN) is a debilitating syndrome characterized by paroxysmal facial pain in one or more divisions of the trigeminal nerve. The etiology and treatment paradigms are still controversial. The endoscopically-assisted procedure has not yet been described in percutaneous procedures for TN. The aim of this study was to assess the utility and feasibility of endoscopic-assisted percutaneous approaches for trigeminal rhizotomy in TN.

Methods This study comprised eight cadaveric sides heads that underwent an endoscopically assisted percutaneous approach using Hakanson's anterior puncture method for targeting the foramen ovale.

Results V3 exiting the foramen ovale was easily visualized with the endoscope on all sides. While approaching the foramen ovale, distal branches of V3 such as the lingual and inferior alveolar nerves were first identified as they traveled between the medial and lateral pterygoid muscles. These branches were then traced proximally to the V3 trunk deep to the lateral pterygoid. Large arteries and veins were easily visualized and avoided in the trajectory to the foramen ovale. No gross injury to any neurovascular structure along the course of the needle insertion was identified.

Conclusion We found that endoscopic-assisted percutaneous approach to the foramen ovale is feasible and allows for accurate canalization and anatomical identification of the precise location for rhizotomy under direct visualization. Such a procedure, after it is confirmed in patients, could offer a new technique for reducing unsuccessful canalization and could improve outcomes.

Keywords

- ▶ trigeminal neuralgia
- ▶ anatomy
- ▶ cadaver
- ▶ endoscopy

article published online
March 27, 2023

DOI <https://doi.org/10.1055/s-0043-1761230>.
ISSN 2248-9614.

© 2023. Asian Congress of Neurological Surgeons. All rights reserved.

This is an open access article published by Thieme under the terms of the Creative Commons Attribution-NonDerivative-NonCommercial-License, permitting copying and reproduction so long as the original work is given appropriate credit. Contents may not be used for commercial purposes, or adapted, remixed, transformed or built upon. (<https://creativecommons.org/licenses/by-nc-nd/4.0/>)

Thieme Medical and Scientific Publishers Pvt. Ltd., A-12, 2nd Floor, Sector 2, Noida-201301 UP, India

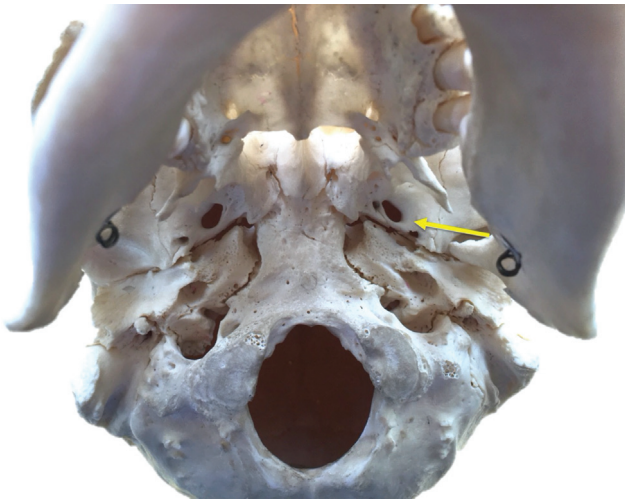


Fig. 1 Skull base of a dry skull noting the trajectory toward the left foramen ovale used in transfacial approaches.

Introduction

Trigeminal neuralgia (TN) is characterized by severe, recurrent facial pain along one or more of the trigeminal nerve divisions.¹ For patients with severe, medication refractory symptoms, there are several destructive and nondestructive surgical techniques that are available including microvascular decompression, stereotactic radiosurgery, and percutaneous rhizotomy.^{1,2} Fluoroscopic percutaneous radiofrequency rhizotomy (RFR), balloon compression (PBC), and glycerol rhizotomy (PGR) are simple procedures with

excellent success rates up to 90%^{3,4}; however, these procedures can pose technical challenges with unsuccessful cannulation of the foramen reported in 2.7 to 8.0%.^{5,6} These techniques are usually performed with fluoroscopy to visualize the bony structures such as the foramen ovale (►Fig. 1); however, the soft tissue anatomical structures are not visible, and therefore, the nerves and vessels are always at risk of injury, e.g., the internal carotid artery and internal jugular vein course posterior to the foramen ovale (►Figs. 2 and 3). Intraoperative bleeding may be caused by puncture of the internal carotid artery, internal jugular vein, maxillary artery, middle meningeal artery, or pterygoid venous plexus.⁷ A previous cadaveric study clearly showed puncture of the second part of the maxillary artery following percutaneous procedures.⁸ The branches of the mandibular division of the trigeminal nerve are also near the needle trajectory (►Fig. 3). Thus, it is impossible to avoid injury of these soft tissue anatomical structures with blind placement of needles destined for the foramen ovale.

Over the past decade, minimally invasive endoscopic procedures and approaches have been used to treat various neurosurgical diseases⁹; however, percutaneous procedures in TN have not yet been supplemented by the endoscopic, video-assisted techniques that could provide better outcomes with less complications. As this approach might encounter and potentially injure important anatomical structures, visualization of structures during advancement of the needle toward the foramen ovale would be beneficial. Therefore, this study aimed to assess the feasibility of using endoscopy as an adjunct to percutaneous approaches for TN.

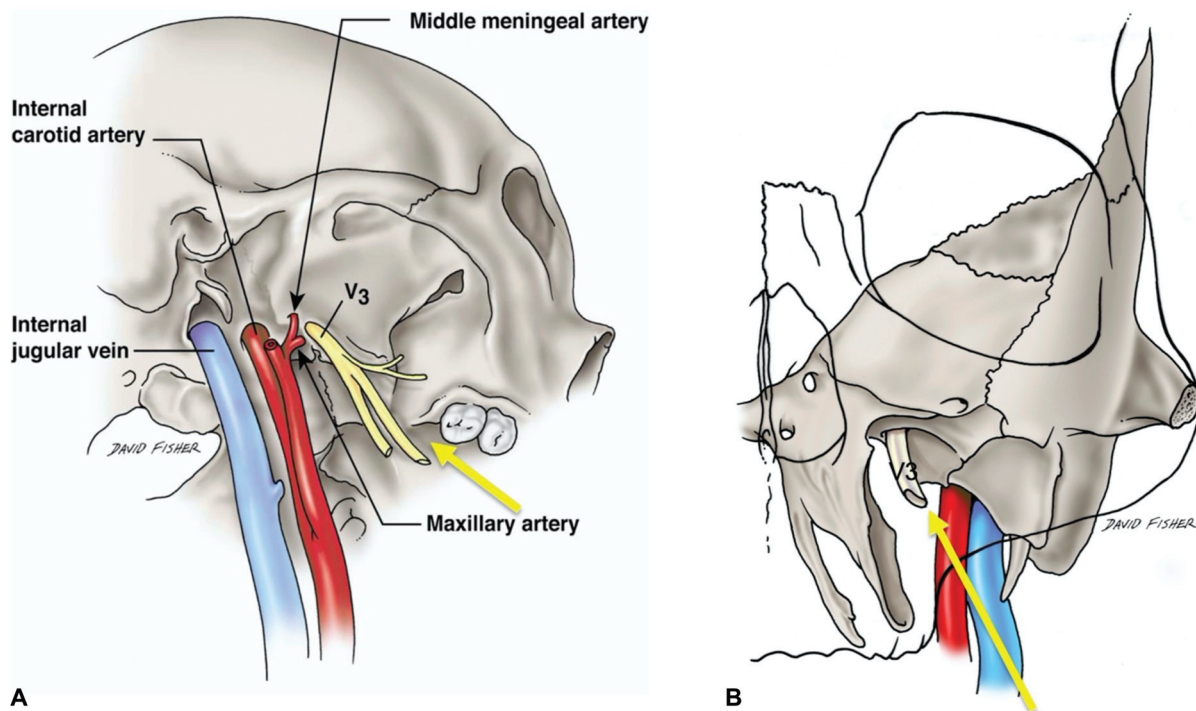


Fig. 2 (A) Inferolateral view of the right skull base noting the trajectory used for transfacial approaches to the right foramen ovale. Important regional anatomy includes the internal carotid artery and internal jugular vein found posterior to the foramen ovale and V3. (B) Anterior view of the trajectory used for transfacial approaches to the left foramen ovale. Note V3 exiting the foramen and the more posteriorly located internal carotid artery and internal jugular vein.

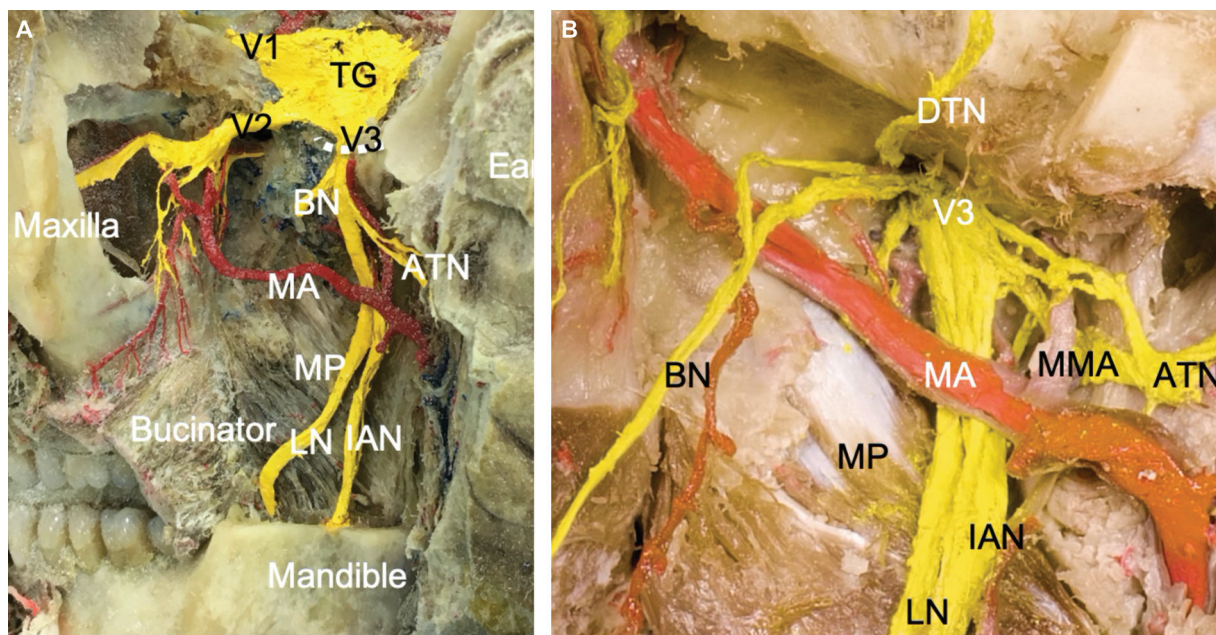


Fig. 3 (A) Cadaveric dissection of the left infratemporal fossa noting V3 exiting the foramen ovale (dotted curved line) that has been partially opened. A large pterional craniotomy with removal of parts of the maxilla and mandible has been performed to show the important regional anatomy including the trigeminal ganglion (TG), V1-V3 branches, buccal nerve (cut) (BN), lingual nerve (LN), inferior alveolar nerve (IAN), auriculotemporal nerve (ATN), maxillary artery (MA), medial pterygoid muscle (MP). (B) Cadaveric dissection of the left infratemporal fossa zoomed in compared with Fig. 4 and noting V3 exiting the foramen ovale. Also, note the buccal nerve (BN), lingual nerve (LN), inferior alveolar nerve (IAN), auriculotemporal nerve (ATN), deep temporal nerve (DTN), maxillary artery (MA), middle meningeal artery (MMA), and medial pterygoid muscle (MP).

Materials and Methods

We conducted a cadaveric study on latex-injected specimens to assess the utility and feasibility of the endoscopic-assisted foramen ovale approach. This study comprised eight cadaveric sides heads that underwent an endoscopically assisted percutaneous approach using Hakanson's anterior puncture method for targeting the foramen ovale. The specimens consisted of two males and two females with a mean age at death of 71 years (range 67–80 years) at the time of death.

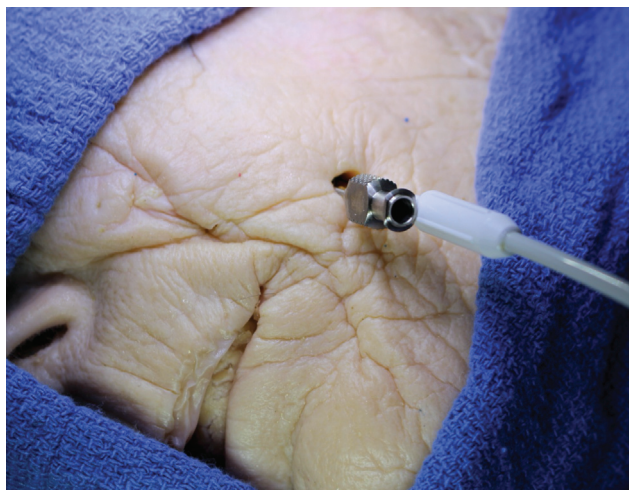

Fig. 4 Tuohy needle placement aimed at the left foramen ovale with endoscope inserted alongside the needle as it is advanced superiorly.

Surgical Approach

On each side, the conventional Hakanson's anterior puncture method¹⁰ for the entry point of the needle (14-gauge Tuohy needle) was used. This method introduces the needle approximately 3 cm lateral to the angle of the mouth where the line from the medial point of the pupil and the point 2.5 cm anterior to tragus intersected (→Fig. 4). We then introduced the endoscope (NeuroPEN Neuroendoscope, Medtronic, USA) parallel to the needle and moved the needle and endoscope as a unit for guidance superiorly toward the foramen ovale at the skull base. Post procedure, the course of the endoscope and needle was evaluated for gross injury to regional nerves and blood vessels. Finally, the endoscope was used to approach the foramen ovale in two dry, adult skulls to visualize the anatomy of the foramen and surrounding relationships as would be seen on fluoroscopy during use of such a procedure in patients, that is, without related soft tissues.

Results

None of the cadavers exhibited evidence of gross disease, previous surgical procedures, or traumatic lesions to the face or skull base. V3 exiting the foramen ovale (→Fig. 5) was easily visualized with the endoscope on all sides. While approaching the foramen ovale, the large distal branches of V3 including the lingual and inferior alveolar nerves were first identified as they traveled between the medial and lateral pterygoid muscles. These branches were then traced proximally up to the main V3 trunk deep to the lateral pterygoid and the needle placed into the foramen ovale.

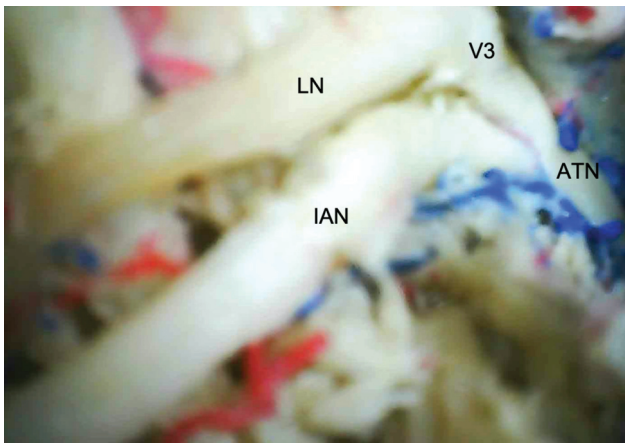


Fig. 5 Anteroinferior view of the left lingual nerve (LN) and inferior alveolar nerve (IAN) as V3 is approached with the endoscope. Also note the auriculotemporal nerve (ATN) extending posteriorly from V3.

Large arteries (maxillary artery) and veins (pterygoid venous plexus) were easily visualized and avoided during the approach to the foramen ovale. No gross injury to any neurovascular structure along the course of the needle insertion was identified. The anatomy of an inferior view of the foramen ovale as would be seen on fluoroscopy was easily appreciated with the endoscope used on dry skulls.

Discussion

This cadaveric study demonstrated successful cannulation of the foramen ovale on all sides using an endoscopically assisted technique. With the endoscope, we first encountered the distal branches of V3 among the pterygoid muscles, and then successfully following these superiorly to the main trunk of V3 at the foramen ovale. There was no gross damage to surrounding neurovascular structures following detailed post-endoscopic dissection. Based on these results, this method could feasibly be used in percutaneous procedures to access the foramen ovale for patients with TN.

Trigeminal neuralgia (tic douloureux) is clinically characterized by paroxysmal, severe, and recurrent facial pain along the trigeminal nerve distribution, affecting one or more branches and causing functional limitation.¹ It is estimated that one in 15,000 to 20,000 individuals suffer from TN; however, the incidence could be higher owing to frequent misdiagnosis.¹¹

Although multiple mechanisms have been proposed, neurovascular compression of the dorsal root entry zone at the ventral aspect of the pons is the most accepted hypothesis.¹ The exact pathophysiology of TN remains controversial. However, it is thought that chronic nerve compression results in demyelination at the transition zone between peripheral and central myelination zones causing progressive axonal degeneration of myelinated and unmyelinated fibers, with ultrastructural and biochemical changes at the nerve root and in the trigeminal ganglion.¹²

The diagnosis of TN is primarily clinical; however, most physicians perform advanced imaging including a brain magnetic resonance imaging (MRI) using diffusion tensor

imaging (DTI) and three-dimensional fast imaging employing steady-state (3D FIESTA) sequences to rule out mass lesions, central demyelination, other secondary pathological changes affecting the nerve root, and properly identify and characterize neurovascular compression (NVC) if present.¹³⁻¹⁶

There are several destructive and nondestructive surgical techniques for patients with severe symptom that are poorly controlled with medications.^{1,2} Microvascular decompression (MVD) is a surgical treatment of choice for TN resistant to medical management, especially in otherwise healthy young patients with evidence of NVC on MR or CT imaging, which provides the best results for long-duration pain freedom.^{1,17} In contrast, percutaneous procedures and stereotactic radiosurgery are among the surgical treatments of choice for pain recurrence, poor surgical candidates, multiple sclerosis cases, and/or in the absence of NVC.^{1,18,19}

Fluoroscopic RFR, PBC, and PGR are simple procedures with excellent success rates up to 90% complete or satisfactory pain relief^{3,4}; however, this procedure can pose technical challenges with unsuccessful cannulation, which is reported in 2.7 to 8.0% of cases.^{5,6}

Skull base fluoroscopic guidance has its own associated learning curve, and even in experienced hands, cannulation using Hartel's approach and Hakanson's anterior puncture has a technical failure rate of 1 to 5%.²⁰ Moreover, a significant positive correlation has been reported between good cannulation and success rate with cerebrospinal fluid (CSF) outflow.⁴ Given its technical challenge and lack of CSF return in some cases, making the conventional fluoroscopic confirmation of adequate cannulation less certain, some studies have proposed salvage procedures using CT- and MRI-guided navigation and frameless navigation to overcome these challenges for accurate cannulation of the foramen ovale and Meckel's cave with improving outcomes.²¹⁻²³

Minimally invasive procedures and approaches have been used to treat various neurosurgical diseases.⁹ Over the past decade, endoscopic approaches have gained popularity and have been used for spinal, transcranial, and skull base approaches.^{9,24-26} The endoscopic technique in TN has been used alone for MVD or as an adjuvant to the microscope, which allows better visualization for effective and completed decompression with improved pain relief and fewer surgical complications and less brain retraction.^{1,27-30} However, percutaneous procedures in TN have not yet been supplemented by video-assisted procedures.

To our knowledge, this is the only cadaveric study to have quantified and assessed the utility and feasibility of endoscopy-assisted percutaneous procedures in TN.

In this study, we have detailed the application of endoscopy-assisted percutaneous trigeminal rhizotomy as a salvage approach. We found that this technique allows for intraoperative confirmation of foramen ovale cannulation. Additionally, such a method might better appreciate anatomical variations, e.g., bony bars in the region of the foramen ovale and aid in navigating around such obstacles.

Conclusion

This report details the application of endoscopic video-assisted percutaneous trigeminal rhizotomy. We found this salvage approach to be feasible. It allows for intraoperative confirmation of foramen ovale cannulation, anatomical identification of surrounding structures, and positioning of the needle tip in Meckel's cave under direct visualization. Such a procedure, after it is confirmed in patients, could offer a new technique for reducing unsuccessful canalization and could improve outcomes.

Authors' Contributions

The manuscript has been read and approved by all the authors. The requirements for authorship in this document have been met. Each author believes that the manuscript represents honest work.

Conflict of Interest

None declared.

Acknowledgments

The authors sincerely thank those who donated their bodies to science so that anatomical research could be performed. Results from such research can potentially increase mankind's overall knowledge that can then improve patient care. Therefore, these donors and their families deserve our highest gratitude.³¹

References

- 1 Yadav YR, Nishtha Y, Sonjjay P, Vijay P, Shailendra R, Yatin K. Trigeminal Neuralgia. *Asian J Neurosurg* 2017;12(04):585–597
- 2 Zakrzewska JM, McMillan R. Trigeminal neuralgia: the diagnosis and management of this excruciating and poorly understood facial pain. *Postgrad Med J* 2011;87(1028):410–416
- 3 Trojnik T, Šmigoc T. Percutaneous trigeminal ganglion balloon compression rhizotomy: experience in 27 patients. *Scientific-WorldJournal* 2012;2012:328936
- 4 Chen L, Xu M, Zou Y. Treatment of trigeminal neuralgia with percutaneous glycerol injection into Meckel's cavity: experience in 4012 patients. *Cell Biochem Biophys* 2010;58(02):85–89
- 5 Georgiopoulou M, Ellul J, Chroni E, Constantoyannis C. Minimizing technical failure of percutaneous balloon compression for trigeminal neuralgia using neuronavigation. *ISRN Neurol* 2014; 2014:630418
- 6 Harries AM, Mitchell RD. Percutaneous glycerol rhizotomy for trigeminal neuralgia: safety and efficacy of repeat procedures. *Br J Neurosurg* 2011;25(02):268–272
- 7 Abdennebi B, Guenane L. Technical considerations and outcome assessment in retrogasserian balloon compression for treatment of trigeminal neuralgia. Series of 901 patients. *Surg Neurol Int* 2014;5:118
- 8 Iwanaga J, Badaloni F, Laws T, Oskouian RJ, Tubbs RS. Anatomic study of extracranial needle trajectory using Hartel technique for percutaneous treatment of trigeminal neuralgia. *World Neurosurg* 2018;110:e245–e248. Doi: 10.1016/j.wneu.2017.10.140
- 9 Fonoff ET, Lopez WO, de Oliveira YS, Lara NA, Teixeira MJ. Endoscopic approaches to the spinal cord. *Acta Neurochir Suppl (Wien)* 2011;108:75–84
- 10 Håkanson S. Trigeminal neuralgia treated by the injection of glycerol into the trigeminal cistern. *Neurosurgery* 1981;9(06): 638–646
- 11 Tallawy HN, Farghaly WM, Rageh TA, et al. Door-to-door survey of major neurological disorders (project) in Al Quseir City, Red Sea Governorate, Egypt. *Neuropsychiatr Dis Treat* 2013;9:767–771
- 12 Marinković S, Gibo H, Todorović V, et al. Ultrastructure and immunohistochemistry of the trigeminal peripheral myelinated axons in patients with neuralgia. *Clin Neurol Neurosurg* 2009;111 (10):795–800
- 13 Liu Y, Li J, Butzkueven H, et al. Microstructural abnormalities in the trigeminal nerves of patients with trigeminal neuralgia revealed by multiple diffusion metrics. *Eur J Radiol* 2013;82 (05):783–786
- 14 Park SH, Hwang SK, Lee SH, Park J, Hwang JH, Hamm IS. Nerve atrophy and a small cerebellopontine angle cistern in patients with trigeminal neuralgia. *J Neurosurg* 2009;110(04):633–637
- 15 Harsha KJ, Kesavadas C, Chinchure S, Thomas B, Jagtap S. Imaging of vascular causes of trigeminal neuralgia. *J Neuroradiol* 2012;39 (05):281–289
- 16 Zhou Q, Liu Z, Li C, Qu C, Ni S, Zeng Q. Preoperative evaluation of neurovascular relationship by using contrast-enhanced and unenhanced 3D time-of-flight MR angiography in patients with trigeminal neuralgia. *Acta Radiol* 2011;52(08):894–898
- 17 Cruccu G, Gronseth G, Alksne J, et al; American Academy of Neurology Society. ; European Federation of Neurological Society. AAN-EFNS guidelines on trigeminal neuralgia management. *Eur J Neurol* 2008;15(10):1013–1028
- 18 Emril DR, Ho KY. Treatment of trigeminal neuralgia: role of radiofrequency ablation. *J Pain Res* 2010;3:249–254
- 19 Pollock BE. Surgical management of medically refractory trigeminal neuralgia. *Curr Neurol Neurosci Rep* 2012;12(02):125–131
- 20 Qiu X, Liu W, Zhang M, et al. Application of virtual navigation with multimodality image fusion in foramen ovale cannulation. *Pain Med* 2017;18(11):2181–2186
- 21 Lepski G, Mesquita Filho PM, Ramina K, et al. MRI-based radiation-free method for navigated percutaneous radiofrequency trigeminal rhizotomy. *J Neurol Surg A Cent Eur Neurosurg* 2015;76(02):160–167
- 22 Paranathala MP, Ferguson L, Bowers R, Mukerji N. Percutaneous retrogasserian glycerol rhizotomy for trigeminal neuralgia: an alternative technique. *Br J Neurosurg* 2018;32(06):657–660
- 23 Thatikunta M, Eaton J, Nuru M, Nauta HJ. Intraoperative CT for neuronavigation guidance and confirmation of foramen ovale cannulation for glycerol trigeminal rhizotomy: a technical report and case series. *Cureus* 2020;12(05):e8100
- 24 Yadav YR, Parihar V, Namdev H, Agarwal M, Bhatele PR. Endoscopic interlaminar management of lumbar disc disease. *J Neurol Surg A Cent Eur Neurosurg* 2013;74(02):77–81
- 25 Yadav YR, Parihar VS, Todorov M, et al. Role of endoscopic third ventriculostomy in tuberculous meningitis with hydrocephalus. *Asian J Neurosurg* 2016;11(04):325–329
- 26 Zada G, Woodmansee WW, Iuliano S, Laws ER. Perioperative management of patients undergoing transsphenoidal pituitary surgery. *Asian J Neurosurg* 2010;5(01):1–6
- 27 Miyazaki H, Deveze A, Magnan J. Neuro-otologic surgery through minimally invasive retrosigmoid approach: endoscope assisted microvascular decompression, vestibular neurectomy, and tumor removal. *Laryngoscope* 2005;115(09):1612–1617
- 28 El-Garem HF, Badr-El-Dine M, Talaat AM, Magnan J. Endoscopy as a tool in minimally invasive trigeminal neuralgia surgery. *Otol Neurotol* 2002;23(02):132–135
- 29 Abdeen K, Kato Y, Kiya N, Yoshida K, Kanno T. Neuroendoscopy in microvascular decompression for trigeminal neuralgia and hemifacial spasm: technical note. *Neurol Res* 2000;22(05):522–526
- 30 Duntze J, Litré CF, Eap C, et al. Adjunctive use of endoscopy during microvascular decompression in the cerebellopontine angle: 27 case reports [article in French]. *Neurochirurgie* 2011;57(02):68–72
- 31 Iwanaga J, Singh V, Ohtsuka A, et al. Acknowledging the use of human cadaveric tissues in research papers: recommendations from anatomical journal editors. *Clin Anat* 2021;34(01):2–4