



Congenital Cataract and Narrow CSP: A Clue to Prenatal Diagnosis of *RAB3GAP1*-Associated Warburg Micro Syndrome

Meenakshi Lallar¹ Ladbans Kaur¹ Meetan Preet¹ U. P. Singh¹

¹Prime Institute of Prenatal Imaging and Diagnostics, Chandigarh, India

Address for correspondence Meenakshi Lallar, MS, DM, Prime Institute of Prenatal Imaging and Diagnostics, Chandigarh 160023, India (e-mail: meenakshilallar@gmail.com).

J Fetal Med 2023;10:46–48.

Abstract

Keywords

- ▶ cavum septum pellucidum
- ▶ autosomal recessive
- ▶ congenital cataract
- ▶ genetic testing
- ▶ Warburg micro syndrome

Warburg Micro Syndrome (WMS) is an autosomal recessive disorder characterized by intellectual disability, bilateral congenital cataracts, microphthalmia, and brain anomalies. We report an 18-week fetus presenting with bilateral congenital cataract and narrow cavum septum pellucidum. Patient was counselled about the possible etiologies ranging from infectious to chromosomal and single gene etiologies. Invasive testing for genetic analysis was done to determine etiology and establish prognosis. A previously reported homozygous frameshift mutation was identified in *RAB3GAP1* gene leading to diagnosis of WMS. This case highlights the role of detailed fetal sonography and genetic testing to prognosticate pregnancies. Also WMS should be suspected in fetuses presenting with bilateral congenital cataract with or without brain anomalies.

Introduction

Warburg Micro Syndrome (WMS) is a rare autosomal recessive syndrome characterized by eye, central nervous system, and endocrinal abnormalities. The hallmark ophthalmologic findings are bilateral congenital cataracts, usually accompanied by microphthalmia, microcornea, and progressive optic atrophy and cortical visual impairment. The nervous system anomalies consist of severe-to-profound intellectual disability, hypotonia, spasticity leading to contractures and brain anomalies (polymicrogyria and corpus callosum hypoplasia). The diagnosis is usually postnatal when the child presents with developmental delay and eye anomalies.

With advancement in fetal scanning, fetal eye and brain anomalies can be detected early in pregnancy and prenatal diagnosis of WMS has been made in cases of congenital cataracts.¹ Cavum septum pellucidum (CSP) is a very important landmark in fetal brain imaging and is present between 18 and 36 weeks of pregnancy. Abnormalities of CSP include

its absence, enlargement, or echogenicity. Isolated narrow and wide CSP have been followed up to have associated chromosomal anomalies and abnormal neurodevelopmental outcome.^{2,3} We report an 18-week fetus presenting with bilateral congenital cataract and narrow CSP diagnosed as WMS on prenatal genetic testing.

Case Report

A 32-year-old, nonconsanguineous woman presented at 18 weeks of pregnancy for an early anomaly scan. There was no significant family and medical history and her aneuploidy screen and the previous ultrasounds in this pregnancy were normal. At 18 weeks, her fetal ultrasound showed bilateral echogenic lens and a narrow CSP measuring 1.4 mm in width (▶ **Figs. 1, 2**). Antenatal developing corpus callosum was seen normally. The rest of the fetal structure including orbital diameter was normal. Fetal

article published online
May 12, 2023

DOI <https://doi.org/10.1055/s-0043-57022>.
ISSN 2348-1153.

© 2023. Society of Fetal Medicine. All rights reserved.

This is an open access article published by Thieme under the terms of the Creative Commons Attribution-NonDerivative-NonCommercial-License, permitting copying and reproduction so long as the original work is given appropriate credit. Contents may not be used for commercial purposes, or adapted, remixed, transformed or built upon. (<https://creativecommons.org/licenses/by-nc-nd/4.0/>)

Thieme Medical and Scientific Publishers Pvt. Ltd., A-12, 2nd Floor, Sector 2, Noida-201301 UP, India

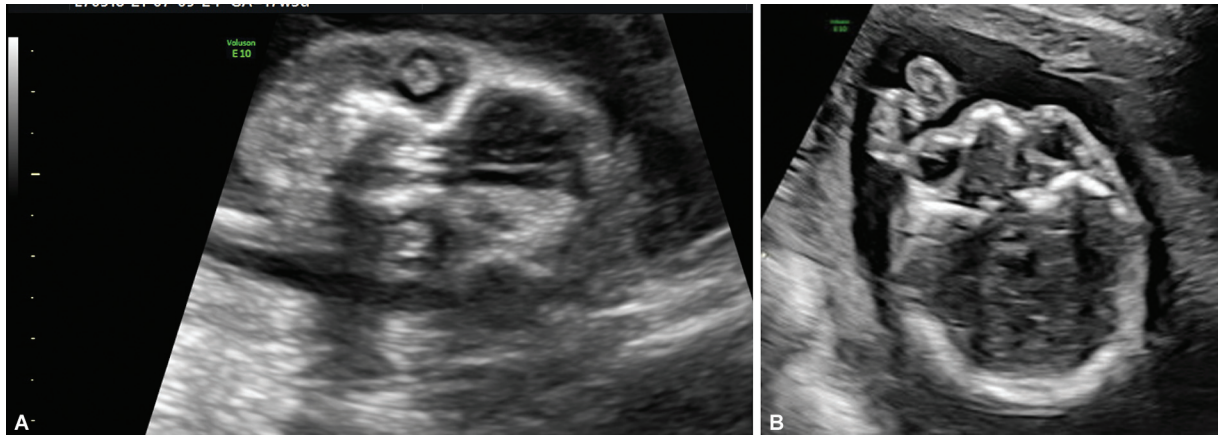


Fig. 1 (A, B) Fetal face coronal and axial section showing bilateral echogenic lens suggestive of cataract.

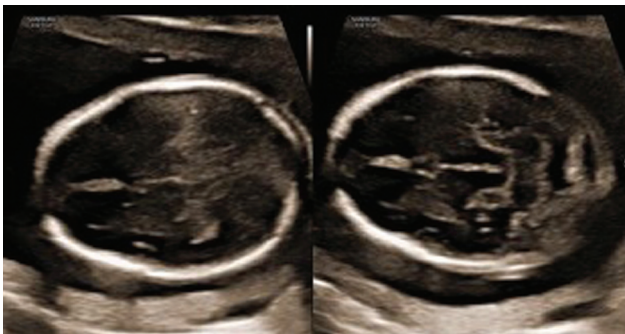


Fig. 2 Fetal brain axial sections showing narrow cavum septum pellucidum measuring 1.4 mm in width.

echocardiography was also normal. Taking into account bilateral congenital cataract and narrow CSP, the woman was referred for pretest genetic counselling. She was counselled about the possible underlying genetic etiologies and the risks to the fetus and the limitations of genetic testing. Congenital cataract is associated with toxoplasmosis, others (syphilis, hepatitis B), rubella, cytomegalovirus, herpes simplex (TORCH) infections, chromosomal, and single gene defects and the prognosis of a narrow CSP varies from being a normal variation to an early indicator of underlying brain anomalies. She was counselled for invasive fetal testing for chromosomal and single gene analysis (to rule out various crystalline mutations, Smith-Lemli-Opitz syndrome, Lowe syndrome, congenital muscular dystrophinopathies, RAB18 deficiencies, etc.) to establish fetal prognosis. She opted for invasive testing and amniocentesis and genetic testing was done. Her maternal TORCH test was negative. The fetal microarray was normal. On next-generation sequencing for single gene analysis, we identified homozygous *RAB3GAP1* mutation, NM_012233(*RAB3GAP1*):c.131delT;p.(Leu44Trpfs*50). This mutation has previously been reported in a patient affected with WMS,⁴ and has not been reported in the 1000 genomes and gnomAD databases. The in-silico prediction of the variant is damaging by MutationTaster2. The reference region is conserved across species. Homozygous *RAB3GAP1* gene mutations are associated with WMS 1 and Martsof syndrome 2. Sanger sequencing in the parents was done and both the

parents were heterozygous carriers of the mutation. Posttest genetic counselling was done, and the couple decided to terminate the pregnancy. They did not opt for fetal autopsy.

Discussion

Congenital cataracts and narrow CSP provided a clue to early prenatal diagnosis of *RAB3GAP1*-associated WMS-1 in this case. Congenital cataracts are present in 1 in 10,000 births and can be either unilateral or bilateral, secondary to fetal TORCH infections, syndromic or nonsyndromic.⁵ The lens differentiates from the surface ectoderm before the 6th week of gestation and during fetal scan it can be visualized as early as 11 to 14 weeks of pregnancy. On ultrasound, it is visualized as anechoic circular structure with thin echogenic rim seen in the orbits. When cataract is present, peripheral as well as central echogenicity is observed in the lens. Following diagnosis of fetal cataract, other eye anomalies like microphthalmia should be ruled out along with fetal brain and systemic anomalies. Clinical history of fever, consanguinity, and familial cataracts should be taken. The aim is to classify cataract being isolated or complex that would help in further testing and management. Prenatal TORCH infection especially rubella accounts for about one-third of cases of congenital cataract. Genetic syndromes are found in approximately 10% of cases. A genetic cause is responsible for 30% of unilateral cataracts and 50% of bilateral cataracts. The transmission mode may be autosomal dominant, recessive, or X-linked. The known syndromic causes of congenital cataract include Walker Warburg syndrome, *RAB3GAP1* deficiencies (WMS and Martsof syndrome 2), Smith-Lemli-Opitz syndrome, Lowe syndrome, galactosemia, homocystinuria, G6PD deficiency, Alport syndrome, and Conradi Hunerman syndrome.

Along with bilateral congenital cataract, the fetus had a narrow CSP with a corpus callosum that was normal for the present period of gestation. A normal CSP is rectangular shaped during the second and third trimester of pregnancy. The width of the CSP was measured by placing the calipers on the inner margin of its lateral borders (inner to- inner measurement). The normal widening of CSP has been standardized between 2 and 4.7 mm (± 2 standard deviation) at 19 to 20 weeks of gestational

age.⁶ When found as an isolated sonographic abnormality, fetal outcome is usually favorable. But as the fetus had narrow CSP with associated bilateral congenital cataract, we narrowed down our differentials to chromosomal abnormalities, Walker-Warburg syndrome, and *RAB3GAP1* deficiencies (WMS and Martsolf syndrome 2). The case highlights the utility of next-generation sequencing techniques, as this being a genomic technique allowed a faster analysis of all phenotype related genes in the fetus, allowing the family a timely decision regarding pregnancy continuation as WMS has severe neurodevelopmental involvement. Also, WMS is an autosomal recessive disorder with 25% risk of recurrence in each pregnancy. The family was explained the risk of recurrence, need for invasive testing in subsequent pregnancies (chorionic villus sampling at 12 weeks) and extended family screening. The option of Preimplantation Genetic Testing-Monogenic (PGT-M) was also discussed.

Conclusion

This case report shows that bilateral congenital cataract and narrow CSP can provide a clue to an early diagnosis of WMS in fetus. It emphasizes the role of phenotype driven genetic testing, which can help the family in management of the present pregnancy and provision of prenatal diagnosis for future pregnancies.

Conflict of Interest

None declared.

Acknowledgment

The authors would like to thank the patients and hospital.

References

- 1 Trkova M, Hynek M, Dudakova L, et al. Early detection of bilateral cataracts in utero may represent a manifestation of severe congenital disease. *Am J Med Genet A* 2016;170(07):1843–1848
- 2 Shen O, Gelot AB, Moutard ML, Jouannic JM, Sela HY, Garel C. Abnormal shape of the cavum septi pellucidi: an indirect sign of partial agenesis of the corpus callosum. *Ultrasound Obstet Gynecol* 2015;46(05):595–599
- 3 Cooper S, Katorza E, Berkenstadt M, Hoffmann C, Achiron R, Bar-Yosef O. Prenatal abnormal width of the cavum septum pellucidum - MRI features and neurodevelopmental outcome. *J Matern Fetal Neonatal Med* 2018;31(22):3043–3050
- 4 Handley MT, Morris-Rosendahl DJ, Brown S, et al. Mutation spectrum in *RAB3GAP1*, *RAB3GAP2*, and *RAB18* and genotype-phenotype correlations in warburg micro syndrome and Martsolf syndrome. *Hum Mutat* 2013;34(05):686–696
- 5 Francis PJ, Berry V, Bhattacharya SS, Moore AT. The genetics of childhood cataract. *J Med Genet* 2000;37(07):481–488
- 6 Timor-Tritsch E. *Ultrasonography of the prenatal brain*, third edition. McGraw Hill; 2012; 2:62–65, 3:128, 6:235–244