

Atypical Presentation Of Achalasia Cardia - A Case Report

GL SHARMA, A KUMAR, A MUKUND, A KEDIA

Ind J Radiol Imag 2005 15:2:175-177

Key words : - Achalasia cardia, MRI

Introduction

Achalasia is defined as failure of organized peristalsis in oesophagus and failure of relaxation at the level of lower oesophageal sphincter. The actual cause is unknown but it can be categorized as (a) primary (idiopathic) achalasia, due to abnormality of oesophageal aurbachs plexus and (b) secondary achalasia (pseudoachalasia) caused by malignant tumor at the gastro-esophageal junction or less commonly, by benign conditions such as chagas' disease [1, 2].

Case report

A 62-year-old man presented with a history of recurrent low-grade fever, cough, mucopurulent sputum, dyspnoea, loss of appetite and loss of weight for the past seven months. There was no history of haemoptysis. He had been receiving symptomatic treatment at his native place but was not relieved.

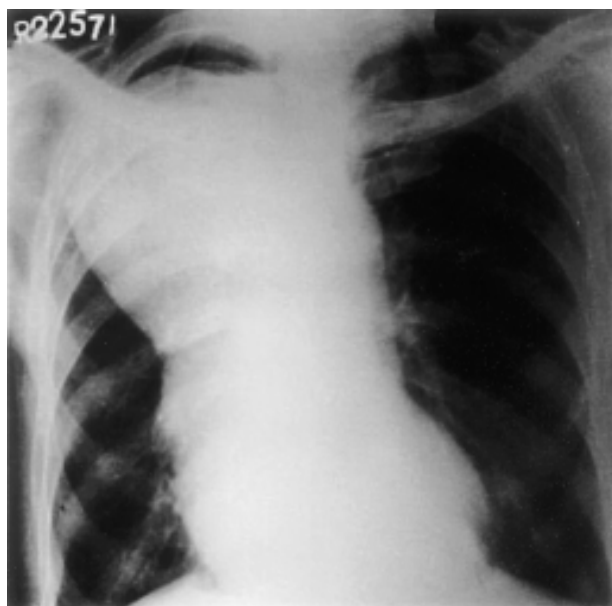


Fig 1

As there was no significant clinical improvement, he was referred to the G.R. Medical College & J.A. Group of hospitals for management. When he presented to our department, in addition to the above mentioned symptoms he also complained of fatigue and giddiness for the preceding one month. He did not give a history of dysphagia, regurgitation or vomiting.

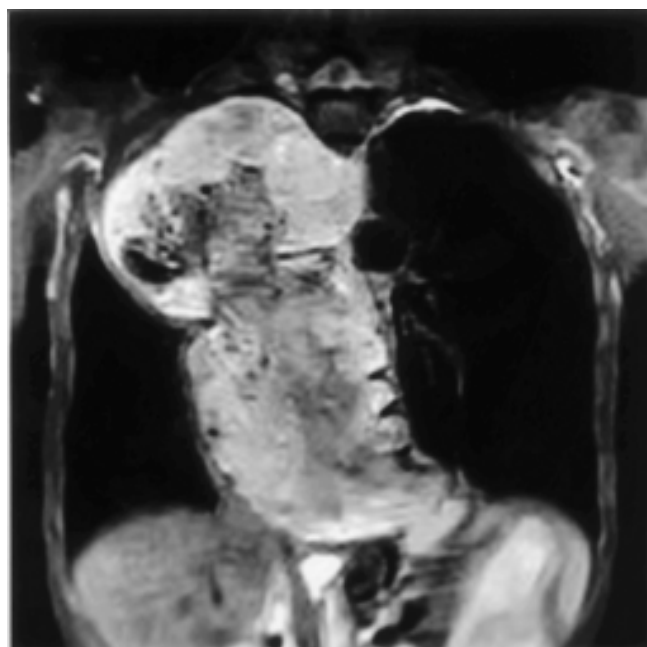


Fig 2

The initial investigation started with a frontal chest radiograph. The chest radiograph was suggestive of a right upper zone mass lesion with widening of mediastinum (Fig. 1) but was inconclusive so further MRI thorax was performed on 0.2T open magnet GE scanner, T1W, T2W and fat suppressed images were obtained in axial, coronal and sagittal planes. MR images revealed dilated tortuous bowel loop in thorax reaching upto the

From the Department of Radio-diagnosis, G. R. Medical College, Gwalior.

Request for Reprints: DR ANIL KUMAR, D-63, Vasant Vihar, Lashkar, Gwalior - 474009, MP

Received 4 October 2004; Accepted 20 December 2005

right apical region with tapering in lower part, causing widening of mediastinum and hiatus, containing food particles and fluid. Secondary as well as tertiary folds were also noted in middle and lower parts of the distended loop. Gastro-oesophageal junction and stomach were below diaphragm. Small area of consolidation was seen in left upper zone with atelectasis of posterior segment of right upper lobe and middle lobe (Fig. 2). Barium swallow was performed which showed dilated, tortuous oesophagus (Fig. 3, 4).

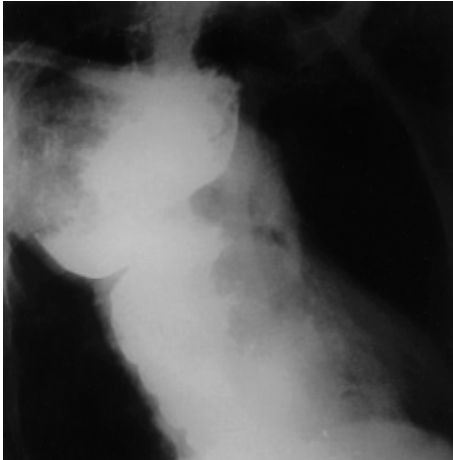


Fig 3

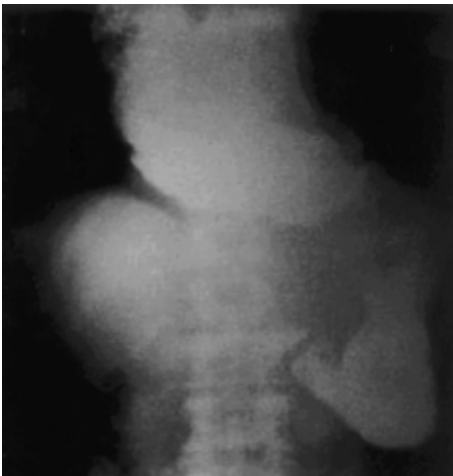


Fig 4

A provisional diagnosis of achalasia cardia was made which was subsequently confirmed by upper gastro-intestinal endoscopy. So the final diagnosis was made as "Primary achalasia cardia with recurrent episodes of aspiration pneumonia".

Discussion

Primary achalasia is a disorder of the oesophageal motility characterised by absent primary peristalsis and incomplete relaxation of the lower oesophageal sphincter caused by loss of ganglion cells in the oesophageal myenteric plexus whereas secondary achalasia (pseudoachalasia) is caused by malignant tumor at the gastro-oesophageal junction or rarely by chagas' disease [1, 2]. These changes result in impaired

oesophageal emptying with a resistance to antegrade flow. As a consequence, the oesophagus becomes dilated and elongated.

Dysphagia is the cardinal symptom in patients with achalasia and is present in more than 90% of the patients [3, 4]. Regurgitation, weight loss, chest pain or discomfort are other common symptoms [3-5]. Most patients are symptomatic. The chest radiograph often reveals a homogeneous paramediastinal mass lesion. Other commonly observed radiological findings include, mediastinal widening, air-fluid levels, absence of gastric air bubble and complications such as aspiration pneumonia or a lung abscess. Primary achalasia is characterised on barium studies by absent primary peristalsis and smooth, tapered narrowing of the distal oesophageal sphincter [6]. CT scan offers no additional information for diagnosis but helps in differentiating between primary and secondary achalasia [7]. Limited information is available regarding MR findings in patients with achalasia cardia.

Our patient did not manifest any of these classical symptoms. On the contrary, his complaints were predominantly related to the respiratory system. It is likely that recurrent episodes of aspiration of oesophageal contents into the respiratory tract would have contributed to the occurrence of respiratory symptoms. The diagnosis was suggested on MRI of the thorax and confirmed by a barium swallow radiograph and upper gastro-intestinal endoscopy.

The present case highlights the fact that oesophageal achalasia remains an elusive diagnosis. While the diagnosis can be ascertained in most of the symptomatic patients by barium oesophagogram and oesophageal manometry, the diagnosis is often delayed in asymptomatic patients as in the case of the present patient.

References

1. CA Woodfeild, M S Levine, S E Rubesin, C P Langlotz, I Laufer. Diagnosis of primary versus secondary achalasia, reassessment of clinical and radiographic criteria. *AJR* 2000; 175:727-731.
2. Kahrilas PJ, Kishk SM, Helm JF, Dodds WJ, Harig JM, Hogan WJ. Comparison of pseudoachalasia and achalasia. *Am J Med* 1987;82:439-446.
3. Muralidharan S, Jairaj PS, Periyannayagam WJ, John S. Achalasia cardia : A review of 100 cases. *Aust NZ J Surg* 1978; 48 : 167-70.
4. Mirchandani LV, Joshi JM. Achalasia cardia : Perplexing chest radiographs. *J Assoc Physicians India* 1995; 43 : 721-22.
5. Haubrich WS, Schaffer F, Berk JE. *Bockus Gastroenterology*. Philadelphia : W.B. Saunders and Co.; 1995 : 422-36.
6. Ott DJ. Motility disorders. In: Gore RM, Levine MS, Laufer I, eds. *Textbook of gastrointestinal radiology*. Philadelphia: Saunders, 1994:346-359
7. Carter M, Deckmann RC, Smith RC, Burrell MI, Traube M. Differentiation of achalasia from pseudoachalasia by computed tomography. *Am J Gastroenterol* 1997; 92 : 624-28.