

Case Report: Acute tuberculous laryngitis presenting as acute epiglottitis

Ahmed H El Beltagi, Pushpinder S Khera, Lamya Alrabiah, Noufa FJ Al Shammari

Department of Clinical Radiology, Al Sabah Hospital, Ministry of Health, Kuwait City, Kuwait

Correspondence: Dr. Pushpinder Singh Khera, 489, DDA SFS, Pocket-2, Sector19, Dwarka, New Delhi – 110 075, India.
E-mail: pushpi707@yahoo.com

Abstract

The incidence of laryngeal tuberculosis (TB), which had dropped dramatically after the institution of modern anti-TB chemotherapy, has shown recent reemergence. It is important to be aware of its possibility, especially as it can present with nonspecific upper airway symptoms and a frequent lack of constitutional manifestations. We report such a case presenting as acute epiglottitis, with diffuse involvement of the supraglottic larynx associated with reactivation lung TB.

Key words: Laryngeal tuberculosis; laryngitis; odynophagia

Introduction

Laryngeal tuberculosis is a rare form of extrapulmonary tuberculosis (TB). It was considered in the preantibiotic era to be the most common disease of the larynx, affecting 35–83% of patients with tuberculosis.^[1]

Currently its incidence is estimated to be less than 1% of all TB cases.^[1,2] Due to its vague clinical presentation and because of a lack of clinical suspicion, laryngeal TB is frequently confused with entities like laryngeal carcinoma and chronic laryngitis.^[3] Its clinical features include odynophagia, cough, and hoarseness of voice.^[4] It is highly contagious^[5] and hence its early diagnosis is very important. Virtually all patients with laryngeal TB have active pulmonary TB, the sputum-positive rate being 90–95%.^[6]

Case Report

A 40-year-old man presented to the otolaryngology

outpatient department with a 10 days' history of dry irritating cough, fever, and throat pain. He also reported a weight loss of 5 kg over the preceding 8 weeks. The physical examination did not reveal cervical lymphadenopathy. Indirect laryngoscopy revealed diffuse edema and swelling of the supraglottic larynx and epiglottis, consistent with supraglottic laryngitis and epiglottitis. Both vocal cords were hyperemic, and nodular lesions were noted on the laryngeal ventricle mucosa bilaterally.

Lateral radiograph of the neck showed thickening of the epiglottis and aryepiglottic fold [Figure 1]. The laboratory investigations showed a raised erythrocyte sedimentation rate (ESR) of 80 mm in the first hour. Sputum production was scanty, and sputum examination was negative for acid fast bacilli (AFB).

A presumptive clinical diagnosis of acute epiglottitis was made and the patient was started on oral azithromycin. However, he did not improve and his cough worsened, becoming productive in nature over the next 10 days.

A plain chest radiograph (CXR) and CT scans of the neck and thorax were performed. The CXR showed bilateral reticulonodular infiltrative lesions in the upper zones [Figure 2]. Contrast-enhanced CT scan of the neck was performed on a 16-slice scanner (GE LightSpeed™, General Electrics, USA). It revealed thickening and enhancement of the epiglottis and both aryepiglottic folds, the pyriform fossae, and both vocal cords, including the anterior commissure [Figures 3 and 4]. There was a

Access this article online

Quick Response Code:



Website:
www.ijri.org

DOI:
10.4103/0971-3026.90690

predominant anterior pattern of involvement, against a diffuse background of multiple, focal, low-attenuation areas and obliteration of the paralaryngeal fat planes. Scattered moderate-sized cervical lymph nodes were also noted [Figure 3A]. CT scan of the chest (not shown) confirmed

the CXR findings and showed bilateral apical fibronodular infiltrates. The sputum examination was repeated and was positive for acid-fast bacilli.

Based on these findings a diagnosis of laryngeal and pulmonary reactivation TB was made and the patient was started on standard four-drug anti-tuberculous treatment. Clinically he responded well to the treatment, and by 3 weeks he was symptom free. Laryngoscopy showed resolution of the supraglottic inflammatory changes and he was discharged from the hospital with instructions to complete the anti-tuberculous treatment. The patient remained stable on routine follow-up visits for 1 year.

Discussion

Laryngeal TB, caused by mycobacterium tuberculosis is usually a complication of pulmonary TB, and most patients with laryngeal TB have coexisting active pulmonary TB, sputum-positive rate being 90-95%. Their medical history can include an absence of BCG vaccination, the

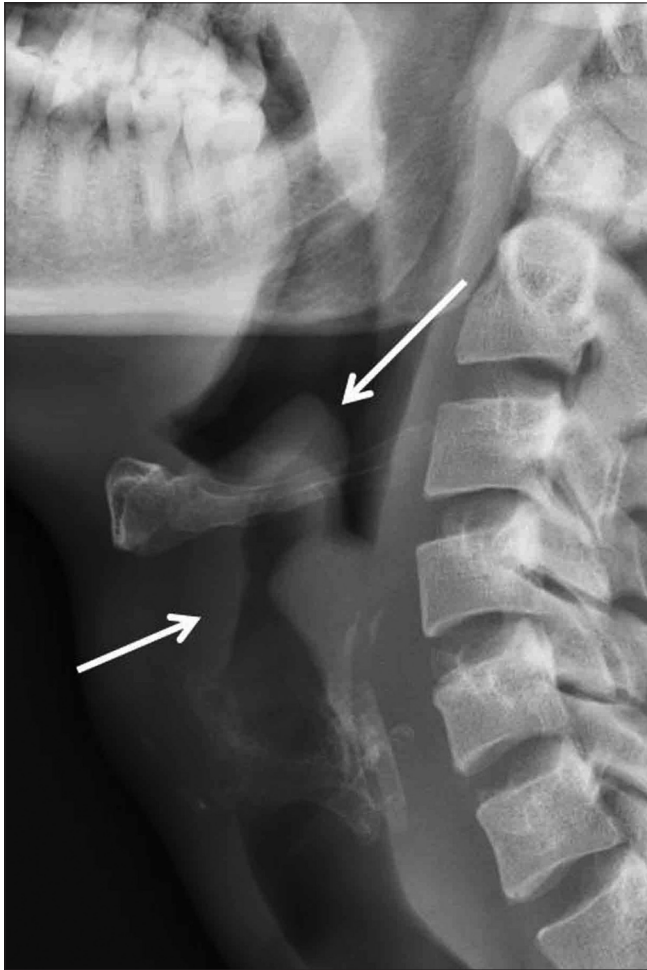

Figure 1: Lateral radiograph of the neck shows a thickened epiglottis (long arrow) and pre-epiglottic tissue (short arrow)

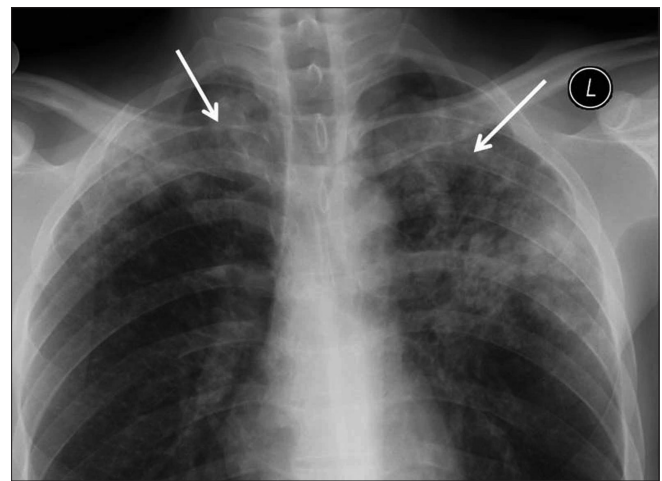


Figure 2: Frontal chest radiograph shows reticulonodular infiltrative lesions (arrows) in both upper zones

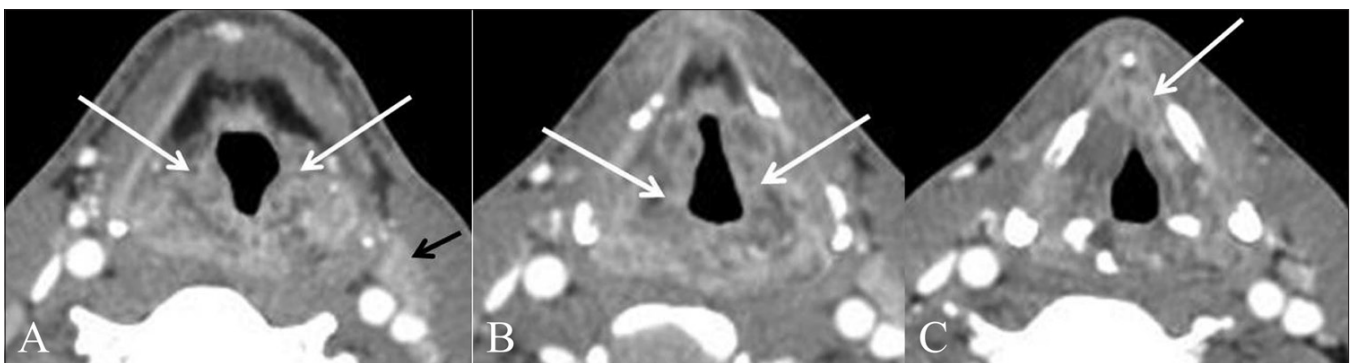


Figure 3 (A-C): Axial contrast-enhanced CT scans. At the supraglottic level (A) there is soft tissue thickening and enhancement of both aryepiglottic folds and pyriform sinuses (white arrows), with an enlarged left deep cervical group lymph node (black arrow). At the level of the false vocal cords, there is thickening and enhancement within the paralaryngeal soft tissues bilaterally (arrows). At the level of the glottis (C) there is soft tissue thickening that extends to the anterior commissure (arrow)

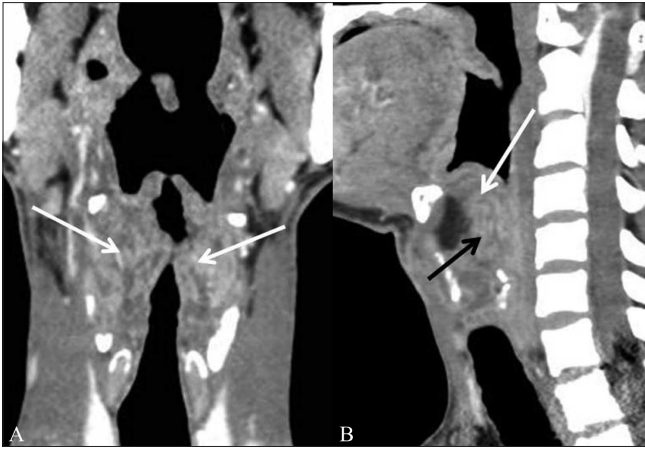


Figure 4 (A, B): Reformatted coronal contrast-enhanced CT scan shows bilateral, thickened, enhancing aryepiglottic folds and supraglottic laryngeal soft tissues, with obliteration of the paralaryngeal fat (arrows). Reformatted sagittal contrast-enhanced CT scan shows thickened, enhancing epiglottis (white arrow), and pre-epiglottic soft tissue (black arrow)

presence of promiscuity, malnutrition, and the acquired immunodeficiency syndrome (AIDS).^[7,8] It occurs generally between the fourth and fifth decades. Particularly, in the last two decades, reports of epiglottic TB have increased.^[9] The clinical presentation in our case is in keeping with the recently reported clinical patterns, where laryngeal TB presented chiefly with laryngeal symptoms such as hoarseness, odynophagia, and dysphagia, with only minimal systemic symptoms.^[4,10]

The radiological appearance of laryngeal TB depends on the stage of the disease. In the acute phase, the lesions are of exudative nature and have a diffuse distribution within the larynx,^[11] as was true in our case. The diagnosis in such cases is suggested by the presence of associated active pulmonary TB.^[12]

On CT scan, patients with acute TB laryngitis show bilateral diffuse thickening of the vocal cords, epiglottis, and paralaryngeal spaces, whereas those with chronic TB laryngitis show focal or asymmetric thickening or a mass.^[12] The most important differential diagnosis to be considered in acute and chronic TB larynx is laryngeal carcinoma – diffuse circumglottic in the former and localized in the latter.^[12] Imaging features that favor a diagnosis of TB laryngitis over laryngeal carcinoma include a bilateral diffuse pattern of involvement [Figure 3]; thickening of the free edge of the epiglottis [Figure 4B]; intact laryngeal architecture (i.e., no sclerosis or destruction of the cartilages); lack of subglottic or hypopharyngeal extension; and focal low-attenuation areas in the lesion, which are probably indicative of caseation necrosis [Figure 3].^[11,12] Paralaryngeal space involvement has been described in certain studies,^[12] though other authors have not mentioned this as a finding in such cases.^[13] Enlarged cervical nodes

with hypodense centers and peripheral rim enhancement are also a feature of laryngeal TB.^[14] Calcification is rare in laryngeal tuberculosis.^[12]

Multidrug antituberculous chemotherapy is the mainstay of treatment leading to an excellent response in most cases and resolution of laryngeal lesions in 4–8 weeks.^[4,12] However untreated laryngeal TB may lead to laryngeal stenosis and cricoarytenoid fixation that may require surgical correction.^[12]

In conclusion, with the worldwide reemergence of tuberculosis, cases of laryngeal tuberculosis have also increased and often simulate laryngeal carcinoma clinically and radiologically. Some imaging features as in our case may favor the diagnosis of tuberculosis. However to establish a definitive diagnosis, chest radiographs, acid fast sputum smears, and bacteriologic cultures may be necessary.

References

1. Uslu C, Oysu C, Uklumen B. Tuberculosis of the epiglottis: A case report. *Eur Arch Otorhinolaryngol* 2008;265:599-601.
2. Williams RG, Tony DJ. Mycobacterium marches back. *J Laryngol Otol* 1995;109:5-13.
3. Lin CJ, Kang BH, Wang HW. Laryngeal tuberculosis masquerading as carcinoma. *Eur Arch Otorhinolaryngol* 2002;259:521-3.
4. Richter B, Fradis M, Köhler G, Ridder GJ. Epiglottic tuberculosis: differential diagnosis and treatment. Case report and review of the literature. *Ann Otol Rhinol Laryngol* 2001;110:197-201.
5. Diktaban T, Lucente FE. Laryngeal tuberculosis: A hazard to the Otolaryngologist. *Ear Nose Throat J* 1980;59:488-94.
6. Soda A, Rubio H, Salazar M, Ganem J, Berlanga D, Sanchez A. Tuberculosis of the larynx: Clinical aspects in 19 patients. *Laryngoscope* 1989;99:1147-50.
7. Travis LW, Hybels RL, Newman MH. Tuberculosis of the larynx. *Laryngoscope* 1976;86:549-58.
8. Levenson MJ, Ingerman M, Grimes C, Robbett WF. Laryngeal tuberculosis: Review of twenty cases. *Laryngoscope* 1984;94:1094-7.
9. Edizer DT, Karaman E, Mercan H, Alimoglu Y, Esen T, Cansiz H. Primary tuberculosis involving epiglottis: A rare case report. *Dysphagia* 2010;25:258-60.
10. Nishiike S, Irifune M, Doi K, Sawada T, Kubo T. Laryngeal tuberculosis: A report of 15 cases. *Ann Otol Rhinol Laryngol* 2002;111:916-8.
11. Thaller SR, Gross JR, Pilch BZ, Goodman LM. Laryngeal tuberculosis as manifested in the decades 1963-1983. *Laryngoscope* 1987;97:848-50.
12. Moon WK, Han MH, Chang KH, Kim HJ, Im JG, Yeon KM, *et al.* Laryngeal tuberculosis: CT findings. *AJR Am J Roentgenol* 1996;166:445-9.
13. Kim MD, Kim DI, Yune HY, Lee BH, Sung KJ, Chung TS, *et al.* CT findings of laryngeal tuberculosis: Comparison to laryngeal carcinoma. *J Comput Assist Tomogr* 1997;21:29-34.
14. Lee Y, Park KS, Chung SY. Cervical tuberculous lymphadenitis: CT findings. *J Comput Assist Tomogr* 1994;18:370-5.

Cite this article as: El Beltagi AH, Khera PS, Alrabiah L, Al Shammari NF. Case Report: Acute tuberculous laryngitis presenting as acute epiglottitis. *Indian J Radiol Imaging* 2011;21:284-6.

Source of Support: Nil, **Conflict of Interest:** None declared.