

CASE REPORT

Cerebral nocardiosis

Sachin Baldawa, Naren Nayak, Sanjay Kukreja, Desma D'souza¹, Batuk Diyora, Alok Sharma

Departments of Neurosurgery and ¹Microbiology, Lokmanya Tilak Municipal Medical College, Mumbai, Maharashtra, India

ABSTRACT

Cerebral Nocardiosis is a rare, challenging, opportunistic infectious disease of the central nervous system occurring in both immunocompetent and immunocompromised hosts. It often results in intraparenchymal abscess formation, which represents only 2% of all cerebral abscesses. The diagnosis of cerebral Nocardiosis is seldom based on imaging. Bacteriological diagnosis is often reached only after surgical excision of the abscess. We report a rare case of brain abscess caused by *Nocardia* species in a 20-year-old immunocompromised lady. Total surgical excision of the abscess, prompt bacteriological diagnosis based on smear and culture of the pus and initiation of specific antimicrobial therapy (trimethoprim and sulfamethoxazole) resulted in good clinical outcome.

Key words: Brain abscess, cerebral nocardiosis, *Nocardia*

Introduction

Brain abscess is one of the several forms of intracranial infection that is though uncommon, can be life-threatening. With the advent of better imaging modalities and effective antimicrobial therapy, there has been a trend toward reduced mortality. Brain abscess in immunocompetent patients are polymicrobial due to aerobic and anaerobic bacteria. However, widespread use of antibiotics has resulted in brain abscess caused by atypical organisms like *Nocardia* species.

Case Report

A 20-year-old female presented with gradual onset progressive weakness in her right upper and lower limbs of 3 weeks duration. She also had persistent holocranial headache associated with multiple episodes of vomiting since 1-week. She did not have convulsions or fever during the course of her illness. Three months prior to the onset of the present illness, she was diagnosed to have pulmonary tuberculosis and was

on intensive regimen of antituberculous therapy (Isoniazid, Rifampicin, Ethambutol and Pyrazinamide). On clinical examination, her pulse was 56/min. She had bilateral sixth nerve palsy and right upper motor neuron facial palsy. Her fundus examination revealed gross papilledema. She had right spastic hemiparesis with power grade 3/5 and 2/5 in upper and lower limbs respectively. Right plantar response was extensor. Magnetic resonance imaging (MRI) of the brain revealed multiple multiloculated lesions in the left medial frontal lobe. Largest of the lesions measured 4 cm in diameter with multiple smaller lesions located posteriorly. The lesions demonstrated central hypointense signals on T1-weighted imaging (T1-WI) with corresponding hyperintense signals on T2-WI [Figure 1a and 1b]. The peripheral rim revealed isointense signals on T1-WI and hypointense signals on T2-WI [Figure 1a and 1b]. On gadolinium contrast administration, thick, smooth enhancement of the peripheral rim was noted [Figure 1c and 1d]. Diffusion-weighted imaging revealed hyperintense signal within the lesions [Figure 2a] with corresponding apparent diffusion coefficient revealing hypointense signals [Figure 2b] suggestive of restricted diffusion. Fluid attenuated inversion recovery sequence revealed hyperintense signals adjacent to the lesions suggestive of vasogenic edema [Figure 2c]. Chest ray revealed right apical infiltrates. Laboratory workup showed the leucocytosis (white blood cell 13000/cmm) and elevated sedimentation rate (70 mm/h in first 1 h). The presumptive imaging diagnosis was multiple tubercular abscesses. At surgery multiloculated, thick walled abscess was encountered in the left medial frontal region. Aspiration of the largest abscess cavity revealed non-foul smelling pus. Total excision of the abscess was performed. Aspirated pus was sent for g stain, aerobic, anaerobic and tubercular bacilli culture. Examination of pus smear revealed g positive

Access this article online

Quick Response Code:



Website:

www.asianjns.org

DOI:

10.4103/1793-5482.146661

Address for correspondence:

Dr. Sachin Baldawa, Department of Neurosurgery, Lokmanya Tilak Municipal Medical College, Mumbai, Maharashtra, India.
E-mail: sachin_baldawa@yahoo.co.in

branching filaments. The bacilli were partially acid alcohol fast suggestive of *Nocardia* species [Figure 3a]. Growth was obtained on blood agar and Lowenstein Jensen media after 96 h of incubation [Figure 3b]. Smears from culture also revealed g positive filaments which were partially acid fast. Biochemical reactions were performed which revealed catalase positive, urease positive, oxidase test negative and reduction of nitrates to nitrites. Blood culture remained sterile. Sputum culture did not reveal growth of *Nocardia* or tuberculous bacilli. Postoperatively, she received broad spectrum empirical antibiotic therapy and antituberculous drugs until culture reports were available. Following the growth of *Nocardia* on culture, she was started on trimethoprim/sulphamethoxazole (TMP/SMX) (960/4800 mg) daily. In the postoperative period, her right hemiparesis improved to grade 4/5 power. On Follow up at 3 months, her bilateral sixth nerve palsy had resolved partially and she was independent for her daily activities. MRI of the brain

performed at 6 months did not show any signs of relapse [Figure 4a and b] following which TMP/SMZ was discontinued.

Discussion

Nocardiosis is a rare opportunistic infection occurring in the immunocompromised host.^[1] The causative organism is *Nocardia* species - an aerobic, catalase positive, g variable to g positive, acid alcohol fast, nonmotile bacilli with branching filaments.^[2-4] These soil-borne ubiquitous actinomycetes often cause localized or disseminated infection. Primary infection is acquired following inhalation of airborne bacilli or by direct cutaneous inoculation resulting in pulmonary or cutaneous manifestations respectively.^[3-6] Hematogenous spread results in widespread systemic dissemination.^[1,6,7] Only 25-40% of patients with systemic nocardiosis develop cerebral infection.^[7]

Cerebral Nocardiosis is a rare clinical entity representing only 2% of all cerebral abscesses.^[5,8] It usually results in

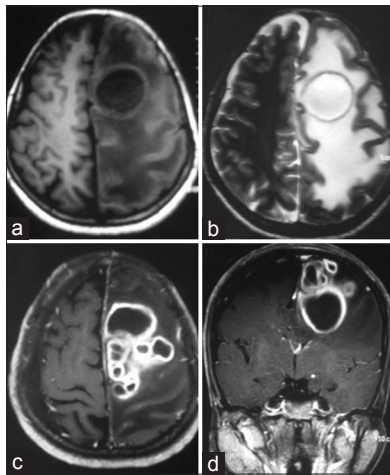


Figure 1: Magnetic resonance imaging of the brain revealed multiloculated lesions in left medial frontal lobe. Largest of these lesions demonstrated central hypointense signals on T1-weighted imaging (T1-WI) with corresponding hyperintense signals on T2-WI (a and b). The peripheral rim revealed isointense signals on T1-WI and hypointense signals on T2-WI (a and b). On administration of gadolinium contrast multiple ring enhancing lesions was noted (c and d)

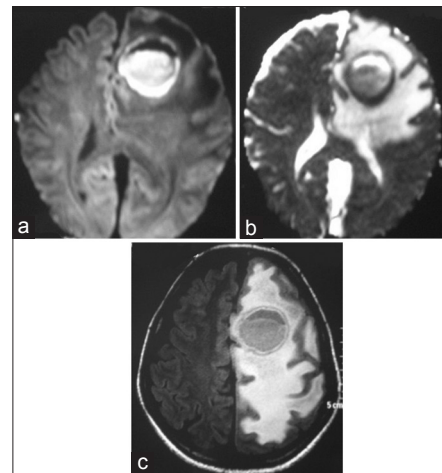


Figure 2: The lesions demonstrated hyperintense signals on diffusion weighted imaging (a) with corresponding hypointense signals on apparent diffusion coefficient imaging (b) suggestive of restricted diffusion. Fluid attenuated inversion recovery sequences shows the extensive vasogenic edema around the lesion (c)

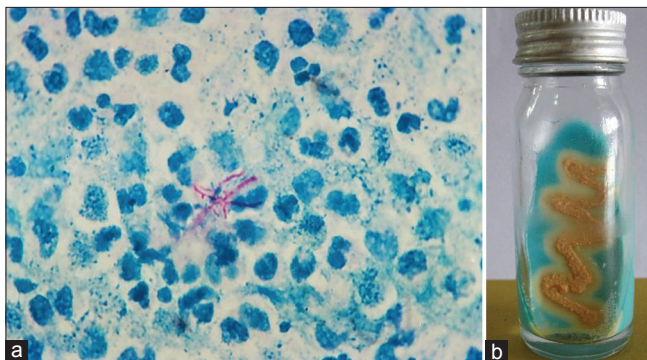


Figure 3: Acid fast branching filaments of *Nocardia asteroides* is evident among pus cells in smear stained by modified Ziehl Neelsen, (x1000) (a). Colony growth is seen on Lowenstein Jensen media (b)

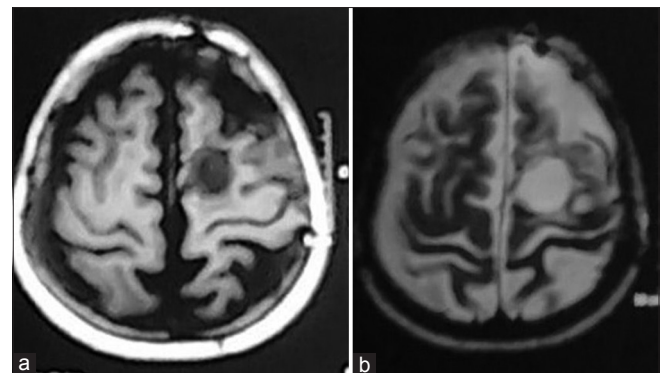


Figure 4: Magnetic resonance imaging of the brain at 6 months follow-up does not reveal any signs of recurrence on T1-weighted imaging (T1-WI) and T2-WI (a and b)

Table 1: The cases of Nocardial brain abscesses published in recent literature

Author	Age/sex	Immunocompromised	Location	Primary	Species	Surgery	Treatment	Morbidity
Present case	20/female	Yes	Left frontal lobe	No	<i>N. asteroides</i>	Craniotomy and total excision	Cotrimoxazole for 6 months	No
Patil et al. ^[1]	53/male	No	Right occipital lobe	No	<i>N. brasiliensis</i>	Craniotomy and total excision (twice)	Linezolid for 4 months followed by cotrimoxazole	No
Lin et al. ^[6]	61/female	No	Right cerebellar	No	<i>N. asteroides</i>	Craniotomy	Ampicillin and amikacin	Death
	52/male	No	Left frontal	No	<i>N. asteroides</i>	Craniotomy	Ceftriaxone and metronidazole for 2 months followed by ampicillin for 1-month	No
Dias et al. ^[3]	69/female	No	Left frontal	No	<i>N. asteroides</i>	Craniotomy	Piperacillin	Death
	67/male	No	Left frontal lobe	No	<i>N. asteroides</i>	Craniotomy and total excision	Cotrimoxazole for 3 months	No
Zakaria et al. ^[4]	40/male	Yes	Right occipital lobe	No	<i>N. asteroides</i>	Multiple burr hole and aspiration	Cotrimoxazole followed by minocycline for 6 months and meropenem for 1-year	Yes
Kennedy et al. ^[5]	79/male	No	Right cerebellum and left frontal	Soft tissue	<i>N. asteroides</i>	No	Cotrimoxazole and ceftriaxone for 2 months followed by cotrimoxazole for 8 months	No
	79/male	No	Right parietal lobe	Lung	<i>N. asteroides</i>	Craniotomy and excision	Cotrimoxazole and ceftriaxone for 45 days followed by cotrimoxazole for 18 months	No
	61/male	No	Right parietal lobe	Lung	<i>N. brasiliensis</i>	Craniotomy and excision	Cotrimoxazole and ceftriaxone for 2 weeks followed by cotrimoxazole for 12 months	No
Braga et al. ^[2]	51/male	No	Left cerebellar	No	<i>N. asteroides</i>	Craniotomy	Cotrimoxazole and ceftriaxone for 2 weeks followed by minocycline for 15 months	No
	58/male	No	Multiple	Lung and soft tissue	<i>N. asteroides</i>	No	Imipenem and amikacin for 2 months followed by cotrimoxazole for 8 months	No
Barnaud et al. ^[9]	33/male	Yes	Right frontal	Lungs	<i>N. cyriacigeorgical</i>	Stereotactic aspiration	Imipenem/amikacin/ ciprofloxacin for 1-month followed by cotrimoxazole, amoxicillin	No
Valarezo et al. ^[15]	65/male	Yes	Right cerebellar	No	<i>N. asteroides</i>	Craniotomy and excision	Cotrimoxazole for 11 months	No
	42/male	No	Right occipital	No	<i>N. asteroides</i>	Craniotomy and aspiration (twice)	Cotrimoxazole for 7 months	No
	68/male	Yes	Right occipital	Lung	<i>N. asteroides</i>	Aspiration (twice) followed by craniotomy	Imipenem and amikacin for 2 months followed by amikacin/cefotaxime and sulfadiazine for 6 months	No
Fleetwood et al. ^[12]	58/male	No	Right frontal	No	<i>N. asteroides</i>	Craniotomy and total excision	Cotrimoxazole for 4 months	No
	65/male	No	Right frontal	No	<i>N. asteroides</i>	Craniotomy and total excision	Cotrimoxazole for 6 months	No
	29/male	No	Left frontal and right parietal	Lungs	<i>N. asteroides</i>	No	Cotrimoxazole 1 month, imipenem 1-month, amikacin, cefotaxime, sulfadiazine 1-month, cefotaxime 4 months, ceftriaxone 5 months	No

N. asteroides - *Nocardia asteroides*; *N. brasiliensis* - *Nocardia brasiliensis*; *N. cyriacigeorgical* - *Nocardia cyriacigeorgical*

intraparenchymal, poorly encapsulated abscess formation.^[2,3,9] One of the major risk factor for the occurrence of cerebral Nocardiosis is the host immunodeficiency following immunosuppressive drugs, organ transplant, HIV, diabetes mellitus, chronic infection and cancer.^[6,10,11] Although Nocardiosis can occur in immunocompetent hosts,^[4,5,12,13] symptomatic human infection needs careful evaluation of clinical conditions causing immunosuppression.^[3,11] 86% of all *Nocardial* infection in humans is caused by members of the *Nocardia asteroides* complex.^[1,3,9,11,12] Infection of the central nervous system can rarely be caused by *N. cyriaciageorgica*, *brasiliensis*, *farcinica*.^[1,9,13]

Diagnosis of primary and systemic Nocardiosis is difficult due to paucity of clinical and laboratory signs of infection. Isolation of *Nocardia* species following colonization of the respiratory tract is often difficult due to the nonspecific clinical manifestation, lack of clinical suspicion, slow growth of the organism on culture and difficulty in isolating the organism on culture due to the presence of commensals.^[9] *Nocardia* abscess is often misdiagnosed as pyogenic abscess or malignant tumor on imaging resulting in a delay in surgical excision and initiating appropriate antimicrobial therapy.^[3,5,13] Like tuberculous abscess, Nocardial abscesses are multiloculated resulting from the coalescence of multiple daughter abscesses.^[1] Definite bacteriological diagnosis is only possible after examination of the pus and abscess wall.^[2,5] Cerebral Nocardiosis is associated with highest mortality and morbidity amongst all brain abscess caused by microorganisms.^[1,4,5] Mortality rates of 55% and 20% have been described in immunocompetent and immunocompromised patients respectively.^[13] With the advent of computed tomography scan and newer generation antibiotics, the mortality has reduced from nearly 90-33% in single brain abscess.^[12,14] However in the presence of multiple abscesses, the mortality remains high at 66%.^[12,14]

The optimal management of cerebral Nocardiosis has not been established. Nocardial brain abscess have been managed either by antimicrobial therapy alone, aspiration or total excision of the abscess wall.^[2,15] Synergetic combination of TMP/SMX (cotrimoxazole) is the drug of choice often requiring prolonged therapy from 6 weeks to 1-year.^[4-6] Total excision of the abscess followed by administration of appropriate antimicrobial therapy based on sensitivity pattern results in complete resolution of symptoms.^[1] Mamelak *et al.* reviewed 120 reported cases of Nocardial brain abscess and concluded that the overall mortality rate was 33% among patients with single abscess.^[8] Mortality rates were much higher following aspiration alone (50%) as compared to craniotomy and excision (24%) and after nonoperative antimicrobial therapy (30%).^[8] On the contrary, Lee *et al.* have demonstrated that single or repeated aspiration alone is a safe and efficacious treatment for

the majority of patients with Nocardial brain abscess.^[14] Complete surgical excision and prolonged antimicrobial therapy are needed to prevent relapse of infection.^[3,5] Table 1 briefly summarizes the cases of Nocardial brain abscesses published in recent literature.

Though cerebral Nocardiosis is often secondary to primary foci in lungs, primary infection could not be detected in our patient. One of the predisposing risk factor could have been her immunocompromised state following pulmonary tuberculosis. The relatively good outcome in our patient was due to her young age, total surgical excision of the abscess and early initiation of antimicrobial therapy with good compliance.

Conclusion

Unusual central nervous system infections like Nocardiosis should be considered in the differential diagnosis of brain abscess especially in the immunocompromised state. In patients with multiple ring-enhancing lesions, high index of clinical suspicion is needed to establish the diagnosis of this atypical infection. Total surgical excision of the abscess reduces the mass effect, surrounding vasogenic edema and provides bacteriological diagnosis, thereby enabling early initiation of organism-specific antimicrobial therapy. Prolonged antimicrobial therapy and long-term surveillance are needed to prevent relapse, thereby ensuring excellent patient outcome.

References

1. Patil A, Cherian A, Iype T, Sandeep P. Nocardial brain abscess in an immunocompetent individual. *Neurol India* 2011;59:779-82.
2. Braga M, Beretta S, Farina C, Pederzoli M, Repaci M, Casati G, *et al.* Medical treatment for nocardial brain abscesses case report. *J Neuro* 2005;252:1120-1.
3. Dias M, Nagarathna S, Mahadevan A, Chandramouli BA, Chandramouli A. Nocardial brain abscess in an immunocompetent host. *Indian J Med Microbiol* 2008;26:274-7.
4. Zakaria A, Elwatidy S, Elgamel E. Nocardia brain abscess: Severe CNS infection that needs aggressive management; case report. *Acta Neurochir (Wien)* 2008;150:1097-101.
5. Kennedy KJ, Chung KH, Bowden FJ, Mews PJ, Pik JH, Fuller JW, *et al.* A cluster of nocardial brain abscesses. *Surg Neurol* 2007;68:43-9.
6. Lin YJ, Yang KY, Ho JT, Lee TC, Wang HC, Su FW. Nocardial brain abscess. *J Clin Neurosci* 2010;17:250-3.
7. Lerner PI. Nocardiosis. *Clin Infect Dis* 1996;22:891-903.
8. Mamelak AN, Obana WG, Flaherty JF, Rosenblum ML. Nocardial brain abscess: Treatment strategies and factors influencing outcome. *Neurosurgery* 1994;35:622-31.
9. Barnaud G, Deschamps C, Manceron V, Mortier E, Laurent F, Bert F, *et al.* Brain abscess caused by *Nocardia cyriaciageorgica* in a patient with human immunodeficiency virus infection. *J Clin Microbiol* 2005;43:4895-7.
10. Kageyama A, Yazawa K, Ishikawa J, Hotta K, Nishimura K, Mikami Y. Nocardial infections in Japan from 1992 to 2001, including the first report of infection by *Nocardia transvalensis*. *Eur J Epidemiol* 2004;19:383-9.
11. Kim J, Minamoto GY, Grieco MH. Nocardial infection as a complication of AIDS: Report of six cases and review. *Rev Infect Dis* 1991;13:624-9.

12. Fleetwood IG, Embil JM, Ross IB. *Nocardia asteroides* cerebral abscess in immunocompetent hosts: Report of three cases and review of surgical recommendations. *Surg Neurol* 2000;53:605-10.
13. Iannotti CA, Hall GS, Procop GW, Tuohy MJ, Staugaitis SM, Weil RJ. Solitary *Nocardia farcinica* brain abscess in an immunocompetent adult mimicking metastatic brain tumor: Rapid diagnosis by pyrosequencing and successful treatment. *Surg Neurol* 2009;72:74-9.
14. Lee GY, Daniel RT, Brophy BP, Reilly PL. Surgical treatment of nocardial brain abscesses. *Neurosurgery* 2002;51:668-71.
15. Valarezo J, Cohen JE, Valarezo L, Spektor S, Shoshan Y, Rosenthal G,

et al. Nocardial cerebral abscess: Report of three cases and review of the current neurosurgical management. *Neurol Res* 2003;25:27-30.

How to cite this article: Baldawa S, Nayak N, Kukreja S, D'souza D, Diyora B, Sharma A. Cerebral nocardiosis. *Asian J Neurosurg* 2014;9:245.

Source of Support: Nil, **Conflict of Interest:** None declared.