

# An Unusual Cause of Acute Abdomen: Massive Amounts of Foreign-Body Bezoar

Mohamed Saleh Addalla<sup>1</sup>, Sammy Senussi Sunni<sup>1</sup>, Asem Bukrah<sup>1</sup>, Ahmed El-Usta<sup>1</sup>

<sup>1</sup>Department of General Surgery, Tripoli Central Hospital, Tripoli, Libya

## Abstract

Acute abdomen, especially in psychiatric patients, can result from bizarre causes such as bezoars. This unique case report intends to shed light on a rare type of bezoars with an unusual presentation. A 30-year-old schizophrenic male, who is in denial of his mental condition and having mystical beliefs instead, presented with acute abdomen. Workups revealed vast amounts of foreign bodies within dilated intestines. Exploratory laparotomy was done extracting about 2 kg of nylon-wrapped foreign bodies which caused distention with multiple perforations to both cecum and sigmoid colon. Interestingly, the foreign materials were either ingested or introduced rectally. Although bezoars are not a common finding nowadays. They should still be considered as a potential cause of acute abdomen in psychiatric and some nonpsychiatric patients alike, especially in countries, where mental illness can easily be disguised as mystical beliefs.

**Keywords:** Acute abdomen, bezoars, foreign bodies, psychiatric illness

## INTRODUCTION

Aggregates of undigested or partially digested materials that could be found within the body or more specifically within the gastrointestinal (GI) tract are known as “Bezoars.”<sup>[1,2]</sup> Although more commonly found in the stomach, they can also be found in the small and large intestines or even less frequently in the rectum.<sup>[3]</sup> Bezoars are classified according to their composition into five types. In decreasing order of frequency, they are phytobezoars (composed of undigested vegetable fibers),<sup>[4]</sup> diospyrobezoars (a type of phytobezoars comprised persimmon fruit),<sup>[4]</sup> trichobezoars (associated with trichotillomania known as the Rapunzel Syndrome),<sup>[4,5]</sup> pharmacobezoars (also known as drug bezoars and made up of accumulated undigested medications;<sup>[4]</sup>), and lactobezoars (made up of milk proteins and mucus.<sup>[4]</sup>

Foreign-body bezoars could be anything from plastic to foams, metals, or even worms such as ascaris.<sup>[4]</sup> Only a few papers were published in the literature regarding foreign-body bezoars in large intestines that were linked to psychiatric patients, even less so, case reports of bezoars being administered orally as well as rectally.

## CASE REPORT

A 30-year-old Libyan male, living in an isolated location, presented to the Accident and Emergency Department complaining of a growing, constant abdominal pain for 3 days, and associated with progressive distension. The patient has schizophrenia but has been off treatment. His family reported that he had recurrent attacks of abdominal cramps and noticed an odd behavior of swallowing foreign materials. The patient had no other chronic illnesses or previous surgeries. On examination, he was conscious, oriented but mildly dehydrated. His pulse rate was 103 bpm, the temperature was 38°C, blood pressure was 135/80 mm Hg, and his respiratory rate was 24 c/m. The abdomen was distended, allowing only a limited movement on respiration. Furthermore, rigidity and tenderness were felt all over the four quadrants, along with diminished bowel sounds. Per rectal examination revealed no visible external lesion, a normal sphincter tone; however, multiple foreign bodies were palpable.

**Address for correspondence:** Dr. Mohamed Saleh Addalla,  
Department of General Surgery, Tripoli Central Hospital,  
Tripoli, Libya.  
E-mail: addalla@gmail.com

### Access this article online

#### Quick Response Code:



**Website:**  
www.ijmbs.org

**DOI:**  
10.4103/ijmbs.ijmbs\_41\_18

This is an open access journal, and articles are distributed under the terms of the Creative Commons Attribution-NonCommercial-ShareAlike 4.0 License, which allows others to remix, tweak, and build upon the work non-commercially, as long as appropriate credit is given and the new creations are licensed under the identical terms.

**For reprints contact:** reprints@medknow.com

**How to cite this article:** Addalla MS, Sunni SS, Bukrah A, El-Usta A. An unusual cause of acute abdomen: Massive amounts of foreign-body bezoar. *Ibnosina J Med Biomed Sci* 2018;10:178-80.

Blood panel reported leukocytosis but was unremarkable otherwise. Abdominal and pelvic radiological workup demonstrated dilated bowel loops containing several intraluminal foreign bodies of varying sizes and shapes as well as a small amount of intra-abdominal-free fluid [Figures 1 and 2]. He underwent exploration laparotomy which revealed dilated bowel loops. Moreover, two perforations in the cecum were detected, in addition to multiple imminent perforations in the sigmoid colon; furthermore, a spillage of a little amount of stool was documented. Limited right hemicolectomy and Hartmann procedures were performed, extracting approximately 2 kg of multiple foreign bodies of different types and sizes wrapped by a green nylon tape [Figure 3a and b]. No trauma to the proximal parts of the GI tract were noted, and those perforations that occurred in the cecum only due to overaccumulation. The patient recovered smoothly postoperatively, and he was referred for further psychiatric care. Six months later, the patient became well and requested reversal of the stoma.

## DISCUSSION

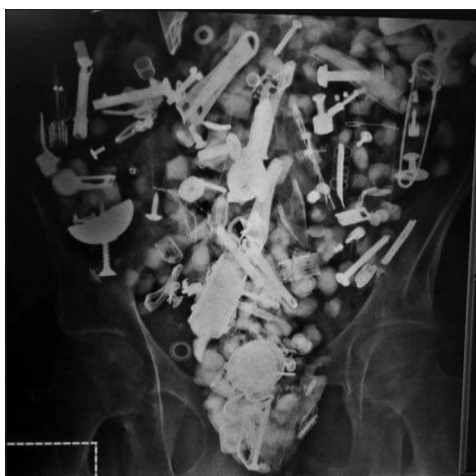The origin of the word “Bezoars” dates to late 15<sup>th</sup> century from French bezoard, based on Arabic bāzahr, bādizahr, from Persian pādzahr which literally means antidote. Historically, animal bezoars were considered to have magical and medicinal properties and were used as such until the 18<sup>th</sup> century.<sup>[2]</sup> The Andalusian physician Ibn Zuhr (d. 1161), known in the West as Avenzoar, is thought to have made the earliest description of bezoar stones as medicinal items. Extensive reference to bezoars also appears in the Picatrix, which may have originated earlier. In current times, some societies still believe in magic only as a cover to avoid the taboo of psychiatric illnesses.

In the present case, a multitude of different types and sizes of foreign materials bypassed the stomach (commonly aggregating near the pylorus) causing no reported trauma to the full length of the GI tract before they eventually accumulated at the ileocecal junction, leading to overstretching and thence perforation of the large intestine giving the picture of acute

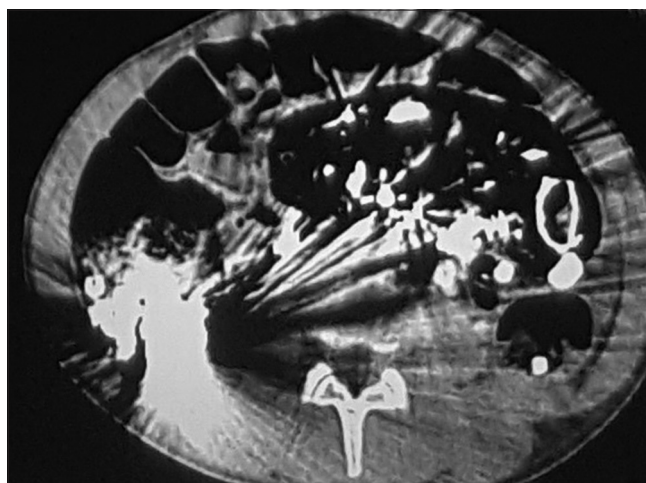peritonitis at presentation. Interestingly, the patient who is a known case of schizophrenia in spite of his and his family’s denial to mental illness and having mystical beliefs instead and so was off-treatment, wrapped the materials with green nylon before intentionally ingesting them. He also introduced plastic-covered stones rectally to his colon, all of which were responsible for this unusual presentation.

Bezoars are rare findings that can occur in all age groups,<sup>[6]</sup> they are conglomeration of indigestible materials found in the GI tract, classified according to their compositions. The diagnosis of bezoars is linked in 9% of cases to behavior disorders.<sup>[6]</sup> They also often occur in patients with abnormal gastric emptying and after gastric surgery.<sup>[7]</sup> Many can be asymptomatic, but some cause symptoms.<sup>[8]</sup>


The highest incidence of bezoars cases is recorded in the stomach for their inability to pass through the pyloric sphincter. Hence, it is less frequent for bezoars to reach the small bowel.<sup>[8]</sup> Rapunzel syndrome is the term given for gastric trichobezoar “hairball” that has a tail-like extension into the small intestine through the pylorus causing gastric outlet obstruction.<sup>[5]</sup> Primary colonic bezoars are extremely rare. Very few reports of primary colonic bezoar causing large-bowel obstruction.<sup>[9]</sup> A primary colonic bezoar in which trichobezoars were obstructing the sigmoid colon and radiographs showed obstruction with no evidence for the cause. Hence, laparotomy was needed for the diagnosis and treatment.<sup>[10]</sup> Another case of primary colonic obstruction was due to a cloth fiber bezoar obstructing the left colon, it was also not diagnosed by radiographs alone and thus required surgery.<sup>[11]</sup> Conventional abdominal radiographs are usually enough to detect bowel obstruction; however, it is difficult to reach a definite diagnose regarding the cause of obstruction on plain radiographs alone. Reportedly, plain radiography could identify bezoars in only 10% of patients.<sup>[10,11]</sup> Fortunately, our case was promptly diagnosed with plain radiograph. Computed tomography scan was further performed to gather extra details for surgery.



**Figure 1:** Erect abdominal plain X-ray huge number of radio-opaque objects with characteristic shapes of domestic materials



**Figure 2:** Computed tomography scan of the abdomen confirming the findings of the plain film and excluding other pathology



**Figure 3:** Nylon wrapped foreign bodies as they were retrieved intraoperatively (a) and after they were cleaned postoperatively (b)

The treatment of colonic bezoars is determined by the site of impaction, the size and type of bezoar, and the presence or absence of any complications.<sup>[4]</sup> Some types of bezoars can be dissolved chemically, others extracted endoscopically, and some require surgery.<sup>[12]</sup> In uncomplicated cases, conservative measures can be used such as enemas and manual disimpaction for bezoars such as lactobezoars or phytobezoars approaches such as enzymatic introduction and Coca-Cola lavages<sup>[4]</sup> were attempted to dissolve the bezoars, although the rarity of these cases still make room for uncharted lands to explore in approaching their management. In case of failure of conservative management or if life-threatening complications are present like sigmoid volvulus, hematochezia and peritonitis, endoscopic or surgical removal of colonic bezoars should be performed.<sup>[13]</sup> An urgent laparotomy was needed due to the acute clinical deterioration with the development of acute peritonitis, tachycardia, and a worsening biochemical picture.

The peculiarity, in this case, is not merely the rarity of its type, site, or extremely rare presentation. The patient wrapped every foreign body in green nylon. This allowed their safe passage through the upper GI tract traversing the pyloric sphincter to become impacted in the large intestines just beyond the

ileocecal junction in the most part. Consequently, this led eventually to overstretching and perforations of the bowels.

### Declaration of patient consent

The authors certify that they have obtained all appropriate patient consent forms. In the form, the patient consented for his images and other clinical information to be reported in the journal. The patient understands that name and initials will not be published, and due efforts will be made to conceal identity, but anonymity cannot be guaranteed.

### Authors' contributions

All authors contributed to the care of the patient, drafting of the case report, revision, and approval of its final version.

### Financial support and sponsorship

Nil.

### Conflicts of interest

There are no conflicts of interest.

### Compliance with ethical principles

No prior ethical approval is usually required for single-case reports at our institution.

## REFERENCES

- Williams RS. The fascinating history of bezoars. *Med J Aust* 1986;145:613-4.
- Taylor JR, Streetman DS, Castle SS. Medication bezoars: A literature review and report of a case. *Ann Pharmacother* 1998;32:940-6.
- Robles R, Parrilla P, Escamilla C, Lujan JA, Torralba JA, Liron R, *et al.* Gastrointestinal bezoars. *Br J Surg* 1994;81:1000-1.
- Iwamuro M, Okada H, Matsueda K, Inaba T, Kusumoto C, Imagawa A, *et al.* Review of the diagnosis and management of gastrointestinal bezoars. *World J Gastrointest Endosc* 2015;7:336-45.
- Lopes LR, Oliveira PS, Pracucho EM, Camargo MA, de Souza Coelho Neto J, Andreollo NA, *et al.* The Rapunzel syndrome: An unusual trichobezoar presentation. *Case Rep Med* 2010;2010:841028.
- DeBakey M, Ochsner A. Bezoars and concretions: A comprehensive review of the literature with an analysis of 303 collected cases and a presentation of 8 additional cases. *Surgery* 1938;4:934-63.
- Case TC. Acute intestinal obstruction from trichobezoar in the sigmoid colon: Case report. *J Am Geriatr Soc* 1974;22:284-5.
- Erzurumlu K, Malazgirt Z, Bektas A, Dervisoglu A, Polat C, Senyurek G, *et al.* Gastrointestinal bezoars: A retrospective analysis of 34 cases. *World J Gastroenterol* 2005;11:1813-7.
- Law GW, Lin D, Thomas R. Colonic phytobezoar as a rare cause of large bowel obstruction. *BMJ Case Rep* 2015;2015: pii: bcr2014208493.
- Gathwal CK, Gathwal MB, Singh K, Arya A. Radiological case: A rare case of left colonic obstruction-cloth fiber bezoar. *Appl Radiol* 2015;44:20-3.
- Verstandig AG, Klin B, Bloom RA, Hadas I, Libson E. Small bowel phytobezoars: Detection with radiography. *Radiology* 1989;172:705-7.
- Wang YG, Seitz U, Li ZL, Soehendra N, Qiao XA. Endoscopic management of huge bezoars. *Endoscopy* 1998;30:371-4.
- Baskonus I, Gökalp A, Maralcan G, Sanal I. Giant gastric trichobezoar. *Int J Clin Pract* 2002;56:399-400.

### Reviewers:

Ali Ghellai (Tripoli, Libya).  
Abdelrahman A Nimeri (Carolinas, USA)  
Abdusalam Abu-Own (Ipswich, UK).  
Mohammed M El-Said (Mansoura, Egypt)  
Milos Ruzicka (Abu Dhabi, UAE)

### Editors:

Elmahdi Elkhammas (Columbus, OH, USA)  
Salem A Beshyah (Abu Dhabi, UAE)