

Imaging in sump syndrome: A rare complication of choledochoduodenostomy

Sir,

We report a case of a 40-year-old female patient who presented with intermittent pain and tenderness in the right upper quadrant, vomiting, fever, and was diagnosed with a rare cause of ascending cholangitis on magnetic resonance cholangiopancreatography (MRCP). MRCP revealed a dilated common bile duct (CBD) of 10 mm diameter and intrahepatic biliary radicle dilatation with marked pneumobilia throughout the liver [Figure 1]. There were filling defects in the distal CBD suggesting impaction of debris [Figure 2]. No fluid level was demonstrated on T2-weighted images [Figure 3A and B]. Magnetic resonance imaging (MRI) findings favoring ascending cholangitis on T2-weighted images were, duct dilatation with irregular wall thickening and ragged margins [Figure 4]. Stricture is a differential diagnosis, but confirmation is possible only with endoscopic retrograde cholangiopancreatography (ERCP). In our case, no demonstrable stricture was identified on MRI and findings were further confirmed with ERCP. Limited computed tomography (CT) sections were carried out to confirm the presence of pneumobilia and intraperitoneal free air. The MRI findings of the ascending cholangitis in the context of a former choledochoduodenostomy (CDD) procedure and MRCP demonstration of sludge in the distal CBD led to the diagnosis of sump syndrome. Pneumobilia is the imaging confirmation for a functioning biliary-enteric anastomosis. Furthermore, the patient underwent ERCP

and sludge was extracted, and with antibiotic treatment the patient recovered.

Sump syndrome is a rare long-term complication of side-to-side CDD, a common surgical procedure in patients with biliary tract disease in the era before ERCP.^[1] Sump syndrome results from accumulation of lithogenic bile, debris, or calculi as well as refluxed duodenal contents in the distal CBD, leading to biliary cholangitis and/or pancreatic complications. In the pre-ERCP era, CDD was a common surgical procedure in patients with biliary tract disease.^[2] In the setting of a side-to-side CDD, the bile does not drain through the distal CBD anymore. Therefore, the part of the CBD distal from the CDD anastomosis transforms into a poorly drained reservoir, making this so-called “sump” prone to accumulation of debris. CDD is rarely performed nowadays, and its complications, including sump syndrome, are almost forgotten, especially due to the long interval until clinical manifestations of sump syndrome occur after CDD.^[3,4] On imaging, diagnostic findings are debris/stones in the CBD with suggested findings of pancreatitis, cholangitis, or liver abscess. Plain radiograph demonstration of calcifications in the right upper quadrant/pneumobilia, especially when showing dilated or debris-filled bile ducts, should suggest inclusion of biliary sump syndrome in the differential diagnosis. Upper gastrointestinal fluoroscopic

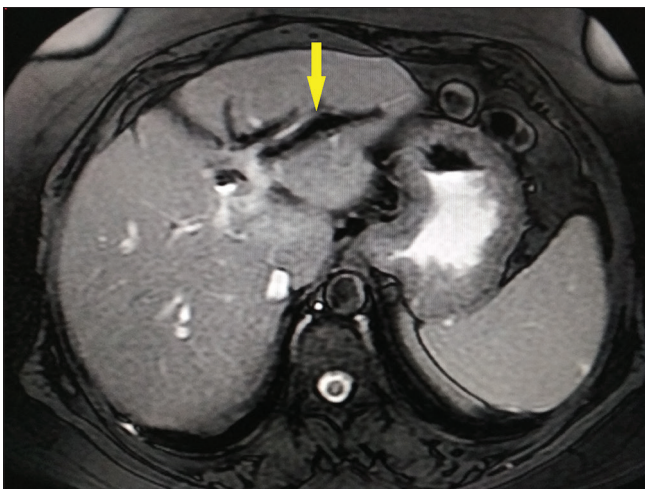


Figure 1: Axial 2D FIESTA MR image demonstrating pneumobilia (arrow) in a 40-year-old female patient who underwent side-to-side choledochoduodenostomy

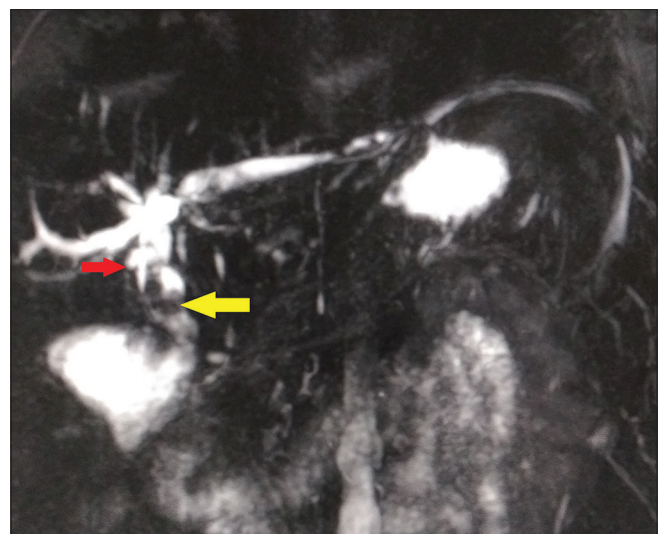


Figure 2: Coronal 3D magnetic resonance cholangiopancreatography image demonstrating debris and fluid in the distal CBD (yellow arrow) and the anastomosis between mid CBD and duodenum (red arrow) in a patient with sump syndrome

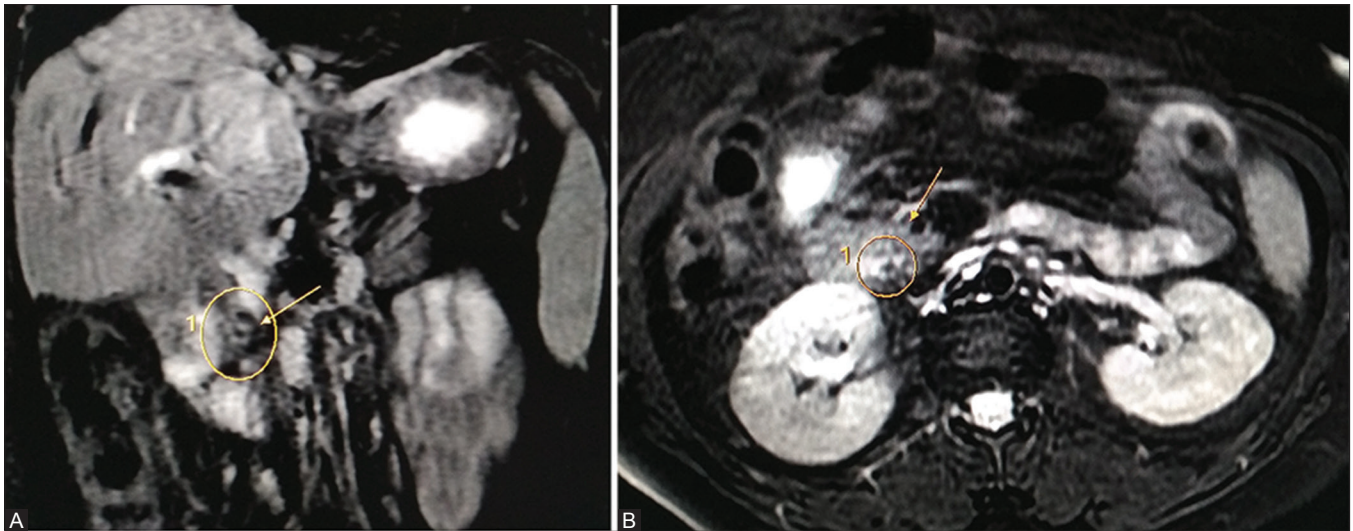


Figure 3 (A and B): Coronal (A) and axial (B) T2 weighted images demonstrating hypointense filling defect (arrow) with no demonstrable fluid level in the distal CBD suggesting sludge

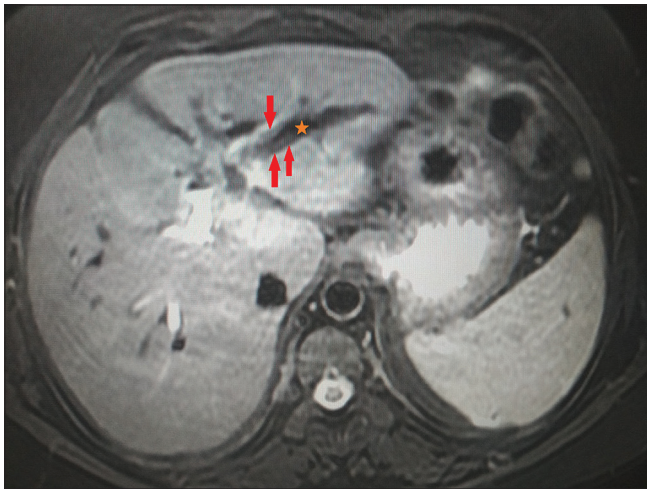


Figure 4: Axial T2-weighted image demonstrating central hypointensity involving left lobe of liver suggesting pneumobilia (star) with irregular wall thickening and ragged margins of the left hepatic duct (arrows). The findings were consistent with ascending cholangitis on MRI

studies may demonstrate reflux of contrast into the biliary tree through a patent anastomosis of the CDD outlining the CBD and intrahepatic biliary tree. Ultrasound may reveal findings of pneumobilia, biliary duct dilatation, biliary stones, cholangitis, pancreatitis, or liver abscess. CT may demonstrate pneumobilia. However, debris or stones in the distal CBD are the most frequent and most indicative CT findings of sump syndrome.^[5] ERCP or percutaneous transhepatic cholangiography (PTC) is necessary for confirming diagnosis of sump syndrome. Enhancement of biliary tree in the form of ERCP or PTC is necessary for the diagnosis of sump syndrome. Dilatation of distal CBD with sludge/debris in a case of biliary-enteric anastomosis should prompt the diagnosis of sump syndrome, especially

in settings where ERCP is not available to avoid delay in management. In conclusion, the diagnosis of sump syndrome is challenging as little is known about CDD and its complications.

Declaration of patient consent

The authors certify that they have obtained all appropriate patient consent forms. In the form the patient(s) has/have given his/her/their consent for his/her/their images and other clinical information to be reported in the journal. The patients understand that their names and initials will not be published and due efforts will be made to conceal their identity, but anonymity cannot be guaranteed.

Financial support and sponsorship

Nil.

Conflicts of interest

There are no conflicts of interest.

Reddy Ravikanth, Kanagasabai Kamalasekar

Department of Radiology, Holy Family Hospital,
Thodupuzha, Kerala, India.
E-mail: ravikanthreddy06@gmail.com

References

- Demirel BT, Kekilli M, Onal IK, Parlak E, Disibeyaz S, Kacar S, *et al.* ERCP experience in patients with choledochoduodenostomy: Diagnostic findings and therapeutic management. *Surg Endosc* 2011;25:1043-7.
- Marbet UA, Stalder GA, Faust H, Harder F, Gyr K. Endoscopic sphincterotomy and surgical approaches in the treatment of the "sump syndrome." *Gut* 1987;28:142-5.
- Hawes DR, Pelsang RE, Janda RC, Lu CC. Imaging of the biliary sump syndrome. *AJR Am J Roentgenol* 1992;158:315-9.

4. Hallstone A, Triadafilopoulos G. "Spontaneous sump syndrome": Successful treatment by duodenoscopic sphincterotomy. *Am J Gastroenterol* 1990;85:1518.
5. Abraham H, Thomas S, Srivastava A. Sump syndrome: A rare long-term complication of choledochoduodenostomy. *Case Rep Gastroenterol* 2017;11:428-33.

This is an open access journal, and articles are distributed under the terms of the Creative Commons Attribution-NonCommercial-ShareAlike 4.0 License, which allows others to remix, tweak, and build upon the work non-commercially, as long as appropriate credit is given and the new creations are licensed under the identical terms.

Access this article online	
Quick Response Code:	Website: www.ijri.org
	DOI: 10.4103/ijri.IJRI_427_18

Cite this article as: Ravikanth R, Kamalasekar K. Imaging in sump syndrome: A rare complication of choledochoduodenostomy. *Indian J Radiol Imaging* 2019;29:229-31.

© 2019 Indian Journal of Radiology and Imaging | Published by Wolters Kluwer - Medknow