

3

Unilateral Cleft Lip

H. S. Adenwalla, P. V. Narayanan, and Karoon Agrawal

- **Introduction**
- **Anatomical Landmarks of the Lip and Nose**
 - Lip
 - Nose
- **Embryology of the Lip and Nose**
- **Surgical Anatomy of the Lip and Nose**
 - Lip
 - Nose
- **Evaluation of the Cleft and the Nature of the Deformity**
- **History and Evolution**
 - **Early Techniques**
 - **Straight Repair**
 - **Mirault Technique**
 - **Le Mesurier Procedure**
 - **Millard's Rotation Advancement Procedure**
 - ◇ Principles
 - ◇ Advantages
 - ◇ C Flap
 - **Triangular Flap Repair of Tennison**
 - ◇ Principle
 - ◇ Advantages
 - ◇ Disadvantages
 - **Triple Wedge Technique**
 - ◇ Advantage
- **Principles of Cleft Lip Repair**
- **Goals of Treatment**
 - **Goals of Unilateral Cleft Lip Surgery**
- **Timing and Protocol**
- **Lip Adhesion**
 - **Advantages**
 - **Disadvantages**
- **Lip Repair Techniques**
 - **Millard's Rotation Advancement Technique**
 - ◇ Markings
 - ◇ Infiltrations
 - ◇ Incisions
 - ◇ The Millard "M" and "L" Flaps
 - ◇ C Flap
 - ◇ Turbinate Flap (T Flap)
 - ◇ Rotation Flap
 - ◇ Advancement Flap
 - ◇ Lateral Mobilization
 - **Primary Nasal Correction**
 - ◇ Primary Alar Cartilage Dissection
 - ◇ Primary Septal Repositioning
 - ◇ Columella
 - ◇ Closure of the Anterior (Hard) Palate at the Time of Cleft Lip Repair
 - ◇ Closure of Lip
 - ◇ Postoperative Care
- **Randall-Tennison-Sawhney Triangular Flap Technique of Unilateral Cleft Lip Repair**
 - **Marking**
 - ◇ Markings on the Medial Element of Lip
 - ◇ Markings on the Lateral Element of the Lip
 - **Incisions**
 - **Anterior Palate Repair**

- **Approximation and Suturing of Lip**
- **Ancillary Procedures**
- **Role of Nasal Conformers**
- **Primary Gingivoperiosteoplasty Technique**
- **Partial Cleft Lip**
- **Microform Cleft Lip**
- **Late Presentations**
- **Prevention of Deformities**
- **Unsolved Problems**
- **Mohler's Modification of Millard's Procedure**
- **Noordhoff-Chen Technique**
- **Fisher's Anatomic Subunit Repair**
- **The Pfeiffer and Afroze Incisions**
- **Secondary Deformities**
 - **Secondary Deformities of the Lip**
 - **Nasal Deformities**
 - **Timing of Secondary Repair**
- **Conclusion**

Introduction

It was Werner Hagedorn who said, "Great things are done when art and science meet." What better example than the repair of a cleft lip where art meets science to forge a formidable weapon for the benefit of mankind. This half art, half science stimulates the mind, challenges the dexterity of the hand and at the same time pulls at your heartstrings. The unilateral cleft lip in its many varying manifestations of shape, size and asymmetry is a complex deformity. To obtain consistent results, one requires a sound basic training in soft tissue handling, a proper understanding of the bony foundation of the face, a knowledge of the muscles of the lip, followed by experience and a fair amount of dexterity and craftsmanship. A cleft surgeon must build his house on rock. Many of us forget in our enthusiasm that behind the complex play of muscles and soft tissues, there lies the bony structure of the face. Great artists like Leonardo da Vinci realized this before we surgeons did and it was Kazanjian who told us that the so-called pretty face without a good bony structure disappears like the mist with the first flush of youth. This chapter deals with the reconstruction of the soft tissues of the lip and therefore, the readers must realize that in itself it is incomplete.

Anatomical Landmarks of the Lip and Nose

Lip

- Philtral ridges or columns are raised areas ascending from the height of the peak of the Cupid's bow point on each side toward the base of the columella. Their configuration varies in different people (**Fig. 3.1**). Type I shows divergence of the column at the base of the columella. Type II shows convergence at the base of the columella.

Type III shows convergence anywhere below the base of the columella.¹

- Cupid's bow is the most striking aspect of the upper lip. Located at its center, it is a V-shaped bow, with an apex at the midline and high points (peaks) on either side.
- White roll is a rolled-up area of skin 1 to 2 mm in height, and it extends from one oral commissure to the other in normal persons.
- Vermillion is the portion of the lip below the white roll. It is made up of a superior dry area and inferior wet area of mucosa. There is a red line at the junction of these two areas.

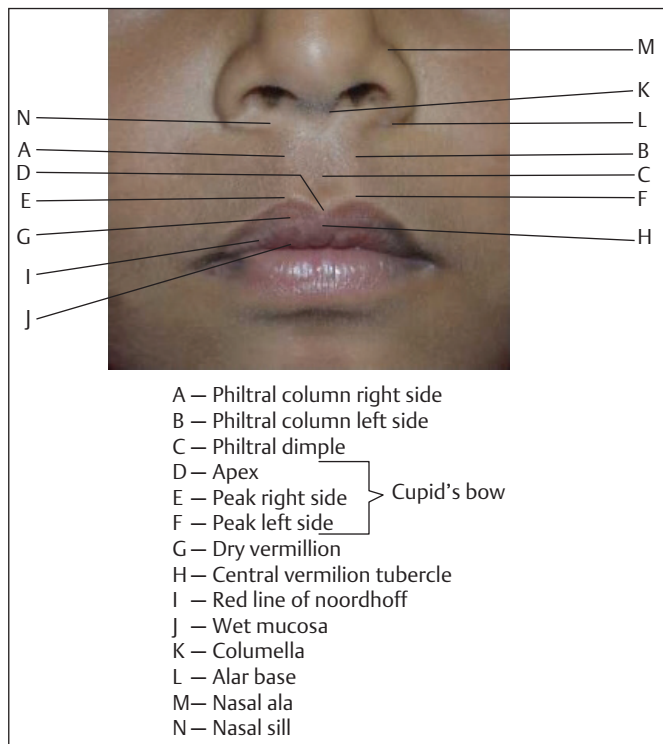


Fig. 3.1 Anatomical landmarks of the lip and nose.

Nose

- Columella is the central column extending from the base to the nasal tip in the midline.
- Nasal sill is the raised fold on either side extending from the lateral part of the columella to the alar base.
- Alar bases are at the lateral most part of the nose.
- The two ala arch symmetrically on each side from the nasal tip.

Embryology of the Lip and Nose

Toward the end of the first week of gestation, facial prominences formed principally by the first pharyngeal arches appear. Lateral to the stomodaeum, the maxillary prominences appear and caudal to this the mandibular prominences are formed. The frontonasal prominence forms on the upper border of the stomodaeum. Nasal placodes are ectodermal thickenings formed on either side of the frontonasal prominence. These placodes deepen into nasal pits with medial and lateral nasal prominences formed on either side of the pits by the fifth week on each side. The maxillary prominence fuses with the medial nasal prominence of that side, forming the upper lip by the seventh week. The lateral nasal prominences have no contribution to the formation of upper lip. The medial nasal prominences of the two sides form the philtrum and Cupid's bow. Failure of fusion of the medial nasal prominence with the maxillary prominence on one side results in a unilateral cleft lip²; and failure of fusion on both sides will end in a bilateral cleft lip.

In the nose, the bridge is formed by the frontal prominence, the tip is formed by the fused medial nasal prominences and the ala is formed on each side from the lateral nasal prominence.

For further details, please refer to Chapter 13 on Development of the Craniofacial Complex, Anatomy, and Congenital Anomalies in Volume III.

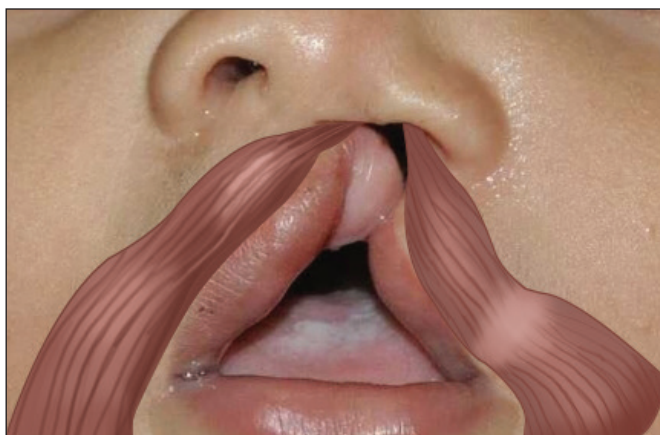

Fig. 3.2 Orbicularis oris.

Surgical Anatomy of the Lip and Nose

Lip

The orbicularis oris muscle has a superficial part originating from bone (maxilla, mandible, and also the nasal septum) and a deep part arising from the facial muscles like the buccinator. In an incomplete unilateral cleft lip, the muscle fibers cross across the lip if there is at least half of the lip that is not cleft. In more severe cases, there is no crossover of the muscle bundles.

In complete cleft lips, the muscle ascends along the cleft margin to the base of the ala laterally.³ These abnormal attachments must be released during the lip repair. Medially, the fibers ascend along the cleft margin to the base of the columella (**Fig. 3.2**). These muscle fibers are arranged in a disorganized manner. For further detail, refer to Chapter 1 on Cleft Lip and Palate: An Anatomical and Physiological Overview in Volume III.

Release of these improper attachments of the muscle and the union of the muscle with its counterpart on the other side of the cleft forms an important aspect of cleft lip repair.

Nose

The hemi columella is shorter on the cleft side as compared to the noncleft side (**Fig. 3.3**). The ala on the cleft side is depressed and buckled. There is a flare of the ala which manifests as a wide nostril. The medial crura on the cleft side is placed at a lower level.

The anterior nasal spine is displaced toward the noncleft side and the nasal septal cartilage is also deviated to the noncleft side anteriorly. Huffmann and Lierle⁴ have extensively described the cleft lip nasal stigmata. For further detail, refer to Chapter 1 on Cleft Lip and Palate: An Anatomical and Physiological Overview in Volume III.

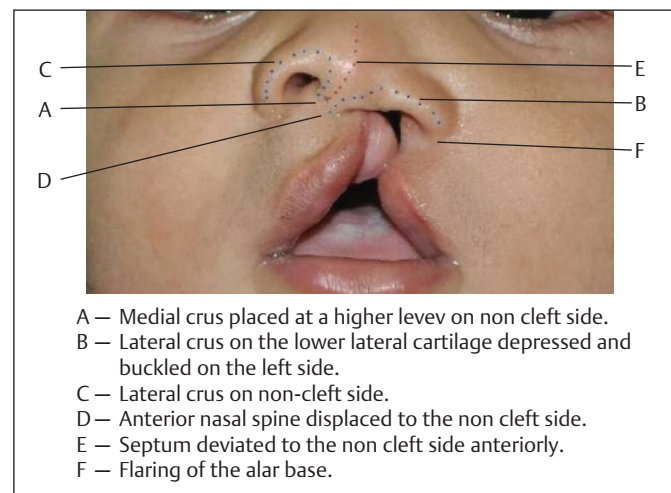


Fig. 3.3 Surgical anatomy of the lip and nose.

Evaluation of the Cleft and the Nature of the Deformity

- The child is carefully evaluated to determine the nature of the cleft whether unilateral or bilateral (**Box 3.1**). Some children with unilateral cleft may have a barely discernible microform cleft of the other side. These may become more pronounced after the repair of the complete cleft. Hence, it is important to identify and also counsel the parents about this (**Fig. 3.4a–c**). The microform clefts are usually repaired at a separate sitting.
- The extent of the cleft is also determined: partial or complete. The involvement of the alveolar bone on the cleft needs to be identified. Sometimes, even though

Box 3.1 Evaluation of a patient of cleft lip

- Side: Right/left/midline/bilateral
- Degree of cleft: Complete/partial/microform
- Width of cleft: Narrow/moderate/wide
- Simonart's band: Present/absent
- Alveolar cleft: Complete/ partial
- Width of alveolar gap
- Presence of cleft palate—If so, details of the cleft palate
- Position of minor and major maxillary segments
- Dentition: Presence/quality/malrotation/caries/palatal
- Nature and degree of nasal deformity
 - Width of nostril
 - Orientation of nostril opening
 - Position of columella
 - Nasal tip
 - Nasal ala
 - Soft triangle
 - Alar webbing
 - Nasal septum
 - Nasal dorsum

the soft tissue deformity is only a partial one, not involving the nasal sill or floor, the alveolus may be grooved. One has to decide on the need for mobilization of the lateral elements in these patients. There may be a bridge of skin between the two sides of the cleft lip. This is known as a Simonart's band (**Fig. 3.5**). Its presence reduces the severity of the deformity and aids in better alignment of the bony segments, thus acting like an orthodontic appliance⁵ and this band was further used by Millard in the repair.

- In patients with gross disparity between the levels of the medial and lateral maxillary segments, there can be significant deficiency of the lateral vermilion height. These, if identified early, are referred for presurgical orthodontics to get the alveolar segments in better alignment. This almost eliminates this deficiency. For details on presurgical orthodontics in cleft lip and palate, please refer to Chapter 6 on Orthodontic Management of Cleft Lip and Palate in Volume III.
- The nature of the nasal deformity and the width of the nostril on the cleft side are also to be assessed preoperatively. When there is a significant nasal blemish, even if the cleft is a partial one, one needs to perform primary alar correction at least. Otherwise these children could go on to develop significant nasal stigmata of the cleft lip and it could be much more difficult to correct later.
- The alveolar disparity mentioned also has a bearing on the outcome with reference to the appearance of the nose. Children with wide clefts and gross alveolar disparity would certainly do well with presurgical orthodontics in the form of nasoalveolar molding or the Latham's device. However, if it is too late for preoperative orthopedics or when the alveolus segments still show disparity despite the presurgical orthodontics, one would have to incorporate additional refinements during the surgical procedure to circumvent this problem.

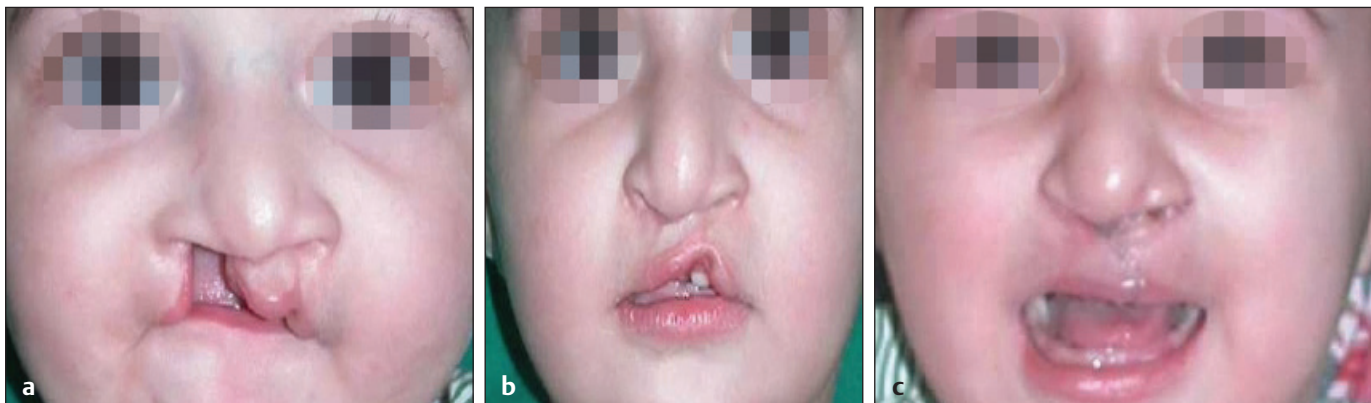


Fig. 3.4 (a) Child with complete cleft lip on the right side and microform cleft lip on the left. (b) After the repair of the complete cleft lip, the microform cleft lip is seen to become more prominent. (c) After correction of the microform cleft lip on left side.

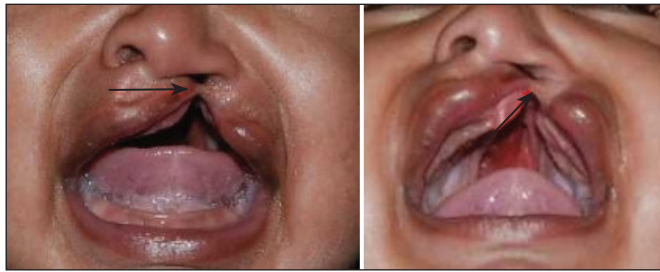


Fig. 3.5 Child with Simonart's band.

History and Evolution

Early Techniques

One does not really know by whom and when the first cleft lip was repaired. Many believe that a Roman physician Aurelius Cornelius Celsus was the first to repair a cleft lip in the first century AD.⁶ KhooBhoo-Chai of Singapore believes that the first lip repair was performed by a Chinese Surgeon Fang Kan in the third century AD. The name of the patient was Wai Yang-chi, a Chinese peasant who later rose to high office during the Tang Dynasty. Udwardia⁷ in his opus magnum "Man and Medicine" believes that Sushruta or perhaps one of his pupils repaired the first cleft lip two centuries before Christ. It is quite possible that this is perhaps the first recorded cleft lip repair as it is mentioned in the Sushruta Samhita. These Indian Ayurvedic surgeons were also responsible for describing the median forehead flap and the cheek flap for nasal reconstructions. Sushruta cauterized the edges to make them raw and then sutured them together. The famous Arabian surgeon Albucasis in 1000AD used Sushruta's method. In the year 950 AD, the Saxon surgeons of Britain known as "the leeches" described their method in the "Leech Book of Bald."

Europe came into the picture much later in the sixth century AD when Pierre Franco and the famous Ambroise Pare gained prominence for their work on cleft lip repair.

Straight Repair

Our contemporary knowledge of cleft lip repair began in the mid-nineteenth century with the work of William Rose of London and James Thompson of Northwick (**Fig. 3.6**). The Oxford School of Kilner and Peet modified and

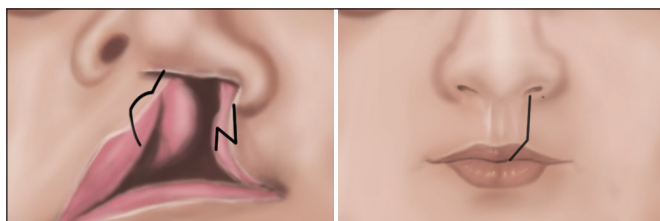


Fig. 3.6 Straight repair.

popularized this method and called it "the Oxford modification of the straight repair." The names of Charles Mayo, William Ladd, Victor Veau, and Alexander Limberg gained prominence in this field of surgery and each of them had monumental contributions to make.⁸

Mirault Technique

Surgeons began to see the flaw in the popular pairing method. Joseph Malgaigne of the University of Paris designed a two-flap operation which overcame the contracture that took place with the straight repair.⁹

As Millard says in his Cleft Craft Vol.I⁹ "Mirault also of Paris immediately saw its value and a flaw." He wrote to Malgaigne suggesting the use of only one horizontal incision, thus came in to existence the famed triangular flap of which there are today many modifications brought about by Vilray Papin Blair, James Barrett Brown, and later Frank McDowell (**Fig. 3.7**).

Le Mesurier Procedure

A different school opened up with the work of Werner Hagedorn who at the age of 53 evolved a new design different from the Mirault. He designed a quadrilateral flap which was modified and popularized by a pediatric surgeon, Le Mesurier at the Toronto Hospital for sick children in Canada¹⁰ (**Fig. 3.8**).

Millard's Rotation Advancement Procedure

Millard trained by Sir Harold Gillies and Kilner and later by James Barrett Brown and Straith broke upon the cleft horizon like a thunderbolt. He enunciated and popularized his rotational advancement technique during the Korean War and it caught the imagination of the world by his logical thought sequence (**Fig. 3.9**).¹¹⁻¹³

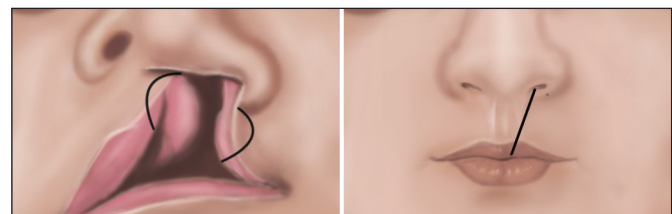


Fig. 3.7 Mirault technique.

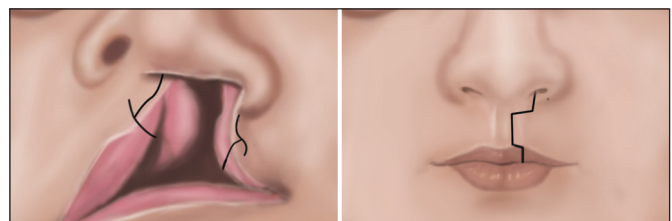


Fig. 3.8 Le Mesurier procedure.

Principles

Millard said that three quarters of the Cupid’s bow is there but riding high, what better way of bringing it down than by a rotational flap on the noncleft side. No rotational flap is complete without a backcut. The defect thus created in the upper part of the lip is filled by an advancement flap from the cleft side (Fig. 3.10a, b).¹⁴

Advantages

Unlike the triangular and quadrilateral flaps, the main flap is taken from the rich noncleft side, and the advancement flap pulls in the nostril flare. The suture line imitates the philtral line on the noncleft side and does not transgress a Langer’s line. This was a masterstroke of logical thinking put into execution by a master craftsman. The Millard procedure with some variations holds center stage in cleft lip surgery today. It was brought to the Charles Pinto Centre by Prof. Charles Pinto (Charles Pinto—Personal communication with

the senior author) after it was demonstrated in Poona by Sir Harold Gillies on one of his visits to India.

C Flap

The skin flap that results following the rotation and the paring incisions resembles the letter ‘C’ and has been called the C flap by Millard.¹² Its evolution is interesting. Millard originally used it to augment the nasal sill laterally. However, later he modified his technique and used it for cleft side hemicolumella, as he felt that all unilateral cleft patients had a cleft side hemicolumella that was shorter than that of the noncleft side.

The first technique of using it for the nasal sill has been termed “Millard I” (Fig. 3.11) and its use for the hemicolumella as “Millard II.” Millard himself in a personal communication with the senior author mentioned that the Millard I was as an obsolete operation and that the C flap must always be used for lengthening the columella (Millard II) (Fig. 3.12).

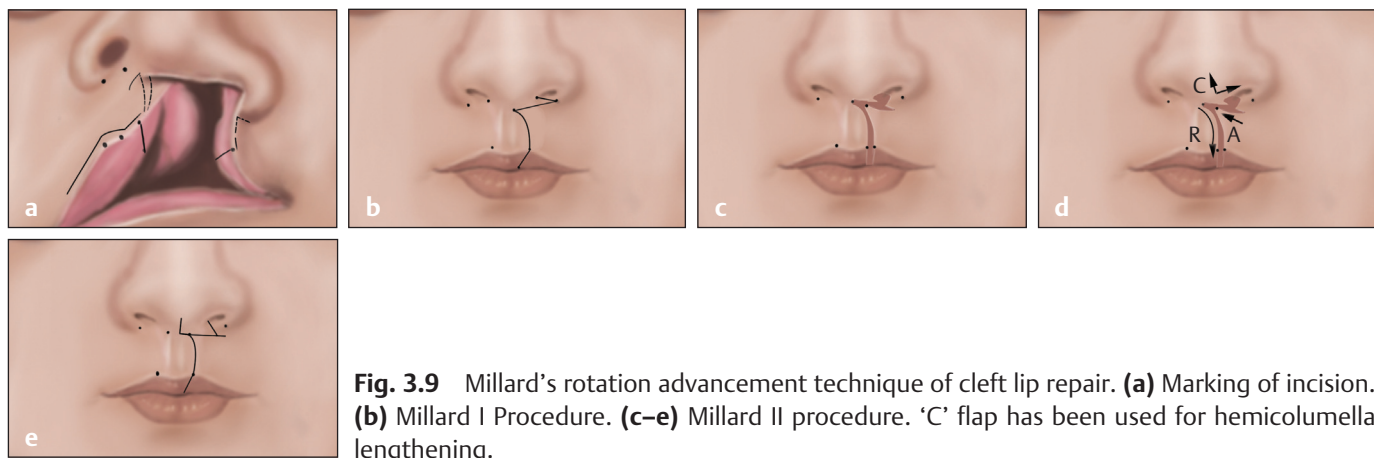


Fig. 3.9 Millard’s rotation advancement technique of cleft lip repair. (a) Marking of incision. (b) Millard I Procedure. (c–e) Millard II procedure. ‘C’ flap has been used for hemicolumella lengthening.

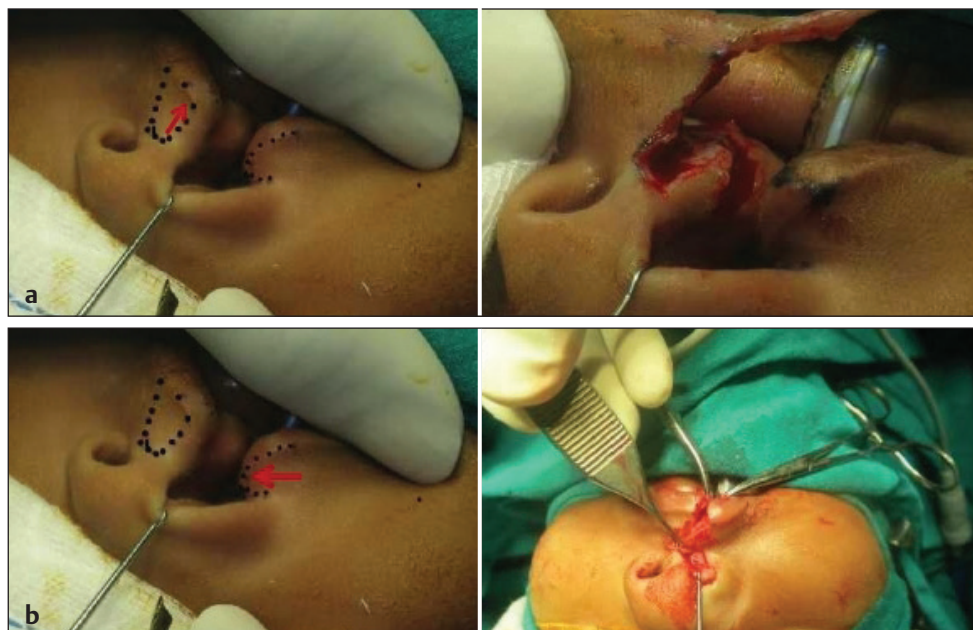


Fig. 3.10 Principle of the Millard procedure. (a) Rotation and (b) advancement.

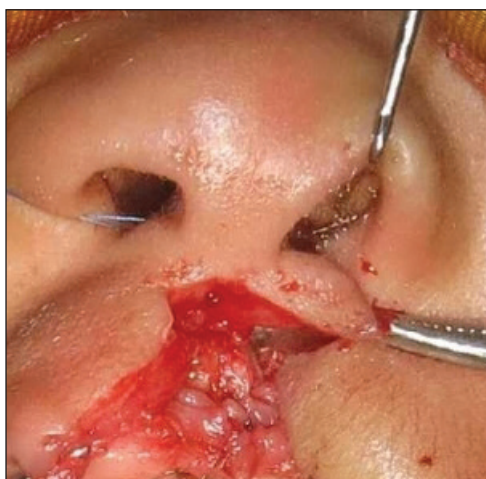

Fig. 3.11 Millard I: C flap used for the nasal sill.

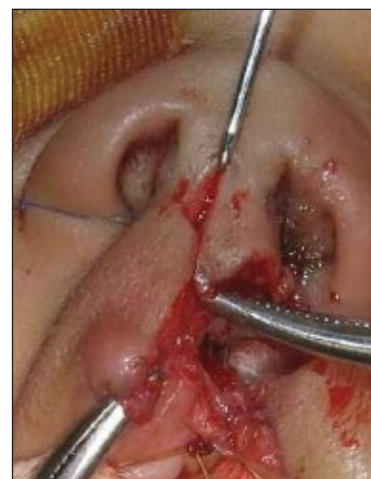


Fig. 3.12 Millard II: C flap used for the hemicolumella.

Triangular Flap Repair of Tennison

Tennison in 1952 described technique for unilateral cleft lip; wherein he applied the principles of transferring tissue from lateral element to medial side in the form of a Z plasty.¹⁵ Care was taken to recreate the natural features of the lip, especially a balanced Cupid's bow. A wedge was inserted from lateral lip into the lower part of medial lip. Muscle approximation and pouting of lower lip were given special attention. Tennison called it "stencil method." Randall¹⁶ applied geometrical principles to this repair by adding measurements and effectively reduced the size of the triangle. Sawhney¹⁷ from Chandigarh India described the geometry of triangular flap technique with great precision.

Principle

A backcut in the form of a transverse incision is placed immediately above the Cupid's bow point to the midline on the cleft side on the medial lip element to bring it down to the level of its counterpart on the noncleft side. This produces a triangular defect that is closed by raising a geometrically designed perfect isosceles triangular flap from the lateral lip element. The base of triangle is the height by which the cleft side is shorter and the sides of the triangle are equal to the length of the horizontal backcut.¹⁵

Advantages

Since the measurements are done to perfection at the beginning, there is no need to change the incision line. This is an easier technique to master than the Millard procedure. It is easy to bring down the Cupid's bow as the transverse incision is lower down on the body of the lip. Postoperative scar contraction and secondary deformity are minimal as the triangular flap breaks the straight line scar.

Disadvantages

This is a geometrical technique and has its learning curve. The main disadvantage of this procedure is the visible transverse scar on the lower part of the lip, where it is visible as it transgresses the philtral column. Nasal correction has been said to be more difficult as there is no ready access. Revision lip surgery, if required later, is also more difficult with this technique. However, surgeons performing Sawhney's procedure have evolved refinements to address these issues. Sawhney further modified the triangular flap to mathematical precision. He suggested to limit the backcut to the midline as the anatomical abnormality exists only on the side of cleft and the noncleft side is essentially normal.¹⁷ The triangular method is used to this day by many surgeons in India with considerable effect.

Triple Wedge Technique

C. Balakrishnan of Nagpur, and later, Chandigarh, devised a Triple wedge technique, a form of multiple triangular flaps repair that was evolved independently of the triangular flap technique. Unfortunately, Balakrishnan did not publish his work. Even today many of his trainees use the triple wedge technique of lip repair.¹⁸ This is an original technique developed independently. This consisted of three wedges one at the alar base, one above the vermilion, and one at the vermilion (**Fig. 3.13**).

Advantage

The advantage is the ease of planning and execution. The triangles are small, hence the scar transgressing the philtral column is not obvious and has the advantage of avoiding a straight line scar preventing secondary contraction

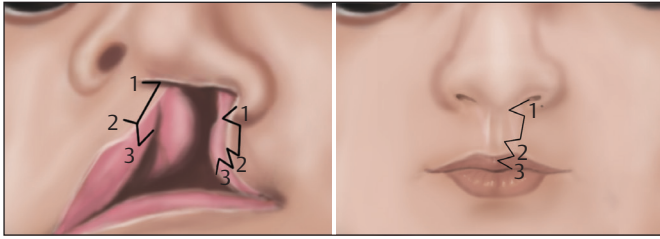


Fig. 3.13 Triple wedge technique of C. Balakrishnan.
1. Wedge at the nostril base. 2. Wedge above the vermilion.
3. Wedge in vermilion

Principles of Cleft Lip Repair

Steffensen, 1953¹⁹

- Achieving accurate skin, muscle, and mucous membrane union.
- Reconstruction of symmetrical nostril floor.
- Symmetrical vermilion border.
- Slight eversion of the lip.
- Minimal scar whose contractions will not jeopardize the remaining objectives mentioned.

Musgrave and Garrett also emphasize preservation of the symmetrical Cupid's bow and vermilion cutaneous ridge.¹⁹

Goals of Treatment

The ultimate aim in the repair of a unilateral cleft lip is to create a functional and aesthetically acceptable lip looking as close to normal as is humanly possible.

Goals of Unilateral Cleft Lip Surgery

- The Cupid's bow, the most visible part of the lip, should be symmetrical with the apices of the bow at the same level on both sides.
- The vermilion should be full without a notch and the color of the reconstructed vermilion and mucosa should match.
- The scar line should be hidden in the natural skin creases a mirror image of the philtral line on the noncleft side. There should be a natural looking philtral dimple.
- A central tubercle on the lip should be produced.
- Repair of orbicularis oris muscle in proper alignment.
- Reconstruction of a fistula free nostril floor and anterior palate.
- The nose should be symmetrical with equal halves of the columella, alar rims at the same level, no flare

or groove on the nose, alar bases at the same level, creating a nostril sill, no soft triangle droop, and a midline septum.

To put it simply, a repaired lip should pass off as a normal one.

Timing and Protocol

Various protocols have been used around the world.

At the Chang Gung Craniofacial center, presurgical orthodontics is done using nasoalveolar moulding (NAM) at 1 to 6 weeks, lip repair is done using modified Millard's procedure at 3 to 4 months, and alveolar bone graft is done at 7 to 9 years followed by orthodontics. The patient is evaluated for orthognathic surgery at 17 years.²⁰

In the Euro cleft study,²¹ five centers were included. Of these, three used presurgical orthodontics. Lip repair was performed at 3 months in two centers, 3 to 5 months in two centers, at 5 months in one center. One center alone performed primary bone graft at 5 months. The rest resorted to alveolar bone graft at 8 to 11 years.

The Ameri Cleft Project included six centers.²² Half of them used presurgical orthopedics. The timing of lip repair varied between 6 weeks and 6 months. One center used primary bone grafting at 6 to 9 months. Secondary bone graft was done at 6 years to 11 years.

Other protocols have been tailored to the compliance of patients. Thus, Agrawal K resorted to cleft palate repair at 6 to 9 months, and then the cleft lip repair at 3 to 6 months later.²³ The parents failed to bring the children for palate repair once the lip repair was done as the external deformity was corrected. This is true in many developing nations.

The timing of cleft lip surgery varies between various centers. There are centers even in India that perform cleft lip repair in the immediate neonatal period. This is done with two intentions. One is that the fetal growth factor favors almost scarless healing. However, these are very rapidly replaced by the adult growth factor and hence unless the lip surgery is performed in the first few days after birth, this benefit will not be availed.

The other reason put forth favoring early neonatal repair is that when the mother is presented with a baby with a repaired cleft, bonding is better between the mother and child. However, we find this difficult to accept, as we have seen the most intense bonding between mothers of children with grotesque deformities and their babies.

Many centers today perform cleft lip repair at 3 months. Most of the children in developing nations attain the optimal weight of 10 lbs or 5 to 6 kg only by then. Hence, the authors believe that it is safer to operate at this age. Also, the increased bulk of the lip tissue enables easier repair (**Table 3.1**).

Table 3.1 Authors' preferred protocol

Soon after birth	First counseling and nasoalveolar moulding (NAM) if appropriate. Pediatric consultation to rule out other anomalies and general assessment
1 month after birth	Counseling, reinforced; nutritional status assessed
6 months	Cleft lip repair
11 months to 1 year	Cleft palate repair
3 years onward	Speech assessment and therapy by speech pathologist
5 ½ years to 6 years (preschool age)	Open rhinoplasty if indicated
6–7 years	Nasoendoscopy and if velopharyngeal incompetence (VPI) present, surgical corrections to be done after errors correctable by speech therapy are corrected
7 years	Alveolar bone graft if indicated
>14 years in girls >16 years in males	Secondary rhinoplasty if indicated
>16 years in girls >18 years in males	Orthognathic surgery if indicated

Lip Adhesion

This was widely practiced prior to the development of presurgical orthodontics. When the cleft of the primary palate is wide with gross alveolar disparity, lip adhesion was widely used to narrow the cleft and to bring the alveolar segment in better alignment. Johansson is credited with performing the first lip adhesion. It was routinely followed by Millard. The technique of lip adhesion used varies from a mere paring along the mucocutaneous edges and turning the mucosa over and closure in three layers, to a nasolabial adhesion as practiced by Chen et al²⁰ using a mucosal C flap, buccal mucosal flap, and an inferior turbinate flap.

Advantages

The benefits of lip adhesion are that the wide cleft is narrowed, bringing the bony segment in better alignment.

Disadvantages

The negative aspects of the procedure are many and include additional surgery and anesthesia, scarring as a result of the first procedure, with the need for excising the scar tissue during definitive repair. There is at present no evidence to indicate that lip adhesion improves the outcome in terms of the lip or the nose.

Lip Repair Techniques

The two most widely practiced unilateral cleft lip repair techniques namely Millard's Rotation-Advancement Technique and Tennison's Triangular Flap Technique are described in detail.

Millard's Rotation Advancement Technique

This is the most commonly used method of repair of the unilateral cleft lip and is also the technique that has been followed at the authors' center for the past five decades and we shall describe this technique in detail along with certain refinements that have been incorporated in to this technique by the senior author to overcome some shortcomings with the original repair.

Markings

We make our skin markings with a marker pen using Bonney's Blue (**Fig. 3.9**). The most vital points on the Cupid's bow on either side of the cleft are tattooed with a needle. The important landmarks that are marked are:

- The apex of the Cupid's bow.
- The high point of the Cupid's bow on the noncleft side.
- The distance between the above two points is measured using calipers and a point just short of this length is measured and marked from the apex of the Cupid's bow on the mucocutaneous junction toward the cleft. This is the corresponding Cupid's bow point. This is tattooed (**Fig. 3.14**).
- A lateral point is marked on the cleft side at the mucocutaneous junction and this is the point that is to be sutured to the Cupid's bow point that has been tattooed on the medial side of the cleft. This lateral point is often not easy to mark. There are at least four ways of arriving at this point:
 - By using the distance on the philtral column from the peak of the Cupid's bow on the noncleft side to the base of the columella (**Fig. 3.15a**).
 - By measuring the distance from the peak of the Cupid's bow on the noncleft side to the ipsilateral alar base (**Fig. 3.15b**).

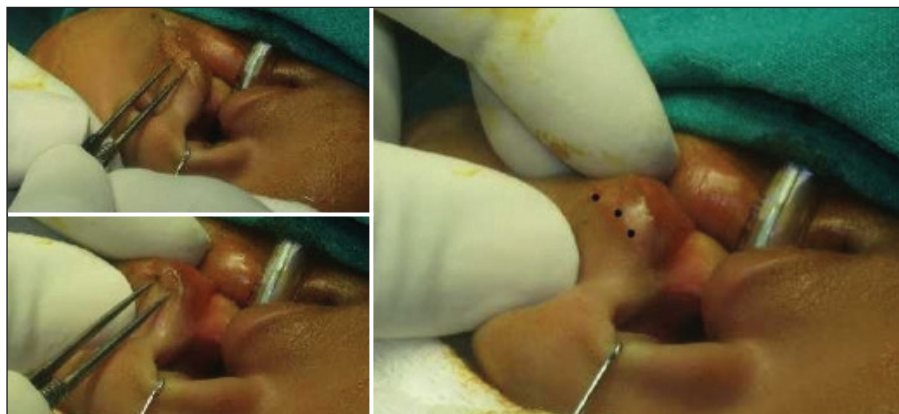

Fig. 3.14 The distance between apex of the Cupid's bow and the peak on the noncleft side is measured using calipers and a point just short of this length is measured and marked from the apex of the Cupid's bow on the mucocutaneous junction toward the cleft.

- By measuring the height of the dry mucosa from the peak of the Cupid's bow on the noncleft side to the red line of Noordhoff (widest part of the dry mucosa) (**Fig. 3.15c**).
- The distance from the oral commissure to the peak of the Cupid's bow on the noncleft side (**Fig. 3.15d**).

These measurements are extrapolated onto the cleft side at the lateral point as shown in the figure.

The lateral point has also been mentioned as the point where the lip begins to thin or the white roll begins to fade off.

Thus, the very fact that there are so many different ways of marking this point amply attests to the fact that this is often an ambiguous point and that none of the methods are accurate all the time. The measurement of the height of the dry mucosa³ and the distance from the oral commissure⁴ are the more popular methods used. Very often one needs to use one's experience in judging the point and should not go by measurements alone. This point is also tattooed.

Infiltrations

Adrenaline in Saline 1: 200,000 solution is infiltrated subperiosteally over the buccal surfaces and also under the mucoperichondrium of the septum and under the mucoperiosteum of the lateral shelf of the maxilla. Some surgeons also infiltrate into the lip tissue itself. But the authors avoid it as it is felt that it may distort the lip anatomy.

Incisions

The cleft edges are pared, using Beaver No. 67 mini blade for the skin and No. 65 for the through and through incisions.

Prior to making the rotation incision, we always divide the frenum of the lip. The attachment of the frenum tethers the lip and only after it is released can one accurately judge the extent of rotation required.

The Millard "M" and "L" Flaps

During the paring of the mucosa, Millard originally left the mucosal attachments to the alveolar ridges both medially and laterally, thus producing the "M" (medial) and "L" (lateral) flaps. These have been used to assist in the closure

of the alveolar cleft (M flap) and laterally to assist in the closure of the nasal floor (L flap). These are still used by many surgeons today. However, Millard himself gave up the use of these later in his career. The authors also do not use these flaps.²⁴

C Flap

The evolution of the flap has been mentioned earlier. The authors always use it for the columella.

Turbinate Flap (T Flap)

The mucosal lining of the inferior turbinate has been used in the reconstruction of the nasal floor. A superiorly based rectangular flap is marked and raised and used for the nasal layer closure. It aids in avoiding excess narrowing of the nostril.²⁰

Rotation Flap

The tattooed Cupid's bow point forms the starting point of the rotation incision. This ascends up to the base of the columella with a gentle convexity facing the cleft. It hugs the base of the columella for about two-thirds of its distance and ends with a backcut that is made perpendicular to the incisions. This backcut should stop short of the noncleft side philtral column. If not, it will lengthen the noncleft side as well and the discrepancy in the heights of the sides of the philtral column will persist, resulting in a high-riding Cupid's bow on the cleft side.

The backcut is necessary to bring about adequate rotation in all complete cleft lips. There is a tendency by many of the present-day surgeons to avoid the backcut due to a fear of scarring at the base of the columella. However, the authors believe, as did Millard, that it is necessary in all patients to bring about adequate rotation. Failure to bring about adequate rotation would lead one to use transverse incisions just above the white roll and these would be against Langer's lines and would lead to unacceptable scarring lower down in the lip where it would be visible.

The skin and the mucosa are undermined to release the false attachments of the orbicularis oris muscle. Paring of the vermillion is then undertaken at the tattooed point

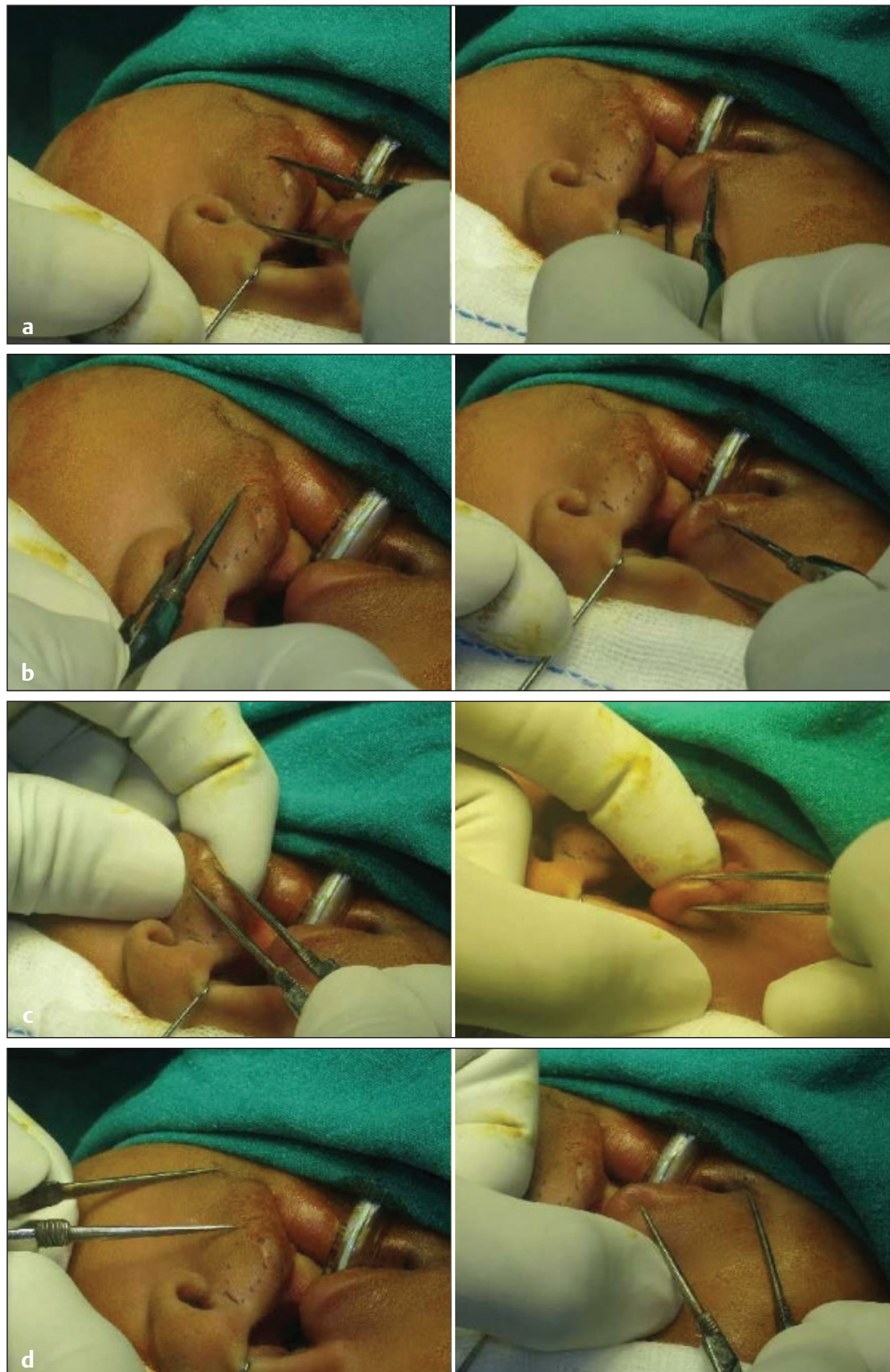

Fig. 3.15 (a) Using the distance on the philtral column from the peak of the cupid's bow on the noncleft side to the base of the columella. (b) Measuring the distance from the peak of the cupid's bow on the noncleft side to the ipsilateral alar base. (c) By measuring the height of the dry mucosa from the peak of the cupid's bow on the noncleft side to the red line of Noordhoff (widest part of the dry mucosa). (d) The distance from the oral commissure to the peak of the cupid's bow on the noncleft side.

proceeding at right angles to the lip. The entire bulk of orbicularis oris marginalis at this level is preserved. This is to avoid muscle deficiency which is a possible cause of a vermillion notch.

Advancement Flap

The cleft edge is paired as on the other side. The incision commences from the base of the ala to the previously tattooed lateral point.

In patients in whom the lateral element is obviously short, Millard recommended that an additional 2 mm in height could be obtained by moving the lateral point out by a mm and the superior point at the base of the nostril by another mm.²⁴ Two mms could be quite a significant gain in these babies. Undermining of the skin and mucosa is performed for a few mm more than on the noncleft side.

The vermillion edge is pared leaving behind a cuff of orbicularis oris muscle just as on the other side.

At the base of the ala, a perialar incision is made. Although Millard's incision originally went all around the ala, this has become less popular as the scar may show. Some surgeons avoid this incision altogether, while the author uses a limited perialar incision as it also provides easy access for the alar dissection and enables direct visualization of the paranasal muscle for placing the cinch suture.

Surgeons who avoid the perialar incision would go into the nostril through the paring incision.

Lateral Mobilization

Extensive lateral mobilization is necessary to facilitate a tension free closure. The authors approach this through an incision above the alveolar margin. Dissection proceeds in a sub-periosteal plane and extends superiorly till the infra orbital foramen with its neurovascular bundle, laterally till the zygomatic prominence and medially to the edge of the nasal process of the maxilla. The mucoperiosteum is separated off the maxilla superiorly.

The orbicularis oris muscle is undermined from the mucosa and from the skin. Surgeons who do not perform the subperiosteal dissection will need to dissect in the subcutaneous plane to achieve adequate lip mobilization.²⁰ With adequate mobilization, it is possible to bring together the widest of cleft lips without any tension in the repair.

Primary Nasal Correction

The nose in a patient with a unilateral cleft lip has some characteristic deformities. These have been well documented by Huffmann and Lierle² as we have discussed earlier. Though there was an initial apprehension that primary nasal correction would be detrimental to the growth of the nose and maxilla, this has largely been disproved. Some form of primary nasal correction is now performed almost universally. Published reports of nasal correction include those of Blair and Brown, Gillies and Millard, and Berkeley.²⁵

Primary closed nasal correction and septal repositioning have been performed from the early 1970s in India almost simultaneously by Dr. Adenwalla and Charles Pinto. There are two aspects to the nasal corrections: alar cartilage dissection and shift and the septal repositioning.

Primary Alar Cartilage Dissection

Primary alar cartilage dissection and stabilization of the shifted cartilage with sutures are now performed by most cleft surgeons across the world. The dissection may be through a closed approach or open, as performed by C Thomas and Mishra²⁶ and Trotter and Mohan.²⁷ There is also a semi open approach practiced by Chen using a Tajima reverse U incision.²⁰ The authors perform a closed alar cartilage dissection; the alar cartilages are approached both medially through the columellar base incision and laterally through the advancement incision (**Fig 3.16a, b**). No attempt is made to separate the cartilages from the nasal vestibular lining as the cartilage is densely adherent to the lining at this level and closed dissection is nearly impossible. Bolster sutures retain the cartilage in place. The original bolster sutures were described by McComb²⁸ and had to be tied over pledgets on the skin. Once these were removed, there was a slumping of the cartilage once again. Noordhoff²⁹ introduced a method of tying the sutures on the vestibular aspect, but this involved cutaneous puncture with the needle and often caused a skin dimpling. The authors use the technique of Erol Demirseren, whereby a hypodermic needle is introduced through the skin and the suture (4-0 Monocryl or PDS) is fed into the needle.³⁰ Such a method is also for interdomal suturing and to straddle the nasal web.

Primary Septal Repositioning

This has not yet gained wide acceptance. However, this has been performed at our center from the early 1970s with no detrimental effect on nasal growth.³¹ This has also been the conclusion from long-term studies published after 35 years of follow-up by Anderl et al³² and 10 years follow-up by Smahel et al.³³

The septal cartilage is approached through an incision at the junction of the septum with the vomer and maxillary crest. The mucoperichondrium is raised off the cartilages on both sides. The septal cartilage is released from its bony attachments (**Fig. 3.17a, b**).

There is a residual bow stringing that is neutralized by transverse and longitudinal scoring incisions on the noncleft side. A sliver of cartilage is excised from its inferior border and used as a columella strut graft (**Fig. 3.18**).

The released, straightened septal cartilage is then fixed. Ideally it has to be fixed in the midline to bone. However, in the unilateral cleft lip child, there is no such anchoring point available. Hence, as an over correction the cartilage is sutured to the just reconstructed cleft side nasal floor. With this the septum comes to lie in the midline (**Fig. 3.19**).

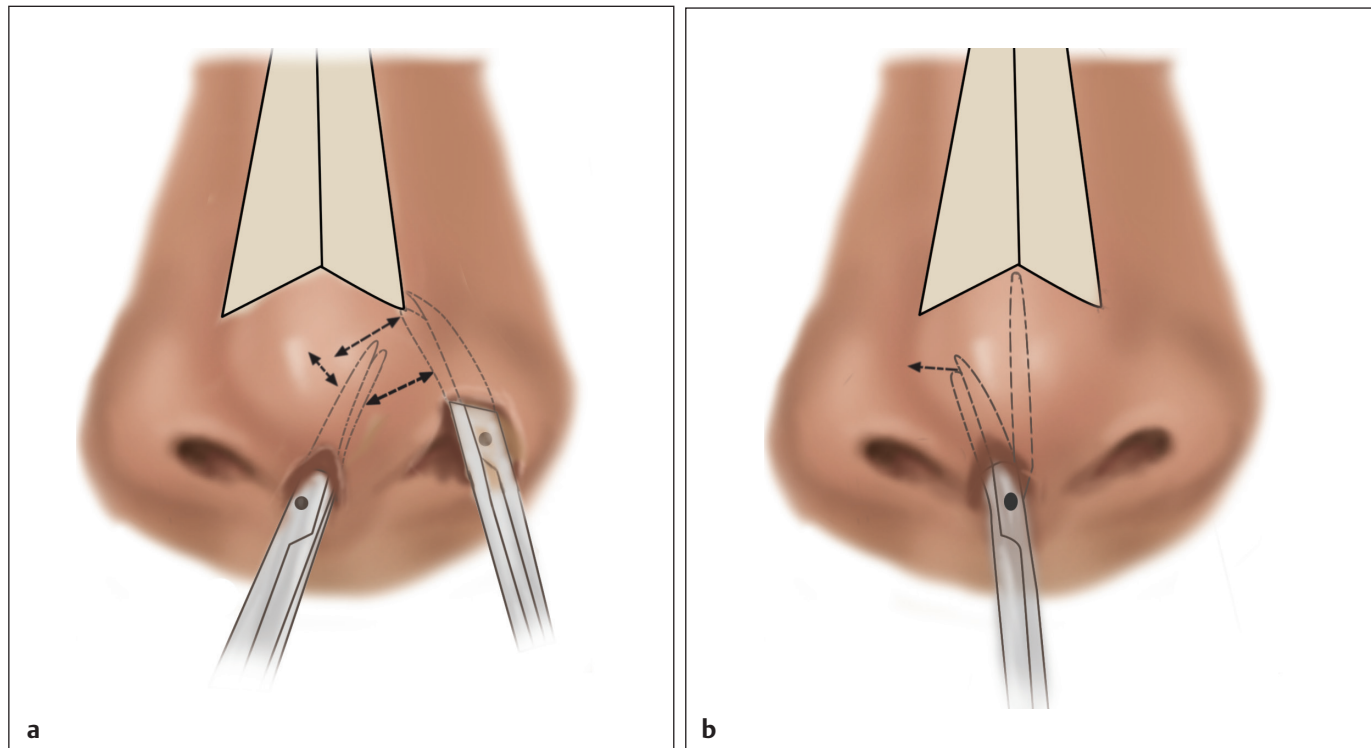


Fig. 3.16 Closed alar dissection. **(a)** On cleft side and **(b)** on non-cleft side.

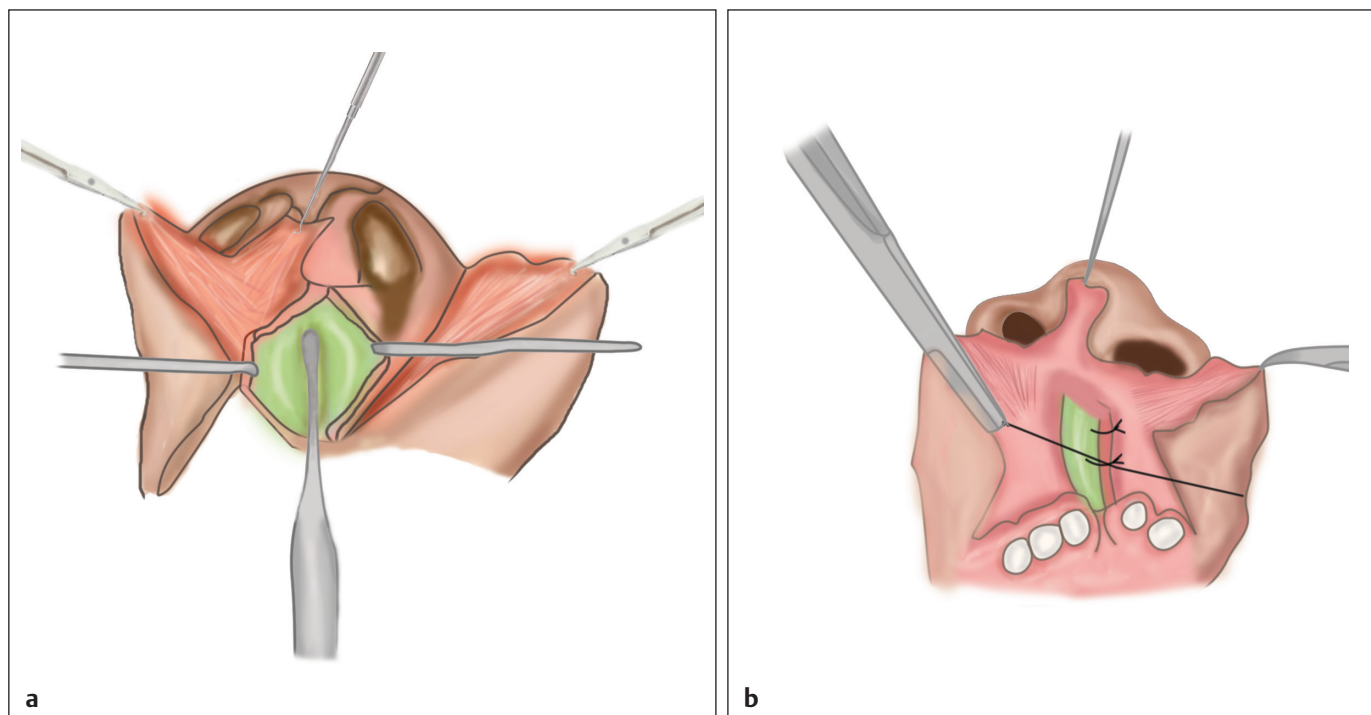


Fig. 3.17 **(a)** Septal cartilage dissected from mucoperichondrium on both sides. **(b)** Septal cartilage fixed to the newly formed nasal floor on cleft side.

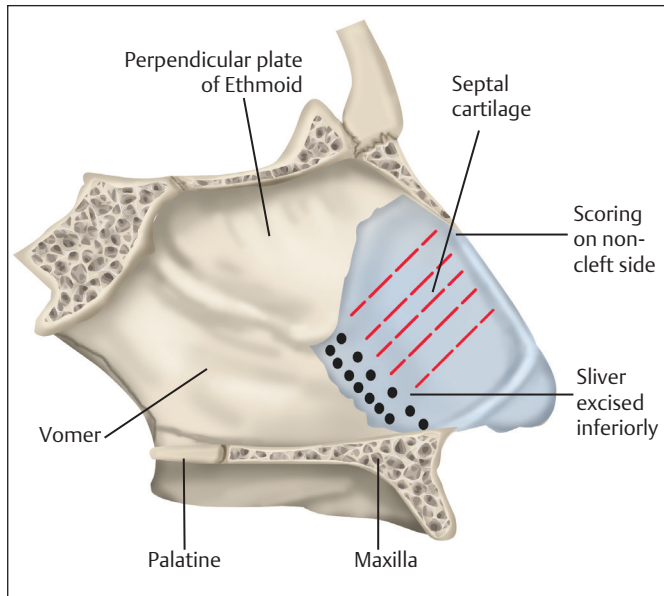


Fig. 3.18 Scoring of septal cartilage and excision of sliver of cartilage inferiorly.

Columella

Hemicolumellar lengthening is obtained using the C flap as mentioned above. The sliver of septal cartilage harvested is used as a columellar strut graft.

Closure of the Anterior (Hard) Palate at the Time of Cleft Lip Repair

Conventionally, the anterior palate has been closed along with the cleft lip repair. Initial surgeons used an inferiorly based nasal septal and vomerine flap from the medial aspect and the mucoperiosteum from the lateral shelf. This led to growth problems and were abandoned.

Pichler (1926)³⁴ used a superiorly based vomer flap and tucked it under the mucoperiosteum of the edge of the palate cleft on the cleft side to close the anterior hard palate in a single layer.³⁴This has been popularized of late by Sommerlad.³⁵

Veau (1931)³⁴ used similar vomerine flaps to close the anterior palate cleft but did not tuck it under the palatal mucoperiosteum but approximated it to the edge of the lateral mucoperiosteum. This has been the preferred method of the authors. We suture the hard palate till its junction with the soft palate.

Two layered closure has been used by some surgeons. Campbell³⁴ used a septal turn over flap, Muir used a labial mucosal flap for the second layer.³⁴These may interfere with the eruption of the tooth later.

When the entire hard palate has been closed at the time of lip repair, the extent of the cleft that needs to be closed at the time of palate repair is much less. However, early

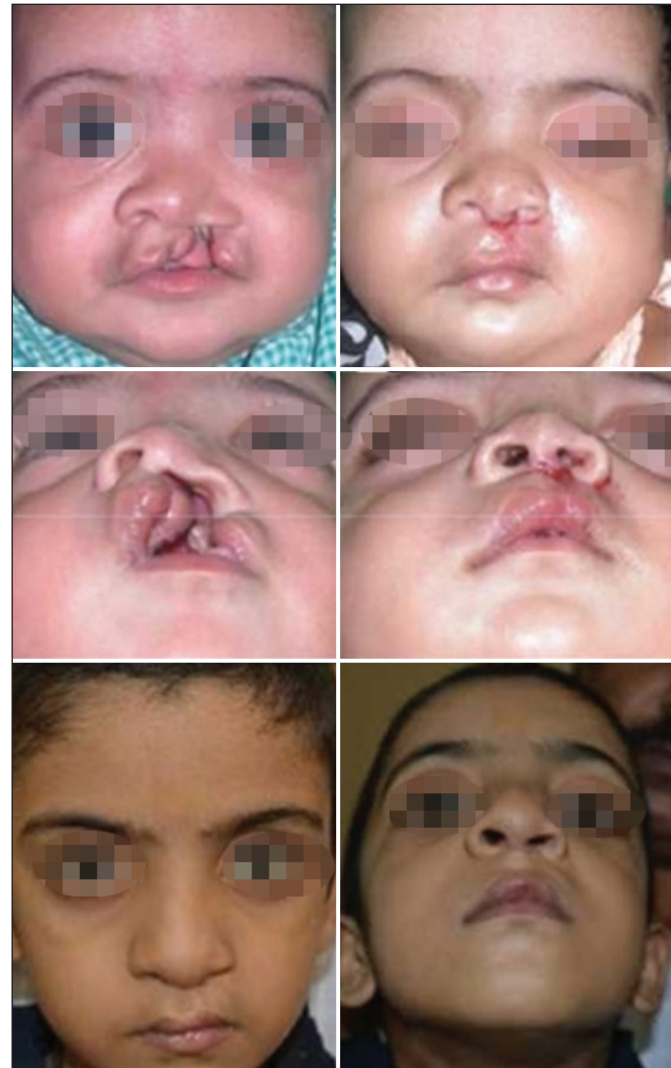

Fig. 3.19 Results of the Millard's procedure prior to repair: immediate postoperative and long term. No rhinoplasty was done.

repair of the hard palate using the entire vomer flap could be interfering with the growth center in the vomer and hence affect the growth of the midface.

Closure of Lip

First the nasal floor is reconstructed by suturing the septal mucoperiosteum with the maxillary mucoperiosteum. The orbicularis oris muscle on either side of the cleft is released from all its false attachments. The Millard cinch suture anchors the perialar muscle on the cleft side to the membranous septum. The extent of tightening on the suture is titrated to the extent of narrowing of the nostril that is required. In addition to the Millard cinch suture, the senior author has introduced another sill cinch suture that goes through the subcutaneous tissue medially and dermis

laterally and can provide a better control of nostril shape.³⁶ The orbicularis oris muscle is then brought together across the cleft with non-absorbable 5-0 polypropylene suture. We close the vestibular mucosa prior to the muscle closure. Muscle and skin closure follow.

Postoperative Care

A tongue stitch placed deep and adequately posteriorly on the tongue helps to pull out the tongue in case of obstruction from the tongue falling back in a baby emerging from the

effects of anesthesia. Arm restraints have been traditionally used to prevent injury to the recently repaired lip. There are many surgeons who do not use it these days.³⁷ A nasal pack is used with paraffin gauze for its tamponade effect in the immediate postoperative period.

Pictures of patients operated with this technique are presented, with only primary lip and nose correction (**Fig. 3.20**), with primary lip and nose repair and preschool rhinoplasty (**Fig. 3.21**), and with primary lip and nose correction and secondary rhinoplasty (**Fig. 3.22**).

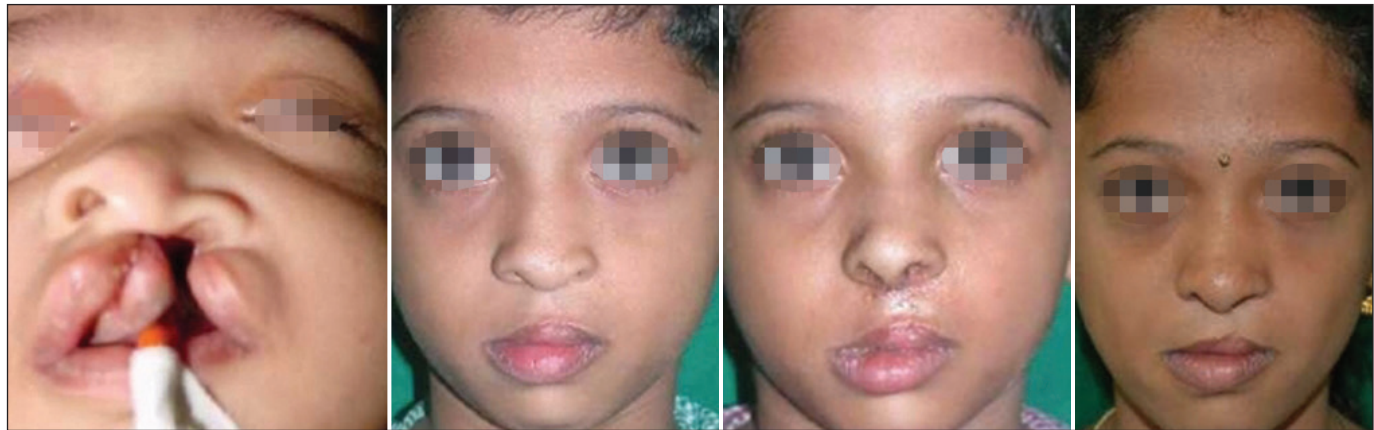

Fig. 3.20 Long-term result of the Millard's procedure: prior to cleft lip repair at 6 months, pre- and post-op preschool rhinoplasty done at 5 years, and 6 years after the rhinoplasty.

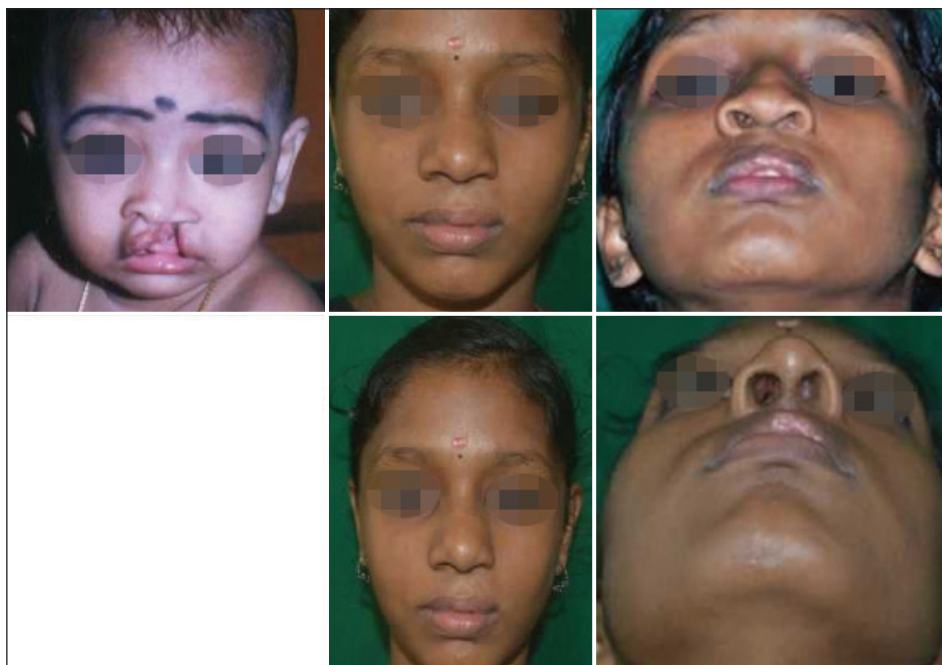

Fig. 3.21 Prior to cleft lip repair at 6 months, prior to definitive rhinoplasty, and after definitive rhinoplasty.

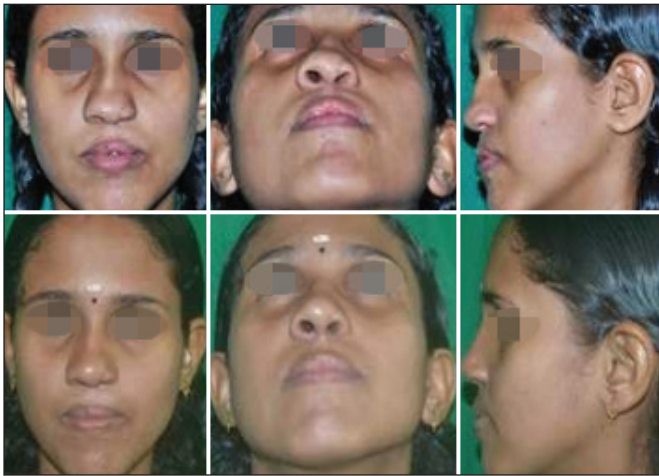

Fig. 3.22 Before and after definitive rhinoplasty frontal, Worm's eye view, and lateral pictures.

Randall-Tennison-Sawhney Triangular Flap Technique of Unilateral Cleft Lip Repair

Marking

Geometrical designing of the incision line and precise marking are soul of this technique.

Markings on the Medial Element of Lip

Lateral philtral point is marked as the highest point of Cupid's bow on noncleft side. Corresponding lateral philtral point is marked on cleft side at the point where white line starts

thinning. Mid-philtral point is marked at the lowest point of Cupid's bow in the midline corresponding to the philtral tubercle. Mid-columella point is marked at the midpoint of base of columella. The lateral columellar base is marked on two sides at the point where the philtral column meets the columella base (**Fig. 3.23a**).

A vertical line is drawn from lateral columellar base point to the lateral philtral point on noncleft side indicating the height of lip. Another vertical line is drawn in the midline from mid-columella point to mid-philtral point at the lowest point of the Cupid's bow. A horizontal line is drawn from the cleft side lateral philtral point bisecting the midline and philtral column. This is the most important line as it decides the difference in the height between cleft and noncleft side. Also this line is the course of backcut upto midline as described by Sawhney¹⁷ (**Fig. 3.23b**).¹⁸

Markings on the Lateral Element of the Lip

Medial side markings are used for marking the triangle on the lateral element of the lip. Lateral philtral point is marked at the point where the white line starts thinning. The alar base point is marked medial to the alar base on the nostril sill (**Fig. 3.23a**).

Castroviejo caliper is used to design the triangular flap using the dimensions from the medial element. The present height of cleft side is used for making an arc from alar base point. Another arc is marked from the lateral philtral point to bisect the previous arc using the difference between heights on two sides of the lip, that is, the required drop. Now the point is marked where two arcs bisect. The distance between this point to lateral philtral point makes the base of the triangle (**Fig. 3.23c**). With caliper, the distance between lateral philtral point to the midline on the medial element is measured. Two arcs of same radius are drawn from two

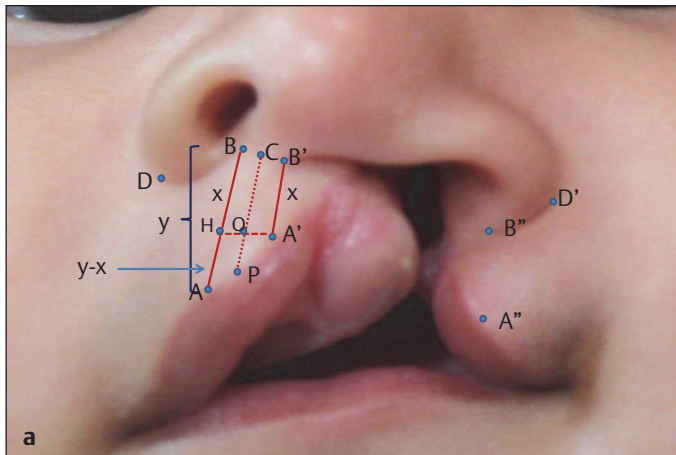


Fig. 3.23 (a) Markings on medial element: A—The highest point of Cupid's bow on the noncleft side; A'—Highest point of Cupid's bow on the medial element where white line starts thinning, almost equidistant from mid-philtral point 'P'; P—Peak of philtral tubercle; C—Mid-columellar point at the base of columella; B—Alar base point on the noncleft side; B'—Alar base point on cleft side; CP—Midline is drawn vertically through the philtrum. Markings on lateral element: A''—Proposed lateral philtral point, where the white line starts thinning; B''—Alar base point which is supposed to meet point B' on the medial side.

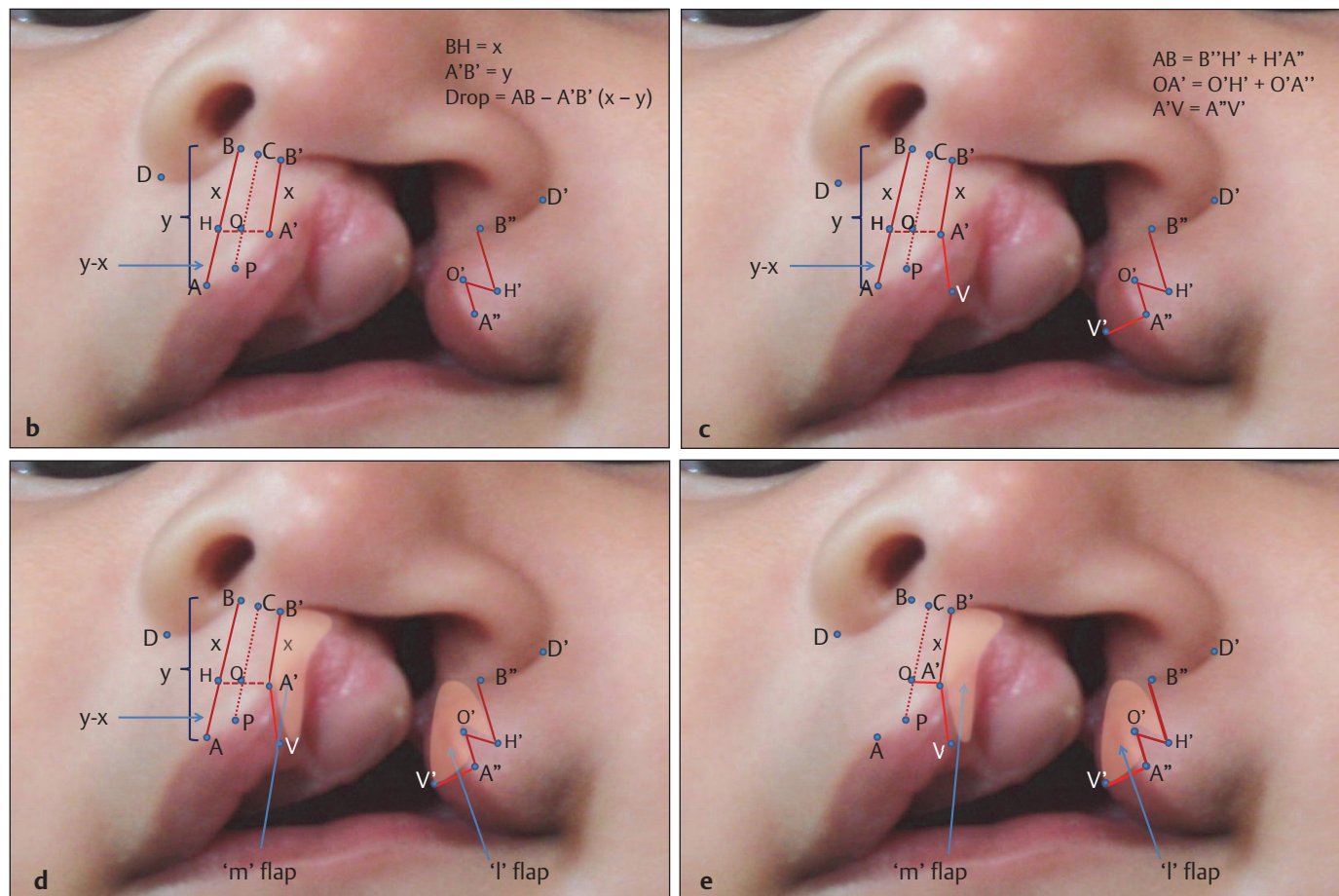


Fig. 3.23 (Continued) (b) AB—Vertical line is drawn on non-cleft side indicating the height of lip on normal side (y), $A'B'$ —vertical line is drawn on cleft side, indicating the present height of lip on cleft side (x). $A'H$ —Horizontal line drawn from A' bisecting the midline at point O and AB line at H . So that $A'B'$ is equal to BH (x height). ($y-x$) is the critical height by which $A'B'$ height needs to be increased. This is the 'required drop' of the existing lip height on cleft side. (c) With Castroviejo caliper, an arc of x radius is drawn from B'' over the lateral element adjacent to A'' . Another arc of $(y-x)$ is marked from A'' bisecting the previous arc. The bisecting point is H' . $x + (y-x)$ will create the normal height of lip as on noncleft side. $A''-H'$ forms the base of the isosceles triangle which will fit in the future backcut on the medial element. (d) A triangle is designed with $H'A''$ base to fit in the backcut on the medial element $A'O$ distance is the backcut. In Sawhney's technique, the backcut stops at point O in midline in all the cases. With Castroviejo caliper, two arcs are drawn from points A'' and H' on its medial side over the skin area. The arcs cut each other at point O' which is the apex of the triangle and will form an isosceles triangle. Vermilion incisions are drawn from points A and A'' so as to create equal size vermilion for suturing. On medial element, the line is drawn obliquely toward vermilion tubercle to point V and on lateral element the line is perpendicular to the white line to point V' over redline and the markings are made over the dry-wet vermilion junction (red line). This is an attempt to create symmetrical vermilion on two sides of the cleft. (e) Incision lines: Medial element incision: $B'-A'-V$ Backcut from A' to O . Tissue lateral to the incision is raised as 'm' flap based at alveolar margin. Lateral element incision: $B''-H'-O'-A''-V'$ ($H'O'A''$ forms an isosceles triangle). Tissue medial to the incision is raised as 'l' flap based at alveolar margin. 'l' and 'm' flaps are used for anterior palate repair or for deepening the sulcus as indicated.

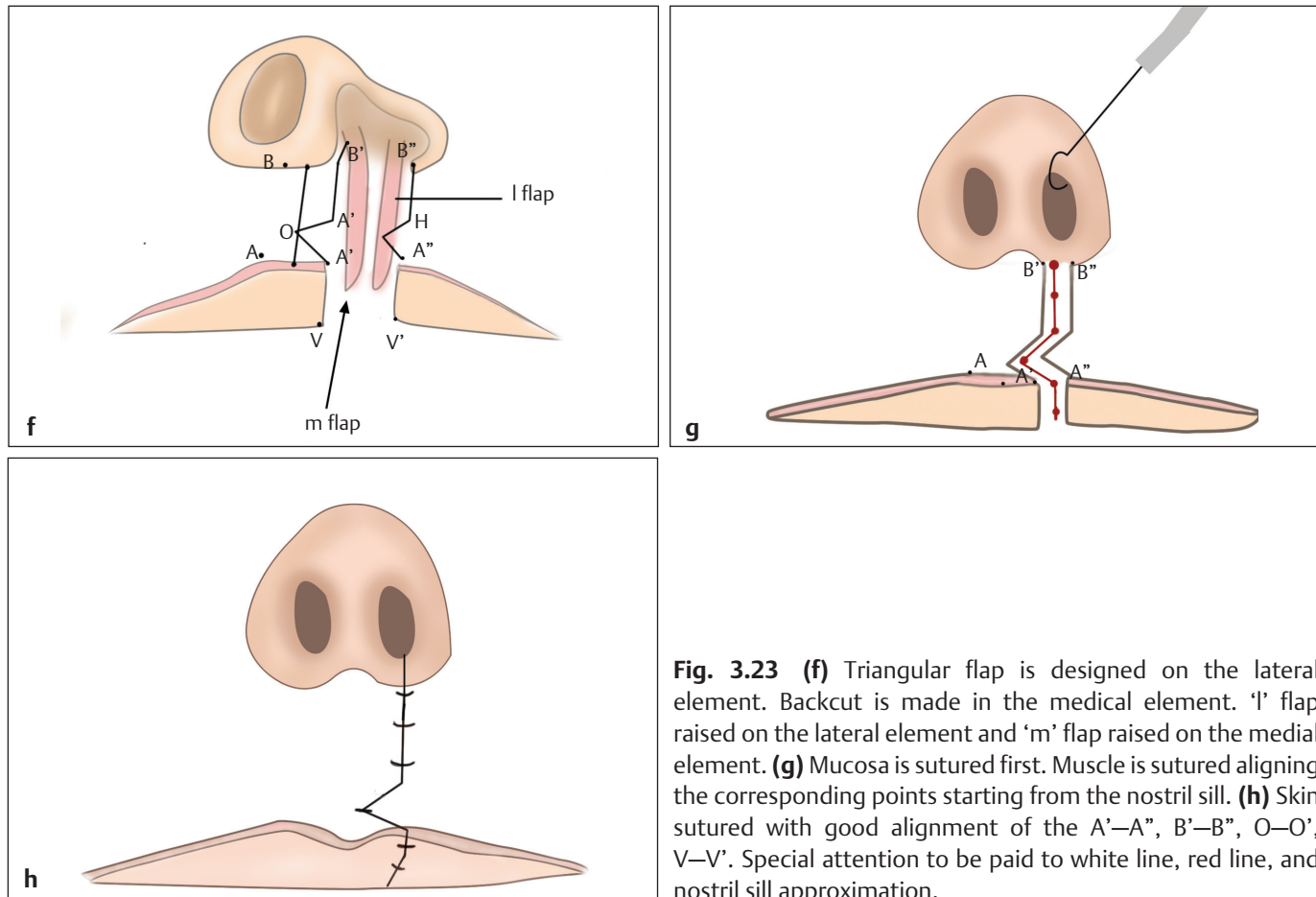


Fig. 3.23 (f) Triangular flap is designed on the lateral element. Backcut is made in the medial element. 'l' flap raised on the lateral element and 'm' flap raised on the medial element. (g) Mucosa is sutured first. Muscle is sutured aligning the corresponding points starting from the nostril sill. (h) Skin sutured with good alignment of the A'—A'', B'—B'', O—O', V—V'. Special attention to be paid to white line, red line, and nostril sill approximation.

points on the base of the triangle toward the medial edge of the lateral lip. This almost always falls on the cutaneous part of the lip. These two arcs bisect each other to make the apex of the triangle (**Fig. 3.23d**). Care is taken to tattoo all the points especially the key points on white line, columella and alar bases, vermilion points, and apex and sides of the triangle.

Incisions

Full-thickness incisions are made along the markings on both sides. The tissue toward the cleft edges was earlier discarded. Now these elements are raised as "m" and "l" flaps attached to the alveolar margin. These flaps are used for second layer of anterior palate repair or for deepening the sulcus as indicated (**Fig. 3.23e**).

The incision on the medial element runs along the future philtral column in the upper part, and in the lower part, a back-up cut is made from the lateral point horizontally upto the midline. It opens up the lip to the level of highest point of Cupid's bow at the level of noncleft side. The triangular

defect will be filled by a triangular flap from lateral element of same dimension.

The incision on the lateral element follows the line from alar base point to the base of triangle and down to lateral philtral point crossing the white line to the redline of vermilion. As discussed earlier, the isosceles triangle is medial to the line of incision and is of the exact dimension of the gap in the medial element (**Fig. 3.23e, f**).

The mucosal incision extends to buccal sulcus on both sides. The lateral and medial elements are dissected off the maxilla sub- or supraperiosteal based on ones' choice. (a) The extent of the dissection varies depending upon the degree of cleft and the cleft distance. The abnormal attachment of orbicularis oris muscle is dissected from skin and mucosa laterally as well as medially. While dissecting on the lateral side, the abnormal fibrofatty tissue from the alar base is excised. Through medial incision, the cartilaginous septum is dissected. The septoplasty is performed by dislocating the cartilaginous septum from the maxillary crest. (b) This part of dissection is essentially surgeons' choice. It is not part of any of the lip repair technique.

Anterior Palate Repair

In case of alveolar cleft and cleft lip and palate, the anterior palate is repaired using vomer flap and lateral nasal mucosa. Second layer is provided by “l” and “m” flaps. (c) Lip is repaired in three layers. Repair is extended to nasal floor to nostril sill.

Approximation and Suturing of Lip

The alar base point is sutured to lateral columellar base point reconstructing an aesthetic nostril sill. Hereafter, the muscle corresponding to specific points is approximated together (Fig. 3.23g).

Special attention is paid to approximate the muscle in the region of white line, apex, and base of the triangle and in the region of nostril sill. Mucosa and skin are also sutured to the corresponding points. Since it is a geometrical technique, once the nostril sill is sutured, rest of the points come together and no modification is required. The lateral philtral points also come at the symmetrical level (Fig. 3.23h).

Vermilion repair should be paid enough attention as it is aesthetically important part of the upper lip. Symmetrical vermilion is achieved by approximating the red line avoiding any notch or elevation and approximating the orbicularis marginalis with little ingenuity. Also the exposure of unsightly parched wet vermilion is avoided.

The incision on two sides is designed in such a way that the dry vermilion is equal on two sides and red vermilion is set at the same level. Effectively more of dry vermilion is used from lateral lip element. Alternatively, Noordhoff's vermilion flap is used to reconstruct the notch free vermilion.²⁰

Ancillary Procedures

As mentioned with the rotation advancement technique, there are many ancillary procedures performed as refinement to the original technique. Options remain same with triangular flap technique too. There are many procedures in armamentarium of the cleft surgeons including “l” flap, “m” flap, inferior turbinate flap, and vomerine flap.

“l” flap is the marginal tissue from lateral element of the lip. This is based on alveolar margin or on the lateral wall of the nose. It is used for lengthening the nasal lining to bring the alar base forward. The “l” flap is inset in a defect created by incising the mucocutaneous junction in the nasal vestibule. Alternatively, it is used for anterior palate repair or for deepening the buccal sulcus as indicated.

“m” flap is the vermilion tissue from medial lip element that can be raised based on the columella base or alveolar margin. This can be used for lengthening the columella, for bridging the alveolar cleft, for anterior palate repair, or for deepening the buccal sulcus as indicated.

Inferior turbinate flap is used to augment the nasal floor or alar base as described by Noordhoff²⁰; this is almost like “l” flap described earlier. This also helps in correcting the position of alar base.

Anterior palate repair and primary nasal corrections are performed as has been described along with rotation advancement technique. Pictures of patient operated using the triangular flap technique are presented (Figs. 3.24a and 3.25).

Role of Nasal Conformers

The state of art in unilateral cleft lip repair being what it is today, one can reconstruct the nose with a fair degree of symmetry after the primary repair. However, with the fourth dimension of growth that follows, these noses show a varying degree of deformity especially of the ala; the commonest of these is a droop of the soft triangle and the grossly deformed patients show all the stigmata of a unilateral cleft lip nose.

In order to sustain the nostril symmetry postoperatively, silastic nasal conformers have been tried.^{38,39} There is no doubt that the nasal symmetry is remarkable during the use of the conformer. However, by and large, there is a relapse of the alar droop once the conformer is discontinued. Interestingly, a study conducted at the Chang Gung Centre by Chen Shin Chang et al⁴⁰ demonstrated that the best result was only obtained when patients underwent a combination

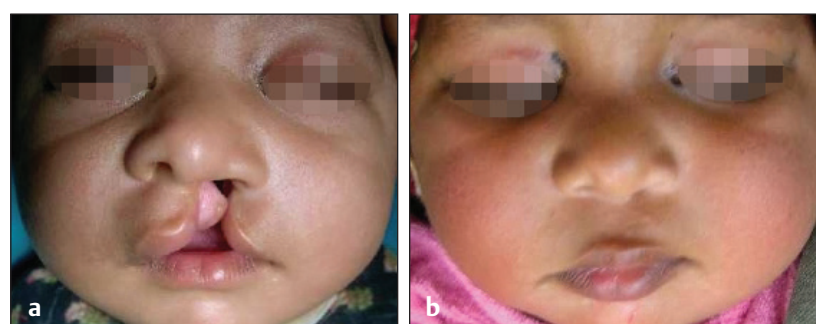

Fig. 3.24 Pre- and postoperative pictures after triangular flap repair.

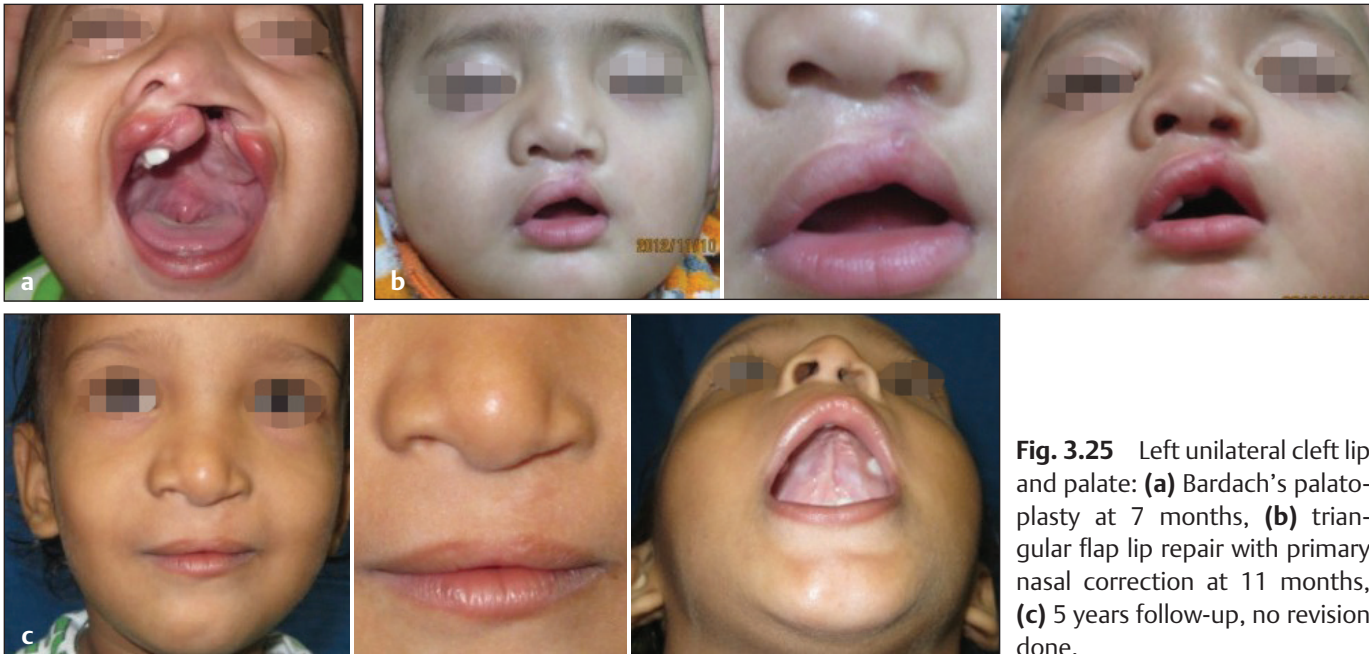

Fig. 3.25 Left unilateral cleft lip and palate: (a) Bardach's palatoplasty at 7 months, (b) triangular flap lip repair with primary nasal correction at 11 months, (c) 5 years follow-up, no revision done.

of NAM, primary rhinoplasty with over correction of the ala, and the use of nasal conformer with incremental size for at least 6 months postoperatively.

Primary Gingivoperiosteoplasty Technique

The alveolar cleft in complete clefts of the primary palate should be addressed either at the time of primary cleft lip repair or secondarily. Primary bone grafting was once popular, but now largely given up because of its deleterious effect on maxillary growth.^{41,42}

The use of presurgical orthodontics like the Latham's device or NAM results in narrowing of the alveolar gap. A gingivoperiosteoplasty has been used in this setting to close the alveolar defect and utilize the presumed potential of the periosteum for bone formation to produce "boneless bone graft." This practice was pioneered by Skoog (1964).⁴³ Millard used it extensively after presurgical orthodontics with the Latham's device. The edges of the cleft alveolus and anterior palate are split and closed in two layers. This has been used with NAM by Cutting and Grayson. They have shown that 73% of patients with GPP do not require secondary bone graft and that GPP alone along with secondary alveolar bone graft produce better bone formation as compared to conventional alveolar bone graft alone.⁴⁴

Hsieh et al⁴⁵ have reported a negative effect on growth of maxilla at 5 years. Other studies have also demonstrated

deleterious effect of GPP on growth of maxilla.^{46,47} GPP continues to be a controversial issue and only further long-term studies can clarify the effect of this on maxillary growth.

Partial Cleft Lip

In these the cleft extends onto the body of the lip to a varying extent up to the nasal sill, which is intact. There is no cleft of the nasal floor or the alveolus.

We perform a Millard's rotation advancement procedure for all of these patients (**Fig. 3.26**). The markings are essentially the same as in the complete variant.

Precautions:

The Cupid's bow is not as high as in a complete cleft lip. On completion of the rotation incisions, it is possible to lengthen the lip excessively unless one is meticulous in planning and executing the rotation incision. A backcut is seldom necessary.

Another point to remember is that though the nostril on the cleft side is usually very wide, one must be wary while excising tissue at the nostril sill. Once the advancement flap is used, there is always some extent of narrowing of the nostril base. If one excises tissue at the sill without taking this factor into account, one is liable to get an excessively narrow nostril that could be difficult to correct later.

The extent of the nasal deformity is also often underestimated in partial cleft lips. Some of these later develop severe cleft lip nasal stigmata. The authors always perform a closed alar dissection on these partial cleft lips.

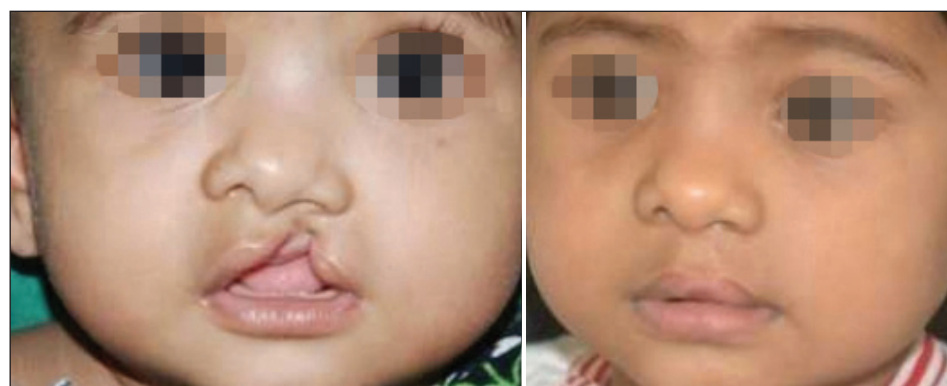

Fig. 3.26 Partial cleft lip (left): pre- and postoperative pictures.

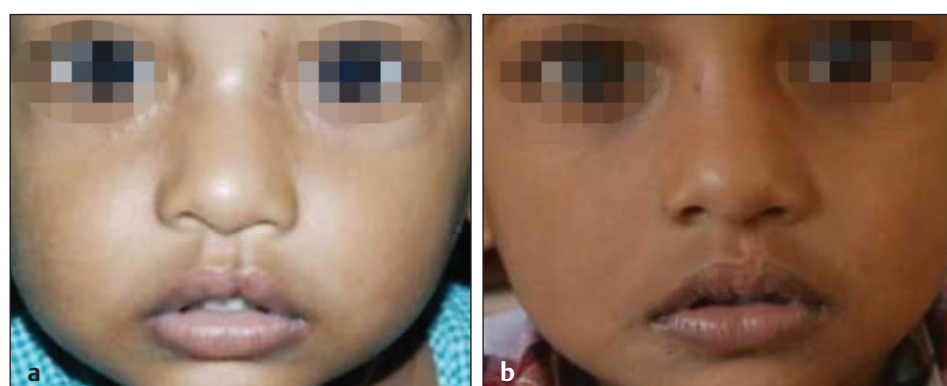

Fig. 3.27 (a) Microform cleft lip (left): preoperative. **(b)** Postoperative after straight line repair and vermilion notch correction.

Microform Cleft Lip

This refers to a variant of cleft lip that primarily involves the vermilion. It has been variously called the mini cleft, forme-fruste cleft, minimal cleft, occult cleft, nature's union, etc. The latter term is based on the belief that there has been an attempt at closure by nature in utero!

Mulliken⁴⁸ has classified microform clefts into:

- Mini microform, where the cleft is confined to a vermilion notch with the Cupid's bow points at the same level.
- Microform, where the cleft involves the vermilion and less than 3 mm of the lip above the Cupid's bow; and
- Minor form, where more than 3 mm of the body of the lip above the Cupid's bow is cleft. These are to be treated like partial cleft lips.

In the mini microform lips, only a vermilion notch correction procedure, including scar excision, muscle build up, and a Z plasty on the mucosa, is required. In the microform variant, a notch correction is required as above.

In addition, there may be a Cupid's bow that is level or pulled up. If the Cupid's bow is level, then a mere scar excision of the intervening tissue and a repair on the body of the lip excising a furrow or a scar is required.

If the Cupid's bow point is raised, however, a rotation is definitely required. In these patients with a trivial deficiency, the aim is to do only as much as is required to avoid excess surgical trauma to minimize the scarring. Hence, in these patients, the senior author at our center has devised a Cutaneous Millard's procedure⁴⁹ in which the incision is confined to the skin and subcutaneous tissue without infringing on the muscular layers. However, one should assess the degree of continuity of muscle across this region and if there is mild deficiency, this can be corrected by plicating the muscle. If there is gross deficiency, then one should perform a classical Millard's procedure (**Fig. 3.27a,b**).

Late Presentations

In developing countries, it is still not uncommon to find patients presenting for cleft repair later in life sometimes even after 50 years! The causes may be ignorance, fear of surgery, and economical reasons.

If these patients have a cleft lip with an unrepaired cleft palate, the cleft palate repair should take precedence for optimal speech. In patients older than 3 years of age, a "whole-in-one" procedure has been popularized by Charles

Pinto,¹⁵ and is still performed today with simultaneously cleft lip and palate repair.

The cleft lips in those patients who turn up later are treated in much the same manner as in the babies. However, the vermillion in these older patients may be a little more difficult to manage as very often there is an excess that needs to be trimmed carefully for an aesthetically acceptable result. The nasal deficiency accompanying the cleft lip is usually more severe. The authors often perform a simultaneous open rhinoplasty and septal repositioning using the approach of Trott and Mohan²⁷ with the sutural technique developed by the authors.

Prevention of Deformities

Preventable deformities following cleft lip repair include:

- Vermillion notching
- High riding nostril
- Web in the nostril
 - Vermillion notching, which is a defect in the free border of the lip is an unsightly blemish that follows cleft lip repair unless care is taken at the primary repair to avoid it.

Causes of a vermillion notch:

- Inadequate rotation of the Cupid's bow.
- Inrolling of the skin and muscle edges.
- Deficiency of orbicularis oris muscle at the vermillion border.
- Contraction of the straight line scar.

One should analyze the causes of such notching and appropriate steps should be taken to prevent these.⁴⁹ These are as follows:

- Inadequate rotation of the Cupid's bow, causing tenting up of the lip and the resultant pull causes notch on the vermillion. This has been countered by an adequate rotation and a complete backcut in every patient.

- Inrolling of the skin and muscle edges causing a groove that resembles a notch and this is prevented by undermining the skin and muscle edges.
- Deficiency of orbicularis oris muscle at the vermillion border that is preempted by retaining adequate muscle bundle at the time of paring (**Fig. 3.28**). These are then sutured with nonabsorbable nylon sutures (6-0).
- Contraction of the straight line scar. Ideally this is to be corrected by a Z plasty on the skin. However, as these would be against the Langer's lines, we use a Z plasty on the mucosa, away from Noordhoff's red line (**Fig. 3.29**).

These measures effectively prevent a notch in almost all patients. Pulling up of the Cupid's bow with resultant notching, the immediate postoperative period does descend with time with a notch free lip if the rotation has been adequate.

- High riding nostril (**Fig. 3.30**): This happens when there is gross alveolar disparity between the medial and lateral maxillary segments, causing the nostril base on the cleft side to lie superiorly as compared to that on the noncleft side. This, we believe, can be eliminated by proper alignment of the bony segments preoperatively with presurgical orthodontics. However, should some amount of disparity remain, we perform an unequal Z plasty as advocated by Jackson⁵⁰ on the nasal layer, with a perpendicular release laterally and an acute angled release medially. This has helped in reducing the incidents of such high riding nostrils.
- Webbing of the nostril is caused by bony, cartilage, and soft tissue components according to Patel and Mulliken.⁵¹ He has used intercartilaginous sutures through a semiopen approach. He releases the bony attachment of the lateral cartilage and also excises a part of the web. We do not excise the web, but use sutures to straddle the web. Any residual web tissue can come in handy during subsequent rhinoplasty.

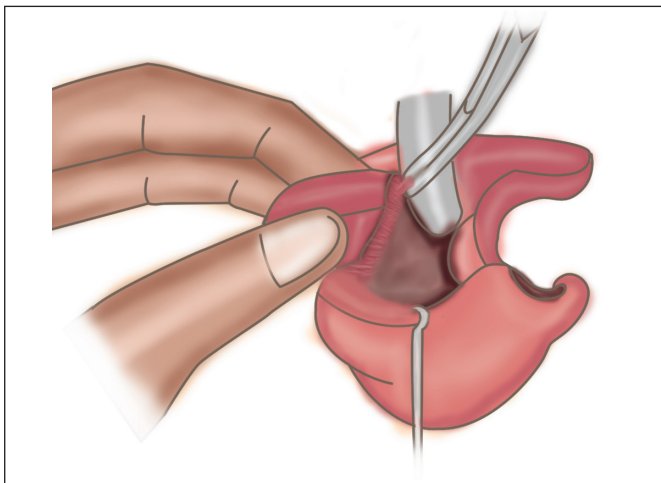


Fig. 3.28 Retaining a good orbicularis oris muscle cuff.

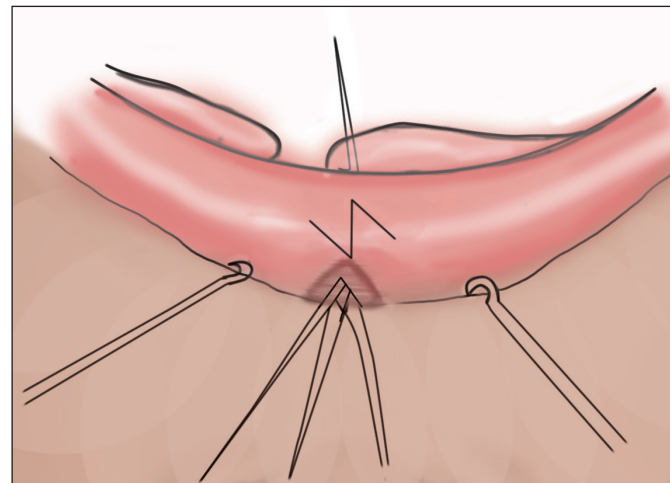


Fig. 3.29 Z plasty on mucosa.

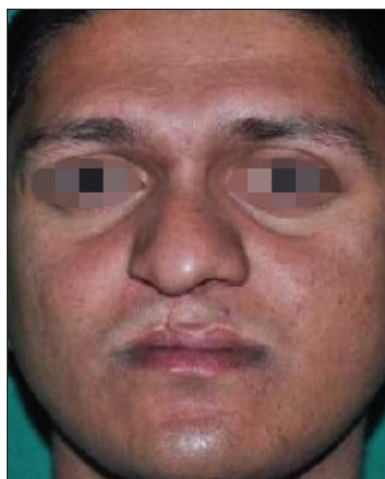

Fig. 3.30 High riding nostril.

Unsolved Problems

Despite the large strides in the correction of the lip and nose, there remain certain problems that remain uncorrected.

In the lip, there is a lateral vermillion deficiency that occurs especially when there is a gross alveolar disparity. This may be reduced significantly by presurgical molding.

In the nose, there remains a soft triangle droop that occurs in a significant number of patients despite all the primary nasal work. This is only corrected during subsequent rhinoplasty.

A nostril sill has not been produced effectively by any of the present methods of lip repair.

Mohler's Modification of Millard's Procedure

Mohler (1986)¹ analyzed the configuration of the philtral column in children and classified these arbitrarily into three types: In type I, the philtral column diverged at the base of the columella. The majority of patients studied by him belonged to this type. Type II showed convergence of the philtral column at the base of the columella, and type III converged anywhere below the base of the columella.

Mohler used a modified technique, with rotation incisions extending into the base of the columella with a backcut at right angles confined to the columella. This was especially useful in type I patients. The aim of this extension was to simulate the noncleft philtral column and to avoid a backcut on the lip. The resultant gap on the columella was covered by the C flap. As a result, the advancement flap was inset more laterally and did not have to go as far across the base of the columella as in the conventional Millard technique. This technique is favored by Noordhoff and Chen.⁵² They decide

on the angle of the back-up cut depending on the width of the columella, using a wider angle in a broader columella. The Mohler variation should be avoided in children with very narrow columellas.

Noordhoff-Chen Technique

Noordhoff used a technique based on the Millard's rotation advancement procedure but modified it in the following manner.²⁹

The rotation incision is as per the Millard, but with a Mohler extension to the columella. A small perialar incision is made. The C flap was used either for the columella or the sill depending on the individual patient. A turbinate flap was used for the nasal floor.

Noordhoff addressed the vermillion mismatch (the vermillion on the cleft side is usually fuller than that on the noncleft side). This is in contrast to most other tissues which are all richer on the noncleft side. He retained a V-shaped extension from the otherwise discarded part of the cleft side vermillion and inset this into a cut made at the junction of the wet and dry mucosa (Noordhoff's red line) on the noncleft side (**Fig. 3.31**).²⁹

This helped in achieving a much better color match of the vermillion. However, care must be taken to meticulously tailor the V flap exactly to match the vermillion height medially. Otherwise, the excess mucosa always shows badly. Dr. Powar⁵³ has described a technique to precisely match the vermillion with this technique.

Fisher's Anatomic Subunit Repair

Having trained with Noordhoff and Thompson, Fisher devised a technique using a smaller triangle that is precisely measured on the noncleft side (**Fig. 3.32**). He relied on the Rose Thompson effect to lengthen the lip.⁵⁴ He stresses the need to mark the lateral point on the cleft side exactly to measurement and not to compromise and move it medially or laterally to gain height. The latter is achieved by accurate measurements with calipers to achieve adequate lip height. A small triangular flap is raised from the lateral lip element to match the medial defect. The advantages are the adequacy of the rotation with very small triangular flaps. The disadvantages are that it is not an easy procedure to master, and like all triangular flaps, the Cupid's bow may flatten out.

The Pfeiffer and Afroze Incisions

Apart from the straight repair, Millard's repair, and Triangular flap techniques, some surgeons prefer the Pfeiffer wavy incision (**Fig. 3.33**). Dr. Gosla Reddy has used a combination

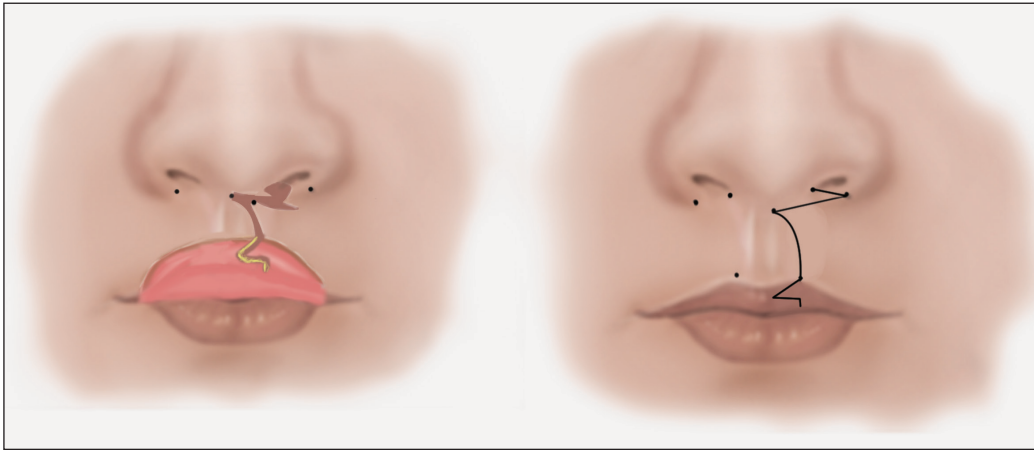


Fig. 3.31 Noordhoff triangular flap for vermilion.

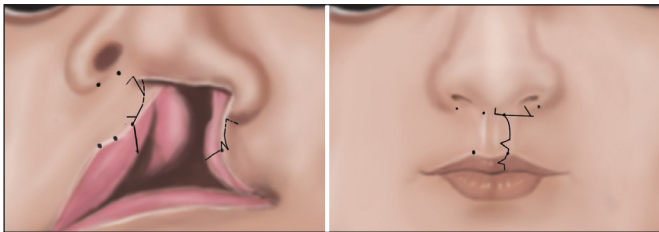


Fig. 3.32 Fisher's anatomic subunit repair technique.

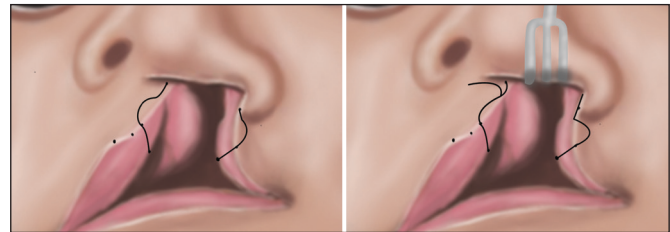


Fig. 3.33 Combined Pfeiffer-Afroze technique.

of the Millard's rotation incision on the nonleft side and the Pfeiffer wavy incision on the cleft side. This is known as the Afroze incision and Dr. Reddy believes that this incision is versatile and gives good scars and also adequate lengthening of the lip.⁵⁵

Secondary Deformities

These are best prevented as mentioned earlier. Nonetheless, they cannot be entirely eliminated (**Fig. 3.34**). These secondary deformities may be classified into those of the lip and those of the nose.

Secondary Deformities of the Lip

- Deformities of the vermilion:
 - These include vermilion deficiencies (notches) which may be along the line of the scar, or central or lateral.
 - Notching along the line of the scar can be corrected by scar excision, muscle build up, and rerotation (if required) (**Fig 3.35**).
 - Central notches and lateral vermilion deficiencies can be corrected by V-Y mucosal advancement with muscle build up (**Fig 3.36**).
 - Rarely do they require fillers like dermal fat graft.
- Deformities of the body of the lip include scar contractures or hypertrophic and depressed scars.

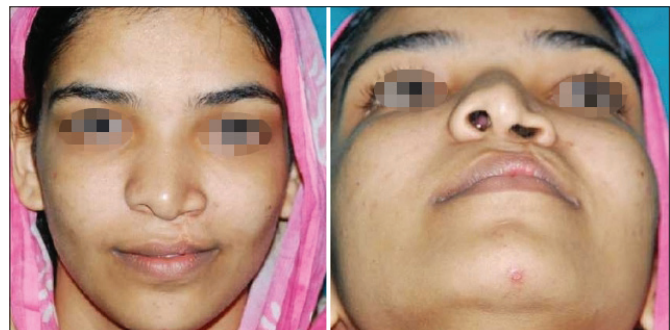

Fig. 3.34 Secondary deformities of the vermilion, body of lip, and the nose.

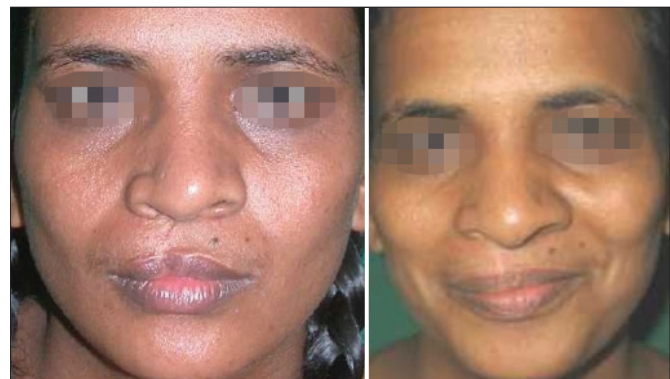

Fig. 3.35 Correction of notch along the scar by scar excision and muscle build up: pre- and postoperative.

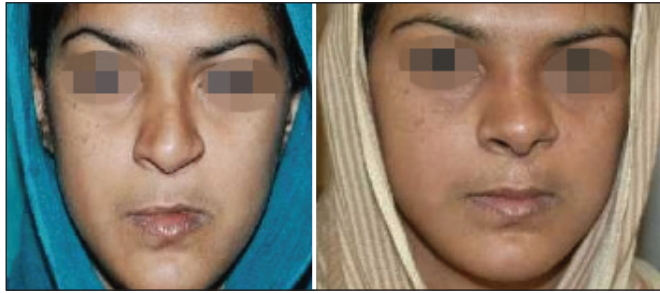

Fig. 3.36 V-Y mucosal advancement and muscle build up for lateral vermilion deficiency.

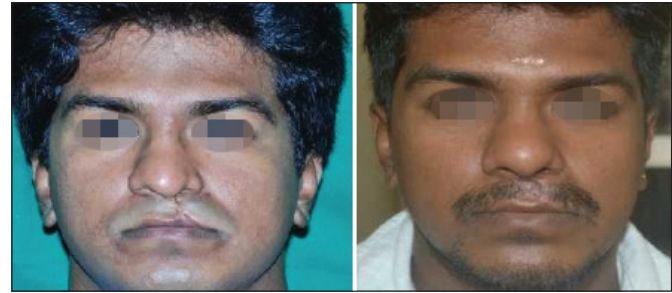

Fig. 3.37 Excision of hypertrophic scar on the lip.

Hypertrophic scars are initially injected with Triamcinolone intradermally with the use of silicone sheet or gel topically. Refractory scars are excised.

Contractures are released; rerotation is necessary in these (**Fig. 3.37**).

Depressed scars are excised. For more detail, refer to Chapter 10 on Secondary Deformities of Cleft Lip in Volume III.

Nasal Deformities

Primary rhinoplasty diminishes the extent of the secondary deformity. One still gets mild blemish which is in the form of a drop of the soft triangle. When the blemish is significant, the authors perform a preschool rhinoplasty, and use a sutural fixation technique for the cartilages; hitching the lower lateral cartilage on the cleft side to the upper lateral cartilage on the noncleft side through the septum. This is a stable fixation and usually there is no need for onlay cartilage grafts.³¹

Timing of Secondary Repair

The preschool rhinoplasty if indicated is done at age 5 ½ to 6 years. Any associated lip deformity is also corrected at the same time to try and avoid additional surgeries for the patient (**Fig. 3.22**). In those who require definitive rhinoplasty for gross septal deviation or bony corrections, it is better to wait until the completion of the growth of the maxilla. If orthognathic surgery is contemplated, then the secondary rhinoplasty is done after that so that there is a stable platform. For further detail, please refer to Chapter 9 on Secondary Rhinoplasty in Cleft Lip Nasal Deformity in Volume III.

Conclusion

It was Sir William Osler who said “he who studies medicine without a book sails an uncharted sea, but he who studies medicine without a patient does not go to sea at all.” Therefore, it is not from books that surgery can be learnt. One must apprentice with a surgeon who has mastered that particular operation. This is equally true in the case of the repair of the unilateral cleft lip.

References

1. Mohler LR. Unilateral cleft lip repair. *Plast Reconstr Surg* 1987; 80(4):511–517
2. Vyas RM, Warren SM. Unilateral cleft lip repair. *Clin Plast Surg* 2014;41(2):165–177
3. Fara M. The musculature of cleft lip and palate. In: McCarthy JG, ed. *Plastic Surgery. Vol 4. Cleft Lip and Palate and Craniofacial Anomalies*. Philadelphia: WB Saunders Company; 1990:2598–2603
4. Huffmann WC, Lierle DM. Studies in the pathologic anatomy of the unilateral hare-lip nose. *Plast Reconstr Surg* 1949;4: 225–234
5. Bardach J, Salyer KE. Unilateral cleft lip repair. In Bardach J, Salyer KE, eds. *Surgical Techniques in Cleft Lip and Palate*. St Louis: Mosby Year Book; 1991:3–4
6. Millard DR Jr. Paring and approximation with needles and/or suturing. In: Millard DR Jr, ed. *Cleft Craft. The Evolution of the Surgery 1. The Unilateral Deformity*. Boston: Little Brown; 1976:79–88
7. Udwadia FE. *Man and Medicine – A History*. 2nd ed. Oxford University Press; New Delhi, 2000
8. Millard DR, Jr. Increasing vertical length of the cleft edge. In: Millard DR Jr, ed. *Cleft Craft. The Evolution of the Surgery 1. The Unilateral Deformity*. Boston: Little Brown: 1976; 90–100
9. Millard DR, Jr. Full-thickness flaps for vertical lengthening. In Millard DR Jr, ed. *Cleft Craft. The Evolution of the Surgery 1. The Unilateral Deformity*. Boston: Little Brown: 1976;102–103
10. Millard DR, Jr. Constructing a Cupid’s bow. In: Millard DR Jr, ed. *Cleft Craft. The Evolution of the Surgery 1. The Unilateral Deformity*. Boston: Little Brown: 1976:123–131
11. Millard DR Jr. Personal approach to cleft lip. In: Millard DR Jr, ed. *Cleft Craft. The Evolution of the Surgery 1. The Unilateral Deformity*. Boston: Little Brown: 1976:165–173
12. Millard DR Jr. Rotation advancement principle in cleft lip closure. *Cleft Palate J* 1964;12:246–252
13. Millard DR Jr. A radical rotation in single harelip. *Am J Surg* 1958;95(2):318–322
14. Adenwalla HS, Narayanan PV. Unilateral cleft lip in surgical correction of facial deformities. In: Varghese Mani, ed. *New Delhi: Jaypee Brothers Medical Publishers (P) Ltd; 2010: 142–152*
15. Tennison CW. The repair of the unilateral cleft lip by the stencil method. *Plast Reconstr Surg* (1946) 1952;9(2):115–120
16. Randall P. A triangular flap operation for the primary repair of unilateral clefts of the lip. *Plast Reconstr Surg Transplant Bull* 1959;23(4):331–347
17. Sawhney CP. Geometry of single cleft lip repair. *Plast Reconstr Surg* 1972;49(5):518–521

18. Bose SC. C. Balakrishnan Lecture presented at the Annual Conference of the Association of Plastic Surgeons of India at Varanasi; 2008
19. Musgrave RM, Garrett WS Jr. The unilateral cleft lip. In: Converse JM, ed. *Reconstructive Plastic Surgery*. Vol III. WB Saunders, Philadelphia; 1964:2016–2047
20. Philip Kuo-Ting Chen, Noordhoff MS, Kane A. Repair of unilateral cleft lip. In: Nelligan PC, ed. *Plastic Surgery*. Elsevier; Philadelphia, 2012:517–549
21. Semb G, Brattstrom V, Molsted K, Prah-Andersen B, Shaw WC. The Euro Cleft Study: intercentre study of treatment outcomes in patients with complete cleft lip and palate. Part 1: introduction and treatment, experience. *Cleft Palate Craniofac J* 2005;42(1):64–68
22. Long RE Jr, Halthaway R, Daskalogiannakis J et al. The Americleft study: an inter center study of treatment outcomes for patient with unilateral cleft lip and palate part 1: principles and study design. *Cleft Palate Craniofac J* 2011;48:239–243
23. Agrawal K. Cleft palate repair and variations. *Indian J Plast Surg* 2009;42(Suppl):S102–S109
24. Millard DR Jr. But how to rotate and advance in a complete cleft: In Millard DR Jr, ed. *Cleft Craft. The Evolution of the Surgery*. vol.1. The Unilateral Deformity. Boston: Little, Brown; 1976:452–456
25. Millard DR Jr. About primary nasal correction. In Millard DR Jr, ed. *Cleft Craft. The Evolution of the Surgery 1. The Unilateral Deformity*. Boston: Little, Brown; 1976:251–267
26. Thomas C, Mishra P. Open tip rhinoplasty along with the repair of cleft lip in cleft lip and palate cases. *Br J Plast Surg* 2000;53(1):1–6
27. Trott JA, Mohan N. A preliminary report on open tip rhinoplasty at the time of lip repair in unilateral cleft lip and palate: the Alor Setar experience. *Br J Plast Surg* 1993;46(5):363–370
28. McComb HK, Coghlan BA. Primary repair of the unilateral cleft lip nose: completion of a longitudinal study. *Cleft Palate Craniofac J* 1996;33(1):23–30, discussion 30–31
29. Noordhoff MS. *The Surgical Technique for the Unilateral Cleft Lip Nasal Deformity*. Taiwan: Noordhoff Craniofacial Foundation; 1997
30. Demirseren ME, Ohkubo F, Kadomatsu K, Hosaka Y. A simple method for lower lateral cartilage repositioning in cleft lip nose deformity. *Plast Reconstr Surg* 2004;113(2):649–652
31. Narayanan PV, Adenwalla HS. Primary rhinoplasty at the time of unilateral cleft lip repair: a review and our protocol. *J Cleft Lip Palate Craniofac Anomal* 2015;2:92–97
32. Anderl H, Hussl H, Ninkovic M. Primary simultaneous lip and nose repair in the unilateral cleft lip and palate. *Plast Reconstr Surg* 2008;121(3):959–970
33. Smahel Z, Müllerová Z, Nejedlý A. Effect of primary repositioning of the nasal septum on facial growth in unilateral cleft lip and palate. *Cleft Palate Craniofac J* 1999;36(4):310–313
34. Millard DR Jr. Nasal and labial flaps for alveolar and hard palate closure. In: Millard DR Jr, ed. *Cleft Craft*. Vol 3. Alveolar and Palatal Deformities. Boston: Little, Brown and Co; 1976:249–262
35. Sommerlad BC. Cleft palate repair. In: Losee EJ, Kirschner RE, eds. *Comprehensive Cleft Care*. New York: McGraw Hill; 2008: 399–412
36. Adenwalla HS, Narayanan PV. Primary unilateral cleft lip repair. *Indian J Plast Surg* 2009;42(Suppl):S62–S70
37. Jigjinni V, Kangesu T, Sommerlad BC. Do babies require arm splints after cleft palate repair? *Br J Plast Surg* 1993;46(8): 681–685
38. Nakajima T, Yoshimura Y, Sakakibara A. Augmentation of the nostril splint for retaining the corrected contour of the cleft lip nose. *Plast Reconstr Surg* 1990;85(2):182–186
39. Walter C. Nasal deformities in cleft lip cases. *Facial Plast Surg* 1995;11(3):169–183
40. Chang CS, Por YC, Liou EJ, Chang CJ, Chen PK, Noordhoff MS. Long-term comparison of four techniques for obtaining nasal symmetry in unilateral complete cleft lip patients: a single surgeon's experience. *Plast Reconstr Surg* 2010;126(4):1276–1284
41. Rintala AE, Ranta R. Periosteal flaps and grafts in primary cleft repair: a follow-up study. *Plast Reconstr Surg* 1989;83(1): 17–24
42. Renkielska A, Wojtaszek-Slominska A, Dobke M. Early cleft lip repair in children with unilateral complete cleft lip and palate: a case against primary alveolar repair. *Ann Plast Surg* 2005;54(6):595–597, discussion 598–599
43. Millard DR Jr. Periosteal flaps and grafts. In: Millard DR Jr, ed. *Cleft Craft*. Vol. 3. Alveolar and Palatal Deformities. Boston: Little, Brown and Co; 1976: 357–374
44. Sato Y, Grayson BH, Garfinkle JS, Barillas I, Maki K, Cutting CB. Success rate of gingivoperiosteoplasty with and without secondary bone grafts compared with secondary alveolar bone grafts alone. *Plast Reconstr Surg* 2008;121(4):1356–1367, discussion 1368–1369
45. Hsieh CH, Ko EW, Chen PK, Huang CS. The effect of gingivoperiosteoplasty on facial growth in patients with complete unilateral cleft lip and palate. *Cleft Palate Craniofac J* 2010; 47(5):439–446
46. Berkowitz S, Mejia M, Bystrick A. A comparison of the effects of the Latham-Millard procedure with those of a conservative treatment approach for dental occlusion and facial aesthetics in unilateral and bilateral complete cleft lip and palate: part I. Dental occlusion. *Plast Reconstr Surg* 2004;113(1):1–18
47. Millard DR, Latham R, Huifen X, Spiro S, Morovic C. Cleft lip and palate treated by presurgical orthopedics, gingivoperiosteoplasty, and lip adhesion (POPLA) compared with previous lip adhesion method: a preliminary study of serial dental casts. *Plast Reconstr Surg* 1999;103(6):1630–1644
48. Yuzuriha S, Mulliken JB. Minor-form, microform, and mini-microform cleft lip: anatomical features, operative techniques, and revisions. *Plast Reconstr Surg* 2008;122(5):1485–1493
49. Narayanan PV, Adenwalla HS. Unfavourable results in the repair of the cleft lip. *Indian J Plast Surg* 2013;46(2):171–182
50. Jackson IT. In plastic surgery in infancy and childhood. In: Mustarde JC, Jackson IT, ed. 3rd ed. Churchill Livingstone; 1988:7
51. Patel KB, Mulliken JB. Correction of the vestibular web during primary repair of unilateral cleft lip. *Plast Reconstr Surg*, New York; 2014;134(4):600e–607e
52. Noordhoff SM, Chen PK. Unilateral cheiloplasty. In: Mathes SJ, ed. *Plastic Surgery 2nd ed*. Vol IV. Saunders Elsevier, Philadelphia; 2006
53. Powar RS, Kumar NV, Das R. A new tailored technique of vermilion repair in unilateral cleft lip. *J Plast Reconstr Aesthet Surg* 2013;66(7):896–899
54. Fisher DM. Unilateral cleft lip repair: an anatomical subunit approximation technique. *Plast Reconstr Surg* 2005;116(1): 61–71
55. Reddy SG, Reddy RR, Bronkorst EM, Prasad R, Kuijpers-Jagtman AM, Bergé S. Comparison of three incision to repair complete Unilateral cleft lip. *Plast Reconstr Surg* 2010;25(4):1208–1216