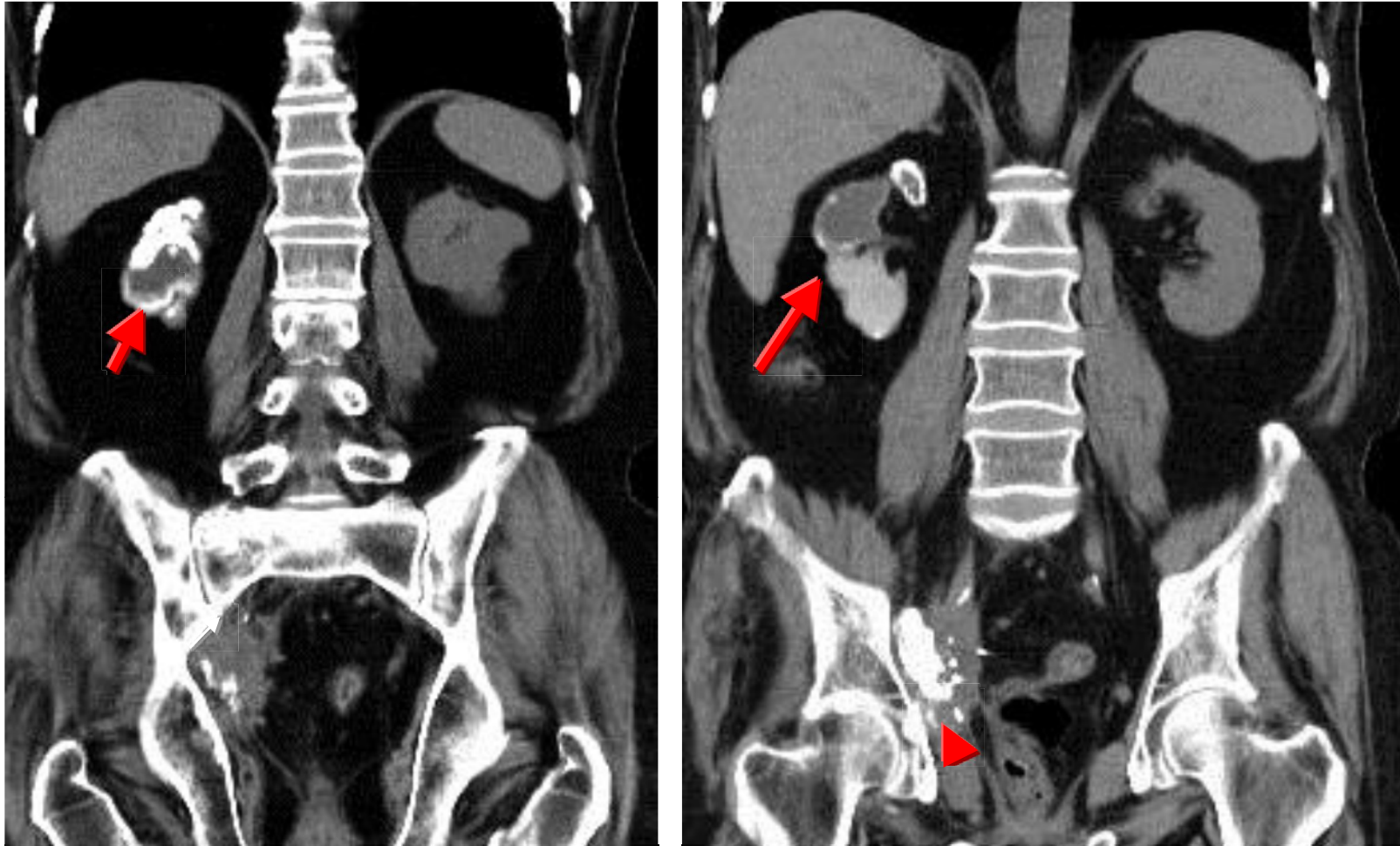


TB with autonephrectomy



- GU tract is 2nd common site of tuberculous infection after lungs.
- Diffuse calcification of right kidney (arrow) with shrinkage known as autonephrectomy & dense calcified shadow in right lower ureter (arrow head) with mass formation