

Clinical Outcome of Rotational Atherectomy in Acute Coronary Syndrome Patients: From the Taiwan Society of Cardiovascular Intervention Retrospective Registry

Yu-An Chen¹, Shih-Sheng Chang¹, Cho-Kai Wu², Hsin-Bang Leu³, Jung-Cheng Hsu⁴,
Ming-Jer Hsieh⁵, Yu-Chen Wang⁶, Wen-Lieng Lee⁷

¹China Medical University Hospital, Taichung, Taiwan

²National Taiwan University Hospital, Taipei, Taiwan

³Taipei Veterans General Hospital, Taipei, Taiwan

⁴Far Eastern Memorial Hospital, Taipei, Taiwan

⁵Chang Gung Memorial Hospital, Taipei, Taiwan

⁶Asia University Hospital, Taichung, Taiwan

⁷Taichung Veterans General Hospital, Taichung, Taiwan

Abstract

Background: With the increasing complexity of acute coronary syndrome (ACS) cases presenting for percutaneous coronary intervention (PCI) and increased identification of severe coronary calcification through the use of intravascular imaging, the Rotablator has become an important tool for optimal lesion preparation before stent deployment. We aim to analyze the clinical outcome after rotational atherectomy in ACS patients in Taiwan.

Methods and Materials: This registry study was a retrospective, multi-center, observational study including 215 consecutive ACS patients undergoing PCI with rotational atherectomy between January, 2018 and December, 2019. We collected data on lesion characteristics, procedural details, and angiographic complications. Clinical outcomes were followed up at 6 and 12 months.

Results: 145 (67.4%) males and 70 (32.6%) females were enrolled in this study, with the majority (62.3%) between 60 and 80 years of age. The procedural success rate was 97.2%. Procedural complications included coronary dissection (15.8%), cardiogenic shock (2.8%), no-reflow (1.9%), and coronary spasm (0.9%). The major adverse outcome after 6- and 12-months was non-fatal MI, accounting for 15.3% and 17.7%, respectively.

Conclusions: The procedural success rate of rotational atherectomy in patients with ACS was very high while the rate of serious procedural complications was quite low. Therefore, for patients ineligible for cardiac surgery or those with calcified, architecturally complex lesions, PCI with rotational atherectomy was effective and safe, with satisfactory revascularization results.

Keywords: acute coronary syndrome, coronary artery calcification, rotational atherectomy, Rotablator

Received: Jun. 24, 2022; Accepted: Jul. 14, 2022

Address for correspondence: Cho-Kai Wu, MD

Cardiovascular Center, National Taiwan University Hospital; No. 7, Chung-Shan South Road, Zhongzheng District, Taipei City 100225, Taiwan

Tel: +886-2-23123456; E-mail: wuchokai@gmail.com

Introduction

Coronary artery disease (CAD) is the leading cause of mortality and loss of disability adjusted life years (DALYs) worldwide.¹ Percutaneous coronary intervention (PCI) including percutaneous transluminal coronary angioplasty (PTCA), stent implantation, and drug-coated balloons (DCBs), is an effective treatment for CAD, which has improved through advancements in technologies and devices in recent decades.²⁻⁴ However, percutaneous treatment of heavily calcified coronary lesions remains a challenge. The prevalence of moderately and severely calcified coronary stenosis has been reported to range from 18% to 26%.⁵⁻⁷ Coronary calcification is associated with stent under-expansion, incomplete apposition, re-stenosis, thrombosis, and coronary dissection. Moreover, it is a predictor of worse clinical outcomes including higher mortality and major adverse cardiovascular events (MACEs).⁸⁻¹⁰

Rotational atherectomy (Boston Scientific, Natick, MA, USA), developed in the 1980s, is the most effective technique for the modification of calcified plaques, and facilitates stent placement during angioplasty.¹¹ This is an over-the-wire system utilizing a sized burr coated with around 1 Ohm diamond chips to ablate the inelastic material (e.g., plaques) rather than elastic material (e.g., normal arterial wall). The system is rotated in the stenosis region at 180,000 to 200,000 rpm. The Rotablator can reach narrow, tortuous and distal coronary lesions with a flexible helical drive shaft. Therefore, it is indicated for the treatment of diffusely calcified lesions and allows plaque modification by debulking to facilitate balloon and stent delivery.¹²

Although there are various indications for rotational atherectomy, its widespread use is still limited. One reason for this may be that rotational atherectomy is a demanding technique which requires device-specific training and experience to perform. Furthermore, rotational atherectomy is associated with several procedural complications

including coronary spasm, slow-flow / no-reflow, and entrapment of the burr, etc. To avoid these complications, contemporary rotational atherectomy has moved to lower burr-to-artery ratios and lower burr speeds than originally recommended.¹³

Current guidelines for coronary intervention recommend that rotational atherectomy PCI only be performed in medical centers with on-site cardiovascular surgical back-up. However, an increasing number of rotational atherectomy PCI procedures are being performed in non-surgical PCI centers worldwide.^{14,15} With mandatory training and proctored support for new operators and catheter laboratory teams, rotational atherectomy is a not uncommon technique in treating complex CAD in Taiwan. Therefore, we have conducted the present multi-center study to investigate the outcomes of ACS patients treated with rotational atherectomy in Taiwan.

Materials and Methods

Patients

This registry study was a retrospective, multi-center, observational study, which collected 233 consecutive acute coronary syndrome (ACS) patients from National Taiwan University Hospital (N=57), Taipei Veterans General Hospital (N=76), Taichung Veterans General Hospital (N=50), Far Eastern Memorial Hospital (N=15) and Linkou Chang Gung Memorial Hospital (N=35), who underwent PCI with rotational atherectomy between January, 2018 and December, 2019. After excluding patients based on pre-specified exclusion criteria, 215 patients were finally enrolled for analysis. The exclusion criteria included 1) patients under 20 years old, 2) patients who did not ultimately receive rotablation, 3) those with incomplete demographic data, 4) those lost to follow-up during the study period, and 5) patients who withheld informed consent (Figure 1). We reviewed the medical records and interventional characteristics retrospectively. We also collected the clinical outcomes including

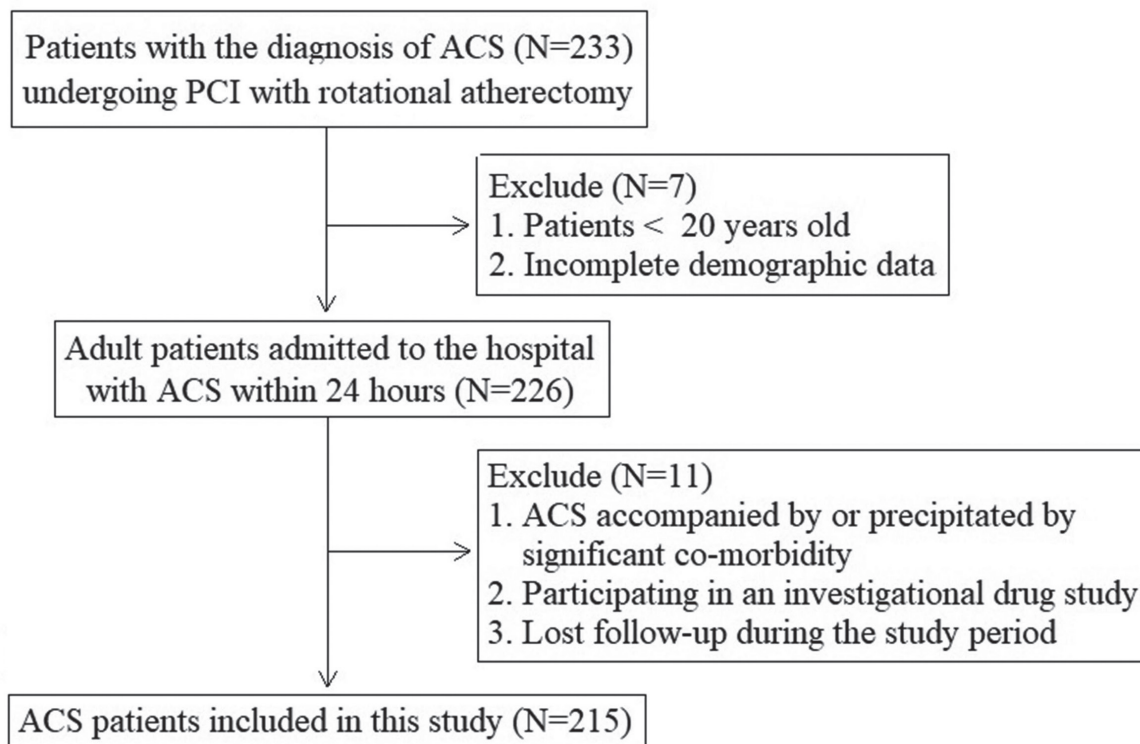


Figure 1. Study inclusion flow chart.

target lesion revascularization (TLR), delayed stent thrombosis, non-fatal myocardial infarction (MI), and all-cause mortality. All data were collected at each site using a standardized case report form. This study was conducted in strict accordance with the Declaration of Helsinki on Biomedical Research involving human subjects, and was approved by the local ethics committee (IRB: 202007135RINC).

Operative Technique

Rotational atherectomy was carried out with the Rotablator (Boston Scientific, Natick, MA, USA). Intracoronary nitroglycerin and/or verapamil were used to avoid coronary spasm. Antiplatelet therapy and peri-procedural anticoagulation were prescribed following the guidelines. Vascular access was through the femoral arteries, radial arteries, or brachial arteries. The Rotablator guidewire was used in all cases, and the Rotablator was advanced to the lesion and operated at 180,000 to 200,000

rpm to modify the calcified lesions. Subsequent balloon angioplasty was performed for further reduction of lumen stenosis or for treatment of coronary dissection/occlusion. The details and characteristics of each procedure were recorded.

Angiographic Analysis

We categorized all angiograms by lesion types, target vessels/sites, and lesion characteristics. Lesion types were classified according to the American College of Cardiology/American Heart Association (ACC/AHA) criteria, defined as type A, B, and C. Bifurcation lesions were defined as those involving a major or moderate-sized branch point. Calcified lesions were defined as angiographically visible calcifications. Procedural success was defined as residual stenosis < 30% in the presence of TIMI grade 3 flow, achieving technical success without MACEs (defined as all-cause mortality, cardiovascular mortality, MI, and TLR). Procedural complications included severe spasm, no-reflow, coronary perforation,

cardiogenic shock and severe coronary dissection (defined as a dissection of at least type B or above). Angiographic and clinical follow-up was carried out at 6 and 12 months. Angiographic re-stenosis was defined as stenosis > 50% of the lumen diameter at the site of rotational atherectomy.

Outcome

The endpoint of this study was the occurrence of target lesion revascularization (TLR), delayed stent thrombosis, non-fatal MI, CV death and non-CV death. MI was defined as any creatine kinase-myocardial band (CKMB) or troponin level elevation above the upper limit of the normal range with ischemic symptoms or signs during follow-up after discharge. CV death was further divided into three categories: sudden death, AMI and CVA. Clinical follow-up data were collected retrospectively, based on medical records and a physician or patient interview.

Statistical Analysis

Continuous normally distributed data were expressed as mean \pm standard deviation (SD) and compared using the Student t-test or Mann-Whitney U test. Categorical variables were presented as counts (percentages) and compared using the Chi-square or Fisher exact test. Event rates were estimated as Kaplan-Meier estimates. A univariate Cox regression analysis was performed to obtain the hazard ratio (HR) for clinical outcomes. Statistical differences were considered significant at a P value < 0.05. Statistical analysis was performed using the SPSS statistical package.

Results

Patient and Lesion Characteristics

Patients' clinical baseline data and lesion characteristics are shown in Tables 1 and 2, respectively. There were 145 (67.4%) male ACS patients and 70 (32.6%) female ACS patients, with the majority (62.3%) between 60 and 80 years of age. Comorbidities and risk factors included

hypertension, diabetes, and previous PCI, etc. 191 (88.8%) cases had calcified lesions, 58 (26.9%) cases had bifurcation lesions and 39 (18.1%) cases had lesions with chronic total occlusion (CTO). Most lesions belonged to type C (67%) and were of diffuse (73%) morphologies. Of the main target vessels, 65.1% involved the left anterior descending artery (LAD), and the most common lesion sites were in the proximal part (52.1%) of the coronary arteries.

Table 1. Demographic and clinical characteristics

Patient characteristics	Value (%)
Patent numbers	215
Age (years)	72.2 \pm 10.5
20-39 years	2 (0.9)
40-59 years	20 (9.3)
60-80 years	134 (62.3)
\geq 80 years	59 (27.4)
Sex	
Male	145 (67.4)
Female	70 (32.6)
Comorbidities	
Hypertension	179 (83.3)
Diabetes	137 (63.7)
Dyslipidemia	115 (53.5)
MI	30 (14.0)
CHF	27 (12.6)
PAOD	15 (7.0)
Gout	18 (8.4)
CABG history	15 (7.0)
PCI history	87 (40.5)
CRF	47 (21.9)
Hemodialysis	41 (19.1)
Smoking	44 (20.5)
Obesity	56 (26.0)

MI: myocardial infarction, CHF: congestive heart failure, PAOD: peripheral artery occlusive disease, CABG: coronary artery bypass graft, CRF: chronic renal failure.

**Table 2.** Lesion characteristics and analysis

Lesion characteristics	Value (%)
Bifurcation lesion	58 (26.9)
Calcified lesion	191 (88.8)
CTO	39 (18.1)
Target vessel	
LM to LAD	10 (4.7)
LAD	140 (65.1)
LCX	16 (7.4)
OM	1 (0.5)
RCA	48 (22.3)
Lesion site	
Ostial	48 (22.3)
Proximal	112 (52.1)
Middle	69 (32.1)
Distal	26 (12.1)
Lesion morphology	
Type A	6 (2.8)
Type B	65 (30.2)
Type C	144 (67.0)
Lesion length	
Diffuse	157 (73.0)
Discrete	39 (18.1)
Tubular	17 (7.9)
Thrombosis	2 (0.9)

CTO: chronic total occlusion, LAD: left anterior descending artery, LCX: left circumflex artery, RCA: right coronary artery, OM: obtuse marginal artery.

Procedural Results and Complications

Table 3 shows procedural results of this study. Vascular access was obtained mostly through femoral arteries (56.3%), followed by radial arteries (41.9%) and brachial arteries (0.9%). Rota floppy guidewires were the most used wires (87.4%) for rotablation. Intravascular ultrasound (IVUS) and microcatheter were used as assistant devices in 124 (57.6%) cases and 102 (47.4%) cases, respectively. The average contrast volume

Table 3. Procedural results and analysis

Procedure details and results	Value (%)
Vascular access	
Femoral	121 (56.3)
Radial	88 (40.9)
Brachial	2 (0.9)
Others	4 (1.8)
Guidewire	
Rota floppy	188 (87.4)
Extra support or others	27 (12.6)
Assistant device	
IVUS	124 (57.6)
Microcatheter	102 (47.4)
OCT	24 (11.1)
Contrast volume	151.0 ± 90.1
eGFR	52.5 ± 34.8
Procedure success	209 (97.2)

IVUS: intravascular ultrasound, OCT: optical coherence tomography, eGFR: estimated glomerular filtration rate.

was 151.0 ± 90.1 ml, and the average eGFR was 52.5 ± 34.8 ml/min/1.73m². Overall, the procedure success rate reached 97.2%. Procedural complications included coronary dissection (15.8%), cardiogenic shock (2.8%), no-reflow (1.9%) and coronary spasm (0.9%) (Figure 2).

6- and 12-Month Clinical Follow-up

Clinical follow-up data at 6- and 12-months after rotational atherectomy is summarized in Table 4. Clinical TLR rate was 3.3% at 6 months and 6.5% at 12 months. Angiographic TLR rate was 1.4% at 6 months and 4.6% at 12 months. In one case (0.5%) delayed stent thrombosis was detected at the 6-month follow-up. Non-fatal MI occurred in 38 (15.3%) patients after 6 months and 38 (17.7%) patients after 12 months. Five (2.3%) patients had died of cardiovascular (CV) causes after 6 months and 12 months. Three (1.4%) patients had died of non-CV causes after 6 months and 4 (1.9%) patients after 12 months.

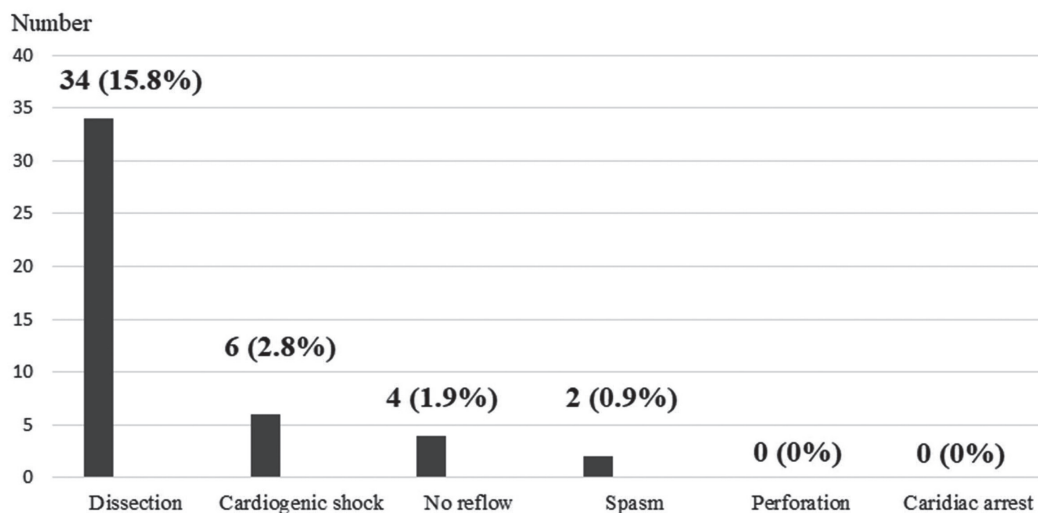


Figure 2. Procedural complications.

Table 4. Six- and Twelve-month clinical follow-up

Outcome	Value (%)	
	6 M	12 M
Clinical outcome (Recurrence of angina or stress positive) TLR	7 (3.3)	14 (6.5)
Angiographic outcome (binary re-stenosis) TLR	3 (1.4)	10 (4.6)
Delayed stent thrombosis	1 (0.5)	1 (0.5)
Non-fatal MI	33 (15.3)	38 (17.7)
CV death: sudden cardiac death	2 (0.9)	2 (0.9)
CV death: AMI	2 (0.9)	2 (0.9)
CV death: CVA	1 (0.5)	1 (0.5)
Non-CV death	3 (1.4)	4 (1.9)

TLR: target lesion revascularization, CV: cardiovascular, AMI: acute myocardial infarction, CVA: cerebrovascular accident.

Discussion

The latest recommendations of the 2018 ESC/EACTS highlight the importance of optimal lesion preparation before stent placement for successful percutaneous angioplasty.¹⁶ In addition to balloon angioplasty, using a cutting balloon or rotational atherectomy for the preparation of well-selected lesions, such as severely calcified lesions, is recommended. The Rotablator was the first high-speed rotational atherectomy device,

developed in the 1980s. In the preparation of hard lesions it is superior to conventional balloon angioplasty. Complications of rotational atherectomy are rare but serious, so it must only be used by experienced interventional cardiologists with specific training and after sufficient case numbers.

Coronary artery calcification (CAC) is an important risk factor for adverse outcomes in patients with CAD. Risk factors for CAC include advanced age, hypertension, diabetes,



dyslipidemia, male gender, cigarette smoking, and renal etiology. It is well acknowledged that calcium regulatory mechanisms have an influence on coronary artery calcification. Alkaline phosphatase invokes early calcium deposition and subsequent vascular calcification. Vascular smooth muscle cells produce matrix vesicles, which regulate mineralization in the vascular intima and media. Microvascular pericytes and adventitial myofibroblasts produce mineralized matrix and undergo osteoblastic differentiation, resulting in calcified deposits.¹⁷⁻²⁰ In this registry study, we analyzed 215 complex ACS cases from five medical centers in Taiwan. The enrolled patients were predominantly male and of advanced age. Moreover, there was a high percentage of hypertension, diabetes, and history of previous PCI in these patients. These factors all contributed to the development of CAC.

In our study, more than half of the patients received the procedures via femoral artery access. Actually, the procedural success rate is not related to the vascular approach, i.e. radial or femoral approach. Some studies show that radial artery access is a feasible, safe, and effective approach for high-speed rotational atherectomy. Overall complication rates are low using radial access, and radial access might be associated with a lower risk of major bleeding events, compared to the femoral approach. Nevertheless, the radial approach might be unsuitable for certain Rotablator procedures, such as those requiring large caliber catheters for the passage of 2.0 mm or larger burrs.^{21,22}

In recent years, several large studies have reported on procedural and clinical outcomes of PCI with rotational atherectomy. The European multicenter Euro4C registry, which is a prospective international registry in 8 European countries and 19 centers, has shown a clinical success rate of 91.9%. The rate of in-hospital MACE is 4.7%, and the 1-year MACE rate is 13.2%. In addition, 1-year MACE occurrence is independently associated with female gender, renal failure, ACS at admission, decreased left ventricular ejection fraction (LVEF) and presence of a significant

left main coronary artery (LMCA) lesion.²³ The J2T Multicenter Registry, which includes the largest Japanese dataset for long-term follow-up of rotational atherectomy, shows a procedural success rate of 96.2%. Furthermore, the rates of in-hospital death, MI and cardiac tamponade are 3.0%, 2.1%, and 0.9%, respectively. During the median follow-up period of 3.8 years, the incidence of MACE is 46.7%. Moreover, advanced age and hemodialysis are strong independent predictors of MACE.²⁴ The latest published meta-analysis of rotational atherectomy in ACS includes 8 retrospective studies with a total population of 1237 and has a median follow-up of 23 months. It shows an angiographic success rate of 97.4%; the incidence of total procedural complications is 7%, and the perforation rate is 1%. The rates of all-cause mortality and cardiac mortality are 5% and 2%, respectively. Rates of in-hospital MACE and long-term MACE are 7% and 29%, respectively.²⁵

Notably, rotational atherectomy was previously considered relatively contraindicated in ACS because of unstable plaques, potential complications associated with platelet activation and the risk of thrombotic events. However, due to advances in the technique of rotational atherectomy and improved antiplatelet pharmacotherapy, rotational atherectomy is now widely used for ACS as well.²⁶ A key factor in the increasing success rates of rotablation for ACS patients has been the time interval between recent MI and rotational atherectomy. Very early rotablation after an MI might be associated with increased angiographic and ischemic complications. Moreover, larger burr-to-artery ratios (> 0.7) and more aggressive debulking have been shown to increase periprocedural infarction and angiographic major complications.²⁷ Doshi SN et al. conducted a comparative study of rotational atherectomy in 1,112 patients, comprising 843 stable coronary syndrome (SCS) patients and 269 ACS patients. The ACS group shows more angiographic complications than the SCS group, including side branch closure (4.5% vs. 2%, p

= 0.029), slow flow (4.1% vs. 2.9%, $p = 0.31$) and residual dissection (10.4% vs. 7.5%, $p = 0.13$). However, there is no difference in major complications (defined as death, emergency bypass surgery, MI, or peak CKMB 8 times the upper limit of normal) between the two groups (ACS 1.1% vs. SCS 0.8%; $p = 0.44$). In addition, the 30-day MACE rate is similar for the ACS and SCS groups (5.9% vs. 4.6%, $p = 0.38$).²⁸ A more recent study conducted by Kübler P et al. reports similar results. 164 stable angina (SA) patients and 43 ACS patients who underwent rotational atherectomy were enrolled. Postprocedural complications are more frequent in the ACS group, including contrast induced nephropathy (9.3% vs. 1.2%, $p < 0.01$) and access site bleedings (14.0% vs. 4.9%, $p = 0.03$), while 1-year follow-up MACE rate and mortality are numerically higher but without significance (25.6% vs. 16.5%, $p = 0.17$ and 16.3% vs. 7.9%, $p = 0.1$, respectively).²⁹

In our registry study, the procedural success rate was promising, reaching 97.2%, despite some complications occurring. We further analyzed the complication events, and found that coronary dissection accounted for the majority of procedural complications. Other rare immediate complications during rotablation included cardiogenic shock, no-reflow, and coronary spasm. Rotational atherectomy exposes patients to the same complications as conventional angioplasty, but with different implications. Several review studies have reported that the Rotablator increases the risks of coronary perforation, vessel spasm, and no-reflow. In an analysis of the Mayo Clinic PCI database, the use of rotational atherectomy appeared to be an independent risk factor for coronary perforation, with a perforation rate of 1.2%. The tamponade rate among perforated patients is 11.6% and in-hospital mortality is 7.4%. By contrast, rotational atherectomy does not increase the risks of in-hospital MACE, periprocedural MI, and emergent CABG.^{22,30,31} On the contrary, in our registry study, no patients developed coronary perforation or cardiac

arrest during rotational atherectomy. Therefore, under certain circumstances (e.g., patients are ineligible for rotablation or have architecturally complex lesions and judicious management), rotational atherectomy can still assist in achieving satisfactory results. To sum up, our current registry study enrolled a group of high-risk patients with multiple comorbidities. Despite this, the overall success rate in our study was even higher than most previous registries, which may be due to the high average quality of coronary intervention and mature rotablation technique in Taiwan.

In this registry study, the 1-year follow-up MACE rate was 33.5%, nearly 2.5 times higher than that of the European multicenter Euro4C registry. In addition, the major adverse outcome at 6 months and 12 months was non-fatal MI, reaching 15.3% and 17.7%, respectively. The reason for the high MACE rate might be that ACS patients are a high-risk group and are susceptible to MI. Some studies have demonstrated that after rotational atherectomy, the risks of clinical events including stent thrombosis, unscheduled or urgent revascularization, TLR and MI increased at the one-year follow-up. Of note, in these studies, MI mostly referred to type 1 and type 4b infarctions.³²

Limitations

Several limitations of this study should be noted when interpreting the data presented. First, our study subjects were all ACS patients, who may have higher adverse outcome rates compared to patients with stable CAD, regardless of the use of rotablation atherectomy. Second, the lack of core laboratory analysis data might have adversely influenced the accuracy of reported outcomes. Third, we did not further analyze predictors associated with MACE. Fourth, this was a retrospective clinical follow-up study without angiography-oriented follow-up. As a result, patients with silent myocardial ischemia or coronary in-stent re-stenosis may have been missed when counting clinical events.

Conclusions

The procedural success rate of rotational atherectomy in patients with ACS was very high and the rate of serious procedural complications was very low. Therefore, it can be concluded that for patients ineligible for cardiac surgery or for those with calcified, architecturally complex lesions, PCI with rotational atherectomy was effective and safe, and provided satisfactory revascularization results.

References

- Ralapanawa U, Sivakanesan R. Epidemiology and the magnitude of coronary artery disease and acute coronary syndrome: A narrative review. *J Epidemiol Glob Health* 2021;11(2):169-77.
- Taniwaki M, Stefanini GG, Silber S, et al. 4-Year clinical outcomes and predictors of repeat revascularization in patients treated with new-generation drug-eluting stents. *J Am Coll Cardiol* 2014;63(16):1617-25.
- Xaplanteris P, Fournier S, Pijls NHJ, et al. Five-year outcomes with PCI guided by fractional flow reserve. *N Engl J Med* 2018;379:250-9.
- Hong SJ, Mintz GS, Ahn CM, et al. Effect of intravascular ultrasound-guided drug-eluting stent implantation: 5-year follow-up of the IVUS-XPL randomized trial. *J Am Coll Cardiol Interv* 2020;(1):62-71.
- Giustino G, Mastoris I, Baber U, et al. Correlates and impact of coronary artery calcifications in women undergoing percutaneous coronary intervention with drug-eluting stents: from the Women in Innovation and Drug-Eluting Stents (WIN-DES) Collaboration. *JACC Cardiovasc Interv* 2016;9:1890-901.
- Huisman J, van der Heijden LC, Kok MM, et al. Two-year outcome after treatment of severely calcified lesions with newer-generation drug-eluting stents in acute coronary syndromes: a patient-level pooled analysis from TWENTE and DUTCH PEERS. *J Cardiol* 2017;69:660-5.
- Copeland-Halperin RS, Baber U, Aquino M, et al. Prevalence, correlates, and impact of coronary calcification on adverse events following PCI with newer-generation DES: findings from a large multiethnic registry. *Catheter Cardiovasc Interv* 2018; 91:859-66.
- Bourantas CV, Zhang YJ, Garg S, et al. Prognostic implications of coronary calcification in patients with obstructive coronary artery disease treated by percutaneous coronary intervention: a patient-level pooled analysis of 7 contemporary stent trials. *Heart* 2014;100:1158-64.
- Généreux P, Redfors B, Witzenbichler B, et al. Two-year outcomes after percutaneous coronary intervention of calcified lesions with drug-eluting stents. *Int J Cardiol* 2017;231:61-7.
- Sorini Dini C, Nardi G, Ristalli F, et al. Contemporary approach to heavily calcified coronary lesions. *Interv Cardiol* 2019;14(3):154-63.
- Reisman M. Technique and strategy of rotational atherectomy. *Cathet Cardiovasc Diagn* 1996; Suppl 3: 2-14.
- Warth DC, Leon MB, O'Neill W, et al. Rotational atherectomy multicenter registry: acute results, complications and 6-month angiographic follow-up in 709 patients. *J Am Coll Cardiol* 1994;24(3):641-8.
- Gupta T, Weinreich M, Greenberg M, et al. Rotational Atherectomy: A Contemporary Appraisal. *Interv Cardiol* 2019;14(3):182-9.
- Sharma SK, Tomey MI, Teirstein PS, et al. North American expert review of rotational atherectomy. *Circ Cardiovasc Interv* 2019;12(5):e007448.
- Sakakura K, Ito Y, Shibata Y, et al. Clinical expert consensus document on rotational atherectomy from the Japanese association of cardiovascular intervention and therapeutics. *Cardiovasc Interv Ther* 2021;36(1):1-18.
- Neumann FJ, Sousa-Uva M, Ahlsson A, et al. 2018 ESC/EACTS Guidelines on myocardial revascularization. *Eur Heart J* 2019;40(2):87-165.
- Demer LL, Tintut Y. Vascular calcification: pathobiology of a multifaceted disease. *Circulation* 2008;117(22):2938-48.
- Johnson RC, Leopold JA, Loscalzo J. Vascular calcification: pathobiological mechanisms and clinical implications. *Circ Res* 2006;99(10):1044-59.
- Abedin M, Tintut Y, Demer LL. Vascular calcification: mechanisms and clinical ramifications. *Arterioscler Thromb Vasc Biol* 2004;24(7):1161-70.
- Madhavan MV, Tarigopula M, Mintz GS, et al. Coronary artery calcification: pathogenesis and prognostic implications. *J Am Coll Cardiol* 2014; 63(17):1703-14.
- Watt J, Oldroyd KG. Radial versus femoral approach for high-speed rotational atherectomy. *Catheter Cardiovasc Interv* 2009;74(4):550-4.
- Seret DG, Perier DM, Corcos DT, et al. Mise au point sur l'athérectomie rotationnelle à haute vitesse par Rotablator en 2021 et données du registre France



- PCI [Focus on high speed rotational atherectomy by Rotablator in 2021 and data from France PCI registry]. *Ann Cardiol Angeiol (Paris)* 2021;70(6):435-45.
23. Bouisset F, Barbato E, Reczuch K, et al. Clinical outcomes of PCI with rotational atherectomy: the European multicentre Euro4C registry. *EuroIntervention* 2020;16(4):e305-12.
 24. Okai I, Dohi T, Okazaki S, et al. Clinical Characteristics and Long-Term Outcomes of Rotational Atherectomy - J2T Multicenter Registry. *Circ J* 2018; 82(2):369-75.
 25. Qaqish O, Sharma S, Kumar A, et al. Rotational atherectomy in acute coronary syndrome: A meta-analysis. *Cardiovasc Revasc Med* 2022:S1553-8389(22) 00102-6. doi: 10.1016/j.carrev.2022.02.020. Epub ahead of print.
 26. Williams MS, Collier BS, Väänänen HJ, et al. Activation of platelets in platelet-rich plasma by rotablation is speed-dependent and can be inhibited by abciximab (c7E3 Fab; ReoPro). *Circulation* 1998 98(8):742-8.
 27. Whitlow PL, Bass TA, Kipperman RM, et al. Results of the study to determine Rotablator and transluminal angioplasty strategy (STRATAS). *Am J Cardiol* 2001;87:699-705.
 28. Doshi SN, Kini A, Kim MC, et al. A comparative study of rotational atherectomy in acute and stable coronary syndromes in the modern era. *Am J Cardiol* 2003;92(12):1404-8.
 29. Kübler P, Zimoch W, Kosowski M, et al. Acute coronary syndrome - Still a valid contraindication to perform rotational atherectomy? Early and one-year outcomes. *J Cardiol* 2018;71(4):382-8.
 30. Wasiake J, Law J, Watson P, et al. Percutaneous transluminal rotational atherectomy for coronary artery disease. *Cochrane Database Syst Rev* 2012; 12(12):CD003334.
 31. Fasseas P, Orford JL, Panetta CJ, et al. Incidence, correlates, management, and clinical outcome of coronary perforation: analysis of 16,298 procedures. *Am Heart J* 2004;147(1):140-5.
 32. Abdel-Wahab M, Baev R, Dieker P, et al. Long-term clinical outcome of rotational atherectomy followed by drug-eluting stent implantation in complex calcified coronary lesions. *Catheter Cardiovasc Interv* 2013;81(2):285-91.