

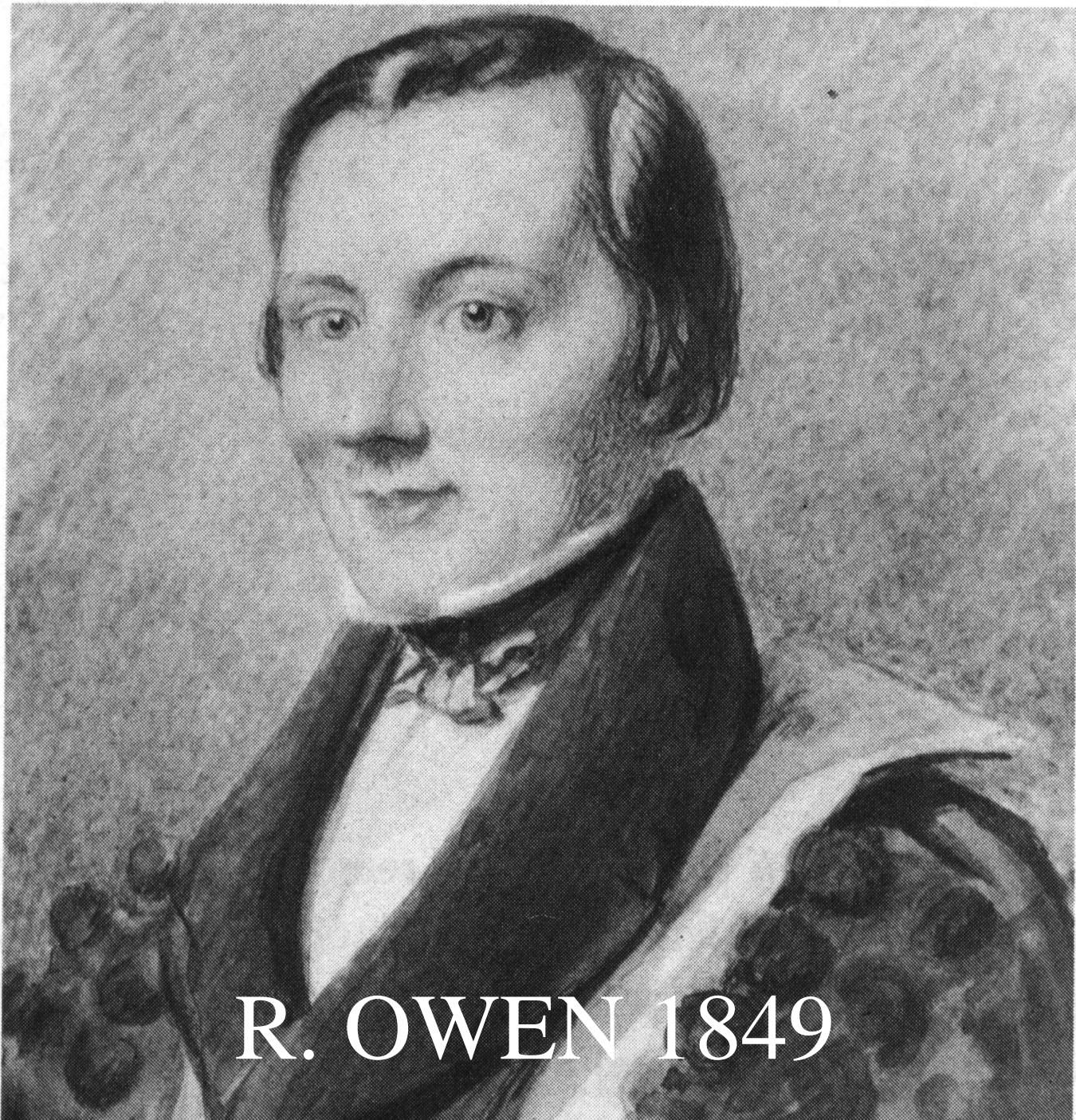
CIRUGÍA DE LAS GLÁNDULAS PARATIROIDES

TIPOS

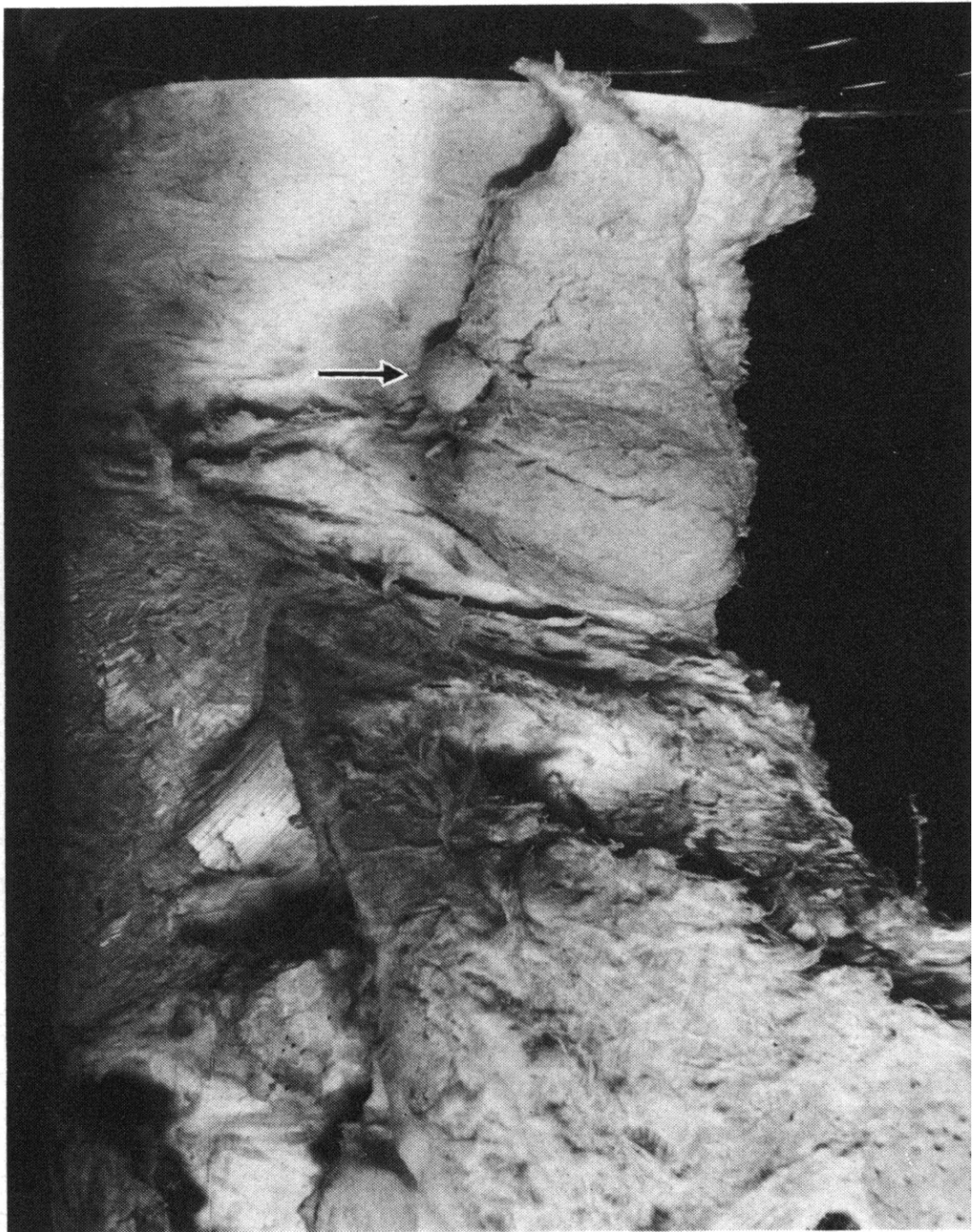
HIPERPARATIROIDISMO PRIMARIO

HIPERPARATIROIDISMO SECUNDARIO

HIPERPARATIROIDISMO TERCARIO



R. OWEN 1849





Sandström 1877-1880



Von Recklinghausen 1891

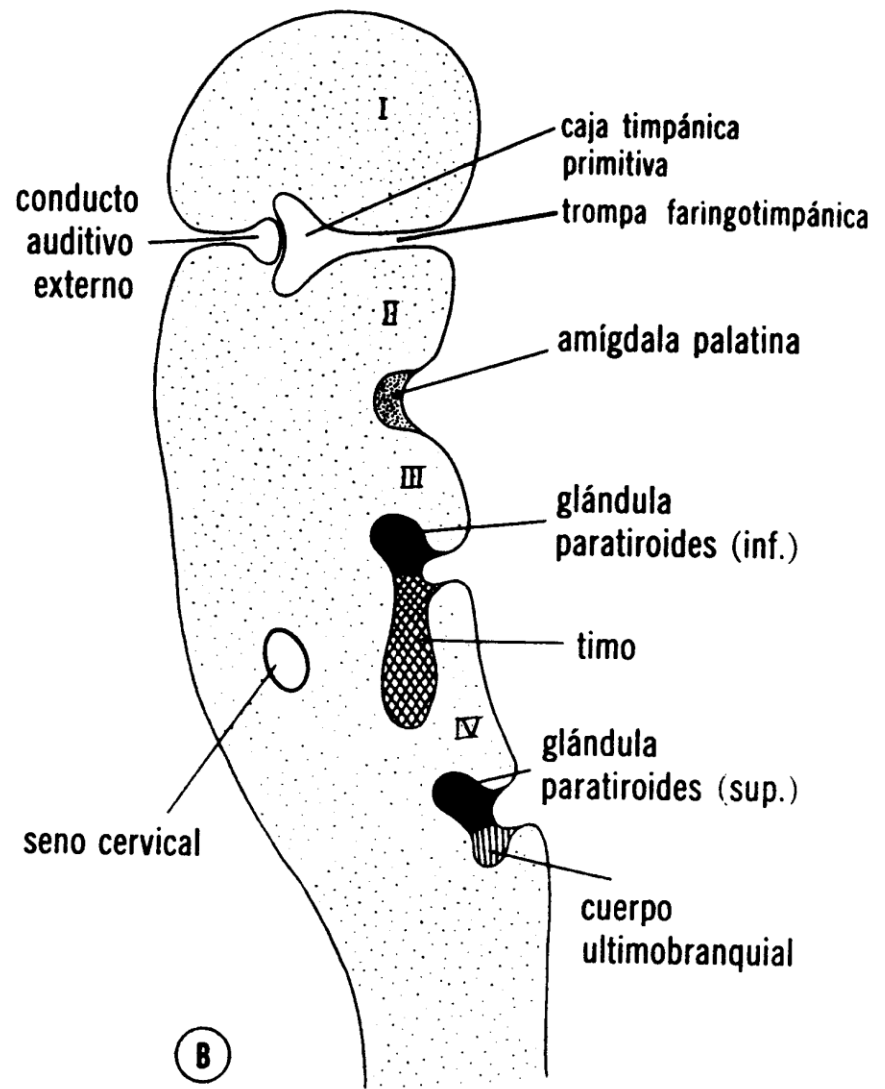
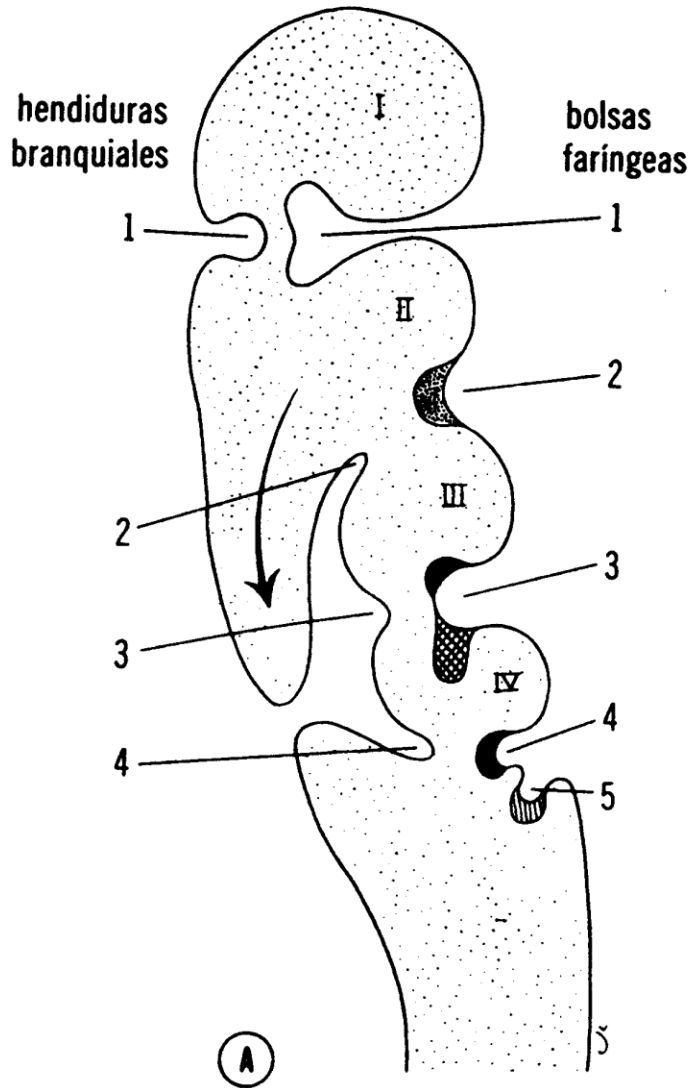

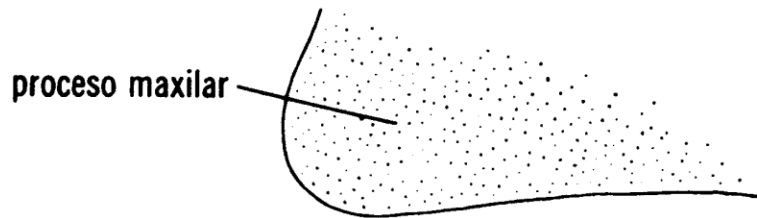
PROGRESOS EN EL CONOCIMIENTO DE LA ENFERMEDAD

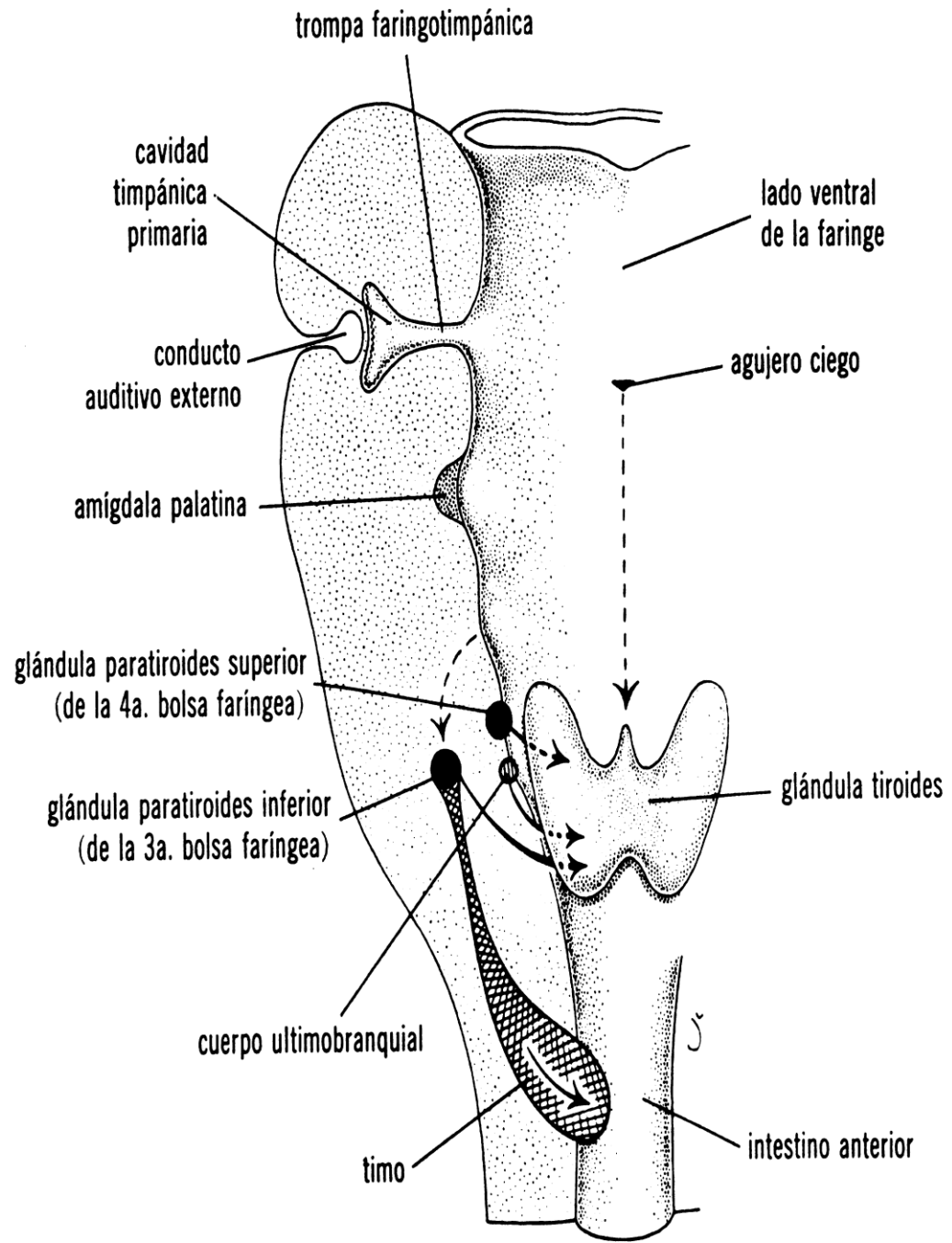
MANDL 1925

EEUU 1934

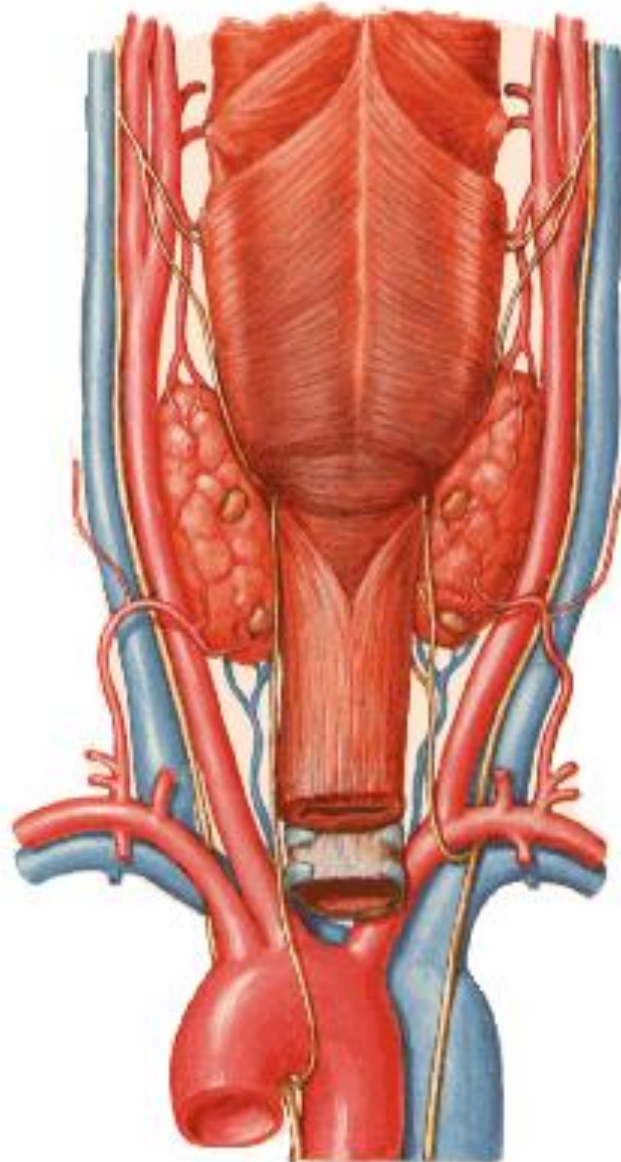
PTH 1959

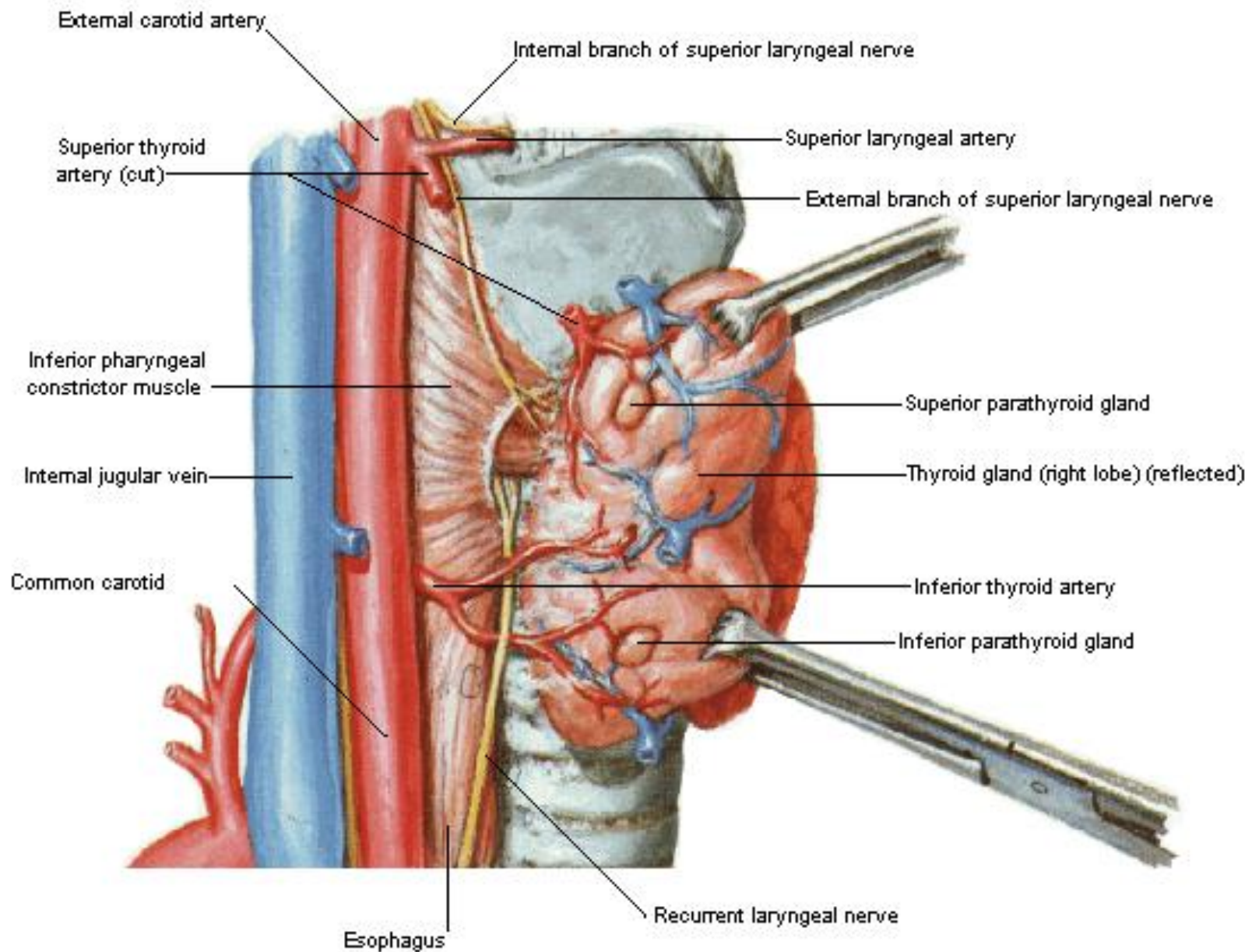
RIA 1963



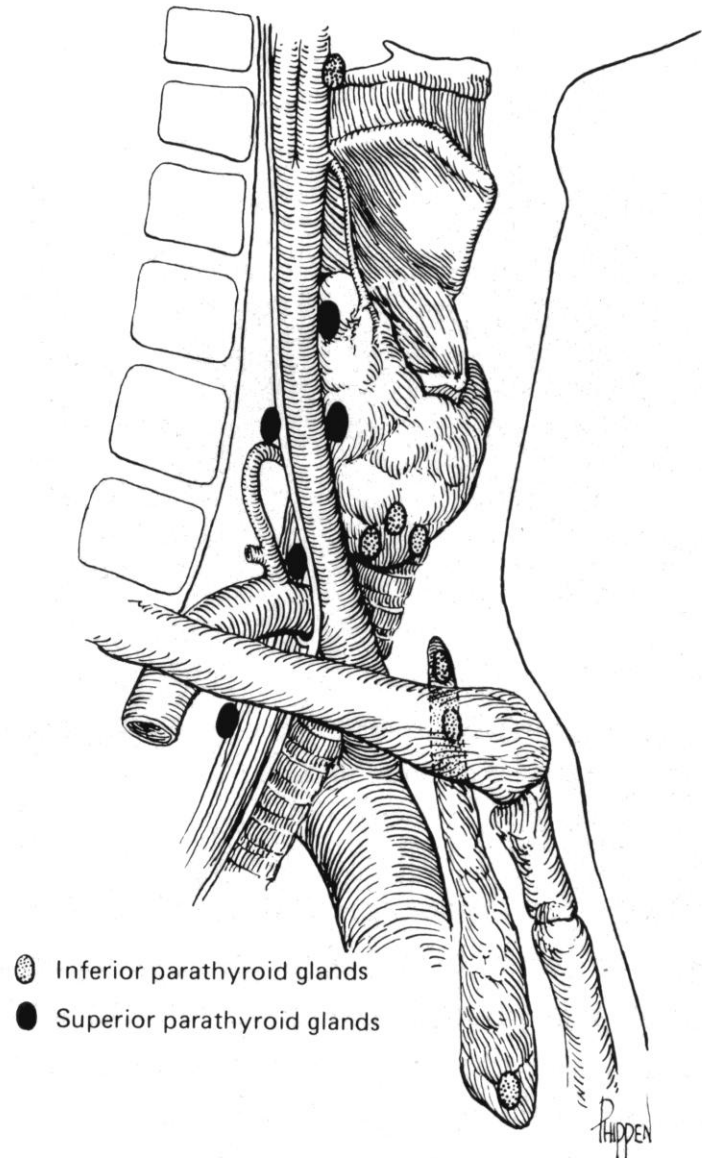


GLÁNDULAS PARATIROIDES VISTA POSTERIOR





Surgical Anatomy of Hyperparathyroidism



Ectopias “Congénitas”: III
Ectopias “Adquiridas”: IV

Fig. 2. Lateral view of the locations of superior and inferior gland adenomas. Note that normal superior glands are rarely found in the posterior upper mediastinum.

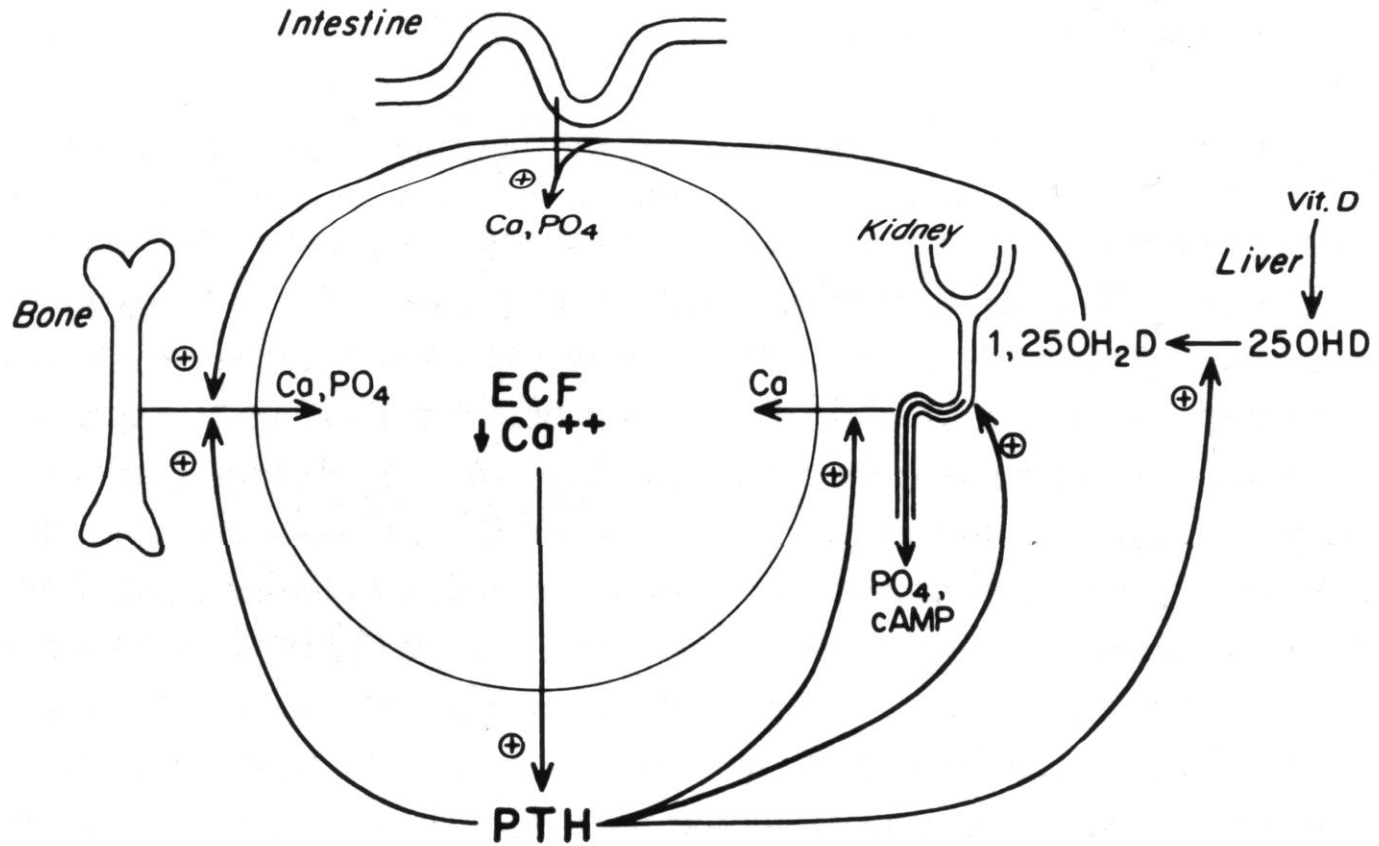


Fig. 2. Principal features of the calcium homeostatic system, indicating the manner in which PTH and $1,25(\text{OH})_2$ vitamin D regulate calcium and phosphate concentrations in the ECF. From ref. [14] with permission.

HIPERPARATIROIDISMO PRIMARIO

ADENOMA	75-90%
HIPERPLASIA	10-25%
CARCINOMA	1-4%
QUISTE	1%

HEREDITARIO (MEN)

Cel. principales > cel. claras

HIPERPARATIROIDISMO SECUNDARIO

HIPERPLASIA DE TODAS LAS GLÁNDULAS

HIPERPARATIROIDISMO PRIMARIO

RIÑÓN

Nefrocalcinosis
Nefrolitiasis
HTA

HUESO

OFQ Dolor
Fracturas patológicas
Quistes

A. DIG.

Pancreatitis
Colelitiasis
Úlcus péptico
Nauseas/vómitos
Anorexia

NEUROMUSCULARES

PSIQUIÁTRICOS

POLIURIA / POLIDIPSIA

CRISIS HIPERCALCÉMICA

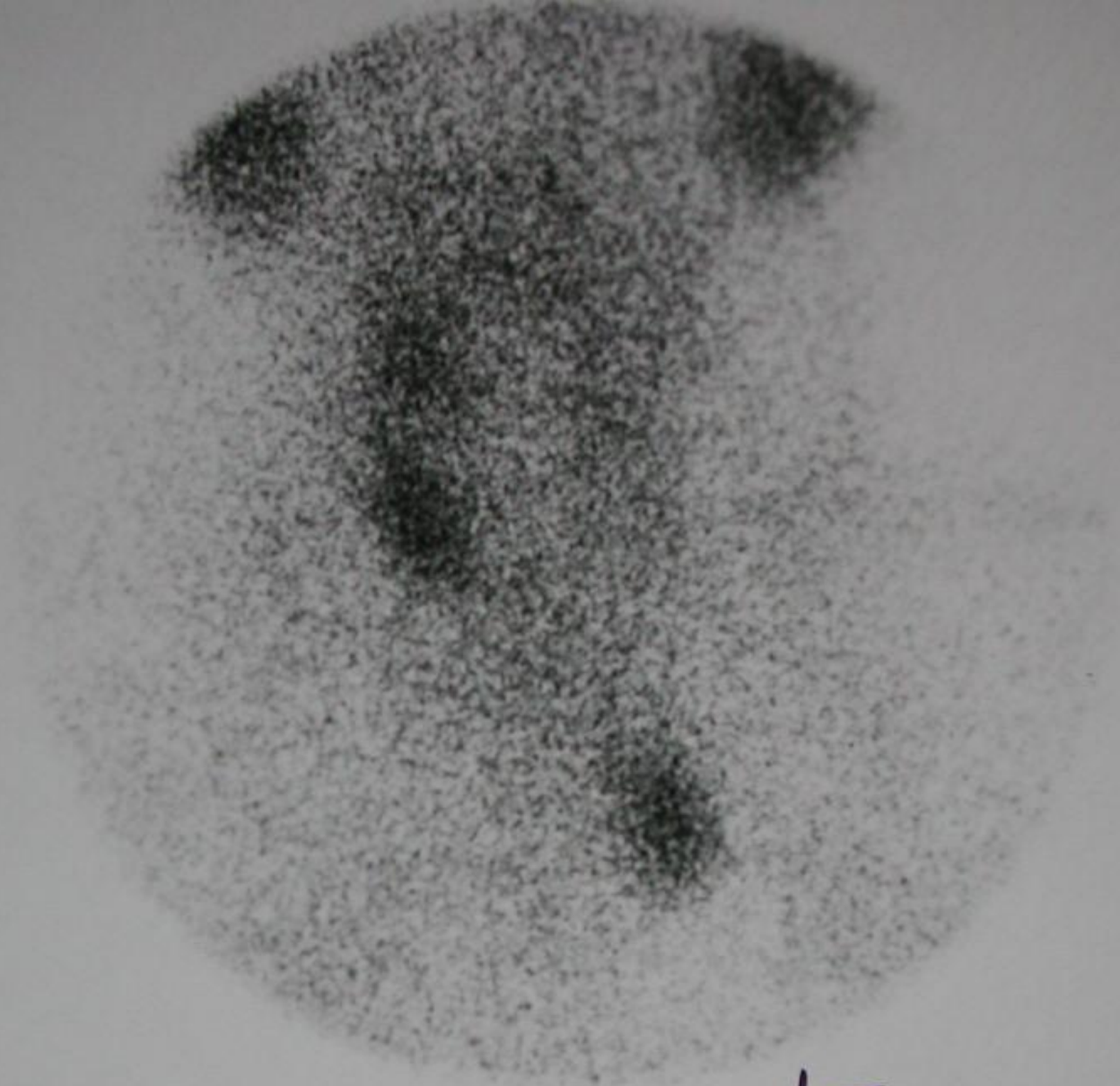
DIAGNÓSTICO

LABORATORIO

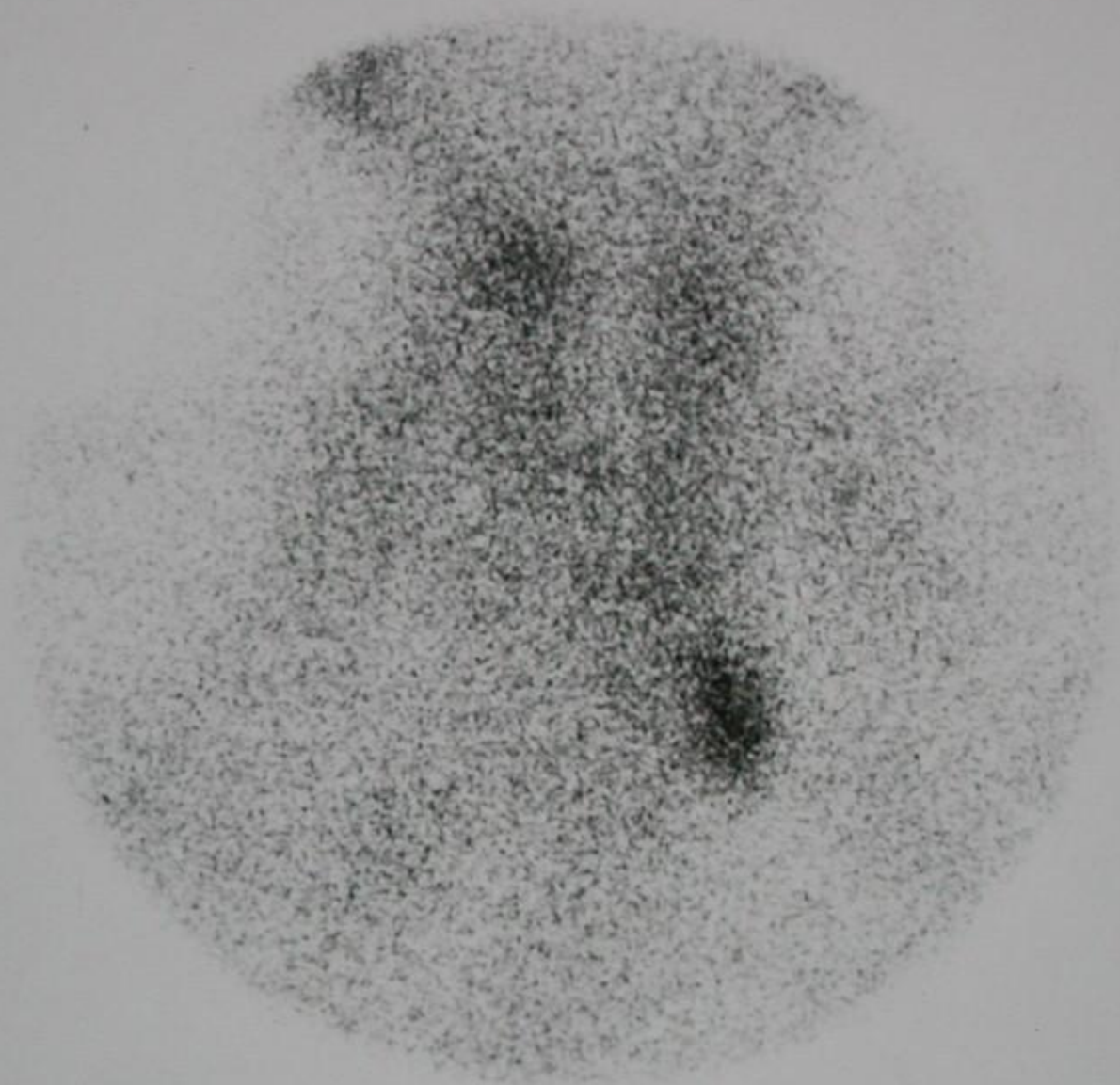
Hipercalcemia
Elevación PTH
Hipofosfatemia
Elev. F Alcalina
Hipercalciuria

IMAGEN

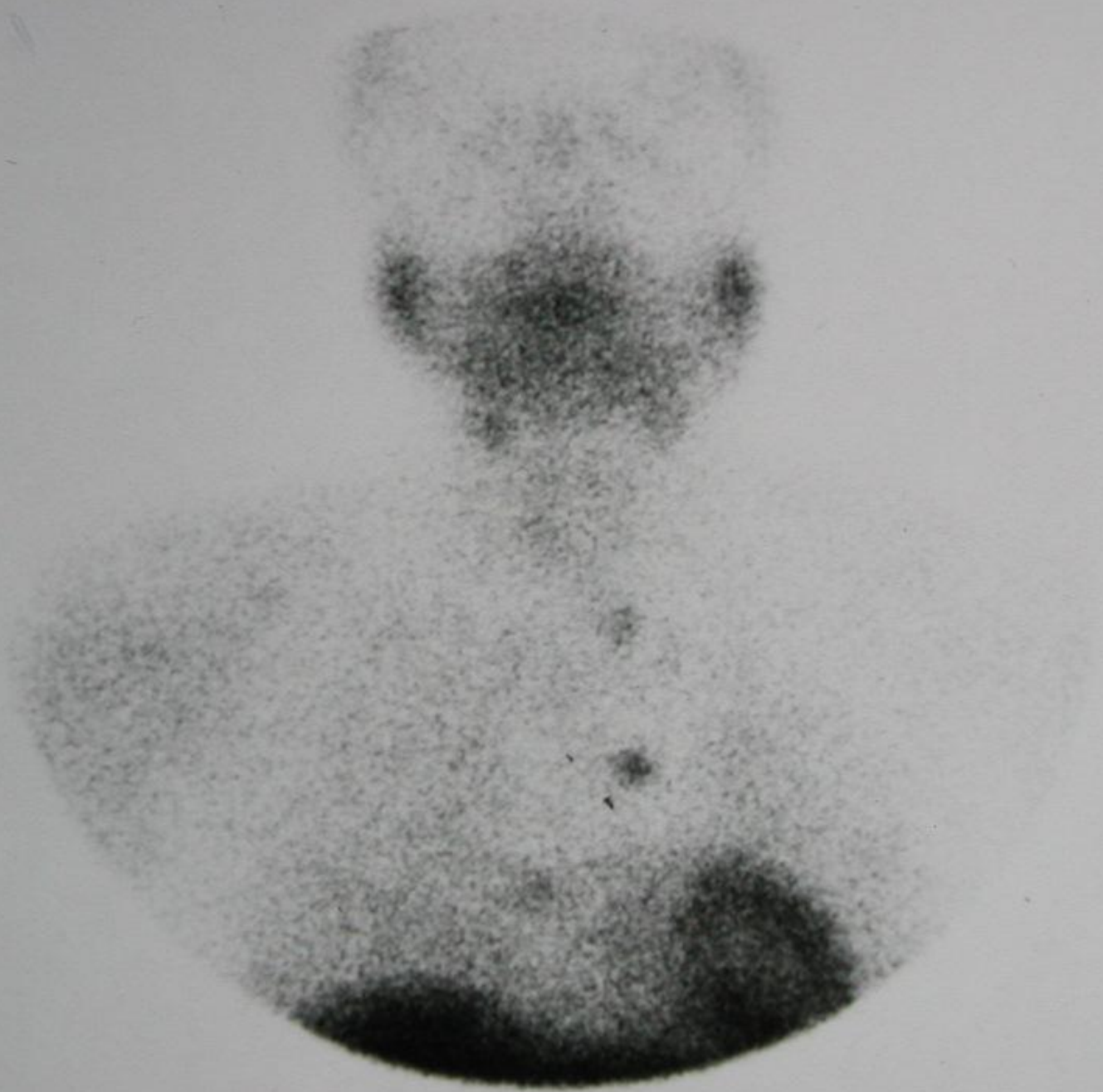
Rx ósea
Rx abdomen
Ecografía
TAC
RNM
99Tc Sestamibi
Rx vascular



10 minutes



3 - rows



TRATAMIENTO QUIRÚRGICO

Todos tienen indicación quirúrgica

UNIGLANDULAR

Exéresis de la patológica
y biopsia de una sana

PLURIGLANDULAR

Paratiroidectomía subtotal
Paratiroidectomía total+AT
Timectomía
Crioconservación

CARCINOMA

Glándula +lóbulo tiroideo homolateral
+ linfadenectomía

HIPERPARATIROIDISMO SECUNDARIO

Normo o hipocalcemia

Hiperfosfatemia

Elev. PTH

Clínica similar + IRC

Mayor afectación ósea

Tratamiento Qx como enf. pluriglandular

