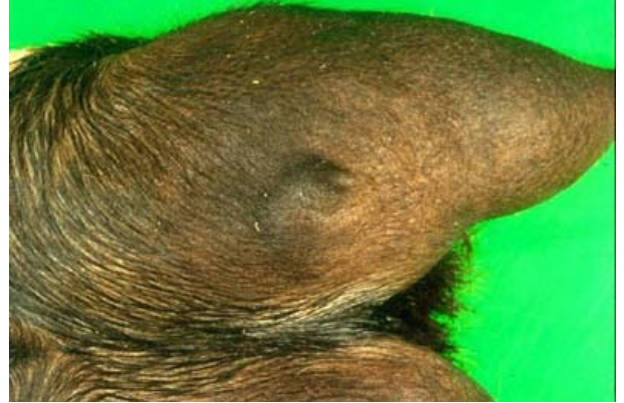

Autor: Juan Seva Alcaraz

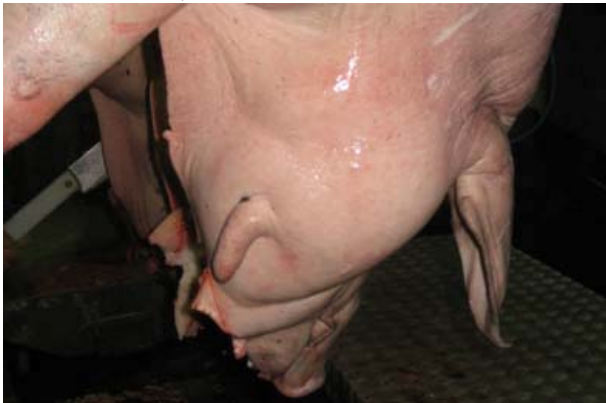Tema 41. Glándula mamaria.



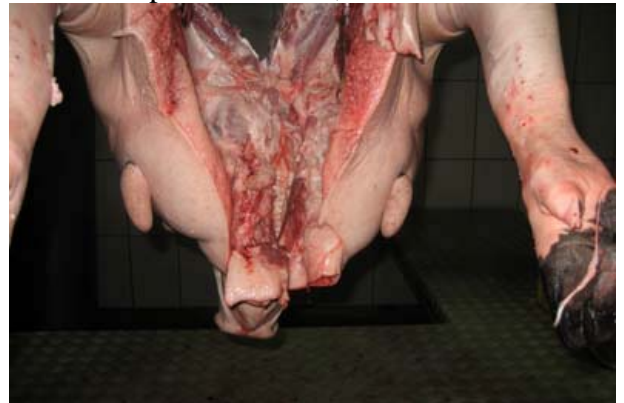Ginecomastia, macho cabrio.



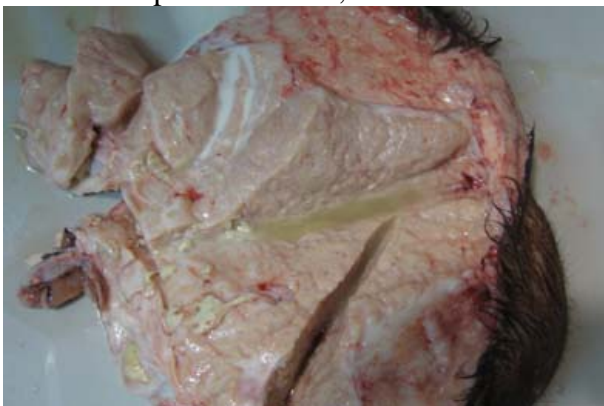Pezones supernumerarios, cabra.



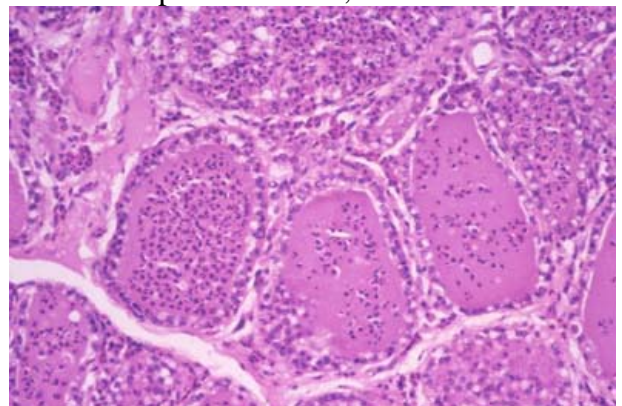
Pezones supernumerarios, cerdo ibérico.



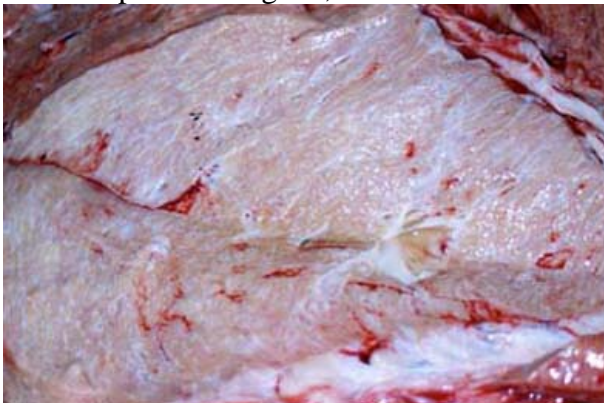Pezones supernumerarios, cerdo ibérico.



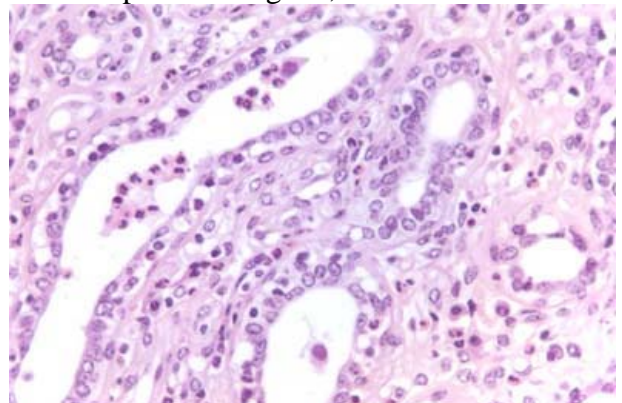
Mamitis purulenta aguda, cabra.



Mamitis purulenta aguda, cabra.

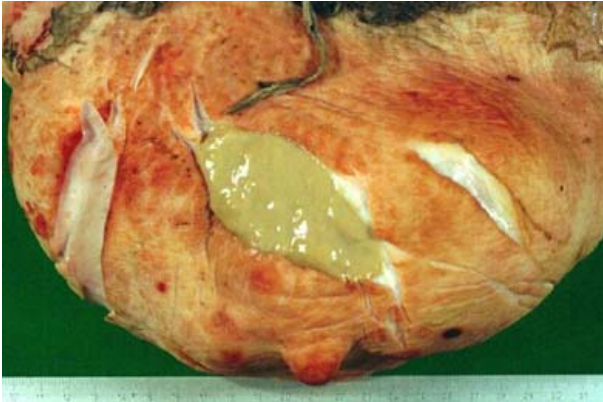


Manitis purulenta crónica, vaca.

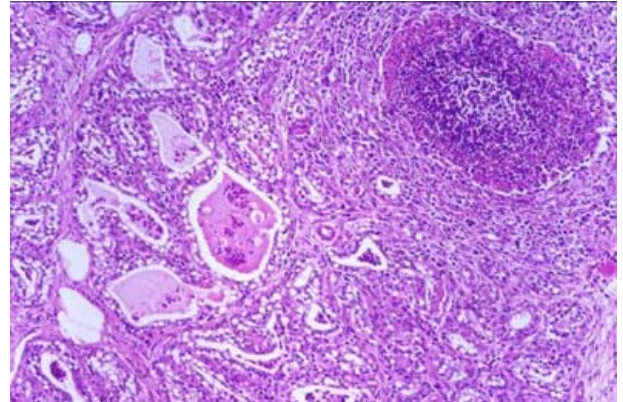


Mamitis purulenta crónica, vaca.

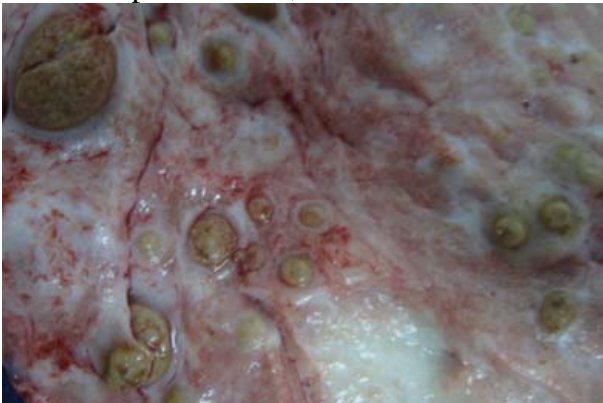Autor: Juan Seva Alcaraz



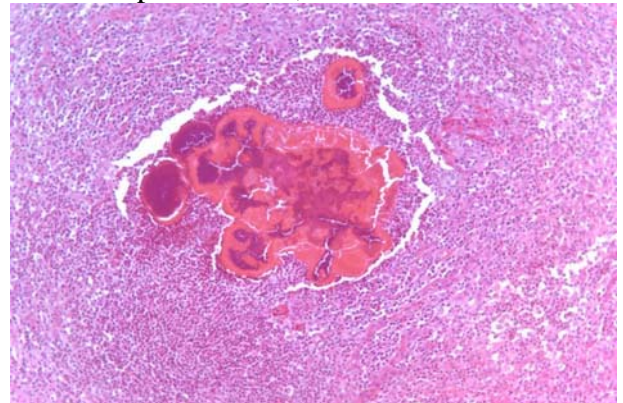
Mamitis apostematosa, cerda.



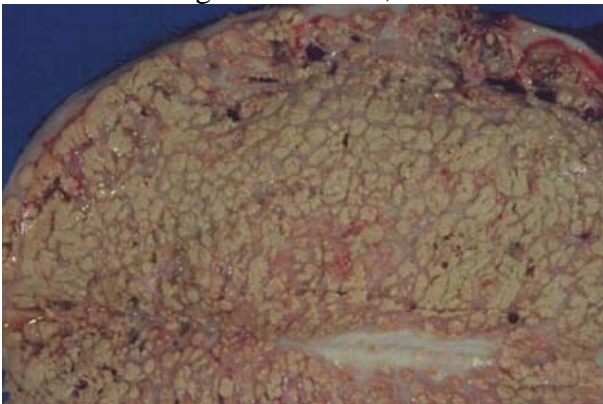
Mamitis apostematosa, cerda.



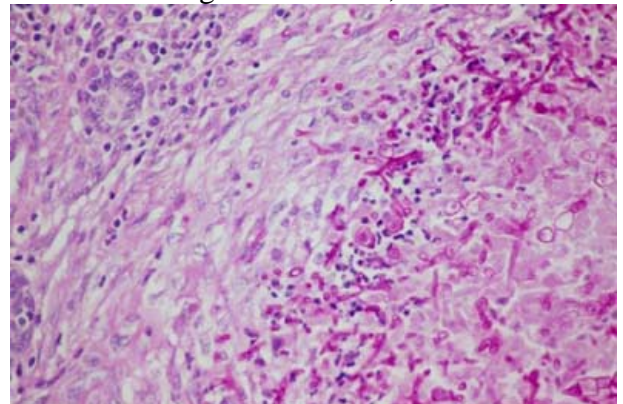
Mamitis actinogranulomatosa, cerda.



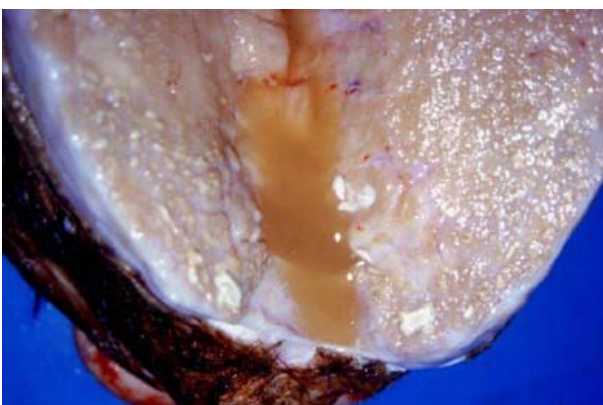
Mamitis actinogranulomatosa, cerda.



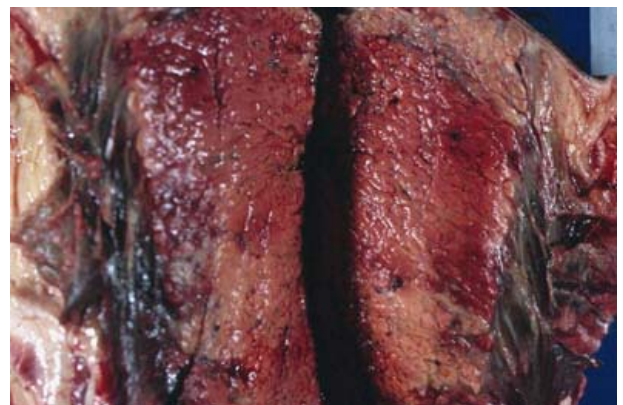Mamitis granulomatosa (micótica), cabra.



Mamitis granulomatosa (micótica), cabra. PAS

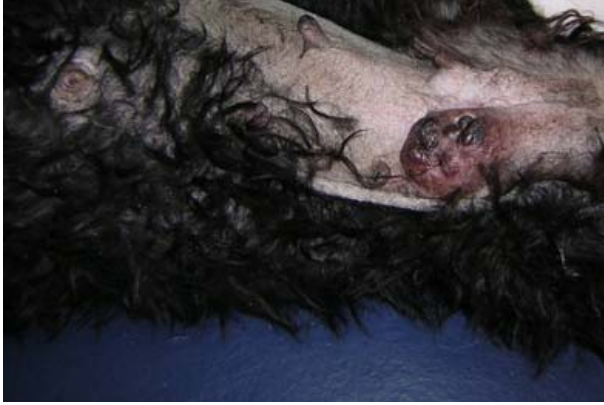

Mamitis granulomatosa (tuberculosa), cabra.

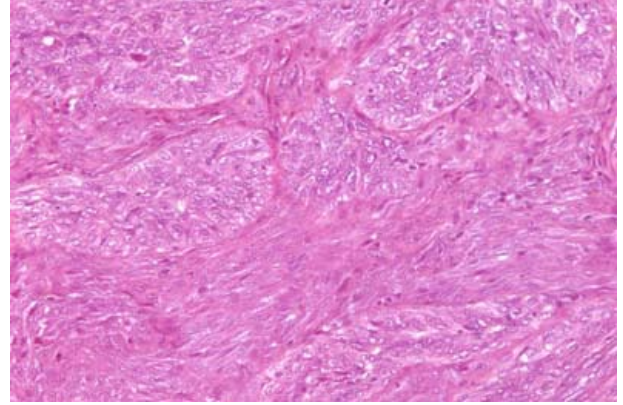


Mamitis necrótico-hemorrágica, cabra.

Autor: Juan Seva Alcaraz



Carcinoma complejo, perra.



Carcinoma complejo, perra.